EUR Research Information Portal

Genetics of congenital heart malformations; clinical and molecular studies

Publication status and date:
Published: 06/05/2009

Document Version
Publisher's PDF, also known as Version of record

Citation for the published version (APA):
Wessels, M. (2009). *Genetics of congenital heart malformations; clinical and molecular studies*. [Doctoral Thesis, Erasmus University Rotterdam]. Erasmus Universiteit Rotterdam (EUR).

Link to publication on the EUR Research Information Portal

Terms and Conditions of Use
Except as permitted by the applicable copyright law, you may not reproduce or make this material available to any third party without the prior written permission from the copyright holder(s). Copyright law allows the following uses of this material without prior permission:

- you may download, save and print a copy of this material for your personal use only;
- you may share the EUR portal link to this material.

In case the material is published with an open access license (e.g. a Creative Commons (CC) license), other uses may be allowed. Please check the terms and conditions of the specific license.

Take-down policy
If you believe that this material infringes your copyright and/or any other intellectual property rights, you may request its removal by contacting us at the following email address: openaccess.library@eur.nl. Please provide us with all the relevant information, including the reasons why you believe any of your rights have been infringed. In case of a legitimate complaint, we will make the material inaccessible and/or remove it from the website.

Erasmus University Rotterdam
Making Minds Matter



Genetics of Congenital Heart Malformations

Clinical and Molecular Studies

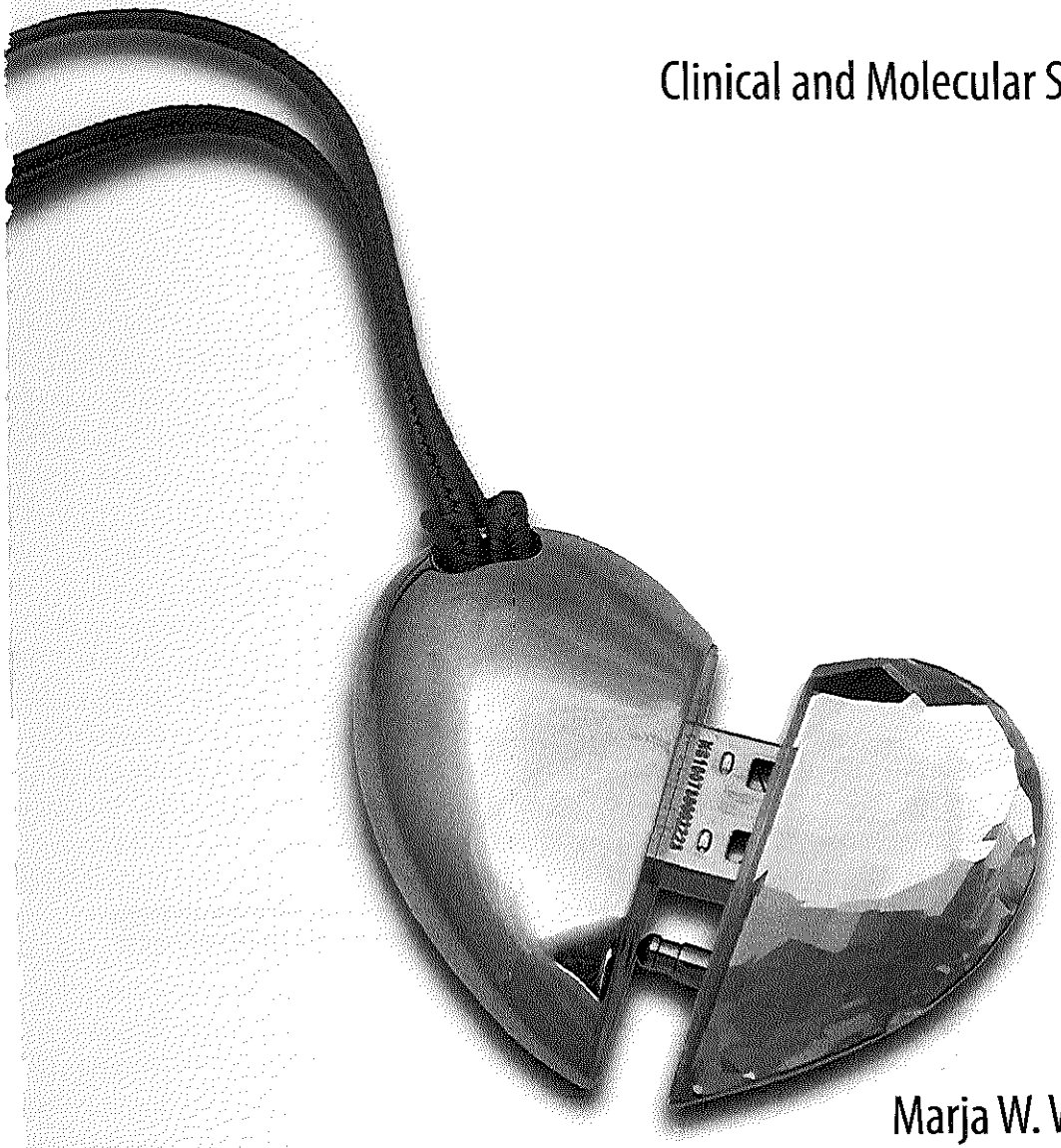

Marja W. Wessels

Publication of this thesis was financially supported by:
GENDIA, Erasmus Medical Center Rotterdam, Department of Clinical Genetics, ErasmusMC



Mixed Sources
Product group from well-managed forests and other controlled sources

Cert no. SGS-COC-004004
www.fsc.org
© 1996 Forest Stewardship Council

© Copyright: Marja Wessels, Rotterdam, 2009
All rights reserved. No part of this thesis may be reproduced in any form or by any means, electronic, mechanical, photocopy, recording or otherwise, without prior permission from the holder of the copyright. The copyrights of the publications remain with the publisher.

ISBN/EAN: 978-90-9024209-5

Photo cover: Ruud Koppenol and Marja Wessels
Lay out, illustrations and graphical assistance: Tom de Vries Lentsch
Drawings: Stijn Wessels
Printed by: Ipskamp Drukkers B.V., Enschede

Genetics of Congenital Heart Malformations

Clinical and Molecular Studies

Genetische aspecten van aangeboren hartafwijkingen

Klinische en moleculaire studies

Proefschrift

ter verkrijging van de graad van doctor
aan de Erasmus Universiteit Rotterdam
op gezag van de rector magnificus
Prof.dr. S.W.J. Lamberts
en volgens besluit van het College voor Promoties.

De openbare verdediging zal plaatsvinden op
woensdag 6 mei 2009 om 13.45 uur door

Maria Wilhelmina Wessels
geboren te Leiden



Promotiecommissie

Promotor: Prof.dr. F. Grosveld

Overige leden: Prof.dr. B.A. Oostra
Prof.dr. W.A. Helbing
Prof.dr. Ing. P. Coucke

A light heart lives longer

From: William Shakespeare in Love's Labour's Lost, quoted in "A matter of the heart", Amy Coombs, Nature Medicine 2008; 14:231

For
my father Prof.dr Jos Wessels, and
my mother Drs Janneke Wessels-Terhal
who both encouraged and inspired me in many ways

Table of Contents

List of abbreviations 8

CHAPTER 1 General introduction

1.1 Introduction 13
1.2 Genetic and environmental factors in non-syndromic congenital heart malformations 27
Submitted
1.3 Aim and outline of the thesis 63

CHAPTER 2 Laterality disorders

2.1 Introduction 67
2.2 Mild fetal cerebral ventriculomegaly as a prenatal sonographic marker for Kartagener syndrome 75
Prenat Diagn 2003; 23: 239-242
2.3 Candidate gene analysis in three families with acilia syndrome 79
Am J Med Genet 2008; 146: 1765-1767
2.4 Polyalanine expansion in the *ZIC3* gene leading to X-linked heterotaxy with VACTERL 83
association, new polyalanine disorder?
J Med Genet 2009; in press

CHAPTER 3 Valvular defects and Left Ventricular Outflow Tract Obstruction (LVOTO)

3.1 Introduction 97
3.2 Autosomal dominant inheritance of left ventricular outflow tract obstruction 103
Am J Med Genet 2005; 134A: 171-17
3.3 Autosomal dominant inheritance of cardiac valves anomalies in two families: expended 113
spectrum of left ventricular outflow tract obstruction
Am J Med Genet 2009; 149A: 216-225

CHAPTER 4 Arterial malformations

4.1 Introduction 127
4.2 Three new families with arterial tortuosity syndrome 139
Am J Med Genet 2004; 131: 134-143

4.3 Homozygosity mapping of a gene for arterial tortuosity syndrome to chromosome 20q13 . . 149
J Med Genet 2003; 40: 747-751
4.4 Mutations in the facilitative glucose transporter GLUT10 alter angiogenesis and cause 155
arterial tortuosity syndrome
Nat Genet 2006; 38: 452-457

CHAPTER 5 Cardiomyopathies with congenital heart malformations

5.1 Introduction 165
5.2 Mutations in sarcomeric protein genes not only lead to cardiomyopathy but also to 171
congenital cardiovascular malformations
Clin Genet 2008; 74:16-19
5.3 A new syndrome with noncompaction cardiomyopathy, bradycardia, pulmonary stenosis, . . 175
atrial septal defect and heterotaxy with suggestive linkage to chromosome 6p
Hum Genet 2008; 122: 595-603
5.4 Compound heterozygosity for truncating mutations in the *MYBPC3* gene causes severe 185
cardiomyopathy with left ventricular noncompaction and septal defects resulting in
neonatal death
Submitted
5.5 Ebstein anomaly can be caused by mutations in the *MYH7* gene encoding the cardiac 199
beta myosin heavy chain
Submitted

CHAPTER 6 General discussion

General discussion 213

Summary 219
Samenvatting 223
Curriculum Vitae 229
PhD Portfolio Summary 230
Publications 232
Dankwoord 239

Abbreviations

AAA	abdominal aortic aneurysm
AF	atrial fibrillation
AI	aortic valve insufficiency
AS	aortic valve stenosis
ASD	atrial septal defect
ATS	arterial tortuosity syndrome
AV	atrioventricular
AVSD	atrioventricular septal defect
BAV	bicuspid aortic valve
CCA	congenital contractural arachnodactyly
CFC	cardio-facio-cutaneous
CHM	congenital heart malformation
CoA	coarctation of the aorta
DCRV	double-chambered right ventricle
DCM	dilated cardiomyopathy
DORV	double outlet right ventricle
EDS	ehlers danlos syndrome
EMT	endothelial-to-mesenchymal transdifferentiation
FHF	first heart field
GWAS	genome wide association studies
HAA	hypoplastic aortic arch
HCM	hypertrophic cardiomyopathy
HLH	hypoplastic left heart
HLHS	hypoplastic left heart syndrome
HLV	hypoplastic left ventricle
HRFC	hepatorenal fibrocystic
HRV	hypoplastic right ventricle
IAA	interrupted aortic arch
IFT	intraflagellar transport
LPM	left plate mesoderm
LR	left-right
LVNC	left ventricular noncompaction
LVOTO	left ventricular outflow tract obstruction
MI	mitral valve insufficiency
MiRNA	microRNA
MV	mitral valve
MS	mitral valve stenosis
MVP	mitral valve prolapse

NCCM	noncompaction cardiomyopathy
PA	pulmonary atresia
PAPVR	partial anomalous pulmonary venous retour
PCD	primary ciliary dyskinesia
PDA	patent ductus arteriosus
PFO	patent foramen ovale
PTA	persistent truncus arteriosus
PS	pulmonary valve stenosis
SD	sudden death
SHF	second heart field
SVAS	supravalvular aortic stenosis
TAA	thoracic aortic aneurysm
TAAD	thoracic aortic aneurysm-dissection
TAPVR	total anomalous pulmonary venous retour
TGA	transposition of the great arteries
TOF	tetralogy of Fallot
VACTERL	vertebral anomalies, cardiac defects, tracheo-esophageal fistula, radial anomalies, limb defects
VSD	ventricular septal defect
XMVD	X-linked myxomatous valvular dystrophy



CHAPTER 1

General introduction

1.1 Introduction

1.1.1 Genetic pathways in cardiac development

1.1.1.1 Transcriptional regulators of cardiac precursors

1.1.1.2 Left-right asymmetry and the nodal signaling pathway

1.1.1.3 Formation of the cardiac outflow tract

1.1.1.4 Valvulogenesis

1.1.2 Syndromic congenital heart malformations

1.1.2.1 Transcription factors in Holt-Oram syndrome and related disorders

1.1.2.2 *TBX1* gene in 22q11.2 deletion syndrome and related disorders

1.1.2.3 RAS-MAPK signaling pathway in Noonan syndrome and related disorders

1.1.2.4 NOTCH signaling pathway in Alagille syndrome and related disorders

1.1.2.5 TGFß signaling pathway in Marfan syndrome and related disorders

1.1.3 Non-syndromic congenital heart malformations

1.1.3.1 Environmental factors

1.1.3.2 Rare variants with high and reduced penetrance

1.1.3.3 Common variants with low penetrance

1.1.3.4 Somatic mutations

1.2 Genetic and environmental factors in non-syndromic congenital heart malformations

Wessels MW, Willems PJ

Submitted

1.3 Aims and outline of this thesis

CHAPTER 1

General introduction

1.1 Introduction

Congenital heart malformations (CHM) are among the most common congenital defects, occurring in 8 out of 1000 live-births [1]. In the past decade significant progress has been made in the identification of genes implicated in the signaling pathways involved in cardiovascular development. A major contribution has come from the study of model systems from fruit fly to mouse. Additionally, multiple disease genes implicated in genetic forms of human CHM have been identified, mainly through positional genetics in multiplex families. Especially human syndromes with CHM ("syndromic" CHM) have been instrumental in the elucidation of these disease genes, but recently also a number of disease genes implicated in "non-syndromic" CHM have been identified.
In this chapter the most important forms of syndromic CHM with the different signaling pathways involved, and the genetic and environmental factors contributing to non-syndromic CHM are summarized. Several recent reviews have addressed the progress in the identification of these genes and pathways [2-9].

1.1.1 Genetic pathways in cardiac development

1.1.1.1 Transcriptional regulators of cardiac precursors

Heart development starts in early gestation when a crescent of mesodermal tissue originating from the anterior lateral plate commits to the cardiac lineages, and differentiates into two pools of progenitors known as the first heart field (FHF) and the second heart field (SHF) (see Figure 1 from ref [10]). FHF cardiomyocyte progenitors arise from the splanchnic mesoderm and are mainly involved in formation of the heart tube and left ventricle. The right ventricle and outflow tract are derived from the SHF progenitors, originating from the pharyngeal mesoderm [11,12]. Both the development of the FHF and SHF appear to be regulated by complex signaling networks involving members of the bone morphogenetic proteins (Bmp), sonic hedgehog (Shh), fibroblast growth factor (Fgf), Wnt, and Notch proteins [2,10,13,14]. A core set of evolutionary conserved transcription factors and regulators (Nkx, Mef2, Gata, Tbx and Hand families) controls heart development from early on by determining cardiac cell fate and expression of cardiac effector genes. These encode contractile proteins such as sarcomeric proteins and other

unknown target genes regulating morphogenesis [13] (Figure 1 from ref [10]). Many of these transcription factors and regulators, including Nkx2-5 and Gata4, operate in both the FHF and the SHF, whereas others are preferentially expressed in one of these two fields: Hand1 and Tbx5 in the FHF, and Isl1, Tbx1, Foxh1 and Fgf in the SHF [15]. Two important upstream regulators in the SHF are Isl1, a LIM-homeodomain transcription factor, and Foxh1. Several studies have indicated that Isl1 expression defines a multipotent cardiovascular SHF progenitor that can differentiate into specific mature cardiac, pacemaker, smooth muscle, and endothelial cell types [16,17]. Both Isl1 and Foxh1 are required for the proliferation and survival of SHF cells and the regulation of many other transcription factors and signaling pathways [13,18]. Isl1 regulates Mef2 expression, a myogenic transcription factor that is known to be associated with differentiation of all muscle types. Foxh1 interacts with Mef2c and is required for right chamber formation [19]. GATA factors and Nkx2.5 are essential for Mef2c expression in the SHF. The latter interacts with Hand2, and is required for proper development of the right ventricle [20]. Another important cardiac transcription factor is Tbx20, which controls expansion of FHF- and SHF-derived cells and outflow tract development, possibly by regulating Nkx2.5 and Mef2c [21]. Also several microRNAs (miRNAs) functioning as negative regulators of target RNAs, are expressed in the developing heart, including MiR1-1, MiR1-2, MiR133a-1 and MiR133a-2. These noncoding RNAs play a role in "fine-tuning" the amount of key proteins during cardiogenesis [10].

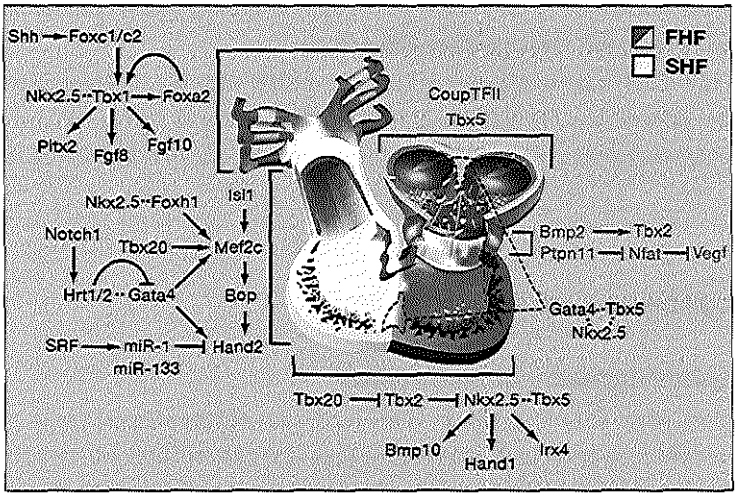

Figure 1 | Pathways regulating cardiac morphogenesis.
Transcription factors, signaling proteins, and miRNAs that play a role in different regions of the developing heart are shown. Positive effects are indicated by arrowheads, and negative effects by bars. Physical interactions are indicated by dashed lines. The FHF is the dark and medium gray area of the atria and left ventricle. The SHF is the white area. The conotruncus is also partly in gray: this represents the area where the cardiac neural crest cells migrate into the outflow tract from the neural folds to septate the outflow tract and pattern the bilaterally symmetric aortic arch arteries (III, IV, and VI)). From ref [10] with permission from Dr. Deepak Srivastava.

1.1.1.2 Left-right asymmetry and the NODAL signaling pathway

The molecular network regulating left-right (LR) asymmetry of the body plan has been studied extensively, and more than 80 genes involved in this process have been identified [22-28]. The NODAL signaling pathway is essential in LR patterning. Four essential proteins in this pathway are the highly conserved proteins Nodal, Lefty1, Lefty2 and Pitx2, which are all expressed asymmetrically near the midline or in the left lateral plate mesoderm at comparable developmental stages [5,28]. Both the Nodal and the sonic hedgehog (Shh) signaling pathways converge on the transcription factor Pitx2. Pitx2 is initially expressed asymmetrically along the LR axis in the linear heart tube, but this asymmetry translates into a dorsal-ventral polarity in the looped heart tube. The precise downstream cardiac targets of the NODAL signaling pathway remain unknown. The NODAL signaling pathway and related CHMs are further described in paragraph 1.1.2.4 of this Chapter and in Chapter 2.

1.1.1.3 Formation of the cardiac outflow tract

Following rightward looping of the heart tube, cardiac neural crest cells migrate into the outflow tract to septate the outflow tract and pattern the bilaterally symmetric aortic arch arteries [29]. Second heart field derived myocardial cells interact with these neural crest cells via Tbx1-dependent secretion of growth factors such as Fgf8 [30].

1.1.1.4 Valvulogenesis

Signal transduction pathways including Wnt/β - Catenin, Vegf, Notch, Bmp - Tgfβ, and Erb, and transcription factors including different Gata, Fox and Sox transcription factors have all been implicated in heart cushion and valve formation in mice. These different signaling pathways exhibit extensive cross-talking, resulting in a complex integrated process of cardiac valve morphogenesis (for review: see ref [31,32]). Genetic pathways implicated in cardiac valve formation and human CHM with cardiac valve defects are further described in Chapter 3.

1.1.2 Syndromic congenital heart malformations

CHM occur in many human syndromes, which reflect the multitude of genes involved in cardiovascular development. Such syndromes might be due to chromosomal imbalances. Genomic deletions detectable by conventional cytogenetics are found in approximately 13% of children with CHM, and include trisomy 21, 13 and 18, Turner syndrome and Cri-du-Chat (5p-) syndrome [33,34]. Submicroscopic deletions, including 22q11.2 deletion syndrome, Williams syndrome (7q11.23 deletion), Smith Magenis syndrome (17p11.2 deletion) and Wolf-Hirschhorn syndrome (4p- deletion) comprise a considerable subgroup of syndromic CHM. Recent CGH array studies demonstrate a high frequency of chromosomal imbalances in syndromic CHM [35], and a lower frequency in non-syndromic CHM [36].

Positional genetics studies in humans have led to the identification of many disease genes that are implicated in monogenic forms of syndromic CHM. Here we only review the more frequent syndromes that led to the discovery of different pathways involved in cardiovascular development.

1.1.2.1 Transcription factors in Holt-Oram syndrome and related disorders

The first identified single gene mutation associated with inherited CHM was identified in the T-box transcription fator *TBX5* gene, and was shown to cause Holt-Oram syndrome [37,38]. Individuals with Holt-Oram syndrome display great phenotypic variability with mild to severe limb defects, and various types of CHM, including atrial septal defect (ASD), ventricular septal defect (VSD), tetralogy of Fallot (TOF) and atrioventricular conduction defects [37,38]. Truncating mutations cause substantial cardiac and limb defects, whereas missense mutations lead to either more prominent heart or more severe limb defects depending on the specific gene domains affected [39]. Soon after the discovery of *TBX5* mutations in Holt-Oram syndrome, mutations in another transcription factor gene *NKX2.5* (*NKX2E*) were discovered in families with inherited ASD and atrioventricular block [40]. Murine models have shown that Tbx5 and the homeobox transcription factor Nkx2.5 interact physically and synergistically to induce downstream targets [41,42]. Tbx5 and Nkx2.5 both interact with the zinc finger transcription factor Gata4, and in humans *GATA4* mutations lead to non-syndromic CHM, including septal defects, PS and TOF. This transcriptional network was further extended by the identification of the Sall4 gene whose gene product has been shown to interact with Tbx5 in a mouse model [43]. In humans the *SALL4* gene is implicated in Okihiro syndrome, a malformation syndrome with cardiac septal defects and radial ray defects clinically overlapping Holt-Oram syndrome [44-46]. Recently, mutations in the T-box DNA-binding domain of *TBX20* were implicated in cardiomyopathy and septal defects in humans [47]. Murine Tbx20 also interacts with the Nkx2.5-Gata4-Tbx5-Sall4 complex [48,49]. Patients with mutations in all these transcription factor genes mainly show septal defects, providing further evidence this transcriptional network is essential for septal development. Other transcription factor genes that interact with this network, such as *ISL1*, *TBX2*, *GATA5*, *HAND2*, *MEF2c*, as well as downstream targets might be additional functional candidate genes for human CHM [19,48,50,51].

1.1.2.2 *TBX1* gene in 22q11.2 deletion syndrome and related disorders

The 22q11.2 deletion syndrome is one of the most common human microdeletion syndromes with an estimated prevalence of one in 4000 live births [52]. CHM in this syndrome include outflow tract anomalies such as interruption of the aortic arch (IAA), persistent truncus arteriosus (PTA), transposition of the great arteries (TGA), Tetralogy of Fallot (TOF), and double outlet right ventricle (DORV) [53]. Disruption of one or two copies of the Tbx1 gene in mice results in heart defects similar to those seen in 22q11.2 deletion patients [54,55], providing evidence that *TBX1* haploinsufficiency is the cause of the cardiac defects seen in 22q11.2 deletion patients. Subsequently, human *TBX1* mutations were demonstrated to cause non-syndromic CHM including VSD and IAA [56,57], and also most of the anomalies seen in the 22q11.2 microdeletion patients [58-60].

TBX1 is needed for the proliferation of SHF cells before they differentiate into cardiomyocytes, and interaction of SHF cells with neural crest cells that migrated into the outflow tract. Tbx1 is a direct target of Foxc1 and Foxc2, two closely related Fox transcription factors [61,62]. Mutations in the human *FOXC2* gene cause Lymphoedema-distichiasis syndrome, which is associated with CHM, including abnormalities of the outflow tract such as TOF, in 6 % of patients [63]. Murine *Tbx1* expression regulates the proliferation

of the splanchnic mesoderm and the expression of *Fgf8*. *Fgf8* mutations in mice result in CHM similar to those with neural crest interruption, including PTA, DORV, and VSD [64]. Also mutations in other signaling pathways affecting neural crest cell migration, including the endothelin and semaphoring pathways, cause outflow tract anomalies (for review: see ref [29]).

1.1.2.3 RAS-MAPK signaling pathway in Noonan syndrome and related disorders

Noonan syndrome, LEOPARD syndrome, Cardio-facio-cutaneous (CFC) syndrome and Costello syndrome are clinically and genetically heterogeneous conditions with overlapping clinical features, including dysmorphic features, short stature, and cardiac defects such as hypertrophic cardiomyopathy (HCM) and pulmonary valve stenosis (PS) [65,66]. Molecular studies of these syndromes have revealed a signaling pathway referred to as the RAS-MAPK signaling pathway, which includes the *PTPN11*, *SOS1*, *KRAS1*, *RAF1*, *BRAF* , *MEK1* and *MEK2* genes. Mutations in all of these genes can lead to cardiomyocte hypertrophy and pulmonary valve anomalies, predominantly by increased signaling leading to suppression of calcineuric/NFAT transcriptional activity [67,68].

Noonan syndrome is an autosomal dominant condition caused by mutations in *PTPN11* in approximately 50% of patients [69]. In a minority of patients with Noonan syndrome, mutations have been found in the *SOS1 (17-28%)* [70,71], *KRAS (2%)* [72,73] or *RAF1 (3-17%)* [74,75] genes. Mutations in SOS1 are associated with a milder phenotype characterized by normal stature and absence of cognitive deficits. Mutations in *KRAS* [72,73] on the other hand may lead to a more severe phenotype resembling CFC syndrome.

LEOPARD syndrome (Lentigines, ECG abnormalities, Ocular Hypertelorism, Pulmonary valve stenosis, Abnormalities of the genitalia, Retardation of growth, Deafness) shares several clinical features with Noonan syndrome, including facial dysmorphism, short stature and CHM, but is characterized by pigmentary abnormalities such as lentigines as seen in Neurofibromatosis type 1 patients. LEOPARD syndrome is caused by heterozygous mutations in *PTPN11* in 90% of cases and *RAF1* mutations in a minority of cases (3%) [76,77]. The Leopard syndrome-associated *PTPN11* mutations are distinct from *PTPN11* mutations found in Noonan syndrome: Leopard mutations lead to dominant-negative effects that disrupt the growth factor activity of Ras effectors, whereas Noonan mutations are gain-of-function mutations that lead to enhanced phosphatase activity, resulting in activation of the RAS-MAPK pathway [78].

Cardio-facio-cutaneous (CFC) syndrome is caused by an autosomal dominant mutation in the *BRAF* (37-78%), *KRAS* (5%), *MEK1* or *MEK2* (10-15%) genes encoding additional proteins in the same RAS-MAPK pathway [79-81]. Although the clinical features of CFC syndrome overlap with Noonan and Costello syndrome, skin disease (eczema, hemangioma, hyperkeratosis and keratosis pilaris), mental retardation, seizures and optic nerve hypoplasia may be key features to discriminate CFC syndrome from Noonan syndrome or Costello syndrome [82].

Costello syndrome phenotypically overlaps with Noonan syndrome and CFC syndrome, and is characterized by failure to thrive, cognitive impairment, tumor predisposition, loose skin, nasal papillomata, and cardiac anomalies including HCM and atrial tachycardia [83,84]. Costello syndrome is caused by heterozygous mutations in the *HRAS* gene in over 80% of patients [80,84-86].

The main CHM seen in individuals with Noonan syndrome, LEOPARD syndrome, CFC syndrome, and

Costello syndrome are PS and HCM, but also VSD and TOF can be found. PS is less frequent in Costello syndrome than in the other 3 syndromes. *RAF1* mutations in Noonan syndrome and LEOPARD syndrome lead to HCM in many cases [74,75,87]. Arrhythmias are observed in over 30% of patients with Costello syndrome [88], and might be a discriminating cardiac feature with Noonan and CFC syndrome, as cardiac rhythm abnormalities are infrequent in the latter 2 syndromes [82]. CHM seem to be less frequent in CFC patients with a *MEK1* or *MEK2* mutation [81].
Although there is an unconfirmed suggestion that *PTPN11* mutations may play a role in non-syndromic PS, mutations in the RAS-MAPK pathway have not been convincingly found to cause non-syndromic CHM [89,90].

1.1.2.4 NOTCH signaling pathway in Alagille syndrome and related disorders

Alagille syndrome is an autosomal dominant disorder characterized by liver disease, vertebral anomalies, dysmorphic features, and various types of CHM. CHMs include PS, TOF and peripheral pulmonary arterial stenosis. In approximately 90% of patients a mutation is found in the *JAG1* gene encoding Jagged1 [91-93]. Jagged1 is a member of the NOTCH signaling pathway and is expressed in a specific population of endocardial cells of the outflow tract that undergo epithelial to mesenchymal transformation. *JAG1* mutations have also been found in patients with non-syndromic forms of TOF with PS, pulmonary atresia and absent pulmonary valve [94,95].
NOTCH signaling is dependent on the interaction between Notch ligands (delta-like 1,3,4 and Jagged1,2) and receptors (Notch 1-4) enabling the transduction of signals between neighbouring cells. The NOTCH signaling pathway is involved in many steps in both vascular and cardiac development, including cardiomyocyte differentiation, boundary formation of the atrioventricular canal, valve development, ventricular trabeculation, and outflow tract remodeling [8,96]. Not surprisingly, mutations in other components of this pathway also lead to CHM. *NOTCH2* mutations have been found in a minority of patients with Alagille syndrome with renal disease representing a differentiating feature between patients with *JAG1* and *NOTCH2* mutations [97]. *NOTCH1* mutations have been identified in individuals with bicuspid aortic valve (BAV) and aortic valve stenosis (AS) although the CHM spectrum included also mitral atresia, hypoplastic left heart (HLH) and DORV [98].

1.1.2.5 TGFß signaling pathway in Marfan syndrome and related disorders

Aortic aneurysms represent a common vascular malformation with life-threatening implications. Aortic aneurysm can be part of syndromes including Marfan syndrome (*FBN1* gene) [99-101], Loeys-Dietz syndromes (*TGFBR1/2* genes) [102-104], Ehlers-Danlos syndromes (*COL3A1* gene and *FLNA* gene) [105,106] and arterial tortuosity syndrome (*SLC2A10* gene) [107,108]. Upregulation of the TGFβ signaling pathway plays a central role in the pathogenesis of Marfan syndrome, Loeys-Dietz syndrome and arterial tortuosity syndrome (ATS), making this pathway the primary pharmacological target for the development of new treatment strategies for arterial wall disorders. In transgenic mouse models Losartan, an angiotensin II type 1 receptor, inhibits TGFβ signaling and results in a rescue of the aortic pathology [109]. Although the

results of human trials with Losartan have to be awaited, a preliminary report suggests that Losartan therapy will benefit young patients with severe Marfan syndrome [110].
Non-syndromic aortic aneurysms can be due to mutations in sarcomeric protein genes such as the *MYH11* gene encoding the smooth muscle cell myosin heavy chain [111] and the *ACTA2* gene encoding smooth muscle cell α-actin [112]. It is currently not known whether TGFβ signaling is increased in patients with mutations in these sarcomeric protein genes, but interaction between the TGFβ pathway and sarcomeric protein genes has been reported [113].

1.1.3 Non-syndromic congenital heart malformations

The majority of CHM with monogenic inheritance is associated with other malformations and constitutes syndromic forms of CHM. In contrast, most cases of non-syndromic CHM occur sporadically. Families with clear monogenic inheritance of non-syndromic CHM are scarce, thereby impairing the identification of disease genes involved in non-syndromic CHM by a classical positional genetics approach. The low percentage of single gene mutations with high penetrance argues against a prominent role of these mutations in sporadic cases of CHM. However, only a limited number of human genes involved in cardiogenesis are currently known. Taken into account the large number of genes that play a role in murine cardiogenesis, many human genes are expected be identified within the coming years. Next-generation sequencing most likely will play an important role in identifying these genes.
Overall, the recurrence risk of non-syndromic CHM (defined as the risk of a child with CHM after a previous child with CHM) is usually in the order of 2-10 %. The traditional hypothesis to explain this relatively low non-Mendelian recurrence risk suggests that the majority of sporadic cases with non-syndromic CHM are due to multifactorial inheritance involving a multitude of susceptibility genes with reduced-penetrance mutations superposed on unfavorable environmental factors. The different environmental factors, disease genes with monogenic mutations, susceptibility genes with reduced-penetrance mutations and somatic mutations implicated in the development of non-syndromic congenital heart malformation are reviewed extensively in Chapter 1.2 [114] and are briefly discussed below.

1.1.3.1 Environmental factors

The environmental factors inducing CHM include mainly maternal embryotoxic factors, including maternal diabetes, hyperphenylalaninemia, hyperhomocysteinemia, medication, alcohol abuse, exposure to solvents, and nutrient deficiencies [115].
Also a few paternal risk factors have been reported, including cannabis and cocaine use and exposure to organic solvents.

1.1.3.2 Rare variants with high and reduced penetrance

The fetal developmental program of the heart involves many signaling pathways with ligands-receptor interactions, secondary signal transduction pathways and transcription factors that determine the ex-

pression of cardio-specific genes. Significant ligand-receptor promiscuity and cross-talking between the different signal transduction pathways exists. Germline mutations contributing to non-syndromic CHM have been identified in a multitude of genes belonging to these pathways, including genes encoding ligands (*NODAL, LEFTY1, GDF1, JAG1*), receptors (*CFC1, TDGF1, ACVR2, NOTCH1*), transcriptional regulators (*CITED2, FOG2, MYOCD*), transcription factors (*ZIC3, NKX2.5, TBX1/5/20, GATA4, FOXH1*), and down stream targets (*ACTC1, MYH6*). However, in only a minority of patients with non-syndromic CHM a mutation can be identified (for reviews: see refs [2-9,114,116]). In most CHM genes both high- and reduced-penetrance mutations have been identified. The high-penetrance mutations result in pedigrees with clear autosomal dominant inheritance. The reduced-penetrance mutations are not only found in the patients with CHM, but can also be present in asymptomatic first-degree relatives, resulting in pedigrees with a non-Mendelian inheritance pattern. Determination of the degree of penetrance of such mutations is very difficult, as it requires a combination of DNA analysis and careful cardiologic examination in many family members.

1.1.3.3 Common variants with low penetrance

A number of susceptibility genes with common variants with low penetrance of CHM have been identified, usually by association studies. Most of these genes, including the *MTHFR, MTHFD1, MTRR, TCN2, SLC19A1*, and *NNMT* genes, are involved in the methylation cycle through the conversion of homocysteine into methionine. Some of these studies have not been replicated or have provided contradictory results. Other susceptibility genes including the *NPPA* gene encoding atrial natriuretic peptide (ANP) [117], the *NOS3* gene encoding endothelial nitric oxide synthase (eNOS) [118], the *VEGF* gene encoding vascular endothelial growth factor [119,120], and the *NFATC1* gene encoding a calcineurin-dependent transcription factor [121] have been described, but the exact functional significance of these remains unclear. Genome-wide association studies (GWAS) have not yet been reported in CHM.

1.1.3.4 Somatic mutations

Somatic mutations not present in the germline may also contribute to non-syndromic CHM. This might explain why the candidate gene approach for non-syndromic CHM usually performed in constitutional DNA derived from blood has had little success. Many years after Knudson's theory about somatic mutations gained universal acceptance, this concept remains largely confined to tumor biology. Only recently somatic mutations confined to affected cardiovascular tissue have been reported in CHM. The group of Reamon-Buettner and Borlak [122-127] has reported the majority of somatic mutations in CHM, including mutations in the cardiac transcription factors *NKX2.5, TBX5, GATA4, HEY2* and lately *HAND1*. The abundance of somatic mutations reported by this group contrasts with the limited number of mutations in other studies: no *NKX2.5* gene mutations were found in cardiac tissue from patients with BAV and associated aortic aneurysm [128], and no somatic 22q11.2 deletions could be identified in heart tissue from patients with conotruncal heart defects without germ line 22q11.2 deletion [129]. Therefore, the concept of somatic mutations in the heart leading to CHM awaits further confirmation.

References

1. Hoffman JI, Kaplan S. 2002. The incidence of congenital heart disease. J Am Coll Cardiol 39:1890-1900.
2. Bruneau BG. 2008. The developmental genetics of congenital heart disease. Nature 451:943-948.
3. Ransom J, Srivastava D. 2007. The genetics of cardiac birth defects. Semin Cell Dev Biol 18:132-139.
4. Weismann CG, Gelb BD. 2007. The genetics of congenital heart disease: a review of recent developments. Curr Opin Cardiol 22:200-206.
5. Zhu L, Belmont JW, Ware SM. 2006. Genetics of human heterotaxias. Eur J Hum Genet 14:17-25.
6. Garg V. 2006. Molecular genetics of aortic valve disease. Curr Opin Cardiol 21:180-184.
7. Piacentini G, Digilio MC, Sarkozy A, Placidi S, Dallapiccola B, Marino B. 2007. Genetics of congenital heart diseases in syndromic and non-syndromic patients: new advances and clinical implications. J Cardiovasc Med (Hagerstown) 8:7-11.
8. High FA, Epstein JA. 2008. The multifaceted role of Notch in cardiac development and disease. Nat Rev Genet 9:49-61.
9. Andelfinger G. 2008. Genetic factors in congenital heart malformation. Clin Genet 73:516-527.
10. Srivastava D. 2006. Making or breaking the heart: from lineage determination to morphogenesis. Cell 126:1037-1048.
11. Waldo KL, Kumiski DH, Wallis KT, Stadt HA, Hutson MR, Platt DH, Kirby ML. 2001. Conotruncal myocardium arises from a secondary heart field. Development 128:3179-3188.
12. Mjaatvedt CH, Nakaoka T, Moreno-Rodriguez R, Norris RA, Kern MJ, Eisenberg CA, Turner D, Markwald RR. 2001. The outflow tract of the heart is recruited from a novel heart-forming field. Dev Biol 238:97-109.
13. Olson EN. 2006. Gene regulatory networks in the evolution and development of the heart. Science 313:1922-1927.
14. Hyun C, Lavulo L. 2006. Congenital heart diseases in small animals: part I. Genetic pathways and potential candidate genes. Vet J 171:245-255.
15. Zeisberg EM, Ma Q, Juraszek AL, Moses K, Schwartz RJ, Izumo S, Pu WT. 2005. Morphogenesis of the right ventricle requires myocardial expression of Gata4. J Clin Invest 115:1522-1531.
16. Kattman SJ, Huber TL, Keller GM. 2006. Multipotent flk-1+ cardiovascular progenitor cells give rise to the cardiomyocyte, endothelial, and vascular smooth muscle lineages. Dev Cell 11:723-732.
17. Moretti A, Caron L, Nakano A, Lam JT, Bernshausen A, Chen Y, Qyang Y, Bu L, Sasaki M, Martin-Puig S, Sun Y, Evans SM, Laugwitz KL, Chien KR. 2006. Multipotent embryonic isl1+ progenitor cells lead to cardiac, smooth muscle, and endothelial cell diversification. Cell 127:1151-1165.
18. Lin L, Bu L, Cai CL, Zhang X, Evans S. 2006. Isl1 is upstream of sonic hedgehog in a pathway required for cardiac morphogenesis. Dev Biol 295:756-763.
19. von Both I, Silvestri C, Erdemir T, Lickert H, Walls JR, Henkelman RM, Rossant J, Harvey RP, Attisano L, Wrana JL. 2004. Foxh1 is essential for development of the anterior heart field. Dev Cell 7:331-345.
20. Srivastava D, Thomas T, Lin Q, Kirby ML, Brown D, Olson EN. 1997. Regulation of cardiac mesodermal and neural crest development by the bHLH transcription factor, dHAND. Nat Genet 16:154-160.
21. Takeuchi JK, Mileikovskaia M, Koshiba-Takeuchi K, Heidt AB, Mori AD, Arruda EP, Gertsenstein M, Georges R, Davidson L, Mo R, Hui CC, Henkelman RM, Nemer M, Black BL, Nagy A, Bruneau BG. 2005. Tbx20 dose-dependently regulates transcription factor networks required for mouse heart and motoneuron development. Development 132:2463-2474.
22. Yost HJ. 2003. Left-right asymmetry: nodal cilia make and catch a wave. Curr Biol 13:R808-809.
23. Yost HJ. 2001. Establishment of left-right asymmetry. Int Rev Cytol 203:357-381.
24. Mercola M. 1999. Embryological basis for cardiac left-right asymmetry. Semin Cell Dev Biol 10:109-116.
25. Mercola M. 2003. Left-right asymmetry: nodal points. J Cell Sci 116:3251-3257.
26. Boorman CJ, Shimeld SM. 2002. The evolution of left-right asymmetry in chordates. Bioessays 24:1004-1011.
27. Bisgrove BW, Yost HJ. 2006. The roles of cilia in developmental disorders and disease. Development 133:4131-4143.
28. Palmer AR. 2004. Symmetry breaking and the evolution of development. Science 306:828-833.
29. Stoller JZ, Epstein JA. 2005. Cardiac neural crest. Semin Cell Dev Biol 16:704-715.
30. Hu T, Yamagishi H, Maeda J, McAnally J, Yamagishi C, Srivastava D. 2004. Tbx1 regulates fibroblast growth factors in the anterior heart field through a reinforcing autoregulatory loop involving forkhead transcription factors. Development 131:5491-5502.
31. Armstrong EJ, Bischoff J. 2004. Heart valve development: endothelial cell signaling and differentiation. Circ Res 95:459-470.
32. Schroeder JA, Jackson LF, Lee DC, Camenisch TD. 2003. Form and function of developing heart valves: coordination by extracellular matrix and growth factor signaling. J Mol Med 81:392-403.

33. Ferencz C, Boughman JA, Neill CA, Brenner JI, Perry LW. 1989. Congenital cardiovascular malformations: questions on inheritance. Baltimore-Washington Infant Study Group. J Am Coll Cardiol 14:756-763.
34. Ferencz C, Neill CA, Boughman JA, Rubin JD, Brenner JI, Perry LW. 1989. Congenital cardiovascular malformations associated with chromosome abnormalities: an epidemiologic study. J Pediatr 114:79-86.
35. Thienpont B, Mertens L, de Ravel T, Eyskens B, Boshoff D, Maas N, Fryns JP, Gewillig M, Vermeesch JR, Devriendt K. 2007. Submicroscopic chromosomal imbalances detected by array-CGH are a frequent cause of congenital heart defects in selected patients. Eur Heart J 28:2778-2784.
36. Erdogan F, Larsen LA, Zhang L, Tumer Z, Tommerup N, Chen W, Jacobsen JR, Schubert M, Jurkatis J, Tzschach A, Ropers HH, Ullmann R. 2008. High frequency of submicroscopic genomic aberrations detected by tiling path array comparative genome hybridisation in patients with isolated congenital heart disease. J Med Genet 45:704-709.
37. Basson CT, Bachinsky DR, Lin RC, Levi T, Elkins JA, Soults J, Grayzel D, Kroumpouzou E, Traill TA, Leblanc-Straceski J, Renault B, Kucherlapati R, Seidman JG, Seidman CE. 1997. Mutations in human TBX5 [corrected] cause limb and cardiac malformation in Holt-Oram syndrome. Nat Genet 15:30-35.
38. Li QY, Newbury-Ecob RA, Terrett JA, Wilson DI, Curtis AR, Yi CH, Gebuhr T, Bullen PJ, Robson SC, Strachan T, Bonnet D, Lyonnet S, Young ID, Raeburn JA, Buckler AJ, Law DJ, Brook JD. 1997. Holt-Oram syndrome is caused by mutations in TBX5, a member of the Brachyury (T) gene family. Nat Genet 15:21-29.
39. Basson CT, Huang T, Lin RC, Bachinsky DR, Weremowicz S, Vaglio A, Bruzzone R, Quadrelli R, Lerone M, Romeo G, Silengo M, Pereira A, Krieger J, Mesquita SF, Kamisago M, Morton CC, Pierpont ME, Muller CW, Seidman JG, Seidman CE. 1999. Different TBX5 interactions in heart and limb defined by Holt-Oram syndrome mutations. Proc Natl Acad Sci U S A 96:2919-2924.
40. Schott JJ, Benson DW, Basson CT, Pease W, Silberbach GM, Moak JP, Maron BJ, Seidman CE, Seidman JG. 1998. Congenital heart disease caused by mutations in the transcription factor NKX2-5. Science 281:108-111.
41. Hiroi Y, Kudoh S, Monzen K, Ikeda Y, Yazaki Y, Nagai R, Komuro I. 2001. Tbx5 associates with Nkx2-5 and synergistically promotes cardiomyocyte differentiation. Nat Genet 28:276-280.
42. Bruneau BG, Nemer G, Schmitt JP, Charron F, Robitaille L, Caron S, Conner DA, Gessler M, Nemer M, Seidman CE, Seidman JG. 2001. A murine model of Holt-Oram syndrome defines roles of the T-box transcription factor Tbx5 in cardiogenesis and disease. Cell 106:709-721.
43. Koshiba-Takeuchi K, Takeuchi JK, Arruda EP, Kathiriya IS, Mo R, Hui CC, Srivastava D, Bruneau BG. 2006. Cooperative and antagonistic interactions between Sall4 and Tbx5 pattern the mouse limb and heart. Nat Genet 38:175-183.
44. Al-Baradie R, Yamada K, St Hilaire C, Chan WM, Andrews C, McIntosh N, Nakano M, Martonyi EJ, Raymond WR, Okumura S, Okihiro MM, Engle EC. 2002. Duane radial ray syndrome (Okihiro syndrome) maps to 20q13 and results from mutations in SALL4, a new member of the SAL family. Am J Hum Genet 71:1195-1199.
45. Kohlhase J, Heinrich M, Schubert L, Liebers M, Kispert A, Laccone F, Turnpenny P, Winter RM, Reardon W. 2002. Okihiro syndrome is caused by SALL4 mutations. Hum Mol Genet 11:2979-2987.
46. McDermott DA, Bressan MC, He J, Lee JS, Aftimos S, Brueckner M, Gilbert F, Graham GE, Hannibal MC, Innis JW, Pierpont ME, Raas-Rothschild A, Shanske AL, Smith WE, Spencer RH, St John-Sutton MG, van Maldergem L, Waggoner DJ, Weber M, Basson CT. 2005. TBX5 genetic testing validates strict clinical criteria for Holt-Oram syndrome. Pediatr Res 58:981-986.
47. Kirk EP, Sunde M, Costa MW, Rankin SA, Wolstein O, Castro ML, Butler TL, Hyun C, Guo G, Otway R, Mackay JP, Waddell LB, Cole AD, Hayward C, Keogh A, Macdonald P, Griffiths L, Fatkin D, Sholler GF, Zorn AM, Feneley MP, Winlaw DS, Harvey RP. 2007. Mutations in cardiac T-box factor gene TBX20 are associated with diverse cardiac pathologies, including defects of septation and valvulogenesis and cardiomyopathy. Am J Hum Genet 81:280-291.
48. Stennard FA, Costa MW, Elliott DA, Rankin S, Haast SJ, Lai D, McDonald LP, Niederreither K, Dolle P, Bruneau BG, Zorn AM, Harvey RP. 2003. Cardiac T-box factor Tbx20 directly interacts with Nkx2-5, GATA4, and GATA5 in regulation of gene expression in the developing heart. Dev Biol 262:206-224.
49. Brown DD, Martz SN, Binder O, Goetz SC, Price BM, Smith JC, Conlon FL. 2005. Tbx5 and Tbx20 act synergistically to control vertebrate heart morphogenesis. Development 132:553-563.
50. Habets PE, Moorman AF, Clout DE, van Roon MA, Lingbeek M, van Lohuizen M, Campione M, Christoffels VM. 2002. Cooperative action of Tbx2 and Nkx2.5 inhibits ANF expression in the atrioventricular canal: implications for cardiac chamber formation. Genes Dev 16:1234-1246.
51. Yamagishi H, Yamagishi C, Nakagawa O, Harvey RP, Olson EN, Srivastava D. 2001. The combinatorial activities of Nkx2.5 and dHAND are essential for cardiac ventricle formation. Dev Biol 239:190-203.

52. Botto LD, May K, Fernhoff PM, Correa A, Coleman K, Rasmussen SA, Merritt RK, O'Leary LA, Wong LY, Elixson EM, Mahle WT, Campbell RM. 2003. A population-based study of the 22q11.2 deletion: phenotype, incidence, and contribution to major birth defects in the population. Pediatrics 112:101-107.
53. Ryan AK, Goodship JA, Wilson DI, Philip N, Levy A, Seidel H, Schuffenhauer S, Oechsler H, Belohradsky B, Prieur M, Aurias A, Raymond FL, Clayton-Smith J, Hatchwell E, McKeown C, Beemer FA, Dallapiccola B, Novelli G, Hurst JA, Ignatius J, Green AJ, Winter RM, Brueton L, Brondum-Nielsen K, Scambler PJ, et al. 1997. Spectrum of clinical features associated with interstitial chromosome 22q11 deletions: a European collaborative study. J Med Genet 34:798-804.
54. Jerome LA, Papaioannou VE. 2001. DiGeorge syndrome phenotype in mice mutant for the T-box gene, Tbx1. Nat Genet 27:286-291.
55. Lindsay EA, Vitelli F, Su H, Morishima M, Huynh T, Pramparo T, Jurecic V, Ogunrinu G, Sutherland HF, Scambler PJ, Bradley A, Baldini A. 2001. Tbx1 haploinsufficieny in the DiGeorge syndrome region causes aortic arch defects in mice. Nature 410:97-101.
56. Rauch A, Devriendt K, Koch A, Rauch R, Gewillig M, Kraus C, Weyand M, Singer H, Reis A, Hofbeck M. 2004. Assessment of association between variants and haplotypes of the remaining TBX1 gene and manifestations of congenital heart defects in 22q11.2 deletion patients. J Med Genet 41:e40.
57. Gong W, Gottlieb S, Collins J, Blescia A, Dietz H, Goldmuntz E, McDonald-McGinn DM, Zackai EH, Emanuel BS, Driscoll DA, Budarf ML. 2001. Mutation analysis of TBX1 in non-deleted patients with features of DGS/VCFS or isolated cardiovascular defects. J Med Genet 38:E45.
58. Zweier C, Sticht H, Aydin-Yaylagul I, Campbell CE, Rauch A. 2007. Human TBX1 missense mutations cause gain of function resulting in the same phenotype as 22q11.2 deletions. Am J Hum Genet 80:510-517.
59. Yagi H, Furutani Y, Hamada H, Sasaki T, Asakawa S, Minoshima S, Ichida F, Joo K, Kimura M, Imamura S, Kamatani N, Momma K, Takao A, Nakazawa M, Shimizu N, Matsuoka R. 2003. Role of TBX1 in human del22q11.2 syndrome. Lancet 362:1366-1373.
60. Torres-Juan L, Rosell J, Morla M, Vidal-Pou C, Garcia-Algas F, de la Fuente MA, Juan M, Tubau A, Bachiller D, Bernues M, Perez-Granero A, Govea N, Busquets X, Heine-Suner D. 2007. Mutations in TBX1 genocopy the 22q11.2 deletion and duplication syndromes: a new susceptibility factor for mental retardation. Eur J Hum Genet 15:658-663.
61. Seo S, Kume T. 2006. Forkhead transcription factors, Foxc1 and Foxc2, are required for the morphogenesis of the cardiac outflow tract. Dev Biol 296:421-436.
62. Yamagishi H, Maeda J, Hu T, McAnally J, Conway SJ, Kume T, Meyers EN, Yamagishi C, Srivastava D. 2003. Tbx1 is regulated by tissue-specific forkhead proteins through a common Sonic hedgehog-responsive enhancer. Genes Dev 17:269-281.
63. Brice G, Mansour S, Bell R, Collin JR, Child AH, Brady AF, Sarfarazi M, Burnand KG, Jeffery S, Mortimer P, Murday VA. 2002. Analysis of the phenotypic abnormalities in lymphoedema-distichiasis syndrome in 74 patients with FOXC2 mutations or linkage to 16q24. J Med Genet 39:478-483.
64. Baldini A. 2005. Dissecting contiguous gene defects: TBX1. Curr Opin Genet Dev 15:279-284.
65. Nava C, Hanna N, Michot C, Pereira S, Pouvreau N, Niihori T, Aoki Y, Matsubara Y, Arveiler B, Lacombe D, Pasmant E, Parfait B, Baumann C, Heron D, Sigaudy S, Toutain A, Rio M, Goldenberg A, Leheup B, Verloes A, Cave H. 2007. Cardio-facio-cutaneous and Noonan syndromes due to mutations in the RAS/MAPK signalling pathway: genotype-phenotype relationships and overlap with Costello syndrome. J Med Genet 44:763-771.
66. Denayer E, de Ravel T, Legius E. 2008. Clinical and molecular aspects of RAS related disorders. J Med Genet 45:695-703.
67. Uhlen P, Burch PM, Zito CI, Estrada M, Ehrlich BE, Bennett AM. 2006. Gain-of-function/Noonan syndrome SHP-2/Ptpn11 mutants enhance calcium oscillations and impair NFAT signaling. Proc Natl Acad Sci U S A 103:2160-2165.
68. Chang CP, Neilson JR, Bayle JH, Gestwicki JE, Kuo A, Stankunas K, Graef IA, Crabtree GR. 2004. A field of myocardial-endocardial NFAT signaling underlies heart valve morphogenesis. Cell 118:649-663.
69. Tartaglia M, Kalidas K, Shaw A, Song X, Musat DL, van der Burgt I, Brunner HG, Bertola DR, Crosby A, Ion A, Kucherlapati RS, Jeffery S, Patton MA, Gelb BD. 2002. PTPN11 mutations in Noonan syndrome: molecular spectrum, genotype-phenotype correlation, and phenotypic heterogeneity. Am J Hum Genet 70:1555-1563.
70. Tartaglia M, Pennacchio LA, Zhao C, Yadav KK, Fodale V, Sarkozy A, Pandit B, Oishi K, Martinelli S, Schackwitz W, Ustaszewska A, Martin J, Bristow J, Carta C, Lepri F, Neri C, Vasta I, Gibson K, Curry CJ, Siguero JP, Digilio MC, Zampino G, Dallapiccola B, Bar-Sagi D, Gelb BD. 2007. Gain-of-function SOS1 mutations cause a distinctive form of Noonan syndrome. Nat Genet 39:75-79.
71. Zenker M, Horn D, Wieczorek D, Allanson J, Pauli S, van der Burgt I, Doerr HG, Gaspar H, Hofbeck M, Gillessen-Kaesbach G, Koch A, Meinecke P, Mundlos S, Nowka A, Rauch A, Reif S, von Schnakenburg C, Seidel H, Wehner LE, Zweier C, Bauhuber S, Matejas V, Kratz CP, Thomas C, Kutsche K. 2007. SOS1 is the second most common Noonan gene but plays no major role in cardio-facio-cutaneous syndrome. J Med Genet 44:651-656.

72. Carta C, Pantaleoni F, Bocchinfuso G, Stella L, Vasta I, Sarkozy A, Digilio C, Palleschi A, Pizzuti A, Grammatico P, Zampino G, Dallapiccola B, Gelb BD, Tartaglia M. 2006. Germline missense mutations affecting KRAS Isoform B are associated with a severe Noonan syndrome phenotype. Am J Hum Genet 79:129-135.
73. Schubbert S, Zenker M, Rowe SL, Boll S, Klein C, Bollag G, van der Burgt I, Musante L, Kalscheuer V, Wehner LE, Nguyen H, West B, Zhang KY, Sistermans E, Rauch A, Niemeyer CM, Shannon K, Kratz CP. 2006. Germline KRAS mutations cause Noonan syndrome. Nat Genet 38:331-336.
74. Pandit B, Sarkozy A, Pennacchio LA, Carta C, Oishi K, Martinelli S, Pogna EA, Schackwitz W, Ustaszewska A, Landstrom A, Bos JM, Ommen SR, Esposito G, Lepri F, Faul C, Mundel P, Lopez Siguero JP, Tenconi R, Selicorni A, Rossi C, Mazzanti L, Torrente I, Marino B, Digilio MC, Zampino G, Ackerman MJ, Dallapiccola B, Tartaglia M, Gelb BD. 2007. Gain-of-function RAF1 mutations cause Noonan and LEOPARD syndromes with hypertrophic cardiomyopathy. Nat Genet 39:1007-1012.
75. Razzaque MA, Nishizawa T, Komoike Y, Yagi H, Furutani M, Amo R, Kamisago M, Momma K, Katayama H, Nakagawa M, Fujiwara Y, Matsushima M, Mizuno K, Tokuyama M, Hirota H, Muneuchi J, Higashinakagawa T, Matsuoka R. 2007. Germline gain-of-function mutations in RAF1 cause Noonan syndrome. Nat Genet 39:1013-1017.
76. Digilio MC, Conti E, Sarkozy A, Mingarelli R, Dottorini T, Marino B, Pizzuti A, Dallapiccola B. 2002. Grouping of multiple-lentigines/LEOPARD and Noonan syndromes on the PTPN11 gene. Am J Hum Genet 71:389-394.
77. Legius E, Schrander-Stumpel C, Schollen E, Pulles-Heintzberger C, Gewillig M, Fryns JP. 2002. PTPN11 mutations in LEOPARD syndrome. J Med Genet 39:571-574.
78. Tartaglia M, Niemeyer CM, Fragale A, Song X, Buechner J, Jung A, Hahlen K, Hasle H, Licht JD, Gelb BD. 2003. Somatic mutations in PTPN11 in juvenile myelomonocytic leukemia, myelodysplastic syndromes and acute myeloid leukemia. Nat Genet 34:148-150.
79. Niihori T, Aoki Y, Narumi Y, Neri G, Cave H, Verloes A, Okamoto N, Hennekam RC, Gillessen-Kaesbach G, Wieczorek D, Kavamura MI, Kurosawa K, Ohashi H, Wilson L, Heron D, Bonneau D, Corona G, Kaname T, Naritomi K, Baumann C, Matsumoto N, Kato K, Kure S, Matsubara Y. 2006. Germline KRAS and BRAF mutations in cardio-facio-cutaneous syndrome. Nat Genet 38:294-296.
80. Schulz AL, Albrecht B, Arici C, van der Burgt I, Buske A, Gillessen-Kaesbach G, Heller R, Horn D, Hubner CA, Korenke GC, Konig R, Kress W, Kruger G, Meinecke P, Mucke J, Plecko B, Rossier E, Schinzel A, Schulze A, Seemanova E, Seidel H, Spranger S, Tuysuz B, Uhrig S, Wieczorek D, Kutsche K, Zenker M. 2008. Mutation and phenotypic spectrum in patients with cardio-facio-cutaneous and Costello syndrome. Clin Genet 73:62-70.
81. Dentici ML, Sarkozy A, Pantaleoni F, Carta C, Lepri F, Ferese R, Cordeddu V, Martinelli S, Briuglia S, Digilio MC, Zampino G, Tartaglia M, Dallapiccola B. 2009. Spectrum of MEK1 and MEK2 gene mutations in cardio-facio-cutaneous syndrome and genotype -phenotype correlations. Eur J Hum Genet.
82. Armour CM, Allanson JE. 2008. Further delineation of cardio-facio-cutaneous syndrome: clinical features of 38 individuals with proven mutations. J Med Genet 45:249-254.
83. Narumi Y, Aoki Y, Niihori T, Neri G, Cave H, Verloes A, Nava C, Kavamura MI, Okamoto N, Kurosawa K, Hennekam RC, Wilson LC, Gillessen-Kaesbach G, Wieczorek D, Lapunzina P, Ohashi H, Makita Y, Kondo I, Tsuchiya S, Ito E, Sameshima K, Kato K, Kure S, Matsubara Y. 2007. Molecular and clinical characterization of cardio-facio-cutaneous (CFC) syndrome: overlapping clinical manifestations with Costello syndrome. Am J Med Genet A 143:799-807.
84. Kerr B, Delrue MA, Sigaudy S, Perveen R, Marche M, Burgelin I, Stef M, Tang B, Eden OB, O'Sullivan J, De Sandre-Giovannoli A, Reardon W, Brewer C, Bennett C, Quarell O, M'Cann E, Donnai D, Stewart F, Hennekam R, Cave H, Verloes A, Philip N, Lacombe D, Levy N, Arveiler B, Black G. 2006. Genotype-phenotype correlation in Costello syndrome: HRAS mutation analysis in 43 cases. J Med Genet 43:401-405.
85. Gripp KW, Lin AE, Stabley DL, Nicholson L, Scott CI, Jr., Doyle D, Aoki Y, Matsubara Y, Zackai EH, Lapunzina P, Gonzalez-Meneses A, Holbrook J, Agresta CA, Gonzalez IL, Sol-Church K. 2006. HRAS mutation analysis in Costello syndrome: genotype and phenotype correlation. Am J Med Genet A 140:1-7.
86. Aoki Y, Niihori T, Kawame H, Kurosawa K, Ohashi H, Tanaka Y, Filocamo M, Kato K, Suzuki Y, Kure S, Matsubara Y. 2005. Germline mutations in HRAS proto-oncogene cause Costello syndrome. Nat Genet 37:1038-1040.
87. Zenker M, Buheitel G, Rauch R, Koenig R, Bosse K, Kress W, Tietze HU, Doerr HG, Hofbeck M, Singer H, Reis A, Rauch A. 2004. Genotype-phenotype correlations in Noonan syndrome. J Pediatr 144:368-374.
88. Lin AE, Grossfeld PD, Hamilton RM, Smoot L, Gripp KW, Proud V, Weksberg R, Wheeler P, Picker J, Irons M, Zackai E, Marino B, Scott CI, Jr., Nicholson L. 2002. Further delineation of cardiac abnormalities in Costello syndrome. Am J Med Genet 111:115-129.
89. Weismann CG, Hager A, Kaemmerer H, Maslen CL, Morris CD, Schranz D, Kreuder J, Gelb BD. 2005. PTPN11 mutations play a minor role in isolated congenital heart disease. Am J Med Genet A 136:146-151.

90. Sarkozy A, Conti E, Esposito G, Pizzuti A, Dallapiccola B, Mingarelli R, Marino B, Digilio MC, Paoletti V. 2003. Nonsyndromic pulmonary valve stenosis and the PTPN11 gene. Am J Med Genet A 116:389-390.
91. Oda T, Elkahloun AG, Pike BL, Okajima K, Krantz ID, Genin A, Piccoli DA, Meltzer PS, Spinner NB, Collins FS, Chandrasekharappa SC. 1997. Mutations in the human Jagged1 gene are responsible for Alagille syndrome. Nat Genet 16:235-242.
92. Warthen DM, Moore EC, Kamath BM, Morrissette JJ, Sanchez P, Piccoli DA, Krantz ID, Spinner NB. 2006. Jagged1 (JAG1) mutations in Alagille syndrome: increasing the mutation detection rate. Hum Mutat 27:436-443.
93. McElhinney DB, Krantz ID, Bason L, Piccoli DA, Emerick KM, Spinner NB, Goldmuntz E. 2002. Analysis of cardiovascular phenotype and genotype-phenotype correlation in individuals with a JAG1 mutation and/or Alagille syndrome. Circulation 106:2567-2574.
94. Krantz ID, Smith R, Colliton RP, Tinkel H, Zackai EH, Piccoli DA, Goldmuntz E, Spinner NB. 1999. Jagged1 mutations in patients ascertained with isolated congenital heart defects. Am J Med Genet 84:56-60.
95. Eldadah ZA, Hamosh A, Biery NJ, Montgomery RA, Duke M, Elkins R, Dietz HC. 2001. Familial Tetralogy of Fallot caused by mutation in the jagged1 gene. Hum Mol Genet 10:163-169.
96. Niessen K, Karsan A. 2007. Notch signaling in the developing cardiovascular system. Am J Physiol Cell Physiol 293:C1-11.
97. McDaniell R, Warthen DM, Sanchez-Lara PA, Pai A, Krantz ID, Piccoli DA, Spinner NB. 2006. NOTCH2 mutations cause Alagille syndrome, a heterogeneous disorder of the notch signaling pathway. Am J Hum Genet 79:169-173.
98. Garg V, Muth AN, Ransom JF, Schluterman MK, Barnes R, King IN, Grossfeld PD, Srivastava D. 2005. Mutations in NOTCH1 cause aortic valve disease. Nature 437:270-274.
99. Faivre L, Collod-Beroud G, Child A, Callewaert B, Loeys BL, Binquet C, Gautier E, Arbustini E, Mayer K, Arslan-Kirchner M, Stheneur C, Kiotsekoglou A, Comeglio P, Marziliano N, Halliday D, Beroud C, Bonithon-Kopp C, Claustres M, Plauchu H, Robinson PN, Ades L, De Backer J, Coucke P, Francke U, De Paepe A, Boileau C, Jondeau G. 2008. Contribution of molecular analyses in diagnosing Marfan syndrome and type I fibrillinopathies: an international study of 1009 probands. J Med Genet 45:384-390.
100. Judge DP, Dietz HC. 2005. Marfan's syndrome. Lancet 366:1965-1976.
101. Robinson PN, Arteaga-Solis E, Baldock C, Collod-Beroud G, Booms P, De Paepe A, Dietz HC, Guo G, Handford PA, Judge DP, Kielty CM, Loeys B, Milewicz DM, Ney A, Ramirez F, Reinhardt DP, Tiedemann K, Whiteman P, Godfrey M. 2006. The molecular genetics of Marfan syndrome and related disorders. J Med Genet 43:769-787.
102. Loeys BL, Schwarze U, Holm T, Callewaert BL, Thomas GH, Pannu H, De Backer JF, Oswald GL, Symoens S, Manouvrier S, Roberts AE, Faravelli F, Greco MA, Pyeritz RE, Milewicz DM, Coucke PJ, Cameron DE, Braverman AC, Byers PH, De Paepe AM, Dietz HC. 2006. Aneurysm syndromes caused by mutations in the TGF-beta receptor. N Engl J Med 355:788-798.
103. Singh KK, Rommel K, Mishra A, Karck M, Haverich A, Schmidtke J, Arslan-Kirchner M. 2006. TGFBR1 and TGFBR2 mutations in patients with features of Marfan syndrome and Loeys-Dietz syndrome. Hum Mutat 27:770-777.
104. Matyas G, Arnold E, Carrel T, Baumgartner D, Boileau C, Berger W, Steinmann B. 2006. Identification and in silico analyses of novel TGFBR1 and TGFBR2 mutations in Marfan syndrome-related disorders. Hum Mutat 27:760-769.
105. Sheen VL, Jansen A, Chen MH, Parrini E, Morgan T, Ravenscroft R, Ganesh V, Underwood T, Wiley J, Leventer R, Vaid RR, Ruiz DE, Hutchins GM, Menasha J, Willner J, Geng Y, Gripp KW, Nicholson L, Berry-Kravis E, Bodell A, Apse K, Hill RS, Dubeau F, Andermann F, Barkovich J, Andermann E, Shugart YY, Thomas P, Viri M, Veggiotti P, Robertson S, Guerrini R, Walsh CA. 2005. Filamin A mutations cause periventricular heterotopia with Ehlers-Danlos syndrome. Neurology 64:254-262.
106. Germain DP. 2007. Ehlers-Danlos syndrome type IV. Orphanet J Rare Dis 2:32.
107. Wessels MW, Catsman-Berrevoets CE, Mancini GM, Breuning MH, Hoogeboom JJ, Stroink H, Frohn-Mulder I, Coucke PJ, Paepe AD, Niermeijer MF, Willems PJ. 2004. Three new families with arterial tortuosity syndrome. Am J Med Genet A 131:134-143.
108. Coucke PJ, Willaert A, Wessels MW, Callewaert B, Zoppi N, De Backer J, Fox JE, Mancini GM, Kambouris M, Gardella R, Facchetti F, Willems PJ, Forsyth R, Dietz HC, Barlati S, Colombi M, Loeys B, De Paepe A. 2006. Mutations in the facilitative glucose transporter GLUT10 alter angiogenesis and cause arterial tortuosity syndrome. Nat Genet 38:452-457.
109. Habashi JP, Judge DP, Holm TM, Cohn RD, Loeys BL, Cooper TK, Myers L, Klein EC, Liu G, Calvi C, Podowski M, Neptune ER, Halushka MK, Bedja D, Gabrielson K, Rifkin DB, Carta L, Ramirez F, Huso DL, Dietz HC. 2006. Losartan, an AT1 antagonist, prevents aortic aneurysm in a mouse model of Marfan syndrome. Science 312:117-121.
110. Brooke BS, Habashi JP, Judge DP, Patel N, Loeys B, Dietz HC, 3rd. 2008. Angiotensin II blockade and aortic-root dilation in Marfan's syndrome. N Engl J Med 358:2787-2795.
111. Zhu L, Vranckx R, Khau Van Kien P, Lalande A, Boisset N, Mathieu F, Wegman M, Glancy L, Gasc JM, Brunotte F, Bruneval P, Wolf JE, Michel JB, Jeunemaitre X. 2006. Mutations in myosin heavy chain 11 cause a syndrome associating thoracic aortic aneurysm/aortic dissection and patent ductus arteriosus. Nat Genet 38:343-349.

112. Guo DC, Pannu H, Tran-Fadulu V, Papke CL, Yu RK, Avidan N, Bourgeois S, Estrera AL, Safi HJ, Sparks E, Amor D, Ades L, McConnell V, Willoughby CE, Abuelo D, Willing M, Lewis RA, Kim DH, Scherer S, Tung PP, Ahn C, Buja LM, Raman CS, Shete SS, Milewicz DM. 2007. Mutations in smooth muscle alpha-actin (ACTA2) lead to thoracic aortic aneurysms and dissections. Nat Genet 39:1488-1493.

113. Lim JY, Park SJ, Hwang HY, Park EJ, Nam JH, Kim J, Park SI. 2005. TGF-beta1 induces cardiac hypertrophic responses via PKC-dependent ATF-2 activation. J Mol Cell Cardiol 39:627-636.

114. Wessels MW and Willems PJ. 2009. Genetic and environmental factors in non-syndromic congenital heart malformations. Submitted.

115. Jenkins KJ, Correa A, Feinstein JA, Botto L, Britt AE, Daniels SR, Elixson M, Warnes CA, Webb CL. 2007. Noninherited risk factors and congenital cardiovascular defects: current knowledge: a scientific statement from the American Heart Association Council on Cardiovascular Disease in the Young: endorsed by the American Academy of Pediatrics. Circulation 115:2995-3014.

116. Bentham J, Bhattacharya S. 2008. Genetic mechanisms controlling cardiovascular development. Ann N Y Acad Sci 1123:10-19.

117. Shaw GM, Iovannisci DM, Yang W, Finnell RH, Carmichael SL, Cheng S, Lammer EJ. 2005. Risks of human conotruncal heart defects associated with 32 single nucleotide polymorphisms of selected cardiovascular disease-related genes. Am J Med Genet A 138:21-26.

118. van Beynum IM, Mooij C, Kapusta L, Heil S, den Heijer M, Blom HJ. 2008. Common 894G>T single nucleotide polymorphism in the gene coding for endothelial nitric oxide synthase (eNOS) and risk of congenital heart defects. Clin Chem Lab Med 46:1369-1375.

119. Vannay A, Vasarhelyi B, Kornyei M, Treszl A, Kozma G, Gyorffy B, Tulassay T, Sulyok E. 2006. Single-nucleotide polymorphisms of VEGF gene are associated with risk of congenital valvuloseptal heart defects. Am Heart J 151:878-881.

120. Lambrechts D, Devriendt K, Driscoll DA, Goldmuntz E, Gewillig M, Vlietinck R, Collen D, Carmeliet P. 2005. Low expression VEGF haplotype increases the risk for tetralogy of Fallot: a family based association study. J Med Genet 42:519-522.

121. Yehya A, Souki R, Bitar F, Nemer G. 2006. Differential duplication of an intronic region in the NFATC1 gene in patients with congenital heart disease. Genome 49:1092-1098.

122. Reamon-Buettner SM, Borlak J. 2004. TBX5 mutations in non-Holt-Oram syndrome (HOS) malformed hearts. Hum Mutat 24:104.

123. Reamon-Buettner SM, Borlak J. 2005. GATA4 zinc finger mutations as a molecular rationale for septation defects of the human heart. J Med Genet 42:e32.

124. Reamon-Buettner SM, Borlak J. 2006. Somatic mutations in cardiac malformations. J Med Genet 43:e45.

125. Reamon-Buettner SM, Borlak J. 2006. HEY2 mutations in malformed hearts. Hum Mutat 27:118.

126. Reamon-Buettner SM, Ciribilli Y, Inga A, Borlak J. 2008. A loss-of-function mutation in the binding domain of HAND1 predicts hypoplasia of the human hearts. Hum Mol Genet 17:1397-1405.

127. Reamon-Buettner SM, Hecker H, Spanel-Borowski K, Craatz S, Kuenzel E, Borlak J. 2004. Novel NKX2-5 mutations in diseased heart tissues of patients with cardiac malformations. Am J Pathol 164:2117-2125.

128. Majumdar R, Yagubyan M, Sarkar G, Bolander ME, Sundt TM, 3rd. 2006. Bicuspid aortic valve and ascending aortic aneurysm are not associated with germline or somatic homeobox NKX2-5 gene polymorphism in 19 patients. J Thorac Cardiovasc Surg 131:1301-1305.

129. Rauch A, Hofbeck M, Cesnjevar R, Koch A, Rauch R, Buheitel G, Singer H, Weyand M. 2004. Search for somatic 22q11.2 deletions in patients with conotruncal heart defects. Am J Med Genet A 124:165-169.

1.2

REVIEW

Genetic and environmental factors in non-syndromic congenital heart malformations

Marja W. Wessels[1] and Patrick J. Willems[2]

[1]Department of Clinical Genetics, Erasmus Medical Center, Rotterdam, The Netherlands, and
[2]GENDIA (GENetic DIAgnostic Network), Antwerp, Belgium

Submitted

Abstract

The genetic defect in most patients with non-syndromic congenital heart malformations (CHM) is unknown, although more than 40 different genes have already been implicated in non-syndromic CHM. Only a minority of CHM seems to be due to monogenetic mutations, and the majority occurs sporadically. The multifactorial inheritance hypothesis of common diseases suggests that the cumulative effect of multiple genetic and environmental risk factors leads to disease.

We review here the different environmental factors, monogenic disease genes with high-penetrance mutations, susceptibility genes with reduced-penetrance mutations, and somatic mutations implicated in non-syndromic CHM.

Introduction

Congenital heart malformations (CHM) are among the most common human congenital defects, occurring in 6 to 8 out of 1000 live-births [1]. The majority of CHM with monogenic inheritance is associated with non-cardiac malformations, and thereby constitutes syndromic forms of CHM. These include wellknown examples such as Holt-Oram syndrome, Alagille syndrome, and Noonan syndrome, among many others (for review: see refs [2-4]). Many of these syndromes have a monogenic mode of inheritance. In contrast, most non-syndromic CHM occurs sporadically, and families with clear monogenic inheritance of non-syndromic CHM are scarce [5-8]. This precludes the identification of human disease genes involved in non-syndromic CHM by a classical positional genetics approach. The sporadic nature of most non-syndromic CHM is traditionally explained by the multifactorial inheritance model which involves a multitude of susceptibility genes with low-penetrance mutations (common variants) or intermediate-penetrance mutations (rare variants) superposed on unfavorable environmental factors [9]. Although widely accepted, this hypothesis remains difficult to proof, and only a handful of studies on accumulating and/or interacting effects in CHM have been reported [10-13].

Here we review the different etiological factors implicated in the development of non-syndromic CHM, including environmental factors, disease genes with high-penetrance mutations, susceptibility genes with intermediate- or low-penetrance mutations, and somatic mutations.

Environmental factors

Environmental factors associated with an increased risk for CHM include mainly maternal factors, thereby suggesting that the majority of these environmental noxes are teratogenic or embryotoxic and not mutagenic (for review: see refs [14,15]). The main maternal factors include hyperhomocysteinemia, diabetes, hyperphenylalaninemia, alcohol, and medication (Table 1) [15].

Especially homocysteine-methionine metabolism has been studied in CHM - in parallel to studies in neural tube defects - in view of the observations that: i) both maternal deficiency of folic acid [16] and vitB12 [17] are associated with an increased risk for CHM, ii) folic acid antagonists, including medication such as trimethoprim, triamterene, carbamazepine, phenytoin, phenobarbital, and primidone, increase the risk for CHM [18], iii) maternal hyperhomocysteinemia is associated with an increased risk for CHM [19], iv) the risk of CHM can be reduced by supplementation during pregnancy with folic acid or multivitamins containing folic acid and vitB12 (for review: see ref [20]), and v) animal studies have implicated maternal folate deficiency in CHM [21,22]. Different enzymes including SCL19A1, MTHFR, MTHFD1, MTRR, and NNMT are active in the "methylation cycle" through the conversion of homocysteine into methionine by a 1-carbon (methyl) transfer. This cycle is essential in the methylation of deoxyuridine monophosphate (dUMP) to generate the thymidylate (dTMP) needed for DNA synthesis. Some common genetic variants in the genes encoding these enzymes represent low-risk factors for CHM. Folic acid antagonists might increase the risk of CHM by interfering with the action of dihydrofolate reductase (DHFR), thereby inhibiting the synthesis of tetrahydrofolic acid (THF) [18]. As the methylation cycle is both determined by maternal and fetal genetic factors on one hand, and environmental factors on the other hand, both the maternal and the patient's genotype combined with maternal intake of nutrients such as folic acid and VitB12 might influence the CHM risk. This makes the "methylation cycle" to a true multifactorial model for CHM. Periconceptional folic acid supplements have led to the prevention of more than 50% of cases neural tube defects [23]. Similarly, a number of studies suggest that the risk for CHM can be decreased by the use of folic acid (alone or in multivitamin supplements) during gestation (for review: see ref [20]).

Maternal pregestational diabetes is associated with specific types of CHM, such as conotruncal defects [24,25] and heterotaxy [26-28]. Heterotaxy is also seen in progeny of the NOD mouse, a model of insulin-dependent diabetes mellitus [29-31]. The pathogenic mechanisms leading to these specific CHM are unclear. The prevention of diabetic embryopathy by antioxidants in diabetic pregnancy in mice suggests that oxidative stress might play a role in this process [32].

Maternal hyperphenylalaninemia is associated with an increased risk of CHM [33-35]. Although different types of CHM are seen, coarctation of the aorta (CoA) and hypoplastic left heart syndrome (HLHS) are overrepresented in children with CHM born after exposure to high levels of phenylalanine during pregnancy [34]. Implementation of a strict diet before conception and in early pregnancy reduces the risk of CHM [34,35]. The mechanism of hyperphenylalanine-related CHM is still unclear.

Table 1. Environmental factors contributing to CHM

Environmental factors	Factors	Cardiac phenotypes	Refs
Maternal			
Diabetes	Hyperglycemia	Heterotaxy, conotruncal defects, HLHS	24,27,212-215
Hyperphenylalaninemia	Hyperphenylalaninemia	TOF, HLHS, CoA	33,34,216
Hyperthermia	High temperature	ASD, HLHS, PS, TA	211,217-219
Hyperhomocysteinemia	Hyperhomocysteinemia	Various	19
Alcohol abuse	Alcohol	ASD, VSD	36,37,220,221
Drug abuse	Cannabis	VSD, Ebstein	27,221
	Cocaine	PS, PDA, VSD, heterotaxy	27,222
Medication	ACE inhibitors	ASD, VSD, PS, PDA	49
	Thalidomide	Conotruncal defects	40,41
	Retinoids	Conotruncal defects	42,43
	Phenytoin, phenobarbital, carbamazepine, valproic acid	Various	18,223-225
	Lithium	Ebstein	44
	Trimetraprim, triamterene, sulfasalazine	Various	18
	Aspirin	IAA, HLHS	45,46
	Indometacin	PDA	47
	Ibuprofen	TGA, AVSD, VSD, BAV	48
Chemical exposures	Organic solvents	Various	46,211,226-228
	Pesticides	TGA	229
Nutrient exposures	Vitamin A	TGA, PS, outflow tract defects	230-232
	Vitamin E	Various	233
Nutrient deficiencies	Folate	Various	16
	Vitamin B12	Various	17
	Nicotinamide	Various	11
Viral infections	Rubella	VSD, PDA, pulmonary valve anomalies	234,235
	Influenza	Conotruncal defects, TGA, TA, CoA, VSD	236
Paternal			
Age	Unknown		51
Drug abuse	Cocaine	VSD	50
	Cannabis	VSD	50
Chemical exposure	Organic solvents	CoA, HLHS	46

ASD, atrial septal defect; AVSD, atrioventricular septal defect; BAV, bicuspid aortic valve; CHM, congenital heart malformation; CoA, coarctation of the aorta; PS, pulmonary valve stenosis; VSD, ventricular septal defect; HLHS, hypoplastic left heart syndrome; IAA, interrupted aortic arch; PDA, patent ductus arteriosus; TA, tricuspid atresia; TAPVR, total anomalous pulmonary venous retour; TGA, transposition of the great arteries; TOF, tetralogy of Fallot

The teratogenetic effect of alcohol on the developing heart is well established, as neonates with fetal alcohol syndrome have a high risk of CHM, mainly atrial septal defects (ASD) [36,37]. Also mice exposed to ethanol exhibit CHM, particularly ASD [38,39].

Medication known to be associated with an increased risk of CHM in offspring includes thalidomide [40,41], retinoids [42,43], lithium [44], aspirin [45,46], indomethacine [47], ibuprofen [48], ACE inhibitors [49] and folic acid antagonists [18].

Only a few paternal factors have been reported to be risk factors for CHM in offspring: the use of can-

nabis and cocaine by older fathers increases the risk for a child with a VSD [50], and also paternal age on itself is a risk factor for CHM [51]. Fathers exposed to organic solvents have an unexplained increased risk of children with left-sided heart malformations [46]. It has been postulated that this teratogenic effect is due to dominant mutations in spermatozoa [52].

Disease genes with high-penetrance mutations

Many syndromic forms of CHM exist, and for many the primary gene defect has been identified. In recent years an increasing number of families with monogenic forms of non-syndromic CHM have been reported, which has facilitated the positional cloning of several disease genes, including *ZIC3, GATA4, NKX2.5, NKX2.6, JAG1, TBX5, FLNA, MYH6, ACTC1, NOTCH1,* and *ELN*. Other disease genes were found through a candidate gene approach: these include *TBX1, TBX20, CFC1, CITED2, CRELD1, FOG2, LEFTY2, NODAL, GDF1, FOXH1, TDGF, MYOCD, TLL1, THRAP2* and *ANKRD1* (Table 2). The majority of monogenic forms of non-syndromic CHM are caused by a single high-penetrance autosomal dominant mutation. Nevertheless, the majority of mutations reported in many of the human HCM genes are missense mutations of which the pathogenic, let alone the monogenic nature, has not been formally demonstrated, and some of these mutations have reduced (intermediate or low) penetrance (Table 3).

Many of the genes implicated in non-syndromic CHM are transcriptional regulators of heart morphogenesis. The fetal developmental program of the heart involves multiple pathways with extensive cross-talking and promiscuous ligand-receptor interactions, secondary signal transduction pathways and a network of transcription factors that determines the expression of cardio-specific effector genes (Figure 1). Various ligands in the circulation or the extracellular space of the heart, including hormones, cytokines, and growth factors, stimulate receptors in the cell membrane of cardiac cells. These ligand-receptor complexes include JAGGED/NOTCH, TGFB-BMP/TGFBR, VEGF/FLT1-FLK1, NODAL/ACVRA-ACVRB, and RTK/RAS. These membrane complexes (in)-activate different signal transduction pathways converging on a network of transcriptional factors and regulators. Phosphorylation / dephosphorylation by kinases such as mitogen-activated protein kinase (MAPK), extracellular signal-regulated kinase 1/2 (ERK1/2), cJUN, GSK, and calcineurin further controls these transcriptional networks. The transcriptional regulators of heart morphogenesis include several T-BOX transcription factors (TBX1, TBX5 and TBX20), various GATA transcription factors (GATA4, FOG2), myocyte enhancer factor 2 (MEF2), nuclear factor of activated T cells (NFAT), serum response factor (SRF), homeobox transcription factors (NKX2.5, NKX2.6), basic helix-loop-helix (bHLH) transcription factors (HAND1, HAND2), and various SMAD transcription factors. These transcription factors regulate the expression of numerous cardiac effector genes, including atrial natriuretic factor (ANF), b-type natriuretic peptide (BNP), myosins including α-myosin heavy chain (α-MHC) encoded by the *MYH6* gene, and cardiac actin encoded by the *ACTC1* gene.

Most high-risk mutations occur in 2 different groups of genes eg. transcription factors-regulators and cardiac effector genes. Several transcriptional regulators, including GATA4, FOG2, NKX2.5, NKX2.6, ZIC3, CITED2, TBX1, and TBX20, have been implicated in non-syndromic CHM. Recently, also mutations in sarcomeric protein genes *MYH6* [53], *ACTC1* [54] and *MYH7* [55] have been shown to cause various CHM [56]. A similar signal transduction pathway, referred to as the NODAL signal transduction pathway, is involved in

the establishment of left-right asymmetry: NODAL, LEFTY1 / LEFTY2 and GDF1 are ligands for a receptor complex consisting of CFC1, TDGF1, ACVR2A /ACVR2B and ACVR1B. This complex determines the activity of transcription factors including FOXH1 that have cardiac-specific downstream targets such as PITX2 (Figure 1). Mutations in the NODAL pathway are not only involved in laterality defects but also in heterotaxy-related CHM such as tetralogy of Fallot (TOF), transposition of the great arteries (TGA) and double outlet right ventricle (DORV) [57].

The different disease genes with high-penetrance mutations implicated in non-syndromic CHM are discussed below (Tables 2 and 6).

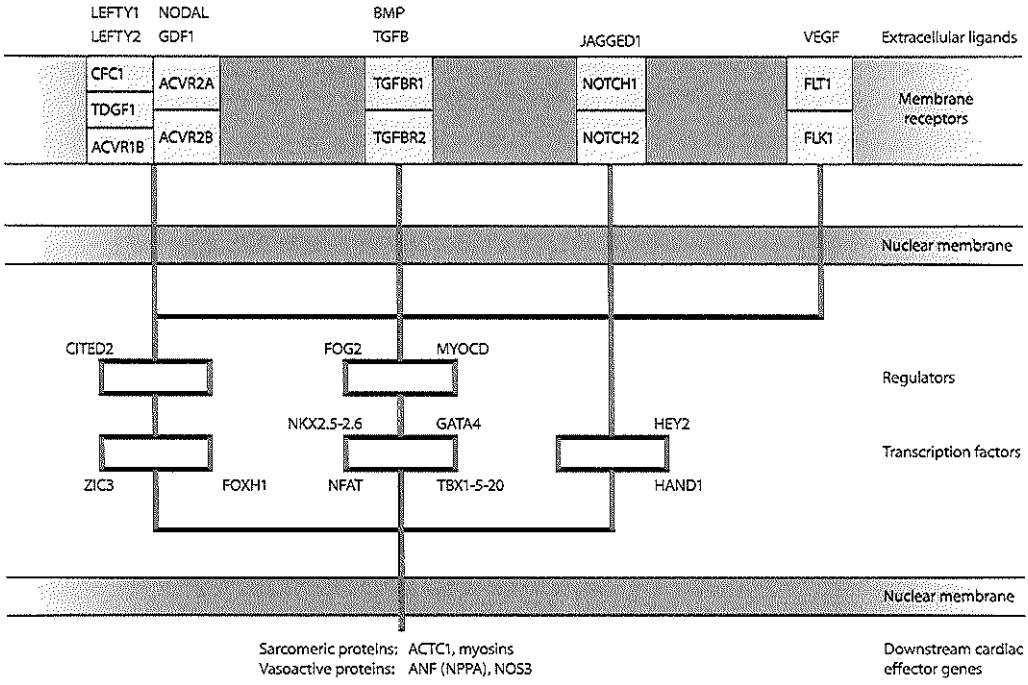

Figure 1 | Signaling pathways in heart morphogenesis involved in non-syndromic CHM

The fetal developmental program of the heart involves many pathways with ligand-receptor interactions, signal transduction pathways and interacting transcription factors that determine the expression of cardio-specific effector genes. The figure is simplified to focus on genes implicated in non-syndromic CHM. The disease genes encode members of all compartments of the pathway, including ligands (LEFTY2, NODAL, VEGF, GDF1, JAGGED1), receptors (CFC1, TDGF1, ACVR2B, NOTCH1), transcription factors-regulators (CITED2, TFAP2B, ZIC3, FOXH1, FOG2, MYOCD, NKX2.5-2.6, TBX1-5-20, GATA4, HEY2), and downstream effectortargets including sarcomeric proteins (ACTC1, Myosins) and vasoactive proteins (ANF, NOS3). Significant ligand-receptor promiscuity and cross-talking between the different signal transduction pathways exists.

Ligands and receptors

NOTCH1

Bicuspid aortic valve (BAV) +/- severe valve calcification, the most common CHM, can be caused by autosomal dominant mutations in the *NOTCH1* gene in a minority of patients [58]. BAV may be part of left ventricular outflow tract obstruction (LVOTO) that can also be caused by *NOTCH1* mutations [59-61] (Tables 2 and 6). NOTCH proteins are single-pass transmembrane receptors that regulate many developmental pathways (Figure 1). Mutations in the genes encoding NOTCH2 and its ligand JAGGED1 lead to Alagille syndrome, a syndromic CHM characterized by peripheral pulmonary artery stenosis and septal defects. Mouse embryos that are double mutant for the Notch1 and Notch2 receptors exhibit defects in left-right (LR) asymmetry, indicating that the Notch signaling pathway plays a primary role in the establishment of LR asymmetry, this by directly regulating expression of the *Nodal* gene [62]. Up to now no *NOTCH1* mutations have been reported in patients with laterality defects.

NODAL

Five % of patients affected with either heterotaxy or heterotaxy-related HCM such as looping defects including TGA and DORV have a mutation in the *NODAL* gene [57] (Tables 2 and 6). In mice Nodal is asymmetrically expressed in the left lateral plate mesoderm, and Nodal signaling specifies left-sidedness by activation of Pitx2. Nodal-deficient mice die prior to the establishment of the LR axis, lack the primitive streak and do not form mesoderm [63,64]. NODAL, a member of TGFβ superfamily of developmental regulators, is part of the NODAL signal transduction pathway, which regulates the establishment of the LR axis. Mutations have also been found in other components of the NODAL signal transduction pathway, including the *GDF1* [65], *LEFTY2* [66], *ACVR2B* [67], *CFC1* [68,69], *FOXH1* [10] and *TDGF1* [10] genes (Figure 1).

GDF1

Mutations in the *GDF1* gene have been found in 2% of a large group of patients with a wide spectrum of CHM, including TGA, DORV, TOF and interrupted aortic arch (IAA) [65] (Tables 2 and 6). Mice lacking Gdf1 exhibit a spectrum of defects related to LR axis formation, including visceral situs inversus, right pulmonary isomerism and looping defects such as TGA and DORV [70]. GDF1 is a growth differentiation factor that belongs to the transforming growth factor-beta (TGFβ) superfamily. It is a ligand of ACVR2, and part of the NODAL signal transduction pathway [71] (Figure 1).

LEFTY2

In two patients with heterotaxy and left isomerism mutations in *LEFTY2* have been described, but overall *LEFTY2* mutations are uncommon in heterotaxy [66] (Tables 2 and 6). Mice with targeted deletion of the *Lefty2* asymmetric enhancer (which regulates LR expression of Lefty2) show left isomerism [72]. *LEFTY2* and the very homologous *LEFTY1* encode TGFβ-like proteins that are ligands in the NODAL signal transduction pathway (Figure 1).

ACVR2B

In 3 patients with heterotaxy mutations in the *ACVR2B* gene have been reported [67] (Tables 2 and 6).

Acvr2b -/- knockout mice show abnormal LR axis development, ASD and ventricular septal defects (VSD), right-sided morphology of the left atrium and left lung, and spleen hypoplasia [73]. *Pitx2* -/- knockout mice have cardiac defects similar to *Acvr2b* knockout mice [74], supporting the evidence that Pitx2 is a downstream target of the Acvr2b signal transduction pathway. ACVR2B belongs to the family of Activins, transforming growth factor-beta-related proteins that act as receptors for ligands such as LEFTY1, LEFTY2, GDF1 and NODAL in the NODAL signaling pathway (Figure 1).

CFC1

A minority of patients with heterotaxy [68], TGA and DORV [75] or TOF [10] show mutations in the *CFC1* gen (Tables 2 and 6). Mutant *Cfc1* mice have heterotaxy [76]. *The CFC1 gene encodes* Cryptic, which belongs to the EGF (epidermal growth factor) - CFC family of proteins (consisting of Cripto, Frl1, and Cryptic). These proteins are membrane-associated NODAL coreceptors in the NODAL pathway (Figure 1).

TDGF1

Only 2 patients with CHM (TOF) [10] have been reported to have a *TDGF1* mutation (Tables 2 and 6). Targeted disruption of the *Tdgf1* gene is lethal. TDGF1 (CRIPTO) is an EGF-CFC family member like CFC1. It acts as a co-receptor in the NODAL signaling pathway (Figure 1).

FOXH1

Several patients with CHM (mainly TOF, few with heterotaxy) have been reported to have a *FOXH1* mutation [10] (Tables 2 and 6). Foxh1-/- mutant mouse embryos fail to form the outflow tract and right ventricle [77]. FOXH1 is a forkhead DNA-binding transcription factor in the NODAL signaling pathway. It is essential in the development of the second heart field (SHF) and derivatives (the right ventricle and outflow tract), during looping morphogenesis of the heart (Figure 1).

Transcription factors and regulators

GATA4

*M*utations in the *GATA4* gene have been reported in familial cases of ASD +/_ pulmonary stenosis (PS) [8,78-80], and in a minority (1-4 %) of sporadic patients with septal defects or conotruncal anomalies [81-84] (Tables 2 and 6). Homozygous *Gata4* knockout mice die in utero and develop two symmetric promyocardial primordia that fail to migrate ventrally and form two independent heart tubes [85,86]. Mice with heterozygous *Gata4* mutations exhibit septal defects and endocardial cushion defects [83]. The different members of the GATA zinc-finger transcription factor family (GATA1-6) recognize the consensus target sequence (T/A)GATA(A/G) in downstream targets, and play critical roles in various developmental processes, including cardiac and coronary vasculature development. The transcriptional activity of the GATA transcription factors is modulated through interaction with multiple nuclear proteins, including other zinc finger proteins such as the FOG family, the NKX2 family, the NFAT family, and coactivators such as p300 and CBP [87,88] (Figure 1).

Table2 | Germline mutations contributing to non-syndromic CHM

Genes	Cardiac phenotypes	Mutations*	Refs
Ligands - receptors			
NOTCH1	BAV, AS	R1108X, H1505del, T596M, P1797H, P1390T, A683T, G661S	58-61
CFC1	Heterotaxy	R112C, R189C	68,69
	TGA	Splice donor site duplication intron 4	75
	TOF	IVS4+2T>C	10
	TA	IVS4+2T>C	10
	AVSD	IVS4+2T>C	10
LEFTY2	Heterotaxy	R314X, S342K	66
ACVR2B	Heterotaxy	R40H, V494I	67
GDF1	TOF	G162D, S309P, P312T	65
	TGA	C227X, A318T	65
	DORV	C267Y	65
	AVSD	G262S, R68H	65
NODAL	Heterotaxy	E203K, G260R, R275C, V284F, R234_P241delinsLTS, IVS1-1G>T, IVS2+1G>A	57
TDGF1	TOF	P125L	10
JAG1	PS, TOF	G274D, E228fs	146,147
PTPN11	AVSD	L43F	237
Transcription factors			
GATA4	ASD	S52F, G296S, S358del, E359fs, Q316E, A411V	8,78-81,84,238,239
	TOF	E216D, D425N, A118_A119insA, P407Q	81,82,84
	ASD ± PS	G296S, S358fs, G296C	8,79,80
	VSD	A411V, E359K, A6V, S46del, A125_A126insAA, S429T, A422V	81,82
	HRV	L403M	83
	PAPVR	A411V	239
FOG2	TOF	E30G, S657G	89
NKX2.5	ASD-AV block	Q149X, R189G, T178M, Y259X, Q170X, Q198X, Q160P, IVS1+1G>T+1T, c.215_221del7, A75fs, A88fs, R190C, Y256X, Q170X, E160P, Y256X, K104fs, A127E, R142C, Q817H, N188K, R189G, Y191C, c.701_702ins5, C264X, E109X	5,78,93-99,101,240-243
	TOF	Q22P, R216C, R142C, A323T, Q149X	93,99-101,244,245
	HLHS, CoA, IAA	T178M, R25C, P275T	97,101
	Heterotaxy	c.215_221del7	95
	TGA	A63V	101
	DORV	N291del	101
	VSD	Y191C, Q149X, Y259X, E109X	99,243
	Ebstein	A42P	244
NKX2.6	PTA	F157L	104

Genes	Cardiac phenotypes	Mutations*	Refs
TBX20	ASD, CoA	I152M, Q195X	7
	VSD	I152M	7
	PDA	I152M	7
	DCM	Q195X	7
	MS, HLV	Q195X	7
CITED2	VSD	S170_G178del	108
	ASD	G178_S179del, S198_G199del	108
FOXH1	TOF	V112M, D350G, P336L, S339G, S113T/S346G	10
	CHM	S16L, G267R, T242I, D328E	10
ZIC3	Heterotaxy	Various mutations	150,246
	TGA	W255G, K467X, K405E	148-150
	ASD, PS	A217P	150
TBX5	ASD, VSD, AVSD	G80R	247
TBX1	VSD	A379_G381del	155
	IAA	A466_A476dup	156
ANKRD1	TAPVR	T116M	110
Sarcomeric proteins			
MYH11	PDA, aorta aneurysm	L1456_N1526del, R1241_L1264del	111
ACTC1	ASD, VSD	M123V, c.215_231del17, E101K, G99L	54,122,123
MYH6	ASD	I820N	53
MYH7	ASD, Ebstein	R281T, F230S	55
MYBPC3	ASD, VSD	Various mutations	117-119
Miscellaneous			
FLNA	XMVD	G288R, V711D, P637Q, deletion exons 16-19	135
ELN	SVAS	Various mutations	140
TLL1	ASD	M182L, A238V, L627V	144
THRAP2	TGA	R1872H, D2023G	143

* Mutations in the open reading frame are described at the protein level.
AS, aortic valve stenosis; ASD, atrial septal defect; AV, atrioventricular; AVSD, atrioventricular septal defect; BAV, bicuspid aortic valve; CHM, congenital heart malformation; CoA, coarctation of the aorta; DORV, double outlet right ventricle; HLHS, hypoplastic left heart syndrome; HLV, hypoplastic left ventricle; HRV, hypoplastic right ventricle; IAA, interrupted aortic arch; MS, mitral valve stenosis; NS, not specified; PA, pulmonary atresia; PAPVR, partial anomalous pulmonary venous retour; PDA, patent ductus arteriosus; PS, pulmonary valve stenosis; PTA, persistent truncus arteriosus; RV, right ventricle; SVAS, supravalvular aortic stenosis; TAPVR, total anomalous pulmonary venous retour; TGA, transposition of the great arteries; TOF, tetralogy of Fallot; VSD, ventricular septal defect; XMVD, X-linked myxomatous valvular dystrophy

FOG2

A minority of patients with TOF have a mutation in the *FOG2* gene [89], whereas patients with chromosomal breakpoints at 8q22, possibly involving *FOG2*, often show TOF [90] (Tables 2 and 6). Also *Fog2* knockout mouse embryos exhibit TOF [91,92]. FOG2 (Friend Of GATA) is a multi-zinc-finger transcription factor modulating the transcriptional activity of GATA4 (Figure 1).

NKX2.5

Mutations in the *NKX2.5* (*NKX2E, CSX*) gene cause various CHM, including ASD and VSD, atrioventricular conduction defects, TOF, subvalvular aortic stenosis (AS), pulmonary atresia, Ebstein anomaly, ventricular hypertrophy, cardiomyopathy and ventricular noncompaction [5,78,93-101] (Tables 2 and 6). Most *NKX2.5* mutations are found in familial atrioventricular block with ASD [5,93,99] and TOF [100,101]. In other CHM *NKX2.5* mutations are uncommon [101]. *Nkx2.5* knockout mice lack the primordium of the AV node [102], whereas ventricular-restricted *Nkx2.5* knockouts display complete heart block and massive trabecular muscle [103]. NKX2.5 is a homeobox transcription factor contributing to diverse cardiac developmental pathways through interaction with the network of transcriptional regulators of heart morphogenesis (Figure 1).

NKX2.6

Only a single mutation in the *NKX2.6* gene has been associated with CHM, in a consanguineous family with persistent truncus arteriosus (PTA) [104] (Tables 2 and 6). Targeted disruption of *Nkx2.6* in mice did not result in an abnormal cardiac phenotype [105]. NKX2.6 is a homeobox transcription factor with great homology to NKX2.5, but its transcriptional targets are unknown (Figure 1).

TBX20

Mutations in the *TBX20* gene have been found in a minority (< 1 %) of CHM patients [7]. A missense mutation has been found in a family with autosomal dominant inheritance of septal defects [7]. A truncating mutation was present in a family with autosomal dominant inheritance of septal defects, LVOTO anomalies including mild CoA, mitral valve stenosis, hypoplastic left ventricle (HLV) and cardiomyopathy [7] (Tables 2 and 6). Heterozygous *Tbx20* knockout mice show atrial septal abnormalities and dilated cardiomyopathy, whereas homozygous mutants show a rudimentary heart that lacks chamber myocardium [106]. TBX20 is a cardiac T-box factor that interacts with other cardiac transcription factors, including NKX2.5, GATA4, and TBX5 [107] (Figure 1).

CITED2

Mutations in the *CITED2* gene have been identified in about 1 % of sporadic patients with various CHM, including ASD and VSD, and anomalous pulmonary venous return [108] (Tables 2 and 6). *Cited2* -/- embryos die with ASD and VSD, overriding aorta, DORV, PTA, and right-sided aortic arches [109]. These mutant mice lack expression of Pitx2c that is a target gene in the Nodal pathway. CITED2 (CBP/p300-interacting transactivator with E/D-rich c-terminal domain, type 2) is a member of the CITED family of cofactors that are involved in regulating a wide variety of CBP/p300-dependent transcriptional responses. CITED2 is a transcriptional co-activator of TFAP2 (Figure 1). One of the TFAP2 transcription factor genes *TFAP2B* is

involved in Char syndrome, which is a syndromic CHM characterized by patent ductus arteriosus (PDA) (Figure 1).

ANKRD1

In a patient with total anomalous pulmonary venous return (TAPVR) showing a de novo 10;21 balanced translocation, the *ANKRD1* gene was found disrupted [110]. An *ANKRD1* missense mutation has been found in another sporadic patient with TAPVR, suggesting that *ANKRD1* gene possibly plays a role in TAPVR [110]. The *ANKRD1* gene, encodes a transcriptional regulator that belongs to the muscle ankyrin repeat protein (MARP) family.

Sarcomeric protein genes

MYH11

Mutations in the *MYH11* gene encoding the myosin heavy chain 11 are responsible for a specific form of familial thoracic aortic aneurysm and/or dissection (TAAD) with PDA [111] (Tables 2 and 6). Patients with a *MYH11* mutation exhibit a severe decrease in the elasticity of the aortic wall. This is consistent with the role of myosin heavy chain 11 in smooth muscle cells in maintaining the mechanical properties of the thoracic aorta. The perinatal changes of the ductus arteriosus require smooth muscle cells to migrate, proliferate, differentiate, and contract [112]. As evidenced by the presence of PDA in these patients and in *Myh11* -/- mice [113], myosin heavy chain 11 is also involved in the perinatal closure of the ductus arteriosus. Myosin heavy chain 11 is a sarcomeric protein that is expressed in smooth muscle cells of the ductus arteriosus and arterial walls (Figure 1).

MYH6

A single missense mutation in the *MYH6* gene has been found in an autosomal dominant family with ASD [53] (Table 2 and 6). Knockdown expression of Myh6 in chicken prevents atrial septum formation [53]. *Myh6* cardiac expression is regulated by the transcription factor Tbx5 in physical interaction with Mef2c [114]. Mutations in *TBX5* reduce activation of the *MYH6* promotor and lead to ASD in Holt-Oram syndrome. Similarly, *GATA4* mutations associated with ASD also affect *MYH6* promotor activation [8] (Figure 1). In heterozygous mice, ablation of the *Myh6* gene leads to focal fibrotic lesions and cardiac myocyte disarray with impairment of both contractility and relaxation, but no septal defects [115]. *MYH6* encodes the alpha-myosin heavy chain, a cardiac sarcomeric protein that is part of the contractile unit of cardiovascular muscle and expressed at high levels in the developing atria.

MYH7

Recently, mutations in the *MYH7* have been shown to cause CHM including Ebstein anomaly and septal defects [55] (Tables 2 and 6). *MYH7* is a cardiac sarcomeric protein gene frequently involved in different forms of cardiomyopathy. Homozygous mutant mice die within a week after birth, while heterozygous mice display hypertrophic cardiomyopathy (HCM), but no CHM [116]. *MYH7* encodes the beta-myosin heavy chain, a cardiac sarcomeric protein that is part of the myosin thick filament of cardiovascular muscle.

MYBPC3

Whereas heterozygous mutations in the *MYBPC3* gene are a frequent cause of HCM, compound heterozygosity or homozygosity for truncating mutations in the *MYBPC3* gene not only causes lethal forms of cardiomyopathy, but also septal defects. Several Old Order Amish with lethal HCM, PDA and septal defects (apical muscular VSD, and ASD) have a homozygous truncating mutation in *MYBPC3* [117,118]. Septal defects were also present in neonates with severe HCM due to compound heterozygous truncating mutations [119] (Tables 2 and 6). Transgenic mice with mutant *Mybpc3* exhibit mild ventricular hypertrophy, but no septal defects or other CHM [120]. *MYBPC3* encodes a cardiac sarcomeric protein cardiac myosin-binding protein C that modulates myosin, assembly actin–myosin interaction in sarcomeres and stabilizes thick filaments [121].

ACTC1

ACTC1 is another sarcomeric protein gene implicated in HCM, dilated cardiomyopathy (DCM), and noncompaction cardiomyopathy (NCCM). A founder mutation E101K in Spanish families with apical HCM/NCCM also causes secundum ASD or atrial septum aneurysm in multiple patients, and VSD in one patient [54]. In another family with apical HCM due to a *ACTC1* missense mutation (G99K) one patient also had ASD [122]. In two large Swedish families with autosomal dominant inheritance of ASD without cardiomyopathy a founder mutation M123V was identified [123] (Table 2). However, the frequency of *ACTC1* mutations in ASD overall is low (1-2 %), and no *ACTC1* mutations were found in various other types of CHM [123]. Actin knockdown in chick embryos produces less developed atrial septa [123]. Mice lacking cardiac actin do not show gross cardiac anomalies, but increased apoptosis in the atrial and ventricular septa [124]. Also in the pathogenesis of human secundum ASD apoptosis may play an important role [125]. The *ACTC1* gene encodes the cardiac actin protein that is an essential structural component of the thin filaments of sarcomeres. One end of the actin filament forms cross bridges with myosin to generate force, whereas the other end is immobilized and anchored to α-actinin in the Z disc. *ACTC1* mutations in patients with ASD seem to reduce affinity of actin for myosin [123].

Miscellaneous genes

GJA1

Mutations in *GJA1* have been reported in various forms of CHM by the group of Britz-Cunningham [126]. However, several other groups were unable to find Cx43 mutations in CHM patients [127-132], and it has been suggested that the mutations identified by the Britz-Cunningham group were not located in *GJA1*, but in the highly homologous *GJA1* pseudogene. Complex mutations indicative of illicit recombination between *GJA1* and the *GJA1* pseudogene have been found in heart tissue from patients with HLHS [133]. Cx43-null mice show delayed looping [134]. *GJA1* encodes a gap junction protein connexin 43 (Cx43), which facilitates cell-to-cell adhesion and intercellular communication.

FLNA

Four different mutations within the same region (repeat 1 to 7) of the X-linked *FLNA* gene encoding

Filamin A have been identified in families affected by valvular dystrophy [135] (Table 2). Loss-of-function *FLNA* mutations are lethal in males, while in females they result in periventricular nodular heterotopia associated with aortic aneurysms, valve regurgitation and overlapping features of Ehlers-Danlos syndrome [136,137]. Mutations that conserve the reading frame lead to a broad range of syndromes, including frontometaphyseal dysplasia, Melnick-Needles syndrome, and otopalatodigital syndrome type 1 (OPD1) and type 2 (OPD2). Flna-null mice die at midgestation with widespread hemorrhage from abnormal vessels, PTA, and septal defects [138]. The *FLNA* gene encodes filamin A, a large cytoplasmatic protein that crosslinks actin filaments and participates in the anchoring of the actin cytoskeleton to membrane proteins.

Elastin

A common microdeletion within chromosomal band 7q11.2 encompassing the *ELN* gene causes Williams syndrome, a syndromic CHM with supravalvular aortic stenosis, poststenotic aortic aneurysms, sometimes associated with arterial stenosis, mainly of pulmonary arteries. Intragenic *ELN* mutations result in the same spectrum of CHM [139,140] (Table 2). Some patients with *ELN* mutations also show bilateral inguinal hernias, cutis laxa, pulmonary disease, and aortic aneurysm and dissection [141]. Transgenic mice hemizygous for the elastin gene show a compensatory increase in the number of elastic lamellae and smooth muscle in their arteries, resulting in arterial stenosis [142]. The *ELN* gene encodes elastin that forms the amorphous component of elastic fibers that are abundantly present in arteries.

THRAP2

Mutations in the *THRAP2* gene are present in 3% of patents with non-syndromic TGA [143] (Table 2). The *THRAP2* gene encodes a TRAP240-like protein, which belongs to the TRAP complex of proteins associated with the thyroid hormone receptor.

TLL1

Missense mutations in *TLL1* have been described in patients with ASD, although the significance of these mutations is not clear as only a limited group of 15 healthy control were screened, no family members were screened for these mutations and no functional analysis of these mutations was performed [144]. Mice with a disrupted *Tll1* gene display incomplete formation of the muscular interventricular septum and abnormal positioning of the heart and aorta [145]. The *TLL1* gene encodes Tolloid-like-1, an astacin-like metalloprotease that is highly similar to the morphogenetically bone morphogenetic protein-1 (BMP1).

Genes implicated in syndromic CHM

Some genes implicated in syndromic forms of CHM have also been found to cause non-syndromic CHM with no or subtle non-cardiac features. These genes include *JAG1* (Alagille syndrome), *ZIC3* (X-linked heterotaxy), *TBX1* (22q11.2 deletion syndrome), *TBX5* (Holt-Oram syndrome) and *TFAP2β* (Char syndrome).

JAG1

JAG1 (JAGGED1) mutations have not only been found in patients with Alagille syndrome, but also in non-syndromic right-sided heart defects such as PS and TOF [146,147] (Tables 2 and 6). Jagged 1 is a ligand for the NOTCH receptors (Figure 1). Also *NOTCH2* mutations have been shown to cause Alagille syndrome, but not non-syndromic CHM.

ZIC3

ZIC3 mutations typically result in X-linked heterotaxy, a combination of left-right asymmetry defects, including complex cardiac anomalies, altered lung lobation, splenic and hepatobiliary abnormalities, and gut malposition. *ZIC3* mutations have also been found in non-syndromic CHM such as TGA, ASD and PS [148-150] (Tables 2 and 6). *Zic3* mutant mice, exhibit heterotaxy, neural tube defects, and vertebral and rib anomalies [151]. ZIC3 is a zinc finger transcription factor that acts as an enhancer of the NODAL signaling pathway (Figure 1).

TBX1

A common microdeletion within chromosomal band 22q11.2 encompassing the *TBX1* gene causes the velocardiofacial syndrome (22q11.2 syndrome), which is a major cause of CHM. Although intragenic *TBX1* mutations have later been shown to cause most of the anomalies of the microdeletion patients [152-154], they can also be associated with non-syndromic CHM, including VSD and IAA [155,156]. *TBX1* encodes a T-box transcription factor which is expressed in neural crest cells (Figure 1).

TBX5

Whereas *TBX5* null alleles usually lead to classical Holt-Oram syndrome, some patients with a *TBX5* missense mutation (eg. the G80R mutation) have non-syndromic CHM with very limited limb anomalies, but severe cardiac defects [157,158] (Table 2). *TBX5* belongs to the Brachyury (T) family, which encodes transcription factors sharing a common DNA-binding motif, the T-box. The TBX5 protein associates with other cardiac transcription factors including GATA4 and NKX2.5, and synergistically activates different cardiac effector target genes (Figure 1).

TFAP2β

Char syndrome is caused by mutations in the *TFAP2β* gene. Although most *TFAP2B* mutations lead to PDA associated with typical facial dysmorphism, patients with the P62R mutation show PDA with only mild facial features [159,160] (Table 2). *TFAP2β* is a transcription factor expressed in neural crest cells (Figure 1).

Reduced-penetrance mutations in susceptibility genes

The hypothesis of the multifactorial inheritance of common diseases suggests that multiple genetic risk factors with reduced penetrance (intermediate or low) superposed on unfavorable environmental factors lead to disease. These risk factors can be rare variants with intermediate penetrance (Table 3) or common gene variants with low penetrance (Table 4).

Rare variants with intermediate penetrance

Rare variants with intermediate penetrance have been associated with CHM, but for most of them there is only limited evidence that they contribute to CHM (Table 3). Most of these mutations are missense mutations in sporadic patients with CHM whose unaffected family members (usually one of the parents) also show this DNA variation; in other cases the mutation is also present in the control population, albeit with a lower frequency. The latter is then considered circumstantial evidence of low penetrance. However, in many cases the functional significance of such missense mutations is unknown, and they could be either nonfunctional polymorphisms or disease mutations with reduced penetrance. Additionally, multiple rare variants sometimes can be found in a single patient, implying a cumulative effect and consequently a reduced penetrance for the individual mutations, as shown for the NODAL pathway [10]. Most studies involve mutation analysis of the open reading frame of genes already implicated in CHM by the presence of high-penetrance monogenic mutations leading to the respective CHM. As variations can also be located in gene control regions the mutations described below might underrepresent the overall amount of intermediate-penetrance mutations.

The different rare variants with intermediate penetrance implicated in non-syndromic CHM are discussed below (Table 3).

CRELD1

Several *CRELD1* missense mutations have been reported in patients with isolated atrioventricular septal defect (AVSD) [161,162] and in 2 patients with Down syndrome, which is the main cause of AVSD [163]. These missense mutations were also found in unaffected parents or other family members, indicating incomplete penetrance of these mutations [161,162] (Table 3). The *CRELD1* gene located on chromosome 3p is also deleted in patients with the 3p- syndrome, which is often associated with CHM, typically AVSD [162,164]. The *CRELD* family of genes encodes for cell adhesion molecules containing cysteine-rich epidermal growth factor (EGF)-like domains, which mediate interactions between proteins of diverse function.

NKX2.5

The identification of *NKX2.5* missense mutations in normal parents of children affected with CHM (and in some cases also in healthy controls) indicates that some of these mutations might have reduced penetrance [100,101] (Table 3).

NOTCH1

In a large series of patients with BAV and/or LVOTO a *NOTCH1* missense mutation with functional significance was demonstrated in almost 7% of patients. Some of these mutations were also present in unaffected parents although echocardiography was only performed in approximately one third of cases. These mutations could therefore represent rare variants with reduced penetrance [61] (Table 3).

GATA4

GATA4 missense mutations in patients with ASD [81], or AVSD [83] were also found in some of their non-affected parents or family members, indicating that some of these mutations might have reduced penetrance (Table 3).

NODAL

In 10 % of Hispanic patients with heterotaxy a G260R mutation in the *NODAL* gene was found, which was shown to exhibit significant impairment of NODAL signaling. As this mutation was also present in one unaffected parent and a control, it must be considered as a rare variant with reduced penetrance [57] (Table 3). Mutations in different genes involved in the NODAL signaling pathway (*NODAL*, *FOXH1*, *CFC1* and *GDF1* [10]) co-occur, suggesting a cumulative effect of mutations leading to reduced NODAL signaling.

CFC1

The R78W mutation in the *CFC1* gene, which is common in African-American patients with heterotaxy [68,75], significantly impairs NODAL signaling, but is also found in controls, and must therefore be considered as a rare variant. Also other *CFC1* variants with reduced penetrance have been reported [10,75,165] (Table 3). Patients with a *CFC1* mutation may show a second mutation in other NODAL pathway components, including the *GDF1* and *FOXH1* genes [10]. Altogether these findings suggest that rare variants in *CFC1* may represent genetic factors with reduced penetrance for heterotaxy and other CHM.

FOXH1

FOXH1 mutations are among the most common mutations found in CHM (mainly TOF), but several of these patients show a second mutation in the *CFC1* gene, another component of the NODAL pathway, indicating a cumulative effect of mutations leading to reduced NODAL signaling [10] (Table 3).

GDF1

A single patient with undefined CHM has been reported to have both a missense mutation R68H in the *GDF1* gene and a missense mutation F162L in the *CFC1* gene [10] (Table 3). Assuming functional significance of both mutations, this further indicates a cumulative effect of different mutations leading to reduced NODAL signaling.

MYOCD

A single *MYOCD* missense mutation has been found in a patient with PS. This functionally important variant was also present in 0.5% of Hispanic controles (Table 3). Selectively ablation of the *Myocd* gene in neural crest-derived smooth muscle cells in mice resulted in PDA [166]. *MYOCD* encodes for Myocardin, a transcriptional coactivator of serum response factor (SRF) that plays a role in myocardial and vascular smooth muscle cell differentiation.

THRAP2

The missense mutation reported in a patient with TGA was also present in the healthy mother of this parent, indicating reduced penetrance [143].

Common variants with low penetrance

Susceptibility genes with low-penetrance mutations (commen variants) are being identified at high speed for various common disorders using genome-wide association studies (GWAS). In these studies hundred thousands of SNPs (Single Nucleotide Polymorphisms) are analyze simultaneously in large numbers of patients and controls using high-technological platforms. GWAS studies have not yet been performed in CHM. However, small-scale case-control studies have identified common variants contributing to CHM. As the numbers of individuals (both patients and controls) included in most of these studies are limited the conclusions are often tentative; furthermore, many studies are contradictory and have not been replicated. The different common variants with low penetrance implicated in non-syndromic CHM are discussed below (Table 4).

Table 3 | Rare variants with intermediate penetrance contributing to non-syndromic CHM

Gene	Function	Cardiac phenotypes	Intermediate-penetrance mutations*	Refs
CRELD1	Matricellular protein	AVSD	R329C, T311I, P162A, E414K	161-163,248
		AVSD, dextrocardia	R107H	161
NKX2.5	Transcription factor	TOF	R25C, E21Q, A219V	100,101,245
		ASD-AV block	K15I	101
		DORV	N291del	101
NOTCH1	Transcription factor	LVOTO	A683T, G661S	61
GATA4	Transcription factor	ASD	D425N, G93A	81
		AVSD	P163S, A346V	83
NODAL	Ligand	Heterotaxy-CHM	G260R	57
THRAP2	Receptor associated protein	TGA	E251G	143
MYOCD	Regulator	PS	K259R	249
CFC1	Receptor	TGA	R78W	75,165
		TOF	R78W, G174fs	10
		IAA	R78W	10
		DORV	G174fs, N21H, R47Q	75,165

*Mutations in the open reading frame are described at the protein level.
ASD, atrial septal defect; AV, atrioventricular; AVSD, atrioventricular septal defect; CHM, congenital heart malformation; DORV, double outlet right ventricle; IAA, interrupted aortic arch; LVOTO, left ventricular outflow tract obstruction; PS, pulmonary valve stenosis; TGA, transposition of the great arteries; TOF, tetralogy of Fallot

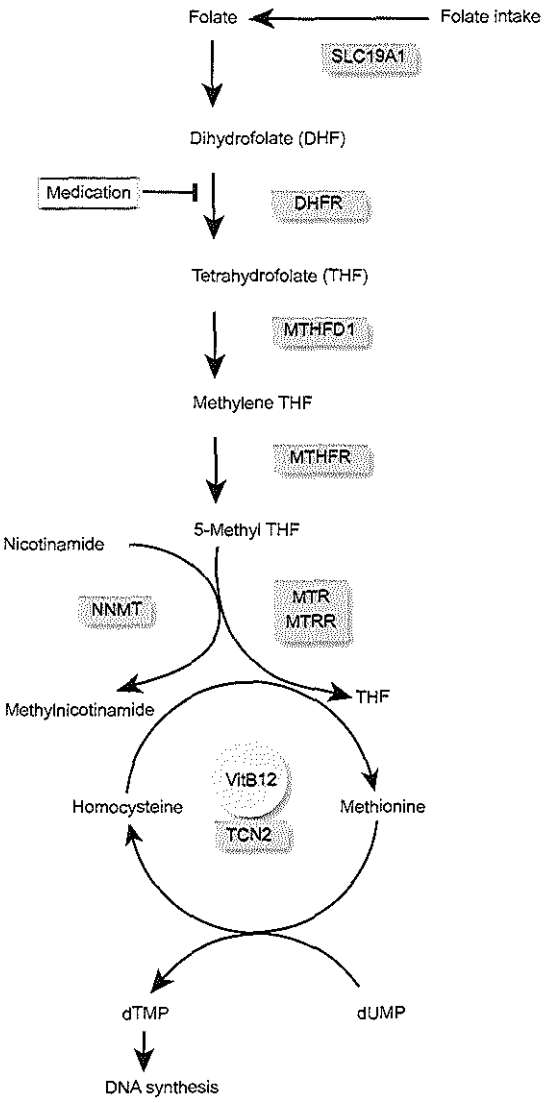

Figure 2 | Methylation cycle with different environmental and genetic risk factors for CHM Nutritional factors such as reduced folate and vitB12 intake, and common variants in the *SLC19A1*, *MTHFD1*, *MTHFR*, *MTRR*, *NNMT*, and *TCN2* genes might lead to decreased availability of methionine necessary for DNA synthesis. Folic acid antagonists, including medication such as trimethoprim, triamterene, carbamazepine, phenytoin, phenobarbital, and primidone, may increase the risk for CHM by inhibiting Dihydrofolate reductase (DHFR).

MTHFR

Different enzymes including MTHFR, MTHFD1, MTRR, SLC19A1 and NNMT are implicated in the methylation cycle through the conversion of homocysteine into methionine (Figure 2). 5,10-Methylenetetrahydrofolate reductase (MTHFR) is an enzyme that converts methylene THF into 5-methyl THF. The latter is a cofactor for methionine synthase (MTR) and MTR reductase (MTRR), two enzymes that convert homocysteine into methionine. Several studies have reported inconsistent associations between *MTHFR* variants and CHM, but a meta-analysis of published studies concluded that the common *MTHFR* variants A222V (c.677C>T) and E429A (c.1298A>C) on patient or maternal genotypes were not significantly associated with CHM [19].

MTHFD1

The *MTHFD1* gene encodes a trifunctional protein involved in the interconversion of folate to methylene tetrahydrofolate (THF). The latter is converted to 5-methyl THF by MTHFR (Figure 2). The c.1958G>A variant, leading to the missense mutation R653Q in *MTHFD1,* decreases MTHFD1 enzyme stability and activity. Homozygosity for this variant (present in approximately 20 % of the European population) is associated with an increased risk for CHM, particularly TOF and AS [167]. This effect could only be demonstrated for the R653Q mutation on the patient's genotype, but not on the maternal genotype (Table 4).

MTRR

The *MTRR* gene encodes the MTR activator methionine synthase reductase enzyme. MTRR restores the activity of methionine synthase (MTR), the enzyme that converts homocysteine into methionine using 5-methyl THF as a cofactor (Figure 2). Homozygosity for the I22M variant (c.66A>G) in the mother [168] in combination with low maternal serum vitB12 [12] is associated with an increased risk for different types of CHM in offspring (Table 4).

SLC19A1 (RFC1)

Transport of folate compounds into mammalian cells can occur via receptor-mediated or carrier-mediated mechanisms. One of the genes involved in carrier-mediated transport is the *SLC19A1* gene encoding the reduced folate carrier-1 (Figure 2). Offspring carrying the G allele for the c.80A>G variation have been reported to show an increased risk for CHM [169] (Table 4).

NNMT

Apart from the *MTHFR, MTHFD1, MTRR* and *SLC19A1* genes that are involved in folate metabolism, also the nicotinamide N-methyltransferase (*NNMT*) gene may be a genetic determinant of plasma homocysteine levels. Nicotinamide N-methyltransferase catalyses the methylation of nicotinamide and other pyridines using methyl groups generated in the methylation cycle of homocysteine-methionine (Figure 2). A G>A variant in intron 1 in both the maternal and fetal *NNMT* gene are associated with an increased CHM risk, but only on a background of periconceptional exposure to medicines and/or a low dietary nicotinamide intake [11] (Table 4).

TCN2

The *TCN2* gene encodes transcobalamin 2, which is the main transporter of vitB12 (cobalamin), an essential vitamine in the synthesis of methionine (Figure 2). Maternal and fetal homozygosity for the P259R variant (c.776C>G) in combination with low maternal serum vitB12 have been reported to cause an increased risk for different types of CHM in offspring [12] (Table 4).

NPPA

The *NPPA* gene encodes atrial natriuretic peptide (ANP) that has natriuretic-diuretic activity important in the control of extracellular fluid volume and electrolyte homeostasis. ANP is a cardiac effector hormone secreted from the cardiac atria to decrease blood pressure and cardiac hypertrophy by interac-

tion with different transcription factors and sarcomeric proteins (Figure 1). The G664A variant in the *NPPA* gene is reported to cause an increased risk for conotruncal defects [170] (Table 4).

NOS3

Endothelial nitric oxide synthase (eNOS) encoded by the *NOS3* gene converts l-arginine into nitric oxide, which plays a role in vasodilatation and in the regulation of cell growth and apoptosis (Figure 1). Homozygozity for the common c.894G>T (E298D) variation in combination with maternal smoking causes an increased risk of CHM [13] (Table 4).

VEGF

VEGF (vascular endothelial growth factor) is a mitogen that specifically acts on endothelial cells and belongs to a family of regulatory peptides controling blood vessel formation by interacting as a ligand with the endothelial tyrosine kinase receptors FLT1 and KDR/FLK1 (Figure 1). The AAG haplotype of three variants -2578A, -1154A, and -634G located in the promoter and leader sequence of *VEGF* are known to lower VEGF levels. These common *VEGF* variants confer an increased risk for TOF, both in non-syndromic cases of TOF and syndromic cases with 22q11.2 deletions [171] (Table 4). Newborn mice lacking Vegf die of anomalies reminiscent of 22q11 deletion syndrome with typical cardiac malformations such as TOF [172]. *TBX1*, the gene implicated in 22q11 deletion syndrome, is most likely a down stream target of the VEGF pathway as Tbx1 expression is downregulated in these mice.

NFATC1

NFATC1 (Nuclear Factor of Activated T cells, cytoplasmic, Calcineurin-dependent 1) is a calcineurin-dependent transcription factor belonging to the NFAT family of transcription factors. Nfatc1 is involved in remodeling of endocardial cushions into mature heart valve leaflets by repression of Vegf expression in the myocardium underlying the site of prospective valve formation (Figure 1). Two of 21 patients with VSD were found to have a homozygous duplication of 44 nucleotides in intron 7 of the *NFATC1* gene, whereas homozygosity for this deletion was not observed in the control population, suggesting that *NFATC1* is a low penetrance susceptibility gene for VSD [173] (Table 4).

Table 4 | Common variants with low penetrance contributing to non-syndromic CHM

Gene	Function	Cardiac phenotypes	Low-penetrance mutations*	Refs
MTHFR	Methylation cycle	Various	A222V, E429A	170,210
MTHFD1	Methylation cycle	TOF, AS	R653Q	167
MTRR	Methylation cycle	Various	I22M	12,168
SLC19A1	Methylation cycle	Various	c.80A>G	169
NNMT	Methylation cycle	Various	G>A in intron 1**	11
TCN2	Methylation cycle	Various	P259R	12
NPPA	Vasoactive protein	Conotruncal defects	G664A	170
NOS3	Vasoactive protein	Conotruncal defects	E298D ***	170
VEGF	Polypeptide mitogen	VSD, PTA, IAA, TOF	-2578C>A, -1154G>A, -634G>C	171,172
NFATC1	Transcription factor	VSD	Duplication of 44 bp in intron 7	173

* Mutations in the open reading frame are described at the protein level.
** Increased risk for CHM when exposed to periconceptional medicines and/or a low dietary nicotinamide intake.
*** Increased risk for CHM in combination with maternal smoking.
AS, aortic valve stenosis; IAA, interrupted aortic arch; PTA, persistent truncus arteriosus; TOF, tetralogy of Fallot; VSD, ventricular septal defect

Chromosomal aberrations

Chromosomal aberrations are well-known causes of syndromic CHM and are detected in 8-13% of children with CHM by conventional cytogenetics alone [174]. After the introduction of fluorescence in situ hybridization (FISH) additional deletions in patients with CHM were identified, with the 22q11.2 deletion syndrome as the prime example of a frequent cause of CHM that escaped detection before the introduction of FISH [175]. With the recent introduction of array-based comparative genomic hybridization (array CGH) as a routine tool in diagnostics, many more chromosomal regions associated with CHM are being found. A high frequency of chromosomal imbalances was demonstrated in a selected group of patients with syndromic CHM [176]. Newly recognized microdeletion/duplication syndromes associated with CHM are the 22q11.1 duplication syndrome [177], the 9q34 deletion syndrome [178], the 17p11.2 deletion syndrome [179], the 16p11.2 deletion syndrome [180,181] and the 1q21.1 deletion syndrome [182-184]. These microdeletions/duplications associated with CHM are good candidate regions to identify CHM genes. Some of the known microdeletion syndromes, such as the 22q11.2 deletion syndrome, can present with CHM without obvious dysmorphic features and/or mental deficit. The recently recognized 1q21.1 microdeletion syndrome has an even more variable phenotype with incomplete penetrance [182-184]. In a large series of 1q21.1 deletion patients, 25% presented with CHM, including PDA, TA, CoA and BAV [183]. This deletion was also found in 3 out of 505 patients with non-syndromic CHM [184]. Overall a high frequency of chromosomal deletions, duplications and copy number variations (CNV) was recently found

in a series of non-syndromic patients with CHM [185]. These studies indicate that arrayCGH should be included in the diagnostic workup of patients with non-syndromic CHM.

Somatic mutations

Knudson has elegantly demonstrated how somatic mutations not present in the germline can contribute to genetic disease with his two-hit hypothesis [186]. There has been much interest in somatic mutations underlying cancer and this has been the subject of many reviews [187]. These somatic mutations not only include mutations affecting nuclear DNA leading to activation of oncogenes or inactivation of tumor suppressor genes, but also epigenetic alterations of DNA, and mitochondrial DNA mutations. The concept of somatic mosaicism has also been demonstrated in many different skin disorders, and several other diseases[188]. Surprisingly, many years after Knudson's theory gained universal acceptance, the concept of somatic mutations remained largely confined to tumor biology and skin disease. This might explain why the candidate gene approach for many non-syndromic malformations, including CHM, has had little success: mutation analysis in most cases still is usually performed in constitutional DNA, whereas the mutations might be somatic and limited to the affected tissue.

Over the last past years, the first somatic mutations confined to affected cardiovascular tissue have been reported in CHM. The genes in which somatic mutations have been found include *GJA1, NKX2.5, TBX5, GATA4, HEY2* and *HAND1* [189-195](Table 5). The group of Reamon-Buettner and Borlak has reported the majority of somatic mutations in CHM, including mutations in *NKX2.5, TBX5, GATA4, HEY2* and *HAND1*. Interestingly, in several patients different mutations in the same gene with cumulative down-regulation of transcription were reported [189-195]. Although only a limited number of studies have been performed, most likely due to the scarceness of affected cardiac tissue, the abundance of somatic mutations reported by the group of Reamon-Buettner and Borlak contrasts with the limited number of mutations in other studies. No *NKX2.5* gene mutations could be found in cardiac tissue from patients with BAV and associated aneurysm [196], and no somatic 22q11.2 deletions could be identified in heart tissue from patients with conotruncal heart defects without germ line 22q11.2 deletion [197]. Recently, no evidence for somatic *NKX2.5* mutations was found in a large series of fresh- frozen cardiac tissue taken near the septal defect of patients with ASD, VSD and AVSD [198]. The latter authors suggested that the poor DNA quality from the formalin-fixed tissue used by the group of Reamon-Buettner and Borlak may account for the high amount of somatic mutations in their study [198], although differences in the location of tissue sampling might also be important. Evidently, the role of somatic mutations in CHM awaits further confirmation.

Table 5 | Somatic mutations contributing to non-syndromic CHM

Gene	Function	Cardiac phenotypes	Somatic mutations*	Refs
GJA1	Gap junction protein	HLHS	Gene conversion	133
NKX2.5	Transcription factor	VSD, ASD, AVSD	Various missense mutations	192,193
GATA4	Transcription factor	VSD, AVSD	Various missense mutations	250,251
TBX5	Transcription factor	ASD, AVSD	Various missense mutations	191
HEY2	Transcription factor	AVSD	T96A, D98A, L100S	190
HAND1	Transcription factor	HLV, HRV	A126fs	195

*Mutations in the open reading frame are described at the protein level.
ASD, atrial septal defect; AVSD, atrioventricular septal defect; HLHS, hypoplastic left heart syndrome; HLV, hypoplastic left ventricle; HRV, hypoplastic right ventricle; VSD, ventricular septal defect

Table 6 | Genes involved in non-syndromic CHM

CHM	BAV / AS	VSD	ASD	PS	TOF	AVSD	TGA	HLHS	DORV	Heterotaxy
Incidence**	14 / 0.8	4	1.0	0.7	0.4	0.3	0.2	0.2	0.16	0.1
Genes	*NOTCH1*	*NKX.2.5*(*)*	*NKX2.5*(*)*	*GATA4*	*NKX2.5*	*GATA4*	*NKX2.5*	*NKX2.5*	*NKX2.5*	*ZIC3*
		GATA4	*GATA4*	*MYOCD*	*GATA4*	*CRELD1*	*THRAP2*	*NOTCH1*	*GDF1*	*GDF1*
		TBX20	*TBX20*	*JAG1*	*TBX1*	*CFC1*	*ZIC3*	*HAND1**	*CFC1*	*CFC1*
		TBX1	*MYH6*		*FOG2*	*GDF1*	*CFC1*	*GJA1**		*LEFTY2*
		ACTC1	*ACTC1*		*CFC1*	*NKX2.5**	*GDF1*			*ACVR2B*
		MYBPC3	*MYH7*		*NOTCH1*	*TBX5**	*THRAP2*			*NODAL*
		TBX5	*MYBPC3*		*GDF1*	*HEY2**				*NKX2.5*
		CITED2	*TBX5*(*)*		*TDGF1*	*PTPN11*				*CRELD1*
			CITED2		*JAG1*					
			TLL1		*FOXH1*					

AS, aortic valve stenosis; ASD, atrial septal defect; AVSD, atrioventricular septal defect; BAV, bicuspid aortic valve; CHM, congenital heart malformation; DORV, double outlet right ventricle; HLHS, hypoplastic left heart syndrome; PS, pulmonary valve stenosis; TGA, transposition of the great arteries; TOF, tetralogy of Fallot; VSD, ventricular septal defect
* somatic mutations, (*) both germline and somatic mutations
**per 1000 live-births

The "multifactorial inheritance" hypothesis

The overall recurrence risk of non-syndromic CHM (defined as the risk of a child with CHM after a previous child with CHM) is usually in the order of 2-10 % [199-206]. Empirical risk studies have revealed higher recurrence risks for specific subsets of CHM, indicating that genetic factors may play a more prominent role in CHM such as ASD, AVSD, and LVOTO. Several studies have indicated a higher risk for offspring of a mother with CHM than for the children of a father with CHM [9,207,208]. Theoretically, this could be due to maternal inheritance, imprinting, maternal environmental factors, but no exact data to explain this discrepancy have been reported.

The "multifactorial inheritance" hypothesis of common diseases suggests that the interaction and cumulative effect of multiple genetic and environmental risk factors leads to disease. One of the arguments underlying the multifactorial hypothesis is the observation that the overall recurrence risk of non-syndromic CHM is 2-10 %; as this is intermediate between the high risk present in monogenic cases and the negligible risk in case of non-genetic CHM, the existence of reduced-penetrance mutations in susceptibility genes has been suggested. However, only a limited number of common gene variants with low penetrance or rare variants with intermediate penetrance have been reported to date (Tables 2-4). Furthermore, few interactions of risk factors for CHM have been reported up to now. *MTHFR* polymorphisms might have an effect on heart development when present with other risk factors such as smoking, hyperhomoysteinaemie [209] or nutrient deficiencies [210]. Some evidence of an increased risk of conotruncal defects in infants of mothers who smoked cigarettes periconceptional and who had a *NOS3* gene variant has been reported [170]. Maternal and fetal variants in the *MTRR* gene (c.66A>G) and in the transcobalamin II gene (c.776C>G) have been reported to be associated with an increased risk for different types of CHM in offspring only in combination with low maternal serum vitamin B12 [12]. The A allele in intron 1 of the *NNMT* gene causes an increased CHM risk only on a maternal background of low dietary nicotinamide intake and periconceptional use of certain drugs [11]. *VEGF* common variants associated with lower VEGF level confer an increased risk for TOF in patients with 22q11 deletions [171], possibly due to the fact that *TBX1*, the gene implicated in 22q11 deletion syndrome, is a downstream target of VEGF (Figure 1). Another example of gene-environment interaction is the increase in risk of ASD reported in offspring of women with low-activity variants of Glutathione-S-transferase when exposed to specific solvents metabolized by Glutathione-S-transferase [211].

The NODAL signaling pathway is a paradigm for multifactorial inheritance of CHM. A minority of patients with heterotaxy [68] or heterotaxy-related HCM such as looping defects (TGA, DORV) [75] or CHM including TOF show several mutations in genes belonging to the NODAL signaling pathway, including the *NODAL*, *CFC1*, *FOXH1* and *GDF1* genes [10]. As the functional significance of each of these mutations could be demonstrated, the cumulative effects of multiple mutations may lead to reduced NODAL signaling eventually resulting in CHM.

Conclusions

The genetics of non-syndromic CHM remains unclear to a large extent: the low percentage of single gene mutations with high or intermediate penetrance argues against a prominent role of such mutations in non-syndromic CHM, the existence of somatic mutations in CHM heart tissue is still a matter of debate, and common variants seem to have a limited contribution. Although more than 40 different genes have already been shown to be implicated in non-syndromic CHM, many human genes are expected be identified within the coming years taking into account the large number of genes that have been shown to play a role in mice cardiogenesis. It is expected that the massive sequencing power of next-generation sequencers will be instrumental in the identification of additional genes implicated in CHM. Furthermore, such studies might shed lights on the interaction of different genetic factors, and finally prove or refute the multifactorial model.

References

1. Hoffman JI, Kaplan S. 2002. The incidence of congenital heart disease. J Am Coll Cardiol 39:1890-1900.
2. Pierpont ME, Basson CT, Benson DW, Jr., Gelb BD, Giglia TM, Goldmuntz E, McGee G, Sable CA, Srivastava D, Webb CL. 2007. Genetic basis for congenital heart defects: current knowledge: a scientific statement from the American Heart Association Congenital Cardiac Defects Committee, Council on Cardiovascular Disease in the Young: endorsed by the American Academy of Pediatrics. Circulation 115:3015-3038.
3. Ransom J, Srivastava D. 2007. The genetics of cardiac birth defects. Semin Cell Dev Biol 18:132-139.
4. Weismann CG, Gelb BD. 2007. The genetics of congenital heart disease: a review of recent developments. Curr Opin Cardiol 22:200-206.
5. Schott JJ, Benson DW, Basson CT, Pease W, Silberbach GM, Moak JP, Maron BJ, Seidman CE, Seidman JG. 1998. Congenital heart disease caused by mutations in the transcription factor NKX2-5. Science 281:108-111.
6. Garg V. 2006. Molecular genetics of aortic valve disease. Curr Opin Cardiol 21:180-184.
7. Kirk EP, Sunde M, Costa MW, Rankin SA, Wolstein O, Castro ML, Butler TL, Hyun C, Guo G, Otway R, Mackay JP, Waddell LB, Cole AD, Hayward C, Keogh A, Macdonald P, Griffiths L, Fatkin D, Sholler GF, Zorn AM, Feneley MP, Winlaw DS, Harvey RP. 2007. Mutations in cardiac T-box factor gene TBX20 are associated with diverse cardiac pathologies, including defects of septation and valvulogenesis and cardiomyopathy. Am J Hum Genet 81:280-291.
8. Garg V, Kathiriya IS, Barnes R, Schluterman MK, King IN, Butler CA, Rothrock CR, Eapen RS, Hirayama-Yamada K, Joo K, Matsuoka R, Cohen JC, Srivastava D. 2003. GATA4 mutations cause human congenital heart defects and reveal an interaction with TBX5. Nature 424:443-447.
9. Burn J, Brennan P, Little J, Holloway S, Coffey R, Somerville J, Dennis NR, Allan L, Arnold R, Deanfield JE, Godman M, Houston A, Keeton B, Oakley C, Scott O, Silove E, Wilkinson J, Pembrey M, Hunter AS. 1998. Recurrence risks in offspring of adults with major heart defects: results from first cohort of British collaborative study. Lancet 351:311-316.
10. Roessler E, Ouspenskaia MV, Karkera JD, Velez JI, Kantipong A, Lacbawan F, Bowers P, Belmont JW, Towbin JA, Goldmuntz E, Feldman B, Muenke M. 2008. Reduced NODAL signaling strength via mutation of several pathway members including FOXH1 is linked to human heart defects and holoprosencephaly. Am J Hum Genet 83:18-29.
11. van Driel LM, Smedts HP, Helbing WA, Isaacs A, Lindemans J, Uitterlinden AG, van Duijn CM, de Vries JH, Steegers EA, Steegers-Theunissen RP. 2008. Eight-fold increased risk for congenital heart defects in children carrying the nicotinamide N-methyltransferase polymorphism and exposed to medicines and low nicotinamide. Eur Heart J 29:1424-1431.
12. Verkleij-Hagoort AC, van Driel LM, Lindemans J, Isaacs A, Steegers EA, Helbing WA, Uitterlinden AG, Steegers-Theunissen RP. 2008. Genetic and lifestyle factors related to the periconception vitamin B12 status and congenital heart defects: a Dutch case-control study. Mol Genet Metab 94:112-119.

13. van Beynum IM, Mooij C, Kapusta L, Heil S, den Heijer M, Blom HJ. 2008. Common 894G>T single nucleotide polymorphism in the gene coding for endothelial nitric oxide synthase (eNOS) and risk of congenital heart defects. Clin Chem Lab Med 46:1369-1375.
14. Mone SM, Gillman MW, Miller TL, Herman EH, Lipshultz SE. 2004. Effects of environmental exposures on the cardiovascular system: prenatal period through adolescence. Pediatrics 113:1058-1069.
15. Jenkins KJ, Correa A, Feinstein JA, Botto L, Britt AE, Daniels SR, Elixson M, Warnes CA, Webb CL. 2007. Noninherited risk factors and congenital cardiovascular defects: current knowledge: a scientific statement from the American Heart Association Council on Cardiovascular Disease in the Young: endorsed by the American Academy of Pediatrics. Circulation 115:2995-3014.
16. Verkleij-Hagoort AC, Verlinde M, Ursem NT, Lindemans J, Helbing WA, Ottenkamp J, Siebel FM, Gittenberger-de Groot AC, de Jonge R, Bartelings MM, Steegers EA, Steegers-Theunissen RP. 2006. Maternal hyperhomocysteinaemia is a risk factor for congenital heart disease. Bjog 113:1412-1418.
17. Verkleij-Hagoort AC, de Vries JH, Ursem NT, de Jonge R, Hop WC, Steegers-Theunissen RP. 2006. Dietary intake of B-vitamins in mothers born a child with a congenital heart defect. Eur J Nutr 45:478-486.
18. Hernandez-Diaz S, Werler MM, Walker AM, Mitchell AA. 2000. Folic acid antagonists during pregnancy and the risk of birth defects. N Engl J Med 343:1608-1614.
19. Verkleij-Hagoort A, Bliek J, Sayed-Tabatabaei F, Ursem N, Steegers E, Steegers-Theunissen R. 2007. Hyperhomocysteinemia and MTHFR polymorphisms in association with orofacial defts and congenital heart defects: A meta-analysis. Am J Med Genet A 143:952-960.
20. Botto LD, Olney RS, Erickson JD. 2004. Vitamin supplements and the risk for congenital anomalies other than neural tube defects. Am J Med Genet C Semin Med Genet 125C:12-21.
21. Baird CD, Nelson MM, Monie IW, Evans HM. 1954. Congenital cardiovascular anomalies induced by pteroylglutamic acid deficiency during gestation in the rat. Circ Res 2:544-554.
22. Asling CW, Nelson MM, Wright HV, Evans HM. 1955. Congenital skeletal abnormalities in fetal rats resulting from maternal pteroylglutamic acid deficiency during gestation. Anat Rec 121:775-799.
23. Blom HJ, Shaw GM, den Heijer M, Finnell RH. 2006. Neural tube defects and folate: case far from closed. Nat Rev Neurosci 7:724-731.
24. Ferencz C, Rubin JD, McCarter RJ, Clark EB. 1990. Maternal diabetes and cardiovascular malformations: predominance of double outlet right ventricle and truncus arteriosus. Teratology 41:319-326.
25. Adams MM, Mulinare J, Dooley K. 1989. Risk factors for conotruncal cardiac defects in Atlanta. J Am Coll Cardiol 14:432-442.
26. Martinez-Frias ML. 2001. Heterotaxia as an outcome of maternal diabetes: an epidemiological study. Am J Med Genet 99:142-146.
27. Kuehl KS, Loffredo C. 2002. Risk factors for heart disease associated with abnormal sidedness. Teratology 66:242-248.
28. Lin AE, Ticho BS, Houde K, Westgate MN, Holmes LB. 2000. Heterotaxy: associated conditions and hospital-based prevalence in newborns. Genet Med 2:157-172.
29. Morishima M, Ando M, Takao A. 1991. Visceroatrial heterotaxy syndrome in the NOD mouse with special reference to atrial situs. Teratology 44:91-100.
30. Morishima M, Yasui H, Ando M, Nakazawa M, Takao A. 1996. Influence of genetic and maternal diabetes in the pathogenesis of visceroatrial heterotaxy in mice. Teratology 54:183-190.
31. Maeyama K, Kosaki R, Yoshihashi H, Casey B, Kosaki K. 2001. Mutation analysis of left-right axis determining genes in NOD and ICR, strains susceptible to maternal diabetes. Teratology 63:119-126.
32. Morgan SC, Relaix F, Sandell LL, Loeken MR. 2008. Oxidative stress during diabetic pregnancy disrupts cardiac neural crest migration and causes outflow tract defects. Birth Defects Res A Clin Mol Teratol 82:453-463.
33. Lenke RR, Levy HL. 1980. Maternal phenylketonuria and hyperphenylalaninemia. An international survey of the outcome of untreated and treated pregnancies. N Engl J Med 303:1202-1208.
34. Levy HL, Guldberg P, Guttler F, Hanley WB, Matalon R, Rouse BM, Trefz F, Azen C, Allred EN, de la Cruz F, Koch R. 2001. Congenital heart disease in maternal phenylketonuria: report from the Maternal PKU Collaborative Study. Pediatr Res 49:636-642.
35. Rouse B, Azen C, Koch R, Matalon R, Hanley W, de la Cruz F, Trefz F, Friedman E, Shifrin H. 1997. Maternal Phenylketonuria Collaborative Study (MPKUCS) offspring: facial anomalies, malformations, and early neurological sequelae. Am J Med Genet 69:89-95.
36. Clarren SK, Smith DW. 1978. The fetal alcohol syndrome. N Engl J Med 298:1063-1067.
37. Loser H, Majewski F. 1977. Type and frequency of cardiac defects in embryofetal alcohol syndrome. Report of 16 cases. Br Heart J 39:1374-1379.

38. Chernoff GF. 1977. The fetal alcohol syndrome in mice: an animal model. Teratology 15:223-229.
39. Webster WS, Germain MA, Lipson A, Walsh D. 1984. Alcohol and congenital heart defects: an experimental study in mice. Cardiovasc Res 18:335-338.
40. Ruckman RN. 1990. Cardiovascular defects associated with alcohol, retinoic acid, and other agents. Ann N Y Acad Sci 588:281-288.
41. Lynberg MC, Khoury MJ, Lammer EJ, Waller KO, Cordero JF, Erickson JD. 1990. Sensitivity, specificity, and positive predictive value of multiple malformations in isotretinoin embryopathy surveillance. Teratology 42:513-519.
42. Dai WS, Hsu MA, Itri LM. 1989. Safety of pregnancy after discontinuation of isotretinoin. Arch Dermatol 125:362-365.
43. Lammer EJ, Chen DT, Hoar RM, Agnish ND, Benke PJ, Braun JT, Curry CJ, Fernhoff PM, Grix AW, Jr., Lott IT, et al. 1985. Retinoic acid embryopathy. N Engl J Med 313:837-841.
44. Cohen LS, Friedman JM, Jefferson JW, Johnson EM, Weiner ML. 1994. A reevaluation of risk of in utero exposure to lithium. Jama 271:146-150.
45. Loffredo CA, Ferencz C, Wilson PD, Lurie IW. 2000. Interrupted aortic arch: an epidemiologic study. Teratology 61:368-375.
46. Kuehl KS, Loffredo CA. 2006. A cluster of hypoplastic left heart malformation in Baltimore, Maryland. Pediatr Cardiol 27:25-31.
47. Souter D, Harding J, McCowan L, O'Donnell C, McLeay E, Baxendale H. 1998. Antenatal indomethacin--adverse fetal effects confirmed. Aust N Z J Obstet Gynaecol 38:11-16.
48. Wilson PD, Loffredo CA, Correa-Villasenor A, Ferencz C. 1998. Attributable fraction for cardiac malformations. Am J Epidemiol 148:414-423.
49. Cooper WO, Hernandez-Diaz S, Arbogast PG, Dudley JA, Dyer S, Gideon PS, Hall K, Ray WA. 2006. Major congenital malformations after first-trimester exposure to ACE inhibitors. N Engl J Med 354:2443-2451.
50. Ewing CK, Loffredo CA, Beaty TH. 1997. Paternal risk factors for isolated membranous ventricular septal defects. Am J Med Genet 71:42-46.
51. Yang Q, Wen SW, Leader A, Chen XK, Lipson J, Walker M. 2007. Paternal age and birth defects: how strong is the association? Hum Reprod 22:696-701.
52. Olshan AF, Schnitzer PG, Baird PA. 1994. Paternal age and the risk of congenital heart defects. Teratology 50:80-84.
53. Ching YH, Ghosh TK, Cross SJ, Packham EA, Honeyman L, Loughna S, Robinson TE, Dearlove AM, Ribas G, Bonser AJ, Thomas NR, Scotter AJ, Caves LS, Tyrrell GP, Newbury-Ecob RA, Munnich A, Bonnet D, Brook JD. 2005. Mutation in myosin heavy chain 6 causes atrial septal defect. Nat Genet 37:423-428.
54. Monserrat L, Hermida-Prieto M, Fernandez X, Rodriguez I, Dumont C, Cazon L, Cuesta MG, Gonzalez-Juanatey C, Peteiro J, Alvarez N, Penas-Lado M, Castro-Beiras A. 2007. Mutation in the alpha-cardiac actin gene associated with apical hypertrophic cardiomyopathy, left ventricular non-compaction, and septal defects. Eur Heart J 28:1953-1961.
55. Budde BS, Binner P, Waldmuller S, Hohne W, Blankenfeldt W, Hassfeld S, Bromsen J, Dermintzoglou A, Wieczorek M, May E, Kirst E, Selignow C, Rackebrandt K, Muller M, Goody RS, Vosberg HP, Nurnberg P, Scheffold T. 2007. Noncompaction of the Ventricular Myocardium Is Associated with a De Novo Mutation in the beta-Myosin Heavy Chain Gene. PLoS ONE 2:e1362.
56. Wessels MW, Willems PJ. 2008. Mutations in sarcomeric protein genes not only lead to cardiomyopathy but also to congenital cardiovascular malformations. Clin Genet 74:16-19.
57. Mohapatra B, Casey B, Li H, Ho-Dawson T, Smith L, Fernbach SD, Molinari L, Niesh SR, Jefferies JL, Craigen WJ, Towbin JA, Belmont JW, Ware SM. 2009. Identification and functional characterization of NODAL rare variants in heterotaxy and isolated cardiovascular malformations. Hum Mol Genet 18:861-871.
58. Garg V, Muth AN, Ransom JF, Schluterman MK, Barnes R, King IN, Grossfeld PD, Srivastava D. 2005. Mutations in NOTCH1 cause aortic valve disease. Nature 437:270-274.
59. Mohamed SA, Aherrahrou Z, Liptau H, Erasmi AW, Hagemann C, Wrobel S, Borzym K, Schunkert H, Sievers HH, Erdmann J. 2006. Novel missense mutations (p.T596M and p.P1797H) in NOTCH1 in patients with bicuspid aortic valve. Biochem Biophys Res Commun 345:1460-1465.
60. McKellar SH, Tester DJ, Yagubyan M, Majumdar R, Ackerman MJ, Sundt TM, 3rd. 2007. Novel NOTCH1 mutations in patients with bicuspid aortic valve disease and thoracic aortic aneurysms. J Thorac Cardiovasc Surg 134:290-296.
61. McBride KL, Riley MF, Zender GA, Fitzgerald-Butt SM, Towbin JA, Belmont JW, Cole SE. 2008. NOTCH1 mutations in individuals with left ventricular outflow tract malformations reduce ligand-induced signaling. Hum Mol Genet 17:2886-2893.
62. Krebs LT, Iwai N, Nonaka S, Welsh IC, Lan Y, Jiang R, Saijoh Y, O'Brien TP, Hamada H, Gridley T. 2003. Notch signaling regulates left-right asymmetry determination by inducing Nodal expression. Genes Dev 17:1207-1212.
63. Conlon FL, Lyons KM, Takaesu N, Barth KS, Kispert A, Herrmann B, Robertson EJ. 1994. A primary requirement for nodal in the formation and maintenance of the primitive streak in the mouse. Development 120:1919-1928.

64. Lowe LA, Supp DM, Sampath K, Yokoyama T, Wright CV, Potter SS, Overbeek P, Kuehn MR. 1996. Conserved left-right asymmetry of nodal expression and alterations in murine situs inversus. Nature 381:158-161.
65. Karkera JD, Lee JS, Roessler E, Banerjee-Basu S, Ouspenskaia MV, Mez J, Goldmuntz E, Bowers P, Towbin J, Belmont JW, Baxevanis AD, Schier AF, Muenke M. 2007. Loss-of-function mutations in growth differentiation factor-1 (GDF1) are associated with congenital heart defects in humans. Am J Hum Genet 81:987-994.
66. Kosaki K, Bassi MT, Kosaki R, Lewin M, Belmont J, Schauer G, Casey B. 1999. Characterization and mutation analysis of human LEFTY A and LEFTY B, homologues of murine genes implicated in left-right axis development. Am J Hum Genet 64:712-721.
67. Kosaki R, Gebbia M, Kosaki K, Lewin M, Bowers P, Towbin JA, Casey B. 1999. Left-right axis malformations associated with mutations in ACVR2B, the gene for human activin receptor type IIB. Am J Med Genet 82:70-76.
68. Bamford RN, Roessler E, Burdine RD, Saplakoglu U, dela Cruz J, Splitt M, Goodship JA, Towbin J, Bowers P, Ferrero GB, Marino B, Schier AF, Shen MM, Muenke M, Casey B. 2000. Loss-of-function mutations in the EGF-CFC gene CFC1 are associated with human left-right laterality defects. Nat Genet 26:365-369.
69. Ozcelik C, Bit-Avragim N, Panek A, Gaio U, Geier C, Lange PE, Dietz R, Posch MG, Perrot A, Stiller B. 2006. Mutations in the EGF-CFC gene cryptic are an infrequent cause of congenital heart disease. Pediatr Cardiol 27:695-698.
70. Rankin CT, Bunton T, Lawler AM, Lee SJ. 2000. Regulation of left-right patterning in mice by growth/differentiation factor-1. Nat Genet 24:262-265.
71. Tanaka C, Sakuma R, Nakamura T, Hamada H, Saijoh Y. 2007. Long-range action of Nodal requires interaction with GDF1. Genes Dev 21:3272-3282.
72. Meno C, Takeuchi J, Sakuma R, Koshiba-Takeuchi K, Ohishi S, Saijoh Y, Miyazaki J, ten Dijke P, Ogura T, Hamada H. 2001. Diffusion of nodal signaling activity in the absence of the feedback inhibitor Lefty2. Dev Cell 1:127-138.
73. Oh SP, Li E. 1997. The signaling pathway mediated by the type IIB activin receptor controls axial patterning and lateral asymmetry in the mouse. Genes Dev 11:1812-1826.
74. Lin CR, Kioussi C, O'Connell S, Briata P, Szeto D, Liu F, Izpisua-Belmonte JC, Rosenfeld MG. 1999. Pitx2 regulates lung asymmetry, cardiac positioning and pituitary and tooth morphogenesis. Nature 401:279-282.
75. Goldmuntz E, Bamford R, Karkera JD, dela Cruz J, Roessler E, Muenke M. 2002. CFC1 mutations in patients with transposition of the great arteries and double-outlet right ventricle. Am J Hum Genet 70:776-780.
76. Gaio U, Schweickert A, Fischer A, Garratt AN, Muller T, Ozcelik C, Lankes W, Strehle M, Britsch S, Blum M, Birchmeier C. 1999. A role of the cryptic gene in the correct establishment of the left-right axis. Curr Biol 9:1339-1342.
77. von Both I, Silvestri C, Erdemir T, Lickert H, Walls JR, Henkelman RM, Rossant J, Harvey RP, Attisano L, Wrana JL. 2004. Foxh1 is essential for development of the anterior heart field. Dev Cell 7:331-345.
78. Hirayama-Yamada K, Kamisago M, Akimoto K, Aotsuka H, Nakamura Y, Tomita H, Furutani M, Imamura S, Takao A, Nakazawa M, Matsuoka R. 2005. Phenotypes with GATA4 or NKX2.5 mutations in familial atrial septal defect. Am J Med Genet A 135:47-52.
79. Okubo A, Miyoshi O, Baba K, Takagi M, Tsukamoto K, Kinoshita A, Yoshiura K, Kishino T, Ohta T, Niikawa N, Matsumoto N. 2004. A novel GATA4 mutation completely segregated with atrial septal defect in a large Japanese family. J Med Genet 41:e97.
80. Sarkozy A, Conti E, Neri C, D'Agostino R, Digilio MC, Esposito G, Toscano A, Marino B, Pizzuti A, Dallapiccola B. 2005. Spectrum of atrial septal defects associated with mutations of NKX2.5 and GATA4 transcription factors. J Med Genet 42:e16.
81. Tomita-Mitchell A, Maslen CL, Morris CD, Garg V, Goldmuntz E. 2007. GATA4 sequence variants in patients with congenital heart disease. J Med Genet 44:779-783.
82. Zhang W, Li X, Shen A, Jiao W, Guan X, Li Z. 2008. GATA4 mutations in 486 Chinese patients with congenital heart disease. Eur J Med Genet 51:527-535.
83. Rajagopal SK, Ma Q, Obler D, Shen J, Manichaikul A, Tomita-Mitchell A, Boardman K, Briggs C, Garg V, Srivastava D, Goldmuntz E, Broman KW, Woodrow Benson D, Smoot LB, Pu WT. 2007. Spectrum of heart disease associated with murine and human GATA4 mutation. J Mol Cell Cardiol 43:677-685.
84. Nemer G, Fadlalah F, Usta J, Nemer M, Dbaibo G, Obeid M, Bitar F. 2006. A novel mutation in the GATA4 gene in patients with Tetralogy of Fallot. Hum Mutat 27:293-294.
85. Kuo CT, Morrisey EE, Anandappa R, Sigrist K, Lu MM, Parmacek MS, Soudais C, Leiden JM. 1997. GATA4 transcription factor is required for ventral morphogenesis and heart tube formation. Genes Dev 11:1048-1060.
86. Molkentin JD, Lin Q, Duncan SA, Olson EN. 1997. Requirement of the transcription factor GATA4 for heart tube formation and ventral morphogenesis. Genes Dev 11:1061-1072.
87. Durocher D, Nemer M. 1998. Combinatorial interactions regulating cardiac transcription. Dev Genet 22:250-262.
88. Mackay JP, Crossley M. 1998. Zinc fingers are sticking together. Trends Biochem Sci 23:1-4.

89. Pizzuti A, Sarkozy A, Newton AL, Conti E, Flex E, Digilio MC, Amati F, Gianni D, Tandoi C, Marino B, Crossley M, Dallapiccola B. 2003. Mutations of ZFPM2/FOG2 gene in sporadic cases of tetralogy of Fallot. Hum Mutat 22:372-377.
90. Gelb BD, Towbin JA, McCabe ER, Sujansky E. 1991. San Luis Valley recombinant chromosome 8 and tetralogy of Fallot: a review of chromosome 8 anomalies and congenital heart disease. Am J Med Genet 40:471-476.
91. Svensson EC, Huggins GS, Lin H, Clendenin C, Jiang F, Tufts R, Dardik FB, Leiden JM. 2000. A syndrome of tricuspid atresia in mice with a targeted mutation of the gene encoding Fog-2. Nat Genet 25:353-356.
92. Tevosian SG, Deconinck AE, Tanaka M, Schinke M, Litovsky SH, Izumo S, Fujiwara Y, Orkin SH. 2000. FOG-2, a cofactor for GATA transcription factors, is essential for heart morphogenesis and development of coronary vessels from epicardium. Cell 101:729-739.
93. Gutierrez-Roelens I, Sluysmans T, Gewillig M, Devriendt K, Vikkula M. 2002. Progressive AV-block and anomalous venous return among cardiac anomalies associated with two novel missense mutations in the CSX/NKX2-5 gene. Hum Mutat 20:75-76.
94. Hosoda T, Komuro I, Shiojima I, Hiroi Y, Harada M, Murakawa Y, Hirata Y, Yazaki Y. 1999. Familial atrial septal defect and atrioventricular conduction disturbance associated with a point mutation in the cardiac homeobox gene CSX/NKX2-5 in a Japanese patient. Jpn Circ J 63:425-426.
95. Watanabe Y, Benson DW, Yano S, Akagi T, Yoshino M, Murray JC. 2002. Two novel frameshift mutations in NKX2.5 result in novel features including visceral inversus and sinus venosus type ASD. J Med Genet 39:807-811.
96. Gutierrez-Roelens I, De Roy L, Ovaert C, Sluysmans T, Devriendt K, Brunner HG, Vikkula M. 2006. A novel CSX/NKX2-5 mutation causes autosomal-dominant AV block: are atrial fibrillation and syncopes part of the phenotype? Eur J Hum Genet 14:1313-1316.
97. Elliott DA, Kirk EP, Yeoh T, Chandar S, McKenzie F, Taylor P, Grossfeld P, Fatkin D, Jones O, Hayes P, Feneley M, Harvey RP. 2003. Cardiac homeobox gene NKX2-5 mutations and congenital heart disease: associations with atrial septal defect and hypoplastic left heart syndrome. J Am Coll Cardiol 41:2072-2076.
98. Rifai L, Maazouzi W, Sefiani A. 2007. Novel point mutation in the NKX2-5 gene in a Moroccan family with atrioventricular conduction disturbance and an atrial septal defect in the oval fossa. Cardiol Young 17:107-109.
99. Benson DW, Silberbach GM, Kavanaugh-McHugh A, Cottrill C, Zhang Y, Riggs S, Smalls O, Johnson MC, Watson MS, Seidman JG, Seidman CE, Plowden J, Kugler JD. 1999. Mutations in the cardiac transcription factor NKX2.5 affect diverse cardiac developmental pathways. J Clin Invest 104:1567-1573.
100. Goldmuntz E, Geiger E, Benson DW. 2001. NKX2.5 mutations in patients with tetralogy of fallot. Circulation 104:2565-2568.
101. McElhinney DB, Geiger E, Blinder J, Benson DW, Goldmuntz E. 2003. NKX2.5 mutations in patients with congenital heart disease. J Am Coll Cardiol 42:1650-1655.
102. Jay PY, Harris BS, Maguire CT, Buerger A, Wakimoto H, Tanaka M, Kupershmidt S, Roden DM, Schultheiss TM, O'Brien TX, Gourdie RG, Berul CI, Izumo S. 2004. Nkx2-5 mutation causes anatomic hypoplasia of the cardiac conduction system. J Clin Invest 113:1130-1137.
103. Pashmforoush M, Lu JT, Chen H, Amand TS, Kondo R, Pradervand S, Evans SM, Clark B, Feramisco JR, Giles W, Ho SY, Benson DW, Silberbach M, Shou W, Chien KR. 2004. Nkx2-5 pathways and congenital heart disease; loss of ventricular myocyte lineage specification leads to progressive cardiomyopathy and complete heart block. Cell 117:373-386.
104. Heathcote K, Braybrook C, Abushaban L, Guy M, Khetyar ME, Patton MA, Carter ND, Scambler PJ, Syrris P. 2005. Common arterial trunk associated with a homeodomain mutation of NKX2.6. Hum Mol Genet 14:585-593.
105. Tanaka M, Yamasaki N, Izumo S. 2000. Phenotypic characterization of the murine Nkx2.6 homeobox gene by gene targeting. Mol Cell Biol 20:2874-2879.
106. Stennard FA, Costa MW, Lai D, Biben C, Furtado MB, Solloway MJ, McCulley DJ, Leimena C, Preis JI, Dunwoodie SL, Elliott DE, Prall OW, Black BL, Fatkin D, Harvey RP. 2005. Murine T-box transcription factor Tbx20 acts as a repressor during heart development, and is essential for adult heart integrity, function and adaptation. Development 132:2451-2462.
107. Stennard FA, Costa MW, Elliott DA, Rankin S, Haast SJ, Lai D, McDonald LP, Niederreither K, Dolle P, Bruneau BG, Zorn AM, Harvey RP. 2003. Cardiac T-box factor Tbx20 directly interacts with Nkx2-5, GATA4, and GATA5 in regulation of gene expression in the developing heart. Dev Biol 262:206-224.
108. Sperling S, Grimm CH, Dunkel I, Mebus S, Sperling HP, Ebner A, Galli R, Lehrach H, Fusch C, Berger F, Hammer S. 2005. Identification and functional analysis of CITED2 mutations in patients with congenital heart defects. Hum Mutat 26:575-582.
109. Bamforth SD, Braganca J, Farthing CR, Schneider JE, Broadbent C, Michell AC, Clarke K, Neubauer S, Norris D, Brown NA, Anderson RH, Bhattacharya S. 2004. Cited2 controls left-right patterning and heart development through a Nodal-Pitx2c pathway. Nat Genet 36:1189-1196.

110. Cinquetti R, Badi I, Campione M, Bortoletto E, Chiesa G, Parolini C, Camesasca C, Russo A, Taramelli R, Acquati F. 2008. Transcriptional deregulation and a missense mutation define ANKRD1 as a candidate gene for total anomalous pulmonary venous return. Hum Mutat 29:468-474.
111. Zhu L, Vranckx R, Khau Van Kien P, Lalande A, Boisset N, Mathieu F, Wegman M, Glancy L, Gasc JM, Brunotte F, Bruneval P, Wolf JE, Michel JB, Jeunemaitre X. 2006. Mutations in myosin heavy chain 11 cause a syndrome associating thoracic aortic aneurysm/aortic dissection and patent ductus arteriosus. Nat Genet 38:343-349.
112. Slomp J, Gittenberger-de Groot AC, Glukhova MA, Conny van Munsteren J, Kockx MM, Schwartz SM, Koteliansky VE. 1997. Differentiation, dedifferentiation, and apoptosis of smooth muscle cells during the development of the human ductus arteriosus. Arterioscler Thromb Vasc Biol 17:1003-1009.
113. Morano I, Chai GX, Baltas LG, Lamounier-Zepter V, Lutsch G, Kott M, Haase H, Bader M. 2000. Smooth-muscle contraction without smooth-muscle myosin. Nat Cell Biol 2:371-375.
114. Ghosh TK, Song FF, Packham EA, Buxton S, Robinson TE, Ronksley J, Self T, Bonser AJ, Brook JD. 2009. Physical Interaction between Tbx5 and Mef2c Is Required for Early Heart Development. Mol Cell Biol:Feb 9. [Epub ahead of print].
115. Jones WK, Grupp IL, Doetschman T, Grupp G, Osinska H, Hewett TE, Boivin G, Gulick J, Ng WA, Robbins J. 1996. Ablation of the murine alpha myosin heavy chain gene leads to dosage effects and functional deficits in the heart. J Clin Invest 98:1906-1917.
116. Geisterfer-Lowrance AA, Christe M, Conner DA, Ingwall JS, Schoen FJ, Seidman CE, Seidman JG. 1996. A mouse model of familial hypertrophic cardiomyopathy. Science 272:731-734.
117. Zahka K, Kalidas K, Simpson MA, Cross H, Keller BB, Galambos C, Gurtz K, Patton MA, Crosby AH. 2008. Homozygous mutation of MYBPC3 associated with severe infantile hypertrophic cardiomyopathy at high frequency among the Amish. Heart 94:1326-1330.
118. Xin B, Puffenberger E, Tumbush J, Bockoven JR, Wang H. 2007. Homozygosity for a novel splice site mutation in the cardiac myosin-binding protein C gene causes severe neonatal hypertrophic cardiomyopathy. Am J Med Genet A 143:2662-2667.
119. Lekanne Deprez RH, Muurling-Vlietman JJ, Hruda J, Baars MJ, Wijnaendts LC, Stolte-Dijkstra I, Alders M, van Hagen JM. 2006. Two cases of severe neonatal hypertrophic cardiomyopathy caused by compound heterozygous mutations in the MYBPC3 gene. J Med Genet 43:829-832.
120. Yang Q, Sanbe A, Osinska H, Hewett TE, Klevitsky R, Robbins J. 1999. In vivo modeling of myosin binding protein C familial hypertrophic cardiomyopathy. Circ Res 85:841-847.
121. Sato N, Kawakami T, Nakayama A, Suzuki H, Kasahara H, Obinata T. 2003. A novel variant of cardiac myosin-binding protein-C that is unable to assemble into sarcomeres is expressed in the aged mouse atrium. Mol Biol Cell 14:3180-3191.
122. Olson TM, Doan TP, Kishimoto NY, Whitby FG, Ackerman MJ, Fananapazir L. 2000. Inherited and de novo mutations in the cardiac actin gene cause hypertrophic cardiomyopathy. J Mol Cell Cardiol 32:1687-1694.
123. Matsson H, Eason J, Bookwalter CS, Klar J, Gustavsson P, Sunnegardh J, Enell H, Jonzon A, Vikkula M, Gutierrez I, Granados-Riveron J, Pope M, Bu'lock F, Cox J, Robinson TE, Song F, Brook DJ, Marston S, Trybus KM, Dahl N. 2008. Alpha-cardiac actin mutations produce atrial septal defects. Hum Mol Genet 17:256-265.
124. Abdelwahid E, Pelliniemi LJ, Szucsik JC, Lessard JL, Jokinen E. 2004. Cellular disorganization and extensive apoptosis in the developing heart of mice that lack cardiac muscle alpha-actin: apparent cause of perinatal death. Pediatr Res 55:197-204.
125. Gong J, Qian L, Kong X, Yang R, Zhou L, Sheng Y, Sun W, Sun F, Huang Y, Cao K. 2007. Cardiomyocyte apoptosis in the right auricle of patients with ostium secundum atrial septal defect diseases. Life Sci 80:1143-1151.
126. Britz-Cunningham SH, Shah MM, Zuppan CW, Fletcher WH. 1995. Mutations of the Connexin43 gap-junction gene in patients with heart malformations and defects of laterality. N Engl J Med 332:1323-1329.
127. Edmar A, Slim G, Boumahni B, Attali T, Bourgoin S, Mariette JB, Bangui A, Renouil M, Fourmaintraux A. 1999. [Viscero-atrial heterotaxia]. Arch Pediatr 6:225-226.
128. Toth T, Hajdu J, Marton T, Nagy B, Papp Z. 1998. connexin43 gene mutations and heterotaxy. Circulation 97:117-118.
129. Gelb BD. 1997. Molecular genetics of congenital heart disease. Curr Opin Cardiol 12:321-328.
130. Debrus S, Tuffery S, Matsuoka R, Galal O, Sarda P, Sauer U, Bozio A, Tanman B, Toutain A, Claustres M, Le Paslier D, Bouvagnet P. 1997. Lack of evidence for connexin 43 gene mutations in human autosomal recessive lateralization defects. J Mol Cell Cardiol 29:1423-1431.
131. Penman Splitt M, Tsai MY, Burn J, Goodship JA. 1997. Absence of mutations in the regulatory domain of the gap junction protein connexin 43 in patients with visceroatrial heterotaxy. Heart 77:369-370.
132. Gebbia M, Towbin JA, Casey B. 1996. Failure to detect connexin43 mutations in 38 cases of sporadic and familial heterotaxy. Circulation 94:1909-1912.

133. Dasgupta C, Martinez AM, Zuppan CW, Shah MM, Bailey LL, Fletcher WH. 2001. Identification of connexin43 (alpha1) gap junction gene mutations in patients with hypoplastic left heart syndrome by denaturing gradient gel electrophoresis (DGGE). Mutat Res 479:173-186.
134. Ya J, Erdtsieck-Ernste EB, de Boer PA, van Kempen MJ, Jongsma H, Gros D, Moorman AF, Lamers WH. 1998. Heart defects in connexin43-deficient mice. Circ Res 82:360-366.
135. Kyndt F, Gueffet JP, Probst V, Jaafar P, Legendre A, Le Bouffant F, Toquet C, Roy E, McGregor L, Lynch SA, Newbury-Ecob R, Tran V, Young I, Trochu JN, Le Marec H, Schott JJ. 2007. Mutations in the gene encoding filamin A as a cause for familial cardiac valvular dystrophy. Circulation 115:40-49.
136. Sheen VL, Dixon PH, Fox JW, Hong SE, Kinton L, Sisodiya SM, Duncan JS, Dubeau F, Scheffer IE, Schachter SC, Wilner A, Henchy R, Crino P, Kamuro K, DiMario F, Berg M, Kuzniecky R, Cole AJ, Bromfield E, Biber M, Schomer D, Wheless J, Silver K, Mochida GH, Berkovic SF, Andermann F, Andermann E, Dobyns WB, Wood NW, Walsh CA. 2001. Mutations in the X-linked filamin 1 gene cause periventricular nodular heterotopia in males as well as in females. Hum Mol Genet 10:1775-1783.
137. Sheen VL, Jansen A, Chen MH, Parrini E, Morgan T, Ravenscroft R, Ganesh V, Underwood T, Wiley J, Leventer R, Vaid RR, Ruiz DE, Hutchins GM, Menasha J, Willner J, Geng Y, Gripp KW, Nicholson L, Berry-Kravis E, Bodell A, Apse K, Hill RS, Dubeau F, Andermann F, Barkovich J, Andermann E, Shugart YY, Thomas P, Viri M, Veggiotti P, Robertson S, Guerrini R, Walsh CA. 2005. Filamin A mutations cause periventricular heterotopia with Ehlers-Danlos syndrome. Neurology 64:254-262.
138. Feng Y, Chen MH, Moskowitz IP, Mendonza AM, Vidali L, Nakamura F, Kwiatkowski DJ, Walsh CA. 2006. Filamin A (FLNA) is required for cell-cell contact in vascular development and cardiac morphogenesis. Proc Natl Acad Sci U S A 103:19836-19841.
139. Tassabehji M, Metcalfe K, Donnai D, Hurst J, Reardon W, Burch M, Read AP. 1997. Elastin: genomic structure and point mutations in patients with supravalvular aortic stenosis. Hum Mol Genet 6:1029-1036.
140. Li DY, Toland AE, Boak BB, Atkinson DL, Ensing GJ, Morris CA, Keating MT. 1997. Elastin point mutations cause an obstructive vascular disease, supravalvular aortic stenosis. Hum Mol Genet 6:1021-1028.
141. Szabo Z, Crepeau MW, Mitchell AL, Stephan MJ, Puntel RA, Yin Loke K, Kirk RC, Urban Z. 2006. Aortic aneurysmal disease and cutis laxa caused by defects in the elastin gene. J Med Genet 43:255-258.
142. Li DY, Faury G, Taylor DG, Davis EC, Boyle WA, Mecham RP, Stenzel P, Boak B, Keating MT. 1998. Novel arterial pathology in mice and humans hemizygous for elastin. J Clin Invest 102:1783-1787.
143. Muncke N, Jung C, Rudiger H, Ulmer H, Roeth R, Hubert A, Goldmuntz E, Driscoll D, Goodship J, Schon K, Rappold G. 2003. Missense mutations and gene interruption in PROSIT240, a novel TRAP240-like gene, in patients with congenital heart defect (transposition of the great arteries). Circulation 108:2843-2850.
144. Stanczak P, Witecka J, Szydlo A, Gutmajster E, Lisik M, Augusciak-Duma A, Tarnowski M, Czekaj T, Czekaj H, Sieron AL. 2009. Mutations in mammalian tolloid-like 1 gene detected in adult patients with ASD. Eur J Hum Genet 17:344-351.
145. Clark TG, Conway SJ, Scott IC, Labosky PA, Winnier G, Bundy J, Hogan BL, Greenspan DS. 1999. The mammalian Tolloid-like 1 gene, Tll1, is necessary for normal septation and positioning of the heart. Development 126:2631-2642.
146. Krantz ID, Smith R, Colliton RP, Tinkel H, Zackai EH, Piccoli DA, Goldmuntz E, Spinner NB. 1999. Jagged1 mutations in patients ascertained with isolated congenital heart defects. Am J Med Genet 84:56-60.
147. Eldadah ZA, Hamosh A, Biery NJ, Montgomery RA, Duke M, Elkins R, Dietz HC. 2001. Familial Tetralogy of Fallot caused by mutation in the jagged1 gene. Hum Mol Genet 10:163-169.
148. Chhin B, Hatayama M, Bozon D, Ogawa M, Schon P, Tohmonda T, Sassolas F, Aruga J, Valard AG, Chen SC, Bouvagnet P. 2007. Elucidation of penetrance variability of a ZIC3 mutation in a family with complex heart defects and functional analysis of ZIC3 mutations in the first zinc finger domain. Hum Mutat 28:563-570.
149. Megarbane A, Salem N, Stephan E, Ashoush R, Lenoir D, Delague V, Kassab R, Loiselet J, Bouvagnet P. 2000. X-linked transposition of the great arteries and incomplete penetrance among males with a nonsense mutation in ZIC3. Eur J Hum Genet 8:704-708.
150. Ware SM, Peng J, Zhu L, Fernbach S, Colicos S, Casey B, Towbin J, Belmont JW. 2004. Identification and functional analysis of ZIC3 mutations in heterotaxy and related congenital heart defects. Am J Hum Genet 74:93-105.
151. Purandare SM, Ware SM, Kwan KM, Gebbia M, Bassi MT, Deng JM, Vogel H, Behringer RR, Belmont JW, Casey B. 2002. A complex syndrome of left-right axis, central nervous system and axial skeleton defects in Zic3 mutant mice. Development 129:2293-2302.
152. Zweier C, Sticht H, Aydin-Yaylagul I, Campbell CE, Rauch A. 2007. Human TBX1 missense mutations cause gain of function resulting in the same phenotype as 22q11.2 deletions. Am J Hum Genet 80:510-517.
153. Yagi H, Furutani Y, Hamada H, Sasaki T, Asakawa S, Minoshima S, Ichida F, Joo K, Kimura M, Imamura S, Kamatani N, Momma K, Takao A, Nakazawa M, Shimizu N, Matsuoka R. 2003. Role of TBX1 in human del22q11.2 syndrome. Lancet 362:1366-1373.

154. Torres-Juan L, Rosell J, Morla M, Vidal-Pou C, Garcia-Algas F, de la Fuente MA, Juan M, Tubau A, Bachiller D, Bernues M, Perez-Granero A, Govea N, Busquets X, Heine-Suner D. 2007. Mutations in TBX1 genocopy the 22q11.2 deletion and duplication syndromes: a new susceptibility factor for mental retardation. Eur J Hum Genet 15:658-663.
155. Rauch A, Devriendt K, Koch A, Rauch R, Gewillig M, Kraus C, Weyand M, Singer H, Reis A, Hofbeck M. 2004. Assessment of association between variants and haplotypes of the remaining TBX1 gene and manifestations of congenital heart defects in 22q11.2 deletion patients. J Med Genet 41:e40.
156. Gong W, Gottlieb S, Collins J, Blescia A, Dietz H, Goldmuntz E, McDonald-McGinn DM, Zackai EH, Emanuel BS, Driscoll DA, Budarf ML. 2001. Mutation analysis of TBX1 in non-deleted patients with features of DGS/VCFS or isolated cardiovascular defects. J Med Genet 38:E45.
157. Basson CT, Bachinsky DR, Lin RC, Levi T, Elkins JA, Soults J, Grayzel D, Kroumpouzou E, Traill TA, Leblanc-Straceski J, Renault B, Kucherlapati R, Seidman JG, Seidman CE. 1997. Mutations in human TBX5 [corrected] cause limb and cardiac malformation in Holt-Oram syndrome. Nat Genet 15:30-35.
158. Basson CT, Cowley GS, Solomon SD, Weissman B, Poznanski AK, Traill TA, Seidman JG, Seidman CE. 1994. The clinical and genetic spectrum of the Holt-Oram syndrome (heart-hand syndrome). N Engl J Med 330:885-891.
159. Satoda M, Zhao F, Diaz GA, Burn J, Goodship J, Davidson HR, Pierpont ME, Gelb BD. 2000. Mutations in TFAP2B cause Char syndrome, a familial form of patent ductus arteriosus. Nat Genet 25:42-46.
160. Zhao F, Weismann CG, Satoda M, Pierpont ME, Sweeney E, Thompson EM, Gelb BD. 2001. Novel TFAP2B mutations that cause Char syndrome provide a genotype-phenotype correlation. Am J Hum Genet 69:695-703.
161. Robinson SW, Morris CD, Goldmuntz E, Reller MD, Jones MA, Steiner RD, Maslen CL. 2003. Missense mutations in CRELD1 are associated with cardiac atrioventricular septal defects. Am J Hum Genet 72:1047-1052.
162. Zatyka M, Priestley M, Ladusans EJ, Fryer AE, Mason J, Latif F, Maher ER. 2005. Analysis of CRELD1 as a candidate 3p25 atrioventicular septal defect locus (AVSD2). Clin Genet 67:526-528.
163. Maslen CL, Babcock D, Robinson SW, Bean LJ, Dooley KJ, Willour VL, Sherman SL. 2006. CRELD1 mutations contribute to the occurrence of cardiac atrioventricular septal defects in Down syndrome. Am J Med Genet A 140:2501-2505.
164. Rupp PA, Fouad GT, Egelston CA, Reifsteck CA, Olson SB, Knosp WM, Glanville RW, Thornburg KL, Robinson SW, Maslen CL. 2002. Identification, genomic organization and mRNA expression of CRELD1, the founding member of a unique family of matricellular proteins. Gene 293:47-57.
165. Selamet Tierney ES, Marans Z, Rutkin MB, Chung WK. 2007. Variants of the CFC1 gene in patients with laterality defects associated with congenital cardiac disease. Cardiol Young 17:268-274.
166. Huang J, Cheng L, Li J, Chen M, Zhou D, Lu MM, Proweller A, Epstein JA, Parmacek MS. 2008. Myocardin regulates expression of contractile genes in smooth muscle cells and is required for closure of the ductus arteriosus in mice. J Clin Invest 118:515-525.
167. Christensen KE, Rohlicek CV, Andelfinger GU, Michaud J, Bigras JL, Richter A, Mackenzie RE, Rozen R. 2009. The MTHFD1 p.Arg653Gln variant alters enzyme function and increases risk for congenital heart defects. Hum Mutat 30:212-220.
168. van Beynum IM, Kouwenberg M, Kapusta L, den Heijer M, van der Linden IJ, Daniels O, Blom HJ. 2006. MTRR 66A>G polymorphism in relation to congenital heart defects. Clin Chem Lab Med 44:1317-1323.
169. Pei L, Zhu H, Zhu J, Ren A, Finnell RH, Li Z. 2006. Genetic variation of infant reduced folate carrier (A80G) and risk of orofacial defects and congenital heart defects in China. Ann Epidemiol 16:352-356.
170. Shaw GM, Iovannisci DM, Yang W, Finnell RH, Carmichael SL, Cheng S, Lammer EJ. 2005. Risks of human conotruncal heart defects associated with 32 single nucleotide polymorphisms of selected cardiovascular disease-related genes. Am J Med Genet A 138:21-26.
171. Lambrechts D, Devriendt K, Driscoll DA, Goldmuntz E, Gewillig M, Vlietinck R, Collen D, Carmeliet P. 2005. Low expression VEGF haplotype increases the risk for tetralogy of Fallot: a family based association study. J Med Genet 42:519-522.
172. Stalmans I, Lambrechts D, De Smet F, Jansen S, Wang J, Maity S, Kneer P, von der Ohe M, Swillen A, Maes C, Gewillig M, Molin DG, Hellings P, Boetel T, Haardt M, Compernolle V, Dewerchin M, Plaisance S, Vlietinck R, Emanuel B, Gittenberger-de Groot AC, Scambler P, Morrow B, Driscol DA, Moons L, Esguerra CV, Carmeliet G, Behn-Krappa A, Devriendt K, Collen D, Conway SJ, Carmeliet P. 2003. VEGF: a modifier of the del22q11 (DiGeorge) syndrome? Nat Med 9:173-182.
173. Yehya A, Souki R, Bitar F, Nemer G. 2006. Differential duplication of an intronic region in the NFATC1 gene in patients with congenital heart disease. Genome 49:1092-1098.
174. Ferencz C, Neill CA, Boughman JA, Rubin JD, Brenner JI, Perry LW. 1989. Congenital cardiovascular malformations associated with chromosome abnormalities: an epidemiologic study. J Pediatr 114:79-86.
175. Johnson MC, Hing A, Wood MK, Watson MS. 1997. Chromosome abnormalities in congenital heart disease. Am J Med Genet 70:292-298.

176. Thienpont B, Mertens L, de Ravel T, Eyskens B, Boshoff D, Maas N, Fryns JP, Gewillig M, Vermeesch JR, Devriendt K. 2007. Submicroscopic chromosomal imbalances detected by array-CGH are a frequent cause of congenital heart defects in selected patients. Eur Heart J 28:2778-2784.
177. Wentzel C, Fernstrom M, Ohrner Y, Anneren G, Thuresson AC. 2008. Clinical variability of the 22q11.2 duplication syndrome. Eur J Med Genet 51:501-510.
178. Stewart DR, Kleefstra T. 2007. The chromosome 9q subtelomere deletion syndrome. Am J Med Genet C Semin Med Genet 145C:383-392.
179. Andrieux J, Villenet C, Quief S, Lignon S, Geffroy S, Roumier C, de Leersnyder H, de Blois MC, Manouvrier S, Delobel B, Benzacken B, Bitoun P, Attie-Bitach T, Thomas S, Lyonnet S, Vekemans M, Kerckaert JP. 2007. Genotype phenotype correlation of 30 patients with Smith-Magenis syndrome (SMS) using comparative genome hybridisation array: cleft palate in SMS is associated with larger deletions. J Med Genet 44:537-540.
180. Ghebranious N, Giampietro PF, Wesbrook FP, Rezkalla SH. 2007. A novel microdeletion at 16p11.2 harbors candidate genes for aortic valve development, seizure disorder, and mild mental retardation. Am J Med Genet A 143A:1462-1471.
181. Hernando C, Plaja A, Rigola MA, Perez MM, Vendrell T, Egocue J, Fuster C. 2002. Comparative genomic hybridisation shows a partial de novo deletion 16p11.2 in a neonate with multiple congenital malformations. J Med Genet 39:E24.
182. Brunetti-Pierri N, Berg JS, Scaglia F, Belmont J, Bacino CA, Sahoo T, Lalani SR, Graham B, Lee B, Shinawi M, Shen J, Kang SH, Pursley A, Lotze T, Kennedy G, Lansky-Shafer S, Weaver C, Roeder ER, Grebe TA, Arnold GL, Hutchison T, Reimschisel T, Amato S, Geragthy MT, Innis JW, Obersztyn E, Nowakowska B, Rosengren SS, Bader PI, Grange DK, Naqvi S, Garnica AD, Bernes SM, Fong CT, Summers A, Walters WD, Lupski JR, Stankiewicz P, Cheung SW, Patel A. 2008. Recurrent reciprocal 1q21.1 deletions and duplications associated with microcephaly or macrocephaly and developmental and behavioral abnormalities. Nat Genet 40:1466-1471.
183. Mefford HC, Sharp AJ, Baker C, Itsara A, Jiang Z, Buysse K, Huang S, Maloney VK, Crolla JA, Baralle D, Collins A, Mercer C, Norga K, de Ravel T, Devriendt K, Bongers EM, de Leeuw N, Reardon W, Gimelli S, Bena F, Hennekam RC, Male A, Gaunt L, Clayton-Smith J, Simonic I, Park SM, Mehta SG, Nik-Zainal S, Woods CG, Firth HV, Parkin G, Fichera M, Reitano S, Lo Giudice M, Li KE, Casuga I, Broomer A, Conrad B, Schwerzmann M, Raber L, Gallati S, Striano P, Coppola A, Tolmie JL, Tobias ES, Lilley C, Armengol L, Spysschaert Y, Verloo P, De Coene A, Goossens L, Mortier G, Speleman F, van Binsbergen E, Nelen MR, Hochstenbach R, Poot M, Gallagher L, Gill M, McClellan J, King MC, Regan R, Skinner C, Stevenson RE, Antonarakis SE, Chen C, Estivill X, Menten B, Gimelli G, Gribble S, Schwartz S, Sutcliffe JS, Walsh T, Knight SJ, Sebat J, Romano C, Schwartz CE, Veltman JA, de Vries BB, Vermeesch JR, Barber JC, Willatt L, Tassabehji M, Eichler EE. 2008. Recurrent rearrangements of chromosome 1q21.1 and variable pediatric phenotypes. N Engl J Med 359:1685-1699.
184. Christiansen J, Dyck JD, Elyas BG, Lilley M, Bamforth JS, Hicks M, Sprysak KA, Tomaszewski R, Haase SM, Vicen-Wyhony LM, Somerville MJ. 2004. Chromosome 1q21.1 contiguous gene deletion is associated with congenital heart disease. Circ Res 94:1429-1435.
185. Erdogan F, Larsen LA, Zhang L, Tumer Z, Tommerup N, Chen W, Jacobsen JR, Schubert M, Jurkatis J, Tzschach A, Ropers HH, Ullmann R. 2008. High frequency of submicroscopic genomic aberrations detected by tiling path array comparative genome hybridisation in patients with isolated congenital heart disease. J Med Genet 45:704-709.
186. Knudson AG, Jr., Strong LC. 1972. Mutation and cancer: a model for Wilms' tumor of the kidney. J Natl Cancer Inst 48:313-324.
187. Kinzler KW, Vogelstein B. 1998. Landscaping the cancer terrain. Science 280:1036-1037.
188. Happle R. 2002. Dohi Memorial Lecture. New aspects of cutaneous mosaicism. J Dermatol 29:681-692.
189. Reamon-Buettner SM, Spanel-Borowski K, Borlak J. 2006. Bridging the gap between anatomy and molecular genetics for an improved understanding of congenital heart disease. Ann Anat 188:213-220.
190. Reamon-Buettner SM, Borlak J. 2006. HEY2 mutations in malformed hearts. Hum Mutat 27:118.
191. Reamon-Buettner SM, Borlak J. 2004. TBX5 mutations in non-Holt-Oram syndrome (HOS) malformed hearts. Hum Mutat 24:104.
192. Reamon-Buettner SM, Hecker H, Spanel-Borowski K, Craatz S, Kuenzel E, Borlak J. 2004. Novel NKX2-5 mutations in diseased heart tissues of patients with cardiac malformations. Am J Pathol 164:2117-2125.
193. Reamon-Buettner SM, Borlak J. 2004. Somatic NKX2-5 mutations as a novel mechanism of disease in complex congenital heart disease. J Med Genet 41:684-690.
194. Reamon-Buettner SM, Borlak J. 2006. Somatic mutations in cardiac malformations. J Med Genet 43:e45.
195. Reamon-Buettner SM, Ciribilli Y, Inga A, Borlak J. 2008. A loss-of-function mutation in the binding domain of HAND1 predicts hypoplasia of the human hearts. Hum Mol Genet 17:1397-1405.

196. Majumdar R, Yagubyan M, Sarkar G, Bolander ME, Sundt TM, 3rd. 2006. Bicuspid aortic valve and ascending aortic aneurysm are not associated with germline or somatic homeobox NKX2-5 gene polymorphism in 19 patients. J Thorac Cardiovasc Surg 131:1301-1305.
197. Rauch A, Hofbeck M, Cesnjevar R, Koch A, Rauch R, Buheitel G, Singer H, Weyand M. 2004. Search for somatic 22q11.2 deletions in patients with conotruncal heart defects. Am J Med Genet A 124:165-169.
198. Draus JM, Jr., Hauck MA, Goetsch M, Austin EH, 3rd, Tomita-Mitchell A, Mitchell ME. 2009. Investigation of somatic NKX2-5 mutations in congenital heart disease. J Med Genet 46:115-122.
199. Nora JJ, McGill CW, McNamara DG. 1970. Empiric recurrence risks in common and uncommon congenital heart lesions. Teratology 3:325-330.
200. Nora JJ, Nora AH. 1988. Update on counseling the family with a first-degree relative with a congenital heart defect. Am J Med Genet 29:137-142.
201. Digilio MC, Marino B, Cicini MP, Giannotti A, Formigari R, Dallapiccola B. 1993. Risk of congenital heart defects in relatives of patients with atrioventricular canal. Am J Dis Child 147:1295-1297.
202. Digilio MC, Casey B, Toscano A, Calabro R, Pacileo G, Marasini M, Banaudi E, Giannotti A, Dallapiccola B, Marino B. 2001. Complete transposition of the great arteries: patterns of congenital heart disease in familial precurrence. Circulation 104:2809-2814.
203. Digilio MC, Marino B, Capolino R, Angioni A, Sarkozy A, Roberti MC, Conti E, de Zorzi A, Dallapiccola B. 2005. Familial recurrence of nonsyndromic congenital heart defects in first degree relatives of patients with deletion 22q11.2. Am J Med Genet A 134:158-164.
204. Digilio MC, Marino B, Giannotti A, Dallapiccola B. 1997. Familial recurrence of transposition of the great arteries and intact ventricular septum. Am J Med Genet 73:93-94.
205. Digilio MC, Marino B, Giannotti A, Toscano A, Dallapiccola B. 1997. Recurrence risk figures for isolated tetralogy of Fallot after screening for 22q11 microdeletion. J Med Genet 34:188-190.
206. Digilio MC, Marino B, Musolino AM, Giannotti A, Dallapiccola B. 2000. Familial recurrence of nonsyndromic interrupted aortic arch and truncus arteriosus with atrioventricular canal. Teratology 61:329-331.
207. Nora JJ, Nora AH. 1987. Maternal transmission of congenital heart diseases: new recurrence risk figures and the questions of cytoplasmic inheritance and vulnerability to teratogens. Am J Cardiol 59:459-463.
208. Connolly HM, Warnes CA. 1994. Ebstein's anomaly: outcome of pregnancy. J Am Coll Cardiol 23:1194-1198.
209. Hobbs CA, James SJ, Parsian A, Krakowiak PA, Jernigan S, Greenhaw JJ, Lu Y, Cleves MA. 2006. Congenital heart defects and genetic variants in the methylenetetrahydroflate reductase gene. J Med Genet 43:162-166.
210. van Beynum IM, Kapusta L, den Heijer M, Vermeulen SH, Kouwenberg M, Daniels O, Blom HJ. 2006. Maternal MTHFR 677C>T is a risk factor for congenital heart defects: effect modification by periconceptional folate supplementation. Eur Heart J 27:981-987.
211. Loffredo CA. 2000. Epidemiology of cardiovascular malformations: prevalence and risk factors. Am J Med Genet 97:319-325.
212. Belmont JW, Mohapatra B, Towbin JA, Ware SM. 2004. Molecular genetics of heterotaxy syndromes. Curr Opin Cardiol 19:216-220.
213. Hornberger LK. 2006. Maternal diabetes and the fetal heart. Heart 92:1019-1021.
214. Becerra JE, Khoury MJ, Cordero JF, Erickson JD. 1990. Diabetes mellitus during pregnancy and the risks for specific birth defects: a population-based case-control study. Pediatrics 85:1-9.
215. Kitzmiller JL, Gavin LA, Gin GD, Jovanovic-Peterson L, Main EK, Zigrang WD. 1991. Preconception care of diabetes. Glycemic control prevents congenital anomalies. Jama 265:731-736.
216. Ferencz C, Boughman JA. 1993. Congenital heart disease in adolescents and adults. Teratology, genetics, and recurrence risks. Cardiol Clin 11:557-567.
217. Botto LD, Lynberg MC, Erickson JD. 2001. Congenital heart defects, maternal febrile illness, and multivitamin use: a population-based study. Epidemiology 12:485-490.
218. Tikkanen J, Heinonen OP. 1991. Maternal hyperthermia during pregnancy and cardiovascular malformations in the offspring. Eur J Epidemiol 7:628-635.
219. Zhang J, Cai WW. 1993. Association of the common cold in the first trimester of pregnancy with birth defects. Pediatrics 92:559-563.
220. Tikkanen J, Heinonen OP. 1992. Risk factors for atrial septal defect. Eur J Epidemiol 8:509-515.
221. Williams LJ, Correa A, Rasmussen S. 2004. Maternal lifestyle factors and risk for ventricular septal defects. Birth Defects Res A Clin Mol Teratol 70:59-64.

222. Lipshultz SE, Frassica JJ, Orav EJ. 1991. Cardiovascular abnormalities in infants prenatally exposed to cocaine. J Pediatr 118:44-51.
223. Dansky LV, Andermann E, Rosenblatt D, Sherwin AL, Andermann F. 1987. Anticonvulsants, folate levels, and pregnancy outcome: a prospective study. Ann Neurol 21:176-182.
224. Pradat P. 1992. A case-control study of major congenital heart defects in Sweden--1981-1986. Eur J Epidemiol 8:789-796.
225. Dansky LV, Finnell RH. 1991. Parental epilepsy, anticonvulsant drugs, and reproductive outcome: epidemiologic and experimental findings spanning three decades; 2: Human studies. Reprod Toxicol 5:301-335.
226. Tikkanen J, Heinonen OP. 1991. Risk factors for ventricular septal defect in Finland. Public Health 105:99-112.
227. Tikkanen J, Heinonen OP. 1992. Risk factors for conal malformations of the heart. Eur J Epidemiol 8:48-57.
228. Tikkanen J, Heinonen OP. 1993. Risk factors for coarctation of the aorta. Teratology 47:565-572.
229. Loffredo CA, Silbergeld EK, Ferencz C, Zhang J. 2001. Association of transposition of the great arteries in infants with maternal exposures to herbicides and rodenticides. Am J Epidemiol 153:529-536.
230. Botto LD, Loffredo C, Scanlon KS, Ferencz C, Khoury MJ, David Wilson P, Correa A. 2001. Vitamin A and cardiac outflow tract defects. Epidemiology 12:491-496.
231. Shaw GM, Wasserman CR, Block G, Lammer EJ. 1996. High maternal vitamin A intake and risk of anomalies of structures with a cranial neural crest cell contribution. Lancet 347:899-900.
232. Khoury MJ, Moore CA, Mulinare J. 1996. Vitamin A and birth defects. Lancet 347:322.
233. Smedts HP, de Vries JH, Rakhshandehroo M, Wildhagen MF, Verkleij-Hagoort AC, Steegers EA, Steegers-Theunissen RP. 2009. High maternal vitamin E intake by diet or supplements is associated with congenital heart defects in the offspring. Bjog 116:416-423.
234. Gibson S, Lewis KC. 1952. Congenital heart disease following maternal rubella during pregnancy. AMA Am J Dis Child 83:317-319.
235. Stuckey D. 1956. Congenital heart defects following maternal rubella during pregnancy. Br Heart J 18:519-522.
236. Scanlon KS, Ferencz C, Loffredo CA, Wilson PD, Correa-Villasenor A, Khoury MJ, Willett WC. 1998. Preconceptional folate intake and malformations of the cardiac outflow tract. Baltimore-Washington Infant Study Group. Epidemiology 9:95-98.
237. Weismann CG, Hager A, Kaemmerer H, Maslen CL, Morris CD, Schranz D, Kreuder J, Gelb BD. 2005. PTPN11 mutations play a minor role in isolated congenital heart disease. Am J Med Genet A 136:146-151.
238. Schluterman MK, Krysiak AE, Kathiriya IS, Abate N, Chandalia M, Srivastava D, Garg V. 2007. Screening and biochemical analysis of GATA4 sequence variations identified in patients with congenital heart disease. Am J Med Genet A 143:817-823.
239. Posch MG, Perrot A, Schmitt K, Mittelhaus S, Esenwein EM, Stiller B, Geier C, Dietz R, Gessner R, Ozcelik C, Berger F. 2008. Mutations in GATA4, NKX2.5, CRELD1, and BMP4 are infrequently found in patients with congenital cardiac septal defects. Am J Med Genet A 146A:251-253.
240. Konig K, Will JC, Berger F, Muller D, Benson DW. 2006. Familial congenital heart disease, progressive atrioventricular block and the cardiac homeobox transcription factor gene NKX2.5: identification of a novel mutation. Clin Res Cardiol 95:499-503.
241. Ikeda Y, Hiroi Y, Hosoda T, Utsunomiya T, Matsuo S, Ito T, Inoue J, Sumiyoshi T, Takano H, Nagai R, Komuro I. 2002. Novel point mutation in the cardiac transcription factor CSX/NKX2.5 associated with congenital heart disease. Circ J 66:561-563.
242. Bjornstad PG, Leren TP. 2008. Familial atrial septal defect in the oval fossa with progressive prolongation of the atrioventricular conduction caused by mutations in the NKX2.5 gene. Cardiol Young:1-5.
243. Pabst S, Wollnik B, Rohmann E, Hintz Y, Glanzer K, Vetter H, Nickenig G, Grohe C. 2008. A novel stop mutation truncating critical regions of the cardiac transcription factor NKX2-5 in a large family with autosomal-dominant inherited congenital heart disease. Clin Res Cardiol 97:39-42.
244. Gioli-Pereira L, Pereira AC, Mesquita SM, Xavier-Neto J, Lopes AA, Krieger JE. 2008. NKX2.5 mutations in patients with non-syndromic congenital heart disease. Int J Cardiol.
245. Akcaboy MI, Cengiz FB, Inceoglu B, Ucar T, Atalay S, Tutar E, Tekin M. 2008. The effect of p.Arg25Cys alteration in NKX2-5 on conotruncal heart anomalies: mutation or polymorphism? Pediatr Cardiol 29:126-129.
246. Gebbia M, Ferrero GB, Pilia G, Bassi MT, Aylsworth A, Penman-Splitt M, Bird LM, Bamforth JS, Burn J, Schlessinger D, Nelson DL, Casey B. 1997. X-linked situs abnormalities result from mutations in ZIC3. Nat Genet 17:305-308.
247. Basson CT, Huang T, Lin RC, Bachinsky DR, Weremowicz S, Vaglio A, Bruzzone R, Quadrelli R, Lerone M, Romeo G, Silengo M, Pereira A, Krieger J, Mesquita SF, Kamisago M, Morton CC, Pierpont ME, Muller CW, Seidman JG, Seidman CE. 1999. Different TBX5 interactions in heart and limb defined by Holt-Oram syndrome mutations. Proc Natl Acad Sci U S A 96:2919-2924.
248. Maslen CL. 2004. Molecular genetics of atrioventricular septal defects. Curr Opin Cardiol 19:205-210.

249. Ransom JF, King IN, Garg V, Srivastava D. 2008. A Rare Human Sequence Variant Reveals Myocardin Autoinhibition. J Biol Chem 283:35845-35852.
250. Reamon-Buettner SM, Borlak J. 2005. GATA4 zinc finger mutations as a molecular rationale for septation defects of the human heart. J Med Genet 42:e32.
251. Reamon-Buettner SM, Cho SH, Borlak J. 2007. Mutations in the 3'-untranslated region of GATA4 as molecular hotspots for congenital heart disease (CHD). BMC Med Genet 8:38.

1.3 Aim and outline of the thesis

This thesis presents clinical and molecular studies of patients and families with different congenital heart malformations (CHM) during a 10-years period between 1998 and 2008. Patients were examined in the Division of Obstetrics and Prenatal Medicine of the Department of Obstetrics and Gynaecology of the ErasmusMC (fetuses), in the outclinic of the Department of Pediatric Cardiology of the Sophia Children's Hospital (children), in the outclinic of the Department of Cardiology at the Thorax Center of the ErasmusMC (adults), and in the Department of Clinical Genetics of the ErasmusMC (children and adults). The variety of cardiac phenotypes described in this thesis reflects the daily practice of the clinical geneticist involved in genetic counseling of patients affected with CHM. Working at different departments (first as ultrasonographist practising fetal echocardiology, and later as a clinical geneticist) I had the opportunity to study CHM in patients at different ages (fetuses, children, and adults) and observe the 'genetic link' between the different phenotypes present in family members sometimes known as 'isolated' cases in the different departments.

The aim of the studies in this thesis was to describe cardiac phenotypes in familial CHM, and identify disease genes involved in human CHM. A broad spectrum of syndromic and non-syndromic forms of CHM was studied, including laterality defects, left ventricular outflow tract obstruction (LVOTO) anomalies, arterial malformations, and CHM in association with cardiomyopathies.

Chapter 1 reviews the genetic and environmental factors contributing to human congenital heart malformations.

Chapter 2 reports clinical and molecular studies in patients with laterality defects. The prenatal phenotype of Kartagener syndrome is described, and molecular studies on a subtype of Kartagener syndrome, acilia syndrome, are presented. A new syndrome with laterality defects and VACTERL association is reported, and this syndrome is shown to be due to a new disease mechanism (repeat amplification) in the *ZIC3* gene.

Chapter 3 describes multiple families with autosomal dominant inheritance of left ventricular outflow tract obstruction (LVOTO) and/or cardiac valve anomalies, and discusses possible pathogenetic pathways and disease genes involved in these CHM.

Chapter 4 delineates the clinical features of arterial tortuosity syndrome, and reports linkage analysis in three inbred families with this syndrome leading to the identification of the *SLC2A10* gene encoding GLUT10 as the disease gene involved in arterial tortuosity syndrome.

Chapter 5 reports different genetic associations of CHM with cardiomyopathies. A new autosomal dominant syndrome with laterality defects and cardiomyopathy could be linked to chromsome 6p. A severe type of early cardiomyopathy with septal defects is reported to be due to compound heterozygosity for mutations in a sarcomeric protein gene MYBPC3. Finally, another sarcomeric protein gene *MYH7* is implicated in Ebstein anomaly and septal defects.

Chapter 6 discusses the significance and implications of our studies and delineates future perspectives.

CHAPTER 2

Laterality disorders

2.1 Introduction

2.1.1 Ciliary defects

2.1.1.1 Primary ciliary dyskinesia

2.1.1.2 Hepatorenal fibrocystic (HRFC) syndromes

2.1.2 Defects of the NODAL pathway

2.2 Mild fetal cerebral ventriculomegaly as a prenatal sonographic marker for Kartagener syndrome

Wessels MW, den Hollander NS, Willems PJ

Prenat Diagn 2003; 23: 239-242

2.3 Candidate gene analysis in three families with acilia syndrome

Wessels MW, Avital A, Failly M, Munoz A, Omran H, Blouin JL, Willems PJ

Am J Med Genet 2008; 146A: 1765-1767

2.4 Polyalanine expansion in the *ZIC3* gene leading to X-linked heterotaxy with VACTERL association, a new polyalanine disorder?

Wessels MW, Kuchinka B, Heydanus R, Smit BJ, Dooijes D, de Krijger RR, Lequin MH, de Jong EM, Husen M, Willems PJ, Casey B

J Med Genet 2009; in press

CHAPTER 2

Laterality disorders

2.1 Introduction

Laterality defects refer to a group of disorders indicating embryonic disruption of normal left- right (LR) patterning. The usual orientation of the heart and other organs is called "situs solitus". A complete mirror image arrangement of all internal organs is called "situs inversus". Any LR arrangement other than situs solitus and situs inversus is called "heterotaxy" or "situs ambiguous". Heterotaxy is frequently associated with "isomerism", a defect in the asymmetry of paired organs with distinct right or left anatomy. "Left isomerism" is characterized by bilateral left-sidedness with anomalies such as bilateral left atrial appendages, bilateral bilobed lungs, polysplenia, and congenital heart malformations (CHM). "Right isomerism" is characterized by bilateral right-sidedness with anomalies including bilateral right atrial appendages, bilateral trilobed lungs, asplenia, and CHM. However, a wide phenotypic spectrum is seen in heterotaxy, and patients can have a mixture of abnormalities of left or right isomerism. Over the past years several extensive reviews on the genetics of heterotaxy have been published [1-6]. It has been postulated that LR patterning genes not only play a role in complex laterality disorders, but are also implicated in isolated CHM, biliary tract anomalies, cystic renal disease and malrotation of the gut [6]. As the phenotypes caused by defects in the determination of LR asymmetry in mice and man are strikingly similar, molecular studies in mice models can be of help to understand human disorders of LR patterning. Up till now more than 80 genes involved in the process of LR patterning have been identified in animal studies. Several excellent reviews concerning the establishment of the LR axis in various animal model systems have been published [7-13].

2.1.1 Ciliary defects

Cilia consist of a microtubule-based axoneme, a highly ordered structure of nine peripheral microtubule doublets arranged around a central core that may or may not contain two central microtubules (9+2 or 9+0 axonemes). Most 9+0 cilia lack dynein arms, are non-motile and also called primairy cilia, whereas 9+2 cilia usually have dynein arms that link the microtubule doublets and are motile. The ciliary axoneme extends from the basal body-centrosome complex in the cytoplasm towards the tip of the cilia. Ciliary assembly and maintenance is accomplished by intraflagellar transport (IFT), which relies on the microtubule motor proteins kinesin 2 and cytoplasmic dynein to transport IFT protein complexes and their associated cargo up and down the length of the cilium [12]. Cilia are present at the node, a local thickening of the blastoderm at the end of the primitive streak of the embryo (Figure 1). The leftward movement of fluid at the ventral node generated by the cilia, called nodal flow, is the essential proc-

ess in symmetry breaking on the LR axis. How nodal flow leads to LR asymmetry is not yet clear [12,14]. However, leftward nodal flow triggers Notch signaling, which is crucial for the asymmetric expression of Nodal in the left perinodal region [15].

Dysfunction of ciliary proteins causes impaired functioning of nodal cilia and nodal flow, leading to phenotypes that range from organ-specific diseases (e.g. polycystic kidney disease) to pleiotropic syndromes (e.g. Meckel syndrome). Situs abnormalities are part of many of these phenotypes. Two distinct groups of human disorders are caused by ciliary defects: primairy ciliary dyskinesia (PCD) caused by defective 9+2 cilia, and the hepatorenal fibrocystic (HRFC) syndromes caused by defective 9+0 cilia. Additionally, many mice models with ciliary defects have been described (for reviews: see refs [12,16]).

2.1.1.1 Primary ciliary dyskinesia

Immotile cilia syndrome (ICS), also called primary ciliary dyskinesia (PCD), is a specific group of laterality disorders. PCD is typically characterised by recurrent respiratory tract infections, and infertility due to immotile sperm. In 50% of PCD patients situs inversus is also present, in which case PCD is referred to as Kartagener syndrome. PCD is diagnosed by electron microscopy of nasal ciliary biopsy, as it is caused by immotile or dysmotile 9+2 (motile) cilia present on the epithelium of the respiratory tract, oviduct, efferent ductules of the testis and ependymal lining of the brain [16]. PCD is caused by defects in the structure of the ciliary axoneme, most commonly loss of the outer dynein arms.

As the cilia are complex structures and more than 20 human genes are predicted to encode outer dynein arm subunits and associated proteins possibly necessary for outer arm assembly, it is not unexpected that PCD is genetically heterogeneous [17]. Until recently molecular defects in four genes encoding dynein components have been identified: *DNAH5* [18], *DNAI1* [19-22], *DNAI2* [23] and *DNAH11* [24]. Mutational analysis has demonstrated that 38% of PCD patients carry mutations in *DNAI1* or *DNAH5* [25]. Recently mutations in the *KTU* gene were identified in patients with PCD [26]. The Ktu protein is required in the cytoplasm for the preassembly of dynein arm complexes before they become transferred to their functional positions in the axenoma [26]. Additionally, mutations in the *TXNDC3* gene, encoding a thioredoxin-nucleoside diphosphate kinase, that was shown to bind microtubules, was recently implicated in PCD patients with situs ambiguous and situs inversus totalis [27]. Mutations in the X-linked retinitis pigmentosa GTPase regulator gene (RPGR), the gene most frequently implicated in X-linked retinitis pigmentosa, have been found in patients with retinitis pigmentosa, PCD and abnormal situs characterized by partial dynein arm defects [28]. About 6 % of Kartagener syndrome patients have no situs inversus but heterotaxy (ambiguous situs with mainly left isomerism), with CHM in more than half of these patients [29].

In this thesis genetic studies are described in three families with acilia syndrome, an infrequent form of PCD characterized by total absence of cilia [30]. In one of these families heterotaxy and CHM are also present [30]. We further describe mild cerebral ventriculomegaly as an early sign of PCD in fetuses [31]. Later also Kosaki et al. [32] reported ventriculomegaly and situs abnormalities in 2 fetuses with Kartagener syndrome. Such ventriculomegaly is caused by impaired flow of the ependymal cilia [33,34]. Ventriculomegaly is not often documented in postnatal series of PCD, as most cases have no clinical symptoms, so this feature escapes attention.

2.1.1.2 Hepatorenal fibrocystic (HRFC) syndromes

The primary or sensory 9+0 (immotile) cilia are present on nearly all cell types in mammals, including principal cells of the nephron, rod and cone photoreceptor cells, hair cells of the inner ear, olfactory sensory neurons and chondrocytes [16,35]. Defects of the 9+0 cilia result in malformation syndromes with overlapping features, referred as hepatorenal fibrocystic (HRFC) syndromes [36]. Features common to HRFC syndromes are hepatorenal fibrocystic disease, situs abnormalities with CHM, retinitis pigmentosa, postaxial polydactyly and skeletal dysplasia. Disorders included in this spectrum are the polycystic kidney disorders, nephronophthisis, Meckel-Gruber syndrome, Joubert syndrome, Leber congenital amaurosis, Bardet-Biedl syndrome, orofaciodigital syndrome, short rib-polydactyly syndromes, Jeune syndrome, and Ellis van Creveld syndrome [36]. Many of these syndromes show clinical overlap with each other, and are due to mutations in the same gene.

2.1.2 Defects of the NODAL pathway

Several excellent reviews provide an overview of the molecular network regulating the establishment of LR asymmetry through NODAL signaling [3,13,37]. Four highly conserved genes *Nodal, Lefty1, Lefty2* and *Pitx2* define the core of the NODAL signaling pathway (Figure 1). These 4 genes are all expressed asymmetrically near the midline or in the left lateral plate mesoderm at comparable developmental stages. The first mutations in patients with laterality defects were identified in the *ZIC3* gene encoding a zinc finger transcription factor from patients with X-linked heterotaxy [38]. *ZIC3* mutations were later also been identified in males with isolated CHM (often transposition of the great arteries), isolated heterotaxy, and a combination of heterotaxy and midline developmental anomalies such as anal and vertebral anomalies [38-40].

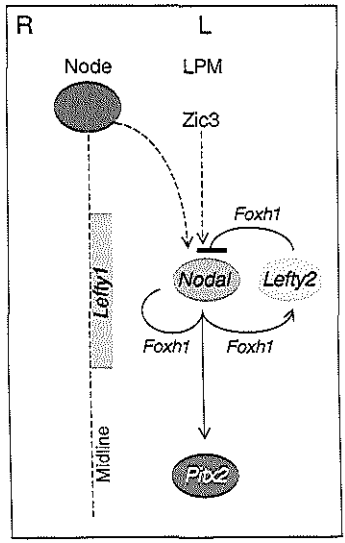

Figure 1 | Genetic pathway for LR patterning
The leftward movement of fluid at the ventral node generated by the cilia, called nodal flow, is the essential process in symmetry breaking on the LR axis. An asymmetric signal initiates Nodal-Lefty1-Lefty2 regulatory loops in the left lateral plate mesoderm (LPM). Nodal activity induces Pitx2 expression in the left LPM. The broken line represents the midline. Foxh1 is a component of the Nodal-Lefty loops. Zic3 acts upstream of Nodal at the node. Adapted from ref [37] with permission from Dr. Hiroshi Hamada.

Zic3 acts upstream of Nodal in the LR axis. Other human orthologs of the NODAL signaling genes have been associated with only a small percentage of human non-syndromic laterality disorders, and overall the specific genetic defect causing heterotaxy is known in less than 5 % of the patients [41-43]. A few mutations have been found in several components of the NODAL signal transduction pathway, including the *ACVR2B* [44], *NODAL* [43], *GDF1* [42], *FOXH1* [41], *TDGF1 (CRIPTO)* [41], *CFC1(CRYPTIC)* [45,46], and *LEFTY2* [47] genes. Mutations in these genes can also give rise to CHM without laterality defects, or combinations of laterality defects with CHM. A limited number of families with autosomal recessive or autosomal dominant laterality defects have been reported [48-50].

In this thesis a mutation in the *ZIC3* gene is described in a patient with heterotaxy and VACTERL association. VACTERL is an acronym for Vertebral anomalies, Anal atresia, Cardiac malformations, Tracheo-esophageal fistula, Renal anomalies, and Limb anomalies. A spectrum of developmental anomalies strikingly similar to that of VACTERL association has been reported in mice with defective Gli-Shh signaling, a pathway that interacts with *Zic* genes [51]. This suggests that *ZIC3* might be involved in the different developmental anomalies of the VACTERL association. The *ZIC3* mutation in our family is a novel type of *ZIC3* mutation, and consists of repeat amplification leading to elongation of the polyalanine stretch. In this thesis a new autosomal dominant form of left isomerism characterized by left bronchial isomerism, azygous continuation of the inferior vena cava, polysplenia and intestinal malrotation is reported. The cardiac anomalies included noncompaction of the ventricular myocardium, bradycardia, pulmonary valvular stenosis, and secundum atrial septal defect. The disease gene could be localized to chromosome 6p, but has not yet been identified [52].

References

1. Casey B. 2001. Genetics of human situs abnormalities. Am J Med Genet 101:356-358.
2. Kosaki K, Casey B. 1998. Genetics of human left-right axis malformations. Semin Cell Dev Biol 9:89-99.
3. Zhu L, Belmont JW, Ware SM. 2006. Genetics of human heterotaxias. Eur J Hum Genet 14:17-25.
4. Belmont JW, Mohapatra B, Towbin JA, Ware SM. 2004. Molecular genetics of heterotaxy syndromes. Curr Opin Cardiol 19:216-220.
5. Peeters H, Devriendt K. 2006. Human laterality disorders. Eur J Med Genet 49:349-362.
6. Maclean K, Dunwoodie SL. 2004. Breaking symmetry: a clinical overview of left-right patterning. Clin Genet 65:441-457.
7. Yost HJ. 2003. Left-right asymmetry: nodal cilia make and catch a wave. Curr Biol 13:R808-809.
8. Yost HJ. 2001. Establishment of left-right asymmetry. Int Rev Cytol 203:357-381.
9. Mercola M. 1999. Embryological basis for cardiac left-right asymmetry. Semin Cell Dev Biol 10:109-116.
10. Mercola M. 2003. Left-right asymmetry: nodal points. J Cell Sci 116:3251-3257.
11. Boorman CJ, Shimeld SM. 2002. The evolution of left-right asymmetry in chordates. Bioessays 24:1004-1011.
12. Bisgrove BW, Yost HJ. 2006. The roles of cilia in developmental disorders and disease. Development 133:4131-4143.
13. Palmer AR. 2004. Symmetry breaking and the evolution of development. Science 306:828-833.
14. Hirokawa N, Tanaka Y, Okada Y, Takeda S. 2006. Nodal flow and the generation of left-right asymmetry. Cell 125:33-45.
15. Raya A, Kawakami Y, Rodriguez-Esteban C, Buscher D, Koth CM, Itoh T, Morita M, Raya RM, Dubova I, Bessa JG, de la Pompa JL, Belmonte JC. 2003. Notch activity induces Nodal expression and mediates the establishment of left-right asymmetry in vertebrate embryos. Genes Dev 17:1213-1218.
16. Eley L, Yates LM, Goodship JA. 2005. Cilia and disease. Curr Opin Genet Dev 15:308-314.
17. Pazour GJ, Agrin N, Walker BL, Witman GB. 2006. Identification of predicted human outer dynein arm genes: candidates for primary ciliary dyskinesia genes. J Med Genet 43:62-73.
18. Hornef N, Olbrich H, Horvath J, Zariwala MA, Fliegauf M, Loges NT, Wildhaber J, Noone PG, Kennedy M, Antonarakis SE, Blouin JL, Bartoloni L, Nusslein T, Ahrens P, Griese M, Kuhl H, Sudbrak R, Knowles MR, Reinhardt R, Omran H. 2006. DNAH5 mutations are a common cause of primary ciliary dyskinesia with outer dynein arm defects. Am J Respir Crit Care Med 174:120-126.
19. Guichard C, Harricane MC, Lafitte JJ, Godard P, Zaegel M, Tack V, Lalau G, Bouvagnet P. 2001. Axonemal dynein intermediate-chain gene (DNAI1) mutations result in situs inversus and primary ciliary dyskinesia (Kartagener syndrome). Am J Hum Genet 68:1030-1035.
20. Pennarun G, Escudier E, Chapelin C, Bridoux AM, Cacheux V, Roger G, Clement A, Goossens M, Amselem S, Duriez B. 1999. Loss-of-function mutations in a human gene related to Chlamydomonas reinhardtii dynein IC78 result in primary ciliary dyskinesia. Am J Hum Genet 65:1508-1519.
21. Zariwala M, Noone PG, Sannuti A, Minnix S, Zhou Z, Leigh MW, Hazucha M, Carson JL, Knowles MR. 2001. Germline mutations in an intermediate chain dynein cause primary ciliary dyskinesia. Am J Respir Cell Mol Biol 25:577-583.
22. Zariwala MA, Leigh MW, Ceppa F, Kennedy MP, Noone PG, Carson JL, Hazucha MJ, Lori A, Horvath J, Olbrich H, Loges NT, Bridoux AM, Pennarun G, Duriez B, Escudier E, Mitchison HM, Chodhari R, Chung EM, Morgan LC, de Iongh RU, Rutland J, Pradal U, Omran H, Amselem S, Knowles MR. 2006. Mutations of DNAI1 in primary ciliary dyskinesia: evidence of founder effect in a common mutation. Am J Respir Crit Care Med 174:858-866.
23. Loges NT, Olbrich H, Fenske L, Mussaffi H, Horvath J, Fliegauf M, Kuhl H, Baktai G, Peterffy E, Chodhari R, Chung EM, Rutman A, O'Callaghan C, Blau H, Tiszlavicz L, Voelkel K, Witt M, Zietkiewicz E, Neesen J, Reinhardt R, Mitchison HM, Omran H. 2008. DNAI2 mutations cause primary ciliary dyskinesia with defects in the outer dynein arm. Am J Hum Genet 83:547-558.
24. Bartoloni L, Blouin JL, Pan Y, Gehrig C, Maiti AK, Scamuffa N, Rossier C, Jorissen M, Armengot M, Meeks M, Mitchison HM, Chung EM, Delozier-Blanchet CD, Craigen WJ, Antonarakis SE. 2002. Mutations in the DNAH11 (axonemal heavy chain dynein type 11) gene cause one form of situs inversus totalis and most likely primary ciliary dyskinesia. Proc Natl Acad Sci U S A 99:10282-10286.
25. Zariwala MA, Knowles MR, Omran H. 2007. Genetic defects in ciliary structure and function. Annu Rev Physiol 69:423-450.
26. Omran H, Kobayashi D, Olbrich H, Tsukahara T, Loges NT, Hagiwara H, Zhang Q, Leblond G, O'Toole E, Hara C, Mizuno H, Kawano H, Fliegauf M, Yagi T, Koshida S, Miyawaki A, Zentgraf H, Seithe H, Reinhardt R, Watanabe Y, Kamiya R, Mitchell DR, Takeda H. 2008. Ktu/PF13 is required for cytoplasmic pre-assembly of axonemal dyneins. Nature 456:611-616.

27. Duriez B, Duquesnoy P, Escudier E, Bridoux AM, Escalier D, Rayet I, Marcos E, Vojtek AM, Bercher JF, Amselem S. 2007. A common variant in combination with a nonsense mutation in a member of the thioredoxin family causes primary ciliary dyskinesia. Proc Natl Acad Sci U S A 104:3336-3341.
28. Moore A, Escudier E, Roger G, Tamalet A, Pelosse B, Marlin S, Clement A, Geremek M, Delaisi B, Bridoux AM, Coste A, Witt M, Duriez B, Amselem S. 2006. RPGR is mutated in patients with a complex X linked phenotype combining primary ciliary dyskinesia and retinitis pigmentosa. J Med Genet 43:326-333.
29. Kennedy MP, Omran H, Leigh MW, Dell S, Morgan L, Molina PL, Robinson BV, Minnix SL, Olbrich H, Severin T, Ahrens P, Lange L, Morillas HN, Noone PG, Zariwala MA, Knowles MR. 2007. Congenital heart disease and other heterotaxic defects in a large cohort of patients with primary ciliary dyskinesia. Circulation 115:2814-2821.
30. Wessels MW, Avital A, Failly M, Munoz A, Omran H, Blouin JL, Willems PJ. 2008. Candidate gene analysis in three families with acilia syndrome. Am J Med Genet A 146A:1765-1767.
31. Wessels MW, den Hollander NS, Willems PJ. 2003. Mild fetal cerebral ventriculomegaly as a prenatal sonographic marker for Kartagener syndrome. Prenat Diagn 23:239-242.
32. Kosaki K, Ikeda K, Miyakoshi K, Ueno M, Kosaki R, Takahashi D, Tanaka M, Torikata C, Yoshimura Y, Takahashi T. 2004. Absent inner dynein arms in a fetus with familial hydrocephalus-situs abnormality. Am J Med Genet A 129:308-311.
33. Jabourian Z, Lublin FD, Adler A, Gonzales C, Northrup B, Zwillenberg D. 1986. Hydrocephalus in Kartagener's syndrome. Ear Nose Throat J 65:468-472.
34. Ibanez-Tallon I, Gorokhova S, Heintz N. 2002. Loss of function of axonemal dynein Mdnah5 causes primary ciliary dyskinesia and hydrocephalus. Hum Mol Genet 11:715-721.
35. Wheatley DN, Wang AM, Strugnell GE. 1996. Expression of primary cilia in mammalian cells. Cell Biol Int 20:73-81.
36. Johnson CA, Gissen P, Sergi C. 2003. Molecular pathology and genetics of congenital hepatorenal fibrocystic syndromes. J Med Genet 40:311-319.
37. Shiratori H, Hamada H. 2006. The left-right axis in the mouse: from origin to morphology. Development 133:2095-2104.
38. Gebbia M, Ferrero GB, Pilia G, Bassi MT, Aylsworth A, Penman-Splitt M, Bird LM, Bamforth JS, Burn J, Schlessinger D, Nelson DL, Casey B. 1997. X-linked situs abnormalities result from mutations in ZIC3. Nat Genet 17:305-308.
39. Megarbane A, Salem N, Stephan E, Ashoush R, Lenoir D, Delague V, Kassab R, Loiselet J, Bouvagnet P. 2000. X-linked transposition of the great arteries and incomplete penetrance among males with a nonsense mutation in ZIC3. Eur J Hum Genet 8:704-708.
40. Ware SM, Peng J, Zhu L, Fernbach S, Colicos S, Casey B, Towbin J, Belmont JW. 2004. Identification and functional analysis of ZIC3 mutations in heterotaxy and related congenital heart defects. Am J Hum Genet 74:93-105.
41. Roessler E, Ouspenskaia MV, Karkera JD, Velez JI, Kantipong A, Lacbawan F, Bowers P, Belmont JW, Towbin JA, Goldmuntz E, Feldman B, Muenke M. 2008. Reduced NODAL Signaling Strength via Mutation of Several Pathway Members Including FOXH1 Is Linked to Human Heart Defects and Holoprosencephaly. Am J Hum Genet.
42. Karkera JD, Lee JS, Roessler E, Banerjee-Basu S, Ouspenskaia MV, Mez J, Goldmuntz E, Bowers P, Towbin J, Belmont JW, Baxevanis AD, Schier AF, Muenke M. 2007. Loss-of-function mutations in growth differentiation factor-1 (GDF1) are associated with congenital heart defects in humans. Am J Hum Genet 81:987-994.
43. Mohapatra B, Casey B, Li H, Ho-Dawson T, Smith L, Fernbach SD, Molinari L, Niesh SR, Jefferies JL, Craigen WJ, Towbin JA, Belmont JW, Ware SM. 2008. Identification and functional characterization of NODAL rare variants in heterotaxy and isolated cardiovascular malformations. Hum Mol Genet.
44. Kosaki R, Gebbia M, Kosaki K, Lewin M, Bowers P, Towbin JA, Casey B. 1999. Left-right axis malformations associated with mutations in ACVR2B, the gene for human activin receptor type IIB. Am J Med Genet 82:70-76.
45. Bamford RN, Roessler E, Burdine RD, Saplakoglu U, dela Cruz J, Splitt M, Goodship JA, Towbin J, Bowers P, Ferrero GB, Marino B, Schier AF, Shen MM, Muenke M, Casey B. 2000. Loss-of-function mutations in the EGF-CFC gene CFC1 are associated with human left-right laterality defects. Nat Genet 26:365-369.
46. Ozcelik C, Bit-Avragim N, Panek A, Gaio U, Geier C, Lange PE, Dietz R, Posch MG, Perrot A, Stiller B. 2006. Mutations in the EGF-CFC gene cryptic are an infrequent cause of congenital heart disease. Pediatr Cardiol 27:695-698.
47. Kosaki K, Bassi MT, Kosaki R, Lewin M, Belmont J, Schauer G, Casey B. 1999. Characterization and mutation analysis of human LEFTY A and LEFTY B, homologues of murine genes implicated in left-right axis development. Am J Hum Genet 64:712-721.
48. Alonso S, Pierpont ME, Radtke W, Martinez J, Chen SC, Grant JW, Dahnert I, Taviaux S, Romey MC, Demaille J, et al. 1995. Heterotaxia syndrome and autosomal dominant inheritance. Am J Med Genet 56:12-15.
49. Casey B, Cuneo BF, Vitali C, van Hecke H, Barrish J, Hicks J, Ballabio A, Hoo JJ. 1996. Autosomal dominant transmission of familial laterality defects. Am J Med Genet 61:325-328.

50. Vitale E, Brancolini V, De Rienzo A, Bird L, Allada V, Sklansky M, Chae CU, Ferrero GB, Weber J, Devoto M, Casey B. 2001. Suggestive linkage of situs inversus and other left-right axis anomalies to chromosome 6p. J Med Genet 38:182-185.
51. Kim J, Kim P, Hui CC. 2001. The VACTERL association: lessons from the Sonic hedgehog pathway. Clin Genet 59:306-315.
52. Wessels MW, De Graaf BM, Cohen-Overbeek TE, Spitaels SE, de Groot-de Laat LE, Ten Cate FJ, Frohn-Mulder IF, de Krijger R, Bartelings MM, Essed N, Wladimiroff JW, Niermeijer MF, Heutink P, Oostra BA, Dooijes D, Bertoli-Avella AM, Willems PJ. 2008. A new syndrome with noncompaction cardiomyopathy, bradycardia, pulmonary stenosis, atrial septal defect and heterotaxy with suggestive linkage to chromosome 6p. Hum Genet 122:595-603.

2.2

PRENATAL DIAGNOSIS
Prenat Diagn 2003; **23**: 239–242.
Published online in Wiley InterScience (www.interscience.wiley.com). **DOI:** 10.1002/pd.551

Mild fetal cerebral ventriculomegaly as a prenatal sonographic marker for Kartagener syndrome

Marja W. Wessels[1,2]*, Nicolette S. den Hollander[2,3] and Patrick J. Willems[4]

[1]*Department of Clinical Genetics, Erasmus University Medical Centre, Rotterdam, The Netherlands*
[2]*Department of Obstetrics and Gynaecology, Erasmus University Medical Centre, Rotterdam, The Netherlands*
[3]*Department of Clinical Genetics, Leiden University Medical Centre, Leiden, The Netherlands*
[4]*Synergene NV, Mechelen, Belgium*

Primary ciliary dyskinesia (PCD), also referred to as immotile-cilia syndrome or Kartagener syndrome, is a group of genetic disorders caused by defective cilia leading to chronic sinupulmonary infection, situs inversus and reduced fertility. Some PCD patients also have cerebral ventriculomegaly or hydrocephalus.

We report here two fetuses and one newborn with mild cerebral ventriculomegaly and a suspected and/or confirmed diagnosis of PCD. These cases demonstrate that mild fetal cerebral ventriculomegaly can be a prenatal sonographic marker of PCD, certainly in fetuses with situs inversus or a history of a previous sib with PCD. Copyright © 2003 John Wiley & Sons, Ltd.

KEY WORDS: fetal cerebral ventriculomegaly; Kartagener syndrome; primary ciliary dyskinesia (PCD); prenatal diagnosis

INTRODUCTION

Primary ciliary dyskinesia (PCD) or immotile-cilia syndrome is a genetically heterogeneous disease with an estimated incidence of 1 in 20.000 to 60.000 live births (Afzelius, 1976; Afzelius *et al.*, 2001). PCD is characterized by recurrent or chronic sinupulmonary infections including sinusitis, rhinitis and bronchitis, which eventually leads to bronchiectasis. The infections are caused by dysmotility, immotility or the absence of cilia. Cilia are normally present on the epithelia lining the sinuses and the respiratory tract where they are responsible for the drainage of foreign particles and microorganisms. Reduced fertility is often present in PCD, certainly in male patients, as cilia are also present on the epithelia of the female oviduct and the male vas deferens. Approximately half of the PCD patients present with situs inversus, in which case PCD is referred to as Kartagener syndrome (KS). Situs inversus in PCD has been suggested to be the consequence of defective monocilia that are normally present on cells of the embryonic node. These cilia are thought to be instrumental in the embryonic movement of organs and the establishment of the left–right body axis (Nonaka *et al.*, 1998; Brueckner, 2001; Hackett, 2002). PCD might therefore cause a random situs with situs inversus in half of the patients. Occasionally, PCD patients also show hydrocephalus or mild enlargement of the cerebral ventricular system and sulci (Greenstone *et al.*, 1984; Jabourian *et al.*, 1986; De Santi *et al.*, 1990; Picco *et al.*, 1993). Also, the chronic headaches occurring in some PCD patients might be related to abnormalities in liquor circulation (Afzelius *et al.*, 2001). The association of PCD with cerebral ventriculomegaly or overt hydrocephalus has also been described in dogs (Edwards *et al.*, 1989; Dhein *et al.*, 1990; Daniel *et al.*, 1995), Wic-Hyd rats (Torikata *et al.*, 1991; Shimizu and Koto, 1992; Nakamura and Sato, 1993), Hpy/Hpy mice (Bryan, 1983), mice with targeted disruption of the *foxj1* gene (Chen *et al.*, 1998) and mice with an insertional mutation in the axonemal dynein heavy-chain gene, *Mdnah5* (Ibañez-Tallon *et al.*, 2002). This suggests a functional role in liquor circulation for the cilia lining the ventricular ependyma of the brain and spinal cord in humans and other species.

Prenatal diagnosis of PCD is sometimes possible by mutation analysis of one of the genes currently known to be involved in PCD (Pennarun *et al.*, 1999; Guichard *et al.*, 2001; Olbrich *et al.*, 2002). However, in the majority of cases, fetal ultrasound examination is the only method to detect PCD prenatally, if at least detectable structural anomalies such as situs inversus are present. However, half of the patients with PCD do not show situs inversus. As ventriculomegaly or hydrocephalus is sometimes present in neonates or children with PCD, it might offer an additional prenatal sonographic marker for PCD.

We present here two fetuses and one newborn with a suspected and/or confirmed diagnosis of PCD presenting with mild cerebral ventriculomegaly.

CASE REPORTS

Family 1

The healthy parents of family 1 were of Caucasian descent and unrelated (Figure 1). They were referred to our centre for prenatal diagnosis in their third pregnancy because of a previous child (II-2) with a primum atrial septal defect, aortic isthmus stenosis, absent right superior vena cava and a persistent left superior and

*Correspondence to: Marja W. Wessels, Department of Clinical Genetics, Erasmus University Medical Centre, Westzeedijk 112, 3016 AH Rotterdam, The Netherlands.
E-mail: wessels@kgen.azr.nl

Copyright © 2003 John Wiley & Sons, Ltd.

Received: 7 October 2002
Accepted: 25 November 2002

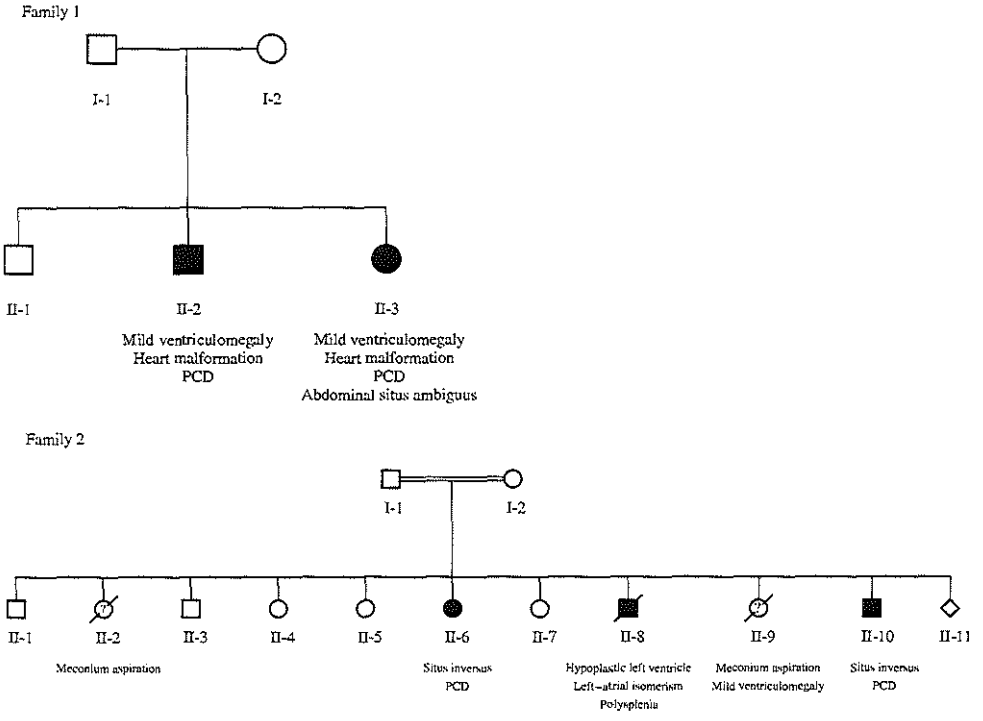

Figure 1—Family pedigrees of the two families with an association of PCD and fetal cerebral ventriculomegaly. Note the variability of the clinical picture

inferior vena cava connected to the coronary sinus. The congenital heart malformations did not necessitate surgical repair. Case II-2 had recurrent atelectases of the right lung and mildly dilated lateral cerebral ventricles in the neonatal period, both of which disappeared later on. However, he had frequent upper-airway infections during his childhood. Occipitofrontal circumference and mental development were normal at the age of five years. The diagnosis of PCD was not made until a suspicion of PCD in the next pregnancy. In that pregnancy (II-3), a fetal anomaly scan at 19 weeks revealed a right-sided stomach and a central liver, a primum atrial septal defect and a persistent left superior vena cava. There also existed mild cerebral ventriculomegaly, with the width of the posterior horn of the lateral ventricle measuring 13 mm (normal upper limit: 10 mm). Amniocentesis revealed a normal female karyotype, and a 22q11 deletion was excluded. PCD was suspected in sib II-2 in view of these ultrasound abnormalities and the presence of similar features with frequent upper-airway infections. After counselling, the parents decided to continue the pregnancy. At 37 weeks, a girl weighing 2750 g was born with Apgar scores of 6 (1′) and 8 (5′). The prenatally diagnosed cardiac abnormalities were confirmed, and in addition an absent inferior vena cava with azygous continuation was found. Abdominal abnormalities included a right-sided stomach, septated spleen with a small accessory spleen, central position of the liver with drainage of the left hepatic veins into a persistent left inferior vena cava and intestinal malrotation with volvulus. The child suffered from respiratory difficulties, and atelectases of the lung developed. An ultrasound of the brain made in the first week of life showed cerebral ventricles within the normal size range. In view of the combination of cardiac and abdominal features compatible with a situs abnormality, neonatal lung atelectases and fetal and/or neonatal cerebral ventriculomegaly in one or both sibs, the diagnosis of PCD was suspected. Electron-microscopic examination of a nasal biopsy showed ciliary aplasia in both infants (II-2 and II-3), confirming the diagnosis of PCD. The first child (II-1) and the parents were healthy, but were not further investigated.

Family 2

A consanguineous couple (first cousins) of Moroccan descent was referred in the 10th pregnancy to our centre for prenatal diagnosis because of a previous child (II-6) with KS (Figure 1). The second child (II-2) died on day 2 after birth because of meconium aspiration, but

Copyright © 2003 John Wiley & Sons, Ltd.

no prenatal or post-natal examination was performed. The sixth child (II-6), a girl, had situs inversus totalis and frequent upper-airway infections. This lead to the diagnosis of KS at the age of one month. This diagnosis of PCD was confirmed by nasal and bronchial biopsies showing impaired ciliary motility and abnormal cilia. Electron-microscopic evaluation revealed strongly abnormal cilia with deficiency of the inner dynein arms, radial spokes and nexin links. In the eighth pregnancy, a fetal anomaly scan at 16 weeks of gestation revealed hypoplasia of the left cardiac ventricle (II-8). Cerebral anatomy and thoracic and abdominal situs were normal. Amniocentesis revealed a normal male karyotype. The pregnancy was terminated, and the hypoplasia of the left ventricle was confirmed at autopsy. Additionally, left-atrial isomerism and polysplenia were found. At that time, the diagnosis of PCD was not made. In the ninth pregnancy, ultrasound examination of the fetus (II-9) revealed a normal situs but mild cerebral ventriculomegaly, with the width of the posterior horn of the lateral ventricle measuring 13 mm. Amniocentesis was performed and a normal female karyotype was found. Virological studies on maternal blood were normal. A girl with a birth weight of 3535 g was born at term. Apgar scores were 3 (1′) and 6 (5′), respectively. The child suffered from severe respiratory insufficiency due to meconium aspiration, and atelectases of the right middle lung lobe developed. She died after one day. No further diagnostic workup was performed.

A fetal anomaly scan in the 19th week of the 10th pregnancy (II-10) revealed situs inversus totalis. In view of these abnormalities and the presence of KS in II-6, the tentative prenatal diagnosis of PCD was made in II-10. The fetal cerebral ventricular width was normal. The parents decided to continue the pregnancy. II-10 was born at 41 weeks of gestation with a birthweight of 3640 g, and was hospitalised because of meconium aspiration and respiratory distress. The diagnosis of KS was confirmed by a nasal biopsy showing absent ciliary motility. The child was discharged from the hospital after 6 weeks. He had recurrent lung atelectases in the neonatal period, and upper-airway infections later on.

In retrospect, it is very likely that apart from II-6 and II-10, the fetus with hypoplastic left ventricle and left-atrial isomerism (II-8), and possibly the child with mild ventriculomegaly and post-natal respiratory distress (II-9), had PCD. The parents and the other children were reported to be healthy, but no further studies were performed.

DISCUSSION

We describe here two families with probable autosomal recessive PCD associated with mild ventriculomegaly. In the first family, both sibs affected with PCD had mild dilatation of the lateral cerebral ventricles. In the second family, PCD was suspected in two sibs, of which one showed mild fetal ventriculomegaly, and was confirmed in two additional sibs. In all three cases, cerebral ventriculomegaly was mild, and was only retrospectively recognised to be a part of PCD. The ventricular dilatation in PCD is probably due to a dysfunction of the cilia that line the ventricular ependyma of the brain and spinal cord. It has not only been described in humans but also in dogs, rats and mice with PCD. Consequently, the beating of these cilia must be important in the circulation of liquor. Mild fetal ventriculomegaly can be caused by many factors leading to parenchymal loss of abnormal cerebrospinal-fluid circulation. When diagnosed, additional prenatal tests (amniocentesis for karyotyping and virological studies, maternal platelet counts and virology) should be performed. As illustrated here, attention should also be paid to organ situs and structural heart defects in order to exclude PCD, certainly when a history of PCD in a previous child is present. Therefore, mild cerebral ventriculomegaly might be an early sign of PCD. This is important as PCD might be responsible for neonatal difficulties due to respiratory distress and/or meconium aspiration (Monnet, 1978; Whitelaw *et al.*, 1981; Losa *et al.*, 1995), or intestinal malrotation and/or congenital heart defects in case of situs ambiguus. To our knowledge, PCD has never been reported in post-natal follow-up studies of fetuses with mild cerebral ventriculomegaly (Bromley *et al.*, 1991; Bloom *et al.*, 1997; Vergani *et al.*, 1998; Pilu *et al.*, 1999; Mercier *et al.*, 2001; Kelly *et al.*, 2001), probably because PCD is not always recognised in the neonatal period (Losa *et al.*, 1995), particularly not in the absence of situs inversus. This highlights the importance of a thorough diagnostic evaluation of fetal and neonatal abnormalities. Furthermore, a careful family history can lead to an etiologic diagnosis that was not considered in individual affected family members, certainly in diseases with a clinical spectrum as variable as that of PCD.

ACKNOWLEDGEMENTS

We are grateful to Prof. Dr M.F. Niermeijer and Prof. Dr J. W. Wladimiroff for their valuable comments on the manuscript.

REFERENCES

Afzelius BA. 1976. A human syndrome caused by immotile cilia. *Science* **193**: 317–319.

Afzelius BA, Mossberg B, Bergstrom SE. 2001. Immotile cilia syndrome (primary ciliary dyskinesia), including Kartagener syndrome. In *The Metabolic and Genetic Bases of Inherited Disease* (8th edn), Scriver C, Beaudet A, Sly W, Valle D, *et al.* (eds). McGraw-Hill: New York; 4817–4827.

Bloom SL, Bloom DD, DellaNebbia C, Martin LB, Lucas MJ, Twickler DM. 1997. The developmental outcome of children with antenatal mild isolated ventriculomegaly. *Obstet Gynecol* **90**: 3–97.

Bromley B, Frigoletto Jr FD, Benacerraf BR. 1991. Mild fetal lateral cerebral ventriculomegaly: clinical course and outcome. *Am J Obstet Gynecol* **164**: 863–867.

Brueckner M. 2001. Cilia propel the embryo in the right direction. *Am J Med Genet* **15**: 339–344.

Bryan JH. 1983. The immotile cilia syndrome. Mice versus man. *Virchows Arch A Pathol Anat Histopathol* **399**: 65–75.

Chen J, Knowles HJ, Hebert JL, Hackett BP. 1998. Mutation of the mouse hepatocyte nuclear factor/forkhead homologue 4 gene results

Copyright © 2003 John Wiley & Sons, Ltd.

in an absence of cilia and random left-right asymmetry. *J Clin Invest* **102**: 1077–1082.

Daniel GB, Edwards DF, Harvey RC, Kabalka GW. 1995. Communicating hydrocephalus in dogs with congenital ciliary dysfunction. *Dev Neurosci* **17**: 230–235.

De Santi MM, Magni A, Valletta EA, Gardi C, Lungarella G. 1990. Hydrocephalus, bronchiectasis, and ciliary aplasia. *Arch Dis Child* **65**: 543–544.

Dhein CR, Prieur DJ, Riggs MW, Potter KA, Widders PR. 1990. Suspected ciliary dysfunction in Chinese Shar Pei pups with pneumonia. *Am J Vet Res* **51**: 439–446.

Edwards DF, Kennedy JR, Patton CS, Toal RL, Daniel GB, Lothrop CD. 1989. Familial immotile-cilia syndrome in English springer spaniel dogs. *Am J Med Genet* **33**: 290–298.

Greenstone MA, Jones RW, Dewar A, Neville BG, Cole PJ. 1984. Hydrocephalus and primary ciliary dyskinesia. *Arch Dis Child* **59**: 481–482.

Guichard C, Harricane MC, Lafitte JJ, *et al*. 2001. Axonemal dynein intermediate-chain gene (DNAI1) mutations result in situs inversus and primary ciliary dyskinesia (Kartagener syndrome). *Am J Hum Gene* **68**: 1030–1035.

Hackett BP. 2002. Formation and malformation of the vertebrate left-right axis. *Curr Mol Med* **2**: 39–66.

Ibañez-Tallon I, Gorokhova S, Heintz N. 2002. Loss of function of axonemal dynein Mdnah5 causes primary ciliary dyskinesia and hydrocephalus. *Hum Mol Genet* **11**: 715–721.

Jabourian Z, Lublin FD, Adler A, Gonzales C, Northrup B, Zwillenberg D. 1986. Hydrocephalus in Kartagener's syndrome. *Ear Nose Throat J* **65**: 468–472.

Kelly EN, Allen VM, Seaward G, Windrim R, Ryan G. 2001. Mild ventriculomegaly in the fetus, natural history, associated findings and outcome of isolated mild ventriculomegaly: a literature review. *Prenat Diagn* **21**: 697–700.

Losa M, Ghelfi D, Hof E, Felix H, Fanconi S. 1995. Kartagener syndrome: an uncommon cause of neonatal respiratory distress? *Eur J Pediatr* **154**: 236–238.

Mercier A, Eurin D, Mercier PY, Verspyck E, Marpeau L, Marret S. 2001. Isolated mild fetal cerebral ventriculomegaly: a retrospective analysis of 26 cases. *Prenat Diagn* **21**: 589–595.

Monnet P. 1978. Situs inversus and long-term bronchopneumopathies, existing since the neonatal period. *Arch Fr Pediatr* **35**: 607–619.

Nakamura Y, Sato K. 1993. Role of disturbance of ependymal ciliary movement in development of hydrocephalus in rats. *Childs Nerv Syst* **9**: 65–71.

Nonaka S, Tanaka Y, Okada Y, *et al*. 1998. Randomization of left-right asymmetry due to loss of nodal cilia generating leftward flow of extraembryonic fluid in mice lacking KIF3B motor protein. *Cell* **95**: 829–837.

Olbrich H, Haffner K, Kispert A, *et al*. 2002. Mutations in DNAH5 cause primary ciliary dyskinesia and randomization of left-right asymmetry. *Nat Genet* **30**: 143–144.

Pennarun G, Escudier E, Chapelin C, *et al*. 1999. Loss-of-function mutations in a human gene related to chlamydomonas reinhardtii dynein IC78 result in primary ciliary dyskinesia. *Am J Hum Genet* **65**: 1508–1519.

Picco P, Leveratto L, Cama A, *et al*. 1993. Immotile cilia syndrome associated with hydrocephalus and precocious puberty: a case report. *Eur J Pediatr Surg* **3**(Suppl. 1): 20–21.

Pilu G, Falco P, Gabrielli S, Perolo A, Sandri F, Bovicelli L. 1999. The clinical significance of fetal isolated cerebral borderline ventriculomegaly: report of 31 cases and review of the literature. *Ultrasound Obstet Gynecol* **14**: 320–326.

Shimizu A, Koto M. 1992. Ultrastructure and movement of the ependymal and tracheal cilia in congenitally hydrocephalic WIC-Hyd rats. *Childs Nerv Syst* **8**: 25–32.

Torikata C, Kijimoto C, Koto M. 1991. Ultrastructure of respiratory cilia of WIC-Hyd male rats. An animal model for human immotile cilia syndrome. *Am J Pathol* **138**: 341.

Vergani P, Locatelli A, Strobelt N, *et al*. 1998. Clinical outcome of mild fetal ventriculomegaly. *Am J Obstet Gynecol* **178**: 218–222.

Whitelaw A, Evans A, Corrin B. 1981. Immotile cilia syndrome: a new cause of neonatal respiratory distress. *Arch Dis Child* **56**: 432–435.

Copyright © 2003 John Wiley & Sons, Ltd.

2.3

© 2008 Wiley-Liss, Inc.

American Journal of Medical Genetics Part A 146A:1765–1767 (2008)

Research Letter

Candidate Gene Analysis in Three Families With Acilia Syndrome

Marja W. Wessels,[1] Avraham Avital,[2] Mike Failly,[3] Analia Munoz,[3] Heymut Omran,[4] Jean-Louis Blouin,[5] and Patrick J. Willems[6]*

[1]Department of Clinical Genetics, Erasmus University and University Hospital, Rotterdam, The Netherlands
[2]Institute of Pulmonology, Hadassah University Hospital, Jerusalem, Israel
[3]Department of Genetic Medicine and Development, University of Geneva Medical School, Geneva, Switzerland
[4]Department of Pediatrics and Adolescent Medicine, Freiburg, Germany
[5]Genetic Medicine, University Hospital of Geneva, Geneva, Switzerland
[6]GENDIA (GENetic DIAgnostic Network), Antwerp, Belgium

Received 16 December 2007; Accepted 9 March 2008

How to cite this article: Wessels MW, Avital A, Failly M, Munoz A, Omran H, Blouin J-L, Willems PJ. 2008. Candidate gene analysis in three families with acilia syndrome. Am J Med Genet Part A 146A:1765–1767.

To the Editor:

Primary ciliary dyskinesia (PCD or CILD) also called immotile cilia syndrome (ICS), is characterised by defective functioning of cilia leading to chronic sinupulmonary infections [Afzelius, 1976; Afzelius et al., 2001]. Approximately half of the patients with PCD have situs inversus, in which case PCD is called Kartagener syndrome [Kartagener, 1933]. PCD appears to be a condition with extensive genetic heterogeneity and 6 genes *DNAI1*, *DNAH5*, *DNAH11*, *RPGR*, *OFD1*, and *TXNDC3*, which altogether are responsible for about a third of PCD families, have been found so far to be implicated in PCD. Of the 11 specific PCD groups defined by Afzelius et al. [2001] one is acilia syndrome (AS). AS is an infrequent form of PCD characterised by total absence of cilia [Dudley et al., 1982; Fonzi et al., 1982; Götz and Stockinger, 1983; Gordon and Kattan, 1984; Welch et al., 1984; Babin and Kavanagh, 1985; Cerezo and Price, 1985; de Santi et al., 1988; Phillips, 1989; Richard et al., 1989; Soferman et al., 1996; Maiti et al., 2000]. AS probably is a separate entity in PCD and the disease gene has not yet been identified [Maiti et al., 2000].

In this study we analyzed several candidate genes in three unrelated AS families. The first family is an inbred Israeli family (Fig. 1) with two related sibships each having two AS patients (three girls, one boy), that have been reported [Soferman et al., 1996]. The parents of all four patients were consanguineous and descendants from a single ancestor. All four patients (III-5, III-6, IV-3, and IV-4) had been diagnosed with AS because of recurrent upper and lower respiratory tract infections, sinusitis and severe lung disease with widespread bronchiectasis (FEV1 around 30%) with absence of cilia on respiratory epithelial cells. No heterotaxy or cardiovascular malformation was reported but no real cardiovascular evaluation was performed [Soferman et al., 1996].

The second family is a nonconsanguineous Israeli family (Fig. 1) with two of the three children, a girl (II-1) and a boy (II-3) having AS. They suffered from recurrent otitis, sinusitis and pneumonia without bronchiectasis. They both need bronchodilator therapy and have reserved lung function (FEV1 around 70–80%) and bronchial hyperresponsiveness. The girl had a partial lobectomy (right side), whereas the boy had atelectases of the right lung. No obvious heterotaxy or cardiovascular malformation was present.

The third family is a Dutch family with two AS sibs, a boy (II-2) and a girl (II-3), that have been reported [Wessels et al., 2003]. The parents are healthy and unrelated (Fig. 1). The first child is healthy. The second child was born with transient mildly dilated lateral cerebral ventricles. He has absent right superior vena cava with persistent left superior and inferior vena cava connected to the coronary sinus, a primum atrial septal defect, and aortic isthmus stenosis. He also showed recurrent lung atelectases and respiratory infections. The diagnosis of PCD was only made when PCD was suspected in the next

*Correspondence to: Patrick J. Willems, MD, PhD, GENDIA, Amerikalei 62, 2000 Antwerp, Belgium. E-mail: willemspatrick@skynet.be

DOI 10.1002/ajmg.a.32340

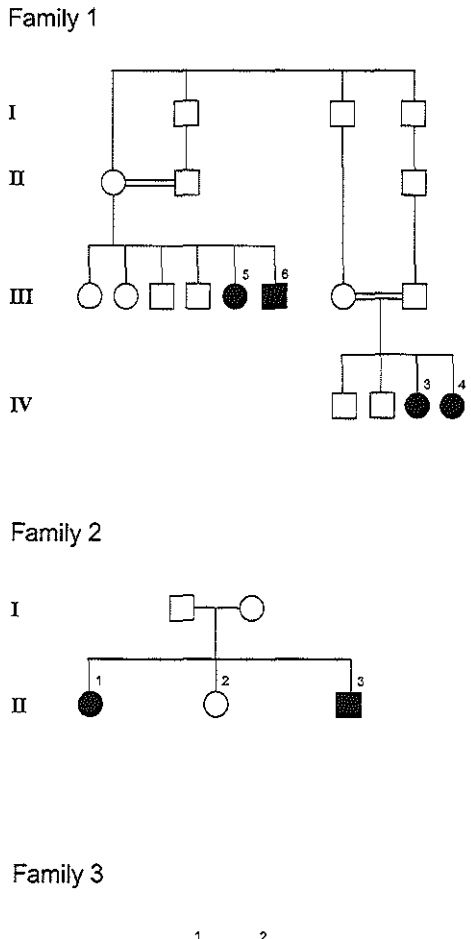

FIG. 1. Pedigrees of the three families with acilia syndrome.

pregnancy when heterotaxy was found at fetal ultrasound with a right-sided stomach and a central liver, a primum atrial septal defect, persistent left superior vena cava. There also existed mild cerebral ventriculomegaly, with the width of the posterior horn of the lateral ventricle measuring 13 mm (normal upper limit: 10 mm). After birth heterotaxy was confirmed; the cardiovascular anomalies consisted of a primum atrial septal defect, persistent left superior vena cava, and absent inferior vena cava with azygous continuation. The abdominal situs anomalies included a right-sided stomach, intestinal malrotation with volvulus, central position of the liver with drainage of the left hepatic veins in a persistent left inferior vena cava, septated spleen with small accessory spleen. The child developed recurrent respiratory difficulties and atelectasis of the lung. PCD in both sibs was confirmed by electromicroscopic examination of a nasal biopsy showing ciliary aplasia in both.

In these three AS families several candidate genes were analyzed in this study. In Family 1 linkage to the *DNAH5* locus could not be excluded by haplotype analysis. Therefore, all 80 coding exons including adjacent intron/exon boundaries of *DNAH5* were amplified and directly sequenced in an affected patient [Hornef et al., 2006]. However, no *DNAH5* mutation was detected. In each of the three families all exons of the *DNAI1* gene were screened for sequence variants by DHPLC in one affected individual, but no variants were found. In addition, DNA of a single affected individual in each of the families was also analyzed specifically for the occurrence of the IVS+2_3insT mutation (also referred to as 219+3insT or c.48+2_48+3insT) by restriction analysis using *Hpa*I onI PCR products of exon 1 and adjacent intronic sequences. None of the three families showed the IVS+2_3insT mutation, which accounts for ~60% of all *DNAI1* mutations [Zariwala et al., 2006]. To exclude homozygous *DNAI1* mutations that DHPLC could not resolve, we performed genotype analysis using 9 Hapmap tag SNPs widely spaced on the entire length of *DNAI1*, which is covered by a single linkage disequilibrium block (LD block) according to Hapmap (www.hapmap.org). Heterozygous tag SNPs genotypes indicated that the investigated patients of the three families were not homozygous for the LD block. Direct sequence analysis of the two coding exons with adjacent intronic regions of the *FOXJ1* (*HFH4*) gene was performed in one affected patient from all three PCD families, but no mutations that could be disease-causing were identified.

In conclusion, we could not find evidence for the involvement of *DNAI1*, *DNAH5*, or *FOXJ1* in any of our three AS families. In general, about 10% of PCD patients have mutations in *DNAI1* [Zariwala et al., 2006], and nearly a quarter (half of PCD families with outer dynein arms defects) have *DNAH5* mutations [Hornef et al., 2006]. All *DNAI1* and *DNAH5* mutations lead to the absence of outer dynein arms, the most frequent abnormality observed in PCD [Zariwala et al., 2007], but not acilia. The *FOXJ1* gene encoding the hepatocyte nuclear factor 3 or forkhead homologue 13 (formerly known as HFH-4 or FKHL 13 gene) on chromosome 17 was a good candidate gene for AS for several reasons. First, inactivation of the *Foxj1* gene in mice results in AS, infertility due to absence of flagella in

sperm and heterotaxy, the three important characteristics of human PCD [Chen et al., 1998; Brody et al., 2000]. Second, inactivation of the *Foxj1* gene leads to reduced expression of left-right dynein. Third, *Foxj1* is expressed in respiratory epithelia and seminiferous tubules of the testes [Blatt et al., 1999]. We did not analyze the *DNAH11*, *RPGR*, TXNDC3, or *OFD1* genes as these were unlikely to be involved in the pathogenesis of our families: DNAH11 mutations are rare [Schwabe et al., 2008], mutations in the X-linked *RPGR* gene are associated retinitis pigmentosa., and mutations in the *TXNDC3* or *OFD1* gene have only been implicated in a single PCD family [Budny et al., 2006; Duriez et al., 2007].

Of the 11 PCD groups defined by Afzelius et al. [2001] one specific group is acilia syndrome (AS). AS probably is a distinct entity within PCD as it breeds true in multiple families. The observation of AS in sibs of both sexes, consanguinity of some of the parents, and the presence of multiplex AS pedigrees in inbred families [Götz and Stockinger, 1983; Soferman et al., 1996] are compatible with an autosomal mode of inheritance. However, up to now no mutations have been identified in AS, and also not in this study. It is therefore likely that acilia syndrome consists of a separate entity within the heterogeneous group of PCDs.

REFERENCES

Afzelius BA. 1976. A human syndrome caused by immotile cilia. Science 193:317–319.

Afzelius BA, Mossberg B, Bergstrom SE. 2001. Immotile cilia syndrome (primary ciliary dyskinesia), including Kartagener syndrome. In: Scriver CR, Beaudet AL, Sly WS, Valle D, Childs B, Kinzler KW, Vogelstein B, editors. The metabolic and genetic bases of inherited disease. 8th edition. New York: McGraw-Hill. pp 4817–4827.

Babin RW, Kavanagh KT. 1985. Familial nasal acilia syndrome. South Med J 78:737–739.

Blatt EN, Yan XH, Wuerffel MK, Hamilos DL, Brody SL. 1999. Forkhead transcription factor HFH-4 expression is temporally related to ciliogenesis. Am J Respir Cell Mol Biol 21:168–176.

Brody SL, Yan XH, Wuerffel MK, Song SK, Shapiro SD. 2000. Ciliogenesis and left-right axis defects in forkhead factor HFH-4-null mice. Am J Respir Cell Mol Biol 23:45–51.

Budny B, Chen W, Omran H, Fliegauf M, Tzschach A, Wisniewska M, Jensen LR, Raynaud M, Shoichet SA, Badura M, Lenzner S, Latos-Bielenska A, Ropers HH. 2006. A novel X-linked recessive mental retardation syndrome comprising macrocephaly and ciliary dysfunction is allelic to oral-facial-digital type I syndrome. Hum Genet 120:171–178.

Cerezo L, Price G. 1985. Absence of cilia and basal bodies with predominance of brush cells in the respiratory mucosa from a patient with immotile cilia syndrome. Ultrastruct Pathol 8: 381–382.

Chen J, Knowles HJ, Hebert JL, Hackett BP. 1998. Mutation of the mouse hepatocyte nuclear factor/forkhead homologue 4 gene results in an absence of cilia and random left-right asymmetry. J Clin Invest 102:1077–1082.

de Santi MM, Gardi C, Barlocco G, Canciani M, Mastella G, Lungarella G. 1988. Cilia-lacking respiratory cells in ciliary aplasia. Biol Cell 64:67–70.

Dudley JP, Welch MJ, Stiehm ER, Carney JM, Soderberg-Warner M. 1982. Scanning and transmission electron microscopic aspects of the nasal acilia syndrome. Laryngoscope 92:297–299.

Duriez B, Duquesnoy P, Escudier E, Bridoux AM, Escalier D, Rayet I, Marcos E, Vojtek AM, Bercher JF, Amselem S. 2007. A common variant in combination with a nonsense mutation in a member of the thioredoxin family causes primary ciliary dyskinesia. Proc Natl Acad Sci USA 104:3336–3341.

Fonzi L, Lungarella G, Palatresi R. 1982. Lack of kinocilia in the nasal mucosa in the immotile-cilia syndrome. Eur J Respir Dis 63:558–563.

Gordon RE, Kattan M. 1984. Absence of cilia and basal bodies with predominance of brush cells in the respiratory mucosa from a patient with immotile cilia syndrome. Ultrastruct Pathol 6:45–49.

Götz M, Stockinger L. 1983. Aplasia of respiratory tract cilia. Lancet 1:1283.

Hornef N, Olbrich H, Horvath J, Zariwala MA, Fliegauf M, Loges NT, Wildhaber J, Noone PG, Kennedy M, Antonarakis SE, Blouin JL, Bartoloni L, Nüsslein T, Ahrens P, Griese M, Kuhl H, Sudbrak R, Knowles MR, Reinhardt R, Omran H. 2006. DNAH5 mutations are a common cause of primary ciliary dyskinesia with outer dynein arm defects. Am J Respir Crit Care Med 174:120–1126.

Kartagener M. 1933. Zur Pathogenese der Bronkiektasien. Bronkiektasien bei Situs viscerum inversus. Beitr Klin Tuberk 83:489.

Maiti AK, Bartoloni L, Mitchison HM, Meeks M, Chung E, Spiden S, Gehrig C, Rossier C, DeLozier-Blanchet CD, Blouin J, Gardiner RM, Antonarakis SE. 2000. No deleterious mutations in the FOXJ1 (alias HFH-4) gene in patients with primary ciliary dyskinesia (PCD). Cytogenet Cell Genet 90:119–122.

Phillips JI. 1989. Lack of cilia and squamous metaplasia in upper respiratory tract biopsies from children. S Afr Med J 76:355–357.

Richard S, Nezelof C, Pfister A, de Blic J, Scheinmann P, Paupe J. 1989. Congenital ciliary aplasia in two siblings. A primitive disregulation of ciliogenesis? Pathol Res Pract 185:181–183.

Schwabe GC, Hoffmann K, Loges NT, Birker D, Rossier C, de Santi MM, Olbrich H, Fliegauf M, Failly M, Liebers U, Collura M, Gaedicke G, Mundlos S, Wahn U, Blouin JL, Niggemann B, Omran H, Antonarakis SE, Bartoloni L. 2008. Primary ciliary dyskinesia associated with normal axoneme ultrastructure is caused by DNAH11 mutations. Hum Mutat 29:289–298.

Soferman R, Ne'man Z, Livne M, Avital A, Spirer Z. 1996. Familial nasal acilia syndrome. Arch Dis Child 75:76–77.

Welch MJ, Stiehm ER, Dudley JP. 1984. Isolated absence of nasal cilia: A case report. Ann Allergy 52:32–34.

Wessels MW, den Hollander NS, Willems PJ. 2003. Mild fetal cerebral ventriculo-megaly as a prenatal sonographic marker for Kartagener syndrome. Prenat Diagn 23:239–242.

Zariwala MA, Leigh MW, Ceppa F, Kennedy MP, Noone PG, Carson JL, Hazucha MJ, Lori A, Horvath J, Olbrich H, Loges NT, Bridoux AM, Pennarun G, Duriez B, Escudier E, Mitchison HM, Chodhari R, Chung EM, Morgan LC, de Iongh RU, Rutland J, Pradal U, Omran H, Amselem S, Knowles MR. 2006. Mutations of DNAI1 in primary ciliary dyskinesia: Evidence of founder effect in a common mutation. Am J Respir Crit Care Med 174:858–866.

Zariwala MA, Knowles MR, Omran H. 2007. Genetic defects in ciliary structure and function. Annu Rev Physiol 69:423–445.

2.4

Polyalanine expansion in the *ZIC3* gene leading to X-linked heterotaxy with VACTERL association, a new polyalanine disorder?

Marja W. Wessels[1], Brian Kuchinka[2], Rogier Heydanus[3], Bert J. Smit[4], Dennis Dooijes[1], Ronald R. de Krijger[5], Maarten H. Lequin[6], Elisabeth M. de Jong[7], Margreet Husen[8], Patrick J. Willems[9] and Brett Casey[2]

[1]Department of Clinical Genetics, [5]Department of Pathology, and [8]Department of Obstetrics and Gynecology, Erasmus Medical Center, Rotterdam, The Netherlands

[4]Department of Pediatrics, Division of Neonatology, [6]Department of Pediatric Radiology, and [7]Department of Pediatric Surgery[7], Erasmus Medical Center, Sophia Children's Hospital, Rotterdam, The Netherlands

[3]Department of Obstetrics and Gynecology, Amphia Hospital, Breda, The Netherlands

[2]Department of Pathology & Laboratory Medicine, University of British Columbia, and BC Children's Hospital, Vancouver, Canada

[9]GENDIA (GENetic DIAgnostic network), Antwerp, Belgium

J Med Genet 2009; in press

Abstract

We describe a newborn male with features of the VACTERL association, including anal atresia, laryngeal and esophageal atresia with tracheo-esophageal fistula, dextroposition of the heart with persistent left superior vena cava, and unilateral multicystic kidney. As the clinical picture of the VACTERL association overlaps with X-linked heterotaxy caused by *ZIC3* mutations, we sequenced the *ZIC3* coding region, and found a 6-nucleotide insertion that is predicted to expand the amino-terminal polyalanine repeat from ten to twelve polyalanines. This novel mutation was not present in the mother, nor in 336 chromosomes from 192 ethnically-matched controls. We hypothesize that this novel and *de novo* polyalanine expansion in the *ZIC3* gene contributes to the VACTERL association in this patient.

Introduction

Mutations in *ZIC3*, a zinc finger transcription factor gene located at Xq26, typically result in a spectrum of left-right asymmetry defects, including complex cardiac anomalies, altered lung lobation, splenic and hepatobiliary abnormalities, and gut malposition. Also renal, anal and lumbosacral anomalies are common. The combination of *ZIC3*-associated anomalies is referred to as X-linked heterotaxy (HTX1, MIM 306955) [1-5]. However, also isolated congenital heart disease can be due to mutations in *ZIC3*.[4] Though usually unaffected, some female heterozygotes manifest abnormalities whose spectrum and severity is indistinguishable from affected males.

The VACTERL association, which comprises vertebral anomalies (V), anal atresia (A), cardiovascular malformations (C), tracheo-esophageal fistula and/or esophageal atresia (TE), renal malformations (R) and limb defects (L) is a non-random association of defects with an unknown etiology in the majority of patients.[6,7] In several recent reviews the syndromes resembling VACTERL association have been discussed: these include Feingold syndrome (*NMYC* gene), Fanconi syndrome (*FANC* genes), CHARGE syndrome (*CHD7* gene), Pallister-Hall syndrome (*GLI3* gene), Anophthalmia-Esophageal-Genital syndrome (*SOX2* gene), Opitz G/BBB syndrome (*MID1* gene), Townes-Brocks syndrome (*SALL1* gene) and Fryns syndrome (disease gene not identified yet) [8,9,10]. VACTERL association phenotypically also overlaps with *ZIC3*-associated X-linked heterotaxy: anal atresia and cardiac defects are common in both disorders, and typical VACTERL features such as tracheo-esophageal fistula, renal and vertebral anomalies have occasionally also been reported in *ZIC3*-associated heterotaxy (Table 1) [5].
In the case presented here, we describe a novel *ZIC3* mutation (elongation of the amino-terminal alanine repeat) in a patient with overlapping features between VACTERL association and X-linked heterotaxy.

Case report

A healthy Caucasian gravida 2 para 1 was referred for ultrasound examination at 31 weeks of gestation because of suspected polyhydramnios. Apart from polyhydramnios advanced ultrasonography revealed absent stomach filling, suggesting esophageal atresia, and a right multicystic kidney. Amniocentesis showed a normal male karyotype, and FISH analysis to exclude a 22q11.2 deletion was normal. In her previous pregnancy the mother delivered a healthy son of 4500 grams at 41 weeks of gestation. There were no congenital anomalies in the family of both nonconsanguineous parents.
She went into premature labor at 33 weeks, and a male infant with birth weight of 2060 grams (50th centile) was born by ventouse extraction because of failure to progress in the second stage of labor and fetal distress. The male newborn was hypotonic, bradycardic, and showed respiratory distress. Bag valve mask ventilation was not successful as no air entry into the fetal lungs could be established. Also oropharyngeal and nasopharyngeal intubation was not successful because of a blind-ending larynx, distal to the vocal cords. An attempt to put a tube in the proximal esophagus to ventilate the lungs through a possible fistula failed. A tracheotomy was established but nevertheless prolonged efforts to resuscitate were unsuccessful, and the patient died one hour after birth.
External examination showed a proportionate male neonate with anal atresia and a sacral dimple. Postmortem MRI revealed a heart positioned in the right thorax with the apex of the heart towards the left indicating dextroposition of the heart, a persistent left superior vena cava, and myocardial hypertrophy of both ventricles (Figure 1). Both lungs, particularly the left lung, were hypoplastic. A normal trachea with bifurcation was seen, but there existed no connection to the larynx. The distal esophagus was identified, but had no connection to the proximal portion. The right kidney was multicystic and positioned centrally in the lower abdominal region. The left kidney and the spleen showed a normal position and aspect. The rectosigmoid was dilated, as seen in anal atresia. No abnormalities of the vertebral bodies or conus medullaris were observed. MRI of the brain showed normal infra- and supratentorial structures. Autopsy confirmed the laryngeal and esophageal atresia. A low tracheo-esophageal fistu-

la was present. The persistent left superior vena cava was connected to the coronary sinus. No other structural abnormalities of the heart were observed. A centrally located right dysplastic kidney with multiple cysts, and a blind-ending rectum with a possible recto-urethral fistula were found. Autopsy of the brain showed no abnormalities. A fibroblast culture showed normal chromosomal breakage after diepoxybutane (DEB) exposure, making Fanconi anemia unlikely. Dysmorphologic examination of the parents was normal.

Molecular studies

Bi-directional sequencing of all coding exons of the *ZIC3* gene did not reveal mutations, apart from a 6-nucleotide insertion within the portion of exon 1 that codes for a polyalanine repeat. The insertion sequence, GCCGCC, maintains the wild-type reading frame and codes for two additional alanines. The repeat therefore contained 12 instead of the normal 10 polyalanines. The polyalanine sequence of the mother of the patient was normal, and the GCCGCC insertion was not present, which suggests that the repeat amplication is *de novo* in the affected patient. Randomly selected controls, 44 males and 146 females, from the ethnically-matched population (Dutch Caucasian) were screened for variation in length of this *ZIC3* polyalanine repeat. All 336 X chromosomes showed a wild-type length of 10 repeats of the ZIC3 polyalanine repeat.

Discussion

We describe a male neonate with a combination of features resembling the VACTERL association, including anal atresia, esophageal atresia with tracheo-esophageal fistula and a unilateral multicystic kidney. Dextroposition of the heart (heart positioned in the right thorax with the apex of the heart towards the left), with persistent left vena cava, abnormalities not typically seen in VACTERL, were also present. As this phenotype shared characteristics with *ZIC3*-associated heterotaxy, the *ZIC3* gene (HTX1, MIM 306955) was analyzed and a de novo *ZIC3* mutation was found.

VACTERL association represents a spectrum of anomalies including vertebral defects, anal atresia, esophageal atresia and/or tracheo-esophageal fistula, renal malformations and predominantly preaxial limb anomalies [11-13]. This broad association has considerable overlap with other syndromes including X-linked heterotaxy due to a *ZIC3* mutation. X-linked heterotaxy typically presents with heart defects characteristic of heterotaxy including common AV canal, double outlet right ventricle, transposition of the great arteries and abnormal pulmonary or systemic venous connection. Dextrocardia, indicating a mirror image position of the heart, is present is some patients [1,5]. In our patient dextroposition of the heart was found, which could be a result of displacement of the heart, as can be seen in patients with lung hypoplasia. Intestinal malrotation, symmetric liver, abnormal lung lobulation, asplenia or polysplenia are frequently seen in patients with X-linked heterotaxy. Also midline malformations are common, and include imperforate anus, rectal stenosis, sacral agenesis, meningomyelocele, cerebellar hypoplasia, and arhinencephaly [3,5]. X-linked heterotaxy shares anorectal, renal and vertebral malformations with VACTERL association (Table 1). However, laterality defects are rarely found in patients

with VACTERL association [11]. Nevertheless, all separate malformations within the VACTERL association have been reported in patients with laterality defects. In two large studies of patients with esophageal atresia and tracheo-esophageal fistula dextrocardia was reported in 3 % of patients [14,12]. Esophageal atresia can also be associated with other features of heterotaxy such as gut malrotation [12,15] and situs inversus [16,17]. Esophageal atresia and tracheo-esophageal fistula are common in VACTERL association, but not in X-linked heterotaxy. Two patients that were initially diagnosed with VACTERL association were later shown to have a *ZIC3* mutation [5,18]. The first patient, described by Purandare et al. [18] showed features of VACTERL, including lumbar and sacral agenesis, anal stenosis, fused kidneys and aqueductal stenosis with hydrocephalus without thoracic or abdominal situs anomalies. This patient did have a heart malformation consistent with heterotaxy including total abnormal pulmonary venous return and bilateral superior vena cava [18]. The other patient had VACTERL association with typical vertebral, anal and renal malformation in combination with tracheo-esophageal fistula, but also dextrocardia, congenital heart malformations and asplenia.[5] The anomalies present in these two VACTERL patients are very similar to those of the patient described here. The combination of the VACTERL association with heterotaxy is therefore suggestive of a *ZIC3* mutation, certainly if the disorder is X-linked (Table 1). The presence of tracheo-laryngeal and/or esophageal anomalies in these 3 patients suggests that *ZIC3* plays a role in the development of the foregut.

The majority of *ZIC3* mutations reported to date consist of point mutations (nonsense, missense) or small insertion-deletions resulting in a frameshift, although rarely whole-gene deletions and X-autosome translocations have been described (Table 1) [2,3,5,19]. In our patient an insertion of GCCGCC in exon 1 of the *ZIC3* gene was identified. This mutation maintains the wild-type reading frame and codes for two additional alanines in the polyalanine stretch of ZIC3. The polyalanine stretch of ZIC3 is an almost perfect repeat where all alanines are encoded by GCC with the exception of the ninth alanine, which is encoded by GCT. As in some dynamic diseases repeat amplification occurs after transition of an incomplete to a complete repeat, we sequenced the alanine repeat from the mother of the patient, but the ninth repeat was normal (GCT). The *ZIC3* repeat amplification is a novel mutation, not reported before neither in patients nor in controls. It is a de novo mutation as it was not present in the mother, whereas the patient is also the only affected family member. All randomly selected controls (336 X chromosomes) from an ethnically-matched Dutch-Caucasian population had 10 *ZIC3* repeats. All together, the *ZIC3* repeat amplification is most likely a disease-causing mutation.

Polyalanine stretches have been predicted in about 500 human proteins, mainly transcription factors. Polyalanine domains in vertebrates are conserved between mammals and the polymorphic nature of sequences coding for polyalanine domains makes them prime candidates for mutations in genetic disorders [20]. Up to now, 9 human diseases have been described that are due to polyalanine stretch elongation [21-23], and X-linked heterotaxy might be the tenth polyalanine repeat disease (Table 2). Nine of these disease genes, including *ZIC3*, encode transcription factors; the only exception is *PABPN1*, a nuclear protein involved in mRNA polyadenylation. Polyalanine stretch elongation of another *ZIC* gene family member *ZIC2* is associated with holoprosencephaly [23-26]. The *ZIC3* repeat expansion described here is the smallest expansion (+ 2 residues) reported, together with the 2-residue polyalanine expansions in *ARX* and *PABPN1* (Table 2). This polyalanine stretch of 12 residues is also the smallest polyalanine stretch

reported to be pathogenic, together with the 12-residue polyalanine expansion in *PABPN1*.

Polyalanine tracts expansions in several transcriptions factors, including *HOXD13, HOXA13, RUNX2, SOX3, PHOX2B* and *FOXL2* have been shown to induce cytoplasmatic mislocalisation and aggregation as well as nuclear aggregation [22,27-30]. Several pathogenetic mechanisms have been proposed: i) Cytoplasmatic aggregation might be dependent upon repeat length as larger oligomers might be unable to pass through the nuclear pores, leading to loss-of-function of the transcription factor as it may not reach the target genes, [30] ii) Intranuclear aggregates might have a toxic gain-of-function affect, as has been suggested for *PABPN1* and *ARX*, [31,32] iii) Aggregation might also induce a dominant-negative effect through the sequestration of the wild type protein or associated proteins in the aggregates. As ZIC and GLI proteins interact, whereby GLI proteins are translocated to the cell nuclei by coexpressed ZIC3 proteins, [33] it is possible that formation of ZIC3 aggregates might also influence the function of ZIC3-related proteins such as GLI3.

In conclusion, we suggest here that *ZIC3* might be the tenth gene implicated in polyalanine expansion diseases, and that *ZIC3* mutations may be present in patients with VACTERL association in combination with heterotaxy.

The Corresponding Author has the right to grant on behalf of all authors and does grant on behalf of all authors, an exclusive licence (or non-exclusive for government employees) on a worldwide basis to the BMJ Publishing Group Ltd and its Licensees to permit this article to be published in Journal of Medical Genetics editions and any other BMJPGL products to exploit all subsidiary rights, as set out in our licence http://jmg.bmjjournals.com/ifora/licence.pdf

Table 1 | *ZIC3* mutations in patients with features overlapping X-linked heterotaxy and VACTERL

ZIC3 mutation	M/F	Heterotaxy	Cardiovascular	Vertebral
p.Arg183Gln	M	Asplenia Altered abdominal situs	TGA AVSD Pulmonary atresia	
p.Arg183Gln	M	Dextrocardia Altered abdominal situs	TGA Pulmonary valve stenosis Mitral valve atresia	Sacral agenesis
c.1507insTT	F	Situs inversus		
c.1507insTT	M	Situs ambiguus	Not specified	
c.1507insTT	M	Situs ambiguus	Not specified	
c.1507insTT	F(2)	Situs inversus		
p.Gln294X	M(2)	Situs ambiguus	Not specified	
p.Cys270X	M	Situs ambiguus	Not specified	Sacral agenesis
p.Cys270X	M	Situs ambiguus	Not specified	
p.Cys253Ser	NR	NR	NR	Lumbosacral spine abnormalities
p.Gln249X	M	Altered abdominal situs Asplenia	AVSD DORV, TGA Pulmonary stenosis TAPVR	
p.Gln249X	M	Dextrocardia Asplenia	AVSD Pulmonary atresia HLHS Bilat. superior vena cava	Vertebral defect
p.Ser43X	M	Normal situs	DORV, TGA ASD, VSD Pulmonary stenosis Interrupted inferior vena cava	Fused lumbar vertebrae
Deletion Xq26	M	Intestinal malrotation Midline stomach, liver Asplenia	AVSD Left superior vena cava	
Deletion Xq26	M	Bilateral trilobated lungs Asplenia Right stomach	AVSD, DORV, TGA LVOT obstruction Bilat. superior vena cava Interrupted inferior vena cava	
Deletion Xq26	M	Normal situs	TAPVR, LVOT obstruction Bilat superior vena cava	Lumbar and sacral agenesis
Polyalanine expansion	M	Dextroposition of the heart	Bilat superior vena cava	

M/F Male/Female, ASD Atrial septal defect, AVSD Atrioventricular septal defect, DORV Double outlet right ventricle, EA esophageal atresia, HLHS Hypoplastic left heart syndrome, LVOT Left ventricular outflow tract, NR, Not reported, TF Tracheo-esophageal fistula, TAPVR Total anomalous pulmonary venous retour, TGA Transposition of the great arteries, VSD Ventricular septal defect

	Laryngeal Esophageal	Anal	Renal	Other	Ref
		Posterior-placed anus		Arhinencephaly	1,3
		Rectal stenosis		Biliary atresia Bilateral clubfeet	1,3
			Double ureter		3
		Anal malformation	Horseshoe kidney	Adrenal aplasia	3
			Renal hypoplasia Ureteral stenosis		3
		Anal malformation			3
		Anal malformation			3
					3
		Anal malformation			3
			Horseshoe kidney	Omphalocele Cystic hygroma	5
			Horseshoe kidney		5
	TF	Anal atresia	Renal dysplasia	Radial dysplasia	5
		Anal atresia		Bilat. club feet Post. embryotoxon Extrahepatic biliary atresia	5
		Anal atresia			2
		Anal stenosis			18
		Anal stenosis	Fused kidneys	Aqueductal stenosis with hydrocephalus	18
	EA/TF laryngeal atresia	Anal atresia	Multicystic dysplasia		This report

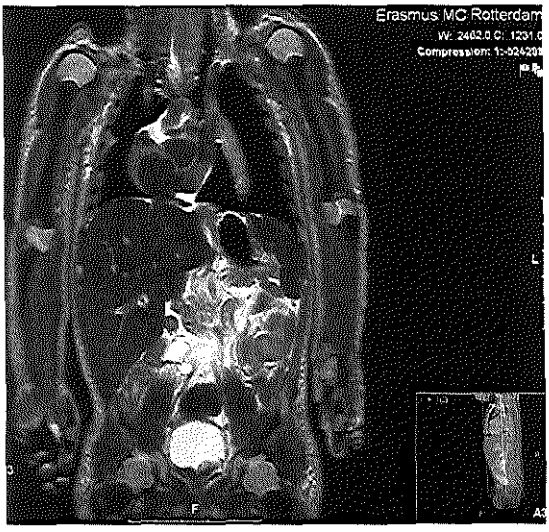

Figure 1 | Postmortem coronal body MRI showing dextroposition of the heart, persistent left superior vena cava and normal position of liver stomach and spleen. The stomach is filled with air and pneumothorax is present after reanimation.

Table 2 | Polyalanine expansions in human disease

Gene	Disease	Expansion
ZIC3	Heterotaxy (HTX1) with VACTERL-like features	10→12
ZIC2	Holoprosencephaly (HPE5)	15→25
FOXL2	Blepharophimosis-ptosis-epicanthus inversus (BPES)	14→22, 24
PHOX2B	Congenital central hypoventilation, Haddad syndrome	20→25–33
ARX	West syndrome, Partington syndrome	16→18, 23
		12→20
SOX3	Mental retardation with growth hormone deficiency	15→26
RUNX2	Cleidocranial dysplasia	17→27
HOXA13	Hand–foot–genital syndrome	14→24, 26
		12→18
		18→24–30
HOXD13	Synpolydactyly	15→22–25, 29
PABPN1	Oculopharyngeal muscular dystrophy	10→12-17 (AD) 10→11 (AR)

References

1. Casey B, Devoto M, Jones KL, Ballabio A. 1993. Mapping a gene for familial situs abnormalities to human chromosome Xq24-q27.1. Nat Genet 5:403-407.
2. Ferrero GB, Gebbia M, Pilia G, Witte D, Peïer A, Hopkin RJ, Craigen WJ, Shaffer LG, Schlessinger D, Ballabio A, Casey B. 1997. A submicroscopic deletion in Xq26 associated with familial situs ambiguus. Am J Hum Genet 61:395-401.
3. Gebbia M, Ferrero GB, Pilia G, Bassi MT, Aylsworth A, Penman-Splitt M, Bird LM, Bamforth JS, Burn J, Schlessinger D, Nelson DL, Casey B. 1997. X-linked situs abnormalities result from mutations in ZIC3. Nat Genet 17:305-308.
4. Megarbane A, Salem N, Stephan E, Ashoush R, Lenoir D, Delague V, Kassab R, Loiselet J, Bouvagnet P. 2000. X-linked transposition of the great arteries and incomplete penetrance among males with a nonsense mutation in ZIC3. Eur J Hum Genet 8:704-708.
5. Ware SM, Peng J, Zhu L, Fernbach S, Colicos S, Casey B, Towbin J, Belmont JW. 2004. Identification and functional analysis of ZIC3 mutations in heterotaxy and related congenital heart defects. Am J Hum Genet 74:93-105.
6. Kallen K, Mastroiacovo P, Castilla EE, Robert E, Kallen B. 2001. VATER non-random association of congenital malformations: study based on data from four malformation registers. Am J Med Genet 101:26-32.
7. Weaver DD, Mapstone CL, Yu PL. 1986. The VATER association. Analysis of 46 patients. Am J Dis Child 140:225-229.
8. Shaw-Smith C. 2006. Oesophageal atresia, tracheo-oesophageal fistula, and the VACTERL association: review of genetics and epidemiology. J Med Genet 43:545-554.
9. Brunner HG, van Bokhoven H. 2005. Genetic players in esophageal atresia and tracheoesophageal fistula. Curr Opin Genet Dev 15:341-347.
10. Genevieve D, de Pontual L, Amiel J, Sarnacki S, Lyonnet S. 2007. An overview of isolated and syndromic oesophageal atresia. Clin Genet 71:392-399.
11. Botto LD, Khoury MJ, Mastroiacovo P, Castilla EE, Moore CA, Skjaerven R, Mutchinick OM, Borman B, Cocchi G, Czeizel AE, Goujard J, Irgens LM, Lancaster PA, Martinez-Frias ML, Merlob P, Ruusinen A, Stoll C, Sumiyoshi Y. 1997. The spectrum of congenital anomalies of the VATER association: an international study. Am J Med Genet 71:8-15.
12. de Jong EM, Felix JF, Deurloo JA, van Dooren MF, Aronson DC, Torfs CP, Heij HA, Tibboel D. 2008. Non-VACTERL-type anomalies are frequent in patients with esophageal atresia/tracheo-esophageal fistula and full or partial VACTERL association. Birth Defects Res A Clin Mol Teratol 82:92-97.
13. Keckler SJ, St Peter SD, Valusek PA, Tsao K, Snyder CL, Holcomb GW, 3rd, Ostlie DJ. 2007. VACTERL anomalies in patients with esophageal atresia: an updated delineation of the spectrum and review of the literature. Pediatr Surg Int 23:309-313.
14. Torfs CP, Curry CJ, Bateson TF. 1995. Population-based study of tracheoesophageal fistula and esophageal atresia. Teratology 52:220-232.
15. Cieri MV, Arnold GL, Torfs CP. 1999. Malrotation in conjunction with esophageal atresia/tracheo-esophageal fistula. Teratology 60:114-116.
16. Luo CC, Lin JN, Lien R, Chu SM. 2003. A new variant of esophageal atresia with distal tracheo-antral fistula associated with congenital intrathoracic stomach and situs inversus. J Pediatr Surg 38:E25-27.
17. Shenoy VG, Jawale SA, Oak SN, Kulkarni BK. 2001. Esophageal atresia with distal tracheoesophageal fistula associated with situs inversus. Pediatr Surg Int 17:538-539.
18. Purandare SM, Chitayat D, Ferrero GB, Kashork CD, Marino B, Schaffer LG, Casey B: VACTERL-H features associated with a deletion of *ZIC3* in Xq26.2 *Am J Hum Genet* 1999: 65(suppl.): A70, Abstract 370.
19. Tzschach A, Hoeltzenbein M, Hoffmann K, Menzel C, Beyer A, Ocker V, Wurster G, Raynaud M, Ropers HH, Kalscheuer V, Heilbronner H. 2006. Heterotaxy and cardiac defect in a girl with chromosome translocation t(X;1)(q26;p13.1) and involvement of ZIC3. Eur J Hum Genet 14:1317-1320.
20. Lavoie H, Debeane F, Trinh QD, Turcotte JF, Corbeil-Girard LP, Dicaire MJ, Saint-Denis A, Page M, Rouleau GA, Brais B. 2003. Polymorphism, shared functions and convergent evolution of genes with sequences coding for polyalanine domains. Hum Mol Genet 12:2967-2979.
21. Amiel J, Trochet D, Clement-Ziza M, Munnich A, Lyonnet S. 2004. Polyalanine expansions in human. Hum Mol Genet 13 Spec No 2:R235-243.
22. Albrecht AN, Kornak U, Boddrich A, Suring K, Robinson PN, Stiege AC, Lurz R, Stricker S, Wanker EE, Mundlos S. 2004. A molecular pathogenesis for transcription factor associated poly-alanine tract expansions. Hum Mol Genet 13:2351-2359.

23. Brown LY, Odent S, David V, Blayau M, Dubourg C, Apacik C, Delgado MA, Hall BD, Reynolds JF, Sommer A, Wieczorek D, Brown SA, Muenke M. 2001. Holoprosencephaly due to mutations in ZIC2: alanine tract expansion mutations may be caused by parental somatic recombination. Hum Mol Genet 10:791-796.
24. Brown SA, Warburton D, Brown LY, Yu CY, Roeder ER, Stengel-Rutkowski S, Hennekam RC, Muenke M. 1998. Holoprosencephaly due to mutations in ZIC2, a homologue of Drosophila odd-paired. Nat Genet 20:180-183.
25. Brown L, Paraso M, Arkell R, Brown S. 2005. In vitro analysis of partial loss-of-function ZIC2 mutations in holoprosencephaly: alanine tract expansion modulates DNA binding and transactivation. Hum Mol Genet 14:411-420.
26. Orioli IM, Castilla EE, Ming JE, Nazer J, Burle de Aguiar MJ, Llerena JC, Muenke M. 2001. Identification of novel mutations in SHH and ZIC2 in a South American (ECLAMC) population with holoprosencephaly. Hum Genet 109:1-6.
27. Caburet S, Demarez A, Moumne L, Fellous M, De Baere E, Veitia RA. 2004. A recurrent polyalanine expansion in the transcription factor FOXL2 induces extensive nuclear and cytoplasmic protein aggregation. J Med Genet 41:932-936.
28. Matera I, Bachetti T, Puppo F, Di Duca M, Morandi F, Casiraghi GM, Cilio MR, Hennekam R, Hofstra R, Schober JG, Ravazzolo R, Ottonello G, Ceccherini I. 2004. PHOX2B mutations and polyalanine expansions correlate with the severity of the respiratory phenotype and associated symptoms in both congenital and late onset Central Hypoventilation syndrome. J Med Genet 41:373-380.
29. Trochet D, Hong SJ, Lim JK, Brunet JF, Munnich A, Kim KS, Lyonnet S, Goridis C, Amiel J. 2005. Molecular consequences of PHOX2B missense, frameshift and alanine expansion mutations leading to autonomic dysfunction. Hum Mol Genet 14:3697-3708.
30. Moumne L, Dipietromaria A, Batista F, Kocer A, Fellous M, Pailhoux E, Veitia RA. 2008. Differential aggregation and functional impairment induced by polyalanine expansions in FOXL2, a transcription factor involved in cranio-facial and ovarian development. Hum Mol Genet 17:1010-1019.
31. Nasrallah IM, Minarcik JC, Golden JA. 2004. A polyalanine tract expansion in Arx forms intranuclear inclusions and results in increased cell death. J Cell Biol 167:411-416.
32. Calado A, Tome FM, Brais B, Rouleau GA, Kuhn U, Wahle E, Carmo-Fonseca M. 2000. Nuclear inclusions in oculopharyngeal muscular dystrophy consist of poly(A) binding protein 2 aggregates which sequester poly(A) RNA. Hum Mol Genet 9:2321-2328.
33. Koyabu Y, Nakata K, Mizugishi K, Aruga J, Mikoshiba K. 2001. Physical and functional interactions between Zic and Gli proteins. J Biol Chem 276:6889-6892.



CHAPTER 3

Valvular defects and Left Ventricular Outflow Tract Obstruction (LVOTO)

3.1 Introduction

3.1.1 Signaling pathways in valvulogenesis

3.1.2 Left Ventricular Outflow Tract Obstruction (LVOTO)

3.2 Autosomal dominant inheritance of left ventricular outflow tract obstruction
Wessels MW, Berger RM, Frohn-Mulder IM, Roos-Hesselink JW, Hoogeboom JJ, Mancini GM, Bartelings MM, de Krijger R, Wladimiroff JW, Niermeijer MF, Grossfeld P, Willems PJ
Am J Med Genet 2005; 134A: 171-179

3.3 Autosomal dominant inheritance of cardiac valves anomalies in two families: extended spectrum of left ventricular outflow tract obstruction
Wessels MW, van de Laar IM, Roos-Hesselink, J Strikwerda S, Majoor-Krakauer DF, de Vries BB, Kerstjens-Frederikse WS, Vos YJ, de Graaf BM, Bertoli-Avella AM, Willems PJ
Am J Med Genet 2009; 149A: 216-225

CHAPTER 3

Valvular defects and Left Ventricular Outflow Tract Obstruction (LVOTO)

3.1 Introduction

Anomalies of the atrioventricular and semilunar heart valves account for almost one third of all congenital heart malformations (CHM) [1]. Cardiac valve anomalies can be part of well-defined syndromes such as Noonan syndrome [2,3] and Alagille syndrome [4,5], but the majority of cardiac valve anomalies is not associated with other organ malformations and represent non-syndromic forms. Many non-syndromic valvular defects are associated with other types of CHM, in particular Left Ventricular Outflow Tract Obstruction (LVOTO).

The paucity of multiplex families with a clear Mendelian inheritance pattern of anomalies of the atrioventricular and semilunar heart valves has precluded the identification of disease genes involved in these types of CHM. Currently, only a few disease genes have been implicated in non-syndromic valvular defects and/or LVOTO.

3.1.1 Signaling pathways in valvulogenesis

Animal model studies have elucidated many genetic pathways that play an important role in cardiac valve malformation (for reviews: see refs [6 7]), and many of these genes are candidate disease genes for human valvular defects[8]. Cardiac valve formation depends on a complex interaction between the myocardium and the overlying endocardium, which undergoes an endothelial-to-mesenchymal transdifferentiation (EMT) [7]. In the mouse localized swellings of the cardiac jelly appear in the atrioventricular and cardiac outflow tract, forming the cardiac cushions. These cushions consist of acellular swellings of extracellular matrix protein secreted from the myocardium, which becomes invaded by endocardial cells that are transformed into mesenchymal cells. This complex EMT process and the remodeling process require the interaction of multiple signaling pathways. The most relevant signaling pathways include the VEGF, NOTCH, WNT/beta-Catenin, and RAS/MAPK pathways [6,7]. As these signaling pathways exhibit extensive cross-talking with each other and other pathways it is not surprising that valvular defects are often found in combination with other CHM such as septal defects, chamber hypoplasia and LVOTO (for review: see ref [8]).

The importance of the RAS/MAPK signaling pathway was underscored by the identification of mutations in the *PTPN11, KRAS, SOS1, BRAF, MEK1, MEK2, NF1* and *HRAS* genes in patients with Noonan syndrome and related syndromes, altogether referred to as the neuro–facial–cutaneous syndromes [9]. In

these syndromes pulmonary valve stenosis is a common finding, pointing towards a specific role of the RAS/MAPK pathway in pulmonary valve development.

Defects in the NOTCH signaling pathway play an important role in several human CHM. Mutations in the *JAG1* gene encoding a NOTCH ligand Jagged1, and mutations in the *NOTCH2* gene, encoding a NOTCH transmembrane receptor, lead to Alagille syndrome. This syndrome is also often associated with pulmonary valve abnormalities. *NOTCH1* mutations are associated with aortic valve anomalies, such as bicuspid aortic valve (BAV) and aortic stenosis (AS), but can also lead to other CHM. The *PSEN* genes encoding presenilins, which act as the catalytic subunit of gamma secretase cleaving the Notch intracellular domain from Notch, have also been implicated in humans: *PSEN2* mutations can lead to BAV in association with ventricular septal defect (VSD) [10]. Also mutations in NOTCH signaling target genes may lead to CHM, and human *HEY2* mutations have been found in cardiac tissue of patients with atrioventricular septal defects (AVSD) [11]. Mutations in several genes, including *Hey1*, *Hey2*, and *Fgf8*, are implicated in valve anomalies in mice [8].

Common human *VEGF* variants confer an increased risk for tetralogy of Fallot (TOF), both in non-syndromic cases of TOF and syndromic cases with 22q11 deletions [12]. Also murine mutations in several genes of this pathway (*Nfatc1*, *eNos*) lead to valve anomalies [8].

Mutations in several genes of the WNT/β-Catenin pathway, including *Has2*, *Hdf*, and *B-Catenin*, cause valvular defects in mice, but human mutations in this pathway have not yet been reported [8].

Some additional genes involved in valvulogenesis have been discovered by genetic studies in patients with valvular defects. Mutations in the *FLNA* gene encoding filamin A have been identified as the cause of myxomatous valvular dystrophy, an X-linked valvular disease characterized by myxomatous degeneration, valvular regurgitation and secondary calcification of all four heart valves [13]. Mutations in the *CRELD1* gene, encoding a cell adhesion molecule that is member of a family of matricellular proteins, have been found in patients with AVSD [14].

3.1.2 Left Ventricular Outflow Tract Obstruction (LVOTO)

Left Ventricular Outflow Tract Obstruction (LVOTO) comprises a spectrum of CHM, including BAV, AS, coarctation of the aorta (CoA) and hypoplastic left heart syndrome (HLHS), representing 15-20% of medically significant CHM [15-17]. Within one family all types of LVOTO may occur [18]. Several human syndromes are associated with LVOTO. Thirty percent of patients with Turner syndrome have LVOTO, indicating that haploinsufficiency of X-linked genes might play a role in LVOTO [19-21]. Also the 11q terminal deletion syndrome (previously called Jacobsen syndrome) is often associated with LVOTO, and it is therefore anticipated that cardiac genes in this chromosomal region might serve as good candidate genes for non-syndromic LVOTO [22,23]. Complex genetic inheritance involving several loci is likely in most non-syndromic LVOTO [24-27] However, a limited number of families show autosomal dominant inheritance [8,18], as presented in this thesis. Only 4 genes have been implicated in human LVOTO. NKX2.5 mutations have been found in a few families with HLHS, CoA or interrupted aortic arch (IAA) [28,29]. *NOTCH1* truncating mutations have been identified in familial calcific aortic valve disease in association with other CHM [30,31]. *NOTCH1* missense mutations were also found in patients with LVOTO [32-34]. As some of these missense

mutations were also present in the control group, albeit at a lower frequency, they might represent reduced penetrance mutations. Not all familial LVOTO is caused by *NOTCH1* mutations as linkage analysis in some families excluded the *NOTCH1* gene [8,35,36] and suggestive linkage to other chromosomal loci including 2p23, 5q21, 10q21, 13q34, 16p12, and18q21, has been reported [35,37]. Also somatic mutations have been found in LVOTO: gene conversion events between *GJA1* and its pseudogene have been found in heart tissue from patients with HLHS [38]. Recently, a single recurrent mutation in the *HAND1* gene (c.376delG - A126fs) was detected in left and right ventricle tissue from a large fraction of hypoplastic left and right ventricles, indicating that HAND1 function is impaired in human hypoplastic hearts [39]. In the majority of hearts the mutation was only found in the hypoplastic ventricle [39]. Further studies are needed to determine the contribution of somatic mutations in LVOTO.

In this thesis we describe several families with presumed autosomal dominant inheritance of LVOTO. In addition, 2 large multiplex families with autosomal dominant inheritance of LVOTO in association with right-sided valve anomalies and septal defects are described, thereby extending the spectrum of cardiac anomalies seen in LVOTO. The disease genes in these families remain unknown: *NOTCH1* mutations were excluded, and a genome-wide linkage analysis is currently being performed.

References

1. Loffredo CA. 2000. Epidemiology of cardiovascular malformations: prevalence and risk factors. Am J Med Genet 97:319-325.
2. Gelb BD, Tartaglia M. 2006. Noonan syndrome and related disorders: dysregulated RAS-mitogen activated protein kinase signal transduction. Hum Mol Genet 15 Spec No 2:R220-226.
3. Tartaglia M, Mehler EL, Goldberg R, Zampino G, Brunner HG, Kremer H, van der Burgt I, Crosby AH, Ion A, Jeffery S, Kalidas K, Patton MA, Kucherlapati RS, Gelb BD. 2001. Mutations in PTPN11, encoding the protein tyrosine phosphatase SHP-2, cause Noonan syndrome. Nat Genet 29:465-468.
4. Li L, Krantz ID, Deng Y, Genin A, Banta AB, Collins CC, Qi M, Trask BJ, Kuo WL, Cochran J, Costa T, Pierpont ME, Rand EB, Piccoli DA, Hood L, Spinner NB. 1997. Alagille syndrome is caused by mutations in human Jagged1, which encodes a ligand for Notch1. Nat Genet 16:243-251.
5. McDaniell R, Warthen DM, Sanchez-Lara PA, Pai A, Krantz ID, Piccoli DA, Spinner NB. 2006. NOTCH2 mutations cause Alagille syndrome, a heterogeneous disorder of the notch signaling pathway. Am J Hum Genet 79:169-173.
6. Schroeder JA, Jackson LF, Lee DC, Camenisch TD. 2003. Form and function of developing heart valves: coordination by extracellular matrix and growth factor signaling. J Mol Med 81:392-403.
7. Armstrong EJ, Bischoff J. 2004. Heart valve development: endothelial cell signaling and differentiation. Circ Res 95:459-470.
8. Wessels MW, van de Laar IM, Roos-Hesselink J, Strikwerda S, Majoor-Krakauer DF, de Vries BB, Kerstjens-Frederikse WS, Vos YJ, de Graaf BM, Bertoli-Avella AM, Willems PJ. 2009. Autosomal dominant inheritance of cardiac valves anomalies in two families: Extended spectrum of left-ventricular outflow tract obstruction. Am J Med Genet A 149A:216-225.
9. Denayer E, de Ravel T, Legius E. 2008. Clinical and molecular aspects of RAS related disorders. J Med Genet 45:695-703.
10. Li D, Parks SB, Kushner JD, Nauman D, Burgess D, Ludwigsen S, Partain J, Nixon RR, Allen CN, Irwin RP, Jakobs PM, Litt M, Hershberger RE. 2006. Mutations of presenilin genes in dilated cardiomyopathy and heart failure. Am J Hum Genet 79:1030-1039.
11. Reamon-Buettner SM, Borlak J. 2006. HEY2 mutations in malformed hearts. Hum Mutat 27:118.
12. Lambrechts D, Devriendt K, Driscoll DA, Goldmuntz E, Gewillig M, Vlietinck R, Collen D, Carmeliet P. 2005. Low expression VEGF haplotype increases the risk for tetralogy of Fallot: a family based association study. J Med Genet 42:519-522.

13. Kyndt F, Gueffet JP, Probst V, Jaafar P, Legendre A, Le Bouffant F, Toquet C, Roy E, McGregor L, Lynch SA, Newbury-Ecob R, Tran V, Young I, Trochu JN, Le Marec H, Schott JJ. 2007. Mutations in the gene encoding filamin A as a cause for familial cardiac valvular dystrophy. Circulation 115:40-49.
14. Robinson SW, Morris CD, Goldmuntz E, Reller MD, Jones MA, Steiner RD, Maslen CL. 2003. Missense mutations in CRELD1 are associated with cardiac atrioventricular septal defects. Am J Hum Genet 72:1047-1052.
15. Hoffman JI, Kaplan S. 2002. The incidence of congenital heart disease. J Am Coll Cardiol 39:1890-1900.
16. McBride KL, Marengo L, Canfield M, Langlois P, Fixler D, Belmont JW. 2005. Epidemiology of noncomplex left ventricular outflow tract obstruction malformations (aortic valve stenosis, coarctation of the aorta, hypoplastic left heart syndrome) in Texas, 1999-2001. Birth Defects Res A Clin Mol Teratol 73:555-561.
17. Pradat P, Francannet C, Harris JA, Robert E. 2003. The epidemiology of cardiovascular defects, part I: a study based on data from three large registries of congenital malformations. Pediatr Cardiol 24:195-221.
18. Wessels MW, Berger RM, Frohn-Mulder IM, Roos-Hesselink JW, Hoogeboom JJ, Mancini GS, Bartelings MM, Krijger R, Wladimiroff JW, Niermeijer MF, Grossfeld P, Willems PJ. 2005. Autosomal dominant inheritance of left ventricular outflow tract obstruction. Am J Med Genet A 134:171-179.
19. Sachdev V, Matura LA, Sidenko S, Ho VB, Arai AE, Rosing DR, Bondy CA. 2008. Aortic valve disease in Turner syndrome. J Am Coll Cardiol 51:1904-1909.
20. Bondy CA. 2008. Congenital cardiovascular disease in Turner syndrome. Congenit Heart Dis 3:2-15.
21. Bondy CA. 2008. Aortic dissection in Turner syndrome. Curr Opin Cardiol 23:519-526.
22. Grossfeld PD, Mattina T, Lai Z, Favier R, Jones KL, Cotter F, Jones C. 2004. The 11q terminal deletion disorder: a prospective study of 110 cases. Am J Med Genet A 129:51-61.
23. Tyson C, Qiao Y, Harvard C, Liu X, Bernier FP, McGillivray B, Farrell SA, Arbour L, Chudley AE, Clarke L, Gibson W, Dyack S, McLeod R, Costa T, Vanallen MI, Yong SL, Graham GE, Macleod P, Patel MS, Hurlburt J, Holden JJ, Lewis SM, Rajcan-Separovic E. 2008. Submicroscopic deletions of 11q24-25 in individuals without Jacobsen syndrome: re-examination of the critical region by high-resolution array-CGH. Mol Cytogenet 1:23.
24. McBride KL, Pignatelli R, Lewin M, Ho T, Fernbach S, Menesses A, Lam W, Leal SM, Kaplan N, Schliekelman P, Towbin JA, Belmont JW. 2005. Inheritance analysis of congenital left ventricular outflow tract obstruction malformations: Segregation, multiplex relative risk, and heritability. Am J Med Genet A 134A:180-186.
25. Hinton RB, Jr., Martin LJ, Tabangin ME, Mazwi ML, Cripe LH, Benson DW. 2007. Hypoplastic left heart syndrome is heritable. J Am Coll Cardiol 50:1590-1595.
26. Lewin MB, McBride KL, Pignatelli R, Fernbach S, Combes A, Menesses A, Lam W, Bezold LI, Kaplan N, Towbin JA, Belmont JW. 2004. Echocardiographic evaluation of asymptomatic parental and sibling cardiovascular anomalies associated with congenital left ventricular outflow tract lesions. Pediatrics 114:691-696.
27. Cripe L, Andelfinger G, Martin LJ, Shooner K, Benson DW. 2004. Bicuspid aortic valve is heritable. J Am Coll Cardiol 44:138-143.
28. Elliott DA, Kirk EP, Yeoh T, Chandar S, McKenzie F, Taylor P, Grossfeld P, Fatkin D, Jones O, Hayes P, Feneley M, Harvey RP. 2003. Cardiac homeobox gene NKX2-5 mutations and congenital heart disease: associations with atrial septal defect and hypoplastic left heart syndrome. J Am Coll Cardiol 41:2072-2076.
29. McElhinney DB, Geiger E, Blinder J, Benson DW, Goldmuntz E. 2003. NKX2.5 mutations in patients with congenital heart disease. J Am Coll Cardiol 42:1650-1655.
30. Garg V, Muth AN, Ransom JF, Schluterman MK, Barnes R, King IN, Grossfeld PD, Srivastava D. 2005. Mutations in NOTCH1 cause aortic valve disease. Nature 437:270-274.
31. Garg V. 2006. Molecular genetics of aortic valve disease. Curr Opin Cardiol 21:180-184.
32. McBride KL, Riley MF, Zender GA, Fitzgerald-Butt SM, Towbin JA, Belmont JW, Cole SE. 2008. NOTCH1 mutations in individuals with left ventricular outflow tract malformations reduce ligand-induced signaling. Hum Mol Genet 17:2886-2893.
33. McKellar SH, Tester DJ, Yagubyan M, Majumdar R, Ackerman MJ, Sundt TM, 3rd. 2007. Novel NOTCH1 mutations in patients with bicuspid aortic valve disease and thoracic aortic aneurysms. J Thorac Cardiovasc Surg 134:290-296.
34. Mohamed SA, Aherrahrou Z, Liptau H, Erasmi AW, Hagemann C, Wrobel S, Borzym K, Schunkert H, Sievers HH, Erdmann J. 2006. Novel missense mutations (p.T596M and p.P1797H) in NOTCH1 in patients with bicuspid aortic valve. Biochem Biophys Res Commun 345:1460-1465.
35. Martin LJ, Ramachandran V, Cripe LH, Hinton RB, Andelfinger G, Tabangin M, Shooner K, Keddache M, Benson DW. 2007. Evidence in favor of linkage to human chromosomal regions 18q, 5q and 13q for bicuspid aortic valve and associated cardiovascular malformations. Hum Genet 121:275-284.

36. Ellison JW, Yagubyan M, Majumdar R, Sarkar G, Bolander ME, Atkinson EJ, Sarano ME, Sundt TM. 2007. Evidence of genetic locus heterogeneity for familial bicuspid aortic valve. J Surg Res 142:28-31.
37. McBride KL, Zender GA, Fitzgerald-Butt SM, Koehler D, Menesses-Diaz A, Fernbach S, Lee K, Towbin JA, Leal S, Belmont JW. 2009. Linkage analysis of left ventricular outflow tract malformations (aortic valve stenosis, coarctation of the aorta, and hypoplastic left heart syndrome). Eur J Hum Genet
38. Dasgupta C, Martinez AM, Zuppan CW, Shah MM, Bailey LL, Fletcher WH. 2001. Identification of connexin43 (alpha1) gap junction gene mutations in patients with hypoplastic left heart syndrome by denaturing gradient gel electrophoresis (DGGE). Mutat Res 479:173-186.
39. Reamon-Buettner SM, Ciribilli Y, Inga A, Borlak J. 2008. A loss-of-function mutation in the binding domain of HAND1 predicts hypoplasia of the human hearts. Hum Mol Genet 17:1397-1405.

3.2

American Journal of Medical Genetics 134A:171–179 (2005)

Autosomal Dominant Inheritance of Left Ventricular Outflow Tract Obstruction

Marja W. Wessels,[1,2]* Rolf M.F. Berger,[3] Ingrid M.E. Frohn-Mulder,[3] Jolien W. Roos-Hesselink,[4] Jeanette J.M. Hoogeboom,[2] Grazia S. Mancini,[2] Margot M. Bartelings,[5] Ronald de Krijger,[6] Jury W. Wladimiroff,[1,2] Martinus F. Niermeijer,[1] Paul Grossfeld,[7] and Patrick J. Willems[8]

[1]*Department of Clinical Genetics, Erasmus University Medical Centre, Rotterdam, The Netherlands*
[2]*Department of Obstetrics & Gynaecology, Erasmus University Medical Centre, Rotterdam, The Netherlands*
[3]*Department of Paediatric Cardiology, Sophia Children's Hospital, Rotterdam, The Netherlands*
[4]*Department of Cardiology, Erasmus University Medical Centre, Rotterdam, The Netherlands*
[5]*Department of Anatomy, Leiden University Medical Centre, The Netherlands*
[6]*Department of Pathology, Erasmus University Medical Centre, Rotterdam, The Netherlands*
[7]*Division of Paediatric Cardiology, Children's Hospital San Diego, San Diego, California*
[8]*GENDIA, Antwerp, Belgium*

Most nonsyndromic congenital heart malformations (CHMs) in humans are multifactorial in origin, although an increasing number of monogenic cases have been reported recently. We describe here four new families with presumed autosomal dominant inheritance of left ventricular outflow tract obstruction (LVOTO), consisting of hypoplastic left heart (HLHS) or left ventricle (HLV), aortic valve stenosis (AS) and bicuspid aortic valve (BAV), hypoplastic aortic arch (HAA), and coarctation of the aorta (CoA). LVOTO in these families shows a wide clinical spectrum with some family members having severe anomalies such as hypoplastic left heart, and others only minor anomalies such as mild aortic valve stenosis. This supports the suggestion that all anomalies of the LVOTO spectrum are developmentally related and can be caused by a single gene defect.
© 2005 Wiley-Liss, Inc.

KEY WORDS: left ventricular outflow tract obstruction; LVOTO; autosomal dominant; prenatal diagnosis

INTRODUCTION

Historically, a congenital heart malformation (CHM) occurring as an isolated feature (nonsyndromic heart malformation) has been considered as a multifactorial disorder with recurrence risks for first-degree relatives in the order of 1–18% [Nora and Nora, 1988]. Nonsyndromic CHM with monogenic inheritance is rare, although an increasing number of reports of single gene defects causing diverse forms of CHM are being reported over the past years.

Left ventricular outflow tract obstruction (LVOTO) includes obstructive anomalies of the left heart and aorta, such as hypoplastic left heart syndrome (HLHS) and hypoplastic left ventricle (HLV), aortic valve stenosis (AS) and bicuspid aortic valve (BAV), hypoplastic aortic arch (HAA), coarctation of the aorta (CoA), and occasionally interrupted aortic arch (IAA).

The frequent occurrence of LVOTO in some human syndromes (syndromic LVOTO), and many animal models indicate that LVOTO is genetically very heterogeneous. Specific human syndromes frequently associated with LVOTO include Turner syndrome [Mazzanti and Cacciari, 1998], Kabuki syndrome [Digilio et al., 2001], Jacobsen syndrome [Grossfeld et al., 2004], Holt-Oram syndrome [Bruneau et al., 1999], and Williams syndrome [Eronen et al., 2002]. LVOTO has also been reported in Alagille syndrome [McElhinney et al., 2002], Noonan syndrome [Marino et al., 1999; Sarkozy et al., 2003], and DiGeorge/velocardiofacial syndrome (DGS/VCFS). A few families with an autosomal dominant association of CoA and aplasia cutis have been reported [Dallapiccola et al., 1992; Bruel et al., 1999], whereas Cornel et al. [1987] reported a family with autosomal dominant CoA, deafness, and bilateral ptosis. Additionally, LVOTO anomalies have been reported in one family with Andersen syndrome due to mutations in the *KCNJ2* gene [Andelfinger et al., 2002].

Nonsyndromic LVOTO anomalies usually occur sporadically or in familial patterns compatible with multifactorial inheritance [Simon et al., 1974; Boon and Roberts, 1976; Brownell and Shokeir, 1976]. Only a small number of nonsyndromic cases with monogenic inheritance of LVOTO have been reported [Cough, 1961; Shokeir, 1971; Beekman and Robinow, 1985; McDonald and Maurer, 1989; Nordenberg et al., 1989; Menahem, 1990; Gerboni et al., 1993; Grobman and Pergament, 1996; Grossfeld, 1999; Stoll et al., 1999].

We describe here four new families with presumed autosomal dominant inheritance of nonsyndromic LVOTO.

CLINICAL REPORTS

Family 1

Patient 1. This male infant (II-2) was born at 41 weeks gestation after an unremarkable pregnancy. A routine ultrasound scan at 22 weeks had not revealed any abnormality. Birth weight was 3,910 g. On day 8, his condition suddenly deteriorated and he was admitted to the pediatric ward. X-rays showed an enlarged heart. Echocardiography demonstrated

*Correspondence to: Marja W. Wessels, M.D., Department of Clinical Genetics, Westzeedijk 112, 3016 AH Rotterdam, The Netherlands. E-mail: m.w.wessels@erasmusmc.nl

Received 12 May 2004; Accepted 16 December 2004

DOI 10.1002/ajmg.a.30601

© 2005 Wiley-Liss, Inc.

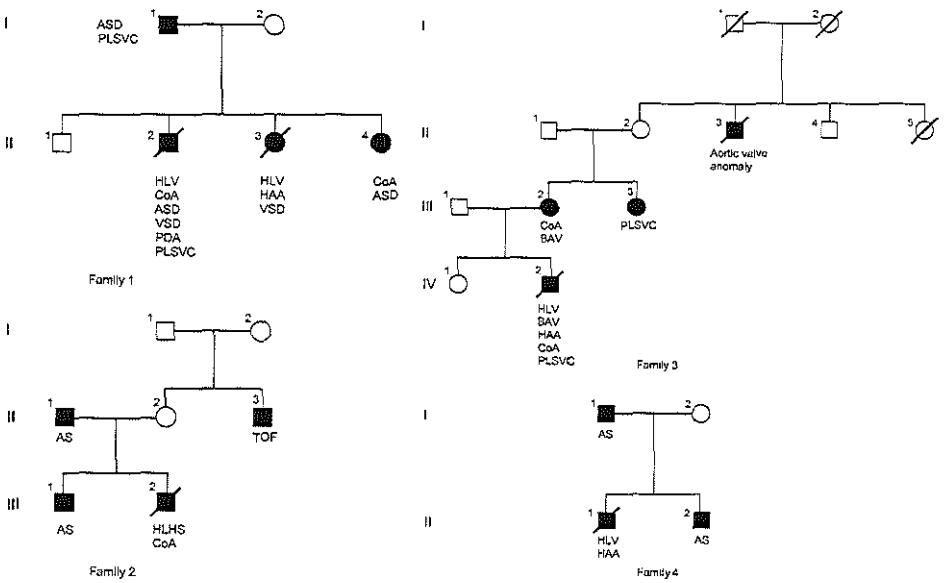

Fig. 1. Pedigrees of four families with probable autosomal dominant inheritance of LVOTO.

persistent left superior vena cava (PLSVC), HLV, perimembraneous ventricular septal defect (VSD), atrial septal defect (ASD), and CoA with patent ductus arteriosus (PDA). Enlargement of the right atrium and ventricle, a coexisting sign of CoA, was present. There was no evidence of other congenital malformations, and no dysmorphic features were observed. The CoA was surgically corrected and the PDA closed. The ASD and VSD were closed surgically 4 weeks later. At the age of 2 months, the baby died from left heart failure and pulmonary hypertension attributed to myocardial ischemia and mild re-CoA. At autopsy, the cardiac abnormalities were confirmed, and no other anomalies were found.

Patient 2. In the next pregnancy (II-3), a fetal echocardiography was performed at 20 weeks because of the history of a previous child with a CHM (Fig. 1). The left ventricular width and diameter of the aortic valve were >2 SDs below the normal mean (Fig. 2), whereas the right ventricular width was normal [Sharland and Allan, 1992]. The ascending aorta and aortic arch were hypoplastic. No other fetal anomalies were detected. Amniocentesis to determine the fetal karyotype was offered, but declined by the parents. After 39 weeks, a female infant (II-3) with a birth weight of 3,080 g was born.

Postnatal echocardiography and catheterization confirmed the prenatal findings of relative HLV, a perimembraneous VSD, and HAA. No other congenital anomalies were identified, and no indication for limb defects such as occur in the Holt-Oram syndrome were present. Three weeks after birth, surgical reconstruction of the aortic arch was performed. At operation, the HAA was confirmed. The diameter of the aorta was 5 mm in the ascending part (normal values between 6.8 and 8.9 mm), 3 mm between the left common carotic artery and the left subclavian artery (normal values between 5.6 and 8.3 mm), and 2 mm at the isthmus (normally between 4.9 and 5.8 mm). Postoperative recovery was complicated by sepsis, and 5 days after surgery bradycardia and hypotension resulted in the death of the child. At autopsy, the abovementioned cardiac anomalies were confirmed, and septic and ischemic foci of the myocardium were found. No other congenital anomalies were observed.

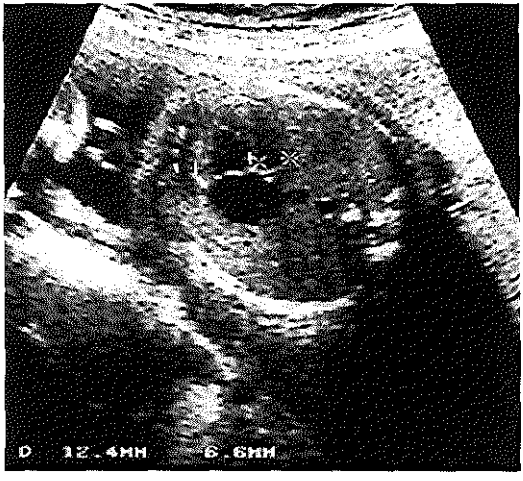

Fig. 2. The four-chamber view of the heart of patient 2 from family 1 at 26 weeks demonstrates ventricular discrepancy with a normal-sized right ventricle but a small left ventricle. The left ventricular width is only 6.6 mm (>2 SDs below the normal mean).

Patient 3. In the fourth pregnancy (II-4), a fetal echocardiography was performed at 20 weeks. A normal-sized left ventricle with a normal appearance of the ascending aorta was found. At 34 weeks, a normal-sized left ventricle was seen with a width of 12 mm. However, enlargement of the right atrium and ventricle with an abnormal ratio between the two ventricles suggested CoA, although the distal aortic arch could not be visualized well. The aortic root diameter and the flow across the aortic valve were normal.

At 39 weeks, a girl (II-4) with a birth weight of 4,010 g was born. She had no dysmorphic features. Echocardiography revealed enlargement of the right heart and a relatively small left ventricle, a small secundum ASD, and a CoA with a hypoplastic isthmus. A successful repair of the CoA with end-to-end anastomosis was performed 1 week after birth. At the age of 3 year, the child is developing well, although the discrepancy in size between the right and the left ventricle remained. Chromosome analysis showed a normal female karyotype, and a microdeletion of the 22q11 region was excluded by fluorescent in situ hybridization (FISH).

Patient 4. The father (I-1) was diagnosed in his childhood with ASD and PLSVC. Retrospective revaluation of the angiographic recordings of the father also suggested a disproportion between the ventricles, with an enlarged right ventricle and a normal-sized left ventricle. After the birth of the first affected child, microsatellite analysis of the 22q11 region was performed in the father, and a deletion of the 22q11 region was excluded.

Additional family members. Echocardiography of the mother (I-2) was unremarkable. The oldest child (II-1) was unaffected. The family history of both parents revealed no other family members with CHM or other congenital malformations. The parents of the father (I-1) were not investigated.

Family 2

Patient 1. This is the first child (III-1) of nonconsanguineous Caucasian parents (Fig. 1). He was born at term with a birth weight of 3,600 g after an unremarkable pregnancy and delivery.

At the age of 1 year, he was evaluated because of an asymptomatic heart murmur. A mild AS with a good ventricular function was diagnosed. At the age of 4, the child was developing normal and no dysmorphic features were present. Chromosome analysis was normal.

Patient 2. In the next pregnancy (III-2), the mother underwent fetal echocardiography in the 20th week of gestation because of the history of a previous child with CHM (patient 1). The four-chamber view revealed a small and poorly functioning left ventricle with endocardial fibroelastosis and restricted mitral valve movement. The ascending aorta was hypoplastic with a diameter of 1.3 mm (>2 SDs below the normal mean). A diagnosis of HLHS was made. Amniocentesis revealed a normal male karyotype, and FISH analysis to exclude a 22q11 deletion was normal. The pregnancy was terminated at 21 weeks, and post mortem examination revealed a HLHS with left ventricular fibroelastosis, mitral valve stenosis, aortic valve atresia, HAA, and juxtaductal CoA. There were no other abnormalities or dysmorphic features.

Patient 3. After the second pregnancy, both parents underwent cardiologic evaluation. The father (II-1) was diagnosed with a thickened tricuspid aortic valve with mild AS and aortic regurgitation. The left ventricular function was good. The mother (II-2) had no cardiac abnormalities.

Patient 4. A brother of the mother (II-3) was diagnosed at the age of 1 year with a tetralogy of Fallot (TOF) with a severe stenotic bicuspid pulmonary valve, overriding aorta, VSD, and PLSVC. He underwent repeated cardiac surgery. At the age of 27, he has a normal psychomotor development without evident dysmorphic features.

Other family members. The grandparents (I-1 and I-2) were not evaluated.

Family 3

Patient 1. This patient (III-2) was diagnosed in her childhood with mild mitral valve stenosis, BAV with regurgitation, and CoA (Fig. 1). She underwent corrective surgery at the age of 6. Her first child is a healthy girl (IV-1).

Patient 2. During the second pregnancy of patient 1, a 20-week anomaly scan was performed because of her CHM. The four-chamber view was abnormal and revealed a poorly contracting HLV with a very small mitral and aortic valve, and diminished forward flow over both valves. The ascending aorta of the fetus (IV-2) was hypoplastic. Amniocentesis revealed a normal male karyotype, and a 22q11 deletion was excluded by FISH. After genetic counseling, the parents decided to terminate the pregnancy. Autopsy showed moderate HLV with a small mitral valve and a small aortic ostium with a bicuspid valve. A PLSVC was connected with the coronary sinus. A premature closure of the foramen ovale was found. The ascending aorta was hypoplastic and a severe preductal CoA was observed. The left vertebral artery originated separately from the aortic arch. No other congenital abnormalities were found.

Patient 3. A maternal uncle of patient 1 (II-3) had a aortic valve replacement at the age of 57, but no more details are known.

Patient 4. The sister of patient 1 (III-3) showed a PLSVC without other structural heart defects.

Additional family members. Cardiologic evaluation of the mother (II-2) of patient 1 revealed no abnormalities. The parents (I-1 and I-2) of patient 3 were not investigated.

Family 4

Patient 1. Patient (I-1) was diagnosed with severe AS and BAV after birth. A valvulectomy was performed in the first year of life. At the age of 13 years, moderate AS and poststenotic dilatation of the aorta was found, which progressed in subsequent years. Now at the age of 30, he is awaiting aortic valve replacement and reconstruction of the ascending aorta.

Patient 2. Patient 2 (II-1) is a child of patient 1 (Fig. 1). At 20 weeks gestation, a cardiac anomaly scan was performed because of the CHM of patient 1. HLH, a small mitral valve and diminished forward flow across the mitral valve were observed. The aortic valve measured 1 mm (>2 SD below the normal mean for gestational age). The ascending aorta and aortic arch could not be visualized well, suggesting HAA. Chromosome analysis including FISH of the 22q11 region was normal. At 23 weeks, the pregnancy was terminated. Post mortem examination was declined by the parents.

Patient 3. In the next pregnancy (II-2), a 20-week cardiac anomaly scan performed elsewhere had revealed no abnormalities. Evaluation at 32 weeks gestation revealed severe valvular AS, and the patient was referred to our unit for second opinion. A dilated, hypokinetic left ventricle without endocardial fibroelastosis was observed. A normal-sized mitral valve with restricted opening was present. The aortic valve measured 4 mm (>2 SD below the normal mean), and was thickened and restricted in motion. High flow velocities (240 cm/sec) were found across the aortic valve. In view of this severe AS and poor left ventricular function, the child was delivered at 33 weeks by Caesarean section. Birth weight was 2,140 g. Apgar scores were 3 and 2 at 1 and 5 min, respectively. Prostaglandin was administrated, and balloon valvoplasty was performed directly after birth. A restricted foramen ovale

was dilated using a Rashkind balloon septostomy technique. Balloon valvoplasty was repeated after a few weeks because of restenosis. At the age of 3 months, he had undergone a Ross procedure with homograft placement in the pulmonary valve position. At age 1 year, he is now stable with diuretics, ACE-inhibitors, and enteral tube feeding.

DISCUSSION

We report on four families (Fig. 1) with multiple cases of nonsyndromic left LVOTO. The three sibs in the first family all presented with relative HLV, and various degrees of hypoplasia of the aorta and/or CoA. In addition, they had an ASD and/or a perimembraneous VSD. The second family presented with mild valvular AS in the father and oldest son, whereas the second son had a HLHS and CoA. In the third family, the mother had CoA, the son had HLV with CoA and HAA, and an uncle of the mother had an undefined abnormality of the aortic valve. The fourth family presented with severe valvular AS in the father and second son. The first child had a HLV and HAA. These families illustrate the wide clinical spectrum of LVOTO, with some family members showing severe anomalies such as HLHS, and others only minor anomalies such as mild AS. This supports the hypothesis that all the separate cardiovascular anomalies of the LVOTO spectrum are developmentally related. This is also suggested by experimental animal studies generating altered flow through the embryonic heart by clipping of the aorta, which also leads to LVOTO [Harh et al., 1973; Fishman et al., 1978]. This so-called flow theory is supported by observations of progression of LVOTO in utero: structural defects of the left heart, which result in decreased left ventricular preload or increased left ventricular afterload alter normal blood flow and are associated with left ventricular hypoplasia [Allan et al., 1989; Anderson and Brown, 1991; Danford and Cronican, 1992]. Thus, mutations in genes that affect embryonic hemodynamics may cause LVOTO.

Nonsyndromic LVOTO usually occurs sporadically, and a multifactorial origin has been proposed [Simon et al., 1974; Boon and Roberts, 1976; Brownell and Shokeir, 1976]. However, strong familial aggregation of LVOTO has been reported by other investigators [Rose et al., 1985; Boughman et al., 1987; Boughman, 1991; Ferencz et al., 1993]. Recently, an extensive study of first-degree relatives of probands with HLHS and CoA revealed a frequency of cardiac malformations that was much

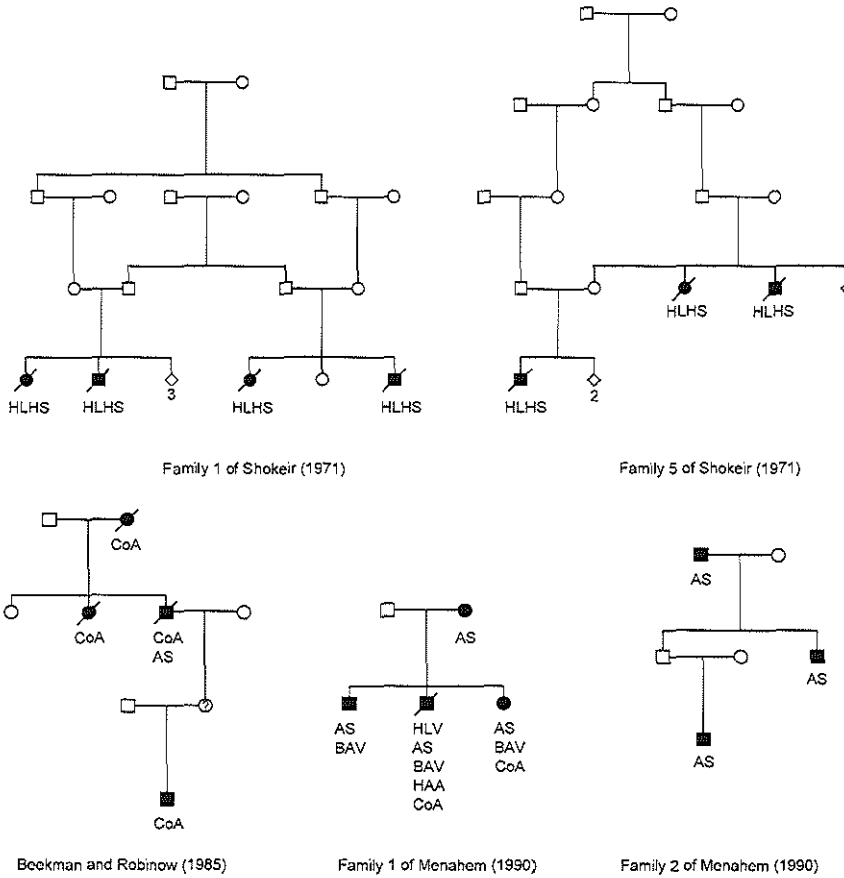

Fig. 3. Families reported in the literature with 3 or more first or second degree relatives affected with LVOTO.

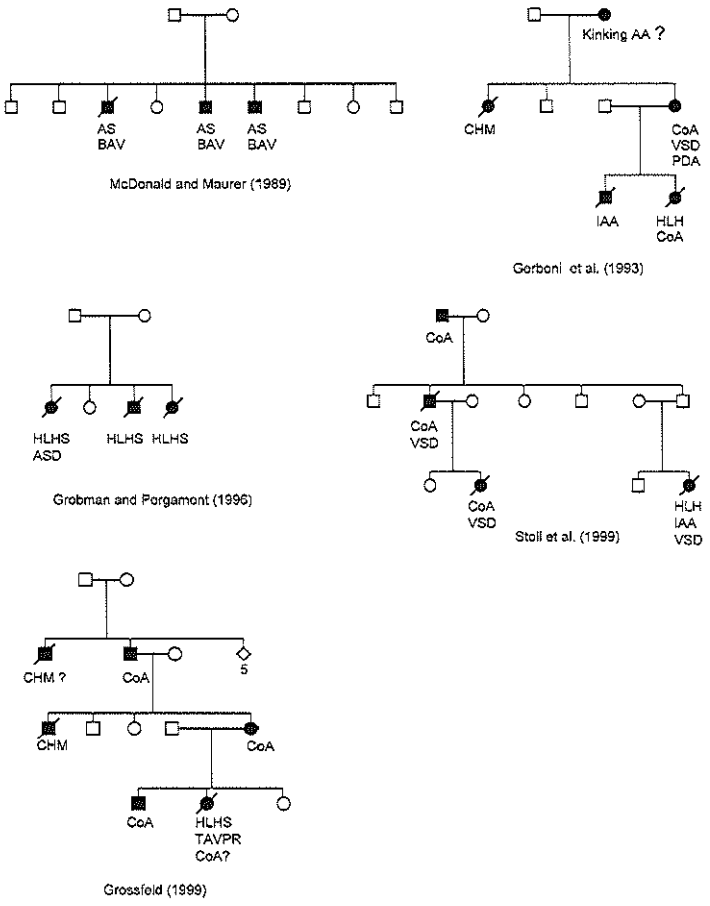

Fig. 3. (*Continued*)

higher than would be expected in a multifactorial model of inheritance [Loffredo et al., 2004]. In the latter study, CHM was detected in 19% of first degree relatives of probands with HLH, and in 9% of first degree relatives of probands with CoA. Predominantly LVOTO and particularly BAV were found in these relatives. Only a limited number of families with presumed monogenic inheritance of nonsyndromic LVOTO has been reported in the literature (cited in Introduction) and those families that had three or more affected cases are presented in Figure 3. LVOTO in our four families most likely shows autosomal dominant inheritance, with CHM in male and female patients in several generations and male-to-male inheritance in families 1, 2, and 4 (Fig. 1).

Altogether the studies above suggest the existence of monogenic forms of nonsyndromic LVOTO. Three genes, *GJA1*, *NKX2.5*, and *ZIC3*, have been involved in nonsyndromic LVOTO in humans. Somatic mutations in the human *GJA1* gene encoding connexin43 have been found in cardiac tissue in a subset of patients with hypoplastic left heart and total anomalous pulmonary venous connections [Dasgupta et al., 2001]. As these findings have not yet been confirmed by other investigators, their significance is not yet clear, although a gene causing total anomalous pulmonary venous connections, and therefore decreased flow to the developing embryonic left ventricle, is consistent with the flow theory. More recently, germline mutations in the cardiac transcription factor gene *NKX2.5* have been identified in a minority of patients with LVOTO (3 patients on a total of 179 investigated), including one patient with CoA, and two patients with HLHS [Elliott et al., 2003; McElhinney et al., 2003]. Ware et al. [2004] recently reported HLHS without manifestations of heterotaxy in two males with a *ZIC 3* mutation.

Also the genes involved in syndromic LVOTO might be candidate genes for nonsyndromic LVOTO. DGS/VCFS is clinically variable with IAA type B, truncus arteriosus, and TOF as the most common heart defects. Although the outflow tract defects in LVOTO are different from the spectrum of CHM in DGS/VCFS, there is at least one patient with HLHS in association with a 22q11 deletion [Consevage et al., 1996]. Furthermore, two patients with autosomal dominant LVOTO

TABLE I. LVOTO Caused By Single Gene Defects in Mice and Man

Mice			Man			
Gene	Cardiac anomaly	Reference	Gene	Cardiac anomaly	Syndrome	Reference
Adam19	AS, PS, VSD	Zhou et al. [2004]				
Clp1	HLV	Huang et al. [2004]				
Ece1	IAA*, VSD	Yanagisawa et al. [1998]	*ECE1*	PDA, ASD,VSD	Hirschprung disease	Hofstra et al. [1999]
Edn1	IAA*, VSD	Kurihara et al. [1995]				
Ednra	IAA*, VSD	Clouthier et al. [1998]				
Eln	Obliterated arteries	Li et al. [1998]	*ELN*	SVAS, PAS, AS, CoA	Williams syndrome	Eronen et al. [2002]
eNos	BAV, AS, ASD, VSD	Lee et al. [2000]				
Ephrin-B2	Thickened semilunar and mitral valve	Cowan et al. [2004]				
Fgf8	HAA, HLV, DORV, defects LR axis	Abu-Issa et al. [2002]				
Foxc1	IAA*, CoA, VSD, valve anomalies	Winnier et al. [1999]	*FKHL7*		Axenfeld-Rieger syndrome	Nishimura et al. [1998]
Foxc2	IAA*, CoA, VSD, valve anomalies	Winnier et al. [1999]	*FKHL14*	VSD, PDA, TOF	Lymphedema-distiachis syndrome	Brice et al. [2002]
Gja1	Pulmonary outflow obstruction	Reaume et al. [1995]	*GJA1*	HLHS, TAPVR	Deafness, oculodentodigital dysplasia	Dasgupta et al. [2001]; Liu et al. [2001]; Paznekas et al. [2003]
Hand1	HLV	Firulli et al. [1998]				
Jagged1		Xue et al. [1999]	*JAGGED1*	PS, TOF, AS, BAV, CoA	Alagille syndrome	McElhinney et al. [2002]
Madh6	Thickened valves, HAA	Galvin et al. [2000]				
NFATc1	Absent semilunar valves	Johnson et al. [2002]				
Nkx2.5	BAV, AS, ASD	Biben et al. [2000]	*NKX2.5*	ASD, AV block, TOF, HLHS		Goldmuntz et al. [2001]; Elliott et al. [2003]; McElhinney et al. [2003]
Egfr/Ptpn11	AS	Chen et al. [2000]	*PTPN11*	PS, cardiomyopathy, CoA, mitral valve disease	Noonan syndrome	Marino et al. [1999]
Sema3C	IAA*, truncus arteriosus	Feiner et al. [2001]				
Tbx1	AAA, truncus arteriosus	Merscher et al. [2001]	*TBX1*	IAA*, VSD	22q11 deletion syndrome	Gong et al. [2001]; Yagi et al. [2003]
Tbx5	HLV, ASD	Bruneau et al. [2001]	*TBX5*	ASD,VSD, conduction defects, HLV, AS, mitral valve disease	Holt-Oram syndrome	Bruneau et al. [1999]
Zic3	TGA, dextrocardia, ASD, VSD	Purandare et al. [2002]	*ZIC3*	HLHS, heterotaxy		Ware et al. [2004]

AAA, aotic arch abnormalities; AS, aortic stenosis; ASD, atrial septal defect; AV, atrio ventricular; BAV, bicuspid aortic valve; CoA, coarctation of the aorta; HAA, hypoplastic aortic arch; HLHS, hypoplastic left heart syndrome; HLV, hypoplastic left ventricle; IAA, interrupted aortic arch; PS, pulmonary stenosis; PAS, pulmonary arterial stenosis; SVAS, supravalvular aortic stenosis; TAPVR, total anomalous pulmonary venous retour; TOF, tetralogy of Fallot; VSD, ventricular septal defect.
*Interruption between left common carotid artery and left subclavian artery.

have IAA [Gerboni et al., 1993; Stoll et al., 1999], although the localization of the interruption in these patients is not clear. The *TBX1* gene, suggested to be responsible for abnormalities in DGS/VCFS [Gong et al., 2001; Jerome and Papaioannou, 2001; Lindsay et al., 2001; Merscher et al., 2001; Yagi et al., 2003] might therefore be a candidate gene for nonsyndromic LVOTO.

Although supravalvular aortic stenosis and pulmonary arterial stenosis are the most common CHMs in patients with Williams syndrome, aortic and mitral valve defects were diagnosed in 11% [Eronen et al., 2002]. Congenital BAV and AS are sometimes associated with dilated ascending aorta due to severe degeneration of the elastic network [Roberts and Roberts, 1991]. Such a postvalvular aortic dilatation was also found in patient 1 from family 4. Thus, also genes involved in the elastin network might therefore be good candidate genes for nonsyndromic LVOTO.

Holt-Oram syndrome is most commonly associated with ASD and VSD, but also LVOTO (including HLHS) has been described [Sletten and Pierpont, 1996; Bruneau et al., 1999]. Furthermore, TBX5, implicated in Holt-Oram syndrome, interacts with NKX2.5, which is involved in nonsyndromic LVOTO.

LVOTO is very frequent in Jacobsen syndrome, which is characterized by mental retardation, craniosynostosis, dysmorphic facies, thrombocytopenia, growth retardation, and deletion of 11q [Penny et al., 1995; Pivnick et al., 1996; Grossfeld et al., 2004]. About half of the patients have a CHM, most commonly LVOTO, and membranous VSDs. Five to ten percent of Jacobsen syndrome patients are born with HLHS, a frequency that is 1,000–2,000 times the frequency of the general population. Candidate genes for Jacobsen syndrome include *JAM3*, *OBCAM*, and Neurotrimin [Phillips et al., 2002].

Many mice models present with LVOTO, displaying abnormalities of left ventricular growth, mitral and aortic valve formation, and aortic hypoplasia and interruption (as listed in Table I). The genes implicated in these mice models might also be candidate genes for human LVOTO.

ACKNOWLEDGMENTS

The authors thank Prof. Dr. A.C. Gittenberger-de Groot for valuable comments on the manuscript. We also thank Tom de Vries Lentsch and Ruud Koppenol for photographic work and Dr. A.D.J. Ten Harkel for clinical information.

REFERENCES

Abu-Issa R, Smyth G, Smoak I, Yamamura K, Meyers EN. 2002. Fgf8 is required for pharyngeal arch and cardiovascular development in the mouse. Development 129:4613–4625.

Allan LD, Sharland G, Tynan MJ. 1989. The natural history of the hypoplastic left heart syndrome. Int J Cardiol 25:341–343.

Andelfinger G, Tapper AR, Welch RC, Vanoye CG, George AL Jr, Benson DW. 2002. KCNJ2 mutation results in Andersen syndrome with sex-specific cardiac and skeletal muscle phenotypes. Am J Hum Genet 71: 663–668.

Anderson NG, Brown J. 1991. Normal size left ventricle on antenatal scan in lethal hypoplastic left heart syndrome. Pediatr Radiol 21:436–437.

Beekman RH, Robinow M. 1985. Coarctation of the aorta inherited as an autosomal dominant trait. Am J Cardiol 56:818–819.

Biben C, Weber R, Kesteven S, Stanley E, McDonald L, Elliott DA, Barnett L, Koentgen F, Robb L, Feneley M, Harvey RP. 2000. Cardiac septal and valvular dysmorphogenesis in mice heterozygous for mutations in the homeobox gene Nkx2.5. Circ Res 87:888–895.

Boon AR, Roberts DF. 1976. A family study of coarctation of the aorta. J Med Genet 13:420–433.

Boughman JA. 1991. Variations of familial risks of congenital cardiovascular malformations (CCVM): Higher risk in left flow defect families. Am J Hum Genet Suppl 49(4):465.

Boughman JA, Berg KA, Astemborski JA, Clark EB, McCarter RJ, Rubin JD, Ferencz C. 1987. Familial risks of congenital heart defect assessed in a population-based epidemiologic study. Am J Med Genet 26:839–849.

Brice G, Mansour S, Bell R, Collin JR, Child AH, Brady AF, Sarfarazi M, Burnand KG, Jeffery S, Mortimer P, Murday VA. 2002. Analysis of the phenotypic abnormalities in lymphoedema-distichiasis syndrome in 74 patients with FOXC2 mutations or linkage to 16q24. J Med Genet 39: 478–483.

Brownell LG, Shokeir MHK. 1976. Inheritance of hypoplastic left heart syndrome (HLHS): Further observations. Clin Genet 9:245–249.

Bruel H, Poinsot J, Chabrolle JP, Layet V. 1999. Association of aplasia cutis congenita with coarctation of the aorta: A coincidence? Arch Pediatr 6:1193–1195.

Bruneau BG, Logan M, Davis N, Levi T, Tabin CJ, Seidman JG, Seidman CE. 1999. Chamber-specific cardiac expression of Tbx5 and heart defects in Holt-Oram syndrome. Dev Biol 211:100–108.

Bruneau BG, Nemer G, Schmitt JP, Charron F, Robitaille L, Caron S, Conner DA, Gessler M, Nemer M, Seidman CE, Seidman JG. 2001. A murine model of Holt-Oram syndrome defines roles of the T-box transcription factor Tbx5 in cardiogenesis and disease. Cell 106:709–721.

Chen B, Bronson RT, Klaman LD, Hampton TG, Wang JF, Green PJ, Magnuson T, Douglas PS, Morgan JP, Neel BG. 2000. Mice mutant for Egfr and Shp2 have defective cardiac semilunar valvulogenesis. Nat Genet 24:296–299.

Clouthier DE, Hosoda K, Richardson JA, Williams SC, Yanagisawa H, Kuwaki T, Kumada M, Hammer RE, Yanagisawa M. 1998. Cranial and cardiac neural crest defects in endothelin-A receptor-deficient mice. Development 125:813–824.

Consevage MW, Scip JR, Belchis DA, Davis AT, Baylen BG, Rogan PK. 1996. Association of a mosaic chromosomal 22q11 deletion with hypoplastic left heart syndrome. Am J Cardiol 77:1023–1025.

Cornel G, Sharratt GP, Virmani S, Rosales T, Lacson A. 1987. Familial coarctation of the aortic arch with bilateral ptosis: a new syndrome? J Pediatr Surg 22:724–726.

Cough JH. 1961. Coarctation of the aorta in father and son. Brit J Radiol 34:670–672.

Cowan CA, Yokoyama N, Saxena A, Chumley MJ, Silvany RE, Baker LA, Srivastava D, Henkemeyer M. 2004. Ephrin-B2 reverse signaling is required for axon pathfinding and cardiac valve formation but not early vascular development. Dev Biol 271:263–271.

Dallapiccola B, Giannotti A, Marino B, Digilio C, Obregon G. 1992. Familial aplasia cutis congenita and coarctation of the aorta. Am J Med Genet 43:762–763.

Danford DA, Cronican P. 1992. Hypoplastic left heart syndrome: progression of left ventricular dilation and dysfunction to left ventricular hypoplasia in utero. Am Heart J 123:1712–1713.

Dasgupta C, Martinez AM, Zuppan CW, Shah MM, Bailey LL, Fletcher WH. 2001. Identification of connexin43 (alpha1) gap junction gene mutations in patients with hypoplastic left heart syndrome by denaturing gradient gel electrophoresis (DGGE). Mutat Res 479:173–186.

Digilio MC, Marino B, Toscano A, Giannotti A, Dallapiccola B. 2001. Congenital heart defects in Kabuki syndrome. Am J Med Genet 100: 269–274.

Elliott DA, Kirk EP, Yeoh T, Chandar S, McKenzie F, Taylor P, Grossfeld P, Fatkin D, Jones O, Hayes P, Feneley M, Harvey RP. 2003. Cardiac homeobox gene NKX2-5 mutations and congenital heart disease: associations with atrial septal defect and hypoplastic left heart syndrome. J Am Coll Cardiol 41:2072–2076.

Eronen M, Peippo M, Hiippala A, Raatikka M, Arvio M, Johansson R, Kahkonen M. 2002. Cardiovascular manifestations in 75 patients with Williams syndrome. J Med Genet 39:554–558.

Feiner L, Webber AL, Brown CB, Lu MM, Jia L, Feinstein P, Mombaerts P, Epstein JA, Raper JA. 2001. Targeted disruption of semaphorin 3C leads to persistent truncus arteriosus and aortic arch interruption. Development 128:3061–3070.

Ferencz C, Rubin JD, Loffredo CA, Magee CA. 1993. Epidemiology of congenital heart disease: The Baltimore-Washington Infant study, 1981–1989. Mt. Kisco, NY: Futura Publishing Co. 45p.

Firulli AB, McFadden DG, Lin Q, Srivastava D, Olson EN. 1998. Heart and extra-embryonic mesodermal defects in mouse embryos lacking the bHLH transcription factor Hand1. Nat Genet 18:266–270.

Fishman NH, Hof RB, Rudolph AM, Heymann MA. 1978. Models of congenital heart defects in fetal lambs. Circulation 58:354–364.

Galvin KM, Donovan MJ, Lynch CA, Meyer RI, Paul RJ, Lorenz JN, Fairchild-Huntress V, Dixon KL, Dunmore JH, Gimbrone MA Jr, Falb D, Huszar D. 2000. A role for smad6 in development and homeostasis of the cardiovascular system. Nat Genet 24:171–174.

Gorboni S, Sabatino G, Mingarelli R, Dallapiccola XX. 1993. Coarctation of the aorta, interrupted aortic arch and hypoplastic left heart syndrome in three generations. J Med Genet 30:328–329.

Goldmuntz E, Geiger E, Benson DW. 2001. NKX2.5 mutations in patients with tetralogy of fallot. Circulation 104:2565–2568.

Gong W, Gottlieb S, Collins J, Blescia A, Dietz H, Goldmuntz E, McDonald-McGinn DM, Zackai EH, Emanuel BS, Driscoll DA, Budarf ML. 2001. Mutation analysis of TBX1 in non-deleted patients with features of DGS/VCFS or isolated cardiovascular defects. J Med Genet 38:e45.

Grobman W, Pergament E. 1996. Isolated hypoplastic left heart syndrome in three siblings. Obstet Gynaecol 88:673–675.

Grossfeld PD. 1999. The genetics of hypoplastic left heart syndrome. Cardiol Young 9:627–632.

Grossfeld PD, Mattina T, Lai Z, Favier R, Jones KL, Cotter F, Jones C. 2004. The 11q terminal deletion disorder: a prospective study of 110 cases. Am J Med Genet 129A(1):51–61.

Harh JY, Paul MH, Gallen WJ, Friedberg DZ, Kaplan S. 1973. Experimental production of hypoplastic left heart syndrome in the chick embryo. Am J Cardiol 31:51–56.

Hofstra RMW, Valdenaire O, Arch E, Osinga J, Kroes H, Loffler B-M, Hamosh A, Meijers C, Buys CHCM. 1999. A loss-of-function mutation in the endothelin-converting enzyme 1 (ECE-1) associated with Hirsch-sprung disease, cardiac defects, and autonomic dysfunction. Am J Hum Genet 64:304–308.

Huang F, Wagner M, Siddiqui MA. 2004. Ablation of the CLP-1 gene leads to down-regulation of the HAND1 gene and abnormality of the left ventricle of the heart and fetal death. Mech Dev 121:559–572.

Jerome LA, Papaioannou VE. 2001. DiGeorge syndrome phenotype in mice mutant for the T-box gene, Tbx1. Nat Genet 27:286–291.

Johnson EN, Lee YM, Sander TL, Rabkin E, Schoen FJ, Kaushal S, Bischoff J. 2002. NFATc1 mediates vascular endothelial growth factor (VEGF)-induced proliferation in human pulmonary valve endothelial cells. J Biol Chem 278:1686–1692.

Kurihara Y, Kurihara H, Oda H, Maemura K, Nagai R, Ishikawa T, Yazaki Y. 1995. Aortic arch malformations and ventricular septal defect in mice deficient in endothelin-1. J Clin Invest 96:293–300.

Lee TC, Zhao YD, Courtman DW, Stewart DJ. 2000. Abnormal aortic valve development in mice lacking endothelial nitric oxide synthase. Circulation 101:2345–2348.

Li DY, Faury G, Taylor DG, Davis EC, Boyle WA, Mecham RP, Stenzel P, Boak B, Keating MT. 1998. Novel arterial pathology in mice and humans hemizygous for elastin. J Clin Invest 102:1783–1787.

Lindsay EA, Vitelli F, Su H, Morishima M, Huynh T, Pramparo T, Jurecic V, Ogunrinu G, Sutherland H, Scambler PJF, Bradley A, Baldini A. 2001. Tbx1 haploinsufficiency in the DiGeorge syndrome region causes aortic arch defects in mice. Nature 410:97–101.

Liu XZ, Xia XJ, Adams J, Chen ZY, Welch KO, Tekin M, Ouyang XM, Kristiansen A, Pandya A, Balkany T, Arnos KS, Nance WE. 2001. Mutations in GJA1 (connexin 43) are associated with non-syndromic autosomal recessive deafness. Hum Mol Genet 10:2945–2951.

Loffredo CA, Chokkalingam A, Sill AM, Boughman JA, Clark EB, Scheel J, Brenner JI. 2004. Prevalence of congenital cardiovascular malformations among relatives of infants with hypoplastic left heart, coarctation of the aorta, and d-transposition of the great arteries. Am J Med Genet 124:225–230.

Marino B, Digilio MC, Toscano A, Giannotti A, Dallapiccola B. 1999. Congenital heart diseases in children with Noonan syndrome: An expanded cardiac spectrum with high prevalence of atrioventricular canal. J Pediatr 135:703–706.

Mazzanti L, Cacciari E. 1998. Congenital heart disease in patients with Turner's syndrome. Italian Study Group for Turner Syndrome (ISGTS). J Pediatr 133:688–692.

McDonald K, Maurer BJ. 1989. Familial aortic valve disease: evidence for a genetic influence? Eur Heart J 10:676–677.

McElhinney DB, Krantz ID, Bason L, Piccoli DA, Emerick KM, Spinner NB, Goldmuntz E. 2002. Analysis of cardiovascular phenotype and genotype-phenotype correlation in individuals with a JAG1 mutation and/or Alagille syndrome. Circulation 106:2567–2574.

McElhinney DB, Geiger E, Blinder J, Woodrow Benson D, Goldmuntz E. 2003. Nkx2.5 mutations in patients with congenital heart disease. J Am Coll Cardiol 42:1650–1655.

Menahem S. 1990. Familial aggregation of defects of the left-sided structures of the heart. Int J Cardiol 29:239–240.

Merscher S, Funke B, Epstein JA, Heyer J, Puech A, Lu MM, Xavier RJ, Demay MB, Russell RG, Factor S, Tokooya K, Jore BS, Lopez M, Pandita RK, Lia M, Carrion D, Xu H, Schorle H, Kobler JB, Scambler P, Wynshaw-Boris A, Skoultchi AI, Morrow BE, Kucherlapati R. 2001. TBX1 is responsible for cardiovascular defects in velo-cardio-facial/DiGeorge syndrome. Cell 104:619–629.

Nishimura DY, Swiderski RE, Alward WL, Searby CC, Patil SR, Bennet SR, Kanis AB, Gastier JM, Stone EM, Sheffield VC. 1998. The forkhead transcription factor gene FKHL7 is responsible for glaucoma phenotypes which map to 6p25. Nat Genet 19:140–147.

Nora JJ, Nora AH. 1988. Update on counseling the family with a first-degree relative with a congenital heart defect. Am J Med Genet 29:137–142.

Nordenberg DF, Hanna B, Fouron JC, Kaloustian VM. 1989. Atrial septal defect, ventri-cular septal defect and coarctation of the aorta. Am J Med Genet 32:182–183.

Paznekas WA, Boyadjiev SA, Shapiro RE, Daniels O, Wollnik B, Keegan CE, Innis JW, Dinulos MB, Christian C, Hannibal MC, Jabs EW. 2003. Connexin 43 (GJA1) mutations cause the pleiotropic phenotype of oculodentodigital dysplasia. Am J Hum Genet 72:408–418.

Penny LA, Dell'Aquila M, Jones MC, Bergoffen J, Cunniff C, Fryns J-P, Grace E, Graham JM Jr, Kousseff B, Mattina T, Syme J, Voullaire L, Zelante L, Zonger-Hain J, Jones OW, Evans GA. 1995. Clinical and molecular characterization of patients with distal 11q deletions. Am J Hum Genet 56:676–683.

Phillips HM, Renforth GL, Spalluto C, Hearn T, Curtis AR, Craven L, Havarani B, Clement-Jones M, English C, Stumper O, Salmon T, Hutchinson S, Jackson MS, Wilson DI. 2002. Narrowing the critical region within 11q24-qter for hypoplastic left heart and identification of a candidate gene, JAM3, expressed during cardiogenesis. Genomics 79:475–478.

Pivnick EK, Velagaleti GVN, Wilroy RS, Smith ME, Rose SR, Tipton RE, Tharapel AT. 1996. Jacobson syndrome: Report of a patient with severe eye anomalies, growth hormone deficiency, and hypothyroidism associated with deletion 11(q23q25) and review of 52 cases. J Med Genet 33:772–778.

Purandare SM, Ware SM, Kwan KM, Gebbia M, Bassi MT, Deng JM, Vogel H, Behringer RR, Belmont JW, Casey B. 2002. A complex syndrome of left-right axis, central nervous system and axial skeleton defects in Zic3 mutant mice. Development 129:2293–2302.

Reaume AG, de Sousa PA, Kulkarni S, Langille BL, Zhu D, Davies TC, Juneja SC, Kidder GM, Rossant J. 1995. Cardiac malformation in neonatal mice lacking connexin43. Science 267:1831–1834.

Roberts CS, Roberts WC. 1991. Dissection of the aorta associated with congenital malformation of the aortic valve. J Am Coll Cardiol 17:712–716.

Rose V, Gold RJ, Lindsay G, Allen M. 1985. A possible increase in the incidence of congenital heart defects among the offspring of affected parents. J Am Coll Cardiol 6:376–382.

Sarkozy A, Conti E, Seripa D, Digilio MC, Grifone N, Tandoi C, Fazio VM, Di Ciommo V, Marino B, Pizzuti A, Dallapiccola B. 2003. Correlation between PTPN11 gene mutations and congenital heart defects in Noonan and LEOPARD syndromes. J Med Genet 40:704–708.

Sharland GK, Allan LD. 1992. Normal fetal cardiac measurements derived by cross-sectional echocardiography. Ultrasound Obstet Gynaecol 2:175–181.

Shokeir MHK. 1971. Hypoplastic left heart syndrome: An autosomal recessive disorder. Clin Genet 2:7–14.

Simon AB, Zloto AE, Perry BL, Sigmann JM. 1974. Familial aspects of coarctation of the aorta. Chest 66:687–689.

Sletten LJ, Pierpont ME. 1996. Variation in severity of cardiac disease in Holt-Oram syndrome. Am J Med Genet 65:128–132.

Stoll C, Alembik Y, Dott B. 1999. Familial coarctation of the aorta in three generations. Ann Genet 42:174–176.

Ware SM, Peng J, Zhu L, Fernbach S, Colicos S, Casey B, Towbin J, Belmont JW. 2004. Identification and functional analysis of ZIC3 mutations in heterotaxy and related congenital heart defects. Am J Hum Genet 74:93–105.

Winnier GE, Kume T, Deng K, Rogers R, Bundy J, Raines C, Walter MA, Hogan BL, Conway SJ. 1999. Roles for the winged helix transcription factors MF1 and MFH1 in cardiovascular development revealed by nonallelic noncomplementation of null alleles. Dev Biol 213: 418–431.

Xue Y, Gao X, Lindsell CE, Norton CR, Chang B, Hicks C, Gendron-Maguire M, Rand EB, Weinmaster G, Gridley T. 1999. Embryonic lethality and vascular defects in mice lacking the Notch ligand Jagged1. Hum Mol Genet 8:723–730.

Yagi H, Furutani Y, Hamada H, Sasaki T, Asakawa S, Minoshima S, Ichida F, Joo K, Kimura M, Imamura S, Kamatani N, Momma K, Takao A, Nakazawa M, Shimizu N, Matsuoka R. 2003. Role of TBX1 in human del22q11.2 syndrome. Lancet 362:1366–1373.

Yanagisawa H, Yanagisawa M, Kapur RP, Richardson JA, Williams SC, Clouthier DE, de Wit D, Emoto N, Hammer RE. 1998. Dual genetic pathways of endothelin-mediated intercellular signaling revealed by targeted disruption of endothelin converting enzyme-1 gene. Development 125:825–826.

Zhou HM, Weskamp G, Chesneau V, Sahin U, Vortkamp A, Horiuchi K, Chiusaroli R, Hahn R, Wilkes D, Fisher P, Baron R, Manova K, Basson CT, Hempstead B, Blobel CP. 2004. Essential role for ADAM19 in cardiovascular morphogenesis. Mol Cell Biol 24:96–104.

3.3

CLINICAL REPORT

AMERICAN JOURNAL OF medical genetics A

Autosomal Dominant Inheritance of Cardiac Valves Anomalies in Two Families: Extended Spectrum of Left-Ventricular Outflow Tract Obstruction

Marja W. Wessels,[1]* Ingrid M.B.H. van de Laar,[1] Jolien Roos-Hesselink,[2] Sipke Strikwerda,[3] Danielle F. Majoor-Krakauer,[1] Bert B.A. de Vries,[4] Wilhelmina S. Kerstjens-Frederikse,[5] Yvonne J. Vos,[5] Bianca M. de Graaf,[1] Aida M. Bertoli-Avella,[1] and Patrick J. Willems[6]

[1]Department of Clinical Genetics, Erasmus University Medical Center, Rotterdam, The Netherlands

[2]Department of Cardiology, Erasmus University Medical Center, Rotterdam, The Netherlands

[3]Department of Cardiology, Amphia Hospital, Breda, The Netherlands

[4]Department of Human Genetics, Radboud University Medical Center, Nijmegen, The Netherlands

[5]Department of Genetics, University Medical Center Groningen, Groningen, The Netherlands

[6]GENDIA, Genetic Diagnostic Network, Antwerp, Belgium

Received 4 May 2007; Accepted 20 August 2008

Only a limited number of families with clear monogenic inheritance of nonsyndromic forms of congenital valve defects have been described. We describe two multiplex pedigrees with a similar nonsyndromic form of heart valve anomalies that segregate as an autosomal dominant condition. The first family is a three-generation pedigree with 10 family members affected with congenital defects of the cardiac valves, including six patients with aortic stenosis and/or aortic regurgitation. Pulmonary and/or tricuspid valve abnormalities were present in three patients, and ventricular septal defect (VSD) was present in two patients. The second family consists of 11 patients in three generations with aortic valve stenosis in seven patients, defects of the pulmonary valves in two patients, and atrial septal defect (ASD) in two patients. Incomplete penetrance was observed in both families. Although left-ventricular outflow tract obstruction was present in most family members, the co-occurrence with pulmonary valve abnormalities and septal defects in both families is uncommon. These families provide evidence that left-sided obstructive defects and thoracic aortic aneurysm may be accompanied by right-sided defects, and even septal defects. These families might be instrumental in identifying genes involved in cardiac valve morphogenesis and malformation. © 2009 Wiley-Liss, Inc.

Key words: aortic dilatation; autosomal dominant; bicuspid aortic valve; candidate genes; congenital heart malformation; heart valves; left-ventricular outflow tract obstruction; pathways; thoracic aortic aneurysm

How to Cite this Article:
Wessels MW, van de Laar IMBH, Roos-Hesselink J, Strikwerda S, Majoor-Krakauer DF, de Vries BBA, Kerstjens-Frederikse WS, Vos YJ, de Graaf BM, Bertoli-Avella AM, Willems PJ. 2009. Autosomal dominant inheritance of cardiac valves anomalies in two families: Extended spectrum of left-ventricular outflow tract obstruction.
Am J Med Genet Part A 149A:216–225.

INTRODUCTION

Anomalies of the atrioventricular and semilunar heart valves and associated structures account for 25–30% of all congenital cardiovascular malformations (CVM) [Loffredo, 2000]. Most occur sporadically in a single patient without affected family members, and unassociated with other malformations (nonsyndromic). On the other hand, well-defined syndromes with autosomal dominant inheritance, such as Noonan syndrome (caused by *PTPN11*, *KRAS*, *SOS1*, or *RAF1* mutations), and Alagille syndrome (caused by *JAGGED1* and *NOTCH2* mutations) are often associated with valve defects [McElhinney et al., 2002; McDaniell et al., 2006; Sznajer et al., 2007].

Only a limited number of families with clear monogenic inheritance of nonsyndromic forms of congenital valve defects have been described. Familial nonsyndromic valve anomalies often include

*Correspondence to:
Marja W. Wessels, M.D., Department of Clinical Genetics, Westzeedijk 112, 3016 AH Rotterdam, The Netherlands.
E-mail: m.w.wessels@erasmusmc.nl
Published online 20 January 2009 in Wiley InterScience (www.interscience.wiley.com)
DOI 10.1002/ajmg.a.32594

© 2009 Wiley-Liss, Inc.

either the left-sided heart valves (aortic and mitral valve) or the right-sided heart valves (tricuspid and pulmonary valve). Left-sided valve anomalies can be part of a spectrum of anomalies of the left-ventricular outflow tract referred to as LVOTO (left-ventricular outflow tract obstruction; also known as obstructive anomalies of the left-heart and aorta) [McBride et al., 2005; Wessels et al., 2005; Garg et al., 2006], but in some families they occur without other LVOTO anomalies [Rao et al., 1969; McDonald and Maurer, 1989; Menahem, 1990]. In two families with LVOTO anomalies including bicuspid aortic valve (BAV) with calcification, Garg et al. [2006] documented truncating mutations in *NOTCH 1*. Two patients in these families also exhibited right-sided heart malformations, including double outlet right-ventricle and tetralogy of Fallot. Bicuspid aortic valve underlies the majority of patients with aortic valve disease and familial BAV has been described in single families suggesting autosomal inheritance [Emanuel et al., 1978; Glick and Roberts, 1994; Clementi et al., 1996; Huntington et al., 1997]. Studies on heritability of BAV support that genetic factors play a major role in BAV and demonstrate that BAV is often associated with other cardiovascular malformations, in particular LVOTO anomalies and thoracic aortic aneurysm (TAA) [Cripe et al., 2004; McBride et al., 2005; Loscalzo et al., 2007]. Locus heterogeneity for familial BAV has been established in several studies [Goh et al., 2002; Ellison et al., 2007; Martin et al., 2007], and genome-wide scans in families with BAV and/or associated CVM has demonstrated linkage to chromosomes 15q25-26, 18q, 5q, and 13q [Goh et al., 2002; Martin et al., 2007].

Another frequent left-sided heart valve anomaly, mitral valve prolapse, can be inherited as an autosomal dominant trait, and has been linked to chromosome 13 [Freed et al., 2003; Nesta et al., 2005]. Familial right-sided valve anomalies frequently represent syndromic forms of CVM and only a few nonsyndromic families are reported. Pulmonary stenosis (PS) is common in families with Noonan syndrome (*PTPN11* mutations), Watson syndrome (*NF1* mutations), and Alagille syndrome (*JAGGED1* mutations). Mutations in *PTPN11*, however, have not been convincingly shown to be present in patients with nonsyndromic PS [Sarkozy et al., 2003], although a few cases of possible nonsyndromic PS with *JAGGED1* mutations have been described [Krantz et al., 1999]. Nonsyndromic familial right-sided valve anomalies have only been described in a few small families. PS has been reported in some families with clear autosomal dominant inheritance [David, 1974; Ciuffo et al., 1985], and in some families with unknown mode of inheritance [Coblentz and Mathivat, 1952; Lamy et al., 1957; McCarron and Perloff, 1974; Klinge and Laursen, 1975; El-Said et al., 1979; Udwadia et al., 1996]. PS combined with ASD in a large pedigree has been shown to be due to a mutation in the *GATA4* gene [Garg et al., 2003]. Familial pulmonic valve atresia and familial occurrence of tricuspid anomalies are very uncommon, and have only been described in a few families [DiChiara et al., 1980; Chitayat et al., 1992; Kumar et al., 1994; Grant, 1996; Grossfeld et al., 1997; Lin and Rosti, 1998; Bonnet et al., 1999].

Only a few families with combined left- and right-sided heart valve anomalies with monogenic inheritance have been described. A large family with autosomal dominant inheritance of mainly atrioventricular valve defects including Ebstein anomaly and atrioventricular canal has been described by Schunkert et al. [1997]. Atrioventricular septal defects (AVSD) (also known as endocardial cushion defects) can be inherited as an autosomal dominant trait with variable expression and incomplete penetrance. These valve anomalies can be due to mutations in the gene encoding the cell adhesion molecule *CRELD1* [Robinson et al., 2003], and a second locus is located on chromosome 1p31-p21. A few families with X-linked valvular dysplasia, a condition characterized by myxomatous degeneration, valvular regurgitation and secondary calcification affecting all four heart-valves have been described [Newbury-Ecob et al., 1993; Kyndt et al., 1998]. Recently mutations in the *FLNA* gene encoding filamin A were identified in these families [Kyndt et al., 2007].

The paucity of multiplex families with a clear Mendelian inheritance pattern of nonsyndromic cardiac valve malformation has precluded the identification of human genes specifically involved in cardiac valve morphogenesis and malformation. We describe two families with a similar autosomal dominant form of congenital heart malformation mainly consisting of cardiac valve anomalies.

CLINICAL REPORTS

Family 1

The pedigree of family 1 is shown in Figure 1.

Patient 1. The index patient (II-1) visited our Department of Clinical Genetics for genetic counseling. She had aortic valve replacement at the age of 42 because of a severely stenotic BAV. She received two new aortic valve prostheses in the following 30 years, and at the age of 60 she developed atrial fibrillation. Three of the five children of patient II-1 were healthy, and cardiologic examination including ECG and echocardiography revealed no abnormalities. Two other children (Patients 2 and 3) are affected.

Patient 2. One of the five children (III-4) of Patient II-1 was asymptomatic until he presented with progressive dyspnea at the age of 44. Echocardiography revealed a BAV, a dilated left-ventricle with thickening of the posterior wall, and left-ventricular dysfunction.

Patient 3. Another son (III-5) of Patient II-1 was diagnosed with a BAV with mild stenosis and regurgitation, and mild dilatation of the aorta at the age of 26 years. An X-ray of the thorax showed an elongated aorta. At the age of 36 years the aortic valve was stenotic, calcified and thickened, and mild tricuspid regurgitation was present. His left-ventricular function remained good. Chromosomal analysis showed a normal male karyotype. A microdeletion of the 22q11 (*TBX1* gene) and 7q11.23 (*elastin* gene) region was excluded by fluorescent in situ hybridization (FISH).

Patient 4. A sister (II-2) of Patient II-1 was diagnosed with valvular aortic stenosis and regurgitation, mitral stenosis with regurgitation, and tricuspid regurgitation. She underwent three operation for aortic and mitral valve prostheses between the age of 40 and 44 years. At the age of 45 years a tricuspid valve correction was performed. She died at the age of 50. In four of her five children cardiologic examination including ECG and echocardiography revealed no abnormalities.

Patient 5. A daughter (III-7) of Patient II-2 was diagnosed with moderate mitral valve regurgitation at the age of 50 years.

Patient 6. A brother (II-4) of Patient II-1 was diagnosed with aortic valve regurgitation and received an aortic valve replacement.

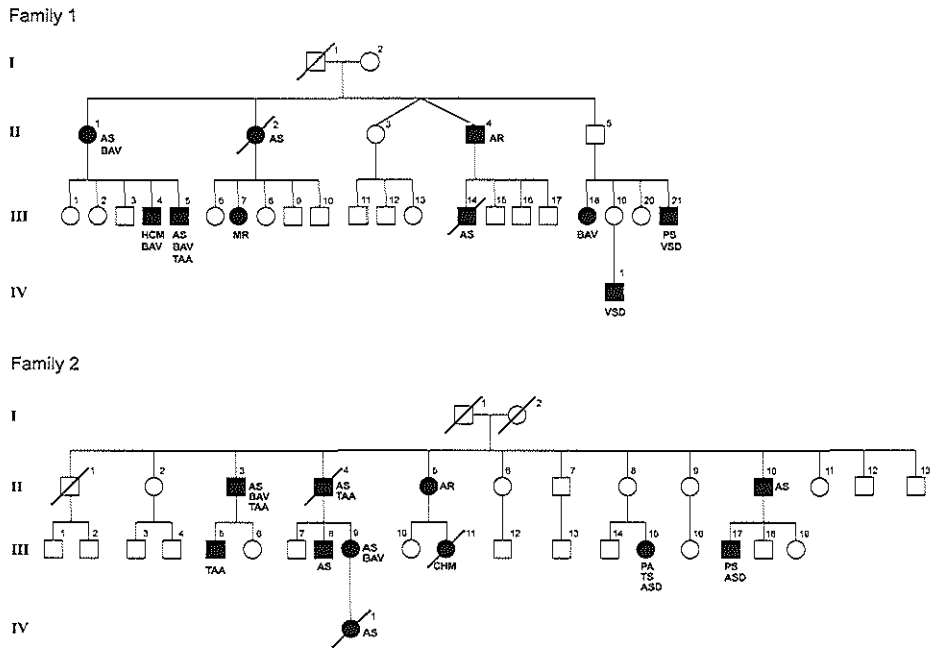

FIG. 1. Pedigrees of two families with autosomal dominant inheritance of congenital valve anomalies. AR, aortic valve regurgitation; AS, aortic valve stenosis; ASD, atrial septal defect; BAV, bicuspid aortic valve; CVM Cardiovascular malformation; HCM, hypertrophic cardiomyopathy; MR, mitral valve regurgitation; PS, pulmonary valve stenosis; PA, pulmonary atresia; TAA, thoracic aortic aneurysm; VSD, ventricular septal defect.

Patient 7. The son (patient III-14) of Patient II-4 was diagnosed with aortic stenosis. Surgical correction was performed at the age of 9 years. He died 1-day after surgery.

Patient 8. One of the three daughters of Patient II-5 (patient III-18) underwent valvulotomy for a severely stenotic BAV at the age of 9 years. She also received a mitral valve prosthesis for severe mitral valve regurgitation.

Patient 9. The brother of Patient III-18 (patient III-21) was operated at the age of 5 years for a VSD and valvular PS. He developed a re-stenosis and pulmonary valve regurgitation.

Patient 10. A son (IV-1) of an asymptomatic sister of Patient III-18 was diagnosed with a perimembranous VSD at the age of 4 months.

Family 2

The pedigree of family 2 is shown in Figure 1.

Patient 1. The parents of Patient (III-15) visited our Department of Clinical Genetics for genetic counseling when their daughter was born with pulmonary atresia with intact ventricular septum, double-chambered right ventricle an ASD. The aortic valve showed no abnormalities. Surgical correction was performed in the first year and again at the age of 5 years. At the age of 7 years an obstructive fibromuscular bundle in the right ventricle was removed, and a small tricuspid valve with prolapse of the leaflets was found during operation. The chordae were abnormally long and attached directly to the ventricle wall without papillary muscles. Chromosomal analysis showed a normal female karyotype. A microdeletion of the 22q11 region and 7q11.23 region were excluded by FISH. Cardiac evaluation of both parents of patient 1 showed no abnormalities, the asymptomatic mother (II-8) was 53 years at examination.

Patient 2. The son (III-17) of a brother of the mother of Patient III-15 was diagnosed at birth with a severe valvular and infundibular PS with intact ventricular septum and a secundum ASD. Surgical correction was performed at the age of 1-year. After a second operation at the age of 6 he died from hypoxic encephalopathy.

Patient 3. The father (II-10) of Patient III-17 underwent cardiologicevaluation at the age of 35 years because of the familialCVM, and a valvular aortic stenosis was diagnosed. Chromo-

somal analysis and FISH of the 22q11 region showed no abnormalities.

Patient 4. A brother (II-4) of Patient II-13 was diagnosed at the age of 31 years with a severe valvular aortic stenosis and regurgitation and dilatation of the ascending aorta. At the age of 32 years his severely calcified aortic valve was replaced by a Bjork Shiley prosthesis. Chromosomal analysis and FISH of the 22q11 region showed no abnormalities. He died suddenly at the age of 50 years.

Patient 5. The daughter (III-9) of Patient II-4 was evaluated at the age of 7 years for a cardiac murmur, but was thought to have no abnormality. After giving birth to an affected child (IV-1) she was re-evaluated and was diagnosed as having a stenotic BAV.

Patient 6. Patient III-9 gave birth to a girl (Patient IV-1) with critical valvular aortic stenosis who died several days after birth.

Patient 7. A son (III-8) of Patient II-4 was diagnosed with a severe valvular aortic stenosis and received aortic valve replacement.

Patient 8. A brother (II-3) of Patients II-4 and II-10 was examined at the age of 47 years because of the familial CVM: echocardiography revealed a mildly stenotic, thickened BAV, with mild dilatation of the ascending aorta. At the age of 58 years the aortic root diameter was 53 mm and there was an ascending aorta aneurysm measuring 61 mm. There was left-ventricular hypertrophy. A Bentall procedure including replacement of the ascending aorta and proximal aortic arch was performed. A severely calcified aortic valve was replaced. Pathological examination showed a calcified aortic valve and wall. Intima fibrosis was present and mild medial degeneration. The elastin fibers showed no abnormalities. The daughter of this patient (III-11) showed no abnormalities on cardiologic examination, including echocardiography.

Patient 9. A son (III-5) of Patient II-3 was examined by the cardiologist and had mild dilatation of the ascending aorta (43 mm) without valvular abnormalities, left ventricular dysfunction or hypertrophy.

Patient 10. A daughter (III-11) of a sister (II-5) of Patients II-8 died 12 days after birth with an enlarged heart.

Patient 11. Cardiologic evaluation of the mother (II-5) of patient 10 at the age of 43 years revealed no abnormalities, but re-evaluation at the age of 57 years showed a sclerotic aortic valve with moderate regurgitation.

Additional family members. Cardiologic evaluation (echocardiography and ECG) of healthy family members in generation II (II-2, II-6, II-7, II-8, II-9 and II-11) showed no abnormalities. These healthy family members were between 39 and 64 years of age at the time of examination. The grandparents in generation I were not investigated. The grandfather died of a cardiac arrest at the age of 57 years.

MOLECULAR STUDIES

Linkage analysis using polymorphic microsatellites D9S1826, D9S158, and D9S1838 flanking the *NOTCH1* gene was performed in both families. This excluded *NOTCH1* as the disease gene in both families since multiple recombinants were found. Additionally, sequence analysis of all coding exons and intron–exon boundaries of the *NOTCH1* gene was normal in one affected patient in each family.

DISCUSSION

We describe two families with autosomal dominant inheritance of isolated CVM mainly involving the cardiac valves. None of the affected family members showed signs of a connective tissue disorder or malformation syndrome. Among the 10 affected family members of the first family, 6 were diagnosed with an abnormal stenotic and/or insufficient aortic valve. In three patients, regurgitation of the mitral valve was present. Pulmonary valve abnormality was diagnosed in one family member. In the second family, abnormal semilunar valves were present in nine family members, seven with abnormal aortic valves, and two with defects of the pulmonary valves (Table I). Different cardiologists evaluated patients and BAV may not always be reported if present. In both families, septal defects were present in several patients, which we believe may be part of the spectrum since they co-existed with valve anomalies in several family members. In the first family, one patient had a VSD and PS. In the second family, an ASD was present in a patient with PS and in a patient with pulmonary atresia. No other congenital abnormalities or dysmorphic features were present in any of the patients, indicating that the CVM in these families is nonsyndromic. In both families, autosomal dominant inheritance is well supported since there are three affected generations with male–male inheritance and expression in both females and males. Nonpenetrance is present in one obligate carrier in both families. In family 2, patient II-2 was unaffected at the age of 43 years but showed moderate aortic valve regurgitation 14 years later at the age of 57. Patient II-8 showed no abnormalities at echocardiography at the age of 53. She has a tri-leaflet aortic valve and normal function of cardiac valves and the left-ventricle.

Autosomal dominant inheritance of nonsyndromic congenital valve anomalies has only been described in a limited number of families. In most cases consistence of valve anomalies of either predominantly left- or right-sided structures of the heart is present. In both presented families predominantly aortic valve anomalies were observed, although right-sided malformations such as pulmonary and tricuspid valve anomalies were present in some patients. This observation is also documented in other studies with smaller families (for instance only two persons affected) where patterns of inheritance are not always clear [Gill et al., 2003; Lewin et al., 2004; Martin et al., 2007]. In a recent study demonstrating high heritability of hypoplastic left-heart syndrome (HLHS) a high percentage of HLHS probands had both left- and right-sided valve dysplasia suggesting that HLHS is a severe form of valve malformation and anomalies of the left- and right-sided valves may have a common etiology [Hinton et al., 2007].

Human genes known to be involved in valvulogenesis include genes associated with elastogenesis and collagen synthesis, as elastin and collagen are major components of semilunar and atrioventricular valves. As mutations in most of these genes are associated with syndromic forms of CVM they are unlikely to be involved in our families with nonsyndromic CVM. Familial BAV and aortic valve stenosis in association with TAA is a well-recognized entity. Loscalzo et al. [2007] suggested that altered TGFB signaling might play a role in BAV with TAA as several aneurysm syndromes, including Marfan syndrome [Neptune et al., 2003], Loeys Dietz syndrome [Loeys et al., 2005], and arterial tortuosity syndrome

TABLE I. Families With Cardiac Valve Abnormalities

	Family 1										Family 2									
	1	2	3	4	5	6	7	8	9	10	1	2	3	4	5	6	7	8	9	10	11
Anomaly	II-1	III-4	III-5	II-2	III-7	II-4	III-14	III-18	III-21	IV-1	III-15	III-17	II-10	II-4	III-9	IV-1	III-8	II-3	III-5	III-11	II-5
Aortic stenosis	+	+	+	+			+	+					+	+	+	+	+	+			
Bicupid aortic valve	+		+					+							+			+			
Thoracic aortic aneurysm		+	+											+				+	+		+
Aortic regurgitation			+	+		+					+										
Pulmonary atresia												+									
Pulmonary stenosis									+												
Mitral stenosis				+																	
Mitral regurgitation				+	+			+			+										
Tricuspid stenosis																					
Tricuspid regurgitation				+								+									
Atrial septal defect										+											
Ventricular septal defect									+												
Cardiomyopathy		+																			
Unspecified CVM																				+	

[Coucke et al., 2006] are associated with upregulation of the TGFB pathway leading to loss of elastic fiber integrity. However, *TGFBR1* and *TGFBR2* gene analysis in 13 families with BAV and TAA revealed no mutations in [Loscalzo et al., 2007]. Recently mutations in the gene *ACTA2*, encoding vascular smooth muscle cell α- actin, were identified as a major cause of autosomal dominant inherited TAA. Interestingly multiple familymembers in 4 out of 14 described families with *ACTA2* mutations showed BAV, indicating that genes encoding sacromeric proteins might be good candicate genes for a subset of familial LVOTO [Guo et al., 2007].

Elastin mutations in our families are unlikely as they predominantly cause supravalvular aortic stenosis, although aortic valve stenosis can also occur. Furthermore, right-sided valve anomalies and ASD/VSD are rarely described in patients with elastin mutations [Metcalfe et al., 2000; Eronen et al., 2002].

Only a few genes have been involved in nonsyndromic CVM with a monogenic mode of inheritance; these include the *NOTCH1*, *Elastin*, *NKX2.5*, *NKX2.6*, *GATA4*, *CRELD1*, *MYH6*, *ACTA0*, *TBX20*, and *FLNA* genes [for reviews: Bruneau, 2008; Ransom and Srivastava, 2007; Weismann and Gelb, 2007]. Mutations in *NOTCH1* have been found in two families with BAV, aortic valve stenosis, aortic valve calcification and other LVOTO anomalies [Garg et al., 2006]. Interestingly one patient with AS and BAV also had ascending aortic dilatation. In both our families *NOTCH1* was excluded as the disease gene by linkage analysis using polymorphic microsatellites (D9S1826, D9S158, D9S1838) flanking the *NOTCH1* gene that showed multiple recombinants in both families. Additionally, sequence analysis of all coding exons and intron–exon boundaries was normal in an affected family member in both families.

Human *NKX2.5* mutations can cause a number of different cardiac phenotypes [McElhinney et al., 2003; Elliott et al., 2003], including ASD/VSD and LVOTO, but anomalies of the semilunar valves, as observed in 17/21 of the patients in our families, are not often described [Majumdar et al., 2006]. A *NKX2.5* mutation was excluded in both our families by mutation analysis in one affected family member. *GATA4* mutations can lead to nonsyndromic ASD and other CVM including PS [Garg et al., 2003], whereas gross deletions of the 8p23 region encompassing the *GATA4* gene are associated with a variety of cardiac anomalies, mainly PS and ASD. However, in contrast to our families left-sided cardiac anomalies are uncommon in these patients, although aortic/mitral regurgitation was reported in 1/18 patient of the families described by Garg et al. [2003]. So far, no good candidate genes have been reported for our families, therefore a genome-wide linkage analyses has been initiated in both families.

Mature valve structures arise from endothelial cells of the endocardial cushions [Lincoln et al., 2004]. The endocardial cushions are formed by endothelial–mesenchymal transdifferentiation of a subset of endothelial cells that invade the extracellular matrix and differentiate into mesenchymal cells [Armstrong and Bischoff, 2004]. Valve leaflets eventually consist of a single endothelial cell layer and a central layer consistent of collagen, elastin, and glycosaminoglycans [Maron and Hutchins, 1974]. The endocardial cushion tissue contributes not only to the formation of valves, but also to the formation of membranous septa [Schroeder et al., 2003]. This might explain why some

TABLE II. Cardiac Valve Anomalies Caused by Gene Defects in Mice

Gene	Cardiac anomaly	References
Wnt/β-Catenin signaling		
Has2	Absence of cardiac jelly/endocardial cushions	Camenisch et al. [2000]
Hdf [Cspg2, versican]	Absence of endocardial cushion swelling	Mjaatvedt et al. [1998]
β-catenin	Lack of heart cushion formation	Liebner et al. [2004]
Notch signaling		
Notch1	Hypoplastic cardiac cushions	Timmerman et al. [2004]
Hesr2	Dysplastic AV valves, ASD, VSD	Kokubo et al. [2004]
Hey 1/HeyL	Dysplastic atrioventricular and pulmonary valves	Fischer et al. [2007]
Hey2	TA, VSD, TOF	Donovan et al. [2002]
EphrinB2	Thickened aortic, pulmonary and mitral valve	Cowan et al. [2004]
Fgf8	Single AV valve, hypoplastic arch arteries, DORV	Abu-Issa et al. [2002]
Ece1/Ece2	Abnormal AV valve formation, truncus arteriosus	Yanagisawa et al. [2000]
Vegf signaling		
Cx45	Endocardial cushion defects	Kumai et al. [2000]
Nfatc1	Absent semilunar valves	Ranger et al. [1998]
Nf1	Hyperplastic valve tissue	Lakkis and Epstein [1998]
Tie 2 (TEK)	Endocardial cushion defects	Puri et al. [1999]
eNos	BAV, AS, ASD, VSD	Lee et al. [2000]
Hhex	AV valve dysplasia	Hallaq et al. [2004]
Bmp-Tgf-β signaling		
Bmpr2	Absent semilunar valves, truncus arteriosus	Delot et al. [2003]
Bmp4	Variable	Winnier et al. [1995]
Bmp6/7	Hypoplastic cardiac cushions	Kim et al. [2001]
Alk3	Hypoplastic cardiac cushions	Gaussin et al. [2002]
Madh6 (Smad6)	Thickened valves	Galvin et al. [2000]
Perlecan (HSPG2)	Malformed semilunar valves, TGA	Costello et al. [2002]
Fibulin-4	Thickened aortic valvular leaflets	Hanada et al. [2007]
Erb signaling		
ErbB1 (Egfr, Her1)	Enlarged thickened semilunar and AV valves	Sibilia et al. [2003], Jackson et al. [2003]
ErbB3 (Her3)	Hypoplastic cardiac cushion	Erickson et al. [1997]
HB-EGF	Enlarged malformed semilunar and AV valves	Yamazaki et al. [2003], Jackson et al. [2003]
Tace (Adam17)	Enlarged semilunar and AV valves	Jackson et al. [2003]
β Meltrin (Adam19)	Immature valves, VSD	Kurohara et al. [2004], Zhou et al. [2004]
Egfr/Ptpn11	Semilunar valve hyperplasia	Chen et al. [2000]
GATA transcription factors		
GATA4	Common AV valve	Crispino et al. [2001]
Fog 1	Common AV valve, DORV	Katz et al. [2003]
Fog 2	TA, PS, AV canal, ASD, VSD, TOF	Svensson et al. [2000], Tevosian et al. [2000]
Nkx2.5	BAV, AS, ASD	Biben et al. [2000]
Pitx2	Enlarged endocardial cushion	Lin et al. [1999]
Sox transcription factors		
Sox4	Semilunar valve defects, truncus arteriosus	Ya et al. [1998]
Sox9	Hypoplastic endocardial cushions	Akiyama et al. [2004]
Fox transcription factors		
Foxp1	Thickened endocardial cushion	Wang et al. [2004]
Foxc1	Valve anomalies, IAA, CoA, VSD	Winnier et al. [1999]
Foxc2	Valve anomalies, IAA, CoA, VSD	Winnier et al. [1999]
Various		
EphA3	Hypoplastic endocardial cushions	Stephen et al. [2007]
Pdgf-a(patch mutation)	Septal and valve defects	Robbins et al. [1999]
Pdgf-b	AV valve malformation, VSD	Van den Akker et al. [2008]
Apoe	Sclerotic, stenotic aortic valves	Tanaka et al. [2005]
Ccn1	Atrioventricular septal defects	Mo and Lau [2006]
Periostin	AV valve abnormalities, ASD	Norris et al. [2008]
Chm1	Thickened, calcified, stenotic aortic valves	Yoshioka et al. [2006]
Cxcr7	Semilunar valve malformation, VSD	Sierro et al. [2007]

AV, atrioventicular; AS, aortic valve stenosis; ASD, atrial septal defect; BAV, bicupid aortic valve; CoA, coarctation of the aorta; DORV, double outlet right ventricle; IAA, interrupted aortic arch; PS, pulmonary
stenosis; TA, tricupid atresia; TGA, transposition of the great arteries; TOF, tetralogy of Fallot; VSD, ventricular septal defect.

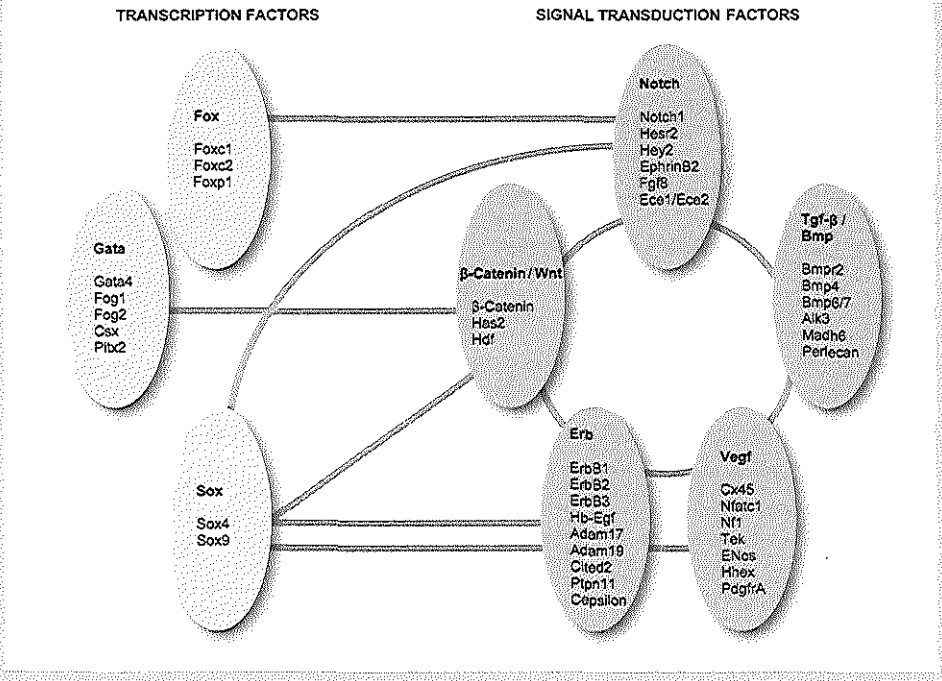

FIG. 2. Molecular pathways and their cross-talking involved in cardiac morphogenesis. [Color figure can be viewed in the online issue, which is available at www.interscience.wiley.com.]

patients in our families have septal defects apart from valve anomalies.

In contrast to the sparse knowledge about the genes involved in human valve formation and malformation much more is known about valvulogenesis in mice. In mice signal transduction pathways including Wnt/β–catenin, Vegf, Notch, Bmp–Tgfβ, and Erb, and transcription factors including different GATA, FOX and SOX transcription factors have been implicated in heart cushion/valve formation (Table II, Fig. 2). These different signaling pathways exhibit extensive cross-talking, resulting in a complex integrated process of cardiac valve morphogenesis [for review: Schroeder et al., 2003; Armstrong and Bischoff, 2004]. These mouse models could provide functional candidate genes for families with cardiac valve anomalies once positional genetics approaches have localized the human disease gene.

The two multiplex families in this report may facilitate identification of human genes specifically involved in cardiac valve morphogenesis and aortic wall disease. The co-occurrence of aortic and pulmonary valve abnormalities and aortic aneurysms in these families supports a common genetic etiology in some forms of left- and right-sided valve anomalies, and expands the phenotype of LVOTO.

REFERENCES

Abu-Issa R, Smyth G, Smoak I, Yamamura K, Meyers E. 2002. Fgf8 is required for pharyngeal arch and cardiovascular development in the mouse. Development 129:4613–4625.

Akiyama H, Chaboissier MC, Behringer RR, Rowitch DH, Schedl A, Epstein JA, de Crombrugghe B. 2004. Essential role of Sox9 in the pathway that controls formation of cardiac valves and septa. Proc Natl Acad Sci USA 101:6502–6507.

Armstrong EJ, Bischoff J. 2004. Heart valve development: Endothelial cell signaling and differentiation. Circ Res 95:459–470.

Biben C, Weber R, Kesteven S, Stanley E, McDonald L, Elliott DA, Barnett L, Koentgen F, Robb L, Feneley M, Harvey RP. 2000. Cardiac septal and valvular dysmorphogenesis in mice heterozygous for mutations in the homeobox gene Nkx 2-5. Circ Res 87:888–895.

Bonnet D, Fermont L, Kachaner J, Sidi D, Amiel J, Lyonnet S, Munnich A. 1999. Tricuspid atresia and conotruncal malformations in five families. J Med Genet 36:349–350.

Bruneau BG. 2008. The developmental genetics of congenital heart disease. Nature 451:943–948.

Camenisch TD, Spicer AP, Brehm-Gibson T, Biesterfeldt J, Augustine ML, Calabro A Jr, Kubalak S, Klewer SE, McDonald JA. 2000. Disruption of hyaluronan synthase-2 abrogates normal cardiac morphogenesis and

hyaluronan-mediated transformation of epithelium to mesenchyme. J Clin Invest 106:349–360.

Chen B, Bronson RT, Klaman LD, Hampton TG, Wang JF, Green PJ, Magnuson T, Douglas PS, Morgan JP, Neel BG. 2000. Mutant for Egfr and Shp2 have defective cardiac semilunar valvulogenesis. Nat Genet 24:296–299.

Chitayat D, McIntosh N, Fouron JC. 1992. Pulmonary atresia with intact ventricular septum and hypoplastic right heart in sibs: A single gene disorder? Am J Med Genet 42:304–306.

Ciuffo AA, Cunningham E, Traill TA. 1985. Familial pulmonary valve stenosis, atrial septal defect, and unique electrocardiogram abnormalities. J Med Genet 22:311–313.

Clementi M, Notari L, Borghi A, Tenconi R. 1996. Familial congenital bicuspid aortic valve: A disorder of uncertain inheritance. Am J Med Genet 62:336–338.

Coblentz B, Mathivat A. 1952. Stenose pulmonaire congenitale chez deux soeurs. Arch Mal Coeur 5:490–495.

Costello M, Carmona R, Gustafsson E, Gonzalez-Iriarte M, Fassler R, Munoz-Chapuli R. 2002. Hyperplastic conotruncal endocardial cushions and transposition of great arteries in perlecan-null mice. Circ Res 91:158–164.

Coucke PJ, Willaert A, Wessels MW, Callewaert B, Zoppi N, De Backer J, Fox JE, Mancini GM, Kambouris M, Gardella R, Facchetti F, Willems PJ, Forsyth R, Dietz HC, Barlati S, Colombi M, Loeys B, De Paepe A. 2006. Mutations in the facilitative glucose transporter GLUT10 alter angiogenesis and cause arterial tortuosity syndrome. Nat Genet 38:452–457.

Cowan CA, Yokoyama N, Saxena A, Chumley MJ, Silvany RE, Baker LA, Srivastava D, Henkemeyer M. 2004. Ephrin-B2 reverse signaling is required for axon pathfinding and cardiac valve formation but not early vascular development. Dev Biol 271:263–271.

Cripe L, Andelfinger G, Martin LJ, Shooner K, Benson DW. 2004. Bicuspid aortic valve is heritable. J Am Coll Cardiol 44:138–143.

Crispino JD, Lodish MB, Thurberg BL, Litovsky SH, Collins T, Molkentin JD, Orkin SH. 2001. Proper coronary vascular development and heart morphogenesis depend on interaction of GATA-4 with FOG cofactors. Genes Dev 15:839–844.

David TJ. 1974. A family with congenital pulmonary valve stenosis. Humangenetik 21:287–288.

Delot EC, Bahamonde ME, Zhao M, Lyons KM. 2003. BMP signaling is required for septation of the outflow tract of the mammalian heart. Development 130:209–220.

DiChiara JA, Pieroni DR, Gingell RL, Bannerman RM, Vlad P. 1980. Familial pulmonary atresia. Its occurrence with a ventricular septal defect. Am J Dis Child 134:506–508.

Donovan J, Kordylewska A, Jan YN, Utset MF. 2002. Tetralogy of fallot and other congenital heart defects in Hey2 mutant mice. Curr Biol 12:1605–1610.

Elliott DA, Kirk EP, Yeoh T, Chandar S, McKenzie F, Taylor P, Grossfeld P, Fatkin D, Jones O, Hayes P, Fenley M, Harvey RP. 2003. Cardiac homeobox gene NKX2-5 mutations and congenital heart disease: Associations with atrial septal defect and hypoplastic left heart syndrome. J Am Coll Cardiol 41:2072–2076.

Ellison JW, Yagubyan M, Majumdar R, Sarkar G, Bolander ME, Atkinson EJ, Sarano ME, Sundt TM. 2007. Evidence of genetic locus heterogeneity for familial bicuspid aortic valve. J Surg Res 142:28–31.

El-Said GM, El-Guindy M, Ibrahim MM, El-Sherif AA. 1979. Familial valvular pulmonic stenosis involving three siblings. Cardiovasc Dis 6:50–54.

Emanuel R, Withers R, O'Brien K, Ross P, Feizi O. 1978. Congenitally bicuspid aortic valves: Clinicogenetic study of 41 families. Br Heart J 40:1402–1407.

Erickson SL, O'Shea KS, Ghaboosi N, Loverro L, Frantz G, Bauer M, Lu LH, Moore MW. 1997. ErbB3 is required for normal cerebellar and cardiac development: A comparison with ErbB2-and heregulin-deficient mice. Development 124:4999–5011.

Eronen M, Peippo M, Hiippala A, Raatikka M, Arvio M, Johansson R, Kahkonen M. 2002. Cardiovascular manifestations in 75 patients with Williams syndrome. J Med Genet 39:554–558.

Fischer A, Steidl C, Wagner TU, Lang E, Jakob PM, Friedl P, Knobeloch KP, Gessler M. 2007. Combined loss of Hey1 and HeyL causes congenital heart defects because of impaired epithelial to mesenchymal transition. Circ Res 100:856–863.

Freed LA, Acierno JS Jr, Dai D, Leyne M, Marshall JE, Nesta F, Levine RA, Slaugenhaupt SA. 2003. A locus for autosomal dominant mitral valve prolapse on chromosome 11p15.4. Am J Hum Genet 72:1551–1559.

Galvin KM, Donovan MJ, Lynch CA, Meyer RI, Paul RJ, Lorenz JN, Fairchild-Huntress V, Dixon KL, Dunmore JH, Gimbrone MA Jr, Falb D, Huszar D. 2000. A role for smad6 in development and homeostasis of the cardiovascular system. Nat Genet 24:171–174.

Garg V, Kathiriya IS, Barnes R, Schluterman MK, King IN, Butler CA, Rothrock CR, Eapen RS, Hirayama-Yamada K, Joo K, Matsuoka R, Cohen JC, Srivastava D. 2003. GATA4 mutations cause human congenital heart defects and reveal an interaction with TBX5. Nature 424:443–447.

Garg V, Muth AN, Ransom JF, Schluterman MK, Barnes R, King IN, Grossfeld PD, Srivastava D. 2006. Mutations in NOTCH1 cause aortic valve disease. Nature 437:270–274.

Gaussin V, Van de Putte T, Mishina Y, Hanks MC, Zwijsen A, Huylebroeck D, Behringer RR, Schneider MD. 2002. Endocardial cushion and myocardial defects after cardiac myocyte-specific conditional deletion of the bone morphogenetic protein receptor ALK3. Proc Natl Acad Sci USA 99:2878–2883.

Gill HK, Splitt M, Sharland GK, Simpson JM. 2003. Patterns of recurrence of congenital heart disease: An analysis of 6,640 consecutive pregnancies evaluated by detailed fetal echocardiography. J Am Coll Cardiol 42:923–929.

Glick BN, Roberts WC. 1994. Congenitally bicuspid aortic valve in multiple family members. Am J Cardiol 73:400–404.

Goh D, Han L, Judge DP, Geutbner J, McIntosh I, Patel A, Thomas G, Basson CT, Milewicz DM, Dietz H. 2002. Linkage of familial bicuspid aortic valve with aortic aneurysm to chromosome15q [abstract 239]. Presented at the annual meeting of the American society of human genetics.

Grant JW. 1996. Congenital malformations of the tricuspid valve in siblings. Pediatr Cardiol 17:327–329.

Grossfeld PD, Lucas VW, Sklansky MS, Kashani IA, Rothman A. 1997. Familial occurrence of pulmonary atresia with intact ventricular septum. Am J Med Genet 72:294–296.

Guo DC, Pannu H, Tran-Fadulu V, Papke CL, Yu RK, Avidan N, Bourgeois S, Estrera AL, Safi HJ, Sparks E, Amor D, Ades L, McConnell V, Willoughby CE, Abuelo D, Willing M, Lewis RA, Kim DH, Scherer S, Tung PP, Ahn C, Buja LM, Raman CS, Shete SS, Milewicz DM. 2007. Mutations in smooth muscle alpha-actin (ACTA2) lead to thoracic aortic aneurysms and dissections. Nat Genet 39:1488–1493.

Hallaq H, Pinter E, Enciso J, McGrath J, Zeiss C, Brueckner M, Madri J, Jacobs HC, Wilson CM, Vasavada H, Jiang X, Bogue CW. 2004. A null mutation of Hhex results in abnormal cardiac development, defective vasculogenesis and elevated Vegfa levels. Development 131:5197–5209.

Hanada K, Vermeij M, Garinis GA, de Waard MC, Kunen MG, Myers L, Maas A, Duncker DJ, Meijers C, Dietz HC, Kanaar R, Essers J. 2007. Perturbations of vascular homeostasis and aortic valve abnormalities in fibulin-4 deficient mice. Circ Res 100:738–746.

Hinton RB Jr, Martin LJ, Tabangin ME, Mazwi ML, Cripe LH, Benson DW. 2007. Hypoplastic left heart syndrome is heritable. J Am Coll Cardiol 50:1590–1595.

Huntington K, Hunter AG, Chan KL. 1997. A prospective study to assess the frequency of familial clustering of congenital bicuspid aortic valve. J Am Coll Cardiol 30:1809–1812.

Jackson LF, Qiu TH, Sunnarborg SW, Chang A, Zhang C, Patterson C, Lee DC. 2003. Defective valvulogenesis in HB-EGF and TACE-null mice is associated with aberrant BMP signaling. EMBO J 22:2704–2716.

Katz SG, Williams A, Yang J, Fujiwara Y, Tsang AP, Epstein JA, Orkin SH. 2003. Endothelial lineage-mediated loss of the GATA cofactor friend of GATA 1 impairs cardiac development. Proc Natl Acad Sci USA 100:14030–14035.

Kim RY, Robertson EJ, Solloway MJ. 2001. Bmp6 and Bmp7 are required for cushion formation and septation in the developing mouse heart. Dev Biol 235:449–466.

Klinge T, Laursen HB. 1975. Familial pulmonary stenosis with underdeveloped or normal right ventricle. Br Heart J 37:60–64.

Kokubo H, Miyagawa-Tomita S, Tomimatsu H, Nakashima Y, Nakazawa M, Saga Y, Johnson RL. 2004. Disruption of hesr2 results in atrioventricular valve anomalies that lead to heart dysfunction. Circ Res 95:540–547.

Krantz ID, Smith R, Colliton RP, Tinkel H, Zackai EH, Piccoli DA, Goldmuntz E, Spinner NB. 1999. Jagged1 mutations in patients ascertained with isolated congenital heart defects. Am J Med Genet 8:56–60.

Kumai M, Nishii K, Nakamura K, Takeda N, Suzuki M, Shibata Y. 2000. Loss of connexin45 causes a cushion defect in early cardiogenesis. Development 127:3501–3512.

Kumar A, Victorica BE, Gessner IH, Alexander JA. 1994. Tricuspid atresia and annular hypoplasia: Report of a familial occurrence. Pediatr Cardiol 15:201–203.

Kurohara K, Komatsu K, Kurisaki T, Masuda A, Irie N, Asano M, Sudo K, Nabeshima Y, Iwakura Y, Sehara-Fujisawa A. 2004. Essential roles of Meltrin beta (ADAM19) in heart development. Dev Biol 267:14–28.

Kyndt F, Schott JJ, Trochu JN, Baranger F, Herbert O, Scott V, Fressinaud E, David A, Moisan JP, Bouhour JB, Le Marec H, Benichou B. 1998. Mapping of X-linked myxomatous valvular dystrophy to chromosome Xq28. Am J Hum Genet 62:627–632.

Kyndt F, Gueffet JP, Probst V, Jaafar P, Legendre A, Le Bouffant F, Toquet C, Roy E, McGregor L, Lynch SA, Newbury-Ecob R, Tran V, Young I, Trochu JN, Le Marec H, Schott JJ. 2007. Mutations in the gene encoding filamin A as a cause for familial cardiac valvular dystrophy. Circulation 115:40–49.

Lakkis MM, Epstein JA. 1998. Neurofibromin modulation of ras activity is required for normal endocardial-mesenchymal transformation in the developing heart. Development 125:4359–4367.

Lamy M, de Grouchy J, Schweisguth O. 1957. Genetic and non-genetic factors in the etiology of congenital heart disease: A study of 1188 cases. Am J Hum Genet 9:17–41.

Lee TC, Zhao YD, Courtman DW, Stewart DJ. 2000. Abnormal aortic valve development in mice lacking endothelial nitric oxide synthase. Circulation 101:2345–2348.

Lewin MB, McBride KL, Pignatelli R, Fernbach S, Combes A, Menesses A, Lam W, Bezold LI, Kaplan N, Towbin JA, Belmont JW. 2004. Echocardiographic evaluation of asymptomatic parental and sibling cardiovascular anomalies associated with congenital left ventricular outflow tract lesions. Pediatrics 114:691–696.

Liebner S, Cattelino A, Gallini R, Rudini N, Iurlaro M, Piccolo S, Dejana E. 2004. Catenin is required for endothelial-mesenchymal transformation during heart cushion development in the mouse. J Cell Biol 166:359–367.

Lin AE, Rosti L. 1998. Tricuspid atresia in sibs. J Med Genet 35:1055–1056.

Lin CR, Kioussi C, O'Connell S, Briata P, Szeto D, Liu F, Izpisua-Belmonte JC, Rosenfeld MG. 1999. Pitx2 regulates lung asymmetry, cardiac positioning, and pituitary and tooth morphogenesis. Nature 401:279–282.

Lincoln J, Alfieri CM, Yutzey KE. 2004. Development of heart valve leaflets and supporting apparatus in chicken and mouse embryos. Dev Dyn 230:239–250.

Loeys BL, Chen J, Neptune ER, Judge DP, Podowski M, Holm T, Meyers J, Leitch CC, Katsanis N, Sharifi N, Xu FL, Myers LA, Spevak PJ, Cameron DE, Backer JD, Hellemans J, Chen Y, Davis EC, Webb CL, Kress W, Coucke P, Rifkin DB, De Paepe AM, Dietz HC. 2005. A syndrome of altered cardiovascular,craniofacial, neurocognitive and skeletal development caused by mutations in TGFBR1 or TGFBR2. Nat Genet 37:275–281.

Loffredo CA. 2000. Epidemiology of cardiovascular malformations: Prevalence and risk factors. Am J Med Genet 97:319–325.

Loscalzo ML, Goh DL, Loeys B, Kent KC, Spevak PJ, Dietz HC. 2007. Familial thoracic aortic dilation and bicommissural aortic valve: A prospective analysis of natural history and inheritance. Am J Med Genet A 143A:1960–1967.

Majumdar R, Yagubyan M, Sarkar G, Bolander ME, Sundt TM III. 2006. Bicuspid aortic valve and ascending aortic aneurysm are not associated with germline or somatic homeobox NKX2-5 gene polymorphism in 19 patients. J Thorac Cardiovasc Surg 131:1301–1305.

Maron BJ, Hutchins GM. 1974. The development of the semilunar valves in the human heart. Am J Pathol 74:331–344.

Martin LJ, Ramachandran V, Cripe LH, Hinton RB, Andelfinger G, Tabangin M, Shooner K, Keddache M, Benson DW. 2007. Evidence in favor of linkage to human chromosomal regions 18q, 5q and 13q for bicuspid aortic valve and associated cardiovascular malformations. Hum Genet 121:275–284.

McBride KL, Pignatelli R, Lewin M, Ho T, Fernbach S, Menesses A, Lam W, Leal SM, Kaplan N, Schliekelman P, Towbin JA, Belmont JW. 2005. Inheritance analysis of congenital left ventricular outflow tract obstruction malformations: Segregation, multiplex relative risk, and heritability. Am J Med Genet 134:180–186.

McCarron WE, Perloff JK. 1974. Familial congenital valvular pulmonic stenosis. Am Heart J 88:357–359.

McDaniell R, Warthen DM, Sanchez-Lara PA, Pai A, Krantz ID, Piccoli DA, Spinner NB. 2006. NOTCH2 mutations cause Alagille syndrome, a heterogeneous disorder of the notch signaling pathway. Am J Hum Genet 79:169–173.

McDonald K, Maurer BJ. 1989. Familial aortic valve disease: Evidence for a genetic influence? Eur Heart J 10:676–677.

McElhinney DB, Krantz ID, Bason L, Piccoli DA, Emerick KM, Spinner NB, Goldmuntz E. 2002. Analysis of cardiovascular phenotype and genotype-phenotype correlation in individuals with a JAG1 mutation and/or Alagille syndrome. Circulation 106:2567–2574.

McElhinney DB, Geiger E, Blinder J, Benson DW, Goldmuntz E. 2003. NKX2.5 mutations in patients with congenital heart disease. J Am Coll Cardiol 42:1650–1655.

Menahem S. 1990. Familial aggregation of defects of the left-sided structures of the heart. Int J Cardiol 29:239–240.

Metcalfe K, Rucka AK, Smoot L, Hofstadler G, Tuzler G, McKeown P, Siu V, Rauch A, Dean J, Dennis N, Ellis I, Reardon W, Cytrynbaum C, Osborne L, Yates JR, Read AP, Donnai D, Tassabehji M. 2000. Elastin: Mutational spectrum in supravalvular aortic stenosis. Eur J Hum Genet 8:955–963.

Mjaatvedt CH, Yamamura H, Capehart AA, Turner D, Markwald RR. 1998. The Cspg2 gene, disrupted in the hdf mutant, is required for right cardiac chamber and endocardial cushion formation. Dev Biol 202:56–66.

Mo FE, Lau LF. 2006. The matricellular protein CCN1 is essential for cardiac development. Circ Res 99:961–969.

Neptune ER, Frischmeyer PA, Arking DE, Myers L, Bunton TE, Gayraud B, Ramirez F, Sakai LY, Dietz HC. 2003. Dysregulation of tgf-[beta] activation contributes to pathogenesis in Marfan syndrome. Nat Genet 33:407–411.

Nesta F, Leyne M, Yosefy C, Simpson C, Dai D, Marshall JE, Hung J, Slaugenhaupt SA, Levine RA. 2005. New locus for autosomal dominant mitral valve prolapse on chromosome 13: Clinical insights from genetic studies. Circulation 112:2022–2030.

Newbury-Ecob RA, Zuccollo JM, Rutter N, Young ID. 1993. Sex linked valvular dysplasia. J Med Genet 30:873–874.

Norris RA, Moreno-Rodriguez RA, Sugi Y, Hoffman S, Amos J, Hart MM, Potts JD, Goodwin RL, Markwald RR. 2008. Periostin regulates atrioventricular valve maturation. Dev Biol 316:200–213.

Puri MC, Partanen J, Rossant J, Bernstein A. 1999. Interaction of the TEK and TIE receptor tyrosine kinases during cardiovascular development. Development 126:4569–4580.

Ranger AM, Grusby MJ, Hodge MR, Gravallese EM, de la Brousse FC, Hoey T, Mickanin C, Baldwin HS, Glimcher LH. 1998. The transcription factor NF-ATc is essential for cardiac valve formation. Nature 392:186–190.

Ransom J, Srivastava D. 2007. The genetics of cardiac birth defects. Semin Cell Dev Biol 18:132–139.

Rao SS, Gootman N, Platt N. 1969. Familial aortic atresia. Report of a case of aortic atresia in siblings. Am J Dis Child 118:919–922.

Robbins JR, McGuire PG, Wehrle-Haller B, Rogers SL. 1999. Diminished matrix metalloproteinase 2 (MMP-2) in ectomesenchyme-derived tissues of the Patch mutant mouse: Regulation of MMP-2 by PDGF and effects on mesenchymal cell migration. Dev Biol 212:255–263.

Robinson SW, Morris CD, Goldmuntz E, Reller MD, Jones MA, Steiner RD, Maslen CL. 2003. Missense mutations in CRELD1 are associated with cardiac atrioventricular septal defects. Am J Hum Genet 72:1047–1052.

Sarkozy A, Conti E, Esposito G, Pizzuti A, Dallapiccola B, Mingarelli R, Marino B, Digilio MC, Paoletti V. 2003. Nonsyndromic pulmonary valve stenosis and the PTPN11 gene. Am J Med Genet A 116A:389–390.

Schroeder JA, Jackson LF, Lee DC, Camenisch TD. 2003. Form and function of developing heart valves: Coordination by extracellular matrix and growth factor signaling. J Mol Med 81:392–403.

Schunkert H, Brockel U, Kromer EP, Elsner D, Jacob HJ, Riegger GA. 1997. A large pedigree with valvuloseptal defects. Am J Cardiol 80:968–970.

Sibilia M, Wagner B, Hoebertz A, Elliott C, Marino S, Jochum W, Wagner EF. 2003. Mice humanized for the EGF receptor display hypomorphic phenotypes in skin, bone and heart. Development 130:4515–4525.

Sierro F, Biben C, Martinez-Munoz L, Mellado M, Ransohoff RM, Li M, Woehl B, Leung H, Groom J, Batten M, Harvey RP, Martinez AC, Mackay CR, Mackay F. 2007. Disrupted cardiac development but normal hematopoiesis in mice deficient in the second CXCL12/SDF-1 receptor, CXCR7. Proc Natl Acad Sci USA 104:14759–14764.

Stephen LJ, Fawkes AL, Verhoeve A, Lemke G, Brown A. 2007. A critical role for the EphA3 receptor tyrosine kinase in heart development. Dev Biol 302:66–79.

Svensson EC, Huggins GS, Lin H, Clendenin C, Jiang F, Tufts R, Dardik FB, Leiden JM. 2000. A syndrome of tricuspid atresia in mice with a targeted mutation of the gene encoding Fog-2. Nature Genet 25:353–356.

Sznajer Y, Keren B, Baumann C, Pereira S, Alberti C, Elion J, Cave H, Verloes A. 2007. The spectrum of cardiac anomalies in Noonan syndrome as a result of mutations in the PTPN11 gene. Pediatrics 119:1325–1331.

Tanaka K, Sata M, Fukuda D, Suematsu Y, Motomura N, Takamoto S, Hirata Y, Nagai R. 2005. Age-associated aortic stenosis in apolipoprotein E-deficient mice. J Am Coll Cardiol 46:134–141.

Tevosian SG, Deconinck AE, Tanaka M, Schinke M, Litovsky SH, Izumo S, Fujiwara Y, Orkin SH. 2000. FOG-2, a cofactor for GATA transcription factors, is essential for heart morphogenesis and development of coronary vessels from epicardium. Cell 101:729–739.

Timmerman LA, Grego-Bessa J, Raya A, Bertran E, Perez-Pomares JM, Diez J, Aranda S, Palomo S, McCormick F, Izpisua-Belmonte JC, de la Pompa JL. 2004. Notch promotes epithelial-mesenchymal transition during cardiac development and oncogenic transformation. Genes Dev 18:99–115.

Udwadia AD, Khambadkone S, Bharucha BA, Lokhandwala Y, Irani SF. 1996. Familial congenital valvar pulmonary stenosis: Autosomal dominant inheritance. Pediatr Cardiol 17:407–409.

Van den Akker NM, Winkel LC, Nisancioglu MH, Maas S, Wisse LJ, Armulik A, Poelmann RE, Lie-Venema H, Betsholtz C, Gittenberger-de Groot AC. 2008. PDGF-B signaling is important for murine cardiac development: Its role in developing atrioventricular valves, coronaries, and cardiac innervation. Dev Dyn 237:494–503.

Wang B, Weidenfeld J, Lu MM, Maika S, Kuziel WA, Morrisey EE, Tucker PW. 2004. Foxp1 regulates cardiac outflow tract, endocardial cushion morphogenesis and myocyte proliferation and maturation. Development 131:4477–4487.

Weismann CG, Gelb BD. 2007. The genetics of congenital heart disease: A review of recent developments. Curr Opin Cardiol 22:200–206.

Wessels MW, Berger RM, Frohn-Mulder IM, Roos-Hesselink JW, Hoogeboom JJ, Mancini GS, Bartelings MM, Krijger RD, Wladimiroff JW, Niermeijer MF, Grossfeld P, Willems PJ. 2005. Autosomal dominant inheritance of left ventricular outflow tract obstruction. Am J Med Genet A 134A:171–179.

Winnier G, Blessing M, Labosky PA, Hogan BL. 1995. Bone morphogenetic protein-4 is required for mesoderm formation and patterning in the mouse. Genes Dev 9:2105–2116.

Winnier GE, Kume T, Deng K, Rogers R, Bundy J, Raines C, Walter MA, Hogan BL, Conway SJ. 1999. Roles for the winged helix transcription factors MF1 and MFH1 in cardiovascular development revealed by nonallelic noncomplementation of null alleles. Dev Biol 213:418–443.

Ya J, Schilham MW, de Boer PA, Moorman AF, Clevers H, Lamers WH. 1998. Sox4-deficiency syndrome in mice is an animal model for common trunk. Circ Res 83:986–994.

Yamazaki S, Iwamoto R, Saeki K, Asakura M, Takashima S, Yamazaki A, Kimura R, Mizushima H, Moribe H, Higashiyama S, Endoh M, Kaneda Y, Takagi S, Itami S, Takeda N, Yamada G, Mekada E. 2003. Mice with defects in HB-EGF ectodomain shedding show severe developmental abnormalities. J Cell Biol 163:469–475.

Yanagisawa H, Hammer RE, Richardson JA, Emoto N, Williams SC, Takeda S, Clouthier DE, Yanagisawa M. 2000. Disruption of ECE-1 and ECE-2 reveals a role for endothelin-converting enzyme-2 in murine cardiac development. J Clin Invest 105:1373–1382.

Yoshioka M, Yuasa S, Matsumura K, Kimura K, Shiomi T, Kimura N, Shukunami C, Okada Y, Mukai M, Shin H, Yozu R, Sata M, Ogawa S, Hiraki Y, Fukuda K. 2006. Chondromodulin-I maintains cardiac valvular function by preventing angiogenesis. Nat Med 12:1151–1159.

Zhou HM, Weskamp G, Chesneau V, Sahin U, Vortkamp A, Horiuchi K, Chiusaroli R, Hahn R, Wilkes D, Fisher P, Baron R, Manova K, Basson CT, Hempstead B, Blobel CP. 2004. Essential role for ADAM19 in cardiovascular morphogenesis. Mol Cell Biol 24:96–104.



CHAPTER 4

Arterial malformations

4.1 Introduction

4.1.1 Syndromic aortic aneurysms

4.1.1.1 Marfan syndrome
4.1.1.2 Loeys-Dietz syndromes
4.1.1.3 Ehlers-Danlos syndromes
4.1.1.4 Cutis laxa
4.1.1.5 Arterial tortuosity syndrome
4.1.1.6 Other syndromes associated with aortic aneurysm

4.1.2 Non-syndromic aortic aneurysms

4.1.2.1 Familial thoracic aortic aneurysms
4.1.2.2 Familial thoracic aortic aneurysms with bicuspid aortic valve and LVOTO
4.1.2.3 Familial abdominal aortic aneurysms

4.2 Three new families with arterial tortuosity syndrome

Wessels MW, Catsman-Berrevoets CE, Mancini GM, Breuning MH, Hoogeboom JJ, Stroink H, Frohn-Mulder I, Coucke PJ, Paepe AD, Niermeijer MF, Willems PJ
Am J Med Genet 2004; 131A: 134-143

4.3 Homozygosity mapping of a gene for arterial tortuosity syndrome to chromosome 20q13

Coucke PJ, **Wessels MW**, Van Acker P, Gardella R, Barlati S, Willems PJ, Colombi M, De Paepe A
J Med Genet 2003; 40: 747-751

4.4 Mutations in the facilitative glucose transporter GLUT10 alter angiogenesis and cause arterial tortuosity syndrome

Coucke PJ, Willaert A, **Wessels MW**, Callewaert B, Zoppi N, De Backer J, Fox JE, Mancini GM, Kambouris M, Gardella R, Facchetti F, Willems PJ, Forsyth R, Dietz HC, Barlati S, Colombi M, Loeys B, De Paepe A
Nat Genet 2006; 38: 452-457

CHAPTER 4

Arterial malformations

4.1 Introduction

During the past decade genetic studies of the cardiovascular system in syndromes such as Marfan syndrome (*FBN1* gene encoding fibrillin) [1], Loeys-Dietz syndrome (*TGFBR1/2* genes encoding TGFβ receptors 1 and 2) [2-4], Ehlers-Danlos syndrome (*COL3A1* gene encoding collagen 3 and *FLNA* gene encoding Filamin A) [5,6] and arterial tortuosity syndrome (*SLC2A10* gene encoding GLUT10) [7,8] have provided insights into the pathogenesis of arterial aneurysms (Tables 1 and 2). The TGFβ signaling pathway plays a central role in the pathogenesis of many of these aortic wall disorders, making this pathway the primary pharmacological target for the development of new treatment strategies for arterial wall disorders [9,10]. Apart from the TGFβ signaling pathway also sarcomeric protein genes of smooth muscle cells have been implicated in familial aortic aneurysm, as mutations in the *MYH11* gene encoding smooth muscle cell myosin heavy chain and in the *ACTA2* gene encoding smooth muscle cell α-actin have been identified in familial thoracic aortic aneurysm/dissection (TAAD) [11,12]. These 2 pathways seem to interact as treatment of cardiomyocytes with TGFβ1 leads to increased expression of sarcomeric proteins [13].

4.1.1 Syndromic aortic aneurysms

4.1.1.1 Marfan syndrome

Marfan syndrome is the "classical" arterial aneurysm syndrome with a prevalence of 1 per 5,000. The aneurysms located in the ascending aorta are caused by cystic medial degeneration due to mutations in the fibrillin-1 (*FBN1*) gene located on chromosome 15q. Fibrillin-1 is a large 350-kDa glycoprotein that is a major component of the microfibrils that make up the elastic fiber. It has a repetitive domain structure containing calcium-binding motifs (epidermal growth factor precursor-like) and motifs that bind to TGFβ, thereby linking fibrillin to the TGFβ pathway. Fibrillin-1 is thought to play a role in the TGFβ signaling cascade via its interaction with latent TGFβ-binding protein (LTBP). LTBP binds TGFβ via an LTBP-associated protein (LAP), forming what is known as the large latent complex [14]. Mutations in *FBN1* likely disrupt the targeting and sequestration of the large latent complex due to an inability of LTBP to bind to the microfibrils. The increased level of available TGFβ leads to an increase in TGFβ activity, which is responsible for the development of symptoms. These mutations result in both a decrease in the amount of elastin in the aortic wall and a loss of elastin's normally highly organized structure. As a consequence, the aorta exhibits markedly abnormal elastic properties leading to progressive increases in stiffness and dilatation [15].

Apart from Marfan syndrome, *FBN1* mutations may also result in a wide range of overlapping clinical entities, including MASS (mitral valve, aorta, skeleton, and skin) syndrome, isolated ectopia lentis, Weill-Marchesani syndrome, Shprintzen-Goldberg syndrome, and familial aortic aneurysms. Many excellent reviews of Marfan syndrome have been published [1,16-18].

4.1.1.2 Loeys-Dietz syndromes

Loeys–Dietz syndrome type 1 is characterized by the triad of hypertelorism, bifid uvula / cleft palate, and generalized arterial anomalies including tortuosity, aneurysm and dissection. Affected patients have a high risk of aortic dissection or rupture at an early age in childhood [19,20]. Histological studies of the aortic wall reveal loss of the elastin content and disarray of elastic fibers, along with increased collagen deposition. Loeys-Dietz syndrome type 2 also has generalized arterial anomalies but less facial features, similar to Ehlers-Danlos syndrome type IV. Both Loeys-Dietz syndromes are due to autosomal dominant inactivating mutations in the *TGFBR1* and *TGFBR2* genes encoding receptors 1 and 2 for transforming growth factor beta. These inactivating mutations lead to a paradoxal upregulation of the TGFβ pathway.

TGFBR1 and *TGFBR2* mutations have been found to cause a large spectrum of genetic disorders, including Loeys-Dietz syndrome type 1, Loeys-Dietz syndrome type 2, some patients with Marfan-like syndrome (Marfan syndrome type 2) and Ehlers-Danlos syndrome type 4 [2-4], and a minority of patients with non-syndromic familial TAAD [21,22].

4.1.1.3 Ehlers-Danlos syndromes

Ehlers-Danlos syndrome type IV (vascular type)

The vascular type of Ehlers-Danlos syndrome, EDS type 4, is an autosomal dominant condition characterized by extreme fragility of skin, blood vessels, intestine, gravid uterus, and lungs. Visceral rupture, easy bruising, wide and atrophic scars, joint laxity, and translucent skin characterize the phenotype. Vascular complications include aneurysm and/or dissection of major or minor arteries. The sites of arterial rupture are throughout the vascular tree, including arteries in the thorax and abdomen, head and neck and extremities. EDS 4 can be caused by mutations in the *COL3A1* gene that affect the integrity and/or synthesis of the precursor procollagen molecules of type 3 collagen. Approximately 5-10% of FAA families without obvious Ehlers-Danlos syndrome exhibit linkage to the *COL3A1* gene, and might exhibit a *COL3A1* mutation [22]. Some patients with EDS 4 have *TGFBR1* or *TGFBR2* mutations: these patients are sometimes referred to as Loeys-Dietz syndrome type 2, although few symptoms of the typical Loeys-Dietz syndrome type 1 are present.

Ehlers-Danlos syndrome type 6 (kyphoscoliotic type)

Ehlers-Danlos syndrome type 6 (kyphoscoliotic form) is characterized by abnormal skin (hyperextensibility, scars, easy bruising), joint laxity, muscle hypotonia, progressive scoliosis, glaucoma, retinal detachment and increased risk of rupture of the globe, and aortic dilation [23,24]. Patients are at risk for aortic

dissection and rupture of medium-sized arteries [23]. Ehlers-Danlos syndrome type 6 is caused by deficient activity of the procollagen-lysine, 2-oxoglutarate 5-dioxygenase 1 (lysyl hydroxylase 1) enzyme due to mutations in the *PLOD1* gene.

Ehlers-Danlos syndrome with nodular heterotopia

Periventricular heterotopia with Ehlers-Danlos syndrome is an X-linked condition, which is lethal in most males in the prenatal or neonatal period. Affected females exhibit nodular brain heterotopia and an Ehlers-Danlos-like syndrome characterized by joint hypermobility, hyperextensible skin, high palate, subarachnoid hemorrhage, visceral hernia, and vascular anomalies: the latter include aortic dilatation and aneurysm, patent ductus arteriosus (PDA), and bicuspid aortic valve (BAV) can be present [5,25]. The disorder is caused by loss-of-function mutations in the X-linked *FLNA* gene encoding filamin A, an actin-binding protein involved in cytoskeletal organization.

4.1.1.4 Cutis laxa

Cutis laxa is a condition characterized by redundant, pendulous, and inelastic skin. It is genetically heterogeneous, and mutations have been found in the *ELN* gene encoding elastin (autosomal dominant cutis laxa), the *ATP7A* gene encoding Cu-transporting ATPase (X-linked cutis laxa, Ehlers-Danlos syndrome type 9, Occipital horn syndrome), the *FBLN4* gene encoding Fibulin 4 (autosomal recessive cutis laxa), and the *FBLN5* gene encoding Fibulin 5 (autosomal recessive and autosomal dominant cutis laxa) [26,27]. Vascular tortuosity and aneurysm can be present in all forms, but is most prevalent in patients with *FBLN4* or *FBLN5* mutations [28]. The corresponding fibulins are essential in elastic fiber formation in connective tissue. Transgenic Fibulin 4-deficient mice show aortic aneurysm and dissection, arterial tortuosity, and aortic valve anomalies with disturbed TGFβ signaling [29].

4.1.1.5 Arterial tortuosity syndrome

Arterial tortuosity syndrome (ATS) is a rare autosomal recessive disorder characterized by tortuosity, elongation, stenosis and aneurysm formation of the major arteries, due to disruption of elastic fibers in the medial layer of the arterial wall [7]. Non-vascular abnormalities include arachnodactyly, joint laxity or contractures, micro-rethrognathia, hypertelorism, cleft palate and/or bifid uvula. These clinical findings are reminiscent of Loeys-Dietz syndrome. Further studies have shown that tortuosity of large and middle-sized arteries is present in all patients, but other aortic abnormalities also occur including aortic root dilation, localized arterial stenosis, and long stenotic arterial stretches [30,31]. The prognosis of ATS may be more favorable than reported before as milder cases may have been underdiagnosed [31].
In this thesis clinical and molecular studies of ATS patients are described. We first reported the clinical features in three consanguineous multiplex families with 11 affected ATS patients, and reviewed the literature on ATS [7]. Using our largest consanguineous multiplex ATS family a genome-wide screen with homozygosity mapping was then performed, and linkage of the ATS gene to chromosome 20q13 was found [32]. Further narrowing of the candidate region to a 1.2 Mb region containing 7 genes, let to the

identification of the disease gene: Mutations in 6 ATS families were found in one of these genes, the *SLC2A10* gene encoding the facilitative glucose transporter GLUT10 [8]. Although fragmented elastic fibers were observed in some areas of aortic wall in ATS patients, the predominant observation in mutant mice with missense mutations in *SLC2A10* was elastic fiber proliferations including both thickened and increased elastic fibers in the lamina interna, lamina media and adventitia of middle size arteries [33]. In older mice deranged elastic fibers and disruption of internal elastic lamina was seen in some areas of the aortic wall. This raises the question whether the long stenotic stretches of the aorta that are observed in some ATS patients might be due to elastic fiber proliferations [31]. No arterial tortuosity, aneurysms, or arterial stenosis was observed in these mice, possibly due to the milder missense mutations versus nonsense mutations in ATS patients. GLUT10 deficiency was found to be associated with upregulation of TGFß signaling in the arterial wall of ATS patients, a finding also observed in Loeys-Dietz syndrome, which also presents with aortic aneurysms and arterial tortuosity. The precise interaction between GLUT10, a glucose transporter and the TGFβ signaling pathway remains elusive (Figure 1).

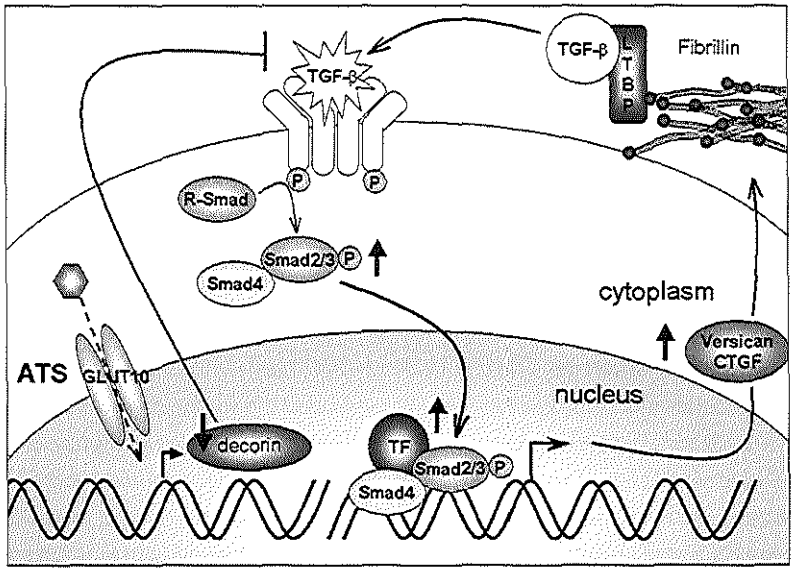

Figure 1 | Possible link between GLUT10 and the TGFβ signaling pathway
In ATS patients with a loss-of-function mutation in *SLC2A10* leading to GLUT10 deficiency decorin expression is decreased and versican expression is increased. Normally glucose is transported into the smooth muscle cell nucleus by GLUT10, activating decorin transcription by binding to a response element in its promotor. Decorin then binds to and inactivates TGFβ extracellularly, attenuating signaling via the TGFβ-Smad pathway. Loss of GLUT10 may reduce nuclear glucose levels resulting in a decreased expression of decorin and upregulation of the TGFβ-Smad pathway by loss of inhibition. As a result versican expression is increased, which might inhibit elastic fiber assembly.
With permission of Prof.Dr.Ing.Paul Coucke

4.1.1.6 Other syndromes associated with aortic aneurysm

Congenital contractural arachnodactyly (CCA) or Beals syndrome is an autosomal dominant connective tissue disorder, comprising marfanoid habitus, flexion contractures, severe kyphoscoliosis, abnormal pinnae, and muscular hypoplasia. CCA is caused by mutations in the *FBN2* gene encoding fibrillin-2. Only in severe CCA cases there exists aortic root dilatation and sometimes even interrupted aortic arch. Autosomal dominant Polycystic Kidney Disease (APKD) is characterised by bilateral renal cysts, and usually also cysts in other organs including the liver and pancreas. Intracranial aneurysms, dilatation and dissection of the aortic root, and mitral valve prolapse might also be present [34]. APKD is caused by mutations in the *PKD1* gene encoding polycystin-1 or in the *PKD2* gene encoding polycystin-2.
In approximately 50 % of patients with Turner syndrome MRI angiography shows elongation of the transverse aorta with kinking in the juxta-ductus region (pseudo-coarctation) [35,36]. Aorta aneurysm is seen in up to 30 % of Turner syndrome patients [37], and the risk is higher in Turner patients with CHM, such as bicuspid aortic valve (BAV) and coarctation of the aorta [38].
Another disease associated with aortic aneurysm is fibromuscular dysplasia (FMD), which can occur as a familial trait. It is characterized by medial hyperplasia of the middle sized arteries, leading to "string-of-beads' stenotic arterial appearances, predominantly in the renal and internal carotic arteries [39].

4.1.2 Non-syndromic aortic aneurysms

Aortic aneurysms represent a common vascular condition with life-threatening implications, and a leading cause of morbidity and mortality [40]. The mortality following rupture of an aortic aneurysm exceeds 75%. Overall, abdominal aortic aneurysms (AAA) are more frequent than thoracic aortic aneurysms (TAA), with the most common location of aortic aneurysm being the infrarenal abdominal aorta, followed by the ascending thoracic aorta. Familial inherited aneurysm are most often TAA located in the ascending aorta (60%), followed by aneurysms of the descending aorta (40%) [15]. TAA have a higher mortality rate (97%) than AAA, genetic factors play a more important role in their pathogenesis, and they are more often caused by monogenic mutations than AAA.

4.1.2.1 Familial thoracic aortic aneurysms

Overall, 15% to 20% of thoracic aortic aneurysm (TAA) and/or aortic dissection (AD) cases (also referred to as TAAD) may be familial [41,42]. Non-syndromic familial TAAD is genetically heterogeneous. Five loci with 3 genes have been identified: these include AAT1 at chromosome 11q23.2-q24 [43], AAT2 at 5q13-q14 [44], AAT3 at 3p25-p24 (*TGFBR2* gene) [2], AAT4 at 16p13 (*MYH11* gene) [11] and AAT6 at 10q22-q24 (*ACTA2* gene) [12]. Some families are not linked to these loci thereby indicating that additional loci for TAA must exist [43-48]. A subset of patients with an *ACTA2* or *MYH11* mutation also presents with PDA. *ACTA2* mutations may additionally lead to BAV. Although classified under non-syndromic TAAD, patients with *ACTA2* mutations sometimes show additional clinical features such as livido reticularis and iris flocculi.

4.1.2.2 Familial thoracic aortic aneurysms with bicuspid aortic valve and LVOTO

TAA can be present in families with left ventricular outflow tract obstruction (LVOTO) anomalies, including BAV [49,50]. Also, aortic dilatation is found in approximately 50% of patients with BAV [15,51]. *NOTCH1* mutations are found in a small subset of patients with LVOTO anomalies [52]. In this thesis we performed linkage analysis in two large families with LVOTO anomalies (including TAA in several family members) and excluded *NOTCH1* as the disease gene, indicating that other genes contribute to this spectrum of CHM [50].

4.1.2.3 Familial abdominal aortic aneurysm

Genetic studies of abdominal aortic aneurysm (AAA) indicate that approximately 15% of the patients with AAA have a positive family history for AAA. This fraction may be higher when more complete screening of family members would be performed. Familial AAA can present as a syndromic disorder such as Marfan, Ehlers-Danlos or Loeys-Dietz syndrome, as described above (Table 2). In these syndromes aneurysms are not only present in the thoracic aorta but also in the abdominal aorta. Familial AAA can also be non-syndromic, and a few families with autosomal dominant and recessive AAA have been described. Different loci for AAA have been identified through genome wide association studies, including loci on chromosome 19q13 (AAA1) [53], 4q31 (AAA2) [53] and 9p21 (AAA3) [54] (Table 1). The AAT1 locus on chromosome 11q23-q24 not only causes TAA but also AAA [43]. No disease gene for AAA has been identified yet.

Table 1 | Syndromic and non-syndromic forms of familial aortic aneurysms

Familial aneurysm	Inheritance	Locus	Gene
Syndromic forms			
Marfan syndrome	AD	15q21	*FBN1*
Loeys-Dietz syndrome type 1	AD	9q33 3p22	*TGFBR1* *TGFBR2*
Loeys-Dietz syndrome type 2 (Ehlers-Danlos syndrome type 4)	AD	9q33 3p22	*TGFBR1* *TGFBR2*
Ehlers-Danlos syndrome type 4	AD	2q31	*COL3A1*
Ehlers-Danlos syndrome type 6 (Kyphoscoliotic type)	AR	1p36	*PLOD1*
Ehlers-Danlos syndrome with periventricular nodular heterotopia	X-linked	Xq28	*FLNA*
Cutis laxa syndrome	AR AR	11q13 14q32	*FBLN4* *FBLN5*
Arterial tortuosity syndrome	AR	20q13	*SLC2A10*
Non-syndromic forms			
Familial thoracic aortic aneurysm/dissection (TAAD)	AD AD AD AD AD	11q23 (AAT1) 5q13 (AAT2) 3p22 (AAT3) 10q22 (AAT6) 9q33	 *TGFBR2* *ACTA2* *TGFBR1*
Thoracic aortic aneurysm with PDA	AD	16p13 (AAT4)	*MYH11*
Familial LVOTO with TAA	AD	9q34	*NOTCH1*
Abdominal aortic aneurysm (AAA)	AD AD AD AD AR	19q13 (AAA1) 4q31 (AAA2) 9p21 (AAA3) 11q23 (AAT1) ?	

Table 2 | Discriminating features in familial aortic aneurysms

	Marfan	LDS1	LDS2	EDS4	EDS6
Features	***FBN1***	***TGFBR1-2***	***TGFBR1-2***	***COL3A1***	***PLOD1***
Cardiovascular					
Aorticrootaneurysm/dissection	+++	+++	+	+	+
Other aneurysm/dissection	+/–	+++	++	++	+
Arterial tortuosity	–	+++	+		
Arterial stenosis/occlusion	–	–	–	–	–
ASD	–	++			–
PDA	–	++			–
BAV	–	+		–	–
Craniofacial					
Hypertelorism	–	+++	–	–	–
Bifid uvula/cleft palate	–	++	+/–	–	–
Micro-retrognathia	++	+++		–	–
Eye					
Myopia	+++	+		–	+
Ectopia lentis	+++	–	–	–	–
Skin/joints					
Velvet skin	–	++	+	+	++
Skin laxity	–	+	+	+	++
Dystrophic scars	–	++	+	+	++
Inguinal hernia	++	++	+	+	+
Joint laxity	++	++	++	+	+
Arachnodactyly	+++	++		–	
Contractures	+/–	++		+	+
Other					
Visceral rupture/perforation	–	+	+	++	
Developmental delay	–	+		–	
Other		Craniosynostosis			

Open space indicates that the feature was not scored.
LDS, Loeys-Dietz Syndrome; LR, Livedo Reticularis; ASD, Atrial Septal defect; PDA: Patent Ductus Arteriosus; BAV, Bicuspid Aortic Valve

	EDS with heterotopia	Cutis laxa	ATS	TAA with PDA	TAA
Features	***FLNA***	***FBLN4-5***	***SCL2A10***	***MYH11***	***ACTA2***
Cardiovascular					
Aorticrootaneurysm/dissection	+	+	+	+	+
Other aneurysm/dissection	+	+	+	–	–
Arterial tortuosity	–	++	+++	–	–
Arterial stenosis/occlusion	–	+	+	–	–
ASD	–	–	–	–	–
PDA	+	–	–	+	+
BAV	+	–	–	–	+
Craniofacial					
Hypertelorism	+	–	++	–	–
Bifid uvula/cleft palate	–	–	+	–	–
Micro-retrognathia	+	–	+	–	–
Eye					
Myopia	–	–	+	–	–
Ectopia lentis	–	–	–	–	–
Skin/joints					
Velvet skin	+	+	++	–	–
Skin laxity	+	+	++	–	–
Dystrophic scars	+	–	–	–	–
Inguinal hernia	+	+	++	–	–
Joint laxity	+	+	++	–	–
Arachnodactyly	–	+	+	–	–
Contractures	–	–	+	–	–
Other					
Visceral rupture/perforation	–	–?	–	–	–
Developmental delay	+/–	–?	–	–	–
Other	Seizures	Emphysema			Iris flocculi, LR

References

1. Judge DP, Dietz HC. 2005. Marfan's syndrome. Lancet 366:1965-1976.
2. Loeys BL, Schwarze U, Holm T, Callewaert BL, Thomas GH, Pannu H, De Backer JF, Oswald GL, Symoens S, Manouvrier S, Roberts AE, Faravelli F, Greco MA, Pyeritz RE, Milewicz DM, Coucke PJ, Cameron DE, Braverman AC, Byers PH, De Paepe AM, Dietz HC. 2006. Aneurysm syndromes caused by mutations in the TGF-beta receptor. N Engl J Med 355:788-798.
3. Singh KK, Rommel K, Mishra A, Karck M, Haverich A, Schmidtke J, Arslan-Kirchner M. 2006. TGFBR1 and TGFBR2 mutations in patients with features of Marfan syndrome and Loeys-Dietz syndrome. Hum Mutat 27:770-777.
4. Matyas G, Arnold E, Carrel T, Baumgartner D, Boileau C, Berger W, Steinmann B. 2006. Identification and in silico analyses of novel TGFBR1 and TGFBR2 mutations in Marfan syndrome-related disorders. Hum Mutat 27:760-769.
5. Sheen VL, Jansen A, Chen MH, Parrini E, Morgan T, Ravenscroft R, Ganesh V, Underwood T, Wiley J, Leventer R, Vaid RR, Ruiz DE, Hutchins GM, Menasha J, Willner J, Geng Y, Gripp KW, Nicholson L, Berry-Kravis E, Bodell A, Apse K, Hill RS, Dubeau F, Andermann F, Barkovich J, Andermann E, Shugart YY, Thomas P, Viri M, Veggiotti P, Robertson S, Guerrini R, Walsh CA. 2005. Filamin A mutations cause periventricular heterotopia with Ehlers-Danlos syndrome. Neurology 64:254-262.
6. Germain DP. 2007. Ehlers-Danlos syndrome type IV. Orphanet J Rare Dis 2:32.
7. Wessels MW, Catsman-Berrevoets CE, Mancini GM, Breuning MH, Hoogeboom JJ, Stroink H, Frohn-Mulder I, Coucke PJ, Paepe AD, Niermeijer MF, Willems PJ. 2004. Three new families with arterial tortuosity syndrome. Am J Med Genet A 131:134-143.
8. Coucke PJ, Willaert A, Wessels MW, Callewaert B, Zoppi N, De Backer J, Fox JE, Mancini GM, Kambouris M, Gardella R, Facchetti F, Willems PJ, Forsyth R, Dietz HC, Barlati S, Colombi M, Loeys B, De Paepe A. 2006. Mutations in the facilitative glucose transporter GLUT10 alter angiogenesis and cause arterial tortuosity syndrome. Nat Genet 38:452-457.
9. Habashi JP, Judge DP, Holm TM, Cohn RD, Loeys BL, Cooper TK, Myers L, Klein EC, Liu G, Calvi C, Podowski M, Neptune ER, Halushka MK, Bedja D, Gabrielson K, Rifkin DB, Carta L, Ramirez F, Huso DL, Dietz HC. 2006. Losartan, an AT1 antagonist, prevents aortic aneurysm in a mouse model of Marfan syndrome. Science 312:117-121.
10. Brooke BS, Habashi JP, Judge DP, Patel N, Loeys B, Dietz HC, 3rd. 2008. Angiotensin II blockade and aortic-root dilation in Marfan's syndrome. N Engl J Med 358:2787-2795.
11. Zhu L, Vranckx R, Khau Van Kien P, Lalande A, Boisset N, Mathieu F, Wegman M, Glancy L, Gasc JM, Brunotte F, Bruneval P, Wolf JE, Michel JB, Jeunemaitre X. 2006. Mutations in myosin heavy chain 11 cause a syndrome associating thoracic aortic aneurysm/aortic dissection and patent ductus arteriosus. Nat Genet 38:343-349.
12. Guo DC, Pannu H, Tran-Fadulu V, Papke CL, Yu RK, Avidan N, Bourgeois S, Estrera AL, Safi HJ, Sparks E, Amor D, Ades L, McConnell V, Willoughby CE, Abuelo D, Willing M, Lewis RA, Kim DH, Scherer S, Tung PP, Ahn C, Buja LM, Raman CS, Shete SS, Milewicz DM. 2007. Mutations in smooth muscle alpha-actin (ACTA2) lead to thoracic aortic aneurysms and dissections. Nat Genet 39:1488-1493.
13. Lim JY, Park SJ, Hwang HY, Park EJ, Nam JH, Kim J, Park SI. 2005. TGF-beta1 induces cardiac hypertrophic responses via PKC-dependent ATF-2 activation. J Mol Cell Cardiol 39:627-636.
14. Chaudhry SS, Cain SA, Morgan A, Dallas SL, Shuttleworth CA, Kielty CM. 2007. Fibrillin-1 regulates the bioavailability of TGFbeta1. J Cell Biol 176:355-367.
15. Isselbacher EM. 2005. Thoracic and abdominal aortic aneurysms. Circulation 111:816-828.
16. Robinson PN, Arteaga-Solis E, Baldock C, Collod-Beroud G, Booms P, De Paepe A, Dietz HC, Guo G, Handford PA, Judge DP, Kielty CM, Loeys B, Milewicz DM, Ney A, Ramirez F, Reinhardt DP, Tiedemann K, Whiteman P, Godfrey M. 2006. The molecular genetics of Marfan syndrome and related disorders. J Med Genet 43:769-787.
17. Mizuguchi T, Matsumoto N. 2007. Recent progress in genetics of Marfan syndrome and Marfan-associated disorders. J Hum Genet 52:1-12.
18. Faivre L, Collod-Beroud G, Child A, Callewaert B, Loeys BL, Binquet C, Gautier E, Arbustini E, Mayer K, Arslan-Kirchner M, Stheneur C, Kiotsekoglou A, Comeglio P, Marziliano N, Halliday D, Beroud C, Bonithon-Kopp C, Claustres M, Plauchu H, Robinson PN, Ades L, De Backer J, Coucke P, Francke U, De Paepe A, Boileau C, Jondeau G. 2008. Contribution of molecular analyses in diagnosing Marfan syndrome and type I fibrillinopathies: an international study of 1009 probands. J Med Genet 45:384-390.
19. Williams JA, Loeys BL, Nwakanma LU, Dietz HC, Spevak PJ, Patel ND, Francois K, DeBacker J, Gott VL, Vricella LA, Cameron DE. 2007. Early surgical experience with Loeys-Dietz: a new syndrome of aggressive thoracic aortic aneurysm disease. Ann Thorac Surg 83:S757-763; discussion S785-790.
20. LeMaire SA, Pannu H, Tran-Fadulu V, Carter SA, Coselli JS, Milewicz DM. 2007. Severe aortic and arterial aneurysms associated with a TGFBR2 mutation. Nat Clin Pract Cardiovasc Med 4:167-171.

21. Stheneur C, Collod-Beroud G, Faivre L, Gouya L, Sultan G, Le Parc JM, Moura B, Attias D, Muti C, Sznajder M, Claustres M, Junien C, Baumann C, Cormier-Daire V, Rio M, Lyonnet S, Plauchu H, Lacombe D, Chevallier B, Jondeau G, Boileau C. 2008. Identification of 23 TGFBR2 and 6 TGFBR1 gene mutations and genotype-phenotype investigations in 457 patients with Marfan syndrome type I and II, Loeys-Dietz syndrome and related disorders. Hum Mutat 29:E284-295.
22. Bee KJ, Wilkes D, Devereux RB, Lerman BB, Dietz HC, Basson CT. 2006. Structural and functional genetic disorders of the great vessels and outflow tracts. Ann N Y Acad Sci 1085:256-269.
23. Wenstrup RJ, Murad S, Pinnell SR. 1989. Ehlers-Danlos syndrome type VI: clinical manifestations of collagen lysyl hydroxylase deficiency. J Pediatr 115:405-409.
24. Yeowell HN, Walker LC. 2000. Mutations in the lysyl hydroxylase 1 gene that result in enzyme deficiency and the clinical phenotype of Ehlers-Danlos syndrome type VI. Mol Genet Metab 71:212-224.
25. Sheen VL, Dixon PH, Fox JW, Hong SE, Kinton L, Sisodiya SM, Duncan JS, Dubeau F, Scheffer IE, Schachter SC, Wilner A, Henchy R, Crino P, Kamuro K, DiMario F, Berg M, Kuzniecky R, Cole AJ, Bromfield E, Biber M, Schomer D, Wheless J, Silver K, Mochida GH, Berkovic SF, Andermann F, Andermann E, Dobyns WB, Wood NW, Walsh CA. 2001. Mutations in the X-linked filamin 1 gene cause periventricular nodular heterotopia in males as well as in females. Hum Mol Genet 10:1775-1783.
26. Hucthagowder V, Sausgruber N, Kim KH, Angle B, Marmorstein LY, Urban Z. 2006. Fibulin-4: a novel gene for an autosomal recessive cutis laxa syndrome. Am J Hum Genet 78:1075-1080.
27. Hu Q, Loeys BL, Coucke PJ, De Paepe A, Mecham RP, Choi J, Davis EC, Urban Z. 2006. Fibulin-5 mutations: mechanisms of impaired elastic fiber formation in recessive cutis laxa. Hum Mol Genet 15:3379-3386.
28. Dasouki M, Markova D, Garola R, Sasaki T, Charbonneau NL, Sakai LY, Chu ML. 2007. Compound heterozygous mutations in fibulin-4 causing neonatal lethal pulmonary artery occlusion, aortic aneurysm, arachnodactyly, and mild cutis laxa. Am J Med Genet A 143A:2635-2641.
29. Hanada K, Vermeij M, Garinis GA, de Waard MC, Kunen MG, Myers L, Maas A, Duncker DJ, Meijers C, Dietz HC, Kanaar R, Essers J. 2007. Perturbations of vascular homeostasis and aortic valve abnormalities in fibulin-4 deficient mice. Circ Res 100:738-746.
30. Drera B, Guala A, Zoppi N, Gardella R, Franceschini P, Barlati S, Colombi M. 2007. Two novel SLC2A10/GLUT10 mutations in a patient with arterial tortuosity syndrome. Am J Med Genet A 143:216-218.
31. Callewaert BL, Willaert A, Kerstjens-Frederikse WS, De Backer J, Devriendt K, Albrecht B, Ramos-Arroyo MA, Doco-Fenzy M, Hennekam RC, Pyeritz RE, Krogmann ON, Gillessen-kaesbach G, Wakeling EL, Nik-zainal S, Francannet C, Mauran P, Booth C, Barrow M, Dekens R, Loeys BL, Coucke PJ, De Paepe AM. 2008. Arterial tortuosity syndrome: clinical and molecular findings in 12 newly identified families. Hum Mutat 29:150-158.
32. Coucke PJ, Wessels MW, Van Acker P, Gardella R, Barlati S, Willems PJ, Colombi M, De Paepe A. 2003. Homozygosity mapping of a gene for arterial tortuosity syndrome to chromosome 20q13. J Med Genet 40:747-751.
33. Cheng CH, Kikuchi T, Chen YH, Sabbagha NG, Lee YC, Pan HJ, Chang C, Chen YT. 2009. Mutations in the SLC2A10 gene cause arterial abnormalities in mice. Cardiovasc Res 81:381-388.
34. Qian Q, Li M, Cai Y, Ward CJ, Somlo S, Harris PC, Torres VE. 2003. Analysis of the polycystins in aortic vascular smooth muscle cells. J Am Soc Nephrol 14:2280-2287.
35. Ho VB, Bakalov VK, Cooley M, Van PL, Hood MN, Burklow TR, Bondy CA. 2004. Major vascular anomalies in Turner syndrome: prevalence and magnetic resonance angiographic features. Circulation 110:1694-1700.
36. Matura LA, Ho VB, Rosing DR, Bondy CA. 2007. Aortic dilatation and dissection in Turner syndrome. Circulation 116:1663-1670.
37. Carlson M, Silberbach M. 2007. Dissection of the aorta in Turner syndrome: two cases and review of 85 cases in the literature. J Med Genet 44:745-749.
38. Sachdev V, Matura LA, Sidenko S, Ho VB, Arai AE, Rosing DR, Bondy CA. 2008. Aortic valve disease in Turner syndrome. J Am Coll Cardiol 51:1904-1909.
39. Plouin PF, Perdu J, La Batide-Alanore A, Boutouyrie P, Gimenez-Roqueplo AP, Jeunemaitre X. 2007. Fibromuscular dysplasia. Orphanet J Rare Dis 2:28.
40. Lilienfeld DE, Gunderson PD, Sprafka JM, Vargas C. 1987. Epidemiology of aortic aneurysms: I. Mortality trends in the United States, 1951 to 1981. Arteriosclerosis 7:637-643.
41. Albornoz G, Coady MA, Roberts M, Davies RR, Tranquilli M, Rizzo JA, Elefteriades JA. 2006. Familial thoracic aortic aneurysms and dissections--incidence, modes of inheritance, and phenotypic patterns. Ann Thorac Surg 82:1400-1405.

42. Coady MA, Davies RR, Roberts M, Goldstein LJ, Rogalski MJ, Rizzo JA, Hammond GL, Kopf GS, Elefteriades JA. 1999. Familial patterns of thoracic aortic aneurysms. Arch Surg 134:361-367.
43. Vaughan CJ, Casey M, He J, Veugelers M, Henderson K, Guo D, Campagna R, Roman MJ, Milewicz DM, Devereux RB, Basson CT. 2001. Identification of a chromosome 11q23.2-q24 locus for familial aortic aneurysm disease, a genetically heterogeneous disorder. Circulation 103:2469-2475.
44. Kakko S, Raisanen T, Tamminen M, Airaksinen J, Groundstroem K, Juvonen T, Ylitalo A, Uusimaa P, Savolainen MJ. 2003. Candidate locus analysis of familial ascending aortic aneurysms and dissections confirms the linkage to the chromosome 5q13-14 in Finnish families. J Thorac Cardiovasc Surg 126:106-113.
45. Hasham SN, Willing MC, Guo DC, Muilenburg A, He R, Tran VT, Scherer SE, Shete SS, Milewicz DM. 2003. Mapping a locus for familial thoracic aortic aneurysms and dissections (TAAD2) to 3p24-25. Circulation 107:3184-3190.
46. Guo D, Hasham S, Kuang SQ, Vaughan CJ, Boerwinkle E, Chen H, Abuelo D, Dietz HC, Basson CT, Shete SS, Milewicz DM. 2001. Familial thoracic aortic aneurysms and dissections: genetic heterogeneity with a major locus mapping to 5q13-14. Circulation 103:2461-2468.
47. Pannu H, Avidan N, Tran-Fadulu V, Milewicz DM. 2006. Genetic basis of thoracic aortic aneurysms and dissections: potential relevance to abdominal aortic aneurysms. Ann N Y Acad Sci 1085:242-255.
48. Ahmad F, Seidman JG, Seidman CE. 2005. The genetic basis for cardiac remodeling. Annu Rev Genomics Hum Genet 6:185-216.
49. Wessels MW, Berger RM, Frohn-Mulder IM, Roos-Hesselink JW, Hoogeboom JJ, Mancini GS, Bartelings MM, Krijger R, Wladimiroff JW, Niermeijer MF, Grossfeld P, Willems PJ. 2005. Autosomal dominant inheritance of left ventricular outflow tract obstruction. Am J Med Genet A 134:171-179.
50. Wessels MW, van de Laar IM, Roos-Hesselink J, Strikwerda S, Majoor-Krakauer DF, de Vries BB, Kerstjens-Frederikse WS, Vos YJ, de Graaf BM, Bertoli-Avella AM, Willems PJ. 2009. Autosomal dominant inheritance of cardiac valves anomalies in two families: Extended spectrum of left-ventricular outflow tract obstruction. Am J Med Genet A 149A:216-225.
51. Nistri S, Sorbo MD, Marin M, Palisi M, Scognamiglio R, Thiene G. 1999. Aortic root dilatation in young men with normally functioning bicuspid aortic valves. Heart 82:19-22.
52. McBride KL, Riley MF, Zender GA, Fitzgerald-Butt SM, Towbin JA, Belmont JW, Cole SE. 2008. NOTCH1 mutations in individuals with left ventricular outflow tract malformations reduce ligand-induced signaling. Hum Mol Genet 17:2886-2893.
53. Shibamura H, Olson JM, van Vlijmen-Van Keulen C, Buxbaum SG, Dudek DM, Tromp G, Ogata T, Skunca M, Sakalihasan N, Pals G, Limet R, MacKean GL, Defawe O, Verloes A, Arthur C, Lossing AG, Burnett M, Sueda T, Kuivaniemi H. 2004. Genome scan for familial abdominal aortic aneurysm using sex and family history as covariates suggests genetic heterogeneity and identifies linkage to chromosome 19q13. Circulation 109:2103-2108.
54. Helgadottir A, Thorleifsson G, Magnusson KP, Gretarsdottir S, Steinthorsdottir V, Manolescu A, Jones GT, Rinkel GJ, Blankensteijn JD, Ronkainen A, Jaaskelainen JE, Kyo Y, Lenk GM, Sakalihasan N, Kostulas K, Gottsater A, Flex A, Stefansson H, Hansen T, Andersen G, Weinsheimer S, Borch-Johnsen K, Jorgensen T, Shah SH, Quyyumi AA, Granger CB, Reilly MP, Austin H, Levey AI, Vaccarino V, Palsdottir E, Walters GB, Jonsdottir T, Snorradottir S, Magnusdottir D, Gudmundsson G, Ferrell RE, Sveinbjornsdottir S, Hernesniemi J, Niemela M, Limet R, Andersen K, Sigurdsson G, Benediktsson R, Verhoeven EL, Teijink JA, Grobbee DE, Rader DJ, Collier DA, Pedersen O, Pola R, Hillert J, Lindblad B, Valdimarsson EM, Magnadottir HB, Wijmenga C, Tromp G, Baas AF, Ruigrok YM, van Rij AM, Kuivaniemi H, Powell JT, Matthiasson SE, Gulcher JR, Thorgeirsson G, Kong A, Thorsteinsdottir U, Stefansson K. 2008. The same sequence variant on 9p21 associates with myocardial infarction, abdominal aortic aneurysm and intracranial aneurysm. Nat Genet 40:217-224.

4.2

American Journal of Medical Genetics 131A:134–143 (2004)

Three New Families With Arterial Tortuosity Syndrome

Marja W. Wessels,[1,2]* Coriene E. Catsman-Berrevoets,[3] Grazia M.S. Mancini,[1] Martijn H. Breuning,[4] Jeanette J.M. Hoogeboom,[1] Hans Stroink,[5] Ingrid Frohn-Mulder,[6] Paul J. Coucke,[7] Anne De Paepe,[7] Martinus F. Niermeijer,[1] and Patrick J. Willems[8]

[1]*Department of Clinical Genetics, Erasmus University Medical Centre, Rotterdam, The Netherlands*
[2]*Department of Obstetrics and Gynaecology, Erasmus University Medical Centre, Rotterdam, The Netherlands*
[3]*Department of Paediatric Neurology, Erasmus University Medical Centre, Rotterdam, The Netherlands*
[4]*Department of Clinical Genetics, Leiden University Medical Centre, Leiden, The Netherlands*
[5]*Department of Neurology, St. Elisabeth Hospital, Tilburg, The Netherlands*
[6]*Department of Paediatric Cardiology, Erasmus University Medical Centre, Rotterdam, The Netherlands*
[7]*Centre for Medical Genetics, Ghent University Hospital, Ghent, Belgium*
[8]*GENDIA, Antwerp, Belgium*

Arterial tortuosity syndrome (ATS) is a rare condition with autosomal recessive inheritance characterized by connective tissue abnormalities. The most specific clinical findings are cardiovascular anomalies including tortuosity, lengthening, aneurysm, and stenosis formation of major arteries. Also ventricular hypertrophy is frequently present. Other anomalies are skin hyperextensibility and cutis laxa, joint laxity or contractures of the joints, and inguinal herniae. Histology shows disruption of elastic fibers of the media. These features suggest that ATS is a connective tissue disorder. A biochemical or molecular defect has not yet been identified. We describe here nine additional ATS patients from three consanguineous Moroccan families and review a total of 35 patients with this uncommon condition.
© 2004 Wiley-Liss, Inc.

KEY WORDS: **arterial tortuosity; ATS; aneurysms; pulmonary stenosis; joint laxity; hyperextensibility; cutis laxa; elastic fibers**

INTRODUCTION

Arterial tortuosity syndrome (ATS) (OMIM 208 050) is a rare disorder, with only 26 ATS patients reported (Table I, and references therein). Tortuosity of most of the major and middle arteries, including the aorta, the carotid, renal, and pulmonary arteries is the most specific feature. Arterial aneurysms, and stenosis of the pulmonary arteries and the aorta are also characteristic features, and ventricular hypertrophy is often present. The majority of patients also have congenital involvement of the skin, with softness, hyperextensibility, or cutis laxa, but no bruisability. Additional ATS abnormalities typical of a connective tissue disorder are laxity and/or contractures of joints, arachnodactyly, inguinal and/or umbilical herniae, and relaxation of the diaphragm leading to hiatal hernia. Most patients have an elongated face with micrognathia. Other facial features might include downslanting palpebral fissures, blepharophimosis, and a beaked nose. High-arched and/or cleft palate can be present. In addition, hypotonia is sometimes observed (Table I). Histopathology reveals fragmentation of the internal elastic membrane and elastic fibers of the tunica media of the large arteries [Ertugrul, 1967; Beuren et al., 1969; Lees et al., 1969; Wagstaff et al., 1970; Welch et al., 1971; Ades et al., 1996; Pletcher et al., 1996; Franceschini et al., 2000; Rivera et al., 2000], whereas the elastin network in fibroblasts derived from a skin biopsy was reported to be normal [Al Fadley et al., 2000]. Biochemical studies of collagen are normal [Ades et al., 1996; Pletcher et al., 1996; Franceschini et al., 2000], and the primary defect at the protein or molecular level in ATS has not yet been identified.

Defects in the elastin network are also found in a group of ill-defined connective tissue disorders having overlapping features with ATS (Tables I and II). These include autosomal recessive cutis laxa type 1 (OMIM 219100) which is due to mutations in fibulin 5 [Loeys et al., 2002], progeroid Ehlers–Danlos syndrome which is caused by mutations in the *B4GALT7* gene encoding the β-1,4-galactosyltransferase 1 enzyme [Okajima et al., 1999], and several conditions without identified primary gene defect, including autosomal recessive cutis laxa type 2 with growth and developmental delay (OMIM 219200), wrinkly skin syndrome (OMIM 278250), gerodermia osteodysplastica (OMIM 231070), and De Barsy syndrome (OMIM 219150). Cutis laxa type 2 with growth and developmental delay was originally described by Reisner et al. [1971] as a new entity with congenital cutis laxa, joint laxity with hip dislocation, growth retardation, and psychomotor delay. Additional patients with this form of cutis laxa have been reported by Sakati et al. [1983] and Patton et al. [1987]. However, many of these patients were later reclassified as examples of Costello syndrome [Patton and Baraitser, 1993]. Moreover, the original patients of Reisner et al. [1971] were republished 2 years later by other authors [Gazit et al., 1973] as the first patients with wrinkly skin syndrome [Zlotogora, 1999]. The latter syndrome is characterized by wrinkling of the skin of the abdomen, the hands and feet, increased creases of the palms and soles, joint laxity, spinal deformities, pre- and post-natal growth retardation, and psychomotor delay [Gazit et al., 1973; Karrar et al., 1983; Casamassima et al., 1987; Hurvitz et al., 1990; Kreuz and Wittwer, 1993; Azuri et al., 1999; AL-Gazali et al., 2001]. This illustrates the overlap between cutis laxa type 2, Costello syndrome, and wrinkly skin syndrome. Al-Gazali et al. [2001] recently suggested that the clinical spectrum of these disorders can be further extended to

*Correspondence to: Marja W. Wessels, M.D., Department of Clinical Genetics and Department of Obstetrics and Gynaecology, Erasmus University Medical Centre Rotterdam, Westzeedijk 112, 3016 AH Rotterdam, The Netherlands.
E-mail: m.w.wessels@erasmusmc.nl

Received 26 March 2003; Accepted 22 February 2004
DOI 10.1002/ajmg.a.30272

© 2004 Wiley-Liss, Inc.

TABLE I. Clinical Features in ATS Patients

Arterial anomalies					Joints					
Tortuosity	Aneurysm	Stenosis A. Pulm.	Skin	Hernia	Laxity	Contractures	Arachnodactyly	Pectus deformity	Facial anomalies	Other findings
+	+								HP	VH
+		+	HES					+	BN, HP, M	VH
+	+	+	HES		+					VH
+	+		Cutis laxa	+						SHT
+	+		HES	+	+				M	VH, H
+	+	+	Cutis laxa		+		+		M	
+	+	+	Soft		+				BN, HP, M	VH, SHT
+	+	+	Cutis laxa	+		+	+		BN, DP, M	VH, AT
+				+						VH
+	+		Soft	+				+	DP, M	
+	+							+	CP	VH, hamartoma
+	+	+			+				HP, M	
+		+	Soft	+	+		+		LF, M, HP	Keratoconus, H, RD
+					+				M	AT
+		+	HES		+	+			LF, M	Kyphoscoliosis
+		+	HES		+	+			LF, M	
+		+	HES			+			LF, M	
+		+	HES		+	+			LF, M	SHT
+		+	HES		+	+			LF, M	SHT
+		+	HES		+	+			LF, M	
+		+	HES		+	+			LF, M	
+		+	HES		+	+			LF, M	
+		+	HES		+	+			LF, M	
+		+	HES		+	+			LF, M	Hip dislocation
+		+	HES		+	+			LF, M	
+		+	HES		+	+			LF, M	
+	+		HES	+	+		+	+	CP, M, BP	RD
+		+	Soft	+	+		+	+	BN, HP, DP, BP	
+			Cutis laxa		+		+		BN	
+			Soft		+		+		LF, HP	
+		+	HES		+	+	+		LF, HP	MR, HP, AC, ST, RD, VH
+			Redundant		+				LF, M, CP	MR, H, AC, ST, AT, RD
+						+	+			MR, H, AC, RD, ST, AT
+			Cutis laxa		+			+	M, HP	H, AC
+			Cutis laxa		+			+	M, CP	H, AC
35/35 (100%)	11/35 (31%)	21/35 (60%)	29/35 (83%)	8/35 (23%)	26/35 (74%)	15/35 (43%)	9/35 (26%)	7/35 (20%)		

ıarophimosis; CP, cleft palate; DP, downslanting palpabral fissures; H, hypotonia; HES, hyperextensibility of the skin; HP, high palate; LF, long
relaxation of diaphragm—hiatal hemia; SHT, systemic hypertension; ST, strabismus; VH, ventricular hypertrophy; yrs, years; mos, months.

TABLE II. Differential Diagnosis of Arterial Tortuosity Syndrome (ATS)

			Symptoms								
Syndrome	OMIM	Inheritance	Arteriopathy	Skin laxity	Progeria	Joint laxity	Hernias	Osteoporosis	Growth delay	Mental retardation
ATS	208050	AR	+	+		+	+		+	+
Progeroid Ehlers–Danlos syndrome	130070	AR		+	+	+		+	+	+
Wrinkly skin syndrome	287250	AR		+	–	+		+	–	+
Gerodermia osteodysplastica	231070	AR		+	+	+		–	–	
Cutis laxa type 1	219100	AR		+	+		+		+	
Cutis laxa type 2	219200	AR		–		+			+	+
De Barsy syndrome	219150	AR		+	+	+			+	+

include gerodermia osteodysplastica, another disorder of the elastin network with similar clinical features [Bamatter et al., 1950; Hunter et al., 1978; Hunter, 1988; Lisker et al., 1979; Al-Torki et al., 1997]. Also De Barsy syndrome [De Barsy et al., 1968; Karnes et al., 1992] and ATS show overlap. However, the main features of ATS including tortuosity, lengthening, stenosis, and aneurysm of multiple major arteries, are infrequent in these conditions.

The mode of inheritance of ATS syndrome is probably autosomal recessive as parental consanguinity and increased recurrence risk in siblings has been observed in many pedigrees (Table I), although ATS might be heterogeneous with involvement of different genes and modes of inheritance.

We describe here nine additional patients with ATS from three consanguineous families from Moroccan descent and review the characteristics of all the patients previously reported in order to delineate this rare disorder.

CLINICAL REPORTS

Family 1

Patient 1. This was the third child (V-3) of healthy Moroccan consanguineous parents (Fig. 1, family 1). The older sibs were reported to be healthy. This pregnancy was uneventful until the 34th week when ultrasound examination revealed a stomach located in the thorax. A diaphragmatic hernia was suspected. Amniocentesis was performed, and cytogenetic analysis showed a normal, female karyotype. The parents continued the pregnancy, and a girl with a birth weight of 3,735 g was born in the 39th week. She was intubated and transferred to the neonatal unit, where a hiatal hernia was found by radiography. She was also noticed to have an umbilical hernia and dysmorphic features, including a cleft of the soft palate, hyperlax skin, long fingers, blepharophimosis, telecanthus, and micrognathia. Echocardiogram of the heart revealed tortuosity and lengthening of the aorta. Also the carotid arteries were tortuous. Angiographic studies confirmed the tortuosity of the thoracic and the abdominal aorta. Also the superior mesenteric arteries were tortuous. The pulmonary arteries were not visualized. Because of the suspicion of Ehlers–Danlos syndrome, a skin biopsy was taken for collagen analysis. This showed a normal electrophoretic pattern of collagen type III, and a normal collagen type I to III ratio. Seven weeks after birth the girl developed severe ileus, for which laparotomy was performed. This showed necrosis of the complete small bowel, probably due to arteriopathy of the mesenteric artery. Two days later the child died. Permission for autopsy was not obtained. ATS was diagnosed retrospectively in view of the typical arteriopathy with tortuosity, and laxity of the joints and skin.

Family 2

Patient 1. This was the second child (IV-2) born to healthy Moroccan parents that were first cousins (Fig. 1, family 2), and originated from the same town as family 1. The first pregnancy ended with a spontaneous miscarriage at 12 weeks gestation, and the oldest child is a healthy son. This girl was born after an uneventful pregnancy and birth at 42 weeks. At the age of 4 months, a systolic heart murmur was found on routine examination. Cardiologic evaluation revealed stenosis and tortuosity of the peripheral pulmonic arteries, together with tortuosity of the abdominal aorta. Hyperlaxity of the joints, especially of the wrists and fingers, was present. She also presented with dysmorphic features, including a large forehead, downslanting palpebral fissures, blepharophimosis, hypertelorism (with outer and inner canthal distances at the 97th percentile), flat supra-orbital margins, a short and beaked

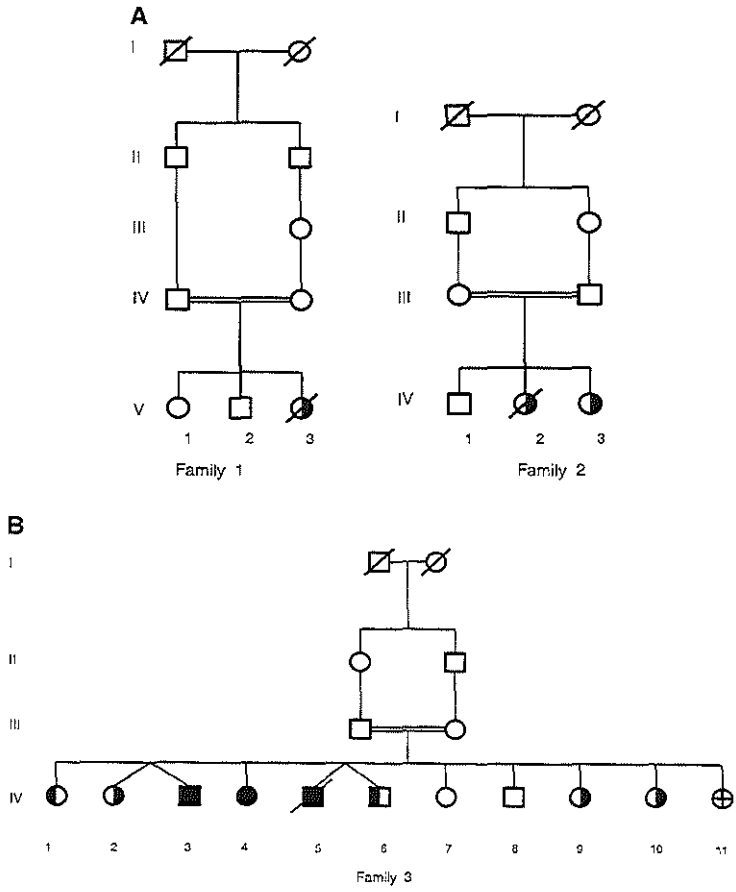

Fig. 1. Pedigrees of the three consanguineous arterial tortuosity syndrome (ATS) families originating from the same region in the north of Morocco. A common ancestor was not found, but is likely. In family 3, there are six patients with ATS, and five patients with an additional disease with mental retardation. Three patients (IV-3, IV-4, IV-5) have both diseases. ◑, ATS; ◧, additional disease; ⊕, Down syndrome.

nose, a long philtrum, a high palate, pectus excavatum, and long fingers (Fig. 2A). Bilateral inguinal herniae were present. The skin was very soft, and she had atopic eczema. Height, weight, and OFC were normal. Psychomotor development was also normal. At the age of 3 years, heart catheterization revealed multiple stenoses of the peripheral pulmonary arteries, pulmonary hypertension, hypertrophy of the right ventricle, tortuosity of the abdominal aorta and the coronary arteries. At the age of 4, she developed *Staphylococcus aureus* sepsis, leading to decompensation and death. The parents refused autopsy.

Patient 2. This patient is the youngest child in this family (IV-3). In view of the congenital abnormalities of her sister, she was evaluated by a pediatrician at the age of 9 days. Apart from mild hypotonia no abnormalities were noted. Ultrasound evaluation of the heart and major arteries revealed tortuosity of the pulmonary arteries and the ascending and descending aorta. Clinical examination at the age of 18 months revealed dysmorphic features including periorbital fullness, downslanting palpebral fissures, a beaked nose, long fingers, and flat feet. Hyperlaxity of the joints, especially of the wrists and fingers, was present. The skin was hyperlax in the abdominal region and hands (Fig. 2B). Her psychomotor development was normal.

Family 3

This consanguineous family originates from the same area in north Morocco as the first two families, although the three families could not be traced back to the same ancestors (Fig. 1, family 3). The healthy parents are first cousins. ATS was diagnosed in six of the 11 children (IV-2 IV-3, IV-4, IV-5, IV-9, IV-10). The youngest child has Down syndrome and complete atrioventricular septal defect with double outlet right ventricle and pulmonary atresia. Five children of this sibship (IV-1, IV-3, IV-4, IV-5, IV-6) have mental retardation, which probably represents another unknown disease. Only the six sibs with ATS are described here.

Patient 1. This is the second child (IV-2) and one of a pair of fraternal twins. She weighed 2,800 g after an uneventful pregnancy and delivery. Long fingers and toes were noted at birth. She was hospitalized at the age of 1 month because of suspected pyloric stenosis, which was corrected by pyloromyotomy. At that time hypotonia, nystagmus and mild psychomotor delay were noted. Stenosis of the peripheral pulmonary arteries was suspected. Echocardiography at the age of 2 years showed an enlarged aortic root, tortuosity of the ascending aorta, and an elongated, tortuous pulmonary artery. Physical examination at the age of 15 years showed a high-arched palate, an elongated face with a long nose, a relatively short philtrum and chin, long fingers and toes, acrocyanosis, and cubitus valgus. There was mild joint laxity of the elbows. MRI of the brain showed tortuosity of the large cerebral arteries without other brain abnormalities. She developed normally and attended a normal school.

Patient 2. IV-3 is the twin brother of IV-2. He weighed 2,800 g at birth. Dysmorphic features observed in the first year of life included hypertelorism, convergent strabismus, micrognathia, high-arched palate, large ears, long fingers, hyperlaxity of the joints of the hands, adducted thumbs, acrocyanosis, and clubfeet. A Nissen fundoplication was performed because of abnormal relaxation of the diaphragm at 16 months. At the age of 2 years, hypotonia with paresis of the lower extremities and psychomotor retardation became evident. Echocardiography and angiography showed tortuous and dilated pulmonary arteries, an enlarged ascending aorta, and tortuosity of the descending aorta, subclavian, carotic, and renal arteries. Two bladder diverticulae were noticed. He developed flexion contractures of the hips and spasticity of the legs and became wheelchair-bound later on. At the age of 15 years, MRI of the brain showed tortuosity of the large cerebral arteries, diffuse atrophy of the cerebellar hemispheres and supratentorial ventriculomegaly with severe white matter loss (Fig. 3A). Chromosome analysis showed a normal male karyotype. Acetylcholinesterase receptor antibodies were absent. He has severe mental retardation and is unable to sit unsupported or walk.

Patient 3. The fourth child in this family (IV-4), was born with a weight of 4,010 g after an uneventful pregnancy of 42 weeks. Asphyxia and cyanosis were noted at birth. Apgar scores were 3 and 4 at 1 and 5 min, respectively. Congenital anomalies were present, including cleft palate (soft and hard), micrognathia, hypertelorism, convergent strabismus, large ears, and acrocyanosis. Her skin was redundant. At 13 months,

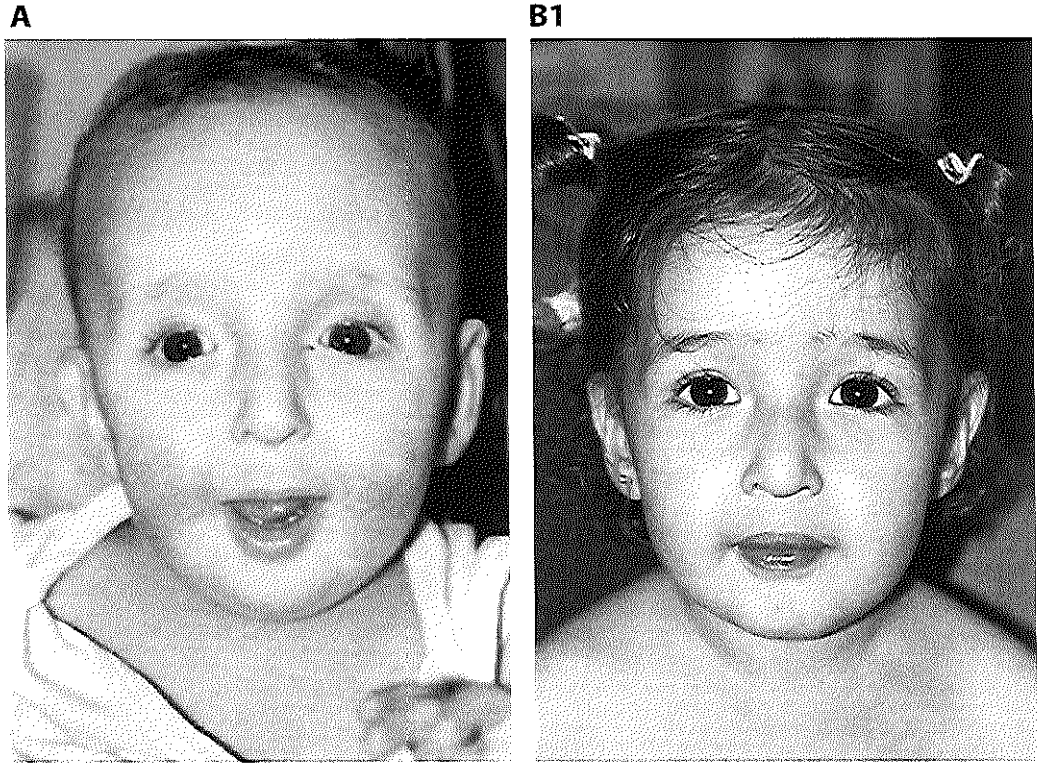

Fig. 2. Photographs of some of the ATS patients. **A**: Patient IV-2 from family 2 shows a large forehead, downslanting palpebral fissures, beaked nose, micrognathia, and eczema at the age of 8 months. **B**: Patient IV-3 from family 2 shows periorbital fullness, large forehead, and a beaked nose (B1). The abdominal skin is hyperlax (B2). **C**: Patient IV-9 from family 3 at the age of 15 months (C1 and C2) and 6 years (C3). A large forehead, posteriorly rotated ears and skin laxity is evident (C2). **D**: Patient IV-10 from family 3 at the age of 5 years. Notice the long face with micrognathia.



Fig. 2. (*Continued*)

hypotonia and delayed early milestones were reported. Echocardiography and angiography at the age of 2 years showed tortuosity and elongation of the pulmonary arteries, thoracic and abdominal aorta as well as the abdominal arteries. She had a large hiatal hernia. She was lost to follow up in the subsequent years, but she was evaluated again at the age of 14 years. MRI of the brain showed microcephaly with slight enlargement of the occipital horns of the lateral ventricles, and white matter loss. Arterial tortuosity was observed, especially of the vertebral and basilar arteries, and of the middle cerebral arteries (Fig. 3B). Other features included long fingers, adducted thumbs, and cyanosis. Chromosome analysis showed a normal female karyotype. At the age of 17 years, she is severely mentally retarded, hypotonic, and unable to stand or walk.

Patient 4. This child (IV-5) was born at 38 weeks with a weight of 2,700 g as twin A of a pair of fraternal twins. He was asphyxiated after birth. Apgar scores were 1 and 5 at 1 and 5 min, respectively. Dysmorphic features including hypertelorism, low set ears, adducted thumbs, long fingers, and clubfeet were noted. Severe hypotonia was present, whereas psychomotor delay became evident later. He had a hiatal hernia with feeding difficulties. A Nissen operation was performed at the age of 3 months. Thirteen months later he died at home. At autopsy bilateral bronchopneumonia was found. The large arteries showed severe tortuosity (Fig. 4).

Patient 5. The ninth child (IV-9), was born after an uneventful pregnancy and delivery with a birth weight of 3,000 g. Hypotonia and hyperlaxity of skin and joints were present from birth on (Fig. 2,C2). Echocardiography and angiography showed tortuosity and elongation of the pulmonary artery, ascending and descending aorta, carotid and vertebral arteries. Arterial aneurysms or stenoses were not found. CT scan of the brain showed tortuosity of the left vertebral artery. At the age of 5 years, she showed mild psychomotor delay with hypotonia, ptosis of the right eye, torticollis, and muscular atrophy. Dysmorphic features included frontal bossing, small nose, large posteriorly rotated ears, bilateral simian creases, joint hyperlaxity, and pectus carinatum (Fig. 2C).

Patient 6. She is the tenth child (IV-10) in this sibship of 11. She was born after 42 weeks of gestation with a birth weight of 4,060 g. Dysmorphic features, including microretrognathia, large ears, medial cleft palate, and clubfeet were noticed after birth (Fig. 2D). The joints and skin were hyperlax and pectus carinatum was present. She was hypotonic. Chromosome analysis showed a normal female karyotype, and FISH analysis showed no deletion of 22q11. At age 5 years, she is developing normally and attending a normal school.

Additional family members. In this sibship of 11 there are six children with ATS (IV-2, IV-3, IV-4, IV-5, IV-9, and IV-10), 4 without ATS (IV-6, IV-7, IV-8, IV-11), and one patient in which no studies of the arterial system were performed (IV-1). At least five patients (IV-1, IV-3, IV-4, IV-5, IV-6) have a separate disease with psychomotor retardation, microcephaly, and adducted thumbs. The youngest sib (IV-11) has Down syndrome due to trisomy 21.

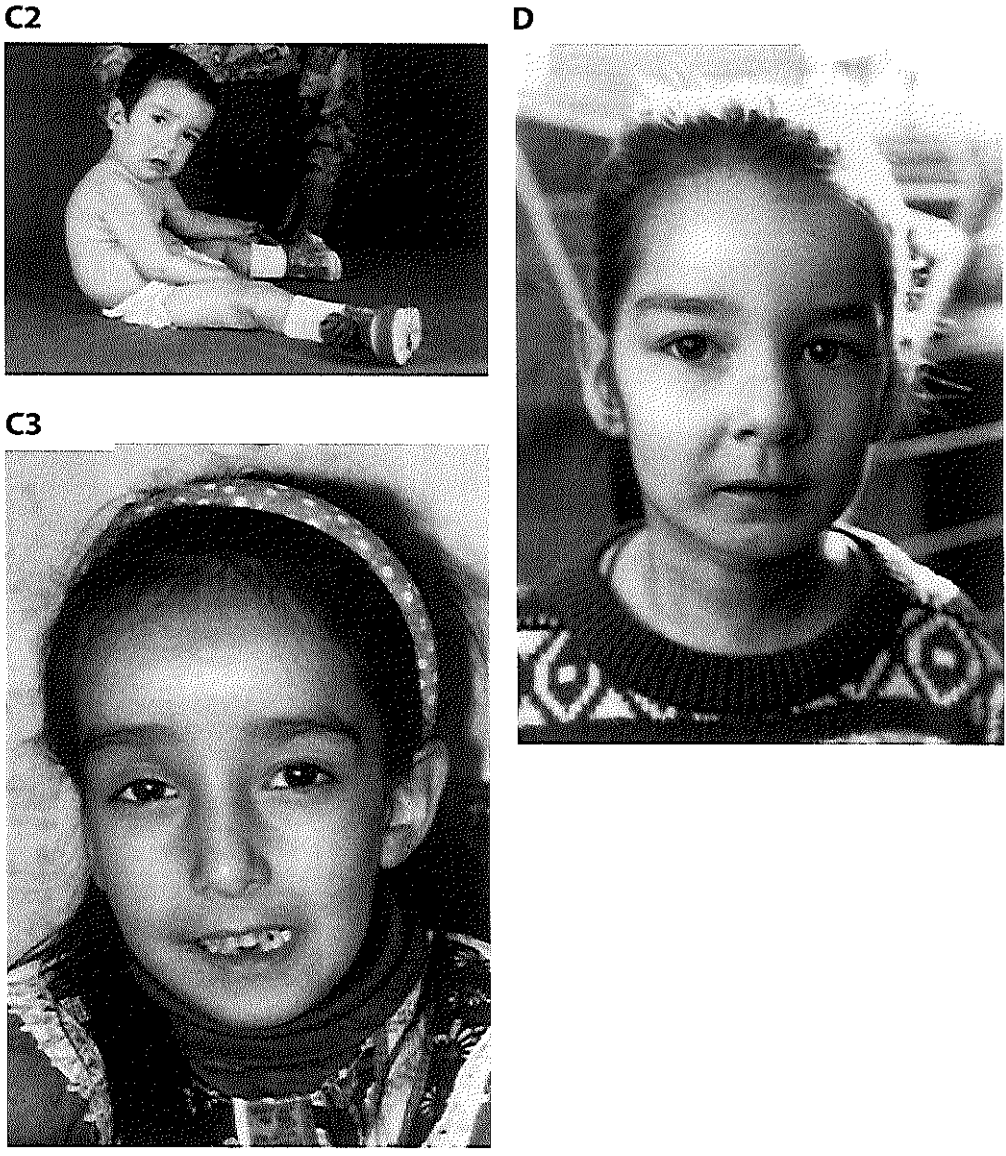

Fig. 2. (*Continued*)

ADDITIONAL STUDIES

Electromyogram studies in several patients from family 3 were normal, excluding myotonic dystrophy. Cytogenetic analysis performed in several patients from all three families were normal. Biochemical studies of collagen in cultured fibroblasts showed normal amounts of collagen, with normal ratio of collagen I to collagen III, and a normal pattern on electrophoresis. Serum copper values in patient 2 from family 3 were normal, excluding Menkes disease. Homocystinuria was excluded in several patients from family 3 by the finding of normal homocysteine values in urine.

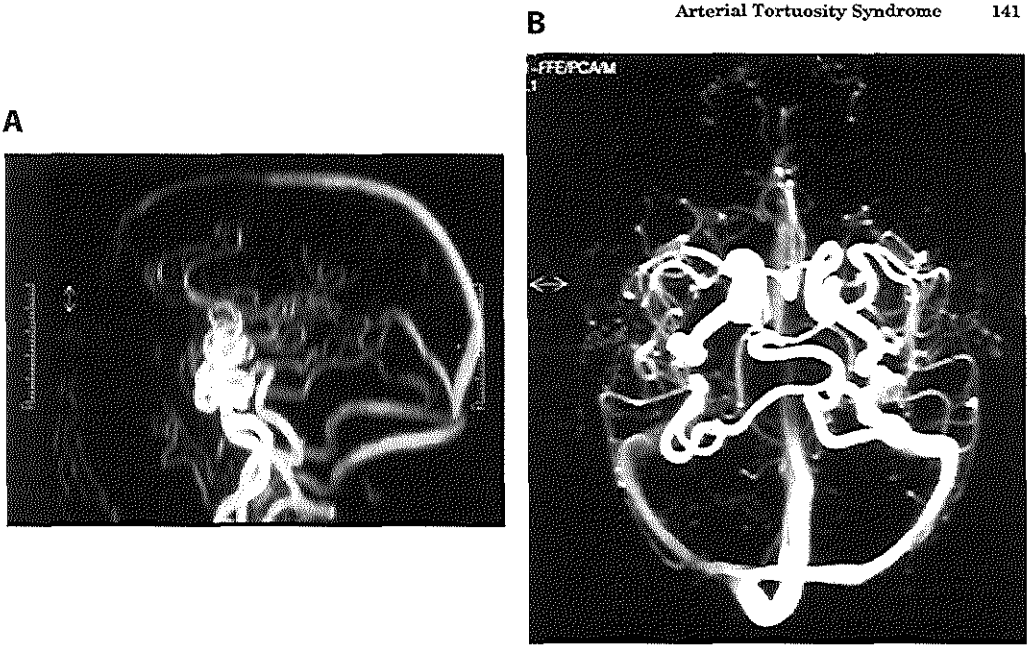

Fig. 3. MR-angiography of patients IV-3 (A) and IV-4 (B) from family 3 showing tortuosity of the cerebral arteries.

DISCUSSION

The three families reported here most likely have ATS in view of the typical clinical picture mainly characterized by extensive tortuosity with aneurysm and stenosis formation of multiple major arteries. As ATS is a very rare disorder, we reviewed all cases reported in the literature (Table I). Approximately 35 patients from 21 families (including our cases) have been reported so far. The major arteries of all of these patients show a degree of tortuosity and lengthening,

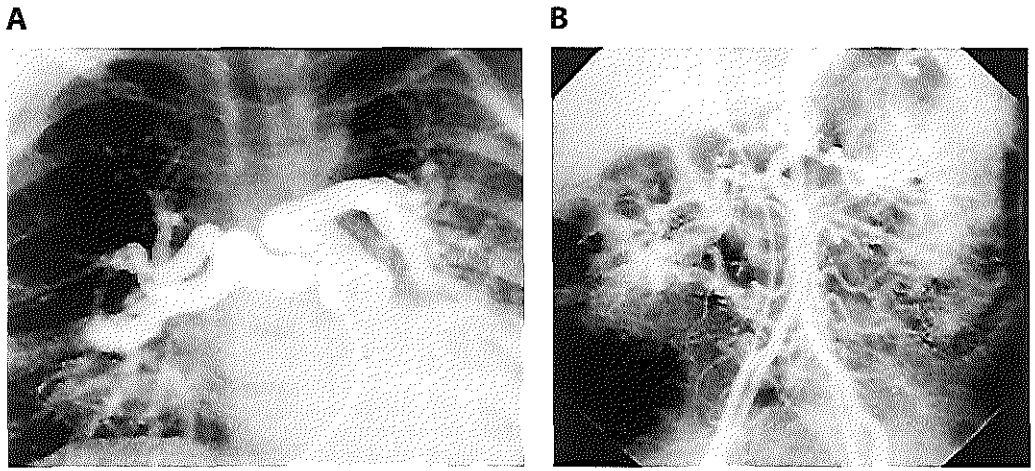

Fig. 4. Angiography of the pulmonary arteries (A), and aorta with large arteries (B) of patient IV-5 from family 3 showing tortuosity and lengthening.

which is much more severe than in other connective tissue disorders such as Menkes disease, Ehlers–Danlos syndrome, Marfan syndrome, and homocystinuria. Also aneurysms and stenoses mainly confined to the aorta and the pulmonary arteries are present in many ATS patients. Apart from arterial involvement, ATS is characterized by abnormalities of the skin including hyperextensibility and cutis laxa (without hemorrhagic diathesis or hypertrophic scar formation). Laxity of the joints and contractures are also present in many patients. Inguinal herniae and abnormal relaxation of the diaphragm leading to the development of hiatal herniae necessitating a Nissen operation are also features of this connective tissue disorder. Additionally, a typical phenotype with an elongated face, micrognathia, high palate, arachnodactyly, and pectus anomalies are also frequent. The ventricular hypertrophy and hypertension reported in many ATS patients might be caused by the arterial involvement.

The clinical picture in our family 3 is complex: six (possibly seven) of the 11 sibs have ATS, one patient has Down syndrome related to the advanced maternal age (42 years), and five sibs have a neurologic disease with severe psychomotor retardation. The latter is most likely caused by another unknown disease with autosomal recessive inheritance because severe psychomotor retardation is infrequent in ATS, and there is no cosegregation of ATS and psychomotor retardation in our family: three patients have ATS but no psychomotor retardation (IV-2, IV-9, IV-10), and one patient has retardation but no ATS (IV-6). Furthermore, psychomotor retardation is only present in family 3 but not in family 1 and 2, although the three families most likely share a common mutation in the putative *ATS* gene (Fig. 1). Severe psychomotor retardation without ATS is also present in four sibs from a consanguineous sibship that has a common ancestor with family 3. Acrocyanosis was evident in the six ATS patients from family 3, but not in the other sibs without ATS.

Consequently, it might be a feature of ATS, although it has only been recorded once in the ATS literature [Pletcher et al., 1996]. Cleft palate was present in the ATS patient from family 1, and in three patients from family 3 of whom two have ATS. This might suggest that it belongs to the ATS spectrum. However, cleft palate was also present in a patient without ATS in family 3, and it has only once been documented in the ATS literature [Ades et al., 1996]. Consequently, it is uncertain that cleft palate is a feature of ATS. High-arched palate, to the contrary, more likely belongs to the ATS spectrum as it was observed in four of our ATS cases, and in many ATS patients reported in the literature [Ertugrul, 1967; Lees et al., 1969; Pletcher et al., 1996; Franceschini et al., 2000].

The clinical severity of ATS is very variable: although the disease is fatal before the age of 5 years in 41% of cases, some patients have very limited symptoms. The diagnosis might not only been missed, but may be misdiagnosed as Ehlers–Danlos syndrome or cutis laxa.

ATS is an autosomal recessive disorder with consanguinity in more than half of the parents of the 35 patients. In view of the presence of arteriopathy, joint abnormalities, herniae, and skin hyperextensibility, ATS can be considered a connective tissue disorder. This is consistent with the finding of histologic abnormalities of the elastin network [Ertugrul, 1967; Lees et al., 1969; Beuren et al., 1969; Wagstaff et al., 1970; Welch et al., 1971; Ades et al., 1996; Pletcher et al., 1996; Franceschini et al., 2000; Rivera et al., 2000]. All major arteries are of the elastic type and contain a large amount of elastic tissue that is necessary for stretching during systole and recoil on blood during diastole. Practically the whole tunica media of these vessels consists of elastic tissue circumferentially organized in concentric elastic membranes composed of elastic fibers. In most ATS cases histologic studies of the larger arteries show fragmentation of the elastic membranes, but biochemical studies have not revealed any abnormality [Ades et al., 1996; Pletcher et al., 1996; Franceschini et al., 2000].

Although it is very likely that ATS is due to a defect of the elastin network, the disease gene(s) and defective protein(s) are still unknown. Human disease with impaired elastogenesis can result from many defects along this pathway (Table III). The identification of the *ATS* gene by functional genetics has been precluded by the absence of a biochemical defect, whereas the positional cloning was hampered by the absence of suitable families amenable to linkage analysis. However, the inbred multiplex families described here offered the possibility to identify the *ATS* gene by positional genetics. Recently, the disease gene responsible for ATS in our families and an additional Italian inbred family [Gardella et al., 2004] was mapped to 20q13 [Coucke et al., 2003].

TABLE III. Disorders of the Elastin Network

Gene mutation	Protein deficiency	Disease
Fibrillin 1	Fibrillin 1	Marfan syndrome
Fibrillin 2	Fibrillin 2	Congenital contractural arachnodactyly
Elastin	Elastin	Supravalvular aortic stenosis
		Williams syndrome
		Cutis laxa
		Intracranial aneurysm (?)
Lysyl hydroxylase	Lysyl hydroxylase	Ehlers–Danlos type 6
Unknown	Lysyl oxidase	Ehlers–Danlos type 5
ATP7A	Lysyl oxidase	Menkes disease
		Occipital horn disease
		X-linked cutis laxa
β-Galactosidase	Elastine-binding protein	GM1 gangliosidosis
		Morquio syndrome
α-Iduronidase	Elastine-binding protein	Hurler syndrome
Unknown	Elastine-binding protein	Costello syndrome
Fibulin 5	Fibulin 5	Cutis laxa type 1
Unknown	Unknown	Cutis laxa type 2
Unknown	Unknown	Wrinkly skin syndrome
Unknown	Unknown	Gerodermia osteodysplastica
Unknown	Unknown	De Barsy syndrome
Unknown	Unknown	ATS

ACKNOWLEDGMENTS

The authors thank Tom de Vries Lentsch and Ruud Koppenol for photographic work.

REFERENCES

Ades LC, Knight WB, Bynrd RW, Bateman JF, Esquivel JA, Mee RB, Haan EA, Milewicz DM. 1996. Clinicopathologic findings in congenital aneurysms of the great vessels. Am J Med Genet 66:289–299.

Al Fadley F, Al Manea W, Nykanen DG, Al Fadley A, Bulbul Z, Al Halees Z. 2000. Severe tortuosity and stenosis of the systemic, pulmonary, and coronary vessels in 12 patients with similar phenotypic features: A new syndrome? Cardiol Young 10:582–589.

Al-Gazali LI, Sztriha L, Skalf F, Hans D. 2001. Gerodermia osteodysplastica and wrinkly skin syndrome: Are they the same? Am J Med Genet 101: 213–220.

Al-Torki NA, Al-Awadi SA, Cindro-Heberle L, Sabry MA. 1997. Gerodermia osteodysplastica in a Bedouin sibship: Further delineation of the syndrome. Clin Dysmorph 6:51–55.

Azuri XX, Mizrachi A, Weintraub S, Lerman-Sagie T. 1999. Neurological involvement in a child with the wrinkly skin syndrome. Am J Med Genet 82:31–33.

Bamatter F, Franceschetti A, Klein D, Sierro A. 1950. Gérodermie ostéodysplastique héréditaire. Ann Pediat 174:126–127.

Beuren AJ, Hort W, Kalbfleisch H, Muller H, Stoermer J. 1969. Dysplasia of the systemic and pulmonary arterial system with tortuosity and lengthening of the arteries. A new entity, diagnosed during life, and leading to coronary death in early childhood. Circulation 39:109–115.

Casamassima AC, Wesson SK, Conlon CJ, Weiss FH. 1987. Congenital cutis laxa with retardation of growth and development. J Med Genet 24:556–561.

Coucke PJ, Wessels MW, Van Acker P, Gardella R, Barlati S, Willems PJ, Colombi M, De Paepe A. 2003. Homozygosity mapping of a gene for arterial tortuosity syndrome to chromosome 20q13. J Med Genet 40: 747–751.

De Barsy AM, Moens E, Dierckx L. 1968. Dwarfism, oligophrenia, and degeneration of the elastic tissue in skin and cornea. A new syndrome? Helv Paediat Acta 23:305–313.

Ertugrul A. 1967. Diffuse tortuosity and lengthening of the arteries. Circulation 36:400–407.

Franceschini P, Guala A, Licata D, Di Cara G, Franceschini D. 2000. Arterial tortuosity syndrome. Am J Med Genet 91:141–143.

Gardella R, Zappi N, Assanelli D, et al. 2004. Exclusion of candidate genes in a family with arterial tortuosity syndrome. Am J Med Genet 126A(3): 221–228.

Gazit E, Goodman RM, Katznelson MB, Rotem Y. 1973. The wrinkly skin syndrome: A new heritable disorder of connective tissue. Clin Genet 4: 186–192.

Hunter AGW. 1988. Is geroderma osteodysplastica underdiagnosed? J Med Genet 25:854–857.

Hunter AGW, Martsolf JT, Baker CG, Reed MH. 1978. Geroderma osteodysplastica: A report of two affected families. Hum Genet 40:311–325.

Hurvitz SA, Baumgarten A, Goodman RM. 1990. The wrinkly skin syndrome: A report of a case and review of the literature. Clin Genet 38: 307–313.

Karnes PS, Shamban AT, Olsen DR, Fazio MJ, Falk RE. 1992. De Barsy syndrome: Report of a case, literature review, and elastin gene expression studies of the skin. Am J Med Genet 42:29–34.

Karrar ZA, Elidrissy ATH, Al Arabi K, Adam KA. 1983. The wrinkly skin syndrome: A report of two siblings from Saudi Arabia. Clin Genet 23: 308–310.

Kreuz FR, Wittwer BH. 1993. Del(2q)-cause of the wrinkly skin syndrome? Clin Genet 43:132–138.

Lees MH, Menashe VD, Sunderland CO, Morgan CL, Dawson PJ. 1969. Ehlers–Danlos syndrome associated with multiple pulmonary artery stenoses and tortuous systemic arteries. J Pediat 75:1031–1036.

Lisker R, Hernandez A, Martinez-Lavin M, Muchinick O, Armas C, Reyes P, Robles-Gil J. 1979. Gerodermia osteodysplastica hereditaria: Report of three affected brothers and literature review. Am J Med Genet 3:389–395.

Loeys B, Van Maldergem L, Mortier G, Coucke P, Gerniers S, Naeyaert JM, De Paepe A. 2002. Homozygosity for a missense mutation in fibulin-5 (FBLN5) results in a severe form of cutis laxa. Hum Mol Genet 11:2113–2118.

Okajima T, Fukumoto S, Furukawa K, Urano T. 1999. Molecular basis for the progeroid variant of Ehlers–Danlos syndrome. Identification and characterization of two mutations in galactosyltransferase I gene. J Biol Chem 274:28841–28844.

Patton MA, Baraitser M. 1993. Cutis laxa and the Costello syndrome. J Med Genet 30:622.

Patton MA, Tolmie J, Ruthnum P, Bamforth S, Baraitser M, Pembrey M. 1987. Congenital cutis laxa with retardation of growth and development. J Med Genet 24:556–561.

Pletcher BA, Fox JE, Boxer RA, Singh S, Blumenthal D, Cohen T, Brunson S, Tafreshi P, Kahn E. 1996. Four sibs with arterial tortuosity: Description and review of the literature. Am J Med Genet 66:121–128.

Roisner SH, Seelenfreund M, Ben-Bassat M. 1971. Cutis laxa associated with severe intrauterine growth retardation and congenital dislocation of the hip. Acta Paediatr Scand 60:357–360.

Rivera IR, Gomes L, Moises VA, Silva CC, Andrade JL, Carvalho AC. 2000. Multiple arterial anomalies in the newborn infant. Echocardiographic and angiographic diagnosis. Arq Bras Cardiol 75:137–144.

Sakati NO, Nyhan WL, Shear CS, Kattan H, Akhtar M, Bay C, Jones KL, Schackner XX. 1983. Syndrome of cutis laxa, ligamentous laxity, and delayed development. Pediatrics 72:850–856.

Wagstaff LA, Firth JC, Levin SE. 1970. Vascular abnormalities in congenital generalized elastolysis (cutis laxa): Report of a case. S Afr Med J 44: 1125–1127.

Welch JP, Aterman K, Day E, Roy DL. 1971. Familial aggregation of a "new" connective-tissue disorder: A nosologic problem. Birth Defects Orig Artic Ser 7:204–213.

Zlotogora J. 1999. Wrinkly skin syndrome and the syndrome of cutis laxa with growth and developmental delay represent the same disorder. Am J Med Genet 85:194.

4.3

747

SHORT REPORT

Homozygosity mapping of a gene for arterial tortuosity syndrome to chromosome 20q13

P J Coucke, M W Wessels, P Van Acker, R Gardella, S Barlati, P J Willems, M Colombi, A De Paepe

J Med Genet 2003;**40**:747–751

Background: Arterial tortuosity syndrome (ATS) is an uncommon connective tissue disorder of unknown aetiology. The most prominent feature is tortuosity of the large arteries, but lengthening, stenosis, and aneurysm formation are also frequent.
Methods: We performed a genomewide screen by homozygosity mapping of three consanguineous multiplex families, two from Morocco, and one from Italy, which included 11 ATS patients. The two families from Morocco may possibly have a common ancestor.
Results: We mapped the ATS gene to chromosome 20q13. Recombinations within an extended haplotype of 11 microsatellite markers localised the ATS gene between markers D20S836 and D20S109, an interval of 9.5 cM.
Conclusions: Cloning and completing functional and structural analysis of the ATS gene may provide new insights into the molecular mechanisms of elastogenesis.

Arterial tortuosity syndrome (ATS; MIM 208 050) is a rare connective tissue disorder characterised by generalised tortuosity, elongation, stenosis, and aneurysms of the major arteries.[1–4] Skin and joint abnormalities, including hyperextensibility or hyperlaxity of the skin, joint laxity or contractures, and inguinal hernias, reminiscent of other connective tissue diseases, can also be observed. Other phenotypic abnormalities include micrognathia, elongated face, high palate, beaked nose, sliding hernia, and ventricular hypertrophy. Histopathological studies show abnormalities of the elastin network in the large arteries.[2–5 7]

The mode of inheritance of ATS is autosomal recessive, but the disease gene has not yet been identified. Recently, the elastin gene and some collagen genes involved in connective tissue disease were excluded as candidate genes in ATS.[10] Until now, a very limited number of ATS patients have been described, and few multiplex families have been published. However, some inbred multiplex families originating from Morocco[9] and Italy[10] have recently been reported. Such families make it possible to localise the ATS gene by positional genetics. This study reports the localisation of the ATS gene by homozygosity mapping in two, and probably three, inbred families.

PATIENTS AND METHODS

Families

The three families, which included 11 ATS patients, originated from Morocco and Italy. All three families are inbred and the parents of all patients are consanguineous (fig 1). The two Moroccan families (family 1 with six affected individuals (IV-2, IV-3, IV-4, IV-5, IV-9, and IV-10) and family 2 with one affected individual (V-3)) might have a common ancestor as they originate from the same town in north Morocco. The clinical picture in these patients consists of tortuosity of the aorta, and pulmonary, subclavian, and renal arteries, as shown by echocardiography, angiography, and/or CT scan (table 1). Additional clinical features present in some of these patients were hyperlax skin and joints, and/or dilation, aneurysms, and stenosis of the pulmonary arteries and ascending aorta. All these clinical manifestations fit the spectrum of ATS, as reviewed by Wessels.[9] The phenotype of one individual (IV-1) in the Moroccan family 1 (fig 1) is unclear because no studies of the major arteries could be performed. The Italian family, originating from south Sicily, has four affected individuals (IV-1, IV-2, IV-4, IV-5). All patients show tortuosity of the major arteries, and two patients (IV-4 and IV-5) also show severe pulmonary artery stenosis. Variable cutaneous, joint, and facial manifestations were observed in all patients (table 1). Occasionally, gastric and inguinal hernias, intestine elongation, and keratoconus were present.

The parents and brother of the ATS patients were clinically normal. The clinical features of the different patients of all three families are described in detail elsewhere.[9 10]

Venous blood was taken for genetic studies from all 11 affected individuals, their parents, and healthy siblings. Informed consent was obtained in each instance from the subject and/or a legal guardian.

DNA analysis and pooling strategy

Genomic DNA was extracted from peripheral blood leukocytes by a standard technique.

A genome search was performed in family 1. To increase the speed of the total genome screen, the DNA samples of the six affected individuals of this Moroccan family were pooled. As it is critical that the pool contains equal quantities of DNA from each individual, DNA quantification was measured by ultraviolet light spectroscopy, followed by quantification on 1% agarose gels with a lambda quantification standard. Each individual sample was diluted to 50 ng/μl stock solution to avoid viscous solutions. Finally, a control PCR was performed on each sample to make sure that they all yielded the same amount of amplified product. Equimolar amounts of each sample were then combined, and the sample pool was assessed empirically by comparing alleles for several polymorphisms between pooled and individual samples (data not shown).

Homozygosity mapping

A set of 400 highly polymorphic microsatellite markers (ABI PRISM™ Linkage Mapping Set Version 2; Applied Biosystems, Foster City, CA, USA) with an average spacing

Abbreviations: ATS, arterial tortuosity syndrome; EDS, Ehlers-Danlos syndrome

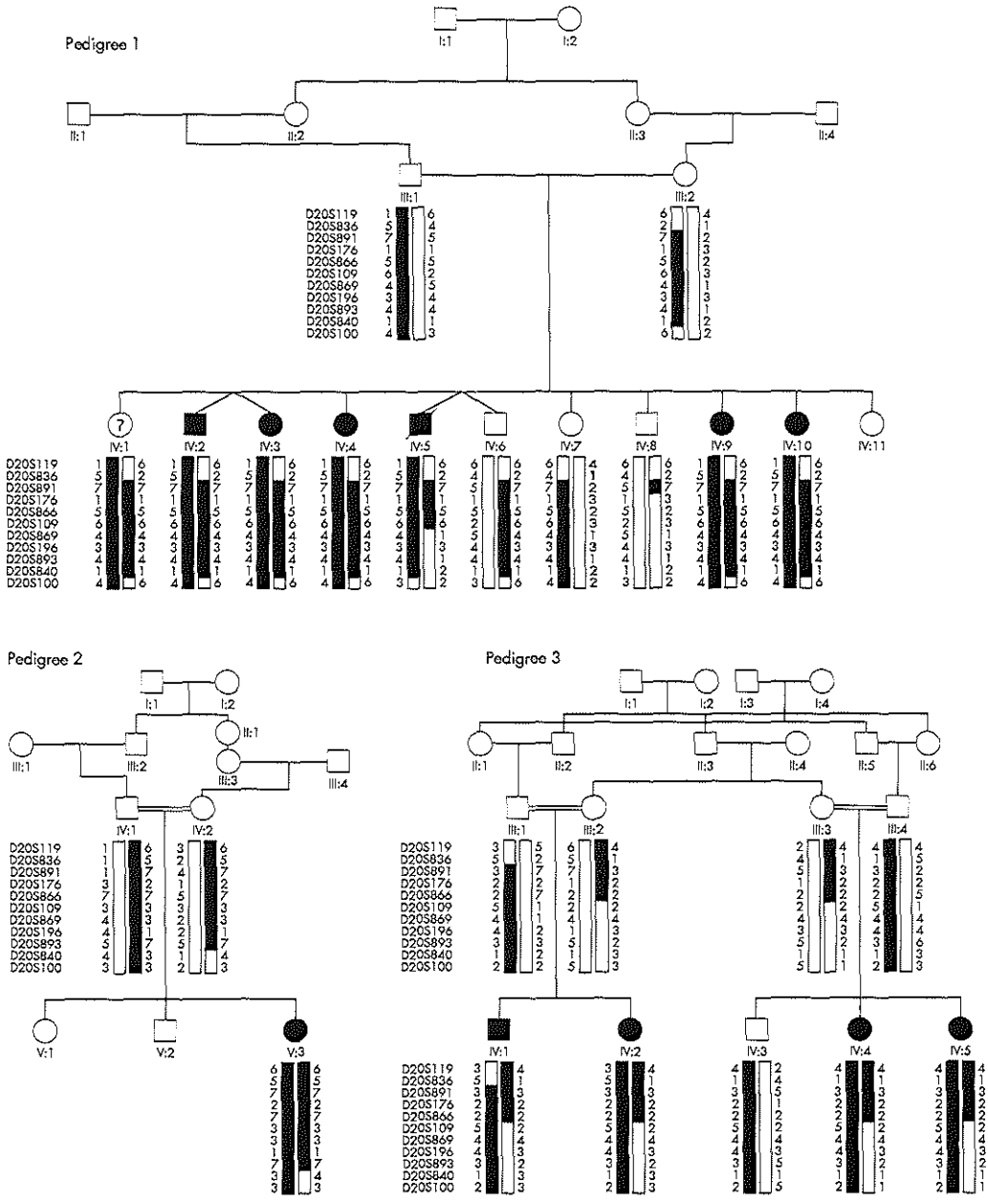

Figure 1 Pedigrees of the three consanguineous families. Pedigrees 1, 2, and 3 represent the Moroccan family 1, Moroccan family 2, and the Italian family respectively. Affected individuals are denoted by closed symbols, unaffected family members by open symbols, and individuals with unknown phenotype by open symbols with a question mark. Haplotypes for the chromosome 20 markers are shown below each family member for whom DNA was available. The solid portion of the bars indicates the haplotypes linked to the gene for ATS.

of 10 centimorgans (cM) was analysed on a capillary sequencer (ABI3100; Applied Biosystems). A pooled DNA sample, containing equimolar amounts of six affected individuals of family 1, was analysed. The data were processed using Genescan and Genemapper software (Applied Biosystems). After the finding of suggestive lod scores in family 1, the DNA of all individuals of the three families was further analysed with microsatellite markers from the Généthon genetic map. Markers were investigated on an ABI3100 capillary sequencer, and alleles were numbered according to length, with the shortest allele being assigned number 1. Haplotypes were constructed, assuming

Table 1 Clinical features of the ATS patients

Family	Individual	Age	Arterial anomalies: Tortuosity	Arterial anomalies: Arterial stenosis	Skin	Hernia	Joint laxity	Arachno dactyly	Pectus deformity	Other findings
Pedigree 1	IV–2	18 y	+	–	HES	–	+	+	–	Long face, high palate
	IV–3	18 y	+	+	Soft	–	+	+	–	Long face, high palate
	IV–4	17 y	+	–	Redundant	–	+	–	–	Long face, micrognathia, cleft palate
	IV–5	17 m	+	–	—	–	–	+	–	—
	IV–9	9 y	+	–	Cutis laxa	–	+	–	+	Micrognathia, high palate
	IV–10	8 y	+	–	Cutis laxa	–	+	–	+	Micrognathia, cleft palate
Pedigree 2	V–3	2 m	+	–	HES	+	+	+	+	Micrognathia, cleft palate, blepharophimosis, arterial aneurysm
Pedigree 3	IV–1	21 y	+	–	Soft	+	+	–	–	Soft nasal cartilage, micrognathia, hypothyroidism
	IV–2	16 y	+	–	Soft	+	+	–	–	Soft nasal cartilage, micrognathia, keratoconus, hypothyroidism
	IV–4	21 y	+	+	Laxity	–	+	–	–	Soft nasal cartilage, micrognathia
	IV–5	19 y	+	+	Laxity	–	+	–	–	Soft nasal cartilage, micrognathia

HES, hyperextensibility of the skin; m, months; y, years.

the minimal number of recombinations, by tracing segregation of alleles in the families using the published marker order (fig 1).

MLINK was used to calculate two-point lod scores between the ATS locus and the markers. The analysis was performed under the assumption of autosomal recessive inheritance of the phenotype with complete penetrance. Individual IV:1 of pedigree 1 was considered to have an unknown phenotype in the linkage analysis. The influence on the lod score is therefore 0, but the inclusion of this sample was helpful in the reconstruction of the haplotypes. Equal allele frequencies were used in the linkage calculations. Although the use of incorrect allele frequencies may lead to false positive evidence of linkage under certain conditions, the power to detect true linkage remained unaffected. The frequency of the ATS was set at 0.00001. LINKMAP was used to perform multipoint linkage analysis using the marker order: centromere –D20S836–1.9 cM–D20S891–7.6 cM–D20S109–telomere.

Mutation screening of the beta GlcNAc beta 1, 4-galactosyltransferase 5 Gene (*B4GALT5*)

PCR products for each of the nine exons of the *B4GALT5* gene were obtained for an affected individual of each of the three families (family1, IV-9; family2, V-3; family3, IV-4). Mutation screening was performed by direct sequencing of the PCR products using dye terminator chemistry (Applied Biosystems).

RESULTS

Genomewide scan

To map the ATS gene, a genomewide scan was performed by homozygosity mapping using pooled DNA from six affected individuals of family 1 (fig 1). Homozygosity mapping of autosomal recessive conditions in inbred families is based upon the fact that affected subjects will be homozygous for polymorphic markers in and around the disease locus due to inbreeding. In our genome scan, 400 polymorphic microsatellite markers, equally spread over the genome, were analysed. In the pool of six patients from family 1 this yielded 10 different markers with a single allele flanked at both sides by a marker with, at most, two different alleles. Subsequently, these 10 markers were typed for each individual member from family 1. This revealed a two-point lod score of 4.11 at $\theta = 0$ for marker D20S178 located in chromosome 20q13, whereas the other nine markers revealed lod scores lower than 1.5. Further analysis of the chromosome 20q13 region was performed in all three ATS families using additional markers (fig 2) originating from the

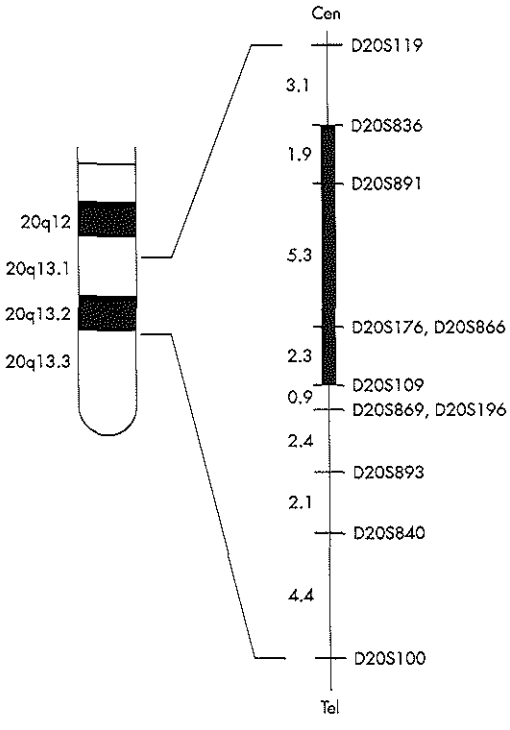

Figure 2 Linkage map of the markers used in the analysis. The genetic distances between the markers were deduced from the Généthon linkage map[16], and are indicated in cM. The candidate region for ATS syndrome is indicated in bold.

Table 2 Two-point lod scores for markers at 20q13

Marker	Theta	Lod score Ped 1	Ped 2	Ped 3	Z_{max} combined
D20S119	0.06	2.29	0.59	1.16	4.04
D20S836	0.06	2.46	0.59	1.14	4.19
D20S891	0.00	4.11	0.75	3.13	7.99
D20S176	0.00	2.17	0.75	2.19	5.11
D20S866	0.00	2.18	0.68	1.18	4.04
D20S109	0.04	3.80	0.50	0.00	4.30
D20S869	0.03	2.37	0.67	1.36	4.40
D20S196	0.04	2.01	0.65	0.33	2.99
D20S893	0.13	0.81	0.36	0.20	1.37
D20S840	0.14	0.79	−0.09	0.69	1.39
D20S100	0.28	0.19	0.17	−0.02	0.34

Ped, pedigree.

Généthon genetic map. This yielded a combined maximum lod score of 7.99 at $\theta = 0$ for D20S891 (table 2).

Lod scores calculated for the three families separately yielded a maximum of 4.11, 0.75, and 3.13 at $\theta = 0$ for marker D20S891 for the Moroccan family 1, the Moroccan family 2 (the two possibly related families), and the Italian family, respectively (table 2). This suggests that the ATS gene in both the large Moroccan family 1 and the Italian family maps to this region on chromosome 20q13. The positive lod scores in the Moroccan family 2 with a single ATS patient is also compatible with linkage to the same region.

Normal haplotypes, as identified in carrier parents, were different from those segregating with the disease. The unaffected subjects were heterozygous or homozygous for the normal haplotypes. The individual with the unknown phenotype (individual IV-1 in Moroccan family 1) was homozygous for the disease haplotype, and might be affected. Multipoint linkage calculations between the ATS locus and markers D20S836, D20S891, and D20S109 revealed a maximum lod score of 7.99 at marker D20S891 (fig 3).

Haplotypes were constructed, revealing key recombinants between marker D20S836 and the ATS gene at the proximal side (Moroccan family 1 and Italian family), and between marker D20S109 and the ATS gene at the telomere side

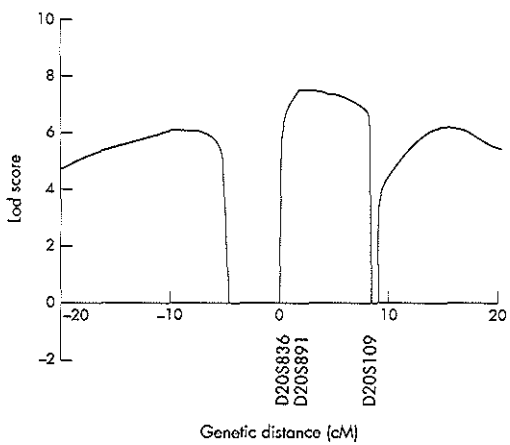

Figure 3 Multipoint linkage analysis between ATS and three chromosome 20q markers. Curves indicate the likelihood that the ATS locus is at the map location with respect to the adjacent markers shown below the horizontal axis. The relative genetic position of D20S836 was arbitrarily placed at zero.

(Italian family) of the chromosome (fig 1). These recombinational events localise the gene for ATS between D20S836 and D20S109 in a genetic interval of 9.5 cM on the Généthon map (fig 2). On the draft sequence of the human genome in the National Center for Biotechnology Information (NCBI) database, this linkage interval corresponds to a physical candidate region of approximately 4.1 Mb.

Candidate gene study in region of interest

A computer search in the human genome resources of NCBI, ENSEMBL, and UCSC revealed over 30 positional candidate genes within the linkage interval between markers D20S836 and D20S109 on chromosome 20q. One of these, *B4GALT5* (EC 2.4.1.22), encodes for beta 4 galactosyl transferase, one of the galactosyl transferases involved in the biosynthesis of glycosaminoglycans.[11] This group of enzymes catalyses the transfer of galactose to galactose beta-1, 4-N-acetylglucosamine, during the formation of different glycoconjugates and saccharide structures. Mutations in another member of the galactosyl transferase gene family, *B4GALT7* (EC 2.4.1.133), have been identified in patients with a progeroid variant of Ehlers-Danlos syndrome (EDS).[12–14] As progeroid EDS disease shares some of the features of ATS, the *B4GALT5* gene was considered a good candidate gene for ATS. Direct sequencing of the nine exons of *B4GALT5* from an affected individual of each of the three ATS families showed no sequence alterations in the coding region. A substitution in intron 3 (IVS3-16 C→T) was identified in the two Moroccan families, and segregated completely with ATS in both. However, this mutation is an uncommon polymorphism in the Moroccan population (frequency of the T allele is 0.07). Other positional candidate genes are *PRKCBP1, NCOA3, PREX, ARFGEF2, CSE1L, STAU, ARPC3B, DDX27, KCNB1,* and *PTGIS,* among others. However, none of these genes is an obvious functional candidate for ATS.

DISCUSSION

In this study we describe the mapping of the gene for arterial tortuosity syndrome (ATS) to a small region on chromosome 20q13. Initially, a genomewide scan was performed on a DNA sample pooled from six affected individuals from a large consanguineous Moroccan family. A single region on the long arm of chromosome 20 was shared by all patients. The homozygosity mapping was confirmed by linkage analysis in three consanguineous ATS kindreds with a total of 11 patients. Multipoint linkage analysis yielded maximum lod scores of 7.99 at marker D20S891 on chromosome 20q13. Analysis of key recombinational events indicated a linkage region of 9.5 cM on the Généthon genetic map (fig 2), which represents 4.1 Mb on to the physical map of chromosome 20q13.

As only three ATS families were investigated, we cannot exclude genetic heterogeneity. However, as ATS is a rare disorder, but two and possibly three families are linked to the same locus, it could be speculated that there is only a single ATS locus.

Based on the different databases, the candidate region for ATS contains over 30 predicted genes. Although the theoretical search for plausible functional candidate genes for ATS is highly speculative, genes (or homologues of structural genes) involved in the extracellular matrix are possible candidates, particularly those involved in the elastogenesis pathway. All major arteries contain a large amount of elastic fibres consisting of elastin, which together with the fibrillins and microfibril associated proteins are responsible for elasticity.[15] Mutations in *FBN1* (Marfan's syndrome), *FBN2* (Beal's syndrome), elastin (Williams' syndrome), fibulin 5 (cutis laxa type I) and *ABCC6* (PXE) all give rise to abnormalities in the elastic network. However,

these disease genes are not located in the linkage interval of ATS on chromosome 20q.

B4GALT5, a functional candidate gene for ATS located in the candidate interval, was excluded by mutation analysis in the patients. None of the remaining positional candidate genes has an obvious relationship with the extracellular matrix or the elastogenesis pathway. The mouse syntenic region of human chromosome 20q13 is located on chromosome 2q; however, no extra obvious candidate genes for ATS have been localised to this region.

In conclusion, we have identified a locus for ATS on chromosome 20q13, which is an important step in the identification of the ATS gene. Cloning and completing functional and structural analysis of the ATS gene may provide new insights into the molecular mechanisms of elastogenesis.

ACKNOWLEDGEMENTS

We thank Dr G Mancini, Dr Catsman, Dr J Hoogeboom and Prof M Breuning for help with the clinical study of the families, Dr W. Kleijer for patient fibroblasts and Dr D Halley for patient DNA. This work was supported by Fondazione Cariplo, 2001, Italy.

Electronic database Information. Online Mendelian Inheritance in Man (OMIM), http://www.ncbi.nlm.nih.gov/Omim/.Généthon, http://www.genethon.en/php/index.php/. National Centre for Biotechnology Information (NCBI), http://www.ncbi.nlm.nih.gov/.

University of California Santa Cruz (UCSC), http://genome.cse.ucsc.edu/. Ensembl database, http://www.ensembl.org/

Authors' affiliations
P J Coucke, P Van Acker, A De Paepe, Center for Medical Genetics, Ghent University Hospital, Ghent, Belgium
M W Wessels, Department of Clinical Genetics and Obstetrics and Gynecology, Erasmus University Medical Center, Rotterdam, The Netherlands
R Gardella, S Barlati, M Colombi, Division of Biology and Genetics, Department of Biomedical Sciences and Biotechnology, University of Brescia, Brescia, Italy
P J Willems, Synergene, Antwerp, Belgium

Correspondence to: Paul Coucke, Ghent University Hospital, Department of Medical Genetics, De Pintelaan 185, B-9000 Ghent, Belgium; paul.coucke@rug.ac.be

REFERENCES

1 **Beuren AJ**, Hort W, Kalbfleisch H, Muller H, Stoermer J. Dysplasia of the systemic and pulmonary arterial system with tortuosity and lengthening of the arteries. A new entity, diagnosed during life, and leading to coronary death in early childhood. *Circulation* 1969;**39**:109–15.
2 **Lees MH**, Manashe VD, Sunderland CO, Mgan CL, Dawson PJ. Ehlers-Danlos syndrome associated with multiple pulmonary artery stenoses and tortuous systemic arteries. *J Pediat* 1969;**75**:1031–136.
3 **Welch JP**, Aterman K, Day E, Roy DL. Familial aggregation of a "new" connective-tissue disorder: a nosologic problem. *Birth Defects Orig Artic Ser* 1971;**7**:204–113.
4 **Ades LC**, Knight WB, Byard RW, Bateman JF, Esquivel JA, Mee RB, Haan EA, Milewicz DM. Clinicopathologic findings in congenital aneurysms of the great vessels. *Am J Med Genet* 1996;**66**:289–99.
5 **Pletcher BA**, Fox JE, Boxer RA, Singh S, Blumenthal D, Cohen T, Brunson S, Tafreshi P, Kahn E. Four sibs with arterial tortuosity: description and review of the literature. *Am J Med Genet* 1996;**66**:121–8.
6 **Al Fadley F**, Al Manea W, Nykanen DG, Al Fadley A, Bulbul Z, Al Haleas Z. Severe tortuosity and stenosis of the systemic, pulmonary and coronary vessels in 12 patients with similar phenotypic features: a new syndrome? *Cardiol Young* 2000;**10**:582–9.
7 **Franceschini P**, Guala A, Licata D, Di Cara G, Franceschini D. Arterial tortuosity syndrome. *Am J Med Genet* 2000;**91**:141–3.
8 **Rivera IR**, Gomes L, Moises VA, Silva CC, Andrade JL, Carvalho AC. Multiple arterial anomalies in the newborn infant. Echocardiographic and angiographic diagnosis. *Arq Bras Cardiol* 2000;**75**:137–44.
9 **Wessels MW**, Catsman-Berrevoets CE, Mancini G, *et al*. Three new families with arterial tortuosity syndrome. Submitted.
10 **Gardella R**, Zoppi N, Assanelli D, *et al*. Exclusion of candidate genes in a family with arterial tortuosity syndrome. Submitted.
11 **Sato T**, Furukawa K, Bakker H, Van den Eijnden DH, Van Die I. Molecular cloning of a human cDNA encoding beta-1, 4-galactosyltransferase with 37% identity to mammalian UDP-Gal:GlncNAc beta-1,4-galacotsyltransferase. *Proc NatlAcad Sci USA* 1998;**95**:472–7.
12 **Quentin E**, Gladen A, Roden L, Krasse H. A genetic defect in the biosynthesis of dermatan sulfate proteoglycan: galactosyltransferase I deficiency in fibroblasts from a patient with a progeroid syndrome. *Proc Natl Acad Sci USA* 1990;**87**:1342–6.
13 **Okajima T**, Fukumoto S, Furukawa K, Urano T. Molecular basis for the progeroid variant of Ehlers-Danlos syndrome. Identification and characterization of two mutations in galactosyltransferase I gene. *J Biol Chem* 1999;**274**:28841–4.
14 **Almeida R**, Levery SB, Mandel U, Kresse H, Schwientek T, Bennett EP, Clausen H. Cloning and expression of a proteoglycan UDP-galactose:beta-xylose beta-1,4-galactosyltransferase I: a seventh member of the human beta4-galactosyltransferase gene family. *J Biol Chem* 1999;**274**:26165–71.
15 **Rosenbloom J**, Abrams WR. Elastin and the microfibrillar apparatus. In: Royce PM and Steinmann B, eds. *Connective Tissue and its heritable disorders*. New York: Wiley-Liss, Inc, 2002:249–70.
16 **Dib C**, Faure S, Fizames C, Samson D, Drouot N, Vignal A, Millasseau P, Marc S, Hazan J, Seboun E, Lathrop M, Gyapay G, Morissette J, Weissenbach J. A comprehensive genetic map of the human genome based on 5,264 microsatellites. *Nature* 1996;14:152–4.

4.4

LETTERS

nature genetics

Mutations in the facilitative glucose transporter GLUT10 alter angiogenesis and cause arterial tortuosity syndrome

Paul J Coucke[1], Andy Willaert[1], Marja W Wessels[2], Bert Callewaert[1], Nicoletta Zoppi[3], Julie De Backer[1], Joyce E Fox[4], Grazia M S Mancini[2], Marios Kambouris[5], Rita Gardella[3], Fabio Facchetti[6], Patrick J Willems[7], Ramses Forsyth[8], Harry C Dietz[9], Sergio Barlati[3], Marina Colombi[3], Bart Loeys[1] & Anne De Paepe[1]

© 2006 Nature Publishing Group http://www.nature.com/naturegenetics

Arterial tortuosity syndrome (ATS) is an autosomal recessive disorder characterized by tortuosity, elongation, stenosis and aneurysm formation in the major arteries owing to disruption of elastic fibers in the medial layer of the arterial wall[1]. Previously, we used homozygosity mapping to map a candidate locus in a 4.1-Mb region on chromosome 20q13.1 (ref. 2). Here, we narrowed the candidate region to 1.2 Mb containing seven genes. Mutations in one of these genes, *SLC2A10*, encoding the facilitative glucose transporter GLUT10, were identified in six ATS families. GLUT10 deficiency is associated with upregulation of the TGFβ pathway in the arterial wall, a finding also observed in Loeys-Dietz syndrome, in which aortic aneurysms associate with arterial tortuosity[3]. The identification of a glucose transporter gene responsible for altered arterial morphogenesis is notable in light of the previously suggested link between GLUT10 and type 2 diabetes[4,5]. Our data could provide new insight on the mechanisms causing microangiopathic changes associated with diabetes and suggest that therapeutic compounds intervening with TGFβ signaling represent a new treatment strategy.

Facilitative glucose transporters (GLUTs), encoded by a family of *SCL2A* genes, are responsible for the uptake of several monosaccharides, including glucose, fructose, mannose, galactose and glucosamine. So far, mutations in two of these genes have been linked to genetic disorders with intuitive relevance to altered glucose metabolism. Heterozygous mutations in *SLC2A1* cause a defect of glucose transport into the brain, resulting in an epileptic encephalopathy with low spinal-fluid glucose levels[6]. Homozygous mutations in *SLC2A2* have been shown to cause Fanconi-Bickel syndrome, characterized by hepatorenal glycogen accumulation, nephropathy and diarrhea[7], whereas heterozygous mutations in this gene result in non–insulin dependent diabetes mellitus[8,9].

We report that loss-of-function mutations in a third member of the *SLC2A* family, *SLC2A10*, cause arterial tortuosity syndrome (ATS; OMIM 208050), an autosomal recessive condition[1] characterized by tortuosity of the large and medium-sized arteries (**Fig. 1a**), often resulting in death at young age. Other typical features include aneurysms of large arteries and stenosis of the pulmonary artery, in association with facial features (**Fig. 1b**) and several connective tissue manifestations. Histopathological findings include fragmentation of the elastic fibers in the tunica media of the large arteries (**Fig. 1c**)[10–13]. Previously, homozygosity mapping in 21 members of two consanguineous families with ATS originating from Morocco (family 1) and Italy (family 4; **Fig. 1d**) assigned the gene to chromosome 20q13.1 (ref. 2). Subsequently, this localization was confirmed in four smaller families originating from Morocco (families 2 and 3) and the Middle East (family 5 and 6). Key recombinants delineated a candidate linkage interval of 4.1 Mb between markers D20S836 and D20S109. We performed further fine mapping in three families (families 1–3) originating from the same region in Morocco, under the assumption that one recessive ancestral mutation might have caused ATS in these families. Families 1 and 2, but not family 3, shared haplotypes between markers D20S888 and μSAT11 (**Fig. 1e**), a region of 1.2 Mb containing seven genes (*SLC13A3*, *TP53RK*, *SLC2A10*, *EYA2*, *PRKCBP1*, *NCOA3*, *SULF2*) and one pseudogene (*RPL35AP*). We sequenced these genes directly and identified homozygous mutations (deletion, nonsense, missense) in the *SLC2A10* gene in all six families (**Fig. 2a,b**). In families 1 and 2, we found a homozygous nonsense mutation 510G→A (W170X) in all clinically affected individuals. All affected individuals in families 3 and 4 were homozygous for frameshift mutations 961delG (V321fsX391) and 1334delG (G445fsX484), respectively. Both mutations result in a premature stop codon. The affected individuals from families 5 and 6 shared the same homozygous missense mutation, 243C→G (S81R). Both families had a common haplotype between markers μSAT1 and μSAT7, indicating a

[1]Center for Medical Genetics, Ghent University, B-9000 Ghent, Belgium. [2]Department of Clinical Genetics, Erasmus University Medical Center, 3015 GD Rotterdam, The Netherlands. [3]Division of Biology and Genetics, Department of Biomedical Sciences and Biotechnology, University of Brescia, Brescia 25123, Italy. [4]Department of Pediatrics, North Shore University Hospital, Manhasset, New York 11030, USA. [5]Yale University School of Medicine, New Haven, Connecticut 06510, USA. [6]Department of Pathology, University of Brescia, Brescia, Italy. [7]GENDIA, B-2000 Antwerp, Belgium. [8]Department of Pathology, Ghent University, B-9000 Ghent, Belgium. [9]McKusick-Nathans Institute of Genetic Medicine and Howard Hughes Medical Institute, Johns Hopkins School of Medicine, Baltimore 21205, Maryland, USA. Correspondence should be addressed to P.J.C. (paul.coucke@ugent.be).

Received 13 October 2005; accepted 13 February 2006; published online 19 March 2006; doi:10.1038/ng1764

© 2006 Nature Publishing Group http://www.nature.com/naturegenetics

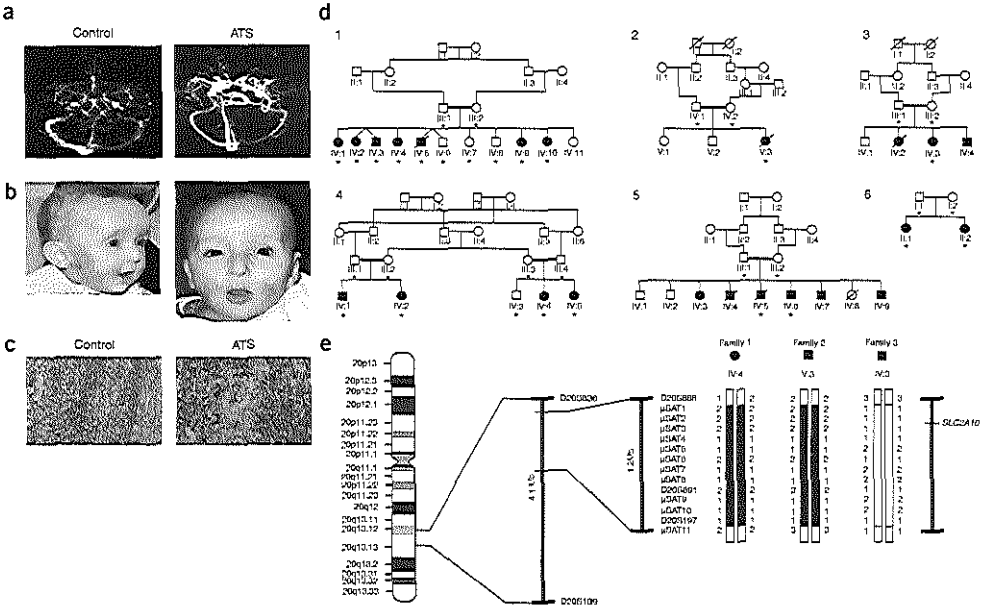

Figure 1 Clinical anomalies in ATS and pedigrees. (a) MR angiography showing typical arterial tortuosity of the cerebral arteries in an individual with ATS (IV:4 in family 1) in comparison with a healthy aged-matched control. (b) Typical facial phenotype with micrognathia, elongated face, down-slanting palpebral fissures, blepharophimosis and a beaked nose (individual IV:4 in family 1). (c) Organization of elastic fibers in a control and in an individual with ATS, as shown by orcein staining. Aorta elastic laminae in the media of an individual with ATS are coarser, less abundant and more disorganized than in control aorta. Magnification: 400×. (d) Pedigree structure of the six ATS families. Symbols: circle, female; square, male; open symbol, unaffected; filled symbol, affected; slash line, deceased; double relationship line, consanguinity. Asterisks indicate that DNA, fibroblasts or both are available. (e) Ideogram of chromosome 20 showing the initial linkage interval, the final candidate region and haplotypes for chromosome 20q13.1 markers in the candidate region in families 1–3.

npg

founder mutation in these families (data not shown). We assume that the latter mutation causes disease on the basis of the following arguments: (i) Ser81 is evolutionarily strictly conserved in GLUT10 (Fig. 2b); (ii) an uncharged amino acid is changed to a positively charged amino acid in the third transmembrane domain and (iii) the mutation was absent in 200 control chromosomes. All parents of affected individuals (in families 1–6) were heterozygous for the respective mutations.

The presence of homozygous loss-of-function mutations in at least four ATS families identifies *SLC2A10* as the gene responsible for ATS. The gene contains five exons and encodes GLUT10, a 541-residue glucose transporter[14–16]. Human GLUT10 has been shown to facilitate D-glucose, D-galactose and 2-deoxy-D-glucose transport when expressed in *Xenopus laevis* oocytes[4]. GLUT10 is an outlier within the GLUT family because of its longer exofacial loop and differences in motif characteristics for glucose transporters, suggesting that GLUT10 may have additional functions, different from other GLUT family members[4,5].

Tissue expression analysis has uncovered a widespread distribution of *SLC2A10* mRNA, mainly in liver, pancreas and adipose tissue[4,5,17]. We studied mRNA and protein expression of GLUT10 in cultured skin fibroblasts and vascular smooth muscle cells (VSMCs) from individuals affected with ATS and from controls. Quantitative PCR (Q-PCR) of samples derived from individuals with ATS homozygous for premature stop codon mutations demonstrated a near-absence of *SLC2A10* mRNA in VSMCs as well as in fibroblasts (Fig. 2c), as expected by virtue of clearance of mutant transcripts by the nonsense-mediated mRNA decay (NMD) pathway. We observed normal *SLC2A10* mRNA expression in samples derived from an individual with ATS homozygous for the 243C→G missense mutation. We observed (peri)nuclear localization of GLUT10 in normal individuals, but there was no detectable GLUT10 signal in individuals with ATS, as shown by immunofluorescence analysis of cultured skin fibroblasts and VSMCs (Fig. 2d). An additional argument to suggest a nuclear localization of GLUT10 is the low dissociation constant (K_m = 0.3 mM), which is compatible with the glucose concentration in the cytoplasm[4].

The *SLC2A10* gene has previously been considered as a candidate gene for diabetes because of its function in glucose transport and its map position, which coincides with a type 2 diabetes locus[4,5]. However, a causal role for *SLC2A10* in diabetes has not been demonstrated[18,19]. Theoretically, homozygous mutations in *SLC2A10* could lead to ATS, whereas heterozygous mutations could lead to diabetes, analogous to the situation where homozygous mutations in *SLC2A2*

LETTERS

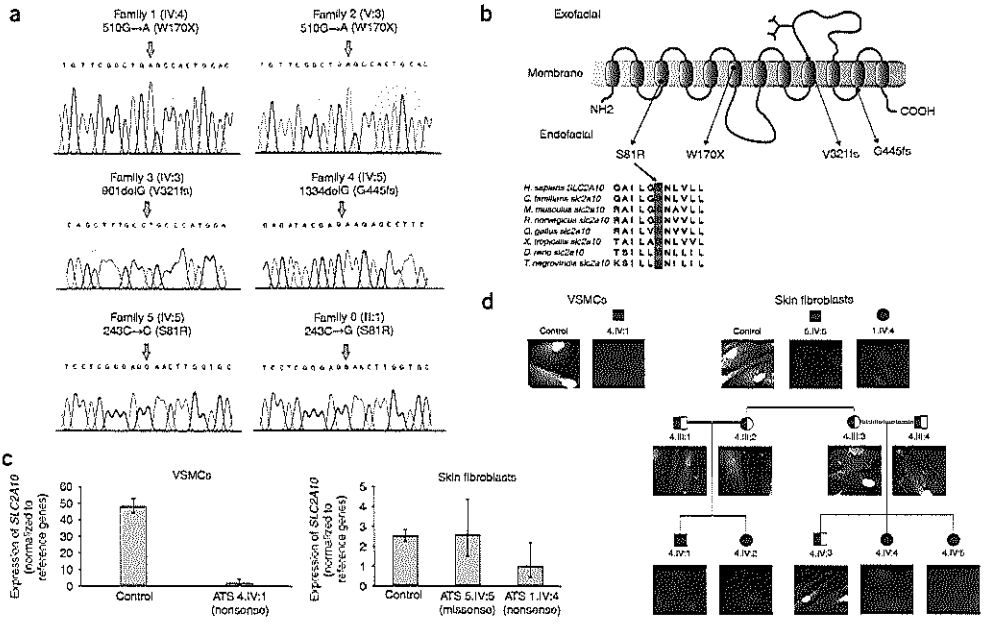

Figure 2 *SLC2A10* (GLUT10) mutation and expression data. (a) *SLC2A10* mutations identified in families 1–6. (b) Location of GLUT10 mutations at a schematic representation of the GLUT10 protein. GLUT10 contains 12 hydrophobic transmembrane domains (ovals) with a hydrophilic endofacial loop between transmembrane domains 6 and 7 and a large exofacial loop containing a potential N-linked glycosylation site between transmembrane domains 9 and 10. Evolutionary conservation of the substituted amino acid observed in families 5 and 6 in GLUT10 is shown. (c,d) *SLC2A10* (GLUT10) expression in the control and in individuals with ATS. (c) mRNA expression of *SLC2A10* as determined by Q-PCR in VSMCs and skin fibroblasts. In VSMCs in individuals with ATS, the level of mRNA was severely reduced. In skin fibroblasts, the individual carrying a homozygous nonsense mutation also showed a significant reduction ($P < 0.05$) compared with the control, but the individual homozygous for a missense mutation did not show any reduction. Bars indicate the 95% confidence interval of the mean expression level. (d) Immunofluorescence analysis of GLUT10 in VSMCs and skin fibroblasts. Expression of GLUT10 was nearly absent in VSMCs and fibroblasts from individuals with ATS, as compared with the control. The fluorescence signal in heterozygous individuals was approximately half that of the controls. Magnification: 1,000×.

lead to Fanconi-Bickel syndrome[7] and heterozygous mutations to diabetes[8]. However, this hypothesis is unlikely, given that we did not observe an increased frequency of diabetes in the heterozygotes from the ATS families.

There is substantial phenotypic overlap between ATS and a newly identified genetic condition called Loeys-Dietz syndrome (LDS; OMIM 609192) that associates arterial tortuosity with aneurysm formation[3]. Other findings in common between the two conditions include arachnodactyly, joint laxity or contractions, microretrognathia, hypertelorism, cleft palate and/or bifid uvula (**Table 1**). LDS is caused by heterozygous loss-of-function mutations in the genes encoding the type 1 or type 2 TGFβ receptors (*TGFBR1* or *TGFBR2*). This leads to a paradoxical increase in TGFβ signaling in the arterial wall, as evidenced by increased phosphorylation and nuclear translocation of Smad2 (pSmad2), a downstream effector of the TGFβ signaling pathway, and increased expression of downstream targets of TGFβ such as connective tissue growth factor (CTGF) and collagens[3]. Because of the clinical overlap with LDS, we investigated whether the TGFβ pathway is involved in the pathogenesis of ATS.

Immunostaining for pSmad2 and CTGF (**Fig. 3a**) in the arterial wall of an individual with ATS demonstrated increased signal intensity compared with control specimens, similar to the increase observed in individuals with LDS[3]. In agreement with the *in vivo* observations, Q-PCR measurements showed a significantly higher steady-state mRNA expression level for CTGF (**Fig. 3b**) in cultured VSMCs of the individual with ATS compared with controls ($P < 0.05$), indicative of upregulation of TGFβ signaling.

The mechanisms by which mutations in *SLC2A10* lead to TGFβ activation are unclear. Notably, the expression of decorin, a proteoglycan inhibitor of TGFβ signaling[20], is regulated by a defined glucose response element in its gene promoter[21]. Therefore, we studied the expression of decorin in cultured VSMCs of individuals with LDS, individuals with ATS and controls (**Fig. 4**). Decorin expression was severely reduced in cultured VSMCs of individuals with ATS as compared with controls, as shown by immunofluorescence staining (**Fig. 4a**). Q-PCR experiments using VSMCs confirmed the reduced expression of decorin mRNA in individuals with ATS (**Fig. 4b**). The specific decrease of decorin expression in individuals with ATS, in contrast to individuals with LDS, might indicate divergent mechanisms

© 2006 Nature Publishing Group http://www.nature.com/naturegenetics

Table 1 Clinical comparison of individuals with ATS and individuals with LDS

Symptoms	ATS	LDS
Arterial anomalies		
Tortuosity	+++	+++
Aneurysms	+	+++
Stenosis a. pulmonalis	++	0
Aneurysm a. pulmonalis	+	++
Skin laxity	+++	+
Skeletal anomalies		
Contractures	++	++
Pectus deformity	+	++
Joint laxity	+++	+++
Arachnodactyly	+	++
Facial anomalies		
Hypertelorism	+	+++
Cleft palate, bifid uvula	++	+++
Micrognathia	+++	++

0, not described; +, present; ++, common; +++, typical

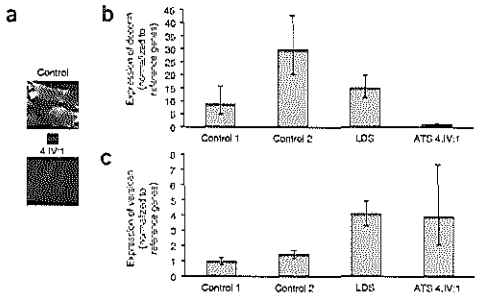

Figure 4 Immunofluorescence and Q-PCR analysis of decorin and versican in VSMC. (**a**) In individual 4.IV:1 with ATS, expression of decorin is nearly absent, as compared with control VSMCs. Magnification: 1,000×. (**b**,**c**) Q-PCR analysis for (**b**) decorin and (**c**) versican in VSMCs of an individual with ATS compared with an individual with LDS and two controls. The expression of decorin mRNA in the individual with ATS is significantly lower ($P < 0.05$) than in the LDS patient and the controls, whereas the expression of versican is significantly higher ($P < 0.05$) in the individual with ATS and the individual with LDS compared with controls. Bars indicate the 95% confidence interval of the mean expression level.

for upregulation of TGFβ signaling in these two conditions. Notably, we did not observe any differences in expression between fibroblasts of individuals with ATS and those of healthy controls (data not shown). Given the (peri)nuclear localization of GLUT10, a decrease in intracellular glucose and failure of glucose-mediated transcriptional upregulation of the decorin promoter seems to be unique to ATS. In contrast, primary alterations in the TGFβ receptors lead to increased TGFβ signaling in LDS. In order to determine the specificity of the decorin response, we monitored the expression of versican, a proteoglycan that is known not to be strongly regulated by glucose but whose expression is driven by TGFβ[22]. As predicted from our pathogenetic model, samples from patients with either ATS or LDS showed increased expression of versican (**Fig. 4c**). An inhibitory role of versican on elastic fiber assembly has been proposed[23], perhaps providing a mechanism for failed elastogenesis in both ATS and LDS.

Although TGFβ signaling is disturbed in cells and connective tissue derived from individuals with ATS, other mechanisms leading to abnormal matrix deposition cannot be excluded. Impaired uptake or transport of other monosaccharides could hinder glycosylation events important for the production of mature glycoproteins and proteoglycans, essential structural components of the arterial wall and connective tissue in general.

We were surprised to identify a glucose transporter gene responsible for a connective tissue disorder. No other connective tissue disorder, with the exception of pseudoxanthoma elasticum (caused by a mutation in *ABCC6*), is known to be caused by a transporter protein defect[24]. No clear function of the ABCC6 transporter has been identified, and the underlying pathogenic mechanism leading to disturbed elastin homeostasis in PXE is unknown. Insights derived from the study of ATS may prove relevant to other disorders related to failed intracellular transport of glucose. Indeed, the microangiopathic changes and fibrosis seen in diabetic retinopathy, nephropathy and peripheral vascular disease correlate with increased TGFβ signaling[25]. Diabetes-associated arteriolar tortuosity is seen in tissues undergoing postnatal angiogenesis, including the retinal and coronary microcirculations, perhaps recapitulating events occurring on a broader scale during embryogenesis in ATS. These data suggest that antagonism of TGFβ signaling may contribute to therapeutic advances in a wide variety of genetically determined and acquired disorders, including ATS.

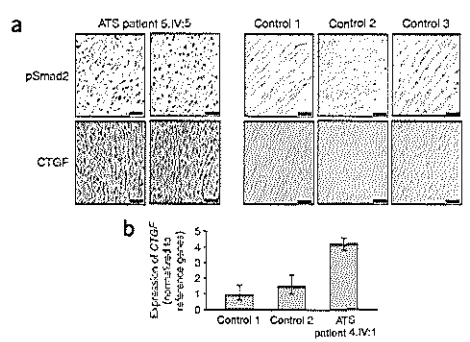

Figure 3 Immunostaining and Q-PCR analysis for phosphorylated Smad2 and CTGF in arterial tissue. (**a**) Three controls and individual 5.IV:5 with ATS were examined. Note the increased intensity of nuclear phosphorylated Smad2 and extracellular CTGF. Scale bars, 10 μm. (**b**) Expression levels of CTGF in VSMCs of affected individual IV:1 of family 4 and two controls in steady-state conditions, as measured by Q-PCR. CTGF shows fourfold higher expression in the individual with ATS. Bars indicate the 95% confidence interval of the mean expression level.

METHODS

Patients. Appropriate informed consent, including specific consent to publish the photos in **Figure 1b**, was obtained from all patients involved in the study. Detailed clinical descriptions of five ATS families, except for family 6, have been

© 2006 Nature Publishing Group http://www.nature.com/naturegenetics

LETTERS

published previously[1,12,26]. DNA was extracted from peripheral blood and/or cultured skin fibroblasts. Skin fibroblasts were cultured in Dulbecco's modified Eagle's medium (DMEM) supplemented with 15% fetal bovine serum (FBS) in the presence of antibiotics. Vascular smooth muscle cells (VSMCs) were obtained from the aortic media from individual IV:1 with ATS in family 4 and from an individual with LDS (TGFBR1 mutation, R487P)[3] and were cultured in smooth muscle basal medium supplemented 5% FBS, 0.2% fibroblast growth factor (FGF), 0.1% insulin, 0.1% epidermal growth factor (EGF), and 0.1% gentamicin sulfate/amphotericin. Paraffin-embedded aortic tissue was available only from individual IV:5 in family 5.

Microsatellite and sequence analysis. Microsatellite markers in the ATS linkage region on chromosome 20q13.1 (ref. 2) were taken from the Marshfield map or designed based on the simple tandem repeat finder in the University of California Santa Cruz genome browser (μSAT1-11). We carried out genotyping on an Applied Biosystems Prism 3100 Genetic Analyzer (Applied Biosystems). The data were processed using Genescan software (Applied Biosystems).

We amplified all coding exons from all seven genes in the ATS linkage region (*SLC13A3*, *TP53RK*, *SLC2A10*, *EYA2*, *PRKCBP1*, *NCOA3*, *SULF2*) by PCR using intronic primers and additional exonic primers for larger exons (**Supplementary Table 1** online). Sequencing was performed using the BigDye v3.1 ET terminator cycle sequencing kit (Applied Biosystems). Sequencing reactions were loaded onto an Applied Biosystems Prism 3100 Genetic Analyzer.

Immunostaining. For GLUT10 and decorin analysis in VSMCs and skin fibroblasts by immunofluorescence microscopy, we grew 1×10^5 VSMCs or skin fibroblasts from controls and from individuals with ATS for 72 h in complete medium. To analyze GLUT10, the cells were washed in PBS, permeabilized in 0.5% Triton X-100 and 3% paraformaldehyde for 2 min, fixed for 20 min in 3% paraformaldehyde, incubated for 30 min at room temperature (21 °C) with 5% BSA/PBS and incubated overnight at 4 °C with 20 μg ml^{-1} polyclonal antibody to GLUT10 (Alpha Diagnostic). To analyze decorin levels, the cells were fixed in 3% paraformaldehyde for 10 min, washed twice for 5 min in PBS and incubated for 40 min at room temperature (21 °C) with 20 μg ml^{-1} monoclonal antibody to decorin (clone 115402, R&D Systems). Next, the VSMCs and fibroblasts were incubated for 1 h at room temperature (21 °C) with rhodamine-conjugated anti-rabbit IgG (1:50 in 1% BSA/PBS) and anti-mouse IgG (1:100 in 1% BSA/PBS), respectively; washed in PBS; mounted in 1:1 PBS-glycerol solution on glass slides and photographed with a Zeiss Axiovert 10S/H fluorescence microscope. Quantitative evaluation of the fluorescence was performed as previously reported[27]. For GLUT10, quantitative evaluation was repeated on 20 randomly selected cells for each cell strain. Images were digitized to measure the cell and the nuclear areas and the integrated optical density (IOD) corresponding to the fluorescence signals.

For immunohistochemical staining for CTGF and pSmad2 in arterial tissue, we selected representative specimens of formalin-fixed, paraffin-embedded arterial media of three healthy control individuals and one individual with ATS. From these specimens, 5-μm thick paraffin sections were cut, deparaffinized and rehydrated. These tissues were pretreated with a protease-1 enzymatic solution (Ventana). For immunohistochemical analysis, we used antibodies directed against pSmad2 and CTGF (Alpha Diagnostic, Cell Signaling Technology and Abcam, respectively) and previously described methods[3]. Light microscopy was performed on an Olympus BX45 microscope.

Q-PCR. RNA was isolated using the RNeasy Mini Kit (Qiagen), and cDNA was synthesized using SuperScript II Reverse Transcriptase Kit with random hexamer primers (Invitrogen) in a total volume of 20 μl. Two microliters of cDNA (1:10 dilution) and 250 nM gene-specific primers were used with the Q-PCR Core Kit for SYBR Green I (Eurogentec) for Q-PCR on a GeneAmp 5700 Sequence Detector (Applied Biosystems). The Q-PCR program consisted of 40 cycles with 15 s at 95 °C and 1 min at 60 °C, followed by a dissociation run to determine melting curves. We carried out all reactions in duplicate and normalized them to the geometric mean of three reference genes (*GAPDH*, *HPRT1* and *YWHAZ*). We used fibroblasts from controls and individuals with ATS and VSMCs, obtained from aortic media from two controls, from individual IV:1 with ATS (from family 4) and from an individual with LDS[3]. We grew cells in 6-cm dishes to 80% confluence. Expression levels were determined in three independent experiments for each cell line. Differential gene expression was considered significant when the difference was at least 50% and the 95% confidence interval of the mean expression levels did not overlap (equivalent to $P < 0.05$).

Accession codes. GenBank: *SLC2A10* cDNA, NM_030777; *SLC2A10* coding region, NT_011362.

Note: Supplementary information is available on the Nature Genetics website.

ACKNOWLEDGMENTS

We are indebted to the families and patients for their interest and cooperation. We thank C.E. Catsman-Berrevoets for referring family 1. We thank P. Van Acker and L.A. Myers for technical assistance. This study was supported by the Fund for Scientific Research, Flanders (Belgium); Ghent University; the Ministero dell'Istruzione, dell'Università e della Ricerca, Fondo per gli Investimenti della Ricerca di Base 2001; Fondazione Cariplo; Fondazione Berlucchi; the William Smilow Center for Marfan Syndrome Research; the Howard Hughes Medical Institute and the US National Institutes of Health. B.C. and B.L. are research assistant and senior clinical investigator, respectively, and are supported by the Fund for Scientific Research, Flanders. J.D.B. is a research fellow from Ghent University.

COMPETING INTERESTS STATEMENT

The authors declare that they have no competing financial interests.

Published online at http://www.nature.com/naturegenetics
Reprints and permissions information is available online at http://npg.nature.com/reprintsandpermissions/

1. Wessels, M.W. *et al.* Three new families with arterial tortuosity syndrome. *Am. J. Med. Genet. A* **131**, 134–143 (2004).
2. Coucke, P.J. *et al.* Homozygosity mapping of a gene for arterial tortuosity syndrome to chromosome 20q13. *J. Med. Genet.* **40**, 747–751 (2003).
3. Loeys, B.L. *et al.* A syndrome of altered cardiovascular, craniofacial, neurocognitive and skeletal development caused by mutations in TGFBR1 or TGFBR2. *Nat. Genet.* **37**, 275–281 (2005).
4. Dawson, P.A. *et al.* Sequence and functional analysis of GLUT10: a glucose transporter in the Type 2 diabetes-linked region of chromosome 20q12–13.1. *Mol. Genet. Metab.* **74**, 186–199 (2001).
5. McVie-Wylie, A.J., Lamson, D.R. & Chen, Y.T. Molecular cloning of a novel member of the GLUT family of transporters, SLC2a10 (GLUT10), localized on chromosome 20q13.1: a candidate gene for NIDDM susceptibility. *Genomics* **72**, 113–117 (2001).
6. Seidner, G. *et al.* GLUT-1 deficiency syndrome caused by haploinsufficiency of the blood-brain barrier hexose carrier. *Nat. Genet.* **18**, 188–191 (1998).
7. Santer, R. *et al.* Mutations in GLUT2, the gene for the liver-type glucose transporter, in patients with Fanconi-Bickel syndrome. *Nat. Genet.* **17**, 324–326 (1997).
8. Tanizawa, Y. *et al.* Variability of the pancreatic islet beta cell/liver (GLUT 2) glucose transporter gene in NIDDM patients. *Diabetologia* **37**, 420–427 (1994).
9. Sakamoto, O. *et al.* Mutation analysis of the GLUT2 gene in patients with Fanconi-Bickel syndrome. *Pediatr. Res.* **48**, 586–589 (2000).
10. Ertugrul, A. Diffuse tortuosity and lengthening of the arteries. *Circulation* **36**, 400–407 (1967).
11. Beuren, A.J., Hort, W., Kalbfleisch, H., Muller, H. & Stoermer, J. Dysplasia of the systemic and pulmonary arterial system with tortuosity and lengthening of the arteries. A new entity, diagnosed during life, and leading to coronary death in early childhood. *Circulation* **39**, 109–115 (1969).
12. Pletcher, B.A. *et al.* Four sibs with arterial tortuosity: description and review of the literature. *Am. J. Med. Genet.* **66**, 121–128 (1996).
13. Franceschini, P., Guala, A., Licata, D., Di Cara, G. & Franceschini, D. Arterial tortuosity syndrome. *Am. J. Med. Genet.* **91**, 141–143 (2000).
14. Barrett, M.P., Walmsley, A.R. & Gould, G.W. Structure and function of facilitative sugar transporters. *Curr. Opin. Cell Biol.* **11**, 496–502 (1999).
15. Joost, H.G. & Thorens, B. The extended GLUT-family of sugar/polyol transport facilitators: nomenclature, sequence characteristics, and potential function of its novel members (review). *Mol. Membr. Biol.* **18**, 247–256 (2001).
16. Scheepers, A., Joost, H.G. & Schurmann, A. The glucose transporter families SGLT and GLUT: molecular basis of normal and aberrant function. *JPEN J. Parenter. Enteral Nutr.* **28**, 364–371 (2004).
17. Wood, I.S., Hunter, L. & Trayhurn, P. Expression of Class III facilitative glucose transporter genes (GLUT-10 and GLUT-12) in mouse and human adipose tissues. *Biochem. Biophys. Res. Commun.* **308**, 43–49 (2003).
18. Andersen, G. *et al.* Genetic variation of the GLUT10 glucose transporter (SLC2A10) and relationships to type 2 diabetes and intermediary traits. *Diabetes* **52**, 2445–2448 (2003).

© 2006 Nature Publishing Group http://www.nature.com/naturegenetics

19. Mohlke, K.L. *et al.* Evaluation of SLC2A10 (GLUT10) as a candidate gene for type 2 diabetes and related traits in Finns. *Mol. Genet. Metab.* **85**, 323–327 (2005).
20. Fischer, J.W., Kinsella, M.G., Levkau, B., Clowes, A.W. & Wight, T.N. Retroviral overexpression of decorin differentially affects the response of arterial smooth muscle cells to growth factors. *Arterioscler. Thromb. Vasc. Biol.* **21**, 777–784 (2001).
21. Wahab, N.A., Parker, S., Sraer, J.D. & Mason, R.M. The decorin high glucose response element and mechanism of its activation in human mesangial cells. *J. Am. Soc. Nephrol.* **11**, 1607–1619 (2000).
22. Schonherr, E., Jarvelainen, H.T., Sandell, L.J. & Wight, T.N. Effects of platelet-derived growth factor and transforming growth factor-beta 1 on the synthesis of a large versican-like chondroitin sulfate proteoglycan by arterial smooth muscle cells. *J. Biol. Chem.* **266**, 17640–17647 (1991).
23. Wight, T.N. & Merrilees, M.J. Proteoglycans in atherosclerosis and restenosis: key roles for versican. *Circ. Res.* **94**, 1158–1167 (2004).
24. Le Saux, O. *et al.* Mutations in a gene encoding an ABC transporter cause pseudoxanthoma elasticum. *Nat. Genet.* **25**, 223–227 (2000).
25. Chiarelli, F., Santilli, F. & Mohn, A. Role of growth factors in the development of diabetic complications. *Horm. Res.* **53**, 53–67 (2000).
26. Gardella, R. *et al.* Exclusion of candidate genes in a family with arterial tortuosity syndrome. *Am. J. Med. Genet. A* **126**, 221–228 (2004).
27. Colombi, M. *et al.* Matrix assembly induction and cell migration and invasion inhibition by a 13-amino acid fibronectin peptide. *J. Biol. Chem.* **278**, 14346–14355 (2003).

© 2006 Nature Publishing Group http://www.nature.com/naturegenetics



CHAPTER 5

Cardiomyopathies with congenital heart malformations

5.1 Introduction

5.1.1 Cardiomyopathies with heterotaxy

5.1.2 Cardiomyopathies with septal defects

5.1.3 Cardiomyopathies with Ebstein anomaly

5.2 Mutations in sarcomeric protein genes not only lead to cardiomyopathy but also to congenital cardiovascular malformations

Wessels MW, Willems PJ

Clin Genet 2008; 74: 16-19

5.3 A new syndrome with noncompaction cardiomyopathy, bradycardia, pulmonary stenosis, atrial septal defect and heterotaxy with suggestive linkage to chromosome 6p.

Wessels MW, De Graaf BM, Cohen-Overbeek TE, Spitaels SE, de Groot-de Laat LE, Ten Cate FJ, Frohn-Mulder IF, de Krijger R, Bartelings MM, Essed N, Wladimiroff JW, Niermeijer MF, Heutink P, Oostra BA, Dooijes D, Bertoli-Avella AM, Willems PJ

Hum Genet 2008; 122: 595-603

5.4 Compound heterozygosity for truncating mutations in the *MYBPC3* gene causes severe cardiomyopathy with left ventricular noncompaction and septal defects resulting in neonatal death

Wessels MW, Hoedemaekers YM, Frohn-Mulder IM, Dalinghaus M, van den Wijngaard A, de Krijger RR, Michels M, Willems PJ, de Coo IMF, Dooijes D

Submitted

5.5 Ebstein anomaly can be caused by mutations in the *MYH7* gene encoding the cardiac beta myosin heavy chain

Wessels MW, Höhne W, Cooley DA, Schoonderwaldt EM, Vliegen HW, Michels M, Frohn-Mulder IM, Hoedemaekers YM, Helbing WA, Willems PJ, Dooijes D

Submitted

CHAPTER 5

Cardiomyopathies with congenital heart malformations

5.1 Introduction

The contractile unit of cardiovascular muscle is made up of different sarcomeric proteins (Figure 1). Hypertrophic cardiomyopathy (HCM), dilated cardiomyopathy (DCM) and restrictive cardiomyopathy (RCM) can be caused by mutations in several sarcomeric protein genes, including the genes encoding alpha cardiac myosin heavy chain (*MYH6*), beta cardiac myosin heavy chain (*MYH7*), cardiac myosin-binding protein C (*MYBPC3*), cardiac troponin T (*TNNT2*), cardiac troponin I (*TNNI3*), essential myosin light chain (*MYL3*), regulatory myosin light chain (*MYL2*), alpha tropomyosin (*TPM1*), and alpha cardiac actin (*ACTC1*). Noncompaction cardiomyopathy (NCCM), also referred to as left ventricular noncompaction (LVNC), can be caused by mutations in some of the sarcomeric protein genes, including *MYH7*, *ACTC1* and *TNNT2* [1-6]. Recently, mutations in sarcomeric protein genes have also been implicated in congenital heart malformations (CHM), including septal defects, and Ebstein anomaly (For review: see Ref [7]).

5.1.1 Cardiomyopathies with heterotaxy

Familial heterotaxy is an infrequent condition that has only been reported in a few families [8-10]. Mutations in several genes, including *LEFTY2* [11], *NODAL* [12,13], *ACVR2B* [14], *CFC1* [15,16], *FOXH1* [16], *GDF1* [17], *TDGF1* [16], *CRELD1* [18] and *NKX2.5* [19] have been identified in patients with heterotaxy, but overall only a minority of heterotaxy patients have demonstrable mutations [13,16]. Monogenetic inheritance of heterotaxy with cardiomyopathy has not yet been reported in the literature, although some patients with situs inversus or heterotaxia also have hypertrophic or noncompaction cardiomyopathy [20-26].

In this thesis a new family is described with autosomal dominant inheritance of noncompaction of the ventricular myocardium, CHM including pulmonary valve stenosis, atrial septal defect (ASD) and persistent azygous continuation and heterotaxy consisting of left bronchial isomerism (or bilateral bilobar lungs), polysplenia and intestinal malrotation. Linkage analysis yielded suggestive lod scores for this new syndrome with DNA markers on chromosome 6p [27]. In a few recent reports similar patients are described confirming that this association is a new recognizable syndrome [28,29].

5.1.2 Cardiomyopathyies with septal defects

Several genes encoding transcription factors are implicated in the development of non-syndromic septal defects: ASD can be caused by mutations in *TBX5* [30], *NKX2.5* [31], *TBX20* [32] and *GATA4* [33], whereas VSD can be caused by mutations in *TBX5* [30] and *TBX20* [32]. The first link between sarcomeric proteins and CHM was provided by Ching et al. [34] who reported mutations in the *MYH6* gene in patients with ASD with or without cardiomyopathy. Recently, several other authors have reported patients with septal defects due to mutation in sarcomeric protein genes, including *MYBPC3* [35-37] (this thesis), *MYH7*[1] (this thesis) and *ACTC1* [5,38].

Familial HCM mainly affects adults, and is usually caused by autosomal dominant mutations in genes encoding sarcomeric cardiac muscle proteins. Also young children with severe hypertrophic cardiomyopathy have been reported, and 7 % of them have 2 mutations in one of the sarcomeric protein genes [39], which suggests that a gene-dosage effect might be responsible for manifestations of HCM at a younger age. Few neonatal cases with severe cardiomyopathy due to homozygous or compound heterozygous truncating mutations in *MYBPC3* have been described previously. Several of these patients present with additional CHM, including septal defects and patent ductus arteriosus [35-37].

In this thesis two unrelated neonates are described with a severe form of cardiomyopathy resembling left ventricular noncompaction associated with septal defects. Molecular studies showed that both patients were compound heterozygous for two common loss-of-function mutations in the sarcomeric protein gene *MYBPC3* encoding cardiac myosin-binding protein C. This demonstrates that the *MYBPC3* gene is involved in left ventricular noncompaction, and also plays a role in septal development. In the family with NCCM, Ebstein anomaly, ASD and VSD, discussed in paragraph 5.1.3 and Chapter 5.5 a *MYH7* mutation was found. This confirms that different sarcomeric protein genes are involved in septation.

5.1.3 Cardiomyopathyies with Ebstein anomaly

Ebstein anomaly of the tricuspid valve is a rare anomaly, occurring in less than 1% of CHM [40]. It is characterized by adherence of the septal and posterior leaflets of the tricuspid valve to the underlying myocardium, apical displacement of the tricuspid annulus, and dilatation of the atrialized portion of the right ventricle, whereas the attached chordae are usually thin and ill formed [41]. Ebstein anomaly is frequently associated with other forms of CHM: in 70-90 % ASD is present [42-44], and occasionally pulmonary or aortic valve stenosis or atresia, mitral valve abnormalities, transposition of the great arteries, or conduction system anomalies, including accessory conduction pathways (eg Wolff-Parkinson-White syndrome) occur [43-46]. NCCM is present in almost 20 % of patients [47,48].

Although most cases of Ebstein anomaly occur sporadically, familial occurrence has been reported in approximately 20 families. As many of these families consist of only two affected patients the pattern of inheritance is not always clear, and only a few pedigrees with clear autosomal dominant inheritance has been described. In some of these families Ebstein anomaly is associated with NCCM [1,49-62]. Only in a minority of cases the disease gene has been identified, with a few mutations in the *NKX2.5* and *TBX5* genes being reported [63,64].

In this thesis we report a clinical and molecular analysis of a Caribbean family with an autosomal

dominant form of Ebstein anomaly associated with septal defects and NCCM. Mutation analysis of the *MYH7* gene revealed a novel missense mutation in the ATP-binding domain of the sarcomeric cardiac ß-myosin heavy chain protein. Subsequently, in another of our NCCM families with a *MYH7* mutation we found a hypertrabeculated left ventricle with mild Ebstein anomaly in a 12-year-old girl, and confirmed she also carried the familial *MYH7* mutation [2]. This corroborates the observation that sarcomeric protein genes are not only involved in different cardiomyopathies including NCCM, but also in the development of congenital heart malformations.

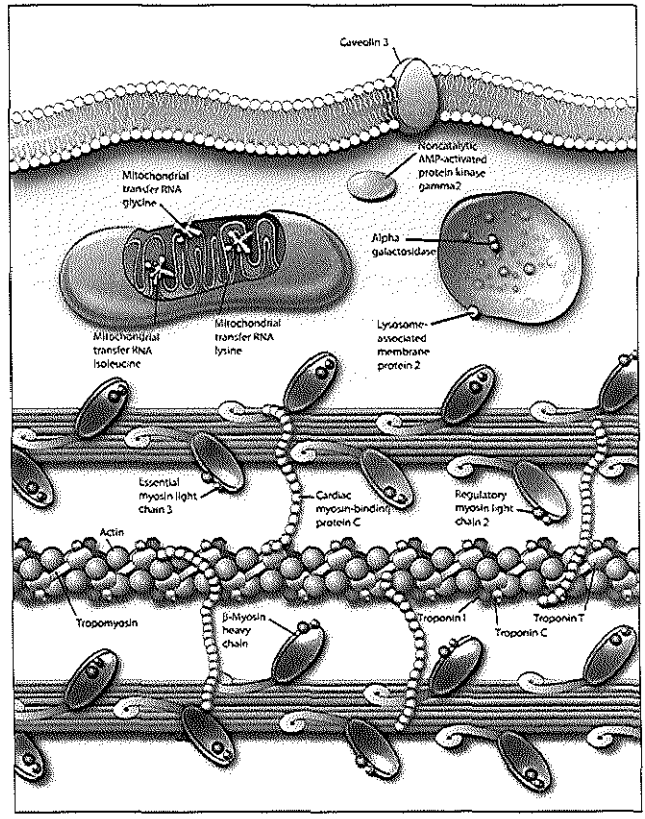

Figure 1 | Musde cell with the different proteins implicated in hypertrophic cardiomyopathies
Components of the thick myosin filament including Myosin-binding protein C (MYBPC3), Regulatory and Essential light chains (MYL2, MYL3), and Myosin heavy chain (MYH7), components of the thin actin filament including Actin (ACTC), Tropomyosin 1 (TPM1), Troponin I (TNNI3), Troponin C (TNNC1), and Troponin T (TNNT2), mitochondrial transfer RNAs for glycine/isoleucine/lysine (MTTG, MTTI, and MTTK), Caveolin 3 (CAV3), Noncatalytic AMP-activated protein kinase gamma 2 (PRKAG2), lysosomal proteins including Alpha galactosidase (GLA), Lysosome-associated membrane protein 2 (LAMP2), and Transthyretin (TTR). From www.genedx.com www.genedx.com with permission.

References

1. Budde BS, Binner P, Waldmuller S, Hohne W, Blankenfeldt W, Hassfeld S, Bromsen J, Dermintzoglou A, Wieczorek M, May E, Kirst E, Seligmow C, Rackebrandt K, Muller M, Goody RS, Vosberg HP, Nurnberg P, Scheffold T. 2007. Noncompaction of the Ventricular Myocardium Is Associated with a De Novo Mutation in the beta-Myosin Heavy Chain Gene. PLoS ONE 2:e1362.
2. Hoedemaekers YM, Caliskan K, Majoor-Krakauer D, van de Laar I, Michels M, Witsenburg M, Ten Cate FJ, Simoons ML, Dooijes D. 2007. Cardiac {beta}-myosin heavy chain defects in two families with non-compaction cardiomyopathy: linking non-compaction to hypertrophic, restrictive, and dilated cardiomyopathies. Eur Heart J 28:2732-2737.
3. Kaneda T, Naruse C, Kawashima A, Fujino N, Oshima T, Namura M, Nunoda S, Mori S, Konno T, Ino H, Yamagishi M, Asano M. 2008. A novel beta-myosin heavy chain gene mutation, p.Met531Arg, identified in isolated left ventricular non-compaction in humans, results in left ventricular hypertrophy that progresses to dilation in a mouse model. Clin Sci (Lond) 114:431-440.
4. Klaassen S, Probst S, Oechslin E, Gerull B, Krings G, Schuler P, Greutmann M, Hurlimann D, Yegitbasi M, Pons L, Gramlich M, Drenckhahn JD, Heuser A, Berger F, Jenni R, Thierfelder L. 2008. Mutations in sarcomere protein genes in left ventricular noncompaction. Circulation 117:2893-2901.
5. Monserrat L, Hermida-Prieto M, Fernandez X, Rodriguez I, Dumont C, Cazon L, Cuesta MG, Gonzalez-Juanatey C, Peteiro J, Alvarez N, Penas-Lado M, Castro-Beiras A. 2007. Mutation in the alpha-cardiac actin gene associated with apical hypertrophic cardiomyopathy, left ventricular non-compaction, and septal defects. Eur Heart J 28:1953-1961.
6. Zaragoza MV, Arbustini E, Narula J. 2007. Noncompaction of the left ventricle: primary cardiomyopathy with an elusive genetic etiology. Curr Opin Pediatr 19:619-627.
7. Wessels MW, Willems PJ. 2008. Mutations in sarcomeric protein genes not only lead to cardiomyopathy but also to congenital cardiovascular malformations. Clin Genet 74:16-19.
8. Alonso S, Pierpont ME, Radtke W, Martinez J, Chen SC, Grant JW, Dahnert I, Taviaux S, Romey MC, Demaille J, et al. 1995. Heterotaxia syndrome and autosomal dominant inheritance. Am J Med Genet 56:12-15.
9. Casey B, Cuneo BF, Vitali C, van Hecke H, Barrish J, Hicks J, Ballabio A, Hoo JJ. 1996. Autosomal dominant transmission of familial laterality defects. Am J Med Genet 61:325-328.
10. Vitale E, Brancolini V, De Rienzo A, Bird L, Allada V, Sklansky M, Chae CU, Ferrero GB, Weber J, Devoto M, Casey B. 2001. Suggestive linkage of situs inversus and other left-right axis anomalies to chromosome 6p. J Med Genet 38:182-185.
11. Kosaki K, Bassi MT, Kosaki R, Lewin M, Belmont J, Schauer G, Casey B. 1999. Characterization and mutation analysis of human LEFTY A and LEFTY B, homologues of murine genes implicated in left-right axis development. Am J Hum Genet 64:712-721.
12. Gebbia M, Ferrero GB, Pilia G, Bassi MT, Aylsworth A, Penman-Splitt M, Bird LM, Bamforth JS, Burn J, Schlessinger D, Nelson DL, Casey B. 1997. X-linked situs abnormalities result from mutations in ZIC3. Nat Genet 17:305-308.
13. Mohapatra B, Casey B, Li H, Ho-Dawson T, Smith L, Fernbach SD, Molinari L, Niesh SR, Jefferies JL, Craigen WJ, Towbin JA, Belmont JW, Ware SM. 2009. Identification and functional characterization of NODAL rare variants in heterotaxy and isolated cardiovascular malformations. Hum Mol Genet 18:861-871.
14. Kosaki R, Gebbia M, Kosaki K, Lewin M, Bowers P, Towbin JA, Casey B. 1999. Left-right axis malformations associated with mutations in ACVR2B, the gene for human activin receptor type IIB. Am J Med Genet 82:70-76.
15. Bamford RN, Roessler E, Burdine RD, Saplakoglu U, dela Cruz J, Splitt M, Goodship JA, Towbin J, Bowers P, Ferrero GB, Marino B, Schier AF, Shen MM, Muenke M, Casey B. 2000. Loss-of-function mutations in the EGF-CFC gene CFC1 are associated with human left-right laterality defects. Nat Genet 26:365-369.
16. Roessler E, Ouspenskaia MV, Karkera JD, Velez JI, Kantipong A, Lacbawan F, Bowers P, Belmont JW, Towbin JA, Goldmuntz E, Feldman B, Muenke M. 2008. Reduced NODAL Signaling Strength via Mutation of Several Pathway Members Including FOXH1 Is Linked to Human Heart Defects and Holoprosencephaly. Am J Hum Genet 83:18-29.
17. Karkera JD, Lee JS, Roessler E, Banerjee-Basu S, Ouspenskaia MV, Mez J, Goldmuntz E, Bowers P, Towbin J, Belmont JW, Baxevanis AD, Schier AF, Muenke M. 2007. Loss-of-function mutations in growth differentiation factor-1 (GDF1) are associated with congenital heart defects in humans. Am J Hum Genet 81:987-994.
18. Robinson SW, Morris CD, Goldmuntz E, Reller MD, Jones MA, Steiner RD, Maslen CL. 2003. Missense mutations in CRELD1 are associated with cardiac atrioventricular septal defects. Am J Hum Genet 72:1047-1052.
19. Watanabe Y, Benson DW, Yano S, Akagi T, Yoshino M, Murray JC. 2002. Two novel frameshift mutations in NKX2.5 result in novel features including visceral inversus and sinus venosus type ASD. J Med Genet 39:807-811.
20. Agirbasli M, Hamid R, Jennings HS, 3rd, Tiller GE. 2000. Situs inversus with hypertrophic cardiomyopathy in identical twins. Am J Med Genet 91:327-330.

21. Cochran PT, Wanamaker JL. 1975. Idiopathic hypertrophic subaortic stenosis in a patient with mirror-image dextrocardia. Chest 67:103-106.
22. Befeler B. 1975. Idiopathic hypertrophic subaortic stenosis in patients with situs inversus totalis. Chest 67:4-5.
23. Wells DE, Befeler B. 1975. Situs inversus totalis associated with subaortic and subpulmonic stenosis. Chest 67:101-103.
24. Dogan R, Dogan OF, Oc M, Duman U, Ozkutlu S, Celiker A. 2005. Noncompaction of ventricular myocardium in a patient with congenitally corrected transposition of the great arteries treated surgically: case report. Heart Surg Forum 8:E110-113.
25. Boe NM, Rhee-Morris L, Towner D, Moon-Grady AJ. 2008. Prenatal diagnosis of omphalocele and left atrial isomerism (polysplenia) including complex congenital heart disease with ventricular noncompaction cardiomyopathy. J Ultrasound Med 27:1117-1121.
26. Friedberg MK, Ursell PC, Silverman NH. 2005. Isomerism of the left atrial appendage associated with ventricular noncompaction. Am J Cardiol 96:985-990.
27. Wessels MW, De Graaf BM, Cohen-Overbeek TE, Spitaels SE, de Groot-de Laat LE, Ten Cate FJ, Frohn-Mulder IF, de Krijger R, Bartelings MM, Essed N, Wladimiroff JW, Niermeijer MF, Heutink P, Oostra BA, Dooijes D, Bertoli-Avella AM, Willems PJ. 2008. A new syndrome with noncompaction cardiomyopathy, bradycardia, pulmonary stenosis, atrial septal defect and heterotaxy with suggestive linkage to chromosome 6p. Hum Genet 122:595-603.
28. Hildebrand H, Gunzenhauser D, Weber K, Frese W, Frober R, Wetter D. 2007. [Heterotaxia syndrome without congenital cardiac defects in dilated cardiomyopathy]. Dtsch Med Wochenschr 132:931-937.
29. Cho YH, Jin SJ, Je HC, Yoon YW, Hong BK, Kwon HM, Kim TH, Rim SJ. 2007. A case of noncompaction of the ventricular myocardium combined with situs ambiguous with polysplenia. Yonsei Med J 48:1052-1055.
30. Basson CT, Huang T, Lin RC, Bachinsky DR, Weremowicz S, Vaglio A, Bruzzone R, Quadrelli R, Lerone M, Romeo G, Silengo M, Pereira A, Krieger J, Mesquita SF, Kamisago M, Morton CC, Pierpont ME, Muller CW, Seidman JG, Seidman CE. 1999. Different TBX5 interactions in heart and limb defined by Holt-Oram syndrome mutations. Proc Natl Acad Sci U S A 96:2919-2924.
31. Schott JJ, Benson DW, Basson CT, Pease W, Silberbach GM, Moak JP, Maron BJ, Seidman CE, Seidman JG. 1998. Congenital heart disease caused by mutations in the transcription factor NKX2-5. Science 281:108-111.
32. Kirk EP, Sunde M, Costa MW, Rankin SA, Wolstein O, Castro ML, Butler TL, Hyun C, Guo G, Otway R, Mackay JP, Waddell LB, Cole AD, Hayward C, Keogh A, Macdonald P, Griffiths L, Fatkin D, Sholler GF, Zorn AM, Feneley MP, Winlaw DS, Harvey RP. 2007. Mutations in cardiac T-box factor gene TBX20 are associated with diverse cardiac pathologies, including defects of septation and valvulogenesis and cardiomyopathy. Am J Hum Genet 81:280-291.
33. Garg V, Kathiriya IS, Barnes R, Schluterman MK, King IN, Butler CA, Rothrock CR, Eapen RS, Hirayama-Yamada K, Joo K, Matsuoka R, Cohen JC, Srivastava D. 2003. GATA4 mutations cause human congenital heart defects and reveal an interaction with TBX5. Nature 424:443-447.
34. Ching YH, Ghosh TK, Cross SJ, Packham EA, Honeyman L, Loughna S, Robinson TE, Dearlove AM, Ribas G, Bonser AJ, Thomas NR, Scotter AJ, Caves LS, Tyrrell GP, Newbury-Ecob RA, Munnich A, Bonnet D, Brook JD. 2005. Mutation in myosin heavy chain 6 causes atrial septal defect. Nat Genet 37:423-428.
35. Xin B, Puffenberger E, Tumbush J, Bockoven JR, Wang H. 2007. Homozygosity for a novel splice site mutation in the cardiac myosin-binding protein C gene causes severe neonatal hypertrophic cardiomyopathy. Am J Med Genet A 143:2662-2667.
36. Lekanne Deprez RH, Muurling-Vlietman JJ, Hruda J, Baars MJ, Wijnaendts LC, Stolte-Dijkstra I, Alders M, van Hagen JM. 2006. Two cases of severe neonatal hypertrophic cardiomyopathy caused by compound heterozygous mutations in the MYBPC3 gene. J Med Genet 43:829-832.
37. Zahka K, Kalidas K, Simpson MA, Cross H, Keller B, Galambos C, Gurtz K, Patton MA, Crosby AH. 2008. Homozygous mutation of MYBPC3 associated with severe infantile hypertrophic cardiomyopathy at high frequency amongst the Amish. Heart.
38. Matsson H, Eason J, Bookwalter CS, Klar J, Gustavsson P, Sunnegardh J, Enell H, Jonzon A, Vikkula M, Gutierrez I, Granados-Riveron J, Pope M, Bu'lock F, Cox J, Robinson TE, Song F, Brook DJ, Marston S, Trybus KM, Dahl N. 2008. Alpha-cardiac actin mutations produce atrial septal defects. Hum Mol Genet 17:256-265.
39. Morita H, Rehm HL, Menesses A, McDonough B, Roberts AE, Kucherlapati R, Towbin JA, Seidman JG, Seidman CE. 2008. Shared genetic causes of cardiac hypertrophy in children and adults. N Engl J Med 358:1899-1908.
40. Correa-Villasenor A, Ferencz C, Neill CA, Wilson PD, Boughman JA. 1994. Ebstein's malformation of the tricuspid valve: genetic and environmental factors. The Baltimore-Washington Infant Study Group. Teratology 50:137-147.
41. Madiwale CV, Deshpande JR, Kinare SG. 1997. Ebstein's anomaly--an autopsy study of 28 cases. J Postgrad Med 43:8-11.

42. Barbara DW, Edwards WD, Connolly HM, Dearani JA. 2008. Surgical pathology of 104 tricuspid valves (2000-2005) with classic right-sided Ebstein's malformation. Cardiovasc Pathol 17:166-171.
43. Attenhofer Jost CH, Connolly HM, Edwards WD, Hayes D, Warnes CA, Danielson GK. 2005. Ebstein's anomaly - review of a multifaceted congenital cardiac condition. Swiss Med Wkly 135:269-281.
44. Munoz-Castellanos L, Espinola-Zavaleta N, Kuri-Nivon M, Keirns C. 2007. Ebstein's Anomaly: anatomo-echocardiographic correlation. Cardiovasc Ultrasound 5:43.
45. Attenhofer Jost CH, Connolly HM, Dearani JA, Edwards WD, Danielson GK. 2007. Ebstein's anomaly. Circulation 115:277-285.
46. Celermajer DS, Cullen S, Deanfield JE, Sullivan ID. 1991. Congenitally corrected transposition and Ebstein's anomaly of the systemic atrioventricular valve: association with aortic arch obstruction. J Am Coll Cardiol 18:1056-1058.
47. Attenhofer Jost CH, Connolly HM, O'Leary PW, Warnes CA, Tajik AJ, Seward JB. 2005. Left heart lesions in patients with Ebstein anomaly. Mayo Clin Proc 80:361-368.
48. Attenhofer Jost CH, Connolly HM, Warnes CA, O'Leary P, Tajik AJ, Pellikka PA, Seward JB. 2004. Noncompacted myocardium in Ebstein's anomaly: initial description in three patients. J Am Soc Echocardiogr 17:677-680.
49. Donegan CC, Jr., Moore MM, Wiley TM, Jr., Hernandez FA, Green JR, Jr., Schiebler GL. 1968. Familial Ebstein's anomaly of the tricuspid valve. Am Heart J 75:375-379.
50. Gueron M, Hirsch M, Stern J, Cohen W, Levy MJ. 1966. Familial Ebstein's anomaly with emphasis on the surgical treatment. Am J Cardiol 18:105-111.
51. Simcha A, Bonham-Carter RE. 1971. Ebstein's anomaly. Clinical study of 32 patients in childhood. Br Heart J 33:46-49.
52. Watson H. 1974. Natural history of Ebstein's anomaly of tricuspid valve in childhood and adolescence. An international cooperative study of 505 cases. Br Heart J 36:417-427.
53. Lo KS, Loventhal JP, Walton JA, Jr. 1979. Familial Ebstein's anomaly. Cardiology 64:246-255.
54. McIntosh N, Chitayat D, Bardanis M, Fouron JC. 1992. Ebstein anomaly: report of a familial occurrence and prenatal diagnosis. Am J Med Genet 42:307-309.
55. Grant JW. 1996. Congenital malformations of the tricuspid valve in siblings. Pediatr Cardiol 17:327-329.
56. Uyan C, Yazici M, Uyan AP, Akdemir R, Imirzalioglu N, Dokumaci B. 2002. Ebstein's anomaly in siblings: an original observation. Int J Cardiovasc Imaging 18:435-438.
57. Margalit-Stashefski R, Lorber A, Margalit E. 1998. [Familial occurrence of Ebstein anomaly]. Harefuah 134:762-764, 832.
58. Rosenmann A, Arad I, Simcha A, Schaap T. 1976. Familial Ebstein's anomaly. J Med Genet 13:532-535.
59. Davido A, Maarek M, Jullien JL, Corone P. 1985. [Ebstein's disease associated with Fallot's tetralogy. Apropos of a familial case, review of the literature, embryologic and genetic implications]. Arch Mal Coeur Vaiss 78:752-756.
60. Pierard LA, Henrard L, Demoulin JC. 1985. Persistent atrial standstill in familial Ebstein's anomaly. Br Heart J 53:594-597.
61. Betrian Blasco P, Gallardo Agromayor E. 2007. Ebstein's anomaly and left ventricular noncompaction association. Int J Cardiol 119:264-265.
62. Sinkovec M, Kozelj M, Podnar T. 2005. Familial biventricular myocardial noncompaction associated with Ebstein's malformation. Int J Cardiol 102:297-302.
63. Benson DW, Silberbach GM, Kavanaugh-McHugh A, Cottrill C, Zhang Y, Riggs S, Smalls O, Johnson MC, Watson MS, Seidman JG, Seidman CE, Plowden J, Kugler JD. 1999. Mutations in the cardiac transcription factor NKX2.5 affect diverse cardiac developmental pathways. J Clin Invest 104:1567-1573.
64. Tongsong T, Chanprapaph P. 2000. Prenatal sonographic diagnosis of Holt-Oram syndrome. J Clin Ultrasound 28:98-100.

5.2

Clin Genet 2008: 74: 16–19
Printed in Singapore. All rights reserved

© 2008 The Authors
Journal compilation © 2008 Blackwell Munksgaard

CLINICAL GENETICS
doi: 10.1111/j.1399-0004.2008.00985.x

HotSpots

Mutations in sarcomeric protein genes not only lead to cardiomyopathy but also to congenital cardiovascular malformations

Marja W. Wessels[a] and Patrick J. Willems[b]

[a]Department of Clinical Genetics, Erasmus Medical Center, Dr. Molewaterplein 50, 3015 GE, Rotterdam, the Netherlands. e-mail: m.w.wessels@erasmusmc.nl
[b]GENDIA (GENetic DIAgnostic network), Antwerp, Belgium

Noncompaction of the ventricular myocardium is associated with de novo mutation in the beta-myosin heavy chain gene
Budde et al. (2007)
PLoS ONE 2: e1362

Homozygosity for a novel splice site mutation in the cardiac myosin-binding protein C gene causes severe neonatal hypertrophic cardiomyopathy
Xin et al. (2007)
Am J Med Genet 143: 2662–2667

Alpha-cardiac actin mutations produce atrial septal defects
Matsson et al. (2008)
Hum Mol Genet 17: 256–265

The contractile unit of cardiovascular muscle is made up of different sarcomeric proteins. Mutations in nine of these genes are known to cause hypertrophic cardiomyopathy (HCM): this includes the genes encoding alpha cardiac myosin heavy chain (*MYH6*), beta cardiac myosin heavy chain (*MYH7*), cardiac myosin-binding protein C (*MYBPC3*), cardiac troponin T (*TNNT2*), cardiac troponin I (*TNNI3*), essential myosin light chain (*MYL3*), regulatory myosin light chain (*MYL2*), alpha tropomyosin (*TPM1*), and alpha cardiac actin (*ACTC1*). After the identification in 1991 of HCM-causing mutations in the cardiac β-myosin heavy chain gene (*MYH7*), more than 400 different mutations in these nine genes have been associated with HCM (1). Overall, mutations in *MYBPC3* and *MYH7* are the most frequent (for review, see 2). Mutations in several of these sarcomeric protein genes, including *TNNT2*, *TNNI3*, *MYBPC3*, *MYH6*, *MYH7*, *ACTC1* and *TTN*, can also lead to dilated cardiomyopathy (DCM). DCM is a very heterogeneous form of cardiomyopathy that can be caused by mutations in more than 20 different genes (for review, see 3). Additionally, non-compaction cardiomyopathy (NCCM) can be caused by mutations in some of the sarcomeric protein genes, including *MYH7* and *MYBPC3* (4–7). NCCM is characterized by left ventricular hypertrophy with deep trabeculations with or without associated left ventricular dilation. This is believed to be due to an arrest of myocardial morphogenesis (for review, see 8).

Recently, congenital cardiovascular malformations including atrial septal defect (ASD), ventricular septal defect (VSD), Ebstein anomaly, patent ductus arteriosus (PDA) and aortic aneurysms have been reported in families with mutations in sarcomeric protein genes (5, 9–12) (Table 1).

Septal defects

Several genes encoding transcription factors are implicated in the development of non-syndromic septal defects: ASD can be caused by mutations in *TBX5* (13), *NKX2.5* (14), *TBX20* (15) and *GATA4* (16), whereas VSD can be caused by mutations in *TBX5* (13) and *TBX20* (15). Mutations in some of these transcription factors can also lead to cardiomyopathies. *NKX2.5* mutations can cause progressive cardiomyopathy (17), *TBX20* mutations are implicated in DCM (15), and expression of GATA proteins regulates cardiomyocyte hypertrophy in several mice models (18, 19), although human *GATA4* mutations are not known to cause cardiomyopathy (20). These transcription factors interact with each other and regulate expression of sarcomeric genes such as *ACTC1*, *MYH7* and *MYH6* (19, 21, 22) (Fig. 1). The first link between sarcomeric proteins and congenital cardiovascular malformations was provided by Ching et al. (22), who reported mutations in *MYH6* in patients with ASD with or without cardiomyopathy. Recently, several other authors have reported patients with a combination of cardiomyopathy and congenital cardiovascular

Table 1. Mutations in sarcomeric protein genes causing congenital cardiovascular malformations ± cardiomyopathy

Gene	Sarcomeric protein	Mutation	Homo/hetero	Number of families	Cardiomyopathy	Cardiovascular malformation	References
ACTA2	SMC α-actin	p.Arg149Cys	Hetero	5	Absent	Aortic aneurysm, BAV	(12)
		p.Arg258His; p.Arg258Cys	Hetero	3	Absent	Aortic aneurysm, PDA	(12)
		Various	Hetero	6	Absent	Aortic aneurysm, BAV	(12)
ACTC1	Cardiac α-actin	p.Glu101Lys	Hetero	4	HCM, NCCM	ASD (8/46); VSD (1/46)	(11)
		p.Met123Val	Hetero	2	Absent	ASD (20/21)	(24)
		Deletion of 17 bp in exon 2	Hetero	1	Absent	ASD (1/2); VSD (1/2)	(24)
MYBPC3	Cardiac myosin-binding protein C	p.Asp1064fsX38	Homo	1	Neonatal HCM	VSD (several/23)	(10)
MYBPC3	Cardiac myosin-binding protein C	p.Glu1096fsX92; p.Arg943X	Homo	1	Neonatal HCM	VSD (1/1)	(23)
MYBPC3	Cardiac myosin-binding protein C	p.Gln791fsX; p.Arg943X	Comp. het.	1	Neonatal NCCM	ASD (1/1)	(7)
MYBPC3	Cardiac myosin-binding protein C	p.Gln791fsX; p.Arg943X	Comp. het.	1	Neonatal NCCM	VSD (1/1)	(7)
MYH6	Cardiac α-myosin heavy chain	p.Ile820Asn	Hetero	1	Absent	ASD (7/12)	(22)
MYH7	Cardiac β-myosin heavy chain	p.Arg281Thr	Hetero	1	NCCM	ASD (4/12); Ebstein (4/12)	(5)
MYH11	SMC myosin heavy chain	L1456-N1526del and p.Arg1758Gln; R1241-L1264del	Hetero	2	Absent	Aortic aneurysm, PDA	(9)

ASD, atrial septal defect; BAV, bicuspid aortic valve; Comp. het., compound heterozygous. HCM, hypertrophic cardiomyopathy; NCCM, non-compaction cardiomyopathy; PDA, patent ductus arteriosus; SMC, smooth muscle cell; VSD, ventricular septal defect.
The number of family members with the cardiovascular malformation is indicated between brackets.

Fig. 1. The dual role of sarcomeric proteins in cardiovascular tissue. On the one hand, sarcomeric proteins determine the structure and contractile force cardiovascular tissue, whereas on the other hand, they have recently been implicated in congenital cardiovascular malformations of the heart and major arteries. As some of these sarcomeric protein genes are downstream targets of these transcription factors, it is possible that mutations in these transcription factors exert their effect through impairment of sarcomeric function.

malformations caused by a mutation in a sarcomeric protein gene (Table 1). Budde et al. (5) described a family with NCCM associated with congenital heart malformations caused by a mutation in *MYH7*. Three of 12 affected family members had NCCM with both ASD and Ebstein anomaly, and one family member had NCCM with ASD. Xin et al. (10) reported a large cohort of Old Amish children with severe lethal HCM caused by homozygous truncating mutations in *MYBPC3*: several of these patients had a VSD. Compound heterozygosity for two truncating mutations in *MYBPC3* was also shown to lead to severe lethal NCCM with ASD or VSD in three unrelated newborns (7, 23). A fourth sarcomeric protein, α-cardiac actin (*ACTC1*), has been implicated in a family with isolated ASD/VSD (24), a family with isolated ASD (10), and a family with ASD/VSD in combination with HCM/NCCM, respectively (11).

Ebstein anomaly

Non-syndromic Ebstein anomaly is characterized by the downward displacement of the attachment of the septal and posterior leaflets of the tricuspid valve. A deletion of the transcription factor *NKX2.5* because of a microdeletion of 5q35 has been found in a patient with syndromic Ebstein anomaly (25). No genes responsible for non-syndromic Ebstein anomaly have been found yet, but transcription factor genes might be good candidate

genes as these are implicated in many different congenital heart malformations. Additionally, sarcomeric protein genes are good candidates as a mutation in *MYH7* was recently described in a family with Ebstein anomaly and NCCM (5), which is a frequent association (26, 27).

Aortic aneurysm and PDA

Aortic aneurysms can be caused by several genes of the transforming growth factor β (TGFβ) signaling pathway, such as fibrillin1 (*FBN1*), transforming growth factor β receptor 1 (*TGFβR1*) and 2 (*TGFβR2*) and the glucose transporter GLUT10 (*SLC2A10*) (28). Mutations in these genes lead to upregulation of the TGFβ signaling pathway. Some patients with arterial tortuosity syndrome caused by *SLC2A10* mutations also show cardiomyopathies (29). Interestingly, treatment of cardiomyocytes with TGFB1 leads to increased expression of sarcomeric proteins, such as beta cardiac myosin heavy chain (*MYH7*), resulting in cardiac hypertrophy (30). Also the sarcomeric protein genes *MYH11* and *ACTA2* are implicated in some forms of familial aortic aneurysms (Table 1). Mutations in the *MYH11* gene lead to thoracic aortic aneurysm and/or dissection (TAAD) associated with PDA (9). Recently, mutations in the smooth muscle α-actin gene *ACTA2* were also shown to cause TAAD (12). Both the *ACTA2* and *MYH11* genes encode sarcomeric proteins of smooth muscle cells (SMCs) that are crucial in the structure and contractile force of the aorta. Not only patients with a *MYH11* mutation but also a minority of the patients with a *ACTA2* mutation show PDA. As closure of the ductus arteriosus at birth requires SMC to contract, impaired contractile force of SMCs might lead to PDA. In a small proportion of patients with a *ACTA2* mutation, bicuspid aortic valves are present (12).

Conclusions

It is well known that mutations in genes encoding sarcomeric proteins lead to different forms of ventricular cardiomyopathy, including HCM, DCM and ventricular non-compaction. Recently, several of these genes have also been implicated in the development of various congenital cardiovascular malformations such as septal defects, Ebstein anomaly, aortic aneurysm and PDA. Several models have been proposed to explain how dominant mutations in sarcomeric protein genes disturb sarcomere structure and function and lead to cardiomyopathies: (i) haploinsufficiency because of inactivation of one allele, (ii) dominant-negative effect of a mutant protein that interferes with normal protein function (protein suicide) and (iii) gain-of-function of the mutant protein that has acquired novel functions. It is unclear which of these three theoretical alternatives is correct, but most research supports the idea that incorporation of mutant protein with altered mechanical properties into the normal sarcomere is central in the pathogenesis (9). Also the effect of these mutations at the biomechanical level is still a matter of debate: some studies suggest a decrease in the motor function of the sarcomere and compensatory hypertrophic response, whereas others suggest augmented myosin motor function resulting in hypertrophy. In any case, inefficient ATP utilization, increased energy consumption, and disrupted Ca2+ homeostasis seem to lead to myocyte disarray, apoptosis and premature death of myocytes resulting in cardiomyopathies (31, 32). The aortic pathology caused by *ACTA2* and *MYH11* mutations with disarray of SMCs, and focal SMC hyperplasia (9, 12, 33) is reminiscent of the myocyte disarray and hypertrophy in cardiomyopathies caused by mutations in sarcomeric protein genes. It remains unclear, however, how deficiencies in the sarcomeric protein network could lead to congenital cardiovascular malformations such as septal defects and valve anomalies.

References

1. Morita H, Seidman J, Seidman CE. Genetic causes of human heart failure. J Clin Invest 2005: 115 (3): 518–526.
2. Bos JM, Ommen SR, Ackerman MJ. Genetics of hypertrophic cardiomyopathy: one, two, or more diseases? Curr Opin Cardiol 2007: 22 (3): 193–199.
3. Burkett EL, Hershberger RE. Clinical and genetic issues in familial dilated cardiomyopathy. J Am Coll Cardiol 2005: 45 (7): 969–981.
4. Hoedemaekers YM, Caliskan K, Majoor-Krakauer D et al. Cardiac {beta}-myosin heavy chain defects in two families with non-compaction cardiomyopathy: linking non-compaction to hypertrophic, restrictive, and dilated cardiomyopathies. Eur Heart J 2007: 28 (22): 2732–2737.
5. Budde BS, Binner P, Waldmuller S et al. Noncompaction of the ventricular myocardium is associated with a de novo mutation in the beta-myosin heavy chain gene. PLoS ONE 2007: 2 (12): e1362.
6. Kaneda T, Naruse C, Kawashima A et al. A novel beta-myosin heavy chain gene mutation, p.Met531Arg, identified in isolated left ventricular non-compaction in humans, resulted in left ventricular hypertrophy that progressed to dilation in a mouse model. Clin Sci (Lond) 2008: 114 (6): 431–440.
7. Wessels MW, Hoedemaekers M, Dalinghaus M et al. Compound heterozygosity for truncating mutations in the MYBPC3 gene causes severe cardiomyopathy with ventricular non-compaction, septal defects and neonatal death. Accepted.

8. Zaragoza MV, Arbustini E, Narula J. Noncompaction of the left ventricle: primary cardiomyopathy with an elusive genetic etiology. Curr Opin Pediatr 2007; 19 (6): 619–627.
9. Zhu L, Vranckx R, Khau Van Kien P et al. Mutations in myosin heavy chain 11 cause a syndrome associating thoracic aortic aneurysm/aortic dissection and patent ductus arteriosus. Nat Genet 2006; 38 (3): 343–349.
10. Xin B, Puffenberger E, Tumbush J et al. Homozygosity for a novel splice site mutation in the cardiac myosin-binding protein C gene causes severe neonatal hypertrophic cardiomyopathy. Am J Med Genet 2007; 143 (22): 2662–2667.
11. Monserrat L, Hermida-Prieto M, Fernandez X et al. Mutation in the alpha-cardiac actin gene associated with apical hypertrophic cardiomyopathy, left ventricular noncompaction, and septal defects. Eur Heart J 2007; 28 (16): 1953–1961.
12. Guo DC, Pannu H, Tran-Fadulu V et al. Mutations in smooth muscle alpha-actin (ACTA2) lead to thoracic aortic aneurysms and dissections. Nat Genet 2007; 39 (12): 1488–1493.
13. Basson CT, Huang T, Lin RC et al. Different TBX5 interactions in heart and limb defined by Holt-Oram syndrome mutations. Proc Natl Acad Sci U S A 1999; 96 (6): 2919–2924.
14. Schott JJ, Benson DW, Basson CT et al. Congenital heart disease caused by mutations in the transcription factor NKX2-5. Science 1998; 281 (5373): 108–111.
15. Kirk EP, Sunde M, Costa MW et al. Mutations in cardiac T-box factor gene TBX20 are associated with diverse cardiac pathologies, including defects of septation and valvulogenesis and cardiomyopathy. Am J Hum Genet 2007; 81 (2): 280–291.
16. Garg V, Kathiriya IS, Barnes R et al. GATA4 mutations cause human congenital heart defects and reveal an interaction with TBX5. Nature 2003; 424 (6947): 443–447.
17. Pashmforoush M, Lu JT, Chen H et al. Nkx2-5 pathways and congenital heart disease: loss of ventricular myocyte lineage specification leads to progressive cardiomyopathy and complete heart block. Cell 2004; 117 (3): 373–386.
18. Liang Q, De Windt LJ, Witt SA et al. The transcription factors GATA4 and GATA6 regulate cardiomyocyte hypertrophy in vitro and in vivo. J Biol Chem 2001; 276 (32): 30245–30253.
19. Oka T, Xu J, Molkentin JD. Re-employment of developmental transcription factors in adult heart disease. Semin Cell Dev Biol 2007; 18 (1): 117–131.
20. Rajagopal SK, Ma Q, Obler D et al. Spectrum of heart disease associated with murine and human GATA4 mutation. J Mol Cell Cardiol 2007; 43 (6): 677–685.
21. Akazawa H, Komuro I. Roles of cardiac transcription factors in cardiac hypertrophy. Circ Res 2003; 92 (10): 1079–1088.
22. Ching YH, Ghosh TK, Cross SJ et al. Mutation in myosin heavy chain 6 causes atrial septal defect. Nat Genet 2005; 37 (4): 423–428.
23. Lekanne Deprez RH, Muurling-Vlietman JJ, Hruda J et al. Two cases of severe neonatal hypertrophic cardiomyopathy caused by compound heterozygous mutations in the MYBPC3 gene. J Med Genet 2006; 43 (10): 829–832.
24. Matsson H, Eason J, Bookwalter CS et al. Alpha-cardiac actin mutations produce atrial septal defects. Hum Mol Genet 2008; 17 (2): 256–265.
25. Backvad-Hansen M, Tumer Z, Delicado A et al. Delineation of a 2.2 Mb microdeletion at 5q35 associated with microcephaly and congenital heart disease. Am J Med Genet 2006; 140 (5): 427–433.
26. Attenhofer Jost CH, Connolly HM, Warnes CA et al. Noncompacted myocardium in Ebstein's anomaly: initial description in three patients. J Am Soc Echocardiogr 2004; 17 (6): 677–680.
27. Sinkovec M, Kozelj M, Podnar T. Familial biventricular myocardial noncompaction associated with Ebstein's malformation. Int J Cardiol 2005; 102 (2): 297–302.
28. ten Dijke P, Arthur HM. Extracellular control of TGFbeta signalling in vascular development and disease. Nat Rev Mol Cell Biol 2007; 8 (11): 857–869.
29. Wessels MW, Catsman-Berrevoets CE, Mancini GM et al. Three new families with arterial tortuosity syndrome. Am J Med Genet 2004; 131 (2): 134–143.
30. Lim JY, Park SJ, Hwang HY et al. TGF-beta1 induces cardiac hypertrophic responses via PKC-dependent ATF-2 activation. J Mol Cell Cardiol 2005; 39 (4): 627–636.
31. Seidman JG, Seidman C. The genetic basis for cardiomyopathy: from mutation identification to mechanistic paradigms. Cell 2001; 104 (4): 557–567.
32. Abdelwahid E, Pelliniemi LJ, Szucsik JC et al. Cellular disorganization and extensive apoptosis in the developing heart of mice that lack cardiac muscle alpha-actin: apparent cause of perinatal death. Pediatr Res 2004; 55 (2): 197–204.
33. Pannu H, Tran-Fadulu V, Papke CL et al. MYH11 mutations result in a distinct vascular pathology driven by insulin-like growth factor 1 and angiotensin II. Hum Mol Genet 2007; 16 (20): 3453–3462.

5.3

Hum Genet (2008) 122:595–603
DOI 10.1007/s00439-007-0436-x

ORIGINAL INVESTIGATION

A new syndrome with noncompaction cardiomyopathy, bradycardia, pulmonary stenosis, atrial septal defect and heterotaxy with suggestive linkage to chromosome 6p

Marja W. Wessels · Bianca M. De Graaf · Titia E. Cohen-Overbeek · Silja E. Spitaels · Lotte E. de Groot-de Laat · Folkert J. Ten Cate · Ingrid F. M. Frohn-Mulder · Ronald de Krijger · Margot M. Bartelings · Nienke Essed · Jury W. Wladimiroff · Martinus F. Niermeijer · Peter Heutink · Ben A. Oostra · Dennis Dooijes · Aida M. Bertoli-Avella · Patrick J. Willems

Received: 12 August 2007 / Accepted: 28 September 2007 / Published online: 16 October 2007
© Springer-Verlag 2007

Abstract We report a three-generation family with nine patients affected by a combination of cardiac abnormalities and left isomerism which, to our knowledge, has not been described before. The cardiac anomalies include non-compaction of the ventricular myocardium, bradycardia, pulmonary valve stenosis, and secundum atrial septal defect. The laterality sequence anomalies include left bronchial isomerism, azygous continuation of the inferior vena cava, polysplenia and intestinal malrotation, all compatible with left isomerism. This new syndrome is inherited in an autosomal dominant pattern. A genome-wide linkage analysis suggested linkage to chromosome 6p24.3–21.2 with a maximum LOD score of 2.7 at marker *D6S276*. The linkage interval is located between markers *D6S470* (telomeric side) and *D6S1610* (centromeric side), and overlaps with the linkage interval in another family with heterotaxy reported previously. Taken together, the genomic region could be reduced to 9.4 cM (12 Mb) containing several functional candidate genes for this complex heterotaxy phenotype.

Introduction

Non-compaction of the ventricular myocard is a congenital cardiomyopathy, presenting with arrhythmias, heart failure or cardio-embolic events. It usually involves the apical, mid-lateral and mid-inferior ventricular segments of the left ventricle. Non-compaction cardiomyopathy is a heterogeneous disorder that can be isolated, or associated with other anomalies. Isolated left ventricular non-compaction (LVNC) can be X-linked (Bleyl et al. 1997a, b) or autosomal dominant (Kurosaki et al. 1999; Sasse-Klaassen et al. 2003). LVNC is frequently associated with neuromuscular

M. W. Wessels, B. M. De Graaf: Both authors contributed equally.

M. W. Wessels (✉) · B. M. De Graaf · J. W. Wladimiroff · M. F. Niermeijer · P. Heutink · Ben A. Oostra · D. Dooijes · A. M. Bertoli-Avella · P. J. Willems
Departments of Clinical Genetics,
Erasmus Medical Centre, Westzeedijk 112,
3016 AH Rotterdam, The Netherlands
e-mail: m.w.wessels@erasmusmc.nl

T. E. Cohen-Overbeek · J. W. Wladimiroff
Departments of Obstetrics and Gynaecology,
Erasmus Medical Centre, Rotterdam, The Netherlands

S. E. Spitaels · L. E. de Groot-de Laat · F. J. Ten Cate
Departments of Cardiology,
Erasmus Medical Centre, Rotterdam, The Netherlands

R. de Krijger
Departments of Pathology,
Erasmus Medical Centre, Rotterdam, The Netherlands

I. F. M. Frohn-Mulder
Department of Paediatric Cardiology,
Sophia Children's Hospital, Rotterdam, The Netherlands

M. M. Bartelings
Department of Anatomy and Embryology,
Leiden University Medical Centre, Leiden, The Netherlands

N. Essed
Department of Pathology, Gelre Hospitals,
Apeldoorn, The Netherlands

P. J. Willems
GENDIA (GENetic DIAgnostic network), Antwerp, Belgium

disorders and mitochondrial disorders (Stollberger and Finsterer 2006). Mutations in the *G4.5* gene (Tafazzin) have been identified in patients with X-linked isolated LVNC (Chen et al. 2002; D'Adamo et al. 1997; Xing et al. 2006). This gene has also been implicated in X-linked infantile cardiomyopathy, and X-linked endocardial fibroelastosis or Barth syndrome. LVNC may also be part of the phenotypic spectrum of the laminopathies due to a mutation in *lamin A/C* (Hermida-Prieto et al. 2004). Mutations in *LDB3* (Cypher/ZASP) were described in a subset of patients with LVNC (Vatta et al. 2003).

Non-compaction of the ventricular myocardium has also been described in association with congenital heart malformations, including obstructive right- and left-ventricular anomalies, ventricular septal defect (VSD) and atrial septal defect (ASD) (Cavusoglu et al. 2003; Dagdeviren et al. 2002; Ichida et al. 2001; Sengupta et al. 2001). In a Japanese family with this type of non-compaction cardiomyopathy a mutation in the *α-dystrobrevin* gene (*DTNA*) has been identified (Ichida et al. 2001).

Autosomal dominant heterotaxy is a very infrequent condition that has only been reported in a few families with variable expression and non-penetrance (Alonso et al. 1995; Casey et al. 1996; Vitale et al. 2001). Mutations in several genes, including *LEFTYA* (Kosaki et al. 1999a), *NODAL* (Gebbia et al. 1997), *ACVR2B* (Kosaki et al. 1999b), *CFC1* (Bamford et al. 2000), *CRELD1* (Robinson et al. 2003) and *NKX2.5* (Watanabe et al. 2002) have been identified in a few patients with heterotaxy.

In this report we describe a three-generation family with non-compaction of the ventricular myocardium, congenital heart malformations, and heterotaxy consisting of left isomerism with left bronchial isomerism, azygous continuation of the inferior vena cava, polysplenia and intestinal malrotation. Linkage analysis yielded suggestive lod scores for this new syndrome with markers on chromosome 6p.

Methods

Genomic DNA was isolated from peripheral blood following standard procedures (Miller et al. 1988). DNA (20 ng) was amplified in 7.5 μL PCR reactions, using 1× GeneAmp PCR Gold buffer, 1.5 mM $MgCl_2$, 10 pmol of each primer (forward primer labeled with FAM, TET or HEX), 250 μM dNTPs and 0.4 U of AmpliTaq Gold DNA polymerase (Applied Biosystems). PCR products were loaded on an ABI3100 automated sequencer, data were analyzed using the GeneMapper v 2.0 software (Applied Biosystems).

A systematic genome scan with short tandem repeat polymorphisms (STRs) from the Cooperative Human Linkage Center (CHLC) Human Screening Set/Weber version 6 was performed. Additional markers for fine mapping were obtained from the Généthon marker set (see "Electronic-database" section).

There were only limited amounts of DNA from individuals in generation IV (Fig. 1) due to their young age, and from the deceased patient III-4 only DNA from paraffin-embedded tumor tissue was available. Therefore, for the initial genome scan we used DNA samples from patients II-1, II-3, II-5, III-1 and III-2, and from an unaffected individual II-2. Chromosomal regions with positive LOD scores were further investigated by including DNA samples from additional affected family members IV-2, IV-3, IV-4, and III-4.

Two-point linkage analysis was performed using the MLINK and LINKMAP programs of the LINKAGE package (version 5.1). Maximum LOD and location scores were calculated for each marker assuming the disease in this family to be an autosomal dominant disorder with penetrances varying from 50 to 99%, and with a gene frequency of 1:10,000. No phenocopies were allowed and equal allele frequencies of the genotyped markers were used in the calculations. Haplotypes were constructed based on the minimal number of recombinations.

Web resources: for genetic maps: http://www.ncbi.nih.gov; for marker information: http://gdbwww.gdb.org/.

Results

Patient reports

The family is presented in Fig. 1 and Table 1.

Patients IV-2, IV-3, IV-4 (triplets)

The parents of a triplet pregnancy (Fig. 1) were referred to our Center for Prenatal Diagnosis after detection in another hospital of fetal bradycardia. The Caucasian couple was non-consanguineous and had a healthy 4-year-old son (IV-1). Clomiphene citrate treatment for ovulatory dysfunction had resulted in this triplet pregnancy. Ultrasound examination at 20 weeks gestation showed tri-amniotic triplets with persistent bradycardia between 90 and 100 beats per minute in all three. Growth parameters were normal for gestational age in all three fetuses.

The female fetus IV-2 was diagnosed with biventricular hypertrophy, an enlarged main pulmonary artery and severe pulmonary valve stenosis. Doppler flow examination revealed a severely reduced flow across the pulmonary valve, and tricuspid valve regurgitation of more than 2.5 m per second. Azygous continuation of the inferior vena cava was observed (Fig. 2). The second fetus (IV-3) also had bradycardia and moderate hypertrophy of both ventricles

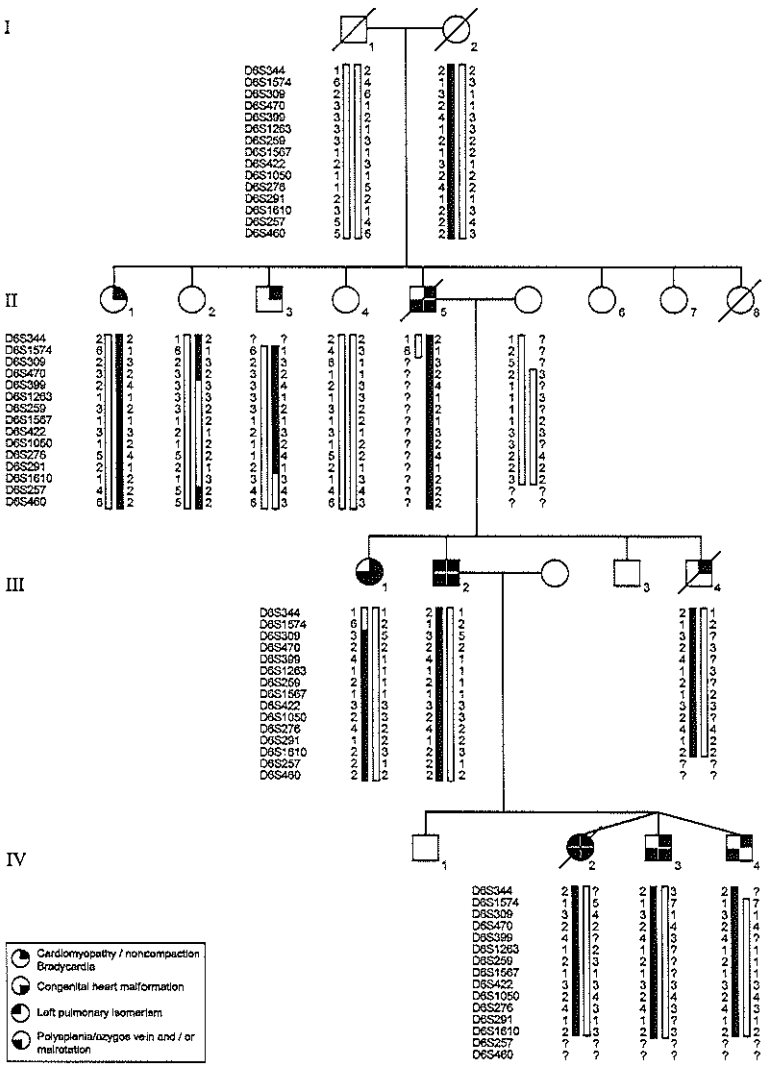

Fig. 1 Pedigree of the nine affected patients with autosomal dominant inheritance of non-compaction/cardiomyopathy, left isomerism, and congenital heart malformations. Haplotypes for the 6p markers are given below the different family members. The disease-associated haplotype is indicated in *bold*; recombinants are present in individuals II-2, II-3, and III-1. The haplotypes were constructed for I-1, I-2, II-5 and his wife

(Fig. 3). The third fetus (IV-4) showed bradycardia but no other abnormalities. Amniocentesis was offered to the parents but declined. In the following weeks fetal heart rates were monitored and persistent bradycardia (90–100 beats per minute) was observed in the three fetuses. At 25 weeks gestation the pulmonary valve stenosis in fetus IV-2 had developed into functional pulmonary valve atresia with severe myocardial thickening of the right ventricle. At that time fetus IV-3 showed small bowel dilation suggestive of intestinal obstruction. The stomach was located in a normal position. The triplets were born vaginally at 34 weeks after an induced delivery because of progressive CTG (cardiotocographic) abnormalities in fetus IV-3. Patient IV-2, a female, had Apgar scores of 8 and 9 after 1 and 5 min, respectively, and her birth weight was 1,870 g. Cardiac anomalies included sinus bradycardia, a small hypertrophic right ventricle, pulmonary valve atresia with intact ventricular septum, secundum ASD and azygous continuation. Prostaglandin infusion was given to maintain patency of the ductus arteriosus. Echography of the abdomen showed intestinal malrotation. Cardiac function and systemic circulation became progressively insufficient and she died of

Table 1 Clinical features of the family members

Symptoms	Patients								
	IV-2	IV-3	IV-4	III-2	III-1	III-4	II-5	II-1	II-3
Noncompaction/cardiomyopathy	+	+	+	+	+	+	+	+	?
Conduction abnormalities									
Bradycardia/sick sinus syndrome	+	+	+	+	+	+		+	+
Bundle branch block					+		+	+	
Congenital heart malformation									
ASD secundum	+			+	+		+		
Pulmonary valve stenosis	+	+			+				
Situs abnormalities									
Bronchial left isomerism	+			+					
Azygous continuation of the vena cava inferior	+			+	+				
Abdominal situs ambiguous	+	+	+						
Polysplenia	+	+			+		+		

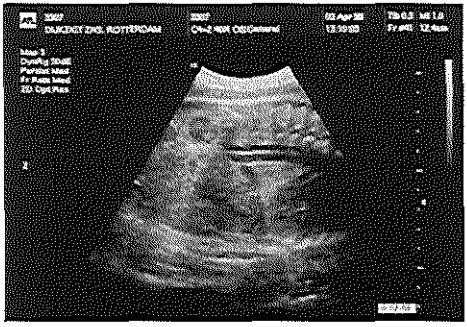

Fig. 2 Prenatal ultrasound demonstrated azygous continuation of the inferior vena cava in fetus IV-2

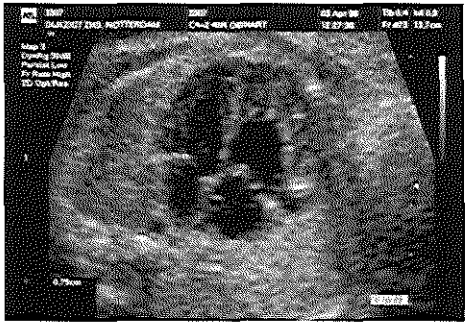

Fig. 3 Prenatal ultrasound demonstrated biventricular hypertrophy in fetus IV-3

cardiac failure 2 weeks after birth. Autopsy showed atrial situs solitus, concordant atrio-ventricular and ventriculo-arterial connections with pulmonary valve atresia, intact atrial and ventricular septa, a small dysplastic tricuspid valve, a small right ventricle with a hypertrophic wall and endocardial fibroelastosis, abnormal trabeculations in the left ventricle and anteroseptal hypertrophy. Additionally, bilateral bi-lobed lungs (bronchial left isomerism), a centrally placed liver, intestinal malrotation and polysplenia were found. Microscopy of the cardiac conduction system revealed a normally placed sinus node with minimal fibrosis. The atrial transitional zone showed edema and fibrosis. The penetrating bundle was absent, as was the connection between the branching bundle and the right bundle branch.

The second triplet, a boy (IV-3) was born with a weight of 1,305 g (<P5), and Apgar scores of 7 and 8 after 1 and 5 min, respectively. External examination showed glandular hypospadias. He also showed sinus bradycardia at 60–70 beats per minute after birth. Echocardiography revealed mild hypertrophy of both ventricles and mild valve pulmonary stenosis. Re-evaluation of the echocardiography showed increased trabeculisation of the left ventricle. Echography of the abdomen revealed polysplenia, whereas a dilated small bowel associated with jejunal atresia with intestinal malrotation and volvulus were found at exploratory laparotomy. Primary anastomosis was performed after partial bowel resection and repair of the intestinal malrotation and midgut volvulus.

His brother's (IV-4) birth weight was 1,920 g. Sinus bradycardia persisted after birth, and echocardiography showed increased trabeculisation of the left ventricle. He was diagnosed with mild intestinal malrotation (caecum in the right upper abdomen). No polysplenia was found.

Patient III-2

The father (III-2) of the triplets (Fig. 1) was known to have had bradycardia from the age of 11 years. Investigation at

Hum Genet (2008) 122:595–603

the age of 22 following an episode of palpitations identified sinus bradycardia, paroxysmal atrial fibrillation and left ventricular hypertrophy. He had been lost to cardiologic follow-up for a few years, until the birth of the triplets. Cardiologic re-evaluation revealed sinus bradycardia, junctional escape beats with episodes of atrial fibrillation, dilation of both atria, a small secundum ASD, and non-compaction of the left and right ventricular myocard (Fig. 4). Echography of the abdomen showed a normal position of the stomach, liver, gallbladder and spleen. A chest X-ray showed absence of the fissura minor and bilateral long hyparterial bronchi, consistent with left bronchial isomerism (Fig. 5). This was confirmed on a CT of the thorax which also demonstrated a large azygous vein with an incomplete inferior vena cava. Clinical examination revealed no dysmorphic abnormalities. Chromosome analysis revealed a normal male karyotype, and a 22q11.2 deletion was excluded by FISH.

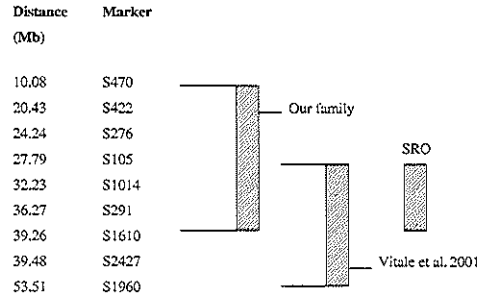

Fig. 5 Linkage intervals in our family and the family described by Vitale et al. (2001) The linkage region in our family is located in a 29 Mb interval between D6S470 and D6S1610. The linkage interval in the family reported by Vitale et al. (2001) is situated between D6S105 and D6S1960. The smallest region of overlap (SRO) between both regions is a 12 Mb interval between D6S105 and D6S1610

Patient III-1

The sister of patient III-2 (III-1) was diagnosed at the age of 3 years with pulmonary valve stenosis, a large secundum ASD and interrupted inferior vena cava with azygous continuation. Valvulotomy and later pulmonary valve replacement were performed. At the age of 15, sick sinus syndrome required pacemaker implantation. At 32 years the ECG demonstrated a complete left bundle branch block. Echocardiography revealed an enlarged left atrium and left ventricle with left ventricular non-compaction of the myocard. The right atrium and ventricle were enlarged. Polysplenia and malrotation of the gut was present. Bronchial situs was normal.

Patient III-4

A brother of the father of the triplets (III-4) was diagnosed at the age of 20 years with a grossly enlarged, hypokinetic heart with biventricular hypertrophy, sick sinus syndrome and atrial fibrillation. He died of a malignant anaplastic large-cell lymphoma at the age of 29. Autopsy was not performed.

Patient II-5

The grandfather of the triplets (II-5) had no medical history until he was hospitalized because of severe heart failure

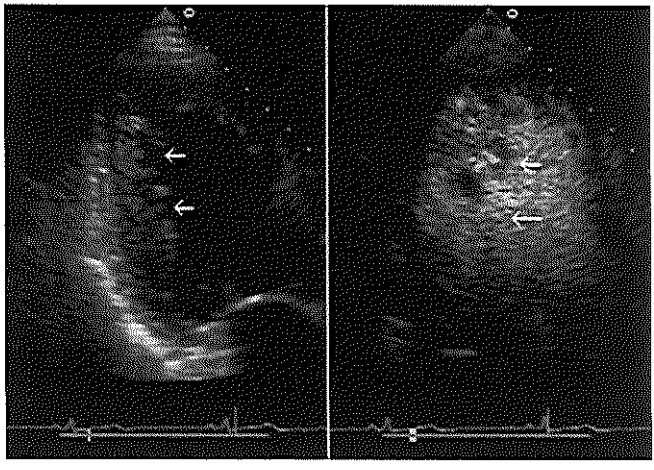

Fig. 4 Apical three-chamber view of the heart of patient III-2 showing prominent trabeculation of the left ventricle on two-dimensional contrast echocardiography (*B*)

after a pulmonary infection at the age of 59. He was diagnosed with cardiomyopathy. ECG showed atrial fibrillation with ventricular response of 70 beats per minute and a complete left bundle branch block.

Echocardiography showed dilatation of both atria and a dilated and hypokinetic left ventricle. Both ventricles showed apical hypertrophy with hypertrabeculation. A small secundum ASD was found. At the age of 62 he suddenly died. Autopsy confirmed the cardiac abnormalities and accessory spleens were found. The heart showed excessively prominent trabeculations and deep intertrabecular recesses of the left ventricle, consistent with non-compaction of the left ventricular myocard. Microscopy of the conduction tissue revealed that the penetrating bundle was present, but there existed discontinuity between the AV node and the penetrating bundle. The right bundle branch was interrupted.

Patient II-1

A sister of the grandfather (II-1) was asymptomatic, however cardiologic evaluation showed complete left bundle branch block on ECG. Echocardiography demonstrated a dilated, hypokinetic left ventricle with non-compaction of the myocard. Bronchial and abdominal situs were normal.

Patient II-3

The brother of the grandfather (II-3) was asymptomatic. Cardiologic evaluation revealed a sinus arrhythmia of 53 beats per minute. Echocardiography was suggestive for non-compaction of the right ventricle, but not conclusive. No abnormalities of bronchial or abdominal situs could be identified.

Additional family members

Cardiologic examination, ECG, echography of the heart and abdomen, and a chest X-ray were performed in two additional asymptomatic sibs (II-2 and II-4) of the grandfather, but no abnormalities could be detected.

Linkage analysis

We performed a semi-automated systematic genome scan in this family, and obtained positive LOD scores for adjacent markers on chromosome 6 (*D6S422* and *D6S276*) and chromosome 12 (*D12S336*, *D12S1617*, *D12S345*, *D12S326*, *D12S351* and *D12S79*). Further analysis of these regions by saturation with additional markers and the inclusion of additional individuals (Fig. 1) confirmed the findings for chromosome 6, but not for chromosome 12. Two-point linkage analysis yielded a maximum LOD score of 2.70 at $\theta = 0$ for marker *D6S276* (Table 2). Changing allele frequencies of the polymorphic markers and setting the penetrance at 50% did not significantly alter LOD and location scores. To extract the full information from the genotypic data, haplotypes for 15 adjacent markers on chromosome 6 were constructed by parsimony, and several recombinants that defined the limits of the disease susceptibility region were detected. The recombination event in individual II-3 suggests that the linkage region is limited by marker *D6S1610* on the centromeric side (Fig. 1). This individual is probably affected in view of his bradycardia and echocardiography suggestive of non-compaction of the right ventricle. A recombinational event for marker *D6S1574* in patient III-1 (who is clearly affected) limits the critical region on the telomeric site. If we assume the disease to be fully penetrant, unaffected individual II-2 shows a recombination between *D6S470* and *D6S399* on the telomeric side. In that case the critical region is flanked by *D6S470* (telomeric side) and *D6S1610* (centromeric side), and spans approximately 35.5 cM (29 Mb, National Center for Biotechnology Information, NCBI build 36.2) (Figs. 1, 5).

Discussion

The common finding in all nine affected members from this three-generation family (Fig. 1) is non-compaction of the ventricular myocard (Fig. 4) with conduction abnormalities. In most affected individuals the cardiomyopathy involves both ventricles.

Non-compaction cardiomyopathy is caused by an arrest in the normal development of the myocard, resulting in a thickened left ventricular wall with deep intertrabecular recesses. Characteristics on echocardiography have been

Table 2 Two-point lod scores for markers on chromosome 6p

Recombination fraction (θ)							
Marker	0.00	0.01	0.05	0.10	0.20	0.30	0.40
Telomeric							
D6S1574	−5.00	−1.04	−0.00	0.37	0.55	0.46	0.25
D6S309	0.40	0.66	0.97	1.03	0.87	0.59	0.28
D6S470	−0.86	−0.57	−0.16	0.02	0.11	0.09	0.03
D1S1263	0.36	0.35	0.31	0.27	0.17	0.08	0.02
D6S259	0.44	0.43	0.38	0.33	0.23	0.15	0.07
D6S1567	0.68	0.66	0.59	0.50	0.32	0.17	0.05
D6S422	1.10	1.07	0.96	0.81	0.53	0.27	0.07
D6S105	1.03	1.01	0.93	0.83	0.63	0.43	0.22
D6S276	2.70	2.65	2.46	2.20	1.64	1.02	0.40
D6S291	0.58	0.56	0.49	0.40	0.25	0.12	0.03
D6S1610	−4.76	−0.97	−0.38	−0.17	−0.01	0.04	0.02
Centromeric							

Hum Genet (2008) 122:595–603

defined as non-compacted trabecular endocard with deep endomyocardial spaces.

Although non-compaction of the ventricular myocard is characterized by a hypertrophy of the left ventricle, the right ventricle might also be affected in some cases. Microscopic examination of the heart at autopsy in two deceased patients from our family (patients IV-2 and II-5) revealed excessively prominent trabeculations with deep intertrabecular recesses, which is characteristic for non-compaction of the ventricular myocard, also referred to as spongy myocardium (Ichida et al. 2001; Kurosaki et al. 1999; Rigopoulos et al. 2002). The disorder was initially misdiagnosed as hypertrophic cardiomyopathy in our family. Eight of the nine patients in this family also had cardiac arrhythmia, in most cases sinus bradycardia, whereas both autopsy cases showed nodoventricular discontinuity and a right bundle branch block. Non-compaction of the ventricular myocard is often associated with conduction defects, most commonly bundle branch block and tachyarrhythmias (Ichida et al. 2001; Kurosaki et al. 1999; Ritter et al. 1997). In our family, non-compaction of the ventricular myocardium was not isolated as structural heart malformations were present in five of the nine patients, including secundum ASD and/or abnormalities of the right sided valve structures such as pulmonary valve stenosis/atresia and tricuspid valve dysplasia.

LVNC is a heterogeneous disorder, associated with neuromuscular and mitochondrial disorders and often has a genetic basis. Mutations in *G4.5* (*Tafazzin*) (Chen et al. 2002; D'Adamo et al. 1997; Xing et al. 2006), *DTNA* (*alpha-dystrobrevin*) (Ichida et al. 2001), *LDB3* (*Cypher/ZASP*) (Vatta et al. 2003) and *Lamin A/C* (Hermida-Prieto et al. 2004) have been described in a minority of patients. In the majority of LVNC cases the disease gene is unknown. An autosomal dominant pattern of inheritance is present in most cases (Sasse-Klaassen et al. 2003), and one form of autosomal dominant LVNC has been mapped to human chromosome 11p15 (Sasse-Klaassen et al. 2004), but the disease gene has not yet been identified. Non-compaction of the ventricular myocardium can also be caused by deletion of chromosome 5q encompassing the *NKX2E* gene (Pauli et al. 1999), and trabecular muscle overgrowth is found in some patients with a *NKX2E* mutation (Pashmforoush et al. 2004). Mice lacking Nkx2e specifically in the ventricular chambers show extensive trabeculae and myocardial non-compaction (Pashmforoush et al. 2004). Targeted inactivation of the murine Fkbp12 (Shou et al. 1998), PBP (Crawford et al. 2002), *Peg1* gene (King et al. 2002), *Jmj* (Lee et al. 2000) *TACE* (Shi et al. 2003) and *Bmp10* (Chen et al. 2004) genes lead to non-compaction of the ventricular myocard.

Apart from non-compaction of the ventricular myocard, situs abnormalities are typical of our family. At least six of the nine patients had anomalies compatible with the left isomerism spectrum, including left bronchial isomerism, azygous continuation of the inferior vena cava, polysplenia and intestinal malrotation. The association of non-compaction with bronchial/abdominal situs abnormalities has not yet been reported in the literature, although some patients with situs inversus also have hypertrophic cardiomyopathy (Agirbasli et al. 2000) or subaortic hypertrophic stenosis (Befeler 1975; Cochran and Wanamaker 1975; Wells and Befeler 1975). The association of situs abnormalities with azygous continuation of the inferior vena cava, and sick sinus syndrome without left atrial isomerism is typical in this family, and has only been reported in a few Japanese patients (Fukuzawa et al. 1993; Kakura et al. 1998; Noguchi et al. 1997). However, cardiomyopathy or noncompaction of the ventricular myocard as present in our family, was not reported in these patients (although one patient had cardiomegaly) (Noguchi et al. 1997). As a mild phenotype with sinus bradycardia and abdominal ambiguous situs with mild or no other cardiac anomalies, is present in some family members (e.g., patients IV-4 and II-3) (Table 1), the phenotype of these Japanese patients and that of the family reported here could be due to allelic mutations. Recently, a patient with non-compaction of the left ventricle and dextroversion was reported (Friedman et al. 2007), and Friedberg et al. (2005) described seven fetuses with non-compaction of the ventricular myocard and heterotaxy, including left atrial appendage, heart block and various structural heart malformations. Overall, non-compaction of the ventricular myocard is clinically and genetically heterogeneous, and a disease-causing mutation has been identified in only a small fraction of patients (Xing et al. 2006).

Only a few families with autosomal dominant laterality defects have been reported (Alonso et al. 1995; Casey et al. 1996; Vitale et al. 2001), and in these families congenital heart malformations in association with left–right axis malformations are present. In humans, a few genes have been associated with heterotaxy, with mutations found in a minority of patients. These genes include *ZIC3* (Gebbia et al. 1997) *LEFTYA* (Kosaki et al. 1999a), *NODAL* (Gebbia et al. 1997) *ACVR2B* (Kosaki et al. 1999b) and *CFC1* (Bamford et al. 2000). Recently single cases with *Nkx2.5* (Watanabe et al. 2002) and *CRELD1* (Robinson et al. 2003) mutations were reported. Additionally, Vitale et al. (2001) found suggestive linkage (LOD scores of 2.95) to chromosome 6p21 in a large five-generation family with autosomal dominant inheritance of left–right axis malformations. This chromosomal 6p region was also the only region with suggestive linkage in our family. The candidate regions in these two families as defined by recombination events are overlapping (Fig. 5). The candidate interval in the family described by Vitale et al. (2001) is located between *D6S105* (telomeric boundary) and

D6S1960 (centromeric boundary), whereas the candidate region in our family is located between *D6S470* (telomeric boundary) and *D6S1610* (centromeric boundary). As both families have autosomal dominant heterotaxy, a very infrequent disorder, it is possible that both conditions are allelic, although cardiomyopathy or non-compaction of the ventricular myocard, pulmonary stenosis, ASD and sinus bradycardia were not reported in the clinical description of the family of Vitale et al. (2001).

If we assume that the same disease gene causes these two forms of heterotaxy, this gene must be located between *D6S105* (telomeric side) and *D6S1610* (centromeric side) in a region of approximately 9.4 cM (12 Mb) (Fig. 5). This interval contains a few interesting functional candidate genes, including the kinesin-like 2 gene (*KNSL2*), the axonemal dynein heavy chain 6 (*DNAH6*), the axonemal dynein heavy chain 8 gene (*DNAH8*), and the tubulin beta gene (*TUBB*). These genes are good candidate genes as dyneins, tubulins and kinesins have been associated with heterotaxy. The region also includes the *NOTCH 4* gene, which plays a critical role in heart development. Notch signaling may be required for endocardial cushion differentiation and/or vascular smooth muscle cell development (Armstrong and Bischoff 2004; Noseda et al. 2004). Notch signaling is also required for normal left–right determination in mice (Przemeck et al. 2003). It is therefore possible that NOTCH4 is implicated in non-compaction and/or hetrotaxy.

To our knowledge, the autosomal dominant complex of anomalies with non-compaction of the ventricular myocard, congenital heart malformations and left isomerism has not been reported before, although different autosomal dominant combinations of several features of this new syndrome have been described previously. The three-generation pedigree with male-to-male transmission supports autosomal dominant inheritance of an unknown mutant gene affecting cardiac morphogenesis.

Acknowledgments The authors thank the family members for their cooperation. They also thank Tom De Vries-Lentsch for the photographic work, and Deon Venter for suggestions.

References

Agirbasli M, Hamid R, Jennings HS 3rd, Tiller GE (2000) Situs inversus with hypertrophic cardiomyopathy in identical twins. Am J Med Genet 91:327–330

Alonso S, Pierpont ME, Radtke W, Martinez J, Chen SC, Grant JW, Dahnert I, Taviaux S, Romey MC, Demaille J et al (1995) Heterotaxia syndrome and autosomal dominant inheritance. Am J Med Genet 56:12–15

Armstrong EJ, Bischoff J (2004) Heart valve development: endothelial cell signaling and differentiation. Circ Res 95:459–470

Bamford RN, Roessler E, Burdine RD, Saplakoglu U, dela Cruz J, Splitt M, Goodship JA, Towbin J, Bowers P, Ferrero GB, Marino B, Schier AF, Shen MM, Muenke M, Casey B (2000) Loss-of-function mutations in the *EGF-CFC* gene CFC1 are associated with human left–right laterality defects. Nat Genet 26:365–369

Befeler B (1975) Idiopathic hypertrophic subaortic stenosis in patients with situs inversus totalis. Chest 67:4–5

Bleyl SB, Mumford BR, Brown-Harrison MC, Pagotto LT, Carey JC, Pysher TJ, Ward K, Chin TK (1997a) Xq28-linked noncompaction of the left ventricular myocardium: prenatal diagnosis and pathologic analysis of affected individuals. Am J Med Genet 72:257–265

Bleyl SB, Mumford BR, Thompson V, Carey JC, Pysher TJ, Chin TK, Ward K (1997b) Neonatal, lethal noncompaction of the left ventricular myocardium is allelic with Barth syndrome. Am J Hum Genet 61:868–872

Casey B, Cuneo BF, Vitali C, van Hecke H, Barrish J, Hicks J, Ballabio A, Hoo JJ (1996) Autosomal dominant transmission of familial laterality defects. Am J Med Genet 61:325–328

Cavusoglu Y, Ata N, Timuralp B, Gorenek B, Goktekin O, Kudaiberdieva G, Unalir A (2003) Noncompaction of the ventricular myocardium: report of two cases with bicuspid aortic valve demonstrating poor prognosis and with prominent right ventricular involvement. Echocardiography 20:379–383

Chen R, Tsuji T, Ichida F, Bowles KR, Yu X, Watanabe S, Hirono K, Tsubata S, Hamamichi Y, Ohta J, Imai Y, Bowles NE, Miyawaki T, Towbin JA (2002) Mutation analysis of the *G4.5* gene in patients with isolated left ventricular noncompaction. Mol Genet Metab 77:319–325

Chen H, Shi S, Acosta L, Li W, Lu J, Bao S, Chen Z, Yang Z, Schneider MD, Chien KR, Conway SJ, Yoder MC, Haneline LS, Franco D, Shou W (2004) BMP10 is essential for maintaining cardiac growth during murine cardiogenesis. Development 131:2219–2231

Cochran PT, Wanamaker JL (1975) Idiopathic hypertrophic subaortic stenosis in a patient with mirror-image dextrocardia. Chest 67:103–106

Crawford SE, Qi C, Misra P, Stellmach V, Rao MS, Engel JD, Zhu Y, Reddy JK (2002) Defects of the heart, eye, and megakaryocytes in peroxisome proliferator activator receptor-binding protein (PBP) null embryos implicate GATA family of transcription factors. J Biol Chem 277:3585–3592

D'Adamo P, Fassone L, Gedeon A, Janssen EA, Bione S, Bolhuis PA, Barth PG, Wilson M, Haan E, Orstavik KH, Patton MA, Green AJ, Zammarchi E, Donati MA, Toniolo D (1997) The X-linked gene *G4.5* is responsible for different infantile dilated cardiomyopathies. Am J Hum Genet 61:862–867

Dagdeviren B, Eren M, Oguz E (2002) Noncompaction of ventricular myocardium, complete atrioventricular block and minor congenital heart abnormalities: case report of an unusual coexistence. Acta Cardiol 57:221–224

Friedberg MK, Ursell PC, Silverman NH (2005) Isomerism of the left atrial appendage associated with ventricular noncompaction. Am J Cardiol 96:985–990

Friedman MA, Wiseman S, Haramati L, Gordon GM, Spevack DM (2007) Noncompaction of the left ventricle in a patient with dextroversion. Eur J Echocardiogr 8:70–73

Fukuzawa J, Haneda T, Ishii Y, Kawashima E, Ogawa Y, Matsuhashi H, Kawamura Y, Imamoto T, Tobise K, Onodera S (1993) A case report of isolated levocardia without intracardiac anomalies associated with sick sinus syndrome. Jpn Circ J 57:245–250

Gebbia M, Ferrero GB, Pilia G, Bassi MT, Aylsworth A, Penman-Splitt M, Bird LM, Bamforth JS, Burn J, Schlessinger D, Nelson DL, Casey B (1997) X-linked situs abnormalities result from mutations in ZIC3. Nat Genet 17:305–308

Hermida-Prieto M, Monserrat L, Castro-Beiras A, Laredo R, Soler R, Peteiro J, Rodriguez E, Bouzas B, Alvarez N, Muniz J, Crespo-Leiro M (2004) Familial dilated cardiomyopathy and isolated left

ventricular noncompaction associated with lamin A/C gene mutations. Am J Cardiol 94:50–54
Ichida F, Tsubata S, Bowles KR, Haneda N, Uese K, Miyawaki T, Dreyer WJ, Messina J, Li H, Bowles NE, Towbin JA (2001) Novel gene mutations in patients with left ventricular noncompaction or Barth syndrome. Circulation 103:1256–1263
Kakura H, Miyahara K, Sohara H, Amitani S, Koga M, Moriyama Y, Taira A (1998) Isolated levocardia associated with absence of inferior vena cava, lobulated spleen and sick sinus syndrome. A case report. Jpn Heart J 39:235–241
King T, Bland Y, Webb S, Barton S, Brown NA (2002) Expression of Peg1 (Mest) in the developing mouse heart: involvement in trabeculation. Dev Dyn 225:212–215
Kosaki K, Bassi MT, Kosaki R, Lewin M, Belmont J, Schauer G, Casey B (1999a) Characterization and mutation analysis of human LEFTY A and LEFTY B, homologues of murine genes implicated in left–right axis development. Am J Hum Genet 64:712–721
Kosaki R, Gebbia M, Kosaki K, Lewin M, Bowers P, Towbin JA, Casey B (1999b) Left–right axis malformations associated with mutations in ACVR2B, the gene for human activin receptor type IIB. Am J Med Genet 82:70–76
Kurosaki K, Ikeda U, Hojo Y, Fujikawa H, Katsuki T, Shimada K (1999) Familial isolated noncompaction of the left ventricular myocardium. Cardiology 91:69–72
Lee Y, Song AJ, Baker R, Micales B, Conway SJ, Lyons GE (2000) Jumonji, a nuclear protein that is necessary for normal heart development. Circ Res 86:932–938
Miller SA, Dykes DD, Polesky HF (1988) A simple salting out procedure for extracting DNA from human nucleated cells. Nucleic Acids Res 16:1215
Noguchi A, Ito T, Tamura M, Harada K, Takada G (1997) Chylothorax in a polysplenia infant with cor triatriatum, pulmonary stenosis and sick sinus syndrome. Heart Vessels 12:247–249
Noseda M, McLean G, Niessen K, Chang L, Pollet I, Montpetit R, Shahidi R, Dorovini-Zis K, Li L, Beckstead B, Durand RE, Hoodless PA, Karsan A (2004) Notch activation results in phenotypic and functional changes consistent with endothelial-to-mesenchymal transformation. Circ Res 94:910–917
Pashmforoush M, Lu JT, Chen H, Amand TS, Kondo R, Pradervand S, Evans SM, Clark B, Feramisco JR, Giles W, Ho SY, Benson DW, Silberbach M, Shou W, Chien KR (2004) Nkx2-5 pathways and congenital heart disease; loss of ventricular myocyte lineage specification leads to progressive cardiomyopathy and complete heart block. Cell 117:373–386
Pauli RM, Scheib-Wixted S, Cripe L, Izumo S, Sekhon GS (1999) Ventricular noncompaction and distal chromosome 5q deletion. Am J Med Genet 85:419–423
Przemeck GK, Heinzmann U, Beckers J, Hrabe de Angelis M (2003) Node and midline defects are associated with left–right development in Delta1 mutant embryos. Development 130:3–13
Rigopoulos A, Rizos IK, Aggeli C, Kloufetos P, Papacharalampous X, Stefanadis C, Toutouzas P (2002) Isolated left ventricular noncompaction: an unclassified cardiomyopathy with severe prognosis in adults. Cardiology 98:25–32
Ritter M, Oechslin E, Sutsch G, Attenhofer C, Schneider J, Jenni R (1997) Isolated noncompaction of the myocardium in adults. Mayo Clin Proc 72:26–31
Robinson SW, Morris CD, Goldmuntz E, Reller MD, Jones MA, Steiner RD, Maslen CL (2003) Missense mutations in CRELD1 are associated with cardiac atrioventricular septal defects. Am J Hum Genet 72:1047–1052
Sasse-Klaassen S, Gerull B, Oechslin E, Jenni R, Thierfelder L (2003) Isolated noncompaction of the left ventricular myocardium in the adult is an autosomal dominant disorder in the majority of patients. Am J Med Genet A 119:162–167
Sasse-Klaassen S, Probst S, Gerull B, Oechslin E, Nurnberg P, Heuser A, Jenni R, Hennies HC, Thierfelder L (2004) Novel gene locus for autosomal dominant left ventricular noncompaction maps to chromosome 11p15. Circulation 109:2720–2723
Sengupta PP, Mohan JC, Arora R (2001) Noncompaction of left ventricular myocardium in the presence of calcific aortic stenosis in an adult. Indian Heart J 53:766–768
Shi W, Chen H, Sun J, Buckley S, Zhao J, Anderson KD, Williams RG, Warburton D (2003) TACE is required for fetal murine cardiac development and modeling. Dev Biol 261:371–380
Shou W, Aghdasi B, Armstrong DL, Guo Q, Bao S, Charng MJ, Mathews LM, Schneider MD, Hamilton SL, Matzuk MM (1998) Cardiac defects and altered ryanodine receptor function in mice lacking FKBP12. Nature 391:489–492
Stollberger C, Finsterer J (2006) Left ventricular noncompaction, cardiac magnetic resonance imaging, and neuromuscular disorders. J Am Coll Cardiol 47:1233–1234; author reply 1234–1235
Vatta M, Mohapatra B, Jimenez S, Sanchez X, Faulkner G, Perles Z, Sinagra G, Lin JH, Vu TM, Zhou Q, Bowles KR, Di Lenarda A, Schimmenti L, Fox M, Chrisco MA, Murphy RT, McKenna W, Elliott P, Bowles NE, Chen J, Valle G, Towbin JA (2003) Mutations in Cypher/ZASP in patients with dilated cardiomyopathy and left ventricular non-compaction. J Am Coll Cardiol 42:2014–2027
Vitale E, Brancolini V, De Rienzo A, Bird L, Allada V, Sklansky M, Chae CU, Ferrero GB, Weber J, Devoto M, Casey B (2001) Suggestive linkage of situs inversus and other left–right axis anomalies to chromosome 6p. J Med Genet 38:182–185
Watanabe Y, Benson DW, Yano S, Akagi T, Yoshino M, Murray JC (2002) Two novel frameshift mutations in NKX2.5 result in novel features including visceral inversus and sinus venosus type ASD. J Med Genet 39:807–811
Wells DE, Befeler B (1975) Situs inversus totalis associated with subaortic and subpulmonic stenosis. Chest 67:101–103
Xing Y, Ichida F, Matsuoka T, Isobe T, Ikemoto Y, Higaki T, Tsuji T, Haneda N, Kuwabara A, Chen R, Futatani T, Tsubata S, Watanabe S, Watanabe K, Hirono K, Uese K, Miyawaki T, Bowles KR, Bowles NE, Towbin JA (2006) Genetic analysis in patients with left ventricular noncompaction and evidence for genetic heterogeneity. Mol Genet Metab 88:71–77

5.4

Compound heterozygosity for truncating mutations in the *MYBPC3* gene causes severe cardiomyopathy with left ventricular noncompaction and septal defects resulting in neonatal death

Marja W. Wessels[1], Yvonne M. Hoedemaekers[1], Ingrid M. Frohn-Mulder[2], Michiel Dalinghaus[2], Arthur van den Wijngaard[3], Ronald R. de Krijger[4], Michelle Michels[5], Patrick J. Willems[6], Irenaeus F.M. de Coo[7] and Dennis Dooijes[1]

[1]Department of Clinical Genetics and [2]Department of Pediatric Cardiology, Erasmus Medical Center, Rotterdam, The Netherlands

[3]Department of Clinical Genetics, University Hospital Maastricht, The Netherlands

[4]Department Pathology, Erasmus Medical Center, Rotterdam, The Netherlands

[5]Department Cardiology, Erasmus Medical Center, Rotterdam, The Netherlands

[6]GENDIA (GENetic DIAgnostic Network), Antwerp, Belgium

[7]Department of Pediatric Neurology, Erasmus Medical Center, Rotterdam, The Netherlands

Submitted

Abstract

Aims Familial hypertrophic cardiomyopathy is usually caused by autosomal dominant mutations in genes encoding sarcomeric cardiac muscle proteins. The disease mainly affects adults, but young children with severe hypertrophic cardiomyopathy have been reported. We describe here two unrelated neonates with a severe form of hypertrophic cardiomyopathy, and performed molecular studies to identify the genetic defect.

Methods and Results Two unrelated neonates with lethal cardiomyopathy were studied at the clinical, pathological and molecular level. Both patients were compound heterozygous for two common loss-of-function mutations in the *MYBPC3* gene. One of the patients also presented with a ventricular septal defect, whereas the other patient had an atrial septal defect.

Conclusions Whereas heterozygous mutations in sarcomeric protein genes usually lead to hypertrophic cardiomyopathy with clinical symptoms starting in child- or adulthood, homozygosity or compound heterozygosity for 2 truncating mutations in the *MYBPC3* gene can cause severe neonatal cardiomyopathy with features of left ventricular noncompaction. Furthermore, mutations in sarcomeric protein genes seem also to be implicated in congenital heart malformations.

Introduction

Hypertrophic cardiomyopathy (HCM) is a major cause of sudden cardiac death in people younger than 35 years of age under physical stress, and a major cause of mortality and morbidity in the elderly, with an estimated prevalence of 1 in 500 individuals according to echocardiographic criteria. In approximately 60% of cases a mutation in one of the sarcomeric contractile protein genes is found [1,2].

Familial HCM is usually transmitted as an autosomal dominant condition due to heterozygous gene mutations with incomplete penetrance. After the identification in 1990 of HCM-causing mutations in the cardiac β-myosin heavy chain gene (MYH7) [3,4], mutations in genes encoding proteins involved in the sarcomere, cytoskeleton and Z-disk, calcium handling, mitochondrial and lysosomal functions have been associated with HCM [5,6]. More than 400 different mutations have been found in the genes that encode sarcomeric proteins, such as ß-cardiac myosin heavy chain (*MYH7*), cardiac myosin-binding protein-C (*MYBPC3*), α-cardiac myosin heavy chain (*MYH6*), regulatory myosin light chain (*MYL2*), essential myosin light chain (*MYL3*), cardiac troponin T (*TNNT2*), cardiac troponin I (*TNNI3*), tropomyosin (*TPM1*), cardiac actin (*ACTC1*), and titin (*TTN*) (see: http://cardiogenomics.med.harvard.edu).
Partly due to the genetic heterogeneity, interfamilial clinical variability in HCM is high. Also intrafamilial variability is considerable, and it has proven difficult to establish good genotype-phenotype correlations in HCM. In addition to the primary genetic defect, the effects of modifier genes or additional mutations in other sarcomeric genes may contribute to the phenotypic expression of HCM [7]. Childhood-onset cardiac hypertrophy is also genetically determined in the majority of cases, and two thirds of familial cases of childhood-onset cardiac hypertrophy are caused by a mutation in one of the sarcomeric protein genes [8].
Here we describe two unrelated children with severe cardiomyopathy, ventricular noncompaction and septal defects, due to compound heterozygosity for truncating mutations in *MYBPC3*, resulting in neonatal death.

Methods

Clinical diagnosis

Two unrelated families with an index patient with severe neonatal cardiomyopathy were studied after informed consent at the clinical, pathological and molecular level. Clinical evaluation included clinical history and physical examination, electrocardiography (ECG) and 2D and M-mode echocardiography. Non-compaction of the left ventricle was diagnosed based upon 3 echocardiographic criteria defined by Jenni et al., [9] including i) a thick non-compacted (NC) endocardial layer in end systole at the parasternal short-axis views (ratio NC/C >2) with numerous, excessively prominent trabeculations and deep intratrabecular recesses, ii) that are perfused on color Doppler studies and iii) predominantly apical localization.

Pathologic studies

Microscopic examination and electronmicropscopy of cardiac autopsy material of patient 1 was performed with standard techniques.

Molecular analysis

Genomic DNA of the patients was isolated from blood samples. All coding regions and intron-exon boundaries of the *MYBPC3* gene were analyzed by direct sequence analysis. Sequence analysis of M13-tagged PCR products was carried out on an ABI3730xl capillary sequencer using Big-Dye Terminator

v 3.1 chemistry (Applied Biosystems). (Details of methods and primer sequences are available on request.) Analysis of sequence data was performed using SeqScape analysis software (v2.5, Applied Biosystems). In addition to sequence analysis, MLPA analysis of the *MYBPC3* gene was carried out (MRC Holland SALSA MLPA kit P100) to detect possible genomic rearrangements. Exons of the *MYBPC3* gene were numbered 1-34 according to international standards with the Adenine of the translation initiation start site (ATG) numbered +1 and the ATG in exon 1 (www.HGVS.org). Subsequently, using the same techniques, the complete coding regions and intron-exon boundaries of 8 other sarcomeric genes (*MYH7, TNNT2, TNNI3, MYL2, MYL3, TNNC, TPM1* and *ACTC1)* were analyzed to exclude that additional pathogenic mutations in these genes contributed to the phenotype observed in the patients.

Results

Patient 1

This male patient was born after an uncomplicated pregnancy at 40 weeks gestation with a birth weight of 3110 grams and Apgar scores of 9/9. He was the second child of healthy Dutch non-consanguineous parents. At the age of 1 week cyanosis was noticed during crying and the child experienced feeding difficulties. At the age of 5 weeks he was hospitalized because of feeding problems, perspiration and facial cyanosis. X-thorax showed a grossly enlarged heart. Echocardiography revealed a moderately dilated left ventricle with severe systolic dysfunction. The apical wall of the left ventricle was excessively thickened with prominent hypertrabeculation. The left and right atria showed mild dilatation. A small secundum atrial septal defect (ASD) was also present. He was treated for heart failure with Furosemide, Captopril, Carnitine and Digoxin. Viral serology showed no abnormalities. Metabolic screening of urine, including oligosaccharide spot test, was normal. Plasma carnitine and amino acid levels were normal. After stabilization, the child was released from hospital, but two weeks later he was readmitted to the hospital presenting with a pallor color and progressive feeding problems. X-thorax and echocardiography revealed further enlargement of the heart (heart-thorax ratio ± 0.7) with severe hypertrophy with a fractional shortening of the left ventricle of less than 10%. The child died from cardiac failure at the age of 12 weeks. Macroscopic examination of the heart revealed severe cardiomegaly and dilatation with a total weight of 115 gr (normal weight at this age: 30 gr). Right ventricular thickening was noted, especially of the LV posterior wall. Also the anterior wall of the left ventricle was severely thickened, and showed abnormal trabeculation and multiple intertrabecular recesses as seen in non-compaction cardiomyopathy. The secundum ASD was confirmed. No other congenital malformations were found. Microscopic examination of cardiac tissue (Figure 1A) showed myofibrillar disarray in both the ventricular septum and the left ventricular wall. No significant amount of interstitial fibrosis was observed. Hypertrophic myocytes with a diameter varying between 20 and 30 micrometers (normal 12 micrometers) and multiple vacuoles on electron microscopy were suggestive of a glycogenosis (Figure 1B). As the echocardiography images and ECG were not suggestive of Pompe disease and urine oligosaccharide analysis was normal, no α-glucosidase enzyme or molecular assay was performed.

Sarcomere mutation analysis was initiated by screening of the complete coding region and intron-exon boundaries of the *MYBPC3* gene. This analysis revealed that the patient was compound heterozygous

for the c.2373dupG mutation and the c.2827C>T (p.Arg943X) mutation. Mutation analysis of additional sarcomeric genes (*MYH7, TNNT2, TNNI3, MYL2, MYL3, TNNC, TPM1* and *ACTC1*) did not result in the identification of additional pathogenic mutations. Large deletions of mitochondral DNA, and several mitochondrial missense mutations associated with hypertrophic cardiomyopathy were excluded. Mutation analysis in both parents identified the c.2373dupG mutation in the mother and the p.Arg943X mutation in the father (Figure 2).

At the time of diagnosis of cardiomyopathy in their newborn child, both parents had no cardiac symptoms. Echocardiography revealed no abnormalities in the mother at age 32 years and the father at age 31 years. ECG in the father showed mild repolarisation abnormalities (ST-elevation of 0,5 mm in V1 followed by a negative T in V1-V4). Re-evaluation of both parents after 7 years, revealed moderate septal hypertrophy (HCM) with an interventricular septum of 14 mm in the mother, and interventricular septal measurements at the upper limit of the normal range (12 mm) in the father. Family history indicated that there were several family members with cardiac symptoms, sudden death, and/or diagnosed with HCM on both sides of the family (Figure 2).

Patient 2

This male patient was born at 38 weeks gestation with a birth weight of 3345 gr. He was the second child of non-consanguineous parents. He experienced feeding problems in the first weeks of life. At the age of four weeks dyspnoea was noticed and he was referred to the hospital. He was mildly hypotonic. A grossly enlarged heart was observed on the X-thorax and low oxygen saturation blood levels were found. He was referred to the pediatric cardiology center for further evaluation. Echocardiography revealed moderately dilated ventricles with severe diastolic and systolic dysfunction. Hypertrabeculation with flow perfused intertrabecular recesses was present in both ventricles, including the apical walls (Figure 3). An apical muscular VSD was visualized, although deep recessal flow complicated interpreta-

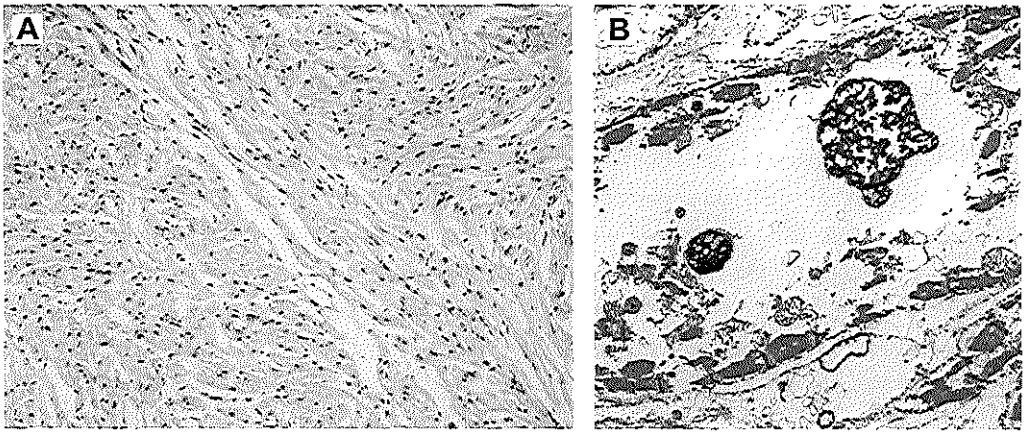

Figure 1 | **A.** Microscopic examination of postmortem heart muscle from patient 1. Hypertrophic myocytes with myofibrillar disarray typical of HCM due to sarcomeric protein mutations, was present, albeit without significant amount of interstitial fibrosis.
B. Electron micrograph showing a large, irregular vacuole

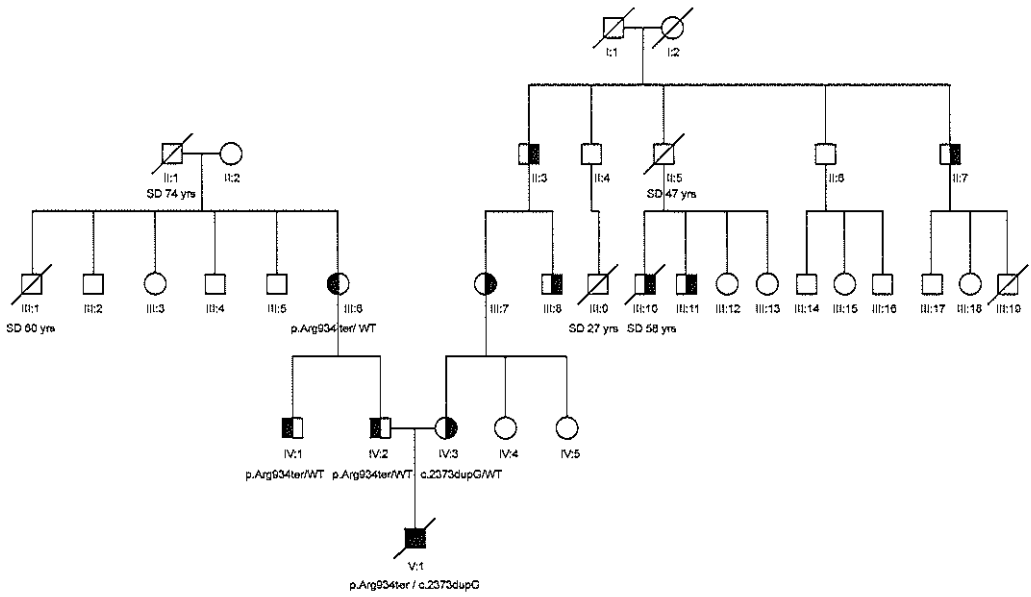

Figure 2 | Pedigree of patient 1 who had severe neonatal cardiomyopathy (■) due to compound heterozygosity for the c.2373dupG and p.Arg943X mutations in the *MYBPC3* gene. On both sides of the pedigree, there are multiple affected individuals with adult HCM (◑ ◨) that are heterozygous for one of the mutations.

tion of the imaging. A muscle CT scan showed no signs of atrophy, and a muscular biopsy revealed no congenital myopathy. Biochemical studies, including lactate, pyruvate, creatine kinase, amino acids, carnitine and sialotransferrines levels, and metabolic screening of urine, including oligosaccharides, were normal. Viral serology showed no abnormalities. The patient was treated for heart failure with Furosemide, Captopril and Digoxin. He deteriorated at the age of 12 weeks, and died.

The complete coding region and intron-exon boundaries of the *MYBPC3* gene were analyzed. Compound heterozygosity for the c.2373dupG and the c.2827C>T (p.Arg943X) in the *MYBPC3* gene was found. Molecular analyses of other sarcomeric genes (*MYH7, TNNT2, TNNI3, MYL2, MYL3, TNNC, TPM1* and *ACTC1*) revealed no additional disease-causing mutation. The parents declined pathological studies of the heart of their deceased child, nor did they decide on further cardiologic evaluation for themselves or pedigree analysis.

Discussion

Here we describe two unrelated newborns with severe cardiomyopathy resulting in neonatal death due to compound heterozygosity for null mutations in the *MYBPC3* gene. Although initially their cardiomyopathies were described as severe atypical HCM, HCM with left ventricular non-compaction (LVNC) was considered after re-evaluation of serial ultrasounds and pathologic examination. LVNC is a genetically

heterogeneous disease associated with mutations in *TAZ(G4.5)* [10], *DTNA* [11], *LDB3* [12], *SCN5A*, and *LMNA* [13] in a limited number of families [14]. Recently, LVNC was shown to be due to heterozygous mutations in genes encoding sarcomeric proteins, including ß-cardiac myosin heavy chain *(MYH7)* [15-18], alpha-cardiac actin *(ACTC)* [18,19] and cardiactroponin T *(TNNT2)* [18]. Here we report that mutations in another sarcomeric protein gene *MyBPC3* also lead to LVNC, as we previously reported [20]. This suggests that LVNC, HCM, dilated cardiomyopathy (DCM) and restrictive cardiomyopathy (RCM) are allelic diseases that share similar pathophysiological mechanisms.

In the majority of patients with familial cardiomyopathy due to a mutation in one of the genes encoding sarcomeric proteins, a single autosomal dominant mutation is found. In contrast our 2 patients are compound heterozygotes for 2 truncating *MYBPC3* mutations, suggesting a cumulative effect of these mutations. Mutations in the *MYBPC3* gene, encoding cardiac myosin binding protein C, are one of the most common genetic causes of HCM in many populations, found in approximately 20-40% of individuals with HCM [21-23]. Autosomal dominant mutations in the *MYBPC3* gene, mostly truncating mutations and sometimes missense mutations, give rise to HCM with an age of onset after the third decade, moderate left ventricular hypertrophy and a favorable prognosis [24]. As mutations in *MYBPC3* (and *MYH7*) are the most common genetic cause of familial HCM [8], compound heterozygous or homozygous mutations should be considered in a neonate which presents with severe HCM or LVNC, even in the absence of symptoms in the parents or a negative family history. This is shown here where both patients with severe neonatal cardiomyopathy are compound heterozygotes for the 2 most frequent HCM mutations in the Netherlands, the c.2373dupG mutation and the p.Arg943X mutation. The c.2373dupG mutation alone accounts for nearly one-fourth of all HCM cases in the Netherlands, and has previously been shown to be an important founder mutation in the Dutch [25] population and also to be present in other [21,26] populations. The mutation creates a new aberrant splice donor site leading to skipping of exon 24, resulting in a frame shift after p.Gln791 and a premature stop [27]. No truncated protein product from the c.2373dupG allele could be detected in the sarcomere using antibodies, suggesting that the truncated protein was unstable, or the aberrant transcript was degraded by cell sur-

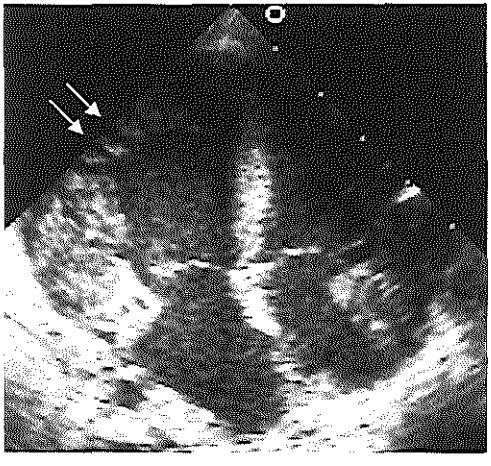

Figure 3 | Echocardiographic studies in patient 2 showing cardiomyopathy with LV non-compaction. The four chamber shows excessive trabeculation (arrows) at the apical left ventricular wall, whereas the right ventricular wall also showed numerous deep trabeculae and recesses.

veillance mechanisms such as nonsense mediated decay [28]. The second mutation found in both our patients is the p.Arg943X mutation. This mutation was identified as an additional founder mutation in the Dutch population (D.D. unpublished results). P.Arg943X is a nonsense mutation in exon 27, leading to a premature stop codon and protein truncation beyond domain C 7 of MYBPC3. Even in the absence of nonsense mediated decay of the mutant *MYBPC3* mRNAs the p.Arg943X mutation is thought to lead to reduction in MYBPC3 due to protein instability and/or loss of the C-terminus of MYBPC3 that binds myosin thick filaments and titin, which is required for normal MYBPC3 incorporation into the A-band of the sarcomere [29]. As a consequence, in our patients no MYBPC3 protein is expected to be incorporated into the sarcomere, which might explain the early and severe presentation of the cardiomyopathy in both patients.

In larger series approximately 3-5 % of HCM patients are compound or double heterozygotes for two disease-causing mutations in the same or different sarcomeric protein genes [21,22]. However, most of these mutations are missense mutations of which the pathogenic nature is not always easy to establish. In these patients generally a more severe HCM phenotype is seen, characterized by an age of onset around the second decade or in childhood (Table 1) [21,22,30-39]. In a recent study on sarcomeric protein gene mutations in childhood-onset HCM 6 out of 84 children (7 %) had compound mutations [8]. This suggests that a gene-dosage effect might be responsible for manifestations at a younger age.

Not only clinical features such as the neonatal onset of severe symptoms, but also the pathology of the heart in patient 1 initially suggested a metabolic origin eg glycogenosis (Figure 1). It is known that mutations in genes regulating glycogen metabolism, including AMP-activated protein kinase $_2$ (*PRKAG2*) in Wolff-Parkinson-White associated cardiomyopathy, lysosome-associated membrane protein 2 (*LAMP2*) in Danon disease, -galactosidase (*GLA*) in Fabry's disease, and acid -1,4-glucosidase (*GAA*) in Pompe's disease can cause left ventricular hypertrophy that mimics HCM [40]. Conversely, metabolic diseases might also be misdiagnosed in patients with HCM due to sarcomeric protein mutations, as shown in our patient. Mutations in genes regulating glycogen metabolism cause myocyte hypertrophy by stimulating glycogen-filled vacuoles but cause neither myocyte disarray nor interstitial fibrosis, which typically occur with defects of sarcomere-protein genes.

Few neonatal cases with severe cardiomyopathy due to homozygous or compound heterozygous truncating mutations in *MYBPC3* have previously been described [21,34,37,38]. A homozygous splice site mutation p.Asp1064GlyfsX38 in *MYBPC3* (leading to a frame shift and premature truncation) was recently described in 3 neonates with severe neonatal HCM that all died at the average age of 3-4 months in an inbred Old Order Amish pedigree with severe HCM [37]. This homozygous *MYBPC3* mutation was also reported in another cohort of 10 neonates with severe infantile HCM from Old Order Amish descent, suggesting that this mutation is a founder mutation in the Amish [38]. It is remarkable that several of the affected neonates from the Old Order Amish with homozygous truncating mutations in *MYBPC3*, present with septal defects including apical muscular VSD, and ASD and patent ductus arteriosus. Septal defects were also present in the neonates with severe HCM due to compound heterozygous truncating mutations described by Lekanne et al. [34] and the two cases described here. Recently, different congenital heart malformations (septal defects, patent ductus arteriosus, aortic aneurysm and Ebstein anomaly) have been reported in families with mutations in sarcomeric protein genes, including *MYB-*

PC3, MYH6, MYH7, MYH11, and *ACTC1* [16,19,37,41-43]. This suggests that sarcomeric cardiac muscle proteins are not only involved in cardiomyopathies but also in congenital heart malformations [44].
In conclusion, the absence of functional MYBPC3 from the sarcomere can lead to a phenotype of severe HCM with features of ventricular noncompaction and septal defects, which appears to be lethal in the postnatal period.

Acknowledgements

We are grateful to the family members of the two patients and the referring physicians for their contributions. The authors kindly thank Dr Koert P. Dingemans for providing a electronic micrograph and Tom de Vries Lentsch for graphical support.

Table 1 next page

Table 1 | Patients with cardiomyopathy due to 2 mutations in the *MYBPC3* gene, and/or additional sarcomeric protein genes*

Gene 1 / Mutation 1	Gene 2 / Mutation 2	Phenotype
***MYBPC3* mutation with mutation in other sarcomeric gene**		
MYBPC3 / p.Arg273His	*MYH7* / p.Arg719Gln	HCM
MYBPC3 / p.Asp605Asn	*MYH7* / p.Glu894Gly	HCM
MYBPC3 / c.2373dupG	*MYH7* / p.Arg694Cys	HCM
MYBPC3 / p.Glu1096X	*MYH7* / p.Glu483Lys	HCM
MYBPC3 / p.Ala833Thr	*TNNT2* / p.Arg286His	HCM
MYBPC3 / p.Val256Ile	*TNNT2* / p.Arg92Trp	HCM
MYBPC3 / p.Arg943X	*TNNI3* / p.Ser166Phe	HCM
MYBPC3 / p.Phe1113Ile	*TPM1* / p.Ile172Thr	HCM
MYBPC3 / p.Arg495Gln	*TNNI3* / p.Arg141Gln	Childhood HCM**
Compound heterozygote or homozygote mutations in *MYBPC3*		
MYBPC3 / p.Pro873His	*MYBPC3* / p.Pro873His	HCM
MYBPC3 / p.Arg810His	*MYBPC3* / p.Arg810His	HCM
MYBPC3 / p.Arg502Trp	*MYBPC3* / p.Gly5Arg	HCM
MYBPC3 / p.Ala954fs	*MYBPC3* / p.Glu258Lys	HCM
MYBPC3 / p.Ala627Val	*MYBPC3* / p.Ala627Val	HCM
MYBPC3 / p.Pro873His	*MYBPC3* / p.Asp745Gly	HCM
MYBPC3 / p.Glu542Gln	*MYBPC3* / p.Ala851Val	HCM
MYBPC3 / p.Gln76X	*MYBPC3* / p.His257Pro	HCM
MYBPC3 / p.Thr1028Ser	*MYBPC3* / c.3490+2T→G	Childhood HCM**
MYBPC3 / p.Arg502Trp	*MYBPC3* / p.Ser858Asn	Childhood HCM**
MYBPC3 / p.Ile154Thr	*MYBPC3* / p.Asp605del	Childhood HCM**
Double truncating mutations in *MYBPC3*		
MYBPC3 / p.Gln76X	*MYBPC3* / p.Gln76X	Neonatal HCM
MYBPC3 / c.1624+1G>A	*MYBPC3* / c.2373dupG	Neonatal HCM
MYBPC3 / p.Arg943X	*MYBPC3* / p.Glu1096fs	Neonatal HCM/**VSD**
MYBPC3 / p. Asp1064GlyfsX38	*MYBPC3* / p. Asp1064GlyfsX38	Neonatal HCM/**ASD, VSD**
MYBPC3 / p.Arg943X	*MYBPC3* / c.2373dupG	Neonatal HCM/**ASD**
MYBPC3 / p.Arg943X	*MYBPC3* / c.2373dupG	Neonatal HCM/**VSD**

*The pathogenicity of some of the missense mutations listed here is uncertain

**More severe HCM and highest incidence of myectomie as compared to patients with single *MYBPC3* mutations[22]

***Diagnosis at a younger age (between 0.2 and 37.4 yrs) as compared to patients with single *MYBPC3* mutations[22]

Severity	Age at first study	Reference
Moderate /severe	35 and 15 yrs	45
**	***	22
**	***	22
Severe	33 and 56 yrs	21,36
**	***	22
**		22
**	***	22
**	***	22
	Before 15 yrs	8
Moderate /severe	27 yrs	39
Severe	39 yrs	39
*1	*2	22
*1	*2	22
Severe	47 yrs	31
Severe	29 yrs	45
Severe	34 yrs	45
Mild symptoms	24 yrs	21
	Before 15 yrs	8
	Before 15 yrs	8
	Before 15 yrs	8
Death 9 months		21
Death 5 weeks	3 days	34
Death 6 weeks	2 weeks	34
Death 6 weeks-7 months	1-3 weeks	37,38
Death 3 months	5 weeks	This study
Death 3 months	4 weeks	This study

References

1. Maron BJ, Gardin JM, Flack JM, Gidding SS, Kurosaki TT, Bild DE. 1995. Prevalence of hypertrophic cardiomyopathy in a general population of young adults. Echocardiographic analysis of 4111 subjects in the CARDIA Study. Coronary Artery Risk Development in (Young) Adults. Circulation 92:785-789.
2. Alcalai R, Seidman JG, Seidman CE. 2008. Genetic basis of hypertrophic cardiomyopathy: from bench to the clinics. J Cardiovasc Electrophysiol 19:104-110.
3. Seidman CE, Seidman JG. 1991. Mutations in cardiac myosin heavy chain genes cause familial hypertrophic cardiomyopathy. Mol Biol Med 8:159-166.
4. Geisterfer-Lowrance AA, Kass S, Tanigawa G, Vosberg HP, McKenna W, Seidman CE, Seidman JG. 1990. A molecular basis for familial hypertrophic cardiomyopathy: a beta cardiac myosin heavy chain gene missense mutation. Cell 62:999-1006.
5. Morita H, Seidman J, Seidman CE. 2005. Genetic causes of human heart failure. J Clin Invest 115:518-526.
6. Bos JM, Ommen SR, Ackerman MJ. 2007. Genetics of hypertrophic cardiomyopathy: one, two, or more diseases? Curr Opin Cardiol 22:193-199.
7. Daw EW, Chen SN, Czernuszewicz G, Lombardi R, Lu Y, Ma J, Roberts R, Shete S, Marian AJ. 2007. Genome-wide mapping of modifier chromosomal loci for human hypertrophic cardiomyopathy. Hum Mol Genet 16:3463-3471.
8. Morita H, Rehm HL, Menesses A, McDonough B, Roberts AE, Kucherlapati R, Towbin JA, Seidman JG, Seidman CE. 2008. Shared genetic causes of cardiac hypertrophy in children and adults. N Engl J Med 358:1899-1908.
9. Jenni R, Oechslin EN, van der Loo B. 2007. Isolated ventricular non-compaction of the myocardium in adults. Heart 93:11-15.
10. Bleyl SB, Mumford BR, Thompson V, Carey JC, Pysher TJ, Chin TK, Ward K. 1997. Neonatal, lethal noncompaction of the left ventricular myocardium is allelic with Barth syndrome. Am J Hum Genet 61:868-872.
11. Ichida F, Tsubata S, Bowles KR, Haneda N, Uese K, Miyawaki T, Dreyer WJ, Messina J, Li H, Bowles NE, Towbin JA. 2001. Novel gene mutations in patients with left ventricular noncompaction or Barth syndrome. Circulation 103:1256-1263.
12. Vatta M, Mohapatra B, Jimenez S, Sanchez X, Faulkner G, Perles Z, Sinagra G, Lin JH, Vu TM, Zhou Q, Bowles KR, Di Lenarda A, Schimmenti L, Fox M, Chrisco MA, Murphy RT, McKenna W, Elliott P, Bowles NE, Chen J, Valle G, Towbin JA. 2003. Mutations in Cypher/ZASP in patients with dilated cardiomyopathy and left ventricular non-compaction. J Am Coll Cardiol 42:2014-2027.
13. Hermida-Prieto M, Monserrat L, Castro-Beiras A, Laredo R, Soler R, Peteiro J, Rodriguez E, Bouzas B, Alvarez N, Muniz J, Crespo-Leiro M. 2004. Familial dilated cardiomyopathy and isolated left ventricular noncompaction associated with lamin A/C gene mutations. Am J Cardiol 94:50-54.
14. Xing Y, Ichida F, Matsuoka T, Isobe T, Ikemoto Y, Higaki T, Tsuji T, Haneda N, Kuwabara A, Chen R, Futatani T, Tsubata S, Watanabe S, Watanabe K, Hirono K, Uese K, Miyawaki T, Bowles KR, Bowles NE, Towbin JA. 2006. Genetic analysis in patients with left ventricular noncompaction and evidence for genetic heterogeneity. Mol Genet Metab 88:71-77.
15. Hoedemaekers YM, Caliskan K, Majoor-Krakauer D, van de Laar I, Michels M, Witsenburg M, Ten Cate FJ, Simoons ML, Dooijes D. 2007. Cardiac {beta}-myosin heavy chain defects in two families with non-compaction cardiomyopathy: linking non-compaction to hypertrophic, restrictive, and dilated cardiomyopathies. Eur Heart J 28:2732-2737.
16. Budde BS, Binner P, Waldmuller S, Hohne W, Blankenfeldt W, Hassfeld S, Bromsen J, Dermintzoglou A, Wieczorek M, May E, Kirst E, Selignow C, Rackebrandt K, Muller M, Goody RS, Vosberg HP, Nurnberg P, Scheffold T. 2007. Noncompaction of the Ventricular Myocardium Is Associated with a De Novo Mutation in the beta-Myosin Heavy Chain Gene. PLoS ONE 2:e1362.
17. Kaneda T, Naruse C, Kawashima A, Fujino N, Oshima T, Namura M, Nunoda S, Mori S, Konno T, Ino H, Yamagishi M, Asano M. 2008. A novel beta-myosin heavy chain gene mutation, p.Met531Arg, identified in isolated left ventricular non-compaction in humans, results in left ventricular hypertrophy that progresses to dilation in a mouse model. Clin Sci (Lond) 114:431-440.
18. Klaassen S, Probst S, Oechslin E, Gerull B, Krings G, Schuler P, Greutmann M, Hurlimann D, Yegitbasi M, Pons L, Gramlich M, Drenckhahn JD, Heuser A, Berger F, Jenni R, Thierfelder L. 2008. Mutations in sarcomere protein genes in left ventricular noncompaction. Circulation 117:2893-2901.
19. Monserrat L, Hermida-Prieto M, Fernandez X, Rodriguez I, Dumont C, Cazon L, Cuesta MG, Gonzalez-Juanatey C, Peteiro J, Alvarez N, Penas-Lado M, Castro-Beiras A. 2007. Mutation in the alpha-cardiac actin gene associated with apical hypertrophic cardiomyopathy, left ventricular non-compaction, and septal defects. Eur Heart J 28:1953-1961.
20. Hoedemaekers YM, Kaliskan K, ten Cate FJ, Majoor-Krakauer D, Dooijes D Genetic analysis of hypertrophic cardiomyopathy genes in noncompaction cardiomyopathy patients: could NCCM be a phenotypic variant of HCM? [abstract]. In: Programme and Abstracts of the American Society of Human Genetics Annual Meeting; 9–13 October 2006; New Orleans, LA: American Society of Human Genetics; 2006.

21. Richard P, Charron P, Carrier L, Ledeuil C, Cheav T, Pichereau C, Benaiche A, Isnard R, Dubourg O, Burban M, Gueffet JP, Millaire A, Desnos M, Schwartz K, Hainque B, Komajda M. 2003. Hypertrophic cardiomyopathy: distribution of disease genes, spectrum of mutations, and implications for a molecular diagnosis strategy. Circulation 107:2227-2232.
22. Van Driest SL, Vasile VC, Ommen SR, Will ML, Tajik AJ, Gersh BJ, Ackerman MJ. 2004. Myosin binding protein C mutations and compound heterozygosity in hypertrophic cardiomyopathy. J Am Coll Cardiol 44:1903-1910.
23. Ho CY, Seidman CE. 2006. A contemporary approach to hypertrophic cardiomyopathy. Circulation 113:e858-862.
24. Niimura H, Bachinski LL, Sangwatanaroj S, Watkins H, Chudley AE, McKenna W, Kristinsson A, Roberts R, Sole M, Maron BJ, Seidman JG, Seidman CE. 1998. Mutations in the gene for cardiac myosin-binding protein C and late-onset familial hypertrophic cardiomyopathy. N Engl J Med 338:1248-1257.
25. Alders M, Jongbloed R, Deelen W, van den Wijngaard A, Doevendans P, Ten Cate F, Regitz-Zagrosek V, Vosberg HP, van Langen I, Wilde A, Dooijes D, Mannens M. 2003. The 2373insG mutation in the MYBPC3 gene is a founder mutation, which accounts for nearly one-fourth of the HCM cases in the Netherlands. Eur Heart J 24:1848-1853.
26. Jaaskelainen P, Kuusisto J, Miettinen R, Karkkainen P, Karkkainen S, Heikkinen S, Peltola P, Pihlajamaki J, Vauhkonen I, Laakso M. 2002. Mutations in the cardiac myosin-binding protein C gene are the predominant cause of familial hypertrophic cardiomyopathy in eastern Finland. J Mol Med 80:412-422.
27. Moolman JA, Reith S, Uhl K, Bailey S, Gautel M, Jeschke B, Fischer C, Ochs J, McKenna WJ, Klues H, Vosberg HP. 2000. A newly created splice donor site in exon 25 of the MyBP-C gene is responsible for inherited hypertrophic cardiomyopathy with incomplete disease penetrance. Circulation 101:1396-1402.
28. Wilkinson MF. 2005. A new function for nonsense-mediated mRNA-decay factors. Trends Genet 21:143-148.
29. Rottbauer W, Gautel M, Zehelein J, Labeit S, Franz WM, Fischer C, Vollrath B, Mall G, Dietz R, Kubler W, Katus HA. 1997. Novel splice donor site mutation in the cardiac myosin-binding protein-C gene in familial hypertrophic cardiomyopathy. Characterization Of cardiac transcript and protein. J Clin Invest 100:475-482.
30. Alpert NR, Mohiddin SA, Tripodi D, Jacobson-Hatzell J, Vaughn-Whitley K, Brosseau C, Warshaw DM, Fananapazir L. 2005. Molecular and phenotypic effects of heterozygous, homozygous, and compound heterozygote myosin heavy-chain mutations. Am J Physiol Heart Circ Physiol 288:H1097-1102.
31. Garcia-Castro M, Reguero JR, Alvarez V, Batalla A, Soto MI, Albaladejo V, Coto E. 2005. Hypertrophic cardiomyopathy linked to homozygosity for a new mutation in the myosin-binding protein C gene (A627V) suggests a dosage effect. Int J Cardiol 102:501-507.
32. Ho CY, Lever HM, DeSanctis R, Farver CF, Seidman JG, Seidman CE. 2000. Homozygous mutation in cardiac troponin T: implications for hypertrophic cardiomyopathy. Circulation 102:1950-1955.
33. Jeschke B, Uhl K, Weist B, Schroder D, Meitinger T, Dohlemann C, Vosberg HP. 1998. A high risk phenotype of hypertrophic cardiomyopathy associated with a compound genotype of two mutated beta-myosin heavy chain genes. Hum Genet 102:299-304.
34. Lekanne Deprez RH, Muurling-Vlietman JJ, Hruda J, Baars MJ, Wijnaendts LC, Stolte-Dijkstra I, Alders M, van Hagen JM. 2006. Two cases of severe neonatal hypertrophic cardiomyopathy caused by compound heterozygous mutations in the MYBPC3 gene. J Med Genet 43:829-832.
35. Richard P, Charron P, Leclercq C, Ledeuil C, Carrier L, Dubourg O, Desnos M, Bouhour JB, Schwartz K, Daubert JC, Komajda M, Hainque B. 2000. Homozygotes for a R869G mutation in the beta -myosin heavy chain gene have a severe form of familial hypertrophic cardiomyopathy. J Mol Cell Cardiol 32:1575-1583.
36. Richard P, Isnard R, Carrier L, Dubourg O, Donatien Y, Mathieu B, Bonne G, Gary F, Charron P, Hagege M, Komajda M, Schwartz K, Hainque B. 1999. Double heterozygosity for mutations in the beta-myosin heavy chain and in the cardiac myosin binding protein C genes in a family with hypertrophic cardiomyopathy. J Med Genet 36:542-545.
37. Xin B, Puffenberger E, Tumbush J, Bockoven JR, Wang H. 2007. Homozygosity for a novel splice site mutation in the cardiac myosin-binding protein C gene causes severe neonatal hypertrophic cardiomyopathy. Am J Med Genet A 143:2662-2667.
38. Zahka K, Kalidas K, Simpson MA, Cross H, Keiler B, Galambos C, Gurtz K, Patton MA, Crosby AH. 2008. Homozygous mutation of MYBPC3 associated with severe infantile hypertrophic cardiomyopathy at high frequency amongst the Amish. Heart.
39. Nanni L, Pieroni M, Chimenti C, Simionati B, Zimbello R, Maseri A, Frustaci A, Lanfranchi G. 2003. Hypertrophic cardiomyopathy: two homozygous cases with "typical" hypertrophic cardiomyopathy and three new mutations in cases with progression to dilated cardiomyopathy. Biochem Biophys Res Commun 309:391-398.

40. Arad M, Maron BJ, Gorham JM, Johnson WH, Jr., Saul JP, Perez-Atayde AR, Spirito P, Wright GB, Kanter RJ, Seidman CE, Seidman JG. 2005. Glycogen storage diseases presenting as hypertrophic cardiomyopathy. N Engl J Med 352:362-372.
41. Ching YH, Ghosh TK, Cross SJ, Packham EA, Honeyman L, Loughna S, Robinson TE, Dearlove AM, Ribas G, Bonser AJ, Thomas NR, Scotter AJ, Caves LS, Tyrrell GP, Newbury-Ecob RA, Munnich A, Bonnet D, Brook JD. 2005. Mutation in myosin heavy chain 6 causes atrial septal defect. Nat Genet 37:423-428.
42. Zhu L, Vranckx R, Khau Van Kien P, Lalande A, Boisset N, Mathieu F, Wegman M, Glancy L, Gasc JM, Brunotte F, Bruneval P, Wolf JE, Michel JB, Jeunemaitre X. 2006. Mutations in myosin heavy chain 11 cause a syndrome associating thoracic aortic aneurysm/aortic dissection and patent ductus arteriosus. Nat Genet 38:343-349.
43. Matsson H, Eason J, Bookwalter CS, Klar J, Gustavsson P, Sunnegardh J, Enell H, Jonzon A, Vikkula M, Gutierrez I, Granados-Riveron J, Pope M, Bu'lock F, Cox J, Robinson TE, Song F, Brook DJ, Marston S, Trybus KM, Dahl N. 2008. Alpha-cardiac actin mutations produce atrial septal defects. Hum Mol Genet 17:256-265.
44. Wessels MW, Willems PJ. 2008. Mutations in sarcomeric protein genes not only lead to cardiomyopathy but also to congenital cardiovascular malformations. Clin Genet 74:16-19.
45. Ingles J, Doolan A, Chiu C, Seidman J, Seidman C, Semsarian C. 2005. Compound and double mutations in patients with hypertrophic cardiomyopathy: implications for genetic testing and counselling. J Med Genet 42:e59.

5.5

Ebstein Anomaly can be caused by Mutations in the *MYH7* Gene encoding Cardiac Beta Myosin Heavy Chain

Marja W. Wessels[1], Wolfgang Höhne[2], Denton A. Cooley[3], Ernst M. Schoonderwaldt[4], Hubert W. Vliegen[5], Michelle Michels[6], Ingrid M. Frohn-Mulder[7], Yvonne M. Hoedemaekers[1], Willem A. Helbing[7], Patrick J.Willems[8], Dennis Dooijes[1]

[1]Department of Clinical Genetics, [4]Department of Obstetrics and Gynecology, [6]Department of Cardiology, [7]Department of Pediatric Cardiology, Erasmus Medical Center, Rotterdam, The Netherlands

[2]Charité University Medicine Berlin, Institute of Biochemistry, Berlin, Germany

[3]Department of Cardiovascular Surgery, Texas Heart Institute at St. Luke's Episcopal Hospital, Houston, TX, USA

[5]Department of Cardiology, Leiden University Medical Center, Leiden, The Netherlands

[8]GENDIA, GENetic DIAgnostic Network, Antwerp, Belgium

Submitted

Abstract

Background Ebstein anomaly of the tricuspid valve occurs in less than 1% of all patients with a congenital heart malformation. Many cases appear sporadic, but familial cases with autosomal dominant inheritance have been reported. No disease gene involved in Ebstein anomaly has been identified yet.

Methods and Results We describe a large family with autosomal dominant inheritance of Ebstein anomaly in association with ventricular septal defect and noncompaction cardiomyopathy. A novel heterozygous missense mutation was identified in the *MYH7* gene encoding the sarcomeric cardiac ß-myosin heavy chain.

Conclusions The association of Ebstein anomaly with ventricular septal defect and noncompaction cardiomyopathy is an autosomal dominant condition that can be caused by mutations in the *MYH7* gene. This indicates that this sarcomeric protein, which is implicated in familial cardiomyopathy, also plays a role in the development of the tricuspid valve and atrial and ventricular septum.

Introduction

Ebstein anomaly of the tricuspid valve is a rare congenital heart malformation (CHM) occurring in less than 1 % of CHM [1]. It was first described by Wilhelm Ebstein in 1866, and in 1927 Alfred Arnstein suggested the name Ebstein anomaly. This anomaly is characterized by adherence of the septal and posterior leaflets of the tricuspid valve to the underlying myocardium, apical displacement of the tricuspid annulus, and dilatation of the atrialized portion of the right ventricle, whereas the attached chordae are usually thin and ill formed [2]. Ebstein anomaly is frequently associated with other forms of CHM: in

70-90 % an interatrial communication is present, and occasional findings include pulmonary or aortic valve stenosis or atresia, mitral valve abnormalities, transposition of the great arteries, or conduction system anomalies, including accessory conduction pathways (eg Wolff-Parkinson-White syndrome) [3-5]. Noncompaction cardiomyopathy (NCCM) is present in almost 20 % of patients [6,7].

Environmental as well as genetic factors may play a role in the etiology of Ebstein anomaly. Maternal exposure to benzodiazepines and maternal lithium therapy may increase the risk of Ebstein anomaly [1,8]. Several chromosomal anomalies and inherited animal models with Ebstein anomaly have been reported [9-17]. Although most cases of Ebstein anomaly occur sporadically, familial occurrence has been reported: several reports of sibs [18-25] or multiple family members with Ebstein anomaly in different generations [19,26-31] suggest that Ebstein anomaly might be caused by autosomal recessive or dominant mutations. The association of Ebstein anomaly with NCCM of both the left and the right ventricle[32] has been reported in several cases [7,33-39], and also a few familial cases with autosomal dominant inheritance of this association have been described [32,40].

Here we report a clinical and genetic analysis of a family with an autosomal dominant form of Ebstein anomaly associated with noncompaction cardiomyopathy. Mutation analysis of the *MYH7* gene encoding the sarcomeric cardiac ß-myosin heavy chain revealed a novel missense mutation in the ATP-binding domain.

Methods

Clinical Evaluation

The proband, his father and paternal uncle were examined at 2 tertiary referral centers (Erasmus Medical Center Rotterdam and Leiden University Center, The Netherlands). Two other family members were studied at the Texas heart Center Houston, USA. Additional family members were investigated by various cardiologists.

The diagnosis of left ventricular noncompaction was made based upon echocardiographic criteria established by Jenni et al. [41] (with the exception of the presence of a CHM). Informed consent was obtained from all participants.

Medical records of the deceased children and participating family members were reviewed by one of us (MWW).

Molecular Analysis

Genomic DNA of the proband's father (patient IV-5) and his brother (IV-4) was isolated from peripheral blood samples. All coding regions and intron-exon boundaries of the *MYH7* gene were analyzed by direct sequence analysis. Sequence analysis of M13-tagged PCR products was carried out on an ABI3730xl capillary sequencer using Big-Dye Terminator v 3.1 chemistry (Applied Biosystems). Details of methods and primer sequences are available on request. Analysis of sequence data was performed using SeqScape analysis software (v2.5, Applied Biosystems). Subsequently, using the same techniques, the complete coding regions and intron-exon boundaries of *MYBPC3, TNNT2, TNNI3, TNNC1, TPM1,* and *ACTC1,* the Z-disk genes *TCAP* and *CSRP3,* the Ca-handling genes *CALM1, CASQ2, CALR3, PLN, SLN, SRI,*

LMNA and *NKX2-5* were analyzed to exclude that additional pathogenic mutations in these genes contributed to the phenotype observed in the patients.

Results

Clinical Evaluation

The family presented here (Figure 1) was first referred to us because of the prenatal diagnosis of mild Ebstein anomaly in a fetus (patient V-1) at 22 weeks of gestation. No tricuspid regurgitation was present and the pregnancy continued uneventfully. A girl was born at term in good condition with a weight of 4400 grams. The prenatal diagnosis of Ebstein anomaly was confirmed by echocardiography. At the present age of 2 years the child has mild Ebstein anomaly without tricuspid regurgitation or ventricular wall thickening. She is developing normally without medication.

The father of patient V-1 (IV- 5) had no medical history or signs of cardiac disease. After the diagnosis of Ebstein anomaly in his daughter he was referred for cardiac evaluation at the age of 40. Clinical examination including ECG, echocardiography and MRI revealed NCCM. A paternal uncle (patient IV-7) of the proband died at the age of one month because of a severe congenital heart malformation. At autopsy (records from 1972) a grossly enlarged heart was found, with dilated and hypertrophic ventricles. A ventricular septal defect (VSD) of 8 mm was present just beneath the insertion of the septal leaflet of the tricuspid valve. The aorta was in a slightly anterior position. Lung edema was seen with thin-walled dilated arteries and dilatation lesions, as seen in pulmonary hypertension.

Another paternal uncle of the proband (patient IV-4) was diagnosed with mild Ebstein anomaly at the age of 10 years. At the age of 40 echocardiography showed tricuspid leaflets inserting 21 mm below the mitral valve. Severe mitral regurgitation and decreased systolic function were present. Both the right and left atria were enlarged. A small right ventricle with hypertrabeculation, and a left ventricle with hypertrabeculation and many crypts were present, confirming NCCM of both ventricles. An aneurysm of the perimembraneous interventricular septum was observed, but no septal defect was visualized (Figure 2).

The paternal grandparents of the proband were consanguineous (first-degree cousins). The paternal grandfather of the proband (III-6) was asymptomatic, but was never evaluated by a cardiologist. His sister (patient III-3) has atrial fibrillation and cardiomyopathy with left ventricular dysfunction and heart failure. A brother (patient III-5) was diagnosed with a VSD. He died suddenly at the age of 40. Another brother of the paternal grandfather was asymptomatic but had three children with a CHM. The first born, a girl (patient IV-1), was diagnosed at birth with a grossly enlarged heart, pulmonary valve stenosis, severe Ebstein anomaly with a hypoplastic right ventricle and a large right atrium. She died at the age of 3 weeks during cardiac surgery. Autopsy confirmed the cardiac malformations. The second girl (patient IV-2) was born with a weight of 4050 grams and had no clinical symptoms. She was examined at the age of three weeks because of the family history of congenital heart malformations. She was diagnosed with a grossly enlarged heart with a VSD, patent ductus arteriosus, double-chambered right ventricle and left ventricular hypertrophy. At the age of 5 months and 2 years the child was in good

condition, according to the medical files and family history she did not receive further cardiological follow up. The third child (patient IV-3), a boy, was born with a weight of 3450 grams. Within the first days a systolic murmur was heard. At the age of 2 months he was admitted to the Texas Heart Institute for cardiac evaluation. Catheterization revealed a patent foramen ovale, a small VSD with a large trabeculated left ventricle, and a double-chambered right ventricle with and a smooth-walled atrialized sinus portion. He was treated for congestive heart failure. At the age of 2 years he was reevaluated and primary closure of the VSD and atrial septal defect (ASD) was performed. The VSD was a type 2 and of moderate size (6-7 mm) with pedunculated aneurysm. An unusual anatomy of the tricuspid valve was noted, with a leaflet overlaying the septal defect, as seen in Ebstein anomaly. The 2 sibs IV-2 and IV-3 are alive at the age of 33 and 32 years, respectively, but no further cardiac evaluations have been performed since childhood.

The paternal grandmother (III-7) died suddenly at the age of 45 years. She had experienced heart palpitations during the last years of her life. No medical records of cardiac evaluations could be obtained from her or her sibs. Her brother was operated before the age of 50 years because of heart valve insufficiency. One sister had a history of cardiac palpitations and a heart murmur. A daughter of another sister has an enlarged heart, but no detailed information could be obtained. It is unclear whether the CHM present in IV-4, IV-5 and IV-7 was inherited through the father III-6 or the mother III-7.

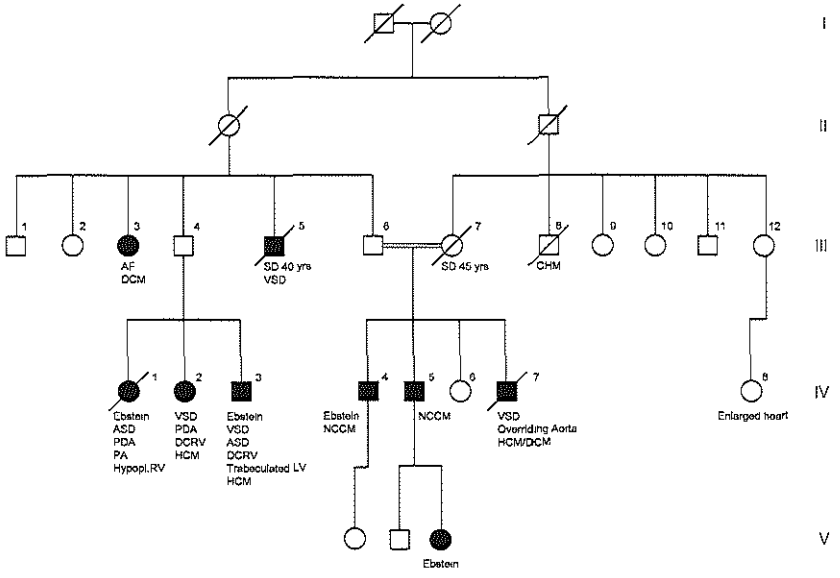

Figure 1 | Pedigree of the family with Ebstein anomaly, septal defects and NCCM

Blackened family members are affected with CHM: 4 family members have Ebstein anomaly, 5 have septal effects, 2 have NCCM and several others have cardiomyopathy. It is unclear whether the NCCM and/or CHM present in IV-4, IV-5 and IV-7 was inherited through the father III-6 or the mother III-7. The p.Phe230Ser mutation was present in patients IV-4 and IV-5.

Abbreviations: AF, atrial fibrillation; ASD, atrial septal defect; DCM, dilated cardiomyopathy; DCRV, double-chambered right ventricle; HCM, hypertrophic cardiomyopathy; LV, left ventricle; PA, pulmonary atresia; PFO, patent foramen ovale; PDA, patent ductus arteriosus; NCCM, noncompaction cardiomyopathy; RV, right ventricle; SD, sudden death; VSD, ventricular septal defect.

Molecular Analyses

Molecular diagnostic work-up of patient IV-4 with Ebstein anomaly and NCCM included sequencing of all coding regions and the intron-exon boundaries of the following genes: the sarcomeric genes *MYH7, MYBPC3, TNNT2, TNNI3, TNNC1, TPM1,* and *ACTC1,* the Z-disk genes *TCAP* and *CSRP3,* the Ca-handling genes *CALM1, CASQ2, CALR3, PLN, SLN, SRI* and *FKBP1B,* and *NKX2-5* and *LMNA.* No disease-associated mutation could be found in all these genes. A heterozygous missense mutation c.689T>C in exon 8 of the *MYH7* gene was identified, predicting the substitution of a phenylalanine by a serine at amino acid position 230 (p.Phe230Ser). This mutation was also identified in his brother (patient IV-5) who has NCCM, and in the affected proband (patient V-1) with Ebstein anomaly. No other family members were available for molecular testing.

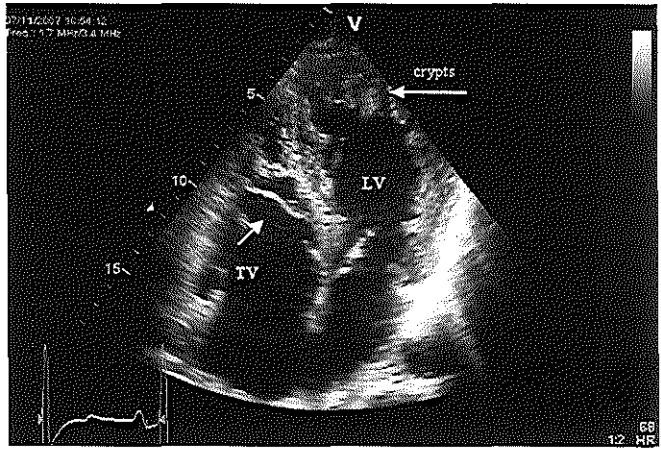

Figure 2 | Echocardiogram (4-chambered view, apex up) of patient IV-4 with NCCM and Ebstein anomaly. Prominent trabeculations are visible, mainly in the left ventricular apex and an apical displacement of the septal and posterior leaflet from the atrioventricular ring.

The c.689T>C (p.Phe230Ser) mutation is a novel mutation, neither present in the literature nor in any database. In our own data set of more than 200 sequenced *MYH7* genes we never encountered this mutation. The phenylalanine residue at position 230 shows complete cross-species conservation until zebrafish (Figure 3), and computer prediction software (SIFT) identifies this missense mutation as pathogenic.

Discussion

We describe an extended Caribbean family with autosomal dominant inheritance of non-syndromic congenital heart malformations. Ebstein anomaly was present in 4 and sepal defects in 5 family members. Several family members were diagnosed with cardiomyopathy, and in two patients NCCM was diagnosed.

Familial Ebstein anomaly is rare and only around 20 families have been described in literature. As many of these families consist of only two affected patients the pattern of inheritance is not always clear [18-25]. Only in a few families autosomal dominant inheritance of Ebstein anomaly has been

described. Balaji et al. [30] described a family with an autosomal dominant association of Ebstein anomaly with joint anomalies (restricted finger extension and extension limitation of larger joints). Schunkert et al. [42] described a family with autosomal dominant inheritance of Ebstein anomaly with valvuloseptal defects and atrioventricular canal. Some families with autosomal dominant inheritance of Ebstein anomaly also show NCCM [32,40,43]. Multiple loci for Ebstein anomaly have been suggested from studies in humans and animals. In humans Ebstein anomaly has been reported in patients with mutations in the *NKX2.5* [44] and *TBX5* genes [45]. Also several chromosomal abnormalities are associated with Ebstein anomaly, including 1p36 deletion, 8p23 deletion, trisomy 9p, 10p13-14 deletion, 11q deletion, 15q duplication, trisomy 21, and 22q11 deletion/duplication. As most of these chromosomal abnormalities were occasional findings it is unclear whether the chromosome imbalance was responsible for Ebstein anomaly [9-17] (for review: see Miller et al.[11]). In Labrador retrievers autosomal dominant tricuspid valve malformation is clinically similar to Ebstein anomaly in humans, and a gene locus has been mapped to a region of canine chromosome 9, which is syntenic to human 17q12-q23 [15]. Finally, several knockout mice exhibit cardiac abnormalities similar to the anomalies seen in humans with Ebstein anomaly. Mice with targeted deletion of Alk3, a type 1A receptor for Bone Morphogenetic Proteins (BMPs), signaling proteins involved in endocardial cushion formation, reveal displacement and adherence of the posterior leaflet of the tricuspid valve, as seen in human Ebstein anomaly [16]. Mice with null mutations of peri-



Figure 3 | Alignment of the regions flanking the novel p.Phe230Ser and the known p.Leu301Gln mutation in *MYH7*. The alignment illustrates the evolutionary conservation of the mutated *MYH7* residues p.Phe230 and p.Leu301, and the respective flanking amino acids across species.

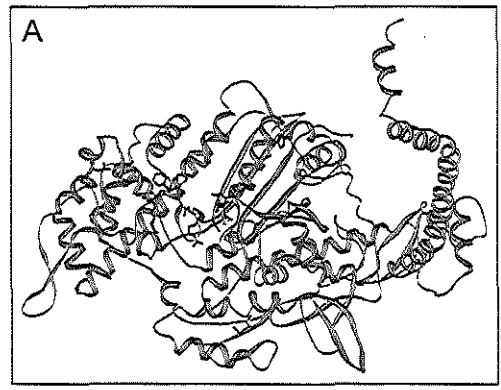

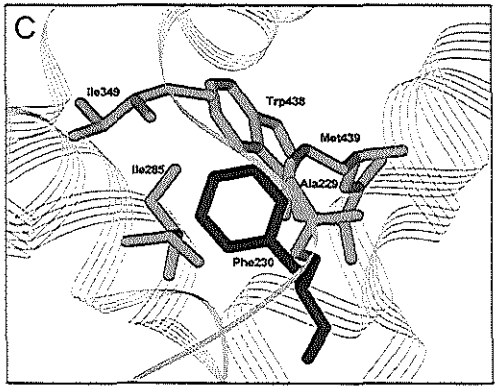

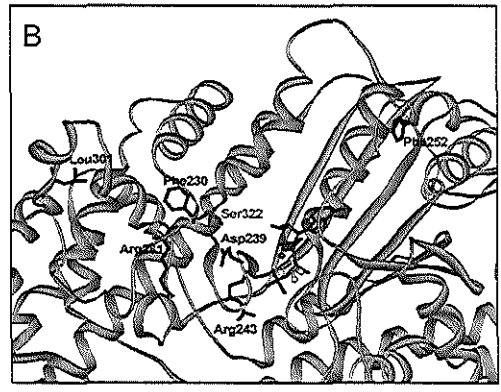

Figure 4 | Position of the p.Phe230Ser and p.Leu301Gln mutations in a protein model of the myosin heavy chain

A. Visualisation of the clustering of amino acid changes found in patients with NCCM and/or Ebstein anomaly in a protein model of the 3D structure of the chicken myosin heavy chain S1 fragment (PDB code 2MYS).

B. Close up view of the ATP binding site and the residues homologous to the human *MYH7* gene. Mutations in the ATP binding site resulting in NCCM are indicated. The mutated residues p.Phe230 and p.Leu301 described here are indicated in red. Other positions in this area known to be mutated with NCCM are shown in brown. The sulfate in the ATP binding site is indicated in yellow, the catalytic serine residue p.Ser322 in margenta. The ATP/ Mg2+ (orange) is from a myosin structure of the slime mold *Dictyostellum discoideum* (PDB code 1MMG).

C. The p.Phe230Ser mutation is situated in a hydrophobic pocket formed by the side chains of residues p.Ala229, p.Ile285, p.Met349, p.Trp438, and p.Met439.

ostin, an extracellular matrix protein involved in atrioventricular valve formation, show various tricuspid valve anomalies resembling human Ebstein anomaly [17].

Apart from the autosomal dominant inheritance of Ebstein anomaly, our family is also unusual in that Ebstein anomaly is associated with NCCM in two family members (patient IV-4 and IV-5), and cardiomyopathy is present in several additional family members. As cardiological examinations in the deceased children took place in 1973/1974, and echocardiography records or pathological specimens were no longer available for re-valuation, it is unclear whether myocardial abnormalities in these children would have fitted the diagnosis NCCM. Patient IV-3 might also have had NCCM as he was diagnosed with a large trabeculated left ventricle and double- chambered right ventricle at the age of two months. The association of Ebstein anomaly and NCCM is well known, and NCCM is present in up to 20% of patients with Ebstein anomaly [6,7]. As this association is also reported in families compatible with autosomal dominant inheritance this might be a specific subgroup of Ebstein anomaly with a monogenic origin [32,40,43]. NCCM is genetically heterogeneous as mutations in several genes, including the *TAZ-G4.5* gene encoding taffazin[46], the *Cypher-ZASP* gene (*LDB3)* encoding LIM domain binding protein 3 [47], and the *DTNA* gene encoding α-dystrobrevin,[48] have been reported, albeit in a limited group of patients [49,50]. Several studies [43,51-54] indicate that NCCM can also be caused by mutations in sarcomeric protein

genes that are also implicated in different cardiomyopathies (hypertrophic, dilated and restrictive). Recently, Budde et al. [43] described a large family with autosomal dominant NCCM (12 family members) and Ebstein anomaly (4 family members) caused by a p.Arg281Thr mutation in the *MYH7* gene. Three of the four patients with Ebstein anomaly also had an ASD. To investigate the possible involvement in our family of one of the genes known to be implicated in familial cardiomyopathies, we sequenced the complete coding regions and intron-exon boundaries of a large number of sarcomeric and other candidate genes, and identified a novel missense mutation c.689T>C (p.Phe230Ser) in the *MYH7* gene. In another of our NCCM families with a *MYH7* mutation (p.Leu301Gln) described by Hoedemaekers et al. [52] we recently found a hypertrabeculated left ventricle with mild Ebstein anomaly in a 12-year-old girl, and confirmed she also had the familial p.Leu301Gln mutation. The observations in these 3 families indicate that a subset of cases with Ebstein anomaly, in particular those associated with NCCM, may be due to mutations in the *MYH7* gene encoding cardiac ß-myosin heavy chain gene. As NCCM is not reported in all familial cases of Ebstein anomaly, other genes might be involved. However, NCCM can be overlooked, indicating that serial examinations are mandatory in patients with familial Ebstein anomaly, even with mild valvular abnormalities to monitor development of cardiomyopathy. Further studies are needed to explore the contribution of sarcomeric mutations in isolated and familial cases of Ebstein malformation, with or without NCCM.

MYH7 mutations are very common in familial forms of cardiomyopathy, including hypertrophic cardiomyopathy (HCM), dilated cardiomyopathy (DCM), restrictive cardiomyopathy (RCM), and distal myopathies with mild cardiac involvement such as Laing distal myopathy, central core disease and myosin storage myopathy. Most mutations leading to the different cardiomyopathies are located in the head and neck regions, much more than in the rod region, whereas *MYH7* mutations leading to distal myopathies with limited cardiomyopathy are located in the rod region. Seven of the 9 *MYH7* mutations associated with NCCM, including the p.Phe230Ser mutation in our family, cluster in the head region of MYH7, more in particular in the ATPase active site encoded by exons 8-11 of *MYH7*.[43,51,52] The ATPase active site is an evolutionary conserved region of MYH7 (Figure 4A and 4B). The p.Phe230 residue is located in a hydrophobic pocket formed by the side chains of residues p.Ala229, p.Ile285, p.Met349, p.Trp438, and p.Met439. Thus this residue keeps the C-terminus of the helix p.Asp218 to p.Phe230 (which is close to the ATP binding site) in proper place. Substitution of the p.Phe230 residue by the smaller and highly polar serine side chain would disturb this hydrophobic cluster (Figure 4C). As the ATPase active site is required for normal force production, impaired force generation might play a role in the aetiology of the abnormal tricuspid development and the septal defects seen in these families.

Ebstein anomaly is characterized by downward displacement of the posterior and septal tricuspid leaflets with a normally positioned anterior leaflet. This is interesting from an embryonic point of view as the anterio-superior leaflet of the tricuspid valve originates from different structures than the inferior and septal leaflets: the anterior-superior leaflet develops out of the endocardial tissue of the atrioventricular canal and the outflow segment, whereas both the septal and posterior leaflets develop out of the endocardial cushion and ventricular musculature. The two latter leaflets are formed by delamination from the underlying myocardium; a process that includes formation of the papillary muscles attached to the leaflets and that takes place during weeks eight through 12. In Ebstein anomaly this

process is disturbed, and the septal and inferior leaflets remain "plastered" to the ventricular myocardium, reminiscent of the topography of the developing tricuspid valve in week eight of development [55]. NCCM is regarded as a developmental arrest in the same embryonic period, when the ventricular myocardium is remodeled and transformed from noncompacted to compacted. We therefore suggest that Ebstein anomaly and NCCM can both be caused by the same developmental arrest between week eight and 12, and therefore sometimes occur together. It has also been established that the development of the tricuspid valve is associated with septation, and the ventricular wall in Ebstein anomaly reveals a decrease or total absence of myocardial fibers in the inlet portion of the interventricular septum [55,56]. The presence of septal defects in several members of our family suggests that the MYH7 protein also plays a important role in septation, and that this developmental process occurs in the same embryological time window as ventricular compaction and formation of the tricuspid valve. This corroborates the earlier observation that mutations in sarcomeric protein genes such as *MYH6* and *ACTC1* not only cause different cardiomyopathies including NCCM, but also developmental defects resulting in congenital heart malformations [54,57,58].

References

1. Correa-Villasenor A, Ferencz C, Neill CA, Wilson PD, Boughman JA. 1994. Ebstein's malformation of the tricuspid valve: genetic and environmental factors. The Baltimore-Washington Infant Study Group. Teratology 50:137-147.
2. Madiwale CV, Deshpande JR, Kinare SG. 1997. Ebstein's anomaly—an autopsy study of 28 cases. J Postgrad Med 43:8-11.
3. Barbara DW, Edwards WD, Connolly HM, Dearani JA. 2008. Surgical pathology of 104 tricuspid valves (2000-2005) with classic right-sided Ebstein's malformation. Cardiovasc Pathol 17:166-171.
4. Munoz-Castellanos L, Espinola-Zavaleta N, Kuri-Nivon M, Keirns C. 2007. Ebstein's Anomaly: anatomo-echocardiographic correlation. Cardiovasc Ultrasound 5:43.
5. Attenhofer Jost CH, Connolly HM, Dearani JA, Edwards WD, Danielson GK. 2007. Ebstein's anomaly. Circulation 115:277-285.
6. Attenhofer Jost CH, Connolly HM, O'Leary PW, Warnes CA, Tajik AJ, Seward JB. 2005. Left heart lesions in patients with Ebstein anomaly. Mayo Clin Proc 80:361-368.
7. Attenhofer Jost CH, Connolly HM, Warnes CA, O'Leary P, Tajik AJ, Pellikka PA, Seward JB. 2004. Noncompacted myocardium in Ebstein's anomaly: initial description in three patients. J Am Soc Echocardiogr 17:677-680.
8. Cohen LS, Friedman JM, Jefferson JW, Johnson EM, Weiner ML. 1994. A reevaluation of risk of in utero exposure to lithium. Jama 271:146-150.
9. Paez MT, Yamamoto T, Hayashi K, Yasuda T, Harada N, Matsumoto N, Kurosawa K, Furutani Y, Asakawa S, Shimizu N, Matsuoka R. 2008. Two patients with atypical interstitial deletions of 8p23.1: mapping of phenotypical traits. Am J Med Genet A 146A:1158-1165.
10. Baekvad-Hansen M, Tumer Z, Delicado A, Erdogan F, Tommerup N, Larsen LA. 2006. Delineation of a 2.2 Mb microdeletion at 5q35 associated with microcephaly and congenital heart disease. Am J Med Genet A 140:427-433.
11. Miller MS, Rao PN, Dudovitz RN, Falk RE. 2005. Ebstein anomaly and duplication of the distal arm of chromosome 15: report of two patients. Am J Med Genet A 139A:141-145.
12. Nakagawa M, Kato H, Aotani H, Kondo M. 1999. Ebstein's anomaly associated with trisomy 9p. Clin Genet 55:383-385.
13. de Lonlay-Debeney P, de Blois MC, Bonnet D, Amiel J, Abadie V, Picq M, Lyonnet S, Sidi D, Munnich A, Vekemans M, Cormier-Daire V. 1998. Ebstein anomaly associated with rearrangements of chromosomal region 11q. Am J Med Genet 80:157-159.
14. Battaglia A, Hoyme HE, Dallapiccola B, Zackai E, Hudgins L, McDonald-McGinn D, Bahi-Buisson N, Romano C, Williams CA, Brailey LL, Zuberi SM, Carey JC. 2008. Further delineation of deletion 1p36 syndrome in 60 patients: a recognizable phenotype and common cause of developmental delay and mental retardation. Pediatrics 121:404-410.
15. Andelfinger G, Wright KN, Lee HS, Siemens LM, Benson DW. 2003. Canine tricuspid valve malformation, a model of human Ebstein anomaly, maps to dog chromosome 9. J Med Genet 40:320-324.
16. Gaussin V, Morley GE, Cox L, Zwijsen A, Vance KM, Emile L, Tian Y, Liu J, Hong C, Myers D, Conway SJ, Depre C, Mishina Y, Behringer RR, Hanks MC, Schneider MD, Huylebroeck D, Fishman GI, Burch JB, Vatner SF. 2005. Alk3/Bmpr1a receptor is required for development of the atrioventricular canal into valves and annulus fibrosus. Circ Res 97:219-226.
17. Norris RA, Moreno-Rodriguez RA, Sugi Y, Hoffman S, Amos J, Hart MM, Potts JD, Goodwin RL, Markwald RR. 2008. Periostin regulates atrioventricular valve maturation. Dev Biol 316:200-213.
18. Gueron M, Hirsch M, Stern J, Cohen W, Levy MJ. 1966. Familial Ebstein's anomaly with emphasis on the surgical treatment. Am J Cardiol 18:105-111.
19. Simcha A, Bonham-Carter RE. 1971. Ebstein's anomaly. Clinical study of 32 patients in childhood. Br Heart J 33:46-49.
20. Watson H. 1974. Natural history of Ebstein's anomaly of tricuspid valve in childhood and adolescence. An international co-operative study of 505 cases. Br Heart J 36:417-427.
21. Lo KS, Loventhal JP, Walton JA, Jr. 1979. Familial Ebstein's anomaly. Cardiology 64:246-255.
22. McIntosh N, Chitayat D, Bardanis M, Fouron JC. 1992. Ebstein anomaly: report of a familial occurrence and prenatal diagnosis. Am J Med Genet 42:307-309.
23. Grant JW. 1996. Congenital malformations of the tricuspid valve in siblings. Pediatr Cardiol 17:327-329.
24. Margalit-Stashefski R, Lorber A, Margalit E. 1998. [Familial occurrence of Ebstein anomaly]. Harefuah 134:762-764, 832.
25. Uyan C, Yazici M, Uyan AP, Akdemir R, Imirzalioglu N, Dokumaci B. 2002. Ebstein's anomaly in siblings: an original observation. Int J Cardiovasc Imaging 18:435-438.
26. Donegan CC, Jr., Moore MM, Wiley TM, Jr., Hernandez FA, Green JR, Jr., Schiebler GL. 1968. Familial Ebstein's anomaly of the tricuspid valve. Am Heart J 75:375-379.
27. Rosenmann A, Arad I, Simcha A, Schaap T. 1976. Familial Ebstein's anomaly. J Med Genet 13:532-535.

28. Pierard LA, Henrard L, Demoulin JC. 1985. Persistent atrial standstill in familial Ebstein's anomaly. Br Heart J 53:594-597.
29. Zalzstein E, Koren G, Einarson T, Freedom RM. 1990. A case-control study on the association between first trimester exposure to lithium and Ebstein's anomaly. Am J Cardiol 65:817-818.
30. Balaji S, Dennis NR, Keeton BR. 1991. Familial Ebstein's anomaly: a report of six cases in two generations associated with mild skeletal abnormalities. Br Heart J 66:26-28.
31. Davido A, Maarek M, Jullien JL, Corone P. 1985. [Ebstein's disease associated with Fallot's tetralogy. Apropos of a familial case, review of the literature, embryologic and genetic implications]. Arch Mal Coeur Vaiss 78:752-756.
32. Sinkovec M, Kozelj M, Podnar T. 2005. Familial biventricular myocardial noncompaction associated with Ebstein's malformation. Int J Cardiol 102:297-302.
33. de Agustin JA, Perez de Isla L, Zamorano JL. 2008. Ebstein anomaly and hypertrophic cardiomyopathy. Eur Heart J.
34. El-Menyar AA, Gendi SM, Numan MT. 2007. Noncompaction cardiomyopathy in the State of Qatar. Saudi Med J 28:429-434.
35. Kiernan TJ, Fahy G. 2007. Multiple accessory pathways, dual AV nodal physiology, non-compacted myocardium and patent foramen ovale in a patient with Ebstein's anomaly: report of a case. Int J Cardiol 114:412-413.
36. Arslan S, Gurlertop HY, Gundogdu F, Senocak H. 2007. Left ventricular noncompaction and mid-caviter narrowing associated with Ebstein's anomaly: three-dimensional transthoracic echocardiographic image. Int J Cardiol 115:e52-55.
37. Ilercil A, Barack J, Malone MA, Barold SS, Herweg B. 2006. Association of noncompaction of left ventricular myocardium with Ebstein's anomaly. Echocardiography 23:432-433.
38. Bagur RH, Lederlin M, Montaudon M, Latrabe V, Corneloup O, Iriart X, Laurent F. 2008. Images in cardiovascular medicine. Ebstein anomaly associated with left ventricular noncompaction. Circulation 118:e662-664.
39. Song ZZ. 2009. A combination of right ventricular hypertrabeculation/noncompaction and Ebstein's anomaly. Int J Cardiol.
40. Betrian Blasco P, Gallardo Agromayor E. 2007. Ebstein's anomaly and left ventricular noncompaction association. Int J Cardiol 119:264-265.
41. Jenni R, Oechslin EN, van der Loo B. 2007. Isolated ventricular non-compaction of the myocardium in adults. Heart 93:11-15.
42. Schunkert H, Brockel U, Kromer EP, Elsner D, Jacob HJ, Riegger GA. 1997. A large pedigree with valvuloseptal defects. Am J Cardiol 80:968-970.
43. Budde BS, Binner P, Waldmuller S, Hohne W, Blankenfeldt W, Hassfeld S, Bromsen J, Dermintzoglou A, Wieczorek M, May E, Kirst E, Seligmow C, Rackebrandt K, Muller M, Goody RS, Vosberg HP, Nurnberg P, Scheffold T. 2007. Noncompaction of the ventricular myocardium is associated with a de novo mutation in the beta-myosin heavy chain gene. PLoS ONE 2:e1362.
44. Benson DW, Silberbach GM, Kavanaugh-McHugh A, Cottrill C, Zhang Y, Riggs S, Smalls O, Johnson MC, Watson MS, Seidman JG, Seidman CE, Plowden J, Kugler JD. 1999. Mutations in the cardiac transcription factor NKX2.5 affect diverse cardiac developmental pathways. J Clin Invest 104:1567-1573.
45. Tongsong T, Chanprapaph P. 2000. Prenatal sonographic diagnosis of Holt-Oram syndrome. J Clin Ultrasound 28:98-100.
46. Brady AN, Shehata BM, Fernhoff PM. 2006. X-linked fetal cardiomyopathy caused by a novel mutation in the TAZ gene. Prenat Diagn 26:462-465.
47. Vatta M, Mohapatra B, Jimenez S, Sanchez X, Faulkner G, Perles Z, Sinagra G, Lin JH, Vu TM, Zhou Q, Bowles KR, Di Lenarda A, Schimmenti L, Fox M, Chrisco MA, Murphy RT, McKenna W, Elliott P, Bowles NE, Chen J, Valle G, Towbin JA. 2003. Mutations in Cypher/ZASP in patients with dilated cardiomyopathy and left ventricular non-compaction. J Am Coll Cardiol 42:2014-2027.
48. Ichida F, Tsubata S, Bowles KR, Haneda N, Uese K, Miyawaki T, Dreyer WJ, Messina J, Li H, Bowles NE, Towbin JA. 2001. Novel gene mutations in patients with left ventricular noncompaction or Barth syndrome. Circulation 103:1256-1263.
49. Xing Y, Ichida F, Matsuoka T, Isobe T, Ikemoto Y, Higaki T, Tsuji T, Haneda N, Kuwabara A, Chen R, Futatani T, Tsubata S, Watanabe S, Watanabe K, Hirono K, Uese K, Miyawaki T, Bowles KR, Bowles NE, Towbin JA. 2006. Genetic analysis in patients with left ventricular noncompaction and evidence for genetic heterogeneity. Mol Genet Metab 88:71-77.
50. Kenton AB, Sanchez X, Coveler KJ, Makar KA, Jimenez S, Ichida F, Murphy RT, Elliott PM, McKenna W, Bowles NE, Towbin JA, Bowles KR. 2004. Isolated left ventricular noncompaction is rarely caused by mutations in G4.5, alpha-dystrobrevin and FK Binding Protein-12. Mol Genet Metab 82:162-166.
51. Klaassen S, Probst S, Oechslin E, Gerull B, Krings G, Schuler P, Greutmann M, Hurlimann D, Yegitbasi M, Pons L, Gramlich M, Drenckhahn JD, Heuser A, Berger F, Jenni R, Thierfelder L. 2008. Mutations in sarcomere protein genes in left ventricular noncompaction. Circulation 117:2893-2901.

52. Hoedemaekers YM, Caliskan K, Majoor-Krakauer D, van de Laar I, Michels M, Witsenburg M, ten Cate FJ, Simoons ML, Dooijes D. 2007. Cardiac beta-myosin heavy chain defects in two families with non-compaction cardiomyopathy: linking non-compaction to hypertrophic, restrictive, and dilated cardiomyopathies. Eur Heart J 28:2732-2737.
53. Kaneda T, Naruse C, Kawashima A, Fujino N, Oshima T, Namura M, Nunoda S, Mori S, Konno T, Ino H, Yamagishi M, Asano M. 2008. A novel beta-myosin heavy chain gene mutation, p.Met531Arg, identified in isolated left ventricular non-compaction in humans, results in left ventricular hypertrophy that progresses to dilation in a mouse model. Clin Sci (Lond) 114:431-440.
54. Monserrat L, Hermida-Prieto M, Fernandez X, Rodriguez I, Dumont C, Cazon L, Cuesta MG, Gonzalez-Juanatey C, Peteiro J, Alvarez N, Penas-Lado M, Castro-Beiras A. 2007. Mutation in the alpha-cardiac actin gene associated with apical hypertrophic cardiomyopathy, left ventricular non-compaction, and septal defects. Eur Heart J 28:1953-1961.
55. Lamers WH, Viragh S, Wessels A, Moorman AF, Anderson RH. 1995. Formation of the tricuspid valve in the human heart. Circulation 91:111-121.
56. Anderson KR, Lie JT. 1979. The right ventricular myocardium in Ebstein's anomaly: a morphometric histopathologic study. Mayo Clin Proc 54:181-184.
57. Ching YH, Ghosh TK, Cross SJ, Packham EA, Honeyman L, Loughna S, Robinson TE, Dearlove AM, Ribas G, Bonser AJ, Thomas NR, Scotter AJ, Caves LS, Tyrrell GP, Newbury-Ecob RA, Munnich A, Bonnet D, Brook JD. 2005. Mutation in myosin heavy chain 6 causes atrial septal defect. Nat Genet 37:423-428.
58. Wessels MW, Willems PJ. 2008. Mutations in sarcomeric protein genes not only lead to cardiomyopathy but also to congenital cardiovascular malformations. Clin Genet 74:16-19.

CHAPTER 6

General discussion



CHAPTER 6

General discussion

In the past decade significant progress has been made in the dissection of the molecular biology of cardiogenesis. An important contribution to this understanding was made by the identification of disease genes implicated in syndromic forms of congenital heart malformation (CHM). These human genes identified important molecular pathways that could be further studied in animal models leading to the identification of more candidate genes for human CHM. Examples of this approach are the discovery of the network of transcription factors in Holt-Oram syndrome and related disorders, the TBX1 pathway in neural crest-related disorders, the RAS-MAPK pathway implicated in Noonan syndrome and related disorders, the NOTCH pathway in Alagille syndrome and related disorders, and the TGFß signaling pathway in Marfan syndrome and related disorders. However, only a minority of CHM without additional malformations (non-syndromic CHM) is caused by mutations in these genes. As non-syndromic CHM is much more frequent than syndromic CHM, the future challenge is to identify genes implicated in non-syndromic CHM. Most non-syndromic CHM occurs sporadically, and extended families with clear monogenic inheritance of non-syndromic CHM are scarce, thereby precluding the identification of diseases genes involved in non-syndromic CHM by a classical positional genetics approach.

In this thesis families with monogenic forms of syndromic CHM (arterial tortuosity syndrome, X-linked heterotaxy, and Kartagener syndrome) and non-syndromic CHM (LVOTO, valvular defects, cardiomyopathy, and Ebstein anomaly) were studied at the clinical level to delineate the phenotypes and at the molecular level to identify the genetic defect in known or novel disease genes. It is clear from several studies in this thesis that specific associations of different CHM may result from the same genetic defect: the association of heterotaxy with VACTERL anomaly caused by repeat amplification in the *ZIC3* gene (Chapter 2), the association between cardiomyopathy and septal defects caused by mutations in the *MYBPC3* and *MYH7* genes (Chapter 5), the association of cardiomyopathy with Ebstein anomaly and/or septal defects caused by mutations in the *MYH7* gene (Chapter 5), and the association between cardiomyopathy and heterotaxy caused by an unknown gene on chromosome 6 (Chapter 2). These associations could only be recognized through family studies, as different family members had different forms of CHM.

Different genetic strategies were used in this thesis to search for genes involved in cardiovascular anomalies in both syndromic and non-syndromic families. The gene for Arterial tortuosity syndrome was identified after homozygosity mapping in several consanguineous families from an inbred North African population (Chapter 4). Homozygosity mapping is a very successful method to identify autosomal recessive disease genes in inbred families. However, families with autosomal recessive forms of CHM are rare, and most monogenetic CHM has an autosomal dominant mode of inheritance. Linkage analysis in autosomal dominant diseases requires large pedigrees with multiple affected family mem-

bers in multiple generations. However, extended families with clear autosomal dominant inheritance of non-syndromic CHM are scarce. Although autosomal dominant pedigrees with noncompaction and heterotaxy (Chapter 2), and LVOTO with valve defects (Chapter 3) could be identified, only suggestive linkage to large chromosomal regions containing multiple candidate genes could be obtained, as the families were too small to yield high lod scores. To identify the disease gene in those families two approaches will be followed. The first approach will be a traditional positional genetics approach: additional families with the same type of CHM will be used to narrow down the linkage region. This approach requires identification of families with similar phenotypes presumably caused by the same disease gene. However, as most cardiac phenotypes are genetically heterogeneous and many genes involved in cardiogenesis have pleiotropic effects, it is not always obvious to classify CHM. The second approach is using next-generation sequencing. Whereas sequencing of large candidate regions obtained after initial linkage studies used to be too time - and cost consuming, this has recently become a realistic approach by the development of new technologies for high-throughput massive parallel sequencing on so-called "next-generation sequencers". Next-generation sequencing of large linkage intervals will facilitate the identification of CHM genes in autosomal dominant families such as presented in our thesis.

Although the families with non-syndromic CHM studied in this thesis are amenable to positional cloning of the disease gene, they are unique families. Overall, most non-syndromic CHM occurs sporadically. Only in a low fraction (less than 5%) of non-syndromic CHM single gene mutations with high penetrance have been found. As adequate genetic counseling of these families requires identification of the genetic defect, the most prominent challenge is to identify these mutations. The traditional approach of serial sequencing of candidate genes is very costly and time-consuming, and therefore inefficient. Also here next-generation sequencing holds great promise. For many genetically heterogeneous diseases including non-syndromic CHM, diagnostic sequencing platforms consisting of a large series of candidate genes are constructed that can be sequenced on next-generation sequencers. These platforms allow the parallel sequencing of billions of nucleotides, so that many genes can be simultaneously sequenced in many samples at low cost. The first platforms for hypertrophic (HCM) and dilated (DCM) cardiomyopathy are already available and diagnostic platforms for CHM most likely will follow. It is anticipated that such technologies will facilitate the sequencing of entire genomes-exomes at relatively low cost [1]. There is little doubt that next-generation sequencing will be instrumental in the dissection of the genetics of non-syndromic CHM. However, as the recurrence risk of non-syndromic CHM is relatively low, only a small proportion of CHM might prove to have a true monogenetic origin being caused by a single mutation. It is likely that next generation sequencing will yield rare variants with unknown significance, often novel, missense mutations in many CHM patients. Even if the functional importance of (each of) these rare variants can be determined by functional studies, the difficulty will be to determine the combined penetrance of these variants, as many will have reduced penetrance. It has been hypothesized that non-syndromic CHM is most likely due to multifactorial inheritance involving a multitude of common variants that may be superposed on unfavorable environmental factors (Chapter 1). Nevertheless, until now little evidence for "multifactorial model" has been provided for human genetic disease, including CHM. Polymorphisms in genes encoding different enzymes MTHFR, MTHFD1, MTRR,

SCL19A1 and NNMT known to be implicated in the methylation cycle through the conversion of homocysteine into methionine by a 1-carbon (methyl) transfer, have a limited effect on the risk of CHM, and represent common variants with low penetrance. No Genome-Wide Association Studies (GWAS) for CHM have been reported, but not much is expected from such approach as GWAS for several common disorders have shown that "common variants" contribute little to its genetic basis [2]. Interestingly, somatic mutations not present in non-cardiac tissue have been found in affected cardiac tissue in a large fraction of CHM. The concept of somatic mutations leading to non-inherited genetic disease has been established in cancer by Knudson 40 years ago, but has not yet been convincingly proven for CHM as these studies originate from a single research group, and therefore await confirmation.

How can patients benefit from the progress of understanding the molecular and genetic mechanisms involved in cardiogenesis? Clinical geneticists counseling patients and families with CHM are confronted with 3 main questions: i) What is the genetic defect leading to this CHM, ii) What is the recurrence risk, and is prenatal diagnosis possible, and iii) Is there any (future) treatment for this genetic disease? The first 2 questions can be answered when the disease gene and disease-causing mutations are identified given the difficulties addressed above. Identification of the genetic defect may also pave the way towards therapeutic strategies interfering with the molecular pathways involved in specific CHM. This is illustrated by the clinical trials with drugs interfering with the TGFβ pathway in patients with Marfan syndrome and related disorders with aortic pathology [3]. Apart from the development of specific treatments for specific forms of CHM caused by specific genes, there might be broader therapeutic implications. The large network of transcription factors including GATA, TBX, FOG, HAND and NKX not only acts as a developmental regulator of cardiogenesis, but is also re-employed in the adult heart in response to acute injury, or longstanding ischemia. Here they are thought to mediate the re-expression of the "fetal program" of cardiac genes [4]. There is currently great interest in the therapeutic manipulation of these transcription factors in the adult heart to promote cardiac repair. Obviously, such strategies include drug-induced orientation of stem cells into specific cardiac cell types that can be used for cellular replacement in the damaged heart [5 6].

References

1. Eid J, Fehr A, Gray J, Luong K, Lyle J, Otto G, Peluso P, Rank D, Baybayan P, Bettman B, Bibillo A, Bjornson K, Chaudhuri B, Christians F, Cicero R, Clark S, Dalal R, Dewinter A, Dixon J, Foquet M, Gaertner A, Hardenbol P, Heiner C, Hester K, Holden D, Kearns G, Kong X, Kuse R, Lacroix Y, Lin S, Lundquist P, Ma C, Marks P, Maxham M, Murphy D, Park I, Pham T, Phillips M, Roy J, Sebra R, Shen G, Sorenson J, Tomaney A, Travers K, Trulson M, Vieceli J, Wegener J, Wu D, Yang A, Zaccarin D, Zhao P, Zhong F, Korlach J, Turner S. 2009. Real-time DNA sequencing from single polymerase molecules. Science 323:133-138.
2. Bodmer W, Bonilla C. 2008. Common and rare variants in multifactorial susceptibility to common diseases. Nat Genet 40:695-701.
3. Brooke BS, Habashi JP, Judge DP, Patel N, Loeys B, Dietz HC, 3rd. 2008. Angiotensin II blockade and aortic-root dilation in Marfan's syndrome. N Engl J Med 358:2787-2795.
4. Oka T, Xu J, Molkentin JD. 2007. Re-employment of developmental transcription factors in adult heart disease. Semin Cell Dev Biol 18:117-131.
5. Chien KR, Domian IJ, Parker KK. 2008. Cardiogenesis and the complex biology of regenerative cardiovascular medicine. Science 322:1494-1497.
6. Garry DJ, Olson EN. 2006. A common progenitor at the heart of development. Cell 127:1101-1104.

Summary

Samenvatting



Summary

Congenital heart malformations (CHMs) are among the most common congenital defects, occurring in 8 out of 1000 live births. In the past decade significant progress has been made in the identification of genes implicated in the signaling pathways involved in cardiovascular development. Human syndromes with CHM (syndromic CHM) have been instrumental in the discovery of these disease genes and developmental pathways. More recently, also a number of disease genes have been identified in families with non-syndromic CHM. Several of these disease genes have been discovered through positional genetics starting from multiplex families with CHM. In this thesis clinical and molecular studies of a broad spectrum of syndromic and non-syndromic forms of CHM are reported, including laterality defects (Chapter 2), left ventricular outflow tract obstruction (LVOTO) anomalies (Chapter 3), arterial malformations (Chapter 4), and CHM associated with cardiomyopathies (Chapter 5).

In **Chapter 1** the most important forms of syndromic CHM with the different cardiovascular signaling pathways are summarized. Also the etiological factors implicated in non-syndromic CHM, including environmental factors, disease genes with high-penetrance mutations, susceptibility genes with intermediate- or low-penetrance mutations, and somatic mutations are reviewed.

In **Chapter 2** clinical and genetic studies in patients with different forms of laterality defects are reported. Laterality defects refer to a group of disorders with embryonic disruption of normal left- right patterning. They can be subdivided into two groups: malformations caused by ciliary defects (including primary ciliary dyskinesia and hepatorenal fibrocystic syndromes), and malformations caused by defects in the nodal signaling pathway. Families with defects in both of these subgroups are reported in this thesis.
Two fetuses and one newborn with mild cerebral ventriculomegaly and a suspected and/or confirmed diagnosis of primary ciliary dyskinesia (PCD) are described. These cases show that fetal cerebral ventriculomegaly can be a prenatal sonographic marker of PCD, certainly in fetuses with laterality defects or a history of a sib with PCD.
Three families with acilia syndrome, which is an infrequent form of primary ciliary dyskinesia (PCD) characterized by total absence of cilia, are reported. No evidence could be found for the involvement of the *DNAI* or *DNAH5* genes that are commonly involved in PCD. Consequently, it is very likely that acilia syndrome forms a separate entity within the heterogeneous group of PCD.
A newborn with features of X-linked heterotaxy and VACTERL association is reported. In this patient we identified a 6-nucleotide insertion in the X-linked heterotaxy gene *ZIC3* that is predicted to expand the amino-terminal polyalanine repeat from ten to twelve polyalanines. It is likely that this novel and *de novo* polyalanine expansion in the *ZIC3* gene causes the VACTERL association in this patient. *ZIC3* is thereby the tenth gene implicated in polyalanine expansion diseases.

In **Chapter 3** various families with autosomal dominant inheritance of Left Ventricular Outflow Tract Obstruction (LVOTO) are reported. LVOTO in these families shows a wide clinical spectrum with some

family members presenting with severe anomalies such as hypoplastic left heart syndrome, and others with only minor anomalies such as mild aortic valve stenosis. This supports the notion that all anomalies of the LVOTO spectrum are developmentally related and can be caused by a single gene defect.
Two additional large pedigrees with autosomal dominant inheritance and incomplete penetrance of LVOTO in combination with heart valve anomalies are reported. These families provide evidence that left-sided obstructive defects and thoracic aortic aneurysm may be accompanied by right-sided heart defects and septal defects. The disease genes in these families remain unknown: *NOTCH1* mutations were excluded, and genome-wide linkage analysis is currently being performed.

In **Chapter 4** clinical and molecular studies of arterial tortuosity syndrome (ATS) are reported. ATS is a rare autosomal recessive condition characterized by cardiovascular anomalies including tortuosity, aneurysm and stenosis of major arteries. Nine new ATS patients from three consanguineous Moroccan families are described, and a clinical review of a total of 35 patients with this infrequent disease is presented. In collaboration with the University of Ghent, Belgium, a genome-wide screen by homozygosity mapping of these three consanguineous multiplex families was performed, which resulted in the mapping of the ATS gene to chromosome 20q13 in a candidate region of 1.2 Mb region containing 7 genes. Mutations in one of these genes *SLC2A10,* which encodes the facilitative glucose transporter GLUT10, were identified in 6 ATS families. GLUT10 deficiency is associated with upregulation of TGFß signaling in the arterial wall, a finding also observed in Loeys-Dietz syndrome, which is a similar syndrome with aortic aneurysms and tortuosity. Therapeutic compounds intervening with TGFß signaling might represent a new, attractive treatment strategy for such disorders.

In **Chapter 5** the association of cardiomyopathies with congenital heart malformations, including heterotaxy, septal defects and Ebstein anomaly, is described.
A three-generation family with nine patients affected by CHM and left isomerism is reported. The cardiac anomalies include noncompaction of the ventricular myocardium, bradycardia, pulmonary valve stenosis, and secundum atrial septal defect. The laterality sequence anomalies include left bronchial isomerism, azygous continuation of the inferior vena cava, polysplenia and intestinal malrotation, all compatible with left isomerism. This new syndrome has an autosomal dominant pattern of inheritance. A genome-wide linkage analysis suggested linkage to chromosome 6p.
Two unrelated neonates with septal defects and a lethal cardiomyopathy were shown to be compound heterozygous for two common loss-of-function mutations in the sarcomeric *MYBPC3* gene. Whereas heterozygous mutations in sarcomeric protein genes usually lead to hypertrophic cardiomyopathy with clinical symptoms starting in adulthood, homozygosity or compound heterozygosity for 2 truncating mutations in the *MYBPC3* gene can lead to severe hypertrophic cardiomyopathy with ventricular noncompaction and septal defects.
A large family with autosomal dominant inheritance of Ebstein anomaly in association with ventricular septal defects and noncompaction cardiomyopathy is reported to have a mutation in the *MYH7* gene. This further indicates that sarcomeric proteins, which are implicated in familial cardiomyopathies, also play a role in CHM.

In **Chapter 6** the results of this thesis are discussed and put in perspective. As adequate genetic counseling of families with CHM requires identification of the genetic defect, the most prominent challenge is to identify these mutations. However, only in a minority of families a disease-causing mutation can currently be identified. New technologies of high-throughput parallel sequencing on "next-generation sequencers" hold great promise for the identification of disease genes and mutations: these new technologies offer cost-effective sequencing of large linkage intervals in families such as presented in this thesis in order to identify the disease gene, or panels with large series of candidate genes in order to identify the disease-causing mutation. Eventually, next-generation sequencing of whole genomes or exomes will identify all variants contributing to non-syndromic CHM.

Samenvatting

Congenitale hartafwijkingen zijn de frequentste aangeboren aandoeningen met een prevalentie van 8 op de 1000 levendgeboren kinderen. De laatste jaren is er grote vooruitgang geboekt in de identificatie van de genen die een rol spelen in de verschillende signaaltransductie netwerken die betrokken zijn bij de hartontwikkeling. Humane syndromen met hartafwijkingen (syndromale hartafwijkingen) hebben een belangrijke rol gespeeld bij de opheldering van deze genen en signaaltransductie netwerken. Recent heeft ook onderzoek in families met niet-syndromale hartafwijkingen tot de identificatie van ziektegenen geleid. Meerdere van deze genen werden ontdekt door positionele klonering in families met vele personen met een aangeboren hartafwijking.
In dit proefschrift worden klinische en moleculaire studies beschreven in families met uiteenlopende vormen van syndromale en niet-syndromale hartafwijkingen. Samengevat betreft het onderzoek in families met lateralisatieafwijkingen (Hoofdstuk 2), hartafwijkingen van de linker hart structuren (LVOTO) (Hoofdstuk 3), arteriële afwijkingen (Hoofdstuk 4), en aangeboren hartafwijkingen in combinatie met cardiomyopathieen (Hoofdstuk 5).

In **Hoofdstuk 1** worden de meest belangrijke vormen van syndromale hartafwijkingen en de bijbehorende signaaltransductie netwerken samengevat. De verschillende etiologische factoren betrokken bij niet-syndromale aangeboren hartafwijkingen, waaronder omgevings-factoren, ziektegenen met hoog penetrante mutaties, ziektegenen met verminderd of laag penetrante mutaties en somatische mutaties, worden besproken.

In **Hoofdstuk 2** worden verschillende klinische en moleculaire studies in patiënten met lateralisatieafwijkingen beschreven. Lateralisatieafwijkingen zijn een groep van aandoeningen waarbij er een verstoring is van de normale links-rechts asymmetrie van de organen en vaatstructuren in het lichaam. Er zijn twee subgroepen lateralisatieafwijkingen: aandoeningen die veroorzaakt worden door een verstoorde opbouw en/of functie van de trilharen of cilia (waaronder primaire ciliaire dyskinesie en hepatorenale fibrocysteuze syndromen), en aandoeningen die veroorzaakt worden door verstoring van de werking van het zogenaamde NODAL signaaltransductie netwerk. In deze thesis worden families beschreven met lateralisatieafwijkingen die behoren tot beide groepen.
Twee foetussen en een pasgeborene met milde verwijding van de achterhoornen van de zijventrikels van de hersenen en een bevestigde en/of vermoedde diagnose van primaire ciliaire dyskinesie (PCD) worden beschreven. Deze casussen illustreren dat een milde cerebrale ventriculomegalie een prenatale marker kan zijn voor PCD, in het bijzonder als er ook een lateralisatieafwijking aanwezig is of een voorgaand kind met PCD.
Drie families met het acilia syndroom, een zeldzame vorm van PCD waarbij er afwezigheid is van de trilharen, worden gerapporteerd. Moleculaire studies toonden geen aanwijzingen voor mutaties in *DNAI1* en *DNAH5*, de 2 genen die het vaakst betrokken zijn bij PCD. Het is daarom zeer waarschijnlijk dat acilia syndroom een aparte entiteit is binnen de heterogene groep van PCD. Omdat mutaties in het Foxj1 gen in de muis acilia syndroom veroorzaken, werd dit gen in onze families onderzocht, maar mutaties werden niet gevonden.

Een pasgeborene met kenmerken van de X-gebonden vorm van heterotaxie en VACTERL associatie (anus atresie, larynx- en oesophagus atresie met tracheo- oesophageale fistel, dextropositie van het hart, persisterende vena cava superior links en een unilaterale multicysteuze nier) wordt beschreven. In deze patiënt werd een insertie van 6 nucleotiden in het *ZIC3* gen geïdentificeerd, welke leidt tot een polyalanine expansie van 10 naar 12 alanines. Deze nooit eerder beschreven en de novo mutatie is zeer waarschijnlijk de oorzaak van de VACTERL associatie in deze patiënt. *ZIC3* is daarmee het 10de gen in de groep van polyalanine aandoeningen.

In **Hoofdstuk 3** worden verschillende families met autosomaal dominant overervende linkszijdige obstructieve aangeboren hartafwijkingen (LVOTO) gepresenteerd. LVOTO in deze families bestaat uit een breed spectrum van aangeboren hartafwijkingen, waaronder ernstige aanlegafwijkingen zoals onderontwikkeling van de linker hartkamer (hypoplastisch linker hart) maar ook milde afwijkingen, zoals een bicuspide aortaklep. De observatie dat dit brede spectrum van hartafwijkingen kan worden veroorzaakt door één enkele mutatie ondersteunt de hypothese deze afwijkingen gerelateerd zijn in de embryonale hartontwikkeling.
Twee families met autosomaal dominant overervende LVOTO met wisselende expressie en penetrantie worden beschreven. Hoewel er bij de meeste aangedane familieleden LVOTO bestond, werden ook andere aangeboren hartafwijkingen geobserveerd, zoals septale defecten en afwijkingen van de rechtszijdige hartstructuren zoals pulmonaalstenose. Dit wijst erop dat LVOTO ook met rechtzijdige hartafwijkingen geassocieerd kan zijn.

In **Hoofdstuk 4** worden klinische en moleculaire studies in families met arterial tortuosity syndroom (ATS) gerapporteerd. ATS is een autosomaal recessief overervende aandoening gekenmerkt door aangeboren afwijkingen van de grote en middelgrote slagaders, zoals kronkeling (tortuosity), verwijding (aneurysma) en vernauwing (stenosis) van de aorta en andere arteriën. Negen patiënten met ATS afkomstig uit 3 families worden beschreven, en de tot 2004 gepubliceerde patiënten met ATS worden besproken. In samenwerking met het Universitair Ziekenhuis Gent, België, werd middels een genoom scan homozygositeits mapping verricht in 3 consanguine Marokkaanse families, vermoedelijk afkomstig uit dezelfde regio in Marokko. Dit resulteerde in de lokalisatie van het ATS gen in een kandidaat regio van 1.2 Mb regio op chromosoom 20q13.1 waarin 7 genen waren gelegen. Tenslotte werden in 6 ATS families mutaties geïdentificeerd in het *SLC2A10* gen, dat codeert voor een glucose transport eiwit GLUT10. GLUT10 deficiëntie is geassocieerd met upregulatie van het TGFβ netwerk in de arterie wand, een bevinding die ook wordt geobserveerd in het Loeys-Dietz syndroom, een vergelijkbaar syndroom met aorta aneurysma en kronkeling. Deze observatie biedt mogelijk een aanknopingspunt voor medicamenteuze therapie met TGFβ antagonisten zoals Losartan.

In **Hoofdstuk 5** wordt gerapporteerd over de associatie van cardiomyopathieen met aangeboren hartafwijkingen waaronder lateralisatieafwijkingen, septale defecten en Ebstein anomalie.
Een drie-generatie familie met 9 patiënten met aangeboren hartafwijkingen en links isomerisme wordt beschreven. De cardiale afwijkingen betreffen noncompaction cardiomyopathie, bradycardie, pulmo-

naalklep stenose en atrium septum defect. De lateralisatieafwijkingen betreffen bronchiaal links isomerisme, azygos continuatie van de vena cava inferior, polysplenie en malrotatie van de darmen, allen passend binnen het spectrum van links isomerisme. Met een genoom wijde scan werd in deze familie vermoedelijke koppeling gevonden met de chromosoom 6p21 regio.
Bij twee pasgeborenen met septale defecten en lethale cardiomyopathie wordt heterozygotie voor twee vaak voorkomende truncerende mutaties in het *MYBPC3* gen vastgesteld. Heterozygote mutaties in genen die coderen voor sarcomeer eiwitten leiden meestal tot klinische symptomen op volwassen leeftijd, terwijl homozygote mutaties of heterozygotie voor twee truncerende mutaties in het *MYBPC3* gen leiden tot een ernstige cardiomyopathie met kenmerken van noncompaction en met septale defecten.
In een grote familie met autosomaal dominant overervende Ebstein anomalie in associatie met noncompaction cardiomyopathie en septale defecten wordt een mutatie in het *MYH7* gen beschreven. Dit ondersteunt eerdere observaties dat defecten in sarcomeer eiwitten een rol spelen bij het ontstaan van aangeboren hartafwijkingen.

In **Hoofdstuk 6** worden de resultaten van de studies van deze thesis besproken. Aangezien voor een adequaat genetisch advies aan patiënten en/of families met aangeboren hartafwijkingen identificatie van de ziekteveroorzakende mutatie(s) van groot belang is, zijn technieken voor kost-effectieve detectie van deze genmutaties essentieel. Nieuwe technieken zoals next-generation sequencing bieden grote mogelijkheden om deze mutaties op te sporen. Sequencing van grote linkage intervals in families zoals gepresenteerd worden in dit proefschrift wordt mogelijk zodat nieuwe ziekte genen geïdentificeerd kunnen worden. Grote panels van kandidaat genen voor aangeboren hartafwijkingen kunnen in individuele patiënten worden geanalyseerd. Uiteindelijk zal deze next-generation sequencing ook toelaten om complete genomen of exomen van patiënten te sequencen om zo de ziekteveroorzakende mutatie(s) te identificeren.

Curriculum Vitae

PhD Portfolio Summary

Publications

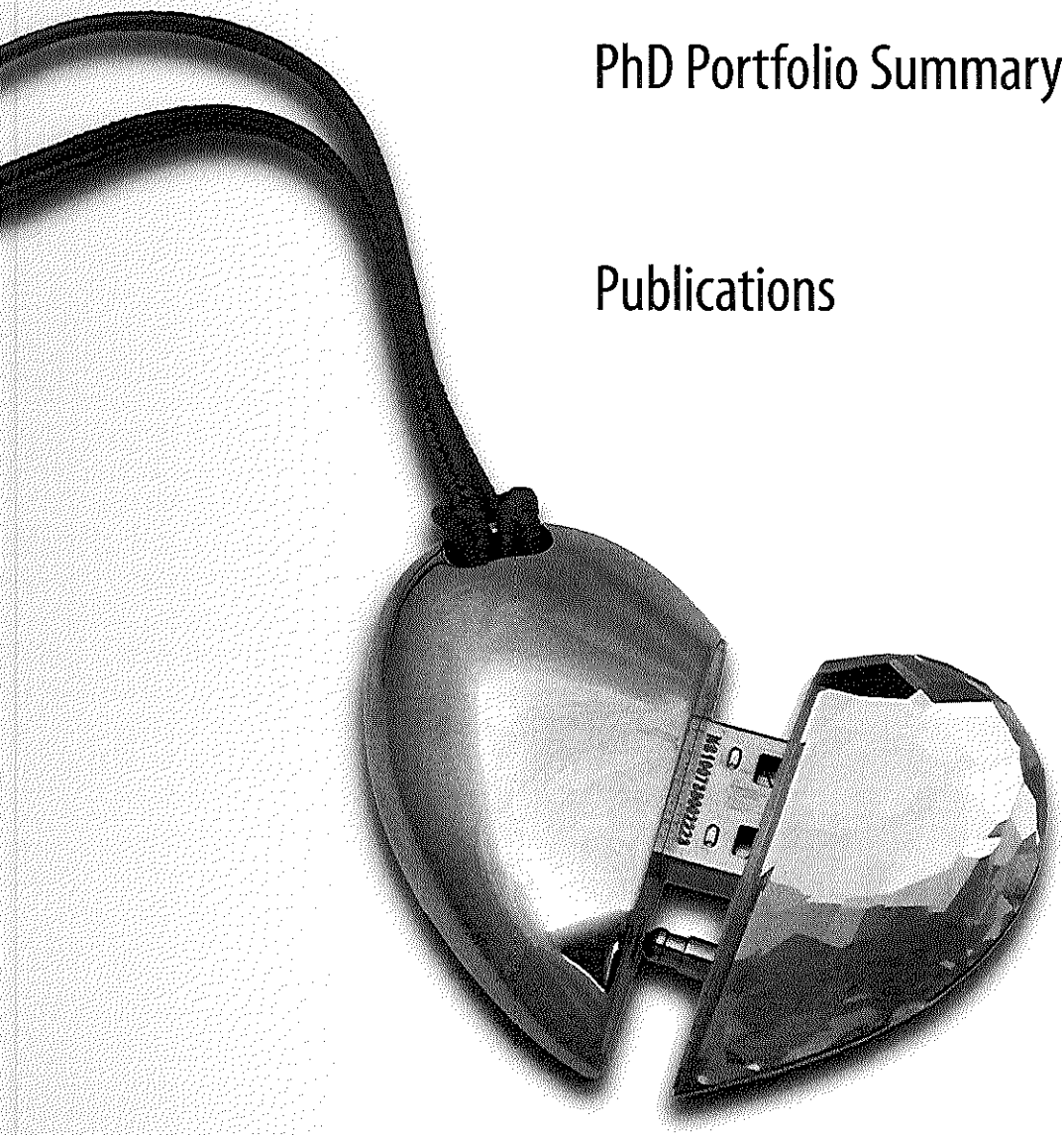

Curriculum Vitae



The author of this thesis was born on April 17th, 1964, in Leiden, The Netherlands. She graduated in 1982 at the 'St Maartenscollege' in Haren (Groningen), and began her medical studies at Leiden University in 1982. As a medical student she participated in clinical research in the Dutch Asthma Centre, Davos, Switzerland. She obtained her Medical Degree (cum laude) in 1990.

From 1990 until 1993 she worked as a resident in the Department of Obstetrics and Gynecology of the 'Groene Hart' Hospital (former 'Blueland' Hospital) in Gouda.

She was trained in fetal echo(cardio)graphy in the Division of Obstetrics and Prenatal Medicine, (Department of Obstetrics and Gynecology) of the Erasmus University Rotterdam (Prof.dr. J. Wladimiroff) from 1993 until 1995. During this period she followed a clinical course in Perinatal Cardiology at the Department of Perinatal Cardiology at Pennsylvania Hospital, Philadelphia, USA. She started her residency in Clinical Genetics at the Department of Clinical Genetics at the ErasmusMC (Prof.dr. H. Galjaard and Prof.dr M.F. Niermeijer) in 1995. She also continued working at the Department of Obstetrics and Gynecology, Division of Obstetrics and Prenatal Medicine one day per week, performing ultrasounds in pregnant women with an increased risk of a child with a congenital heart malformation.

She became registered as a clinical geneticist in 2000, and was appointed staff member of the Clinical Genetics section of the Department of Clinical Genetics at the ErasmusMC Rotterdam (Prof.dr. F. Grosveld), where she is currently working.

From 2005 she also became staff member in the Amphia Hospital in Breda, participating one day per week in the outclinic of Gynecology and Obstetrics and the outclinic of Pediatrics (Moeder en kind centrum).

The studies in this thesis were conducted during 2002 and 2008 in the Department of Clinical Genetics at the ErasmusMC Rotterdam (Promotor Prof.dr. F. Grosveld).

Her main professional interests are prenatal diagnosis, dysmorphology and cardiogenetics.

PHD Portfolio Summary

Name PhD student:	Marja W. Wessels
Erasmus MC Department:	Clinical Genetics
Research School:	Medisch Genetisch Centrum Zuid-West Nederland - MGC
PhD period:	2002-2008
Promotor(s):	Prof.dr. F. Grosveld
Date of public defence thesis:	May 6th, 2009
Thesis title:	Genetics of Congenital Heart Malformations

Professional academic skills

Residency and intern training prenatal echo(cardio)graphy, Division of Obstetrics and Prenatal Medicine, Department of Obstetrics and Gynaecology, Erasmus MC Rotterdam, **1993-1995**
Clinical course in Perinatal Cardiology, Department of Perinatal Cardiology, Pennsylvania Hospital, Philadelphia, USA, **1995**
Residency Clinical Genetics Erasmus MC Rotterdam, **1995-2000**
Board certified registration as Clinical Geneticist, **2000**

In-depth courses

Course Fetal Echocardiography, Thomas Jefferson University Hospital, Philadelphia, USA, **1995**
European School of Medical Genetics – 9th course, Sestri Levante, Genoa, Italy, **1996**
PAOG cursus presymptomatische DNA diagnostiek, Erasmus MC, Rotterdam, **1996**
6th International Workshop on fetal Genetic Pathology, Dead Sea, Israel, **1999**
Cursus Rekenen aan Genen, Afdeling Klinische Genetica, Academisch Ziekenhuis VU, Amsterdam, **1999**
Second European course in clinical dysmorphology "what I know best" Rome, Italy, **2008**

International conferences with presentations

American Society of Human Genetics, 51th Annual Meeting, San Diego, USA, ***2001***
Poster presentation 1: A new autosomal dominant syndrome with hypertrophic cardiomyopathy, heterotaxy, conduction abnormalities, atrial septal defect and pulmonary stenosis. M. Wessels, S. Spitaels, R. De Krijger, T. Cohen-Overbeek, M. Niermeijer, P. Heutink, P. Willems.
Poster presentation 2: Poor outcome in Down syndrome fetuses with cardiac anomalies or growth retardation. I.M.E. Frohn-Mulder, M. Wessels, F. Los, P. Willems, M. Niermeijer, J. Wladimiroff.

European Society of Human Genetics Conference, Prague, Czech Republic, ***2005***
Poster presentation: Autosomal dominant inheritance of cardiac valve anomalies. Marja W. Wessels, Danielle Majoor-Krakauer, Bert A. de Vries and Patrick J. Willems.

American Society of Human Genetics, 57th Annual Meeting, San Diego, USA, ***2007***
Poster presentation: *SOX9* micro- and macrodeletions are not uncommon in campomelic dysplasia. G. Scherer, W. Jin, M. Wessels, R. Hordijk, C. van Ravenswaaij, E. Obersztyn, E. Blair, E. McPherson, D. Sillence.

19th European meeting on dysmorphology, Strasbourg, France, ***2008***
Oral presentation: X-linked heterotaxy with VACTERL a new polyalanine disorder ? Marja W. Wessels, Brian Kuchinka, Rogier Heydanus, Bert J. Smit, Dennis Dooijes ,Ronald R. de Krijger, Maarten H. Lequin, Elisabeth M. de Jong, Margreet Husen, Patrick J. Willems, Brett Casey.

American Society of Human Genetics, 58th Annual Meeting, Philadelphia, USA, ***2008***
Poster presentation: The integration of transcriptional profiling and functional genetics reveals RBM24 to be a novel candidate for cardiac defects. R. Miller, A. Bertoli-Avella, B. de Graaf, M. Wessels, J. Gearhart, D. McGaughey, A. McCallion.

European Society of Human Genetics Conference, Barcelona, Spain, ***2008***
Poster presentation: First locus for primary pulmonary vein stenosis maps to chromosome 2q. Ingrid van de Laar, Marja Wessels, Ingrid Frohn-Mulder, Michiel Dalinghaus, Bianca de Graaf, Marianne van Tienhoven, Paul van der Moer, Margreet Husen-Ebbinge, Maarten Lequin, Dennis Dooijes, Ronald de Krijger, Ben A. Oostra, Aida M. Bertoli-Avella.

Teaching courses

Cardiovascular Research School Erasmus MC Rotterdam (CEOUR): PhD Course Congenital heart disease, ***2004***
Talk: "Genetics of human congenital heart disease"

1e PAOK Sectie Erfelijke en Aangeboren Aandoeningen: Genetische diagnostiek: conventionele en nieuwe technieken, ***2007***
Talk: "Aangeboren afwijkingen: verschillende indelingen" en "Basis-diagnostiek van aangeboren afwijkingen"

Cardiovascular Research School ErasmusMC Rotterdam (CEOUR) Research Seminar Tetralogy of Fallot, ***2008***
Talk: "Genetics of Tetralogy of Fallot"

3e PAOK Sectie Erfelijke en Aangeboren Aandoeningen: Een levenlang leven met het Turner syndroom en Noonan syndroom, ***2008***
Talk: "Turner syndroom: genetica en cardiologische afwijkingen"

List of publications

Wessels MW, Kuchinka B, Heydanus R, Smit BJ, Dooijes D, de Krijger RR, Lequin MH, de Jong EM, Husen M, Willems PJ, Casey B. Polyalanine expansion in the *ZIC3* gene leading to X-linked heterotaxy with VACTERL association, a new polyalanine disorder? J Med Genet 2009; in press.

Wilmink FA, Grijsseels E, Papatsonis DNM, **Wessels MW**. Cornelia de Lange syndrome: a recognisable fetal phenotype. Fetal Diagn Ther 2009; in press.

Wessels MW, van de Laar IM, Roos-Hesselink, J Strikwerda S, Majoor-Krakauer DF, de Vries BB, Kerstjens-Frederikse WS, Vos YJ, de Graaf BM, Bertoli-Avella AM, Willems PJ. Autosomal dominant inheritance of cardiac valves anomalies in two families: Extended spectrum of left-ventricular outflow tract obstruction. Am J Med Genet A 2009; 149A: 216-225.

Wessels MW, Willems PJ. Genetic and environmental factors in non-syndromic congenital heart malformations. Submitted.

Wessels MW, Hoedemaekers YM, Frohn-Mulder IM, Dalinghaus M, van den Wijngaard A, de Krijger RR, Michels M, Willems PJ, de Coo IMF, Dooijes D. Compound heterozygosity for truncating mutations in the *MYBPC3* gene causes severe cardiomyopathy with left ventricular noncompaction and septal defects resulting in neonatal death. Submitted.

Wessels MW, Höhne W, Cooley DA, Schoonderwaldt EM, Vliegen HW, Michels M, Frohn-Mulder IM, Hoedemaekers YM, Helbing WA, Willems PJ, Dooijes D. Ebstein anomaly can be caused by mutations in the *MYH7* gene encoding the cardiac beta myosin heavy chain. Submitted.

van de Laar I, **Wessels MW**, Frohn-Mulder IM, Dalinghaus M, de Graaf B, van Tienhoven M, van der Moer P, Husen-Ebbinge M, Lequin M, Dooijes D, de Krijger R, Oostra BA, Bertoli-Avella AM. First locus for Primary Pulmonary Vein Stenosis maps to chromosome 2q. Eur Heart J 2009; in press.

Valstar MJ, Bertoli-Avella AM, **Wessels MW**, Ruijter GJG, de Graaf B, Olmer R, Karimi Nejad MH, Ezgü FS, Tokatli A, Czartoryska B, Bosschaart AN, van den Bos-Terpstra F, Puissant F, Bürger F, Omran H, Eckert D, Filocamo R, Simeonov E, Willems PJ, Wevers RA, Halley DJJ, Poorthuis BJHM, van Diggelen OP. Mucopolysaccharidosis type IIID: Clinical description of 11 new patients and identification of 16 novel mutations. Submitted.

Verkerk AJMH, Schot R, Ekel B, Schellekens K, Swagemakers S, Bertoli-Avella AM, Lequin MH, Dudink J, Govaert P, van Zwol AL, Hirst J, **Wessels MW**, Catsman-Berrevoets C, Verheijen FW, de Graaff E, de Coo IFM, Kros JM, Willemsen R, Willems PJ, van der Spek PJ, Mancini GMS. Mutations in the human *AP4M1* gene encoding the μ-subunit of the adaptor-related protein complex-4 result

in aberrant glutamate receptor cycling in the brain and provide a genetic model for white matter injury in cerebral palsy. Submitted.

Wessels MW, Avital A, Failly M, Munoz A, Omran H, Blouin JL, Willems PJ. Candidate gene analysis in three families with acilia syndrome. Am J Med Genet A 2008; 146A: 1765-1767.

Zweier C, Sticht H, Bijlsma E, Clayton-Smith J, Boonen SE, Fryer A, Greally MT, Hoffmann L, den Hollander NS, Jongmans M, Kant SG, King MD, Lynch SA, McKee S, Midro AT, Park SM, Ricotti V, Tarantino E, **Wessels M**, Peippo M, Rauch A. Further delineation of Pitt-Hopkins syndrome: phenotypic and genotypic description of sixteen novel patients. J Med Genet 2008; 45: 738-744.

Wessels MW, Willems PJ. Mutations in sarcomeric protein genes not only lead to cardiomyopathy but also to congenital cardiovascular malformations. Clin Genet 2008; 74:16-19.

Wessels MW, De Graaf BM, Cohen-Overbeek TE, Spitaels SE, de Groot-de Laat LE, Ten Cate FJ, Frohn-Mulder IF, de Krijger R, Bartelings MM, Essed N, Wladimiroff JW, Niermeijer MF, Heutink P, Oostra BA, Dooijes D, Bertoli-Avella AM, Willems PJ. A new syndrome with noncompaction cardiomyopathy, bradycardia, pulmonary stenosis, atrial septal defect and heterotaxy with suggestive linkage to chromosome 6p. Hum Genet 2008; 122: 595-603.

Nellist M, Sancak O, Goedbloed M, Goedbloed M, Adriaans A, **Wessels M**, Maat-Kievit A, Baars M, Dommering C, van den Ouweland A, Halley D. Functional characterisation of the TSC1-TSC2 complex to assess multiple TSC2 variants identified in single families affected by tuberous sclerosis complex. BMC Med Genet 2008; 9: 10.

Coucke PJ, Willaert A, **Wessels MW**, Callewaert B, Zoppi N, De Backer J, Fox JE, Mancini GM, Kambouris M, Gardella R, Facchetti F, Willems PJ, Forsyth R, Dietz HC, Barlati S, Colombi M, Loeys B, De Paepe A. Mutations in the facilitative glucose transporter GLUT10 alter angiogenesis and cause arterial tortuosity syndrome. Nat Genet 2006; 38: 452-457.

Wessels MW, Berger RM, Frohn-Mulder IM, Roos-Hesselink JW, Hoogeboom JJ, Mancini GM, Bartelings MM, de Krijger R, Wladimiroff JW, Niermeijer MF, Grossfeld P, Willems PJ. Autosomal dominant inheritance of left ventricular outflow tract obstruction. Am J Med Genet A 2005; 134: 171-179.

Bicknell LS, Morgan T, Bonafe L, **Wessels MW**, Bialer MG, Willems PJ, Cohn DH, Krakow D, Robertson SP. Mutations in FLNB cause boomerang dysplasia. J Med Genet 2005; 42: e43.

Wessels MW, Catsman-Berrevoets CE, Mancini GM, Breuning MH, Hoogeboom JJ, Stroink H, Frohn-Mulder I, Coucke PJ, Paepe AD, Niermeijer MF, Willems PJ. Three new families with arterial tortuosity syndrome. Am J Med Genet A 2004; 131: 134-143.

Wessels MW, Los FJ, Frohn-Mulder IM, Niermeijer MF, Willems PJ, Wladimiroff JW. Poor outcome in Down syndrome fetuses with cardiac anomalies or growth retardation. Am J Med Genet A 2003; 116: 147-151.

Wessels MW, den Hollander NS, Willems PJ. Mild fetal cerebral ventriculomegaly as a prenatal sonographic marker for Kartagener syndrome. Prenat Diagn 2003; 23: 239-242.

Wessels MW, Den Hollander NS, De Krijger RR, Bonifé L, Superti-Furga A, Nikkels PG, Willems PJ. Prenatal diagnosis of boomerang dysplasia. Am J Med Genet A 2003; 122: 148-154.

Wessels MW, Den Hollander NJ, De Krijger RR, Nikkels PG, Brandenburg H, Hennekam R, Willems PJ. Fetus with an unusual form of nonrhizomelic chondrodysplasia punctata: case report and review. Am J Med Genet A 2003; 120: 97-104.

Coucke PJ, **Wessels MW**, Van Acker P, Gardella R, Barlati S, Willems PJ, Colombi M, De Paepe A. Homozygosity mapping of a gene for arterial tortuosity syndrome to chromosome 20q13. J Med Genet 2003; 40: 747-751.

Wessels MW, Willems PJ. Images in clinical medicine. Chondrodysplasia punctata. N Engl J Med 2002; 347: 110.

Wessels MW, Den Hollander NS, Cohen-Overbeek TE, Lesnik Oberstein MS, Nash RM, Wladimiroff JW, Niermeijer MF, Willems PJ. Prenatal diagnosis and confirmation of the acrofacial dysostosis syndrome type Rodriguez. Am J Med Genet 2002; 113: 97-100.

Wessels MW, Brooks AS, Hoogeboom J, Niermeijer MF, Willems PJ. Kabuki syndrome: a review study of three hundred patients. Clin Dysmorphol 2002; 11: 95-102.

den Hollander NS, **Wessels MW**, Niermeijer MF, Los FJ, Wladimiroff JW. Early fetal anomaly scanning in a population at increased risk of abnormalities. Ultrasound Obstet Gynecol 2002; 19: 570-574.

Brandenburg H, de Krijger RR, Visser W, **Wessels MW**, Steegers EA. [Maternal complications of fetal hydrops]. Ned Tijdschr Geneeskd 2002; 146: 2367-2370.

Zollinger PE, **Wessels MW**, Wladimiroff JW, Diepstraten AF. Prenatal ultrasonographic diagnosis of posteromedial bowing of the leg: two case reports. Ultrasound Obstet Gynecol 2000; 15: 150-153.

van Haelst MM, Brooks AS, Hoogeboom J, **Wessels MW**, Tibboel D, de Jongste JC, den Hollander JC, Bongers-Schokking JJ, Niermeijer MF, Willems PJ. Unexpected life-threatening complications in Kabuki syndrome. Am J Med Genet 2000; 94: 170-173.

den Hollander NS, **Wessels MW**, Los FJ, Ursem NT, Niermeijer MF, Wladimiroff JW. Congenital microcephaly detected by prenatal ultrasound: genetic aspects and clinical significance. Ultrasound Obstet Gynecol 2000; 15: 282-287.

van Slegtenhorst M, Verhoef S, Tempelaars A, Bakker L, Wang Q, **Wessels M**, Bakker R, Nellist M, Lindhout D, Halley D, van den Ouweland A. Mutational spectrum of the *TSC1* gene in a cohort of 225 tuberous sclerosis complex patients: no evidence for genotype-phenotype correlation. J Med Genet 1999; 36: 285-289.

Wessels MW, Frohn-Mulder IM, Cromme-Dijkhuis AH, Wladimiroff JW. In utero diagnosis of infra-diaphragmatic total anomalous pulmonary venous return. Ultrasound Obstet Gynecol 1996; 8: 206-209.

Wessels MW, Doekes G, Van Ieperen-Van Kijk AG, Koers WJ, Young E. IgE antibodies to Pityrosporum ovale in atopic dermatitis. Br J Dermatol 1991; 125: 227-232.

Hypertrabeculated heart musculature of the salamandra.

From: On the heart and arterial arches of salamandra maculosa laur. and
ambystoma mexicanum shaw during metamorphosis. H.J.J.Terhal (my grandfather), thesis,
The Government University, Leyden, 1941

the young specimens consists in a homogeneous connective tissue, becomes fibrous in the older animals. We cannot discover any muscular elements in this structure. The dorsal and ventral valves are in a few larvae connected by a small endocard ridge at the left lateral ostium edge. In the adult animals this ridge is more strongly developed and can, by [illegible] small hollowness

Dankwoord

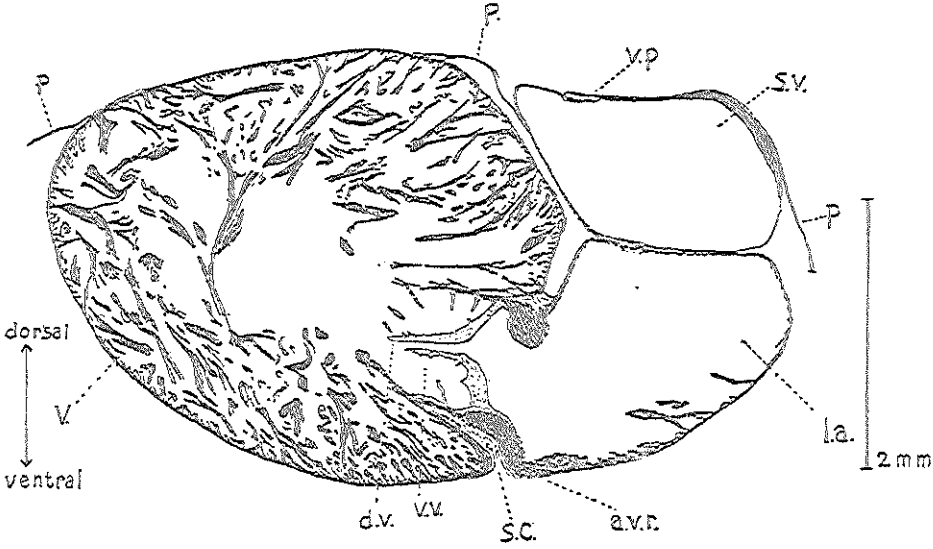

Fig. 13. Transverse section through the heart of adult *Salamandra maculosa* Laur.

v., ventricle; s.c., sulcus coronarius; a.v.r., auriculo-ventricular ring; d.v., dorsal valve; v.v., ventral valve; l.a., left atrium; s.v., sinus venosus; v.p., pulmonary vein; p., pericardium.

even take the structure of a left lateral valve. The cavity of the ventricle is, from the ostium atrio-ventriculare to the entrance of the bulbus cordis, more or less L-shaped. This space is surrounded by a spongy musculature, consisting of septa arranged chaotically and enclosing larger or smaller chambers (fig. 13). This spongy structure is developed most strongly in the apex of the ventricle and in the cranial part of the ventricle especially most strongly on the ventral and ventrally right ventricle wall. This latter spongy structure, in the cranial part of the ventricle only, is in specimen no 1 only very feebly developed (fig. 12). In that specimen the musculature is not yet cross-striped (fig. 14, A). The septa change gradually into the ventricle wall (corticalis).

This ventricle wall consists in younger animals of a very thin epicardial layer, connected with the myocardium, into which the

Dankwoord

Allereerst dank ik de vele patiënten en familieleden, die de basis vormen van dit proefschrift, voor hun openhartigheid, medewerking, en het vertouwen dat zij in mij hebben getoond.

Lieve Patrick, dankzij jouw steun, toewijding, suggesties, discussies, vele correcties en liefde is dit proefschrift ontstaan en afgerond. Ik kon je vaak niet bijbenen, maar gelukkig liet je me toch mijn eigen pas lopen. Mijn dank aan jou is verweven met al dat andere wat je voor mij betekent.



Prof.dr. Frank Grosveld dank ik voor de vrijheid en hulp die hij mij gaf om dit proefschrift af te ronden.

Prof.dr. Ben Oostra, Prof.dr. Wim Helbing en Prof.dr.Ing. Paul Coucke wil ik hartelijk bedanken voor hun bereidheid zitting te nemen in de promotiecommissie en voor de vlotte beoordeling van het manuscript.

Prof.dr. Martinus Niermeijer, U wil ik bedanken voor uw steun en aanmoedigingen gedurende mijn werkzaamheden als arts-echoscopist, mijn opleiding tot klinisch geneticus, mijn werk als staflid, en de tot standkoming van dit proefschrift. Het was een voorrecht door u te worden opgeleid.

Ik dank Prof.dr H. Galjaard voor zijn vertrouwen om mij eerst aan te stellen als arts-echoscopist op de afdeling Prenatale Diagnostiek, en later de opleiding tot klinisch geneticus te laten volgen.

Prof.dr Juri Wladimiroff dank ik voor het vertrouwen dat hij mij gaf tijdens mijn werkzaamheden als arts-echoscopist op de afdeling Prenatale Diagnostiek, en de mogelijkheden die ik kreeg om mij verder te verdiepen in foetale hartafwijkingen en de overstap te maken naar de klinische genetica.

De meeste families, die de basis vormen van dit proefschrift, kwamen onder mijn aandacht vanwege een aangedane zwangerschap. Dit was deels in de tijd dat ik zelf op de afdeling Prenatale Diagnostiek werkte, maar later ook na verwijzing door de echo-artsen/gynaecologen. Aan de jaren op de afdeling Prenatale Diagnostiek heb ik heel goede herinneringen dankzij mijn collega's destijds: Dr Jahoda, Helen Brandenburg, Hajo Wildschut, Marjolein Wijman, Patricia Stewart, Jacqueline Laudy, Nicolette den Hollander, Titia Cohen-Overbeek, Ernst Schoonderwaldt, Irene Groenenberg, Margreet Husen, Anne-Marie Westerveld, en 'de meiden' van het secretariaat. Veel dank aan diegenen die families verwezen voor verder onderzoek. Veel heb ik in die jaren ook geleerd van Dr. Frans Los. Beste Frans, vaak heb ik je moeilijke situaties in alle rust zien oplossen, met grote deskundigheid. Ik kon altijd om je hulp vragen, waarvoor dank.

Het uitwerken van deze thesis kwam tot stand tijdens mijn werkzaamheden op de afdeling Klinische Genetica. Jeannette Hoogeboom, een van mijn 'opleiders': Lieve Jeannette, naar je pluis niet-pluis gevoel heb ik altijd geluisterd (nog steeds). Ik ben je ook dankbaar voor wat je hebt neergezet in het Amphia Ziekenhuis, jouw enthousiasme voor het vak is daar zeker overgenomen ! Dank ook voor je extra supervisie op maandag. Marleen Simon, mijn kamer-maatje. Lieve Marleen, je hebt langer dan verwacht een deel van de genetische zorg in het Amphia ziekenhuis op je genomen en daarbij ook nog dagelijkse beslommeringen met mij gedeeld op onze chaotische kamer. Ineens stond er dan een plantje op mijn buro, ging je mijn 10 beschimmelde koffiekoppen afwassen of hingen er kerstballen aan mijn lamp. Dank ! Ingrid van de Laar, mijn cardio maatje. Lieve Ingrid, vanaf 2005 gingen we intenser samenwerken en het is mede dankzij jou dat we in de afgelopen jaren zoveel hebben kunnen opbouwen binnen de cardiogenetica. Doordat je er in slaagde een Hartstichting beurs te krijgen kwamen er middelen om aan meer families verder te werken. Je bent een fantastische collega en ik verheug me er op nog lang samen te werken; nu ben jij aan de beurt ! Lieve Judith V. , een jaar lang heb je je ingespannen voor de cardio counselingen en ik heb een beroep moeten doen op je zelfstandigheid. Doordat alles zo goed liep heb je voor rust gezorgd en mij heel erg geholpen, dank je. Ik hoop natuurlijk dat je uiteindelijk binnen het cardioteam blijft. Dr Grazia Mancini, lieve Grazia, dank voor je inspanningen en betrokkenheid bij de ATS familie.
Ook de overige collega's wil ik bedanken voor de collegialiteit en goede sfeer: Alice Brooks, Anja Wagner, Anneke Maat-Kievit, Fred Petrij, Gretel Oudesluijs, Rogier Oldenburg, Margriet Collee, Marieke van Dooren, Robert-Jan Galjaard, Lutgarde Govaerts, Yolande van Bever, en natuurlijk de assistenten, psychologen en genetisch consulenten.
Fred, dank voor al je inspanningen om de organisatie van de cardiogenetica te verbeteren.
Het secretariaat en administratief medewerkers wil ik bedanken voor alle hulp en gezelligheid. Vooral Agnes natuurlijk, een rots in de branding.

Prof.dr. Ben Oostra, beste Ben, dank voor de mogelijkheden die je biedt om binnen het DNA researchlab aan cardiovasculaire afwijkingen te werken. En dat we dit in samenwerking met Dr. Aida Bertoli-Avella kunnen doen ! Dear Aida, dankzij jouw inspanningen lopen de projecten rondom de verschillende 'cardio-families', en het is altijd een plezier om met je te overleggen. Dr Dennis Dooijes, Beste Dennis, heel jammer vind ik het dat je weg gaat; je hebt de hele cardio DNA diagnostiek in Rotterdam opgezet en het loopt perfect dankzij jou. Ook je enthousiasme bij nieuwe bevindingen zal ik missen, maar we hebben nog het een en ander af te maken en blijven hopelijk samenwerken. Prof.dr. Peter Heutink en Bianca de Graaf dank ik voor het werk aan de lateralisatie familie.
Het cardiogenetica team is breder en heeft kunnen groeien dankzij het enthousiasme en de energie van de cardiologen en kindercardiologen van het Thoraxcentrum en Sophia kinderziekenhuis. De afgelopen jaren is de samenwerking sterker geworden mede dankzij de inspanningen van collega's die de patiënten naar ons verwijzen. Dr Jolien Roos-Hesselink, dear Jolien, mede dank zij jouw toenemende verwijzingen van patiënten en families met aortapathologie, is er de afgelopen jaren een groot bestand opgebouwd van families met LVOTO en aneurysma's. We hebben allerlei plannen en ik heb zin in de voortzetting van onze samenwerking ! Ingrid Frohn-Mulder, kindercardiologe. Lieve Ingrid, al vanaf de

tijd bij de Prenatale Diagnostiek overleg ik met je, en ben jij ons belangrijkste aanspreekpunt geworden voor de cardiogenetica in het Sophia kinderziekenhuis. Omdat je ook in de zorg rondom de (familiaire) cardiomyopathieën actief betrokken bent bij de 'vrijdag cardiogenetica bespreking', sla je een brug tussen kinder- en volwassen cardiologie. Dank je ook voor het gezellige overleg bij jou thuis ! Hierbij bedank ik tevens de andere cardiologen betrokken bij de volwassen cardiogenetica, Prof.dr. Folkert ten Cate en Dr. Michelle Michels, voor hun bijdrage aan het onderzoek in de verschillende families met (noncompaction) cardiomyopathie, beschreven in deze thesis. De volwassen cardiogenetica poli is de afgelopen jaren steviger neergezet dankzij de inzet van Dr. Danielle Majoor-Krakauer en het vele werk dat Judith Phefferkorn, genetisch consulente, heeft verricht. Lieve Judith, door jouw inzet en betrokkenheid bij de families met cardiomyopathieën loopt de volwassen cardiogenetica poli zo goed, je hebt bergen werk verzet. Ook Yvonne Hoedemaekers en Conny van de Meer hebben een belangrijk aandeel geleverd!
Mieke Kerstjens-Frederikse en de 'Groningse groep' dank ik voor de *NOTCH1* analyses in de LVOTO families en de samenwerking met betrekking tot LVOTO afwijkingen; hopelijk gaan we die nog uitbreiden.

Alle mede-auteurs wil ik bedanken voor hun bijdrage.

Prof.dr Paul Coucke, beste Paul, dank je voor het (DNA) werk wat jij en je collegas van het Universitair Ziekenhuis Gent hebben verricht in de Rotterdamse ATS families. Daarnaast dank ik jou en Veerle voor de vriendschap en gastvrijheid die je hebt geboden aan mij, collega's en familie !

In 2005 begon ik als buitengewoon staflid in het Amphia Ziekenhuis, nadat Prof.dr. Hanne Meijers mij vroeg een poli op te zetten in samenwerking met de gynaecologen en kinderartsen. Beste Hanne, ik ben je heel dankbaar dat je me destijds deze mogelijkheid bood, het heeft mij veel plezier en voldoening in mijn werk bezorgd.
Dr. Roger Heydanus, dr. Dimitri Papatsonis, en dr. Simone Lunshof, gynaecologen van de Prenatale Diagnostiek in het Amphia ziekenhuis. Beste Roger, Dimitri en Simone, dank voor alle verwijzingen en de prettige samenwerking. Dank ook voor jullie flexibiliteit om deze laatste maanden wat meer ruimte te krijgen voor het afronden van dit proefschrift en jullie belangstelling hiervoor. Helmi, Miranda en Margie, dank voor jullie perfecte (en gezellige) ondersteuning van de prenatale-genetica poli, waardoor het elke keer weer zo plezierig is om aan het spreekuur te beginnen.
De kinderartsen waarmee ik intensief samenwerk dr. Stella de Man en dr. Coranne Aarts. Lieve Stella, jou wil ik bedanken voor de manier waarop je ruimte schept om, in een gezamenlijk spreekuur, samen na te denken over genetische diagnostiek bij kinderen met een ontwikkelingsachterstand/aangeboren afwijkingen. Ik denk dat we een vrij unieke formule hebben ! Dank ook voor alle fijne gesprekken, je bent meer dan alleen collega voor mij. Lieve Coranne, ook jou dank ik voor de fijne samenwerking.
Carla Verkooijen, lieve Carla, je bent van onschatbare waarde voor de kinder-genetica poli in het Amphia en ik ben je heel erg dankbaar dat je mijn zaken ook 'een beetje in de gaten houdt'.

De mannen van de 'Erasmus room of Horror': Tom de Vries Lentsch en Ruud Koppenol. Beste Tom, het spijt me voor de 'puinhoop' die ik je aanleverde, waardoor je heel hard hebt moeten werken. Ik ben je enorm dankbaar voor je professionele hulp ! Ruud, ook jij bedankt voor je bijdrage, en voor de broodnodige humor ! Graag geen poppetjes op mijn promotiedag.

Lieve Aswin, jou vriendschap is nog steeds heel belangrijk !
Lieve Carolien, al jaren zijn we vriendinnen en hebben lief en leed gedeeld. Bijna elke maandag logeer ik bij je en hierdoor heb ik niet alleen heel efficiënt kunnen werken maandagavond, maar kon ik ook elke week met je bijpraten, en de kids zien. Dank je dat je er altijd bent voor mij.
Mijn paranimfen en vriendinnen Alice Brooks en Nicolette den Hollander. Ik ben heel blij dat jullie naast mij staan. Lieve Alice, stelling 10 gaf je mij, en het typeert ook meteen wat wij hebben. Bij jou kan ik terecht voor alle 'matters of the heart', tijdens het werk en daarbuiten ! Dank voor je vriendschap, die mij heel dierbaar is. Lieve Nicolette, je bent als familie voor mij. Ontelbare keren heb je me moed ingesproken en goede raad gegeven. Wat moet ik zonder jou ? Dank voor alles wat je voor mij, Patrick en Stijn betekent !

Mijn familie en (belgische) vrienden dank ik voor alle steun, aandacht, belangstelling en afleiding. Lieve Els, Godelieve, Suzanne en Maja, ik zie jullie veel te weinig maar ik denk vaak aan alle goede momenten, jullie zijn een deel van mij.

Mijn peter en meter, die ook voor mij zorgen. Lieve Piet, dank voor alle troost en steun die je me gaf. Liesbeth, jouw liefde en steun aan mama, papa, de rest van de familie en aan mij is ongelofelijk. Door jou (en papa) kon ik af en toe ongestoord verder werken, heel erg bedankt. Je bent een ware oma voor Stijn. Mama zou er blij om zijn.
Lieve papa, dank je voor alles wat je voor mij hebt gedaan. Jouw en mama's liefde voor de natuur was een rode draad door ons leven thuis en daarna. Ik hoop dat je dit ook aan Stijn kunt meegeven. Dank je dat je er voor Stijn altijd bent, hij is dol op opa !

Ik begon en sluit af met jou. Lief Patje, **compañero**, dank je..... voor alles