



ORIGINAL ARTICLE

Quantifying displacement of urogenital organs after abdominoperineal resection for rectal cancer

Sarah Sharabiany¹ | Gaby J. Strijk¹ | Robin D. Blok¹ | Colin G. Ferrett² | Jaap Stoker³ | Christopher Cunningham⁴ | Jarmila D. W. van der Bilt⁵ | Anna A. W. van Geloven⁶ | Wilhelmus A. Bemelman¹ | Roel Hompes¹ | Gijsbert D. Musters¹ | Pieter J. Tanis¹

¹Department of Surgery, Amsterdam University Medical Centres, University of Amsterdam, Amsterdam, The Netherlands

²Department of Radiology, Oxford University Hospitals NHS Foundation Trust, Oxford, UK

³Department of Radiology, Amsterdam University Medical Centres, University of Amsterdam, Amsterdam, The Netherlands

⁴Department of Colorectal Surgery, Churchill Hospital, Oxford University Hospitals NHS Foundation Trust, Oxford, UK

⁵Department of Surgery, Flevo Hospital, Almere, The Netherlands

⁶Department of Surgery, Tergooi Hospital, Hilversum, The Netherlands

Correspondence

Pieter J. Tanis, Department of Surgery, Amsterdam UMC, University of Amsterdam, Cancer Center Amsterdam, De Boelelaan 1117, 1081 HV Amsterdam, the Netherlands.
Email: p.j.tanis@amsterdamumc.nl

Funding information

No funding has been received by any author in relation to this article.

Abstract

Aim: This study aimed to quantify displacement of urogenital organs after abdominoperineal resection (APR), and to explore patient and treatment characteristics associated with displacement.

Method: Patients from 16 centres who underwent APR for primary or recurrent rectal cancer (2001–2018) with evaluable preoperative and 6–18 months postoperative radiological imaging were included in the study. Anatomical landmarks on sagittal images were related to a coordinate system based on reference lines between fixed bony structures and absolute displacements were calculated using the Pythagorean theorem. Rotation of landmarks was measured relative to a pubic-S5 reference line.

Results: There were 248 patients included of which 171 were men and 77 women. The median displacement of the internal urethral orifice was 25 mm in men (maximum 65), and 17 mm in women (maximum 50). Rotation of the internal urethral orifice was in a caudal direction in 160/170 (94%) of men and 65/73 (89%) of women, with a median of 32 degrees (maximum 85) and 33 degrees (maximum 83), respectively. Displacements of the posterior bladder wall, distal end of prostatic urethra and cervix were significantly correlated with the internal urethral orifice. In linear regression analysis, biological mesh reconstruction of the pelvic floor and visceral interposition were significantly associated with increased displacement of the internal urethral orifice, and female gender and any filling of the presacral space with decreased displacement.

Conclusions: Substantial absolute displacement and rotation of urogenital organs after APR for rectal cancer were observed, but with high variability among both men and women, and being significantly associated with reconstructive interventions.

KEYWORDS

abdominoperineal resection, quantification of displacement, rectal cancer, urogenital organs

INTRODUCTION

Abdominoperineal resection (APR) is the primary treatment in up to one third of rectal cancer patients [1]. Total mesorectal excision with

resection of the sphincter complex results in a large empty cavity in the pelvis. Posterior displacement of the anterior pelvic compartment can partially fill the pelvic cavity by intrinsic laxity or disrupted attachments between pelvic organs and absence of pelvic floor continuity. Further obliteration of the cavity is accomplished by either

This is an open access article under the terms of the Creative Commons Attribution-NonCommercial-NoDerivs License, which permits use and distribution in any medium, provided the original work is properly cited, the use is non-commercial and no modifications or adaptations are made.

© 2021 The Authors. Colorectal Disease published by John Wiley & Sons Ltd on behalf of Association of Coloproctology of Great Britain and Ireland.

spontaneous descent of small bowel loops or omentum, surgical procedures such as omentoplasty or caecal transposition, or a combination of mechanisms. All anatomical changes might contribute to some degree of displacement of bladder, prostate, uterus and vagina.

Urogenital dysfunction frequently occurs after rectal cancer treatment, with a great impact on a patient's life [2]. The cause is multifactorial, including preoperative radiotherapy, direct autonomic nerve injury, aging, and pre-existing comorbidities [3]. It is conceivable that postoperative anatomical changes can also play a role, considering the existing literature on functional problems secondary to pelvic organ prolapse in women [4]. In daily practice, pelvic organ displacements after APR are noticeable on radiological imaging, but we are not aware of studies that address or quantify these anatomical changes with potential functional implications. We hypothesized that substantial urogenital organ displacement occurs, probably most pronounced in women, and that filling the cavity with an omentoplasty might potentially prevent this [5,6].

The first step in clarifying the phenomenon of urogenital organ displacement is quantification of the anatomical changes in a large cohort of patients, which subsequently enables correlation with urogenital dysfunction and evaluation of therapeutic strategies in subsequent studies. Therefore, the aim of this multicentre cohort study was to develop methods to radiologically quantify displacement of urogenital organs after APR for rectal cancer, to determine the magnitude of displacement of different anatomical landmarks and their interlandmark correlation, and to determine the impact of patient and treatment factors on the degree of displacement.

METHODS

Patients and design

Patients who underwent APR for primary or recurrent rectal cancer were selected from three existing databases between 2001 and 2018 [5,7,8]. Inclusion was based on available sagittal pelvic imaging prior to APR and between 6 and 18 months postoperatively. A specific time interval was set for the postoperative scan to increase comparability of the data and diminish the effect of time on pelvic organ displacement. Patients with total exenteration were excluded.

One of the three existing databases included the BIOPEX trial, which is a randomized controlled trial in which primary closure of the perineal wound was compared with biological mesh reconstruction of the pelvic floor after APR for rectal cancer [7]. Postoperative pelvic imaging was part of this trial. The study had been approved by the ethical review board of the Academic Medical Centre and informed consent was obtained for all participating patients. In the other two existing cohort studies, postoperative imaging was performed as part of routine daily practice. The need for informed consent was waived for these retrospective studies [5,8].

What does this paper add to the literature?

Anatomical changes after abdominoperineal resection can result in urogenital organ displacement, but this is an understudied phenomenon. This large observational study demonstrated that displacement of urogenital organs is highly variable among both male and female patients, and seems modifiable to a certain degree.

Reference lines and anatomical landmarks

Urogenital displacement was measured by determining the location of predefined anatomical landmarks on the midsagittal plane of preoperative T2-weighted magnetic resonance imaging (MRI) and the corresponding midsagittal plane of postoperative MRI or sagittal multiplanar reformat of computed tomography (CT). Reference lines between fixed bony structures were used as a coordinate system, resulting in pre- and postoperative x- and y-coordinates of the anatomical landmarks. The y-axis was drawn from the anterior inferior border of the fifth lumbar vertebra to the posterior inferior border of the pubic bone (Figure 1). The x-axis was drawn perpendicular to the y-axis from the anterior inferior border of the fifth sacral vertebra. Furthermore, rotation of anatomical landmarks relative to the posterior inferior border of the pubic bone was measured in degrees, with a reference line towards the anterior inferior border of the fifth sacral vertebra (white line in Figure 1).

Three anatomical landmarks were determined for both men and women. The two common landmarks for both genders were the internal urethral orifice and the posterior bladder wall (most posterior part). The third anatomical landmark was the distal end of the prostatic urethra in male, and the cervix or top of the vagina (after hysterectomy) in female. If patients had undergone posterior exenteration, preoperative location of the cervix was compared with postoperative location of the top of the vagina.

Measurements were performed by two investigators (SSH or GJS). Any discrepancy was resolved through discussion with a third investigator (PJT) until consensus was reached.

Outcome measures and patient subgroups

Outcome measures were the absolute displacement in millimetres, and the rotation in degrees of the four anatomical landmarks and interlandmark correlation. Displacement of the internal urethral orifice was compared between clinically distinct subgroups of patients, based on gender, neoadjuvant radiotherapy, surgical factors, and type of presacral filling on postoperative imaging (omentum, small bowel, a combination of omentum or tissue flap and small bowel, and no filling).

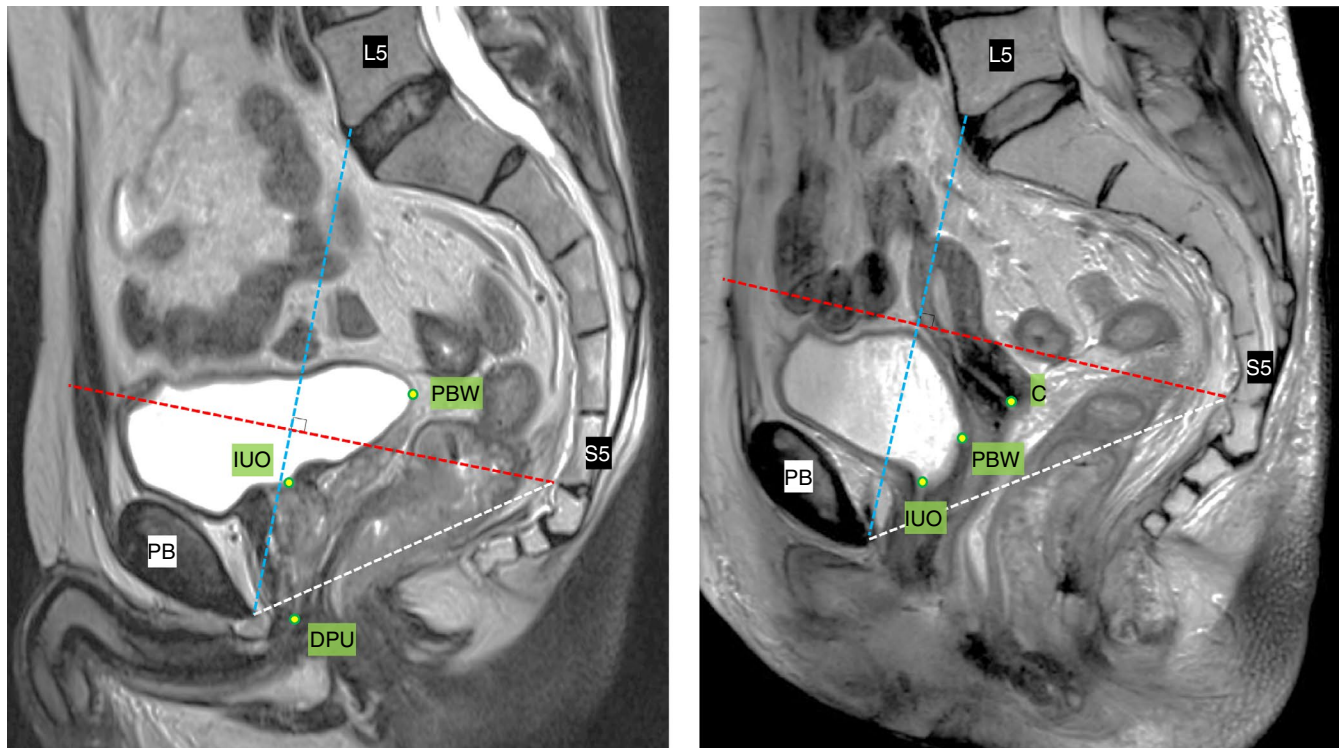


FIGURE 1 Anatomical reference lines used for comparing location of anatomical landmarks between pre- and postoperative images in men (left) and women (right). Coordinate system for measuring absolute displacement: y-axis (blue line) between anterior inferior border of fifth lumbar vertebra (L5) and posterior inferior border of the pubic bone (PB), and x-axis (red line) from the anterior inferior border of the fifth sacral vertebra (S5) and perpendicular to the y-axis. Reference line between posterior inferior border of the pubic bone and anterior inferior border of the fifth sacral vertebra (white) for measuring rotation of the anatomical landmarks. Anatomical landmarks for both genders are the internal urethral orifice (IUO) and posterior bladder wall (PBW). Additional landmarks are the distal end of the prostatic urethra (DPU) in men, and the cervix or top of vagina (C) in women

Calculation of displacement

The preoperative x- and y-coordinates of anatomical landmarks were subtracted from the postoperative x- and y-coordinates. The absolute displacement (D) could then be calculated by using the Pythagorean theorem with the following equation: $\Delta X^2 + \Delta Y^2 = D^2$. The direction of displacement was dorsal if ΔX was positive, ventral if ΔX was negative, cranial if ΔY was positive, and caudal if ΔY was negative. Herewith, four directions of displacement were defined: dorsal-caudal, dorsal-cranial, ventral-cranial and ventral-caudal.

Regarding the rotation relative to the posterior inferior border of the pubic bone, landmarks located cranial to the reference line resulted in a positive value, and when located caudal to this line in a negative value. The rotation was calculated by subtracting the postoperative angle from the preoperative angle. A positive rotation indicated caudal displacement and a negative rotation indicated cranial displacement.

Statistical analysis

Categorical data were compared using the chi-squared test, and numerical data with the independent *t*-test or Mann-Whitney *U*

(MWU) test according to distribution. The absolute displacement was presented as median with interquartile range (IQR) as well as minimum and maximum to show all parameters reflecting interindividual variability. Displacement of the internal urethral orifice was the outcome parameter in subgroup analyses: omentoplasty during APR (muscle flaps excluded), hysterectomy (muscle flaps excluded), biological mesh closure of the pelvic floor (absorbable polyglactin meshes excluded), type of presacral filling as found on postoperative imaging, and neoadjuvant radiotherapy. For the subgroup analysis of type of presacral filling, presence of only fibrosis in the presacral area was defined as no filling, while presacral seroma, abscess and tumour recurrence were excluded. Subgroup analyses were performed by the MWU or Kruskal-Wallis test according to the number of groups and were graphically presented in boxplots. Displacement of the internal urethral orifice was used as dependent variable in a linear regression analysis to determine the association with omentoplasty, hysterectomy, gender, type of APR, prior pelvic surgery, biological mesh reconstruction of the pelvic floor, visceral interposition, type of presacral filling on postoperative imaging, and neoadjuvant radiotherapy. Results are presented as Beta in millimetres and 95% CI. Correlations between displacements of different landmarks within each patient were graphically presented in scatterplots, and Spearman's correlation was calculated. All missing data

were excluded from analysis. The statistical significance level was set at a p -value of <0.05 . Statistical analysis was performed using SPSS software for Windows version 26 (IBM Corp).

RESULTS

Patient characteristics

A total of 489 patients underwent APR for primary or recurrent rectal cancer in 14 centres in the Netherlands (2001–2018) and two centres in the United Kingdom (2010–2018). After exclusion for total pelvic exenteration ($n = 12$), neobladder reconstruction ($n = 1$) and no pre- or postoperative evaluable scan ($n = 228$), a total of 248 patients were included (Figure 2). Mean age was 64 years (SD 12.5), and 171 (69%) were male. Twenty-nine of 171 male patients had previously undergone pelvic surgery (17%), and this was the case in 35 of 77 female patients (46%), of whom 14 (18%) had a prior hysterectomy. Neoadjuvant radiotherapy was given in 216 patients (84%). The APR consisted of an additional resection in 57 male patients (34%) and 41 female patients (53%). Six women had a hysterectomy as part of the APR (8%). Baseline characteristics are summarized in Table 1.

Urogenital displacement

Absolute distance (mm)

The displacement of the internal urethral orifice for men was median 25 mm (IQR, 17–33) with a maximum of 65 mm, and for women median 17 mm (IQR, 10–31) with a maximum of 50 mm. The direction of displacement of the internal urethral orifice was towards dorsal-caudal in 72% (122/170) of men and 64% (47/73) of women (Table 2). The absolute displacement of the posterior bladder wall was median 32 mm (IQR, 25–44) in men and median 36 mm (IQR, 24–47) in women, with a maximum of 83 and 75 mm, respectively. The distal end of the prostatic urethra displaced with a median of 12 mm (IQR, 9–17) and a maximum of 76 mm, and the cervix/top of the vagina with a median of 40 mm (IQR, 27–46) and a maximum of 77 mm.

Rotation (degrees)

The rotation of the internal urethral orifice relative to the posterior inferior border of the pubic bone was in a caudal direction in 94% (160/170) of men and 89% (65/73) of women. This rotation was median 32 degrees (IQR, 23–41) and median 33 degrees (IQR, 14–47) for men and women, with a maximum of 85 and 83 degrees, respectively (Table 2). Median caudal rotation of the posterior bladder wall for men was 22 degrees (IQR, 15–30) and for women 33 degrees (IQR, 15–42). The distal end of the prostatic urethra rotated with a

median of 25 degrees (IQR, 13–38), and the cervix with a median of 29 degrees (IQR, 16–34).

Subgroup analysis

In patients with an omentoplasty, the median displacement of the internal urethral orifice was 20 mm (IQR, 13–31), compared to 26 mm (IQR, 16–34) in patients without omentoplasty. When only women were analysed, corresponding median displacements were 17 mm (IQR, 9–30) and 21 mm (IQR, 11–31), respectively. All subgroup analyses are displayed in Figure 3.

In linear regression analysis, biological mesh reconstruction of the pelvic floor (B 8 mm; 95% CI: 2, 13; $p = 0.007$) and visceral interposition (B 13 mm; 95% CI: 0, 26; $p = 0.046$) were associated with increased displacement, whereas female gender (B -11 mm; 95% CI: -16, -6; $p < 0.001$) and a filled presacral space by any tissue/organ (B -6 mm; 95% CI: -11, -1; $p = 0.021$) was associated with less displacement of the internal urethral orifice (Table S1).

Correlation anatomical landmarks

The Spearman test in both men and women showed a significant correlation between the displacement of the posterior bladder wall and internal urethral orifice (Table S2). The correlation in absolute displacement showed more interindividual variability, compared to the correlation in rotation (Figure S1). The displacements of the distal end of the prostatic urethra and the cervix were also significantly correlated with the internal urethral orifice. The distal end of the prostatic urethra and the cervix were more closely correlated with the internal urethral orifice when measuring rotation in degrees if compared to absolute displacement in millimetres.

DISCUSSION

In this study, we aimed to quantify displacement of pelvic organs after APR since there are no studies which address this research question. We observed substantial urogenital organ displacements with a large interindividual variation (Figures S2 and S3). As expected, the direction of displacement was almost exclusively in a dorsal-caudal direction. The hypothesis of women having more urogenital displacement after APR could not be confirmed, and even an association in the opposite direction was suggested. If the postoperative imaging revealed filling of the presacral space with any tissue, displacement was less if compared to no filling.

Since this subject has not previously been studied, we set up the methodology by defining reference lines and specific anatomical landmarks from scratch. The internal urethral orifice was easy to locate on both CT- and MRI-scan and is not supposed to be affected by bladder volume, for which reason it is assumed to be a reliable

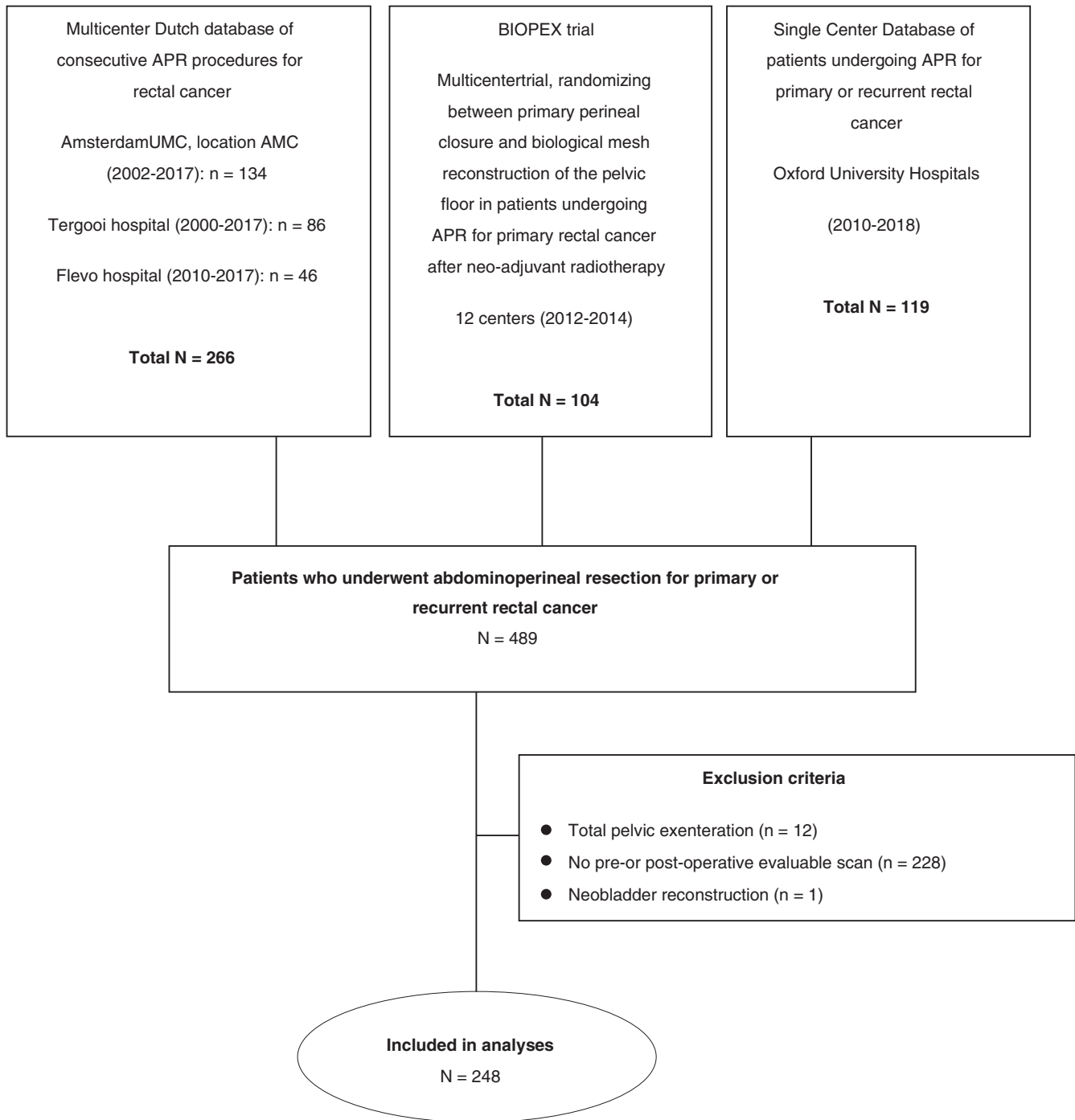


FIGURE 2 Flow diagram of patient inclusion

and reproducible landmark. Furthermore, this landmark can be used independent of gender. For this reason, we used the internal urethral orifice as the primary outcome measure for subgroup analyses. The only disadvantage of this landmark is the decreased variability if compared to the posterior bladder wall (Figure S1a), and might therefore not accurately represent the outliers. The posterior bladder wall was also easy to locate on both CT- and MRI-scan, but might be affected by the bladder volume and difficult to reliably define in case the posterior bladder wall is oriented vertically for several centimetres, which can cause interobserver variability.

Due to the lower intrinsic contrast resolution, the distal end of the prostatic urethra and cervix were difficult to locate on CT-scan which limits its applicability. To enhance the reproducibility and simplify further studies related to this topic, we propose using either the internal urethral orifice or posterior bladder wall as anatomical landmarks to quantify the degree of urogenital organ displacement.

A wider variance was seen in the distribution of absolute numbers and the rotation mainly represents the shift in cranial and caudal direction and to a lesser extent in dorsal direction. Therefore,

TABLE 1 Baseline characteristics

		Male (n = 171)	Female (n = 77)
Age	Years (mean ± SD)	64 ± 12	64 ± 13
BMI	kg/m ² (mean ± SD)	27 ± 5	27 ± 6
Prior pelvic surgery	Total	29/171 (17)	35/77 (46)
	Sacral colpopexy	-	4/77 (5)
	Caesarean section	-	5/77 (7)
	Oophorectomy	-	6/77 (8)
	Hysterectomy	-	14/77 (18)
	Sterilization	1/171 (1)	5/77 (7)
	TURP or TURBT	7/171 (4)	-
	(Partial) prostatectomy	5/171 (3)	-
	TEM	4/171 (2)	5/77 (7)
	Low anterior resection	9/171 (5)	6/77 (8)
	Other	6/171 (4)	7/77 (9)
APR indication	Primary rectal cancer	155/171 (91)	69/77 (90)
	Recurrent rectal cancer	16/171 (9)	8/77 (10)
Neoadjuvant treatment	None	22/169 (13)	8/77 (10)
	Short-course radiotherapy	27/169 (16)	13/77 (17)
	Long-course radiotherapy	39/169 (23)	18/77 (23)
	Chemoradiotherapy	81/169 (48)	38/77 (49)
APR type	Intersphincteric	21/168 (13)	4/77 (5)
	Conventional	41/168 (24)	15/77 (20)
	Extralevator	106/168 (63)	58/77 (75)
Additional resection	Total	57/168 (34)	41/77 (53)
	Vaginal wall	-	26/77 (34)
	Adnex	-	9/77 (12)
	Uterus	-	6/77 (8)
	Seminal vesicle	13/168 (8)	-
	(Partial) Prostate	17/168 (10)	-
	Partial bladder	4/168 (2)	0/77 (0)
	Coccyx	26/168 (16)	13/77 (17)
	Pelvic side wall	5/168 (3)	4/77 (5)
	Presacral fascia	1/168 (1)	1/77 (1)
Omentoplasty	Total	68/171 (40)	37/77 (48)
Visceral interposition	Total	1/134 (1)	6/63 (10)
	Uterus	-	6/63 (10)
	Caecum	1/134 (1)	0/63 (0)
Perineal closure	Primary closure	89/168 (53)	38/77 (49)
	Biological mesh	47/168 (28)	22/77 (29)
	Resorbable synthetic mesh	28/168 (17)	9/77 (12)
	Gluteal turnover flap	2/168 (1)	2/77 (3)
	Muscle flap	2/168 (1)	6/77 (8)

Note: Data are presented as absolute numbers (proportions), unless otherwise stated.

Abbreviations: APR, abdominoperineal resection; BMI, body mass index; SD, standard deviation; TEM, transanal endoscopic microsurgery; TURBT, transurethral resection of bladder tumour; TURP, transurethral resection of the prostate.

TABLE 2 Measured urogenital displacements in male and female patients who underwent abdominoperineal resection on sagittal pelvic imaging

Absolute displacement of anatomical landmarks (mm)	Male (n = 171)			Female (n = 77)		
	n	Median (IQR)	Range (min-max)	n	Median (IQR)	Range (min-max)
Direction of displacement						
Internal urethral orifice (n = 243)						
Any	170	25 (17-33)	0-65	73	17 (10-31)	2-50
Dorsal-caudal	122	27 (19-34)	4-65	47	20 (13-31)	2-50
Dorsal-cranial	32	23 (16-32)	0-42	19	18 (10-30)	4-46
Ventral-cranial	4	6 (6-22)	5-27	2	7	4-9
Ventral-caudal	12	9 (6-19)	3-27	5	7 (6-10)	6-11
Posterior bladder wall (n = 248)						
Any	171	32 (25-44)	1-83	77	36 (24-47)	3-75
Dorsal-caudal	116	32 (26-43)	3-83	39	41 (27-48)	4-75
Dorsal-cranial	43	36 (21-46)	2-77	32	36 (24-47)	3-67
Ventral-cranial	3	35	10-44	1	11	-
Ventral-caudal	9	18 (14-31)	1-39	5	20 (14-26)	8-28
Distal end of prostatic urethra (n = 163)						
Any	163	12 (9-17)	1-76	-	-	-
Dorsal-caudal	84	14 (10-19)	1-76	-	-	-
Dorsal-cranial	31	11 (6-15)	2-28	-	-	-
Ventral-cranial	10	8 (2-13)	2-25	-	-	-
Ventral-caudal	38	12 (8-18)	1-28	-	-	-
Cervix/top of the vagina (n = 58)						
Any	-	-	-	58	40 (27-46)	8-77
Dorsal-caudal	-	-	-	36	40 (27-46)	11-77
Dorsal-cranial	-	-	-	19	39 (23-50)	9-70
Ventral-cranial	-	-	-	0	-	-
Ventral-caudal	-	-	-	3	32	8-54
Degrees of rotation						
Internal urethral orifice (n = 243)						
Caudal	160	32 (23-41)	2-85	65	33 (14-47)	0-83
Cranial	10	9 (4-13)	0-25	8	8 (3-12)	0-25
Posterior bladder wall (n = 248)						
Caudal	164	22 (15-30)	0-59	72	33 (15-42)	0-64
Cranial	7	8 (2-10)	1-26	5	6 (4-8)	4-10
Distal end of prostatic urethra (n = 163)						
Caudal	134	25 (13-38)	0-86	-	-	-
Cranial	29	11 (5-27)	0-102	-	-	-
Cervix/top of the vagina (n = 58)						
Caudal	-	-	-	56	29 (16-34)	2-75
Cranial	-	-	-	2	6	5-6

the absolute displacement might be a more accurate reflection of the clinical condition.

We assumed that presacral filling might prevent displacement of urogenital organs, which could be confirmed by linear regression analysis. Remarkably, performing an omentoplasty resulted in

a minimal reduction of displacement of the internal urethral orifice if compared to no omentoplasty, even when only women were included. In addition, the magnitude of displacement in the presence of presacral omentum was comparable to filling with some small bowel loops. However, presacral filling by small bowel cannot be predicted

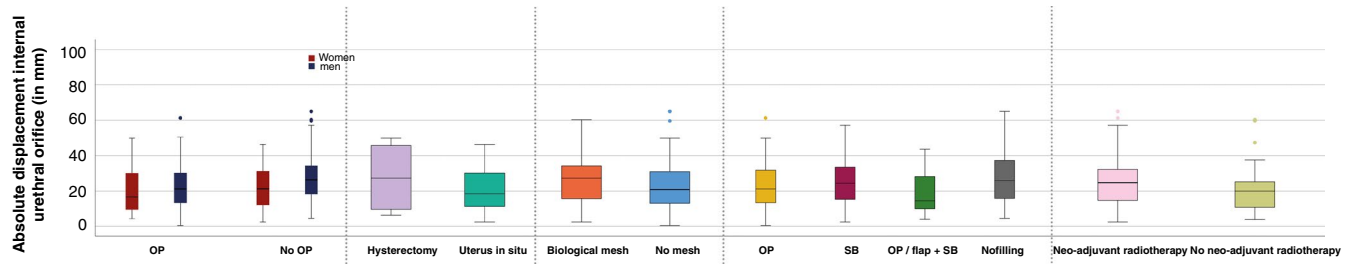


FIGURE 3 Boxplots showing the absolute displacement of the internal urethral orifice in millimetres for different subgroups of patients: with or without omentoplasty (OP), hysterectomy or not in women, depending on pelvic floor closure with a biological mesh or not, depending on filling of the presacral space with omentum, small bowel (SB) or a combination of omentum or tissue flap and SB, and depending on whether or not they received neoadjuvant radiotherapy

or controlled by the surgeon, and a larger amount of displacement was observed in case of no filling. In addition, an omentoplasty might have been performed in patients in whom a larger pelvic defect was created. Also the surgical technique of the omentoplasty might have influenced the results.

Little is known about organ displacement after pelvic surgery, which makes it difficult to compare our findings with the literature. Alternatively, the results of gynaecological studies related to pelvic organ prolapse can be used as a reference. One of these studies examined the effect of sacropexy surgery in patients with cervical prolapse by using dynamic MRI scans in a supine position at rest and during maximal straining [9]. This study found no vertical displacement of the cervix at rest and around 20 mm at maximal straining. We found a median displacement of 40 mm after APR. However, no organs have been resected in patients with pelvic organ prolapse and the displacement is measured actively, hence their results cannot be fully compared to our patient cohort.

Regarding the clinical implications of the present findings, the substantial displacements in some of the patients are probably resulting in functional problems. Dorsal displacement of the bladder in both genders can result in bladder emptying difficulties and risk of overflow incontinence. Specifically in women, the vagina can become angulated, or the top of the vagina can even herniate through the pelvic floor defect (Figure S2), after which sexual intercourse might no longer be possible. Future studies should elucidate the contribution of the specific anatomical changes after APR to urogenital dysfunction. If a correlation between urogenital displacement and dysfunction is found, effectiveness of possible preventive or therapeutic interventions should be explored. Such interventions might consist of specific techniques of pelvic floor reconstruction with or without filling of the presacral and/or perineal dead space.

The major limitation of our study was the retrospective assessment of pelvic imaging that was not performed for the purpose of the study. Imaging was performed with patients in a supine position without active pressure, while patients mainly experience urogenital dysfunction in a standing position and with straining. The literature reveals that upright MRI scanning and straining can both show a larger extent of prolapse [9,10]. Therefore, our results could possibly

underestimate the true amount of displacement. Furthermore, selection bias has probably occurred due to the strict time interval between the pre- and postoperative scan. We do not have the details of overall rectal cancer volumes of the participating centres in this study, and annual volumes for APR seem to be relatively low (<10). The external validity of the study might also be influenced by other population characteristics such as age, although a mean of 64 years has commonly been found in European rectal cancer studies [11]. The relatively small number of patients in the subgroup analyses makes it difficult to draw firm conclusions.

CONCLUSION

In this study, displacement of urogenital organs after APR for rectal cancer has been addressed and quantified. A remarkable variability in anatomical changes of the anterior pelvic compartment after proctectomy were observed among both male and female patients, with significant outliers. Given the associations with certain surgical treatment characteristics suggests that urogenital organ displacement might be modifiable. The proposed quantification method can be used in future studies.

ETHICAL APPROVAL

This study has been approved by the medical ethical committee of the UMC – location AMC and have therefore been performed in accordance with the ethical standards laid down in the 1964 Declaration of Helsinki and its later amendments.

ACKNOWLEDGEMENT

The authors would like to thank the BIOPEX study group for their contribution.

CONFLICT OF INTEREST

The authors declare that they have no conflict of interest.

DATA AVAILABILITY STATEMENT

The data that support the findings of this study are available from the corresponding author upon reasonable request.

**ORCID**Sarah Sharabiany  <https://orcid.org/0000-0003-2222-2037>Pieter J. Tanis  <https://orcid.org/0000-0002-3146-3310>**REFERENCES**

1. Nagtegaal ID, van de Velde CJ, Marijnen CA, van Krieken JH, Quirke P, Dutch Colorectal Cancer G, et al. Low rectal cancer: a call for a change of approach in abdominoperineal resection. *J Clin Oncol*. 2005;23(36):9257–64.
2. Ledebro A, Bock D, Prytz M, Haglind E, Angenete E. Urogenital function 3 years after abdominoperineal excision for rectal cancer. *Colorectal Dis*. 2018;20(6):O123–34.
3. Lange MM, van de Velde CJ. Urinary and sexual dysfunction after rectal cancer treatment. *Nat Rev Urol*. 2011;8(1):51–7.
4. Barber MD. Pelvic organ prolapse. *BMJ*. 2016;354:i3853.
5. Blok RD, de Jonge J, de Koning MA, van de Ven AWH, van der Bilt JDW, van Geloven AAW, et al. Propensity score adjusted comparison of pelviperineal morbidity with and without omentoplasty following abdominoperineal resection for primary rectal cancer. *Dis Colon Rectum*. 2019;62(8):952–9.
6. Musters GD, Lapid O, Stoker J, Musters BF, Bemelman WA, Tanis PJ. Is there a place for a biological mesh in perineal hernia repair? *Hernia*. 2016;20(5):747–54.
7. Musters GD, Klaver CEL, Bosker RJI, Burger JWA, van Duijvendijk P, van Etten B, et al. Biological mesh closure of the pelvic floor after extralevator abdominoperineal resection for rectal cancer: a multi-center randomized controlled trial (the BIOPEX-study). *Ann Surg*. 2017;265(6):1074–81.
8. Blok RD, Sharabiany S, Ferrett CG, Hompes R, Tanis PJ, Cunningham C. CT assessment of the quality of omentoplasty and its implications for perineal wound healing. *Int J Colorectal Dis*. 2019;34(11):1963–70.
9. van IJsselmuiden MN, Lecomte-Grosbras P, Witz JF, Brieu M, Cosson M, van Eijndhoven HWF. Dynamic magnetic resonance imaging to quantify pelvic organ mobility after treatment for uterine descent: differences between surgical procedures. *Int Urogynecol J*. 2020;31(10):2119–27.
10. Grob ATM, Olde Heuvel J, Futterer JJ, Massop D, Veenstra van Nieuwenhoven AL, Simonis FFJ, et al. Underestimation of pelvic organ prolapse in the supine straining position, based on magnetic resonance imaging findings. *Int Urogynecol J*. 2019;30(11):1939–44.
11. Detering R, Rutgers MLW, Bemelman WA, Hompes R, Tanis PJ. Prognostic importance of circumferential resection margin in the era of evolving surgical and multidisciplinary treatment of rectal cancer: a systematic review and meta-analysis. *Surgery*. 2021;170(2):412–31.

SUPPORTING INFORMATION

Additional supporting information may be found online in the Supporting Information section.

How to cite this article: Sharabiany S, Strijk GJ, Blok RD, Ferrett CG, Stoker J, Cunningham C, et al. Quantifying displacement of urogenital organs after abdominoperineal resection for rectal cancer. *Colorectal Dis*. 2021;23:2923–2931. <https://doi.org/10.1111/codi.15885>