



Quantification of Severity of Unilateral Coronal Synostosis

Sophia A. J. Kronig, MD¹ , Otto D. M. Kronig, MD¹ ,
Henri A. Vrooman, PhD^{2,3}, Jifke F. Veenland, PhD^{2,3},
and Léon N. A. Van Adrichem, MD, PhD¹

The Cleft Palate-Craniofacial Journal
2021, Vol. 58(7) 832-837

© 2020, American Cleft Palate-
Craniofacial Association



Article reuse guidelines:

sagepub.com/journals-permissions

DOI: 10.1177/1055665620965099

journals.sagepub.com/home/cpc



Abstract

Objectives: Severity of unilateral coronal synostosis (UCS) can vary. Quantification is important for treatment, expectations of treatment and natural outcome, and education of the patient and parents.

Design: Retrospective study.

Setting: Primary craniofacial center.

Patients, Participants: Twenty-three preoperative patients with unilateral coronal craniosynostosis (age < 2 years).

Intervention: Utrecht Cranial Shape Quantifier (UCSQ) was used to quantify severity using the variables: asymmetry ratio of frontal peak and ratio of frontal peak gradient.

Main Outcome Measures(s): The UCSQ variables were combined and related to visual score using Pearson correlation coefficient; UCSQ and visual score were additionally compared to Di Rocco classification by one-way analysis of variance or Kruskal-Wallis test. All measurements were made on computed tomography scans.

Results: Good correlation between UCSQ and visual score was found ($r = 0.67$). No statistically significant differences were found between group means of UCSQ in the 3 categories of Di Rocco classification ($F_{2,20} = 0.047$; $P > .05$). Kruskal-Wallis test showed no significant differences between group means of visual score in the 3 categories of Di Rocco classification (Kruskal-Wallis $H(2) = 0.871$; $P > .05$).

Conclusions: Using UCSQ, we can quantify UCS according to severity using characteristics, it outperforms traditional methods and captures the whole skull shape. In future research, we can apply UCSQ to 3D-photogrammetry due to the utilization of external landmarks.

Keywords

quantification, cranial suture, synostosis, anterior plagiocephaly

Introduction

Isolated unilateral coronal synostosis (UCS) is defined as the premature, one-sided, fusion of a coronal suture, resulting in left- or right-sided plagiocephaly anterior, naturally depending on the side of the fused suture. Unilateral coronal synostosis is the third most common type of simple (unisutural) craniosynostosis following scaphocephaly and trigonocephaly, accounting for 13% to 16% of all craniosynostoses (Selber et al., 2008, Di Rocco et al., 2009, Kolar, 2011, Di Rocco et al., 2012).

This distorted (craniofacial) skull consists of a spectrum of features, varying from mild to severe asymmetry (Persing, 2008). The most common clinical feature is forehead asymmetry; furthermore, UCS is associated with other craniofacial

¹ Department of Plastic and Reconstructive Surgery, University Medical Center Utrecht, The Netherlands

² Department of Radiology, Erasmus MC, Rotterdam, University Medical Center Rotterdam, The Netherlands

³ Department of Medical Informatics, Erasmus MC, Rotterdam, University Medical Center Rotterdam, The Netherlands

Corresponding Author:

Sophia A. J. Kronig, Department of Plastic and Reconstructive Surgery and Hand Surgery, University Medical Center Utrecht, Heidelberglaan 100, 3584 CX Utrecht, The Netherlands.

Email: sophiakronig@gmail.com

dysmorphology (orbital, nasal, and zygomatic asymmetry) and skull base abnormality (Bruneteau & Mulliken, 1992, Hansen et al., 1997).

Since UCS can present in different stages of severity, it is important to classify the severity considering treatment options, expectations of treatment and natural outcome, and education of the patient and its parents. Several tools are developed in order to either diagnose or quantify craniosynostosis and more specifically anterior plagiocephaly. These methods vary from calculated ratios to visual ratings and are helpful in getting insights in the severity of the anterior plagiocephaly (Bruneteau & Mulliken, 1992, Loveday & de Chalain, 2001, Di Rocco et al., 2012).

Some of the currently available quantification tools are widely accepted and used, therefore the current study will compare these methods with Utrecht Cranial Shape Quantifier (UCSQ) for diagnosing craniosynostosis. Utrecht Cranial Shape Quantifier is a newly introduced outline-based method of classification of skull shape deformities (Kronig et al., 2020). This method has the advantage of capturing the actual skull shape variation with every 3D diagnostic system capturing the surface of the head. External landmarks (soft tissue landmarks, visible with the bare eye) are used to extract an outline of the skull shape in this study using computed tomography (CT) scans, resulting in sinusoid curves. Specific and characteristic curves and parameters for UCS are found. Additionally, we will quantify the patients with UCS based on severity using the aforementioned methods and our proposed method; these different methods will be compared. The aim of this study is to implement our method to distinguish between different stages of severity of UCS.

Material and Methods

Patients

For the purposes of this study, we included children (age < 2 years) with nonsyndromic UCS. These patients were diagnosed at the Erasmus Medical Center, Sophia Children's Hospital Rotterdam. A full head preoperative CT scan needed to be available.

The study was approved by the local Medical Ethics Review Committee (MEC-2016-467). The study was deemed a retrospective clinical study and did not require formal research ethics approval under the Medical Research Involving Human Subjects Act.

Diagnosis of Plagiocephaly

The methodology for the quantification of craniosynostosis developed in our previous study (Kronig et al., 2020) is used in this study. Curves resulting from UCSQ were used to extract values needed for (calculations in) the flowchart (height and location of forehead peak and troughs, asymmetry ratio of frontal peak) (Figures 1 and 2). We used the term “affected side” to characterize the side of premature fusion of the coronal

suture and “unaffected side” refers to the absence of premature closure of the coronal suture. This does not mean that the skull shape of the unaffected side is normal.

Classification of Severity

Different parameters (Cranial Vault Asymmetry Index [CVAI], Di Rocco classification, visual score, UCSQ) were measured, calculated, and determined to qualify the severity of the UCS. All parameters were measured on CT scan.

Cranial Vault Asymmetry Index

Cranial Vault Asymmetry Index was calculated from dual cranial diagonal diameters (A and B) on CT scan as follows: $CVAI = \text{absolute difference in cranial diagonal diameters} / \text{largest cranial diagonal} \times 100$ (Loveday & de Chalain, 2001). Additionally, CVAI was divided in 5 categories according to severity, with a CVAI < 3.5 as normal symmetry and a CVAI of > 11.0 as the most severe asymmetry (category 1: < 3.5; category 2: 3.5-6.25; category 3: 6.25-8.75; category 4: 8.75-11.0; category 5: > 11.0) (Loveday & de Chalain, 2001, Holowka et al., 2017).

Di Rocco Classification

The patients were divided into 3 different types based on clinical observation and basicranium (skull base) analysis using CT scans, according to the proposed classification by Di Rocco et al. (2012). Type 1 is characterized by unilateral flattening of the frontal bone and elevation of the superior orbital ridge without deviation of the nasal pyramid. Type 2 refers to the deviation of the nasal pyramid and homolateral anterior displacement of the petrous bone in addition to frontal and orbital anomalies. Type 3 is characterized by severe deviation of the sphenobasilar bone in addition to the above-described anomalies.

Visual Score

Bruneteau and Mulliken (1992) described which visual features can be present in UCS and how they differ from those in positional plagiocephaly. These features include flattened ipsilateral forehead, larger ipsilateral orbit, ipsilateral anterosuperior displacement of ear, deviated nasal root toward ipsilateral, deviated nasal tip toward contralateral, ipsilateral anterior cheek displacement, and deviated chin toward contralateral. We rated these features in the included patients; 0 for “normal” appearance (no deformity), 1 for mild, 2 for moderate, and 3 for severe deformity. For each patient these ratings were added, leading to a minimum possible visual score of 0 and a maximum possible score of 21.

Our Proposed Method (UCSQ)

In order to classify the UCS patients according to severity using our proposed method, we used characteristics as listed in Table 1 (Kronig et al., 2020). The most distinctive variables for UCS

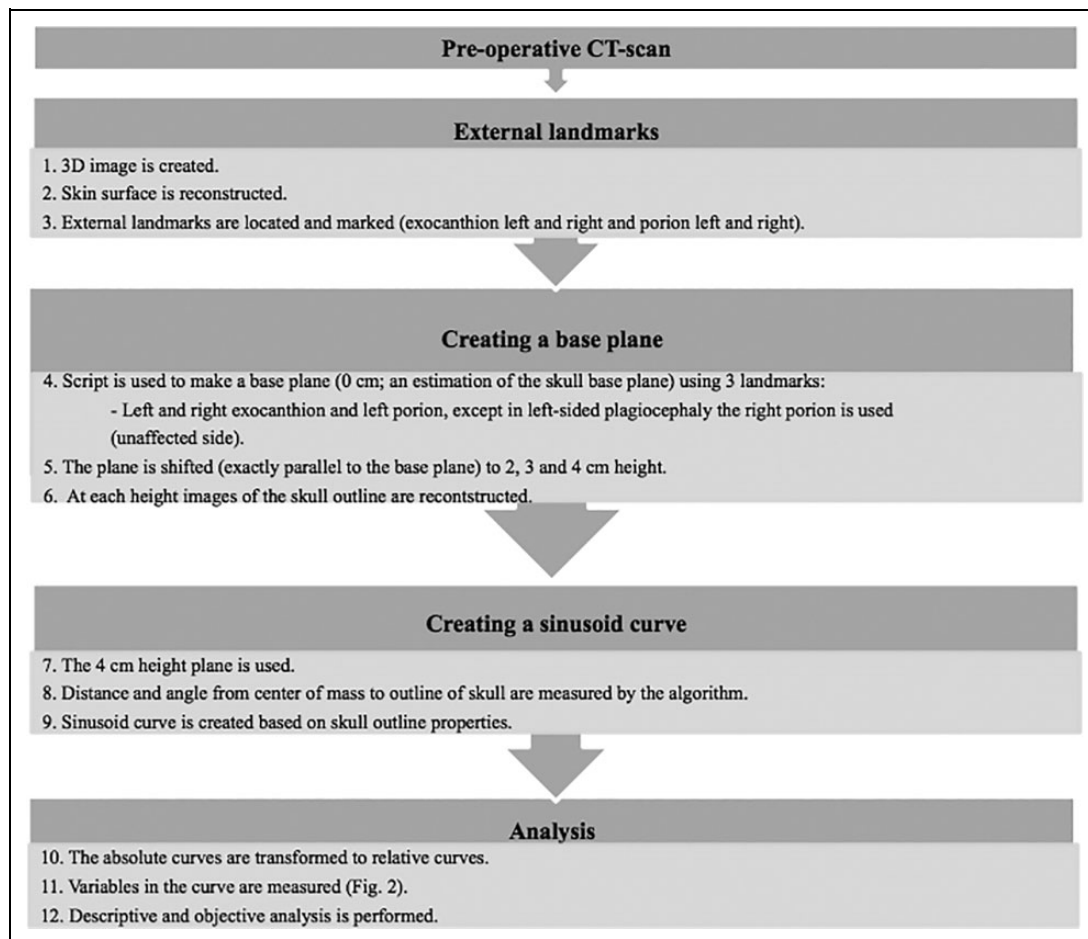


Figure 1. Summary of methods.

are asymmetry of frontal peak ratio and ratio of gradient of legs of curve.

Asymmetry ratio of frontal peak is calculated (Table 1; an asymmetry ratio of ≤ 0.8 was used to describe a peak shifted to the left side and ≥ 1.2 for a peak shifted to the right side, a ratio of 0.8 to 1.2 equals no significant shifting of the forehead peak). However in this study, we calculated asymmetry of frontal peak ratio by dividing affected side by unaffected side. The larger the ratio, the more severe the UCS.

Additionally, we considered the curve between the trough (XR, R and XL, L) and peak (XF, F) as a straight line for the purposes of the calculation of gradient (slope) of this line (Figure 2). This gradient (slope) can be calculated with the general formula: gradient = vertical rise/horizontal run. Table 1 shows the specific formula using variables extracted from our created curve. The ratio of gradient affected side to unaffected side was calculated (Table 1).

Included patients were ranked separately according to asymmetry ratio of frontal peak, where the lowest rank (1) is the lowest ratio (less severe), the highest rank is the most severe asymmetry ratio of the included patients. The same applies to the ratio of gradient. Both ranking numbers were added.

Statistical Analysis

Statistical analyses were performed using the Statistical Package for the Social Sciences (SPSS) for Windows (Version 21, SPSS Inc).

One-way analysis of variance (ANOVA) or Kruskal-Wallis test was used to compare UCSQ and visual score to Di Rocco classification and UCSQ and visual score to category of CVAI. The used test was based on normality of data. Appropriate post hoc tests were used (Tukey post hoc). Additionally, we compared Di Rocco classification to category of CVAI by using χ^2 test. Statistical significance was set at a P value $\leq .05$.

Pearson correlation coefficient or Spearman rank correlation coefficient was used to determine correlation between UCSQ and visual score, and CVAI, and visual score with CVAI. The used test was based on normality of data. The accepted guidelines for interpreting the correlation coefficients are: +1 indicates a perfect positive linear relationship, -1 indicates a perfect negative linear, and 0 indicates no linear relationship (Ratner, 2009). The outcomes of the correlation coefficient are characterized as poor (0.00 to 0.20), fair (0.21 to 0.40), moderate (0.41 to 0.60), good (0.61 to 0.80), or excellent

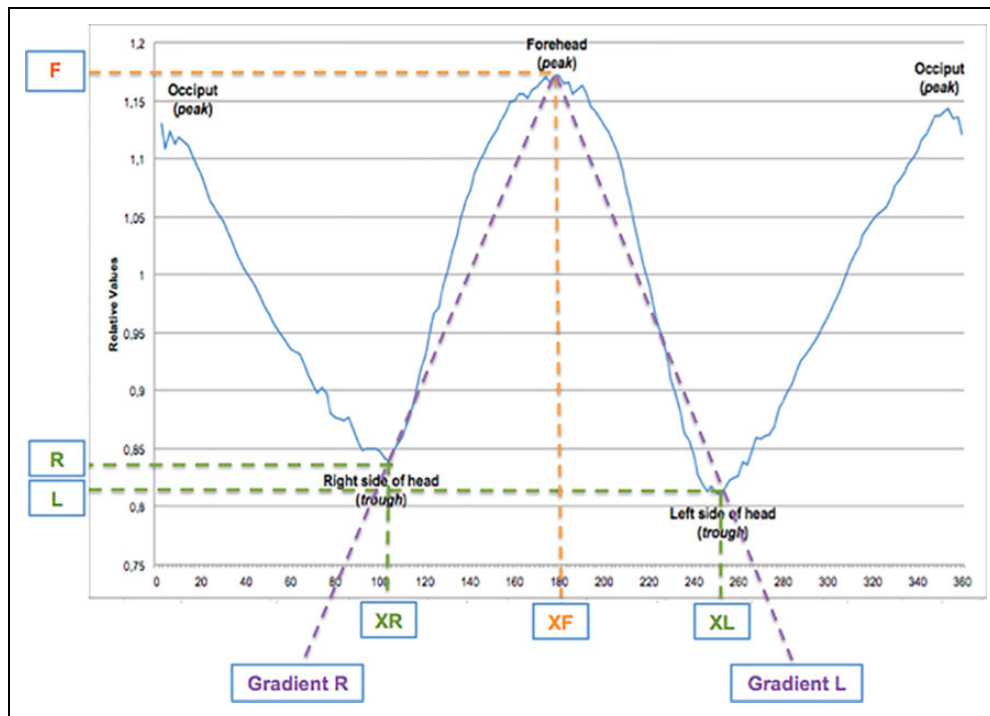


Figure 2. Visualization of the used variables.

Table 1. Extracted and Calculated Variables From Curve.

Extracted variable	Abbreviation	Extracted variable	Abbreviation
Maximum value of forehead peak	F	x-value (in degrees) of the maximum forehead value	XF
Minimum value of left side of head (trough)	L	Minimum value of right side of head (trough)	R
x-value (in degrees) of minimum value of width on left side	XL	x-value (in degrees) of minimum value of width on right side	XR
Calculated variable	Formula	Calculated variable	Formula
Asymmetry ratio of frontal peak (left-sided)	$(XL-XF)/(XF-XR)$	Asymmetry ratio of frontal peak (right-sided)	$(XF-XR)/(XL-XF)$
Vertical rise (ΔY) Gradient	F-R and/or F-L $\Delta Y/\Delta X$	Horizontal run (ΔX)	XF-XR and/or XL-XF
		Ratio of gradient affected to unaffected leg of curve	Gradient affected side/gradient unaffected side

(0.81 to 1.00) (Landis & Koch, 1977). Additionally, we separately compared both variables of UCSQ (asymmetry ratio of frontal peak and ratio of gradient of legs of curve) with the noted other quantification methods.

Results

Patient Characteristics

A total of 23 patients with UCS were included in this study, of which 14 (61%) with left-sided and 9 (40%) with right-sided anterior plagiocephaly. There were 10 (43%) boys and 13 (57%) girls. Mean age at the time of CT scan was 7 months (min 1 to max 19 months).

Figure 3 shows the mean curves for both right- and left-sided UCS and control (N = 5) patients. Control patients were included in our previous study (Kronig et al., 2020).

Table 2A shows calculated values of CVAI, mean CVAI is 4.5 (min 0.0 to max 11.9) and most common category of CVAI was 1 (CVAI < 3.5).

Table 2B shows the Di Rocco classification for the included patients, most common category of Di Rocco was 2. Mean visual score was 10.9 (min 6 to max 16).

Utrecht Cranial Shape Quantifier resulted in a mean asymmetry ratio of frontal peak of 1.6 (min 0.5 to max 2.7) and a mean ratio of gradient of leg of curve of 0.7 (min 0.3 to max 2.0). When rank numbers of both variables are combined, this result into a mean value of 24 (min 14 to max 31.5).

Comparison UCSQ and Existing Methods

No statistically significant differences were found between group means of UCSQ in the 3 categories of Di Rocco

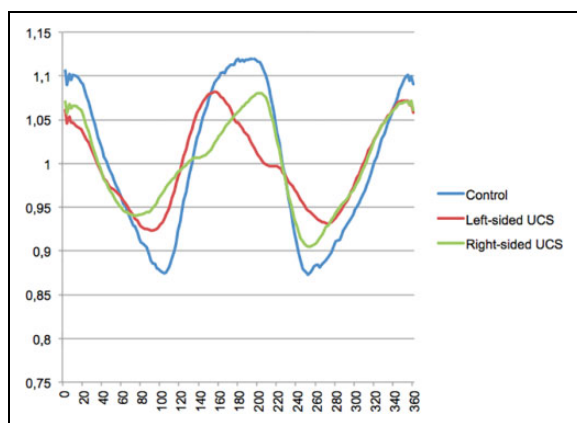


Figure 3. Mean curves for patients with right- and left-sided UCS and control patients, showing differences between the curves.

classification as determined by one-way ANOVA ($F_{2,20} = 0.047$; $P > .05$).

When comparing categories of CVAI, no statistically significant differences were found between group means of UCSQ in the categories of CVAI ($F_{4,18} = 0.287$; $P > .05$).

Kruskal-Wallis test was conducted to examine the differences in group means of visual score between the different categories of Di Rocco classification and the different categories of CVAI. No significant differences were found for Di Rocco classification (Kruskal-Wallis $H(2) = 0.871$; $P > .05$). No significant differences were found for categories of CVAI (Kruskal-Wallis $H(4) = 3.251$; $P > .05$).

Chi-Square test between Di Rocco classification and categories of CVAI showed no significant differences ($\chi^2(8) = 7.977$; $P > .05$).

Good correlation between UCSQ and visual score was found ($r = 0.67$). Poor correlation was found between UCSQ and (value of) CVAI ($r = 0.01$).

Correlations between visual score and (value of) CVAI were found to be poor ($r = -0.06$).

Additionally, there were no statistically significant differences found between group means of both the separate variables of UCSQ (asymmetry ratio of frontal peak and ratio of gradient of legs of curve) in the different categories of Di Rocco classification by using one-way ANOVA ($F_{2,20} = 0.126$; $P > .05$ and $F_{2,20} = 0.221$; $P > .05$, respectively). Kruskal-Wallis test showed no significant differences between the group means of asymmetry ratio of frontal peak in the different categories of CVAI (Kruskal-Wallis $H(4) = 6.322$; $P > .05$). One-way ANOVA showed no significant differences between the group means of ratio of gradient of legs of curve in the different categories of CVAI ($F_{4,18} = 1.908$; $P > .05$). A fair correlation was found between ratio of gradient and visual score ($r = 0.25$) and fair correlation between asymmetry ratio and (value of) CVAI ($r = -0.30$), moderate correlation between ratio of gradient and (value of) CVAI ($r = 0.51$). Poor correlation was found between asymmetry ratio and visual score ($r = 0.01$).

Table 2A. Calculated Values of CVAI.

Category	n	%
<3.5	10	43.5
3.5-6.25	8	34.8
6.25-8.75	3	13.0
8.75-11.0	1	4.3
>11.0	1	4.3

Abbreviation: CVAI, Cranial Vault Asymmetry Index.

Table 2B. Di Rocco Classification.

Type	n	%
1	4	17.4
2	15	65.2
3	4	17.4

Discussion

The aim of the present study was to quantify UCS according to UCSQ; we compared our quantification method with existing methods for quantification of UCS. These methods are CVAI, in which the asymmetry of the skull is being measured and calculated (Loveday & de Chalain, 2001). Di Rocco classification captures the skull base abnormality and asymmetry of the forehead, orbit, and nose (Di Rocco et al., 2012), this asymmetry of facial features is also described by the visual description of Bruneteau and Mulliken (1992). However, limitations also apply for these methods and are for example the incomplete capturing of the whole skull shape (CVAI) (Loveday & de Chalain, 2001), the subjectivity (visual description [Bruneteau & Mulliken, 1992] and Di Rocco classification [Di Rocco et al., 2012]), and the need of CT scanning (and therefore radiation load in children [Di Rocco classification] [Di Rocco et al., 2012]).

However, none of the above-described methods are universally accepted or used for the quantification of UCS. In the present study, we compared the previous methods with our UCSQ. We found no statistically significant differences in group means of UCSQ between the different categories of CVAI and we found a poor correlation between UCSQ and value of CVAI, this is as expected, because CVAI is mostly useful in positional plagiocephaly, due to the shifting of the skull and the resulting increase in diagonal length. Positional plagiocephaly gives a rhombic skull deformation, UCS gives a trapezoid skull malformation due to unilateral growth retardation. Additionally, no correlation between (value of) CVAI and visual score was noted and no significant differences in group means of visual score between the different categories of CVAI was found.

No statistically significant differences in group means of UCSQ between the different categories of Di Rocco were found. Comparing the other quantification methods to Di Rocco classification, no significant differences in group means

between the different categories of Di Rocco classification were found. Di Rocco classification is mostly based on skull base deformity, possibly resulting in an over- or under-estimation of the cranium. Furthermore, no correlation with severity of the skull deformation was found.

We found a good correlation between UCSQ and visual score, indicating that we now can put the visual aspects of asymmetry into numbers of severity using UCSQ. Utrecht Cranial Shape Quantifier outperforms the other analyzed methods. It is notable that our separate variables (asymmetry ratio of frontal peak and ratio of gradient of legs of curve) show less strong correlation with for example visual score, however combined they capture all aspects of the abnormal skull shape.

Several limitations should be considered when interpreting the results. We used data from only one craniofacial centre, resulting in an apparent relatively small patient group. However, we included a homogeneous group of patients, with regard to age and preoperative status. A study on a greater cohort could highlight the benefits of UCSQ and determine the generalizability to other populations. Secondly, this study would include the general drawback of any retrospective study.

Using UCSQ, we were able to quantify UCS according to severity using external landmarks and variables. For future research, we can use this method and apply the external landmarks to 3D-photogrammetry, which is less invasive and not damaging (no radiation load, no need for sedation) for children. When 3D photogrammetry is used to perform UCSQ analysis, it can be used for monitoring skull shape and growth without radiation. Finally, the application of UCSQ will lead to accurate classification of the severity of UCS. Furthermore, UCSQ gives an actual visualization of the morphology of the skull shape; in future research, this method can provide insight in changes in skull shape due to (varying) surgical techniques in comparison to nonsurgical management. Based on the outcomes of skull shape following surgery, further research is necessary to implement UCSQ in surgical decision-making.

Utrecht Cranial Shape Quantifier is available to diagnose different types of craniosynostosis, additionally we are now able to use UCSQ to quantify UCS by using distinctive features of UCS (asymmetry ratio of frontal peak and ratio of gradient of legs of curve), it outperforms traditional methods and captures the whole skull shape.

Declaration of Conflicting Interests


The author(s) declared no potential conflicts of interest with respect to the research, authorship, and/or publication of this article.

Funding

The author(s) received no financial support for the research, authorship, and/or publication of this article.

ORCID iDs

Sophia A. J. Kronig, MD  <https://orcid.org/0000-0003-0239-0375>

Otto D. M. Kronig, MD  <https://orcid.org/0000-0002-2663-5448>

References

- Bruneteau RJ, Mulliken JB. Frontal plagiocephaly: synostotic, compensational, or deformational. *Plast Reconstr Surg.* 1992;89(1):21-31; discussion 32-23.
- Di Rocco C, Paternoster G, Caldarelli M, Massimi L, Tamburrini G. Anterior plagiocephaly: epidemiology, clinical findings, diagnosis, and classification. A review. *Childs Nerv Syst.* 2012;28(9):1413-1422.
- Di Rocco F, Arnaud E, Renier D. Evolution in the frequency of non-syndromic craniosynostosis. *J Neurosurg Pediatr.* 2009;4(1):21-25.
- Hansen M, Padwa BL, Scott RM, Stieg PE, Mulliken JB. Synostotic frontal plagiocephaly: anthropometric comparison of three techniques for surgical correction. *Plast Reconstr Surg.* 1997;100(6):1387-1395.
- Holowka MA, Reisner A, Giavedoni B, Lombardo JR, Coulter C. Plagiocephaly Severity Scale to aid in clinical treatment recommendations. *J Craniofac Surg.* 2017;28(3):717-722.
- Kolar JC. An epidemiological study of nonsyndromal craniosynostoses. *J Craniofac Surg.* 2011;22(1):47-49.
- Kronig OD, Kronig SA, Vrooman HA, Veenland JF, Jippes M, Boen T, Van Adrichem LN. Introducing a new method for classifying skull shape abnormalities related to craniosynostosis. *Eur J Pediatr.* 2020;179(10):1569-1577.
- Landis JR, Koch GG. The measurement of observer agreement for categorical data. *Biometrics.* 1977;33(1):159-174.
- Loveday BP, de Chalain TB. Active counter positioning or orthotic device to treat positional plagiocephaly? *J Craniofac Surg.* 2001;12(4):308-313.
- Persing JA. MOC-PS(SM) CME article: management considerations in the treatment of craniosynostosis. *Plast Reconstr Surg.* 2008;121(4 Suppl):1-11.
- Ratner B. The correlation coefficient: its values range between +1/-1, or do they? *J Target Meas Anal Market.* 2009;17(2):139-142.
- Selber J, Reid RR, Chike-Obi CJ, Sutton LN, Zackai EH, McDonald-McGinn D, Sonnad SS, Whitaker LA, Bartlett SB. The changing epidemiologic spectrum of single-suture synostoses. *Plast Reconstr Surg.* 2008;122(2):527-533.