

# Cerebrospinal Fluid Penetration of Daratumumab in Leptomeningeal Multiple Myeloma

Marina Zajec<sup>1,2</sup>, Kristine A. Frerichs<sup>3</sup>, Martijn M. van Duijn<sup>1</sup>, Inger S. Nijhof<sup>3</sup>, Claudia A.M. Stege<sup>3</sup>, Hervé Avet-Loiseau<sup>4</sup>, Theo M. Luiders<sup>1</sup>, Yolanda B. de Rijke<sup>2</sup>, Joannes F.M. Jacobs<sup>5</sup>, Niels W.C.J. van de Donk<sup>3</sup>

**Correspondence:** Niels W.C.J. van de Donk (e-mail: n.vandedonk@vumc.nl).

To the editor: Central nervous system (CNS) involvement in multiple myeloma (MM) is a rare manifestation of extramedullary disease with an incidence of approximately 1%,<sup>1</sup> which is characterized by the presence of leptomeningeal disease, or less frequently, solitary or multiple intraparenchymal plasmacytomas.<sup>1</sup> CNS disease is more common in patients with advanced MM.<sup>2,3</sup> Patients with high-risk cytogenetics, high levels of circulating MM cells and extramedullary disease at initial diagnosis, have an increased risk of developing CNS MM.<sup>2</sup> The outcome is very poor with an overall survival ranging from 2 to 7 months from the detection of CNS involvement.<sup>1,2,4</sup> To date, there is no standard treatment for CNS MM. Patients are frequently treated with intrathecal therapy and irradiation, but evidence supporting their efficacy is limited and only obtained from case reports and small case series.<sup>3</sup> Importantly, the majority of systemically administered anti-MM agents do not substantially cross the blood brain barrier (BBB), which protects the CNS from a multitude of drugs as well as circulating pathogens. However, several studies have shown that the immunomodulatory drugs (IMiDs) thalidomide and pomalidomide, as well as the novel proteasome inhibitor marizomib, can be detected in cerebrospinal fluid (CSF) after systemic administration.<sup>5-7</sup> To the best of our knowledge, no data is currently available on the ability of CD38-targeting monoclonal antibodies, such as daratumumab, to cross the BBB. To improve our understanding of the BBB penetration properties of daratumumab, as well as intrathecal M-protein production, we measured the concentration of daratumumab and M-protein in serum and CSF in a patient who presented with CNS MM

during daratumumab maintenance treatment, using a previously developed mass spectrometry (MS) assay.<sup>8</sup>

A 54-year old woman, diagnosed with MM in May 2016, presented with CNS MM in July 2018. At initial diagnosis, she had an IgG-lambda M-protein of 27 g/L, 60% plasma cells (PCs) in bone marrow (BM) biopsy, anemia (hemoglobin 6.8 mmol/L), fluorodeoxyglucose-positron emission tomography (FDG-PET)-positive bone lesions, a biopsy-confirmed extramedullary plasmacytoma in the right submandibular gland, and high-risk cytogenetic abnormalities (amplification 1q).<sup>9</sup> Magnetic resonance imaging (MRI) showed no signs of leptomeningeal involvement at diagnosis. She was enrolled in the CASSIOPEIA study (NCT02541383) and randomized to receive induction treatment with daratumumab, bortezomib, thalidomide and dexamethasone (D-VTd), followed by high-dose melphalan, autologous stem cell transplantation and 2 cycles of D-VTd consolidation, which resulted in a stringent complete remission (sCR) with minimal residual disease (MRD) negativity, as assessed by flow cytometry (detection limit  $10^{-5}$ ). After consolidation, she received daratumumab maintenance treatment (16 mg/kg every 8 weeks), which was initiated in April 2017. In July 2018, 15 months after the start of daratumumab maintenance, she presented with neurological symptoms, which included pain and fasciculations in the right leg, loss of muscle strength in lower legs and paresthesias in both hands. In addition, she had painful nodular lesions in both upper arms, which appeared to be biopsy-confirmed extramedullary plasmacytomas of ulnar nerves and right plexus brachialis. Contrast-enhanced craniospinal MRI showed multiple enhancing leptomeningeal nodules. CSF analysis revealed leukocytosis ( $86 \times 10^6/L$ ) and an elevated total protein level (6.4 g/L). Microscopic analysis of the CSF showed the presence of PCs and immunophenotypic analysis confirmed the presence of lambda-positive, CD19<sup>+</sup>CD56<sup>+</sup> PCs in the CSF (85% of all nucleated cells). Serum electrophoresis combined with immunofixation electrophoresis showed the recurrence of the IgG-lambda M-protein (2.3 g/L; Fig. 1A). The M-protein concentration in the CSF was 1.1 g/L (Fig. 1B). The electrophoretic methods were not sensitive enough to detect daratumumab in either serum or CSF.<sup>10,11</sup> Additional staging with FDG-PET scan and BM aspiration showed no signs of systemic MM progression.

To evaluate the CSF penetration of daratumumab, we investigated daratumumab concentrations in serum and CSF using the recently developed MS method that enables sensitive monoclonal antibody measurement well beyond electrophoretic methods.<sup>8</sup> At the time of relapse, we obtained 3 paired serum and

MZ and KAF shared first authorship and JFM and NWCJD shared last authorship.

<sup>1</sup>Erasmus MC University Medical Center, Department of Neurology, Rotterdam, The Netherlands

<sup>2</sup>Erasmus MC University Medical Center, Department of Clinical Chemistry, Rotterdam, The Netherlands

<sup>3</sup>Amsterdam UMC, Vrije Universiteit Amsterdam, Department of Hematology, Cancer Center Amsterdam, Amsterdam, The Netherlands

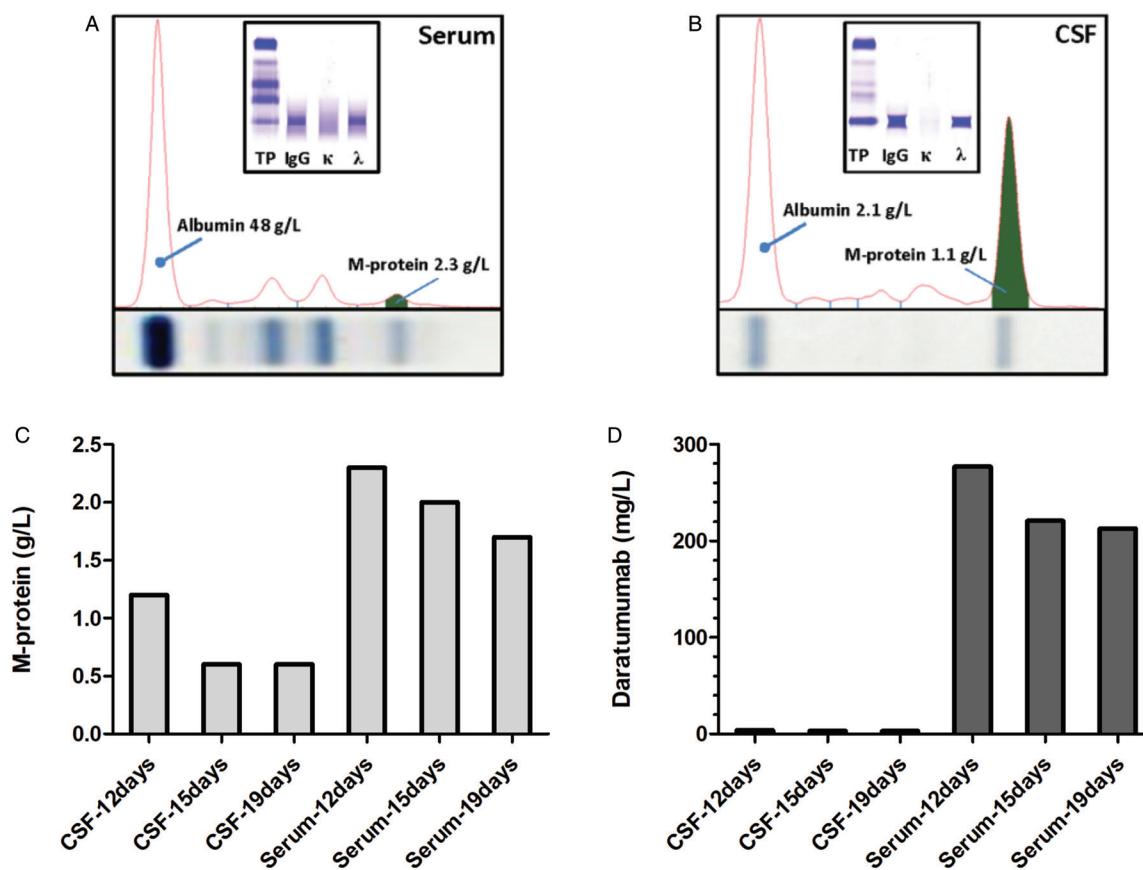
<sup>4</sup>Institute Universitaire du Cancer de Toulouse Oncopole, Unite de Genomique du Myeloma, Toulouse, France

<sup>5</sup>Radboud University Medical Center, Department of Laboratory Medicine, Nijmegen, The Netherlands

Copyright © 2020 the Author(s). Published by Wolters Kluwer Health, Inc. on behalf of the European Hematology Association. This is an open access article distributed under the Creative Commons Attribution-NoDerivatives License 4.0, which allows for redistribution, commercial and non-commercial, as long as it is passed along unchanged and in whole, with credit to the author.

HemaSphere (2020) 4:4(e413). <http://dx.doi.org/10.1097/HHS9.0000000000000413>

Received: 24 January 2020 / Accepted: 6 May 2020



**Figure 1. Protein electrophoresis and mass spectrometry of serum and cerebrospinal fluid.** (A) Serum protein electrophoresis with an M-protein of 2.3 g/L, shown in green. Immunofixation electrophoresis (insert) confirms an IgG-lambda M-protein. (B) Cerebrospinal fluid (CSF) protein electrophoresis with an M-protein of 1.1 g/L, shown in green. Immunofixation electrophoresis (insert) confirms an IgG-lambda M-protein. The electrophoretic methods were not sensitive enough to identify the IgG-kappa monoclonal antibody daratumumab in either serum or CSF. (C) M-protein concentration in CSF and serum, measured using mass spectrometry. (D) Daratumumab concentration in CSF and serum, measured using mass spectrometry. Mass spectrometry (C-D) was performed on 3 paired serum and CSF samples obtained 12, 15, and 19 days after the last daratumumab infusion.

CSF samples: 12, 15, and 19 days after the last daratumumab infusion. All serum and CSF samples were analyzed by MS to quantify daratumumab, as well as M-protein levels in one multiplexed assay (see Supplementary Methods for more details). To verify MS-specificity of daratumumab and the M-protein measurements, additional matched control serum and CSF samples were obtained from 5 patients suspected of multiple sclerosis and 4 patients suspected of CNS infection. None of these control patients were diagnosed with MM nor did they receive treatment.

Both M-protein and daratumumab were detected in patient's serum and CSF samples, while all 9 control samples were negative. The M-protein concentration, calculated as an average of heavy (IgG) and light (lambda) chain M-protein concentrations, was 2.3, 2.0 and 1.7 g/L in serum samples obtained at day 12, 15 and 19, respectively; and 1.1, 0.6, and 0.6 g/L in CSF samples (Fig. 1C). The daratumumab concentration was 277, 221, and 213 mg/L in these serum samples at day 12, 15, and 19, respectively; and 4, 3, and 3 mg/L in the CSF samples (Fig. 1D). Taken into account daratumumab pharmacokinetics, higher daratumumab-concentrations would have been measured if samples were obtained during more intense weekly daratumumab-infusions.<sup>12</sup> The M-protein index was calculated using the formula:  $(\text{CSF M-protein} \times \text{serum albumin}) / (\text{CSF albumin} \times \text{serum M-protein})$ . Based on these MS data, the M-protein index was 11.9, which indicates

intrathecal M-protein production (reference IgG-index  $< 0.85$ ).<sup>13</sup> Using MS it was also possible to calculate the daratumumab index  $(\text{CSF daratumumab} \times \text{serum albumin}) / (\text{CSF albumin} \times \text{serum daratumumab})$ , which was calculated at three independent sampling time-points and ranged from 0.33 to 0.37. It can therefore be concluded that daratumumab is able to penetrate the BBB, although with a low efficiency, that resembles normal human polyclonal IgG (normal IgG index  $< 0.85$ ).<sup>13</sup>

We concluded that the patient's neurological symptoms were due to progressive MM with extramedullary disease in CSF and peripheral nerves. In normal brain parenchyma, the BBB limits passive entry of antibodies. We here show that the CNS concentration of daratumumab was 71 times lower compared to the serum concentration. Optimal therapeutic serum levels of daratumumab exceed 100 mg/L,<sup>12</sup> indicating that the insufficient penetration of the BBB, resulting in subtherapeutic CSF levels, may have contributed to the development of leptomeningeal disease in this patient. However, in case of underlying inflammatory or neoplastic disease, the BBB may become more permeable for antibodies or other serum proteins.<sup>14</sup> Therefore, we cannot exclude that deterioration of the BBB may result in more efficient penetration of the BBB and higher daratumumab levels in other patients with CNS MM. Intrathecal administration may lead to higher CSF levels, but safety and efficacy of intrathecal therapy with daratumumab is currently unknown.

Treatment of patients with CNS MM should consist of a systemic agent that crosses the BBB, in combination with local therapy.<sup>3</sup> In this respect, an IMiD-based regimen with concomitant multi-dosing intrathecal therapy seems to be most active.<sup>1,2,4</sup> In addition, high-dose therapy followed by autologous stem cell transplantation may also contribute to improved disease control.<sup>3</sup> To date, there is one case report describing systemic treatment with pomalidomide followed by daratumumab, combined with craniospinal radiotherapy and intrathecal chemotherapy, resulting in a durable response in a patient with CNS MM. However, the relative contribution of daratumumab in achieving disease control is unknown, and the authors did not assess CSF concentrations of daratumumab.<sup>15</sup>

Our patient was treated with systemic pomalidomide, which has been shown to cross the BBB,<sup>7</sup> combined with dexamethasone, and with concomitant twice-weekly intrathecal methotrexate and prednisone, which resulted in a decrease, but not complete elimination of clonal PCs in CSF. Therefore, after 14 doses, methotrexate was replaced by cytarabine, and after 5 administrations, immunophenotyping revealed complete CSF clearance. In addition, radiation therapy (8Gy) was administered on the extramedullary MM lesions in both upper arms. After achieving good tumor control, 6 months after diagnosis of disease progression (December 2018), she received a second autologous stem cell transplantation as consolidation therapy, with busulphan and high-dose cyclophosphamide conditioning, followed by maintenance treatment with monthly intrathecal cytarabine-prednisone administrations. Although serum immunofixation remained positive, there was complete CSF clearance of PCs and complete resolution of the extramedullary lesions. Her neurological symptoms improved. However, nine months after the second transplant (August 2019), she developed recurrence of leptomeningeal disease.

Despite the markedly improved outcome of MM patients over the last few years, outcome of CNS MM remains poor.<sup>1,2,4</sup> Although thalidomide and pomalidomide have been shown to cross the BBB, most other approved anti-MM agents do not substantially penetrate the CSF. Our analysis of paired serum and CSF samples and the low daratumumab index indicate that the penetrance of systemic daratumumab into the CNS is limited, which may affect the therapeutic value for the treatment of MM CNS involvement. The novel proteasome inhibitor marizomib can be effective in CNS MM, but has not been approved for the treatment of MM.<sup>5</sup> Altogether, this indicates that clinical trials evaluating new drugs in CNS MM are urgently needed. These trials should incorporate assessments of drug levels in serum and CSF to gain insights in the ability of the investigational drug to cross the BBB, which is a prerequisite for clinical activity in CNS MM. In this respect, MS may be useful to measure levels of protein-based biotherapeutics, such as monoclonal antibodies, in both CSF and serum, combined with MS measurements of the M-protein to further monitor minimal residual disease in both CSF and serum.

## Sources of Funding

JFMJ received a research grant from the Dutch Cancer Society (#10817). NWCJvdD received research support from Janssen Research and Development.

## Disclosures

NWCJvdD and ISN participated in advisory boards organized by Janssen Pharmaceuticals. The other authors report no conflicts.

## References

- Chen CI, Masih-Khan E, Jiang H, et al. Central nervous system involvement with multiple myeloma: long term survival can be achieved with radiation, intrathecal chemotherapy, and immunomodulatory agents. *Br J Haematol*. 2013;162:483–488.
- Jurczyszyn A, Grzasko N, Gozzetti A, et al. Central nervous system involvement by multiple myeloma: A multi-institutional retrospective study of 172 patients in daily clinical practice. *Am J Haematol*. 2016;91:575–580.
- Touzeau C, Moreau P. How I treat extramedullary myeloma. *Blood*. 2016;127:971.
- Lee D, Kalff A, Low M, et al. Central nervous system multiple myeloma – potential roles for intrathecal therapy and measurement of cerebrospinal fluid light chains. *Br J Haematol*. 2013;162:371–375.
- Williamson MJ, Blank JL, Bruzzese FJ, et al. Comparison of biochemical and biological effects of ML858 (salinosporamide A) and bortezomib. *Mol Cancer Ther*. 2006;5:3052.
- Yutaka H, Mariko Y, Shinichiro O, et al. Thalidomide for the treatment of leptomeningeal multiple myeloma. *Eur J Haematol*. 2006;76:358–359.
- Mussetti A, Dalto S, Montefusco V. Effective treatment of pomalidomide in central nervous system myelomatosis. *Leuk Lymphoma*. 2013;54:864–866.
- Zajec M, Jacobs JFM, Groenen PJTA, et al. Development of a targeted mass-spectrometry serum assay to quantify M-protein in the presence of therapeutic monoclonal antibodies. *J Proteome Res*. 2018;17:1326–1333.
- Sonneveld P, Avet-Loiseau H, Lonial S, et al. Treatment of multiple myeloma with high-risk cytogenetics: a consensus of the International Myeloma Working Group. *Blood*. 2016;127:2955.
- McCudden C, Axel Amy E, Slaets D, et al. Monitoring multiple myeloma patients treated with daratumumab: teasing out monoclonal antibody interference. *Clin Chem Lab Med*. 2016;54:1095–1104.
- van de Donk Niels WCJ, Otten Henry G, El Haddad O, et al. Interference of daratumumab in monitoring multiple myeloma patients using serum immunofixation electrophoresis can be abrogated using the daratumumab IFE reflex assay (DIRA). *Clin Chem Lab Med*. 2016;54:1105–1109.
- Xu XS, Yan X, Puchalski T, et al. Clinical implications of complex pharmacokinetics for daratumumab dose regimen in patients with relapsed/refractory multiple myeloma. *Clin Pharmacol Ther*. 2017;101:721–724.
- Link H, Tibbling G. Principles of albumin and IgG analyses in neurological disorders. III. Evaluation of IgG synthesis within the central nervous system in multiple sclerosis. *Scand J Clin Lab Invest*. 1977;37:397–401.
- Lampson LA. Editorial: immunotherapy for tumor in the brain: insights from-and for-other tumor sites. *Front Oncol*. 2018;8:128.
- Elhassadi E, Murphy M, Hacking D, et al. Durable treatment response of relapsing CNS plasmacytoma using intrathecal chemotherapy, radiotherapy, and Daratumumab. *Clin Case Rep*. 2018;6:723–728.