



# Watchful waiting for small non-functional pancreatic neuroendocrine tumours: nationwide prospective cohort study (PANDORA)

C. M. Heidsma <sup>1</sup>, A. F. Engelsman<sup>2</sup>, S. van Dieren<sup>1</sup>, M. W. J. Stommel<sup>3</sup>, I. de Hingh<sup>4</sup>, M. Vriens <sup>5</sup>, L. Hol<sup>6</sup>, S. Festen<sup>7</sup>, L. Mekenkamp<sup>8</sup>, F. J. H. Hoogwater<sup>9</sup>, F. Daams<sup>2</sup>, H.-J. Klümpen<sup>10</sup>, M. G. Besselink<sup>1</sup>, C. H. van Eijck<sup>11</sup> and E. J. Nieveen van Dijkum<sup>1\*</sup>, on behalf of the Dutch Pancreatic Cancer Group

<sup>1</sup>Department of Surgery, Cancer Centre Amsterdam, Amsterdam UMC, University of Amsterdam, Amsterdam, the Netherlands

<sup>2</sup>Department of Surgery, Cancer Centre Amsterdam, Amsterdam UMC, Vrije Universiteit, Amsterdam, the Netherlands

<sup>3</sup>Department of Surgery, Radboud University Medical Centre, Nijmegen, the Netherlands

<sup>4</sup>Department of Surgery, Catharina Hospital, Eindhoven, the Netherlands

<sup>5</sup>Department of Surgery, University Medical Centre Utrecht, Utrecht, the Netherlands

<sup>6</sup>Department of Gastroenterology and Metabolism, Maasstad Hospital, Rotterdam, the Netherlands

<sup>7</sup>Department of Surgery, Onze Lieve Vrouwe Gasthuis, Amsterdam, the Netherlands

<sup>8</sup>Department of Medical Oncology, Medisch Spectrum Twente, Enschede, the Netherlands

<sup>9</sup>Department of Surgery, University Medical Centre Groningen, Groningen, the Netherlands

<sup>10</sup>Department of Medical Oncology, Cancer Centre Amsterdam, Amsterdam UMC, University of Amsterdam, Amsterdam, the Netherlands

<sup>11</sup>Department of Surgery, Erasmus Medical Centre, Rotterdam, the Netherlands

\*Correspondence to: Department of Surgery, Cancer Centre Amsterdam, Amsterdam UMC, University of Amsterdam, Meibergdreef 9, 1105 AZ Amsterdam, the Netherlands (e-mail: e.j.nieveenvandijkum@amsterdamumc.nl)

## Introduction

Non-functional pancreatic neuroendocrine tumours (NF-pNETs) are rare neoplasms, often detected incidentally. The prognosis varies and is largely dependent on the Ki-67 proliferation index, presence of a genetic syndrome, lymph node involvement, and tumour size<sup>1–4</sup>. Resection of pancreatic lesions is associated with significant morbidity, and may include long-term complications such as new-onset diabetes and exocrine pancreatic insufficiency<sup>5,6</sup>. Clearly, the potential survival benefit obtained with surgery needs to outweigh the morbidity associated with pancreatic surgery. This explains the current controversy regarding small (2 cm or less) asymptomatic NF-pNETs, for which some advocate surgery and others suggest a conservative approach<sup>7–11</sup>.

Based on retrospective data, guidelines advise watchful waiting for NF-pNETs of 2 cm or smaller, but provide no clear recommendation on the required follow-up<sup>4,12</sup>. Therefore, the objective of this study was to prospectively evaluate disease-related outcomes and quality of life (QoL) after implementation of a nationwide, watchful-waiting programme for NF-pNETs no larger than 2 cm. The study also sought to evaluate the feasibility of the proposed follow-up protocol, as well as adherence to the protocol in participating centres.

## Methods

This was an interim analysis of the multicentre prospective PANDORA study of the Dutch Pancreatic Cancer Group. Full details of the study design, methods employed, and statistical analysis can be found in *Appendix S1*. All patients with sporadic,

asymptomatic NF-pNETs of 2 cm or smaller were included if they met the eligibility criteria, in particular absence of nodal and/or distant metastases. The trial was registered in the Netherlands Trial Register (NL6510).

Patients were enrolled into a watchful-waiting protocol to monitor tumour progression (*Fig. 1*). Surgical resection was recommended if patients developed symptoms, tumour growth exceeding 0.5 cm/year, total tumour size greater 2 cm, pathological lymph node enlargement, vascular involvement or infiltration into surrounding organs, or pancreatic duct dilatation, or if the patient expressed a strong preference for operation.

## Results

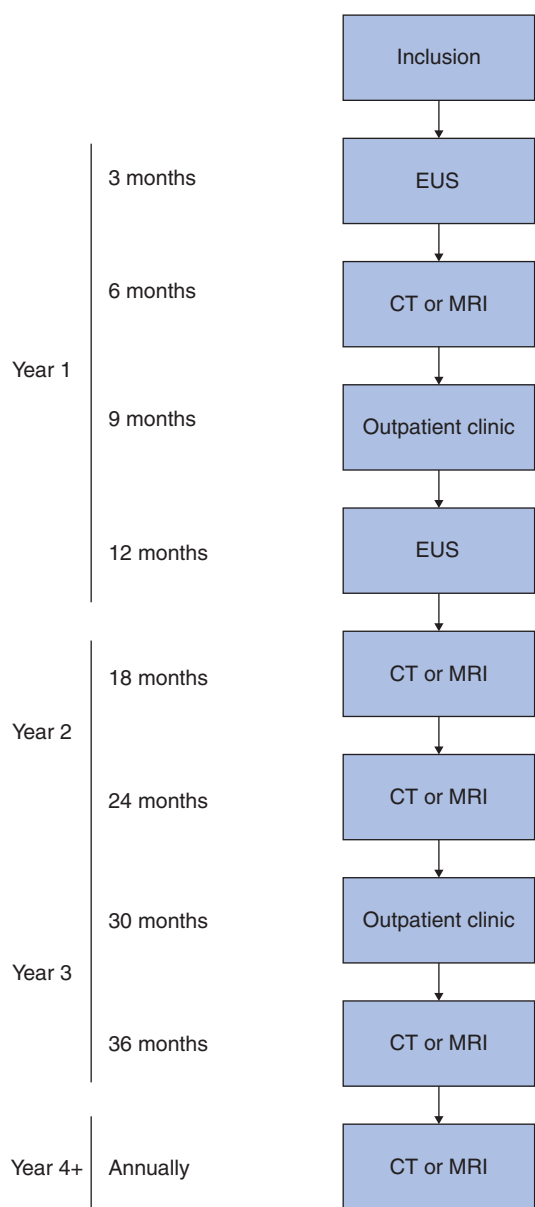
Between 1 January 2017 and 29 February 2020, a total of 76 patients with a NF-pNET no larger than 2 cm were included. Baseline characteristics are summarized in *Table S1*. During a median follow-up of 17 (i.q.r. 8–35) months, 68 participants (89 per cent) had no signs of tumour progression. Eight patients (11 per cent) showed tumour progression exceeding 0.5 cm/year, and two also had a final tumour size of more than 2.0 cm. No other tumours larger than 2.0 cm were noted, and 21 patients (28 per cent) had tumours smaller than 1.0 cm. Characteristics of patients with progression are shown in *Table 1* and *Table S1*.

Overall, six patients (8 per cent) underwent surgery during follow-up (*Table S2*). Two patients had surgery because of significant tumour growth, detected after 3 and 10 months of follow-up. One patient had tumour progression of 0.8 cm in 1 year (from 1.8 to 2.6 cm). Gallium-68 DOTATATE PET-CT showed two enlarged lymph

Received: November 25, 2020. Revised: January 21, 2021. Accepted: February 15, 2021

© The Author(s) 2021. Published by Oxford University Press on behalf of BJS Society Ltd.

This is an Open Access article distributed under the terms of the Creative Commons Attribution Non-Commercial License (<http://creativecommons.org/licenses/by-nc/4.0/>), which permits non-commercial re-use, distribution, and reproduction in any medium, provided the original work is properly cited. For commercial re-use, please contact [journals.permissions@oup.com](mailto:journals.permissions@oup.com)



**Fig. 1** Follow-up protocol for watchful waiting of patients with a non-functional pancreatic neuroendocrine tumour of 2 cm or smaller included in the PANDORA study

EUS, endoscopic ultrasonography.

nodes (aortocaval and para-aortal). During surgery, one unexpected peritoneal deposit was identified and the patient underwent laparoscopic enucleation of the primary tumour with lymphadenectomy and removal of the peritoneal lesion. The final histopathological diagnosis was a pNET of 2.0 cm, with a Ki-67 index of 5–10 per cent, two positive lymph nodes and, indeed, peritoneal metastasis. Two new lymph nodes were detected 11 months after surgery, for which somatostatin analogue therapy was started.

The second patient showed tumour progression exceeding 0.5 cm (from 1.0 to 1.7 cm) within 3 months of follow-up and as a result underwent surgery. The final histopathological diagnosis showed a pNET of 1.7 cm, R0 resection, with a Ki-67 index of less than 3 per cent, and 0 of 17 positive lymph nodes. The patient is currently asymptomatic at 11 months' follow-up without signs of disease progression.

**Table 1** Follow-up of patients with progressive non-functional pancreatic neuroendocrine tumours

	No. of patients* (n = 8)
<b>Clinical characteristics</b>	
Tumour size at last follow-up (cm) <sup>†</sup>	1.2 (0.7)
Time to progression (months) <sup>‡</sup>	17 (13–30)
Duration of follow-up (months) <sup>‡</sup>	24 (9–61)
Developed symptoms	0
Developed metastases	
None	7
Lymph node + peritoneal	1
<b>Surgical resection</b>	
Type of surgery	
Spleen-preserving distal pancreatectomy	1
Enucleation	1
Surgical approach	
Open	1
Laparoscopic	0
Clavien–Dindo ≥ grade III complications	1
<b>Postoperative histopathology</b>	
Positive lymph nodes	1
Ki-67 index (%)	
< 3	1
3–20	1
> 20	0

\*Unless indicated otherwise; values are <sup>†</sup>s.d. and <sup>‡</sup>median (i.q.r.).

Three patients had a pNET resected despite lacking an indication according to the study protocol. Of these, two underwent spleen-resecting distal pancreatectomy, citing fear of disease progression as the predominant reason for requesting surgery. One patient underwent laparoscopic spleen-resecting distal pancreatectomy because the surgeon did not support the decision for watchful waiting and advocated tumour resection. All three patients had a pNET on final histopathology.

A fourth patient had a pNET enucleated owing to uncertainty regarding the pNET diagnosis on delayed (contrast-enhanced) endoscopic ultrasonography (EUS) at 8 months' follow-up. The final histopathological report showed an intravascular pyogenic granuloma, but no pNET.

In total, four patients died, all from non-pNET-related causes.

Although the study protocol recommended confirmation of the diagnosis to be by at least 2 different imaging modalities, only one type of imaging was used at the time of diagnosis in 19 patients (25 per cent). Thirty-two patients (42 per cent) had two, and 25 (33 per cent) had three or more imaging modalities to confirm the diagnosis. Only 17 patients (22 per cent) underwent EUS at the suggested 3-month time point. Instead, patients opted for CT (31, 41 per cent), MRI (16, 21 per cent), or no imaging at all (12, 16 per cent). At 6 and 12 months, 21 (28 per cent) and 11 (15 per cent) patients did not undergo any imaging.

QoL scores on the European Organisation for Research and Treatment of Cancer QLQ-C30 questionnaire were statistically significantly worse at baseline for the study population compared with the mean of the reference population regarding emotional functioning (83.9 versus 89.0;  $P=0.042$ ), nausea and vomiting (6.9 versus 2.7;  $P=0.037$ ), dyspnoea (18.8 versus 7.1;  $P=0.004$ ), and insomnia (22.9 versus 14.0;  $P=0.046$ ) (Fig. S1).

## Discussion

This multicentre prospective cohort study, which evaluated watchful waiting for NF-pNETs no larger than 2 cm, found that

short-term follow-up is both safe and feasible. A small proportion of patients showed tumour progression. Application of a watchful-waiting protocol successfully prevented surgery in over 9 of 10 patients. Furthermore, heterogeneity in pNET management, despite use of a study protocol, was observed in this study, along with poor QoL at the time of diagnosis.

The present finding of slow tumour progression supports previous studies<sup>9,11,13–17</sup> of NF-pNETs of 2 cm or smaller, which advised wait-and-see in certain patients. In contrast, other authors<sup>18</sup> have recommended upfront surgery for all pNETs, as even small lesions may have malignant characteristics that could impair survival. Importantly, patients with malignant tumour features were excluded from the present study, and, even when significant tumour growth occurred, six of eight patients with tumour progression refused surgery and opted to continue watchful waiting. Collectively, these results indicate that, under strict criteria, patients with a NF-pNET no larger than 2 cm can safely be treated conservatively.

In turn, it is clear that implementation of this novel watchful-waiting approach to pNET is challenging<sup>19–21</sup>. As is common in investigator-driven multicentre studies, not all centres adhered strictly to the follow-up protocol. EUS was included at 3 and 12 months of follow-up to reduce the number of scans per patient, and so that multiple imaging modalities could confirm tumour size stability. It also provided an immediate opportunity to perform fine-needle aspiration (FNA) if there was doubt regarding tumour origin. However, EUS was considered a high burden for patients, and was frequently rejected by both patients and physicians. In addition, not all patients underwent the suggested CT or MRI at 6 and 12 months' follow-up, as the interval after diagnosis was deemed too short by some physicians. A reduction in the follow-up protocol has been made by the study group, whereby the EUS examination at 3 months is suggested only for patients who have not undergone EUS previously. In future studies, EUS FNA could also be used to examine other tumour characteristics.

A potential pitfall of a wait-and-see approach is late detection of disease spread. This was the case in one patient in the present study who underwent surgery for rapid tumour progression, in whom peritoneal metastases were diagnosed during surgery. The sensitivity of CT, MRI, and DOTATATE PET-CT is known to be low for (small) peritoneal metastases<sup>22,23</sup>. However, the optimal timing of adjuvant treatment for metastases in pNET is unknown, and treatment in the absence of radiologically measurable disease is usually not recommended. To truly evaluate the oncological safety of watchful waiting of pNET, longer follow-up is necessary. Nevertheless, it is important to report these short-term findings, because they give insight into the obstacles of implementation of new guidelines, as well as the pitfalls regarding treatment indication and sensitivity of imaging techniques. QoL was poorer at baseline in the study population than that of the reference population, but the results are too premature for conclusions to be drawn on the exact reason for this difference.

The authors further recommend improved patient support during the first years of watchful waiting. The PANDORA study is continuing to evaluate long-term outcomes of a wait-and-see approach for NF-pNETs no larger than 2 cm.

**Disclosure.** The authors declare no conflict of interest.

## Supplementary material

Supplementary material is available at BJS online.

## References

- Genç CG, Jilesen AP, Partelli S, Falconi M, Muffatti F, van Kemenade FJ *et al*. A new scoring system to predict recurrent disease in grade 1 and 2 nonfunctional pancreatic neuroendocrine tumors. *Ann Surg* 2018;**267**:1148–1154
- Merath K, Bagante F, Beal EW, Lopez-Aguilar AG, Poultsides G, Makris E *et al*. Nomogram predicting the risk of recurrence after curative-intent resection of primary non-metastatic gastrointestinal neuroendocrine tumors: an analysis of the U.S. Neuroendocrine Tumor Study Group. *J Surg Oncol* 2018;**117**: 868–878
- Billimoria KY, Talamonti MS, Tomlinson JS, Stewart AK, Winchester DP, Ko CY *et al*. Prognostic score predicting survival after resection of pancreatic neuroendocrine tumors: analysis of 3851 patients. *Ann Surg* 2008;**247**:490–500
- Falconi M, Eriksson B, Kaltsas G, Bartsch DK, Capdevila J, Caplin M *et al*. ENETS consensus guidelines update for the management of patients with functional pancreatic neuroendocrine tumors and non-functional pancreatic neuroendocrine tumors. *Neuroendocrinology* 2016;**103**:153–171
- De Rooij T, Van Hilst J, Van Santvoort H, Boerma D, Van Den Boezem P, Daams F *et al*. Minimally invasive versus open distal pancreatectomy (LEOPARD): a multicenter patient-blinded randomized controlled trial. *Ann Surg* 2019;**269**:2–9
- van Hilst J, De Rooij T, Bosscha K, Brinkman DJ, Van Dieren S, Dijkgraaf MG *et al*. Laparoscopic versus open pancreateoduodenectomy for pancreatic or periampullary tumours (LEOPARD-2): a multicentre, patient-blinded, randomised controlled phase 2/3 trial. *Lancet Gastroenterol Hepatol* 2019;**4**:199–207
- Sharpe SM, In H, Winchester DJ, Talamonti MS, Baker MS. Surgical resection provides an overall survival benefit for patients with small pancreatic neuroendocrine tumors. *J Gastrointest Surg* 2015;**19**:117–123
- Gratian L, Pura J, Dinan M, Roman S, Reed S, Sosa JA. Impact of extent of surgery on survival in patients with small nonfunctional pancreatic neuroendocrine tumors in the United States. *Ann Surg Oncol* 2014;**21**:3515–3521
- Gaujoux S, Partelli S, Maire F, D'Onofrio M, Larroque B, Tamburrino D *et al*. Observational study of natural history of small sporadic nonfunctioning pancreatic neuroendocrine tumors. *J Clin Endocrinol Metab* 2013;**98**:4784–4789
- Partelli S, Cirocchi R, Crippa S, Cardinali L, Fendrich V, Bartsch DK *et al*. Systematic review of active surveillance versus surgical management of asymptomatic small non-functioning pancreatic neuroendocrine neoplasms. *Br J Surg* 2017;**104**:34–41
- Sallinen V, Haglund C, Seppanen H. Outcomes of resected non-functional pancreatic neuroendocrine tumors: do size and symptoms matter? *Surgery* 2015;**158**:1556–1563
- Howe JR, Merchant NB, Conrad C, Keutgen XM, Hallet J, Drebin JA *et al*. The North American Neuroendocrine Tumor Society consensus paper on the surgical management of pancreatic neuroendocrine tumors. *Pancreas* 2020;**49**:1–33
- Lee LC, Grant CS, Salomao DR, Fletcher JG, Takahashi N, Fidler JL *et al*. Small, nonfunctioning, asymptomatic pancreatic neuroendocrine tumors (pNETs): role for nonoperative management. *Surgery* 2012;**152**:965–974
- Sadot E, Reidy-Lagunes DL, Tang LH, Do RK, Gonen M, D'Angelica MI *et al*. Observation versus resection for small asymptomatic pancreatic neuroendocrine tumors: a matched case-control study. *Ann Surg Oncol* 2016;**23**:1361–1370
- Partelli S, Gaujoux S, Boninsegna L, Cherif R, Crippa S, Couvelard A *et al*. Pattern and clinical predictors of lymph node

- involvement in nonfunctioning pancreatic neuroendocrine tumors (NF-PanNETs). *JAMA Surg* 2013;**148**:932–939
16. Rosenberg AM, Friedmann P, Del Rivero J, Libutti SK, Laird AM. Resection versus expectant management of small incidentally discovered nonfunctional pancreatic neuroendocrine tumors. *Surgery* 2016;**159**:302–309
  17. Sallinen VJ, Le Large TYS, Tieftrunk E, Galeev S, Kovalenko Z, Haugvik SP et al. Prognosis of sporadic resected small ( $\leq 2$  cm) nonfunctional pancreatic neuroendocrine tumors—a multi-institutional study. *HPB (Oxford)* 2018;**20**:251–259
  18. Ricci C, Casadei R, Taffurelli G, Pacilio CA, Campana D, Ambrosini V et al. Sporadic small ( $\leq 20$  mm) nonfunctioning pancreatic neuroendocrine neoplasm: is the risk of malignancy negligible when adopting a more conservative strategy? A systematic review and meta-analysis. *Ann Surg Oncol* 2017;**24**:2603–2610
  19. Mintziras I, Keck T, Werner J, Fichtner-Feigl S, Wittel U, Senninger N et al. Implementation of current ENETS guidelines for surgery of small ( $\leq 2$  cm) pancreatic neuroendocrine neoplasms in the German surgical community: an analysis of the prospective DGAV StuDoQPancreas Registry. *World J Surg* 2019;**43**:175–182
  20. Partelli S, Mazza M, Andreasi V, Muffatti F, Crippa S, Tamburrino D et al. Management of small asymptomatic non-functioning pancreatic neuroendocrine tumors: limitations to apply guidelines into real life. *Surgery* 2019;**166**:157–163
  21. Mansour JC, Chavin K, Morris-Stiff G, Warner SG, Cardona K, Fong ZV et al. Management of asymptomatic, well-differentiated PNETs: results of the Delphi consensus process of the Americas Hepato-Pancreato-Biliary Association. *HPB (Oxford)* 2019;**21**:515–523
  22. Bastiaenen VP, Klaver CEL, Kok NFM, de Wilt JHW, de Hingh I, Aalbers AGJ et al. Second and third look laparoscopy in pT4 colon cancer patients for early detection of peritoneal metastases; the COLOPEC 2 randomized multicentre trial. *BMC Cancer* 2019;**19**:254
  23. Komek H, Ansal Balci T, Can C. Efficacy of galium-68 DOTATATE PET/CT in the detection of metastasis rate of well-differentiated gastroenteropancreatic neuroendocrine tumors. *Asia Ocean J Nucl Med Biol* 2019;**7**:141–148