

Transcatheter Aortic Valve Implantation: The Evolving Role of the Radiologist in 2021

Transkatheter-Aortenklappenimplantation: Die neue Rolle des Radiologen im Jahr 2021

Authors

Rodrigo Salgado^{1,2}, Haroun El Addouli¹, Ricardo P J Budde³

Affiliations

- 1 Radiology, UZA, Edegem, Belgium
- 2 Radiology, Holy Heart Hospital Lier, Belgium
- 3 Radiology and Nuclear Medicine, Erasmus MC, Rotterdam, Netherlands

Key words

TAVI, aortic valve, aortic valve stenosis, TAVR, CT angiography

received 29.11.2020

accepted 08.04.2021

published online 2021

Bibliography

Fortschr Röntgenstr 2021; 193: 1411–1425

DOI 10.1055/a-1645-1873

ISSN 1438-9029

© 2021. Thieme. All rights reserved.

Georg Thieme Verlag KG, Rüdigerstraße 14, 70469 Stuttgart, Germany

Correspondence

Dr. Rodrigo Salgado

Radiology, Antwerp University Hospital, Wilrijkstraat 10, 2650 Edegem, Belgium

Tel.: +32 38 21 44 98

rodrigo.salgado@uza.be

ZUSAMMENFASSUNG

Hintergrund Die Transkatheter-Aortenklappenimplantation (TAVI) hat sich weltweit als alternative therapeutische Option bei Patienten mit schwerer Aortenklappenstenose durchgesetzt, bei denen ein Aortenklappenersatz durch offene chirurgische Operation zu risikobehaftet wäre. Bei dieser transformativen Technik nimmt der Radiologe eine Schlüsselposition ein, indem er präprozedural potenzielle Kandidaten beurteilt und wichtige anatomische Informationen liefert, die für die Eignung des Patienten und die Sicherheit des Eingriffs notwendig sind. Neuere Studien zeigen auch ermutigende Ergebnisse hinsichtlich einer Ausweitung der Indikation auf Patienten mit sichereren Risikoprofilen.

Methode Die Übersichtsarbeit basiert auf einer PubMed-Literaturrecherche von 2010–2020 mit den Suchbegriffen „transcatheter heart valve“, „TAVI“, „TAVR“, „CT“, „imaging“,

„MR“ verbunden mit persönlichen Kommentaren basierend auf der Erfahrung des Verfassers.

Ergebnisse und Schlussfolgerung Die CT spielt eine herausragende Rolle in der präprozeduralen Aufarbeitung und liefert als echte 3D-Bildgebungsmodalität eine optimale Visualisierung der komplexen Anatomie der Aortenwurzel bei gleichzeitiger Beurteilung der Durchgängigkeit der verschiedenen Zugänge. Somit ist der Beitrag der CT entscheidend für die Feststellung der Eignung des Patienten und für die Sicherheit des Eingriffs. Diese Informationen ergänzen die Beiträge der anderen bildgebenden Verfahren und sind ein wichtiges Element der Diskussionen des Herzklappen-Teams. Die Kenntnis des Eingriffs und seiner Charakteristika ist notwendig, um einen umfassenden und vollständigen Bericht zu erstellen. Während die Rolle der CT in der präprozeduralen Evaluation gut etabliert ist, sind der Beitrag von CT und MR und die klinische Bedeutung ihrer Befunde in der routinemäßigen Nachuntersuchung nach dem Eingriff weniger eindeutig und werden derzeit intensiv untersucht. Es bleiben wichtige Fragen offen, einschließlich des Auftretens und der Bedeutung von subklinischen Klappenthrombosen, Endokarditis der Herzklappenprothese und langfristiger struktureller Klappen-degeneration.

Kernaussagen:

- Die CT spielt eine entscheidende Rolle bei der Beurteilung von Kandidaten für Transkatheter-Herzklappen.
- Die Bewertung muss die Dimensionen der Aortenwurzel und der Zugänge umfassen.
- Die genaue Rolle von CT und MR nach dem Eingriff ist noch ungeklärt.

ABSTRACT

Background Transcatheter aortic valve implantation (TAVI) has gained worldwide acceptance and implementation as an alternative therapeutic option in patients with severe aortic valve stenosis unable to safely undergo surgical aortic valve replacement. This transformative technique places the radiologist in a key position in the pre-procedural assessment of potential candidates for this technique, delivering key anatomical information necessary for patient eligibility and procedural safety. Recent trials also provide encouraging results to potentially extend the indication to patients with safer risk profiles.

Method The review is based on a PubMed literature search using the search terms “transcatheter heart valve”, “TAVI”, “TAVR”, “CT”, “imaging”, “MR” over a period from 2010–2020, combined with personal comments based on the author’s experience.

Results and Conclusion CT plays a prominent role in the pre-procedural workup, delivering as a true 3D imaging modality optimal visualization of the complex anatomy of the aortic root with simultaneous evaluation of the patency of the different access routes. As such, the contribution of CT is key for the determination of patient eligibility and procedural safety. This input is supplementary to the contributions of other imaging modalities and forms an important element in the discussions of the Heart Valve Team. Knowledge of the procedure and its characteristics is necessary in order to provide a comprehensive and complete report. While the role of CT in the pre-procedural evaluation is well established, the contribution of CT and MR and the clinical significance of their findings in the routine follow-up after the intervention are less

clear and currently the subject of intense investigation. Important issues remain, including the occurrence and significance of subclinical leaflet thrombosis, prosthetic heart valve endocarditis, and long-term structural valve degeneration.

Key Points:

- CT plays a crucial role in evaluating transcatheter heart valve candidates
- Evaluation must include the dimensions of the aortic root and access paths
- The exact post-procedural role of CT and MRI has not yet been determined.

Citation Format

- Salgado R, El Addouli H, Budde RP. Transcatheter Aortic Valve Implantation: The Evolving Role of the Radiologist in 2021. *Fortschr Röntgenstr* 2021; 193: 1411–1425

Introduction

Transcatheter aortic valve implantation, commonly abbreviated as TAVI, has significantly gained further ground since the first proof-of-concept procedure performed by Alain Cribier in 2002 [1]. Introduced as an alternative therapeutic option for patients with severe aortic valve stenosis (AS) unable to safely undergo surgical valve replacement, its application has since gained major momentum, supported by large carefully performed multicenter trials indicating an acceptable safety profile and the non-inferiority of transfemoral and apical TAVI compared to a surgical procedure in the mentioned population. Today, it is used worldwide with satisfactory clinical results in an increasing number of specialized centers.

In this article, we will further explore the evolution of the number of TAVI interventions and the repercussions on surgical procedures, the role of the radiologist in the pre-procedural workup and patient management, and the remaining imaging challenges for the future.

The evolution of TAVI procedures vs. surgical interventions

The scientific validation of the TAVI procedure

Today, the TAVI procedure has become a standard therapeutic option for patients with severe AS and a high or unacceptable risk for surgical intervention. Confirmation of the non-inferiority of this procedure in these populations compared with surgical valve replacement, together with encouraging follow-up studies, has led to a significantly increase in the worldwide adoption of this technique [2, 3]. An overview of landmark TAVI studies and their contribution to existing knowledge is summarized in ► **Table 1**. Both balloon- and self-expandable transcatheter heart valves

(THV) are currently used, in practice usually represented by the Edwards Lifesciences SAPIEN series and the Medtronic Evolut range, respectively. The physical properties of these devices and their imaging characteristics on CT have been extensively described elsewhere [4].

The evolving number of surgical vs. transcatheter aortic valve replacement

The rise of TAVI in Europe has been well-documented in Germany, a country which has required registration of all surgical and transcatheter valve replacement procedures in a nationwide quality assurance program since 2008 [5, 6]. In 2017, a total of 19 752 TAVI procedures had been performed since 2008, representing not only a thirty-fold increase since registration began, but also a 50 % increase since a more recent reference point of 2014 (► **Fig. 1**). Conversely, the number of surgical valve replacement (SAVR) procedures (either isolated or combined with coronary artery bypass graft) declined with 23 % since 2008. According to this registry, older age is currently the main reason for heart teams to select TAVI over SAVR, with 95 % of patients over 80 years of age undergoing a TAVI procedure.

Other countries also report an increasing dissemination and number of TAVI procedures [7, 8]. Nevertheless, differences remain in the management of severe aortic stenosis between different European centers, with, e. g., Germany having a stronger TAVI preference compared to the United Kingdom and France [9]. Many registries also point to an evolution of using TAVI in lower-risk patients with lower Logistic EuroSCOREs [6, 8, 10].

The mainstream availability of TAVI comes at an opportune time, since the growing Western elderly population and the subsequent increase in age-related AS will result in an increasing workload, representing a particular challenge for clinicians,

► **Table 1** Selected landmark TAVI trials and their contribution to existing knowledge.

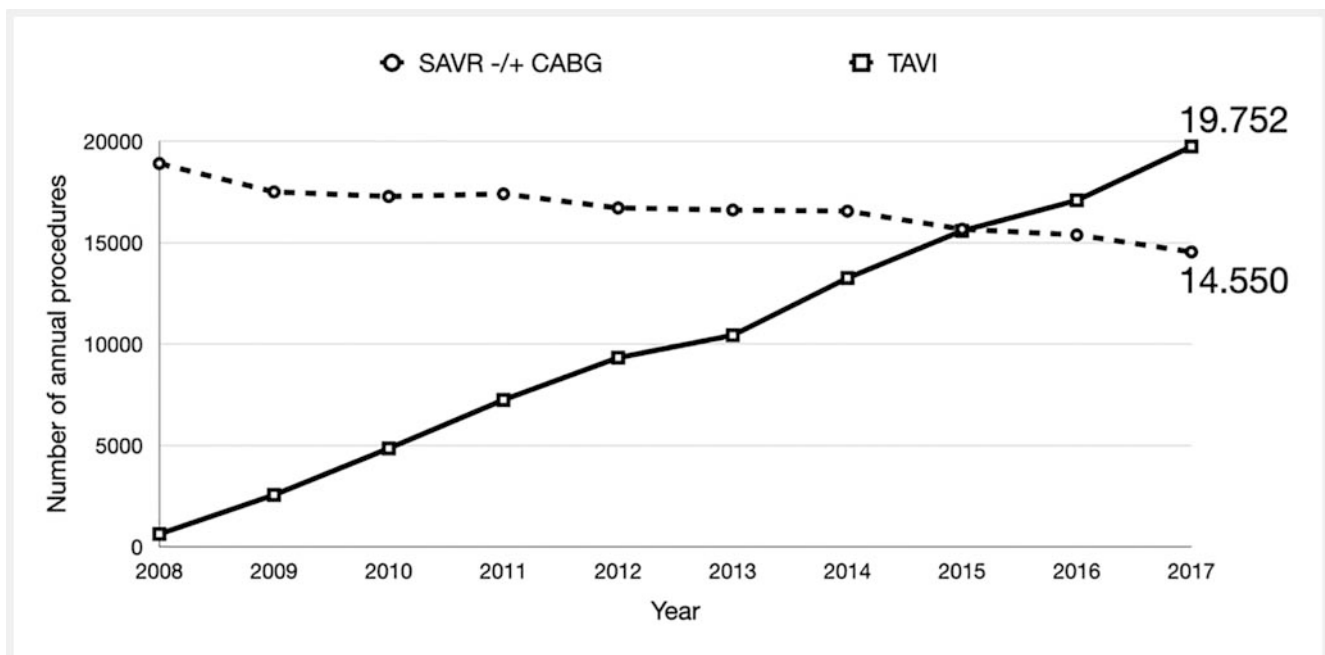
trial	year*	surgical risk	investigated device	type	acquired knowledge	reference publication
PARTNER 1B	2010	inoperable	SAPIEN	BE	TAVI, as compared with standard therapy, significantly reduced the rates of death from any cause, the composite end point of death from any cause or repeat hospitalization, and cardiac symptoms.	N Engl J Med 2010, 363: 1597–1607
PARTNER 1A	2011	high	SAPIEN	BE	in high-risk patients with severe aortic stenosis, transcatheter and surgical procedures for aortic valve replacement were associated with similar rates of survival at 1 year.	N Engl J Med 2011, 364: 2187–2198
CoreValve US HR	2014	high	CoreValve	SE	in patients with severe aortic stenosis who are at increased surgical risk, TAVR with a self-expanding transcatheter aortic valve bioprosthesis was associated with a significantly higher rate of survival at 1 year than surgical aortic valve replacement.	N Engl J Med 2014, 370: 1790–1798
CoreValve US ER	2014	extreme	CoreValve	SE	TAVR with a self-expanding bioprosthesis was safe and effective in patients with symptomatic severe aortic stenosis at prohibitive risk for surgical valve replacement.	J Am Coll Cardiol 2014, 63: 1972–1981
CHOICE	2013	high-Extreme	CoreValve/SAPIEN XT	BE & SE	Among patients with high-risk aortic stenosis undergoing TAVR, the use of a balloon-expandable valve resulted in a greater rate of device success than use of a self-expandable valve. 1-year follow-up of patients revealed clinical outcomes after transfemoral transcatheter aortic valve replacement with both balloon- and self-expandable prostheses that were not statistically significantly different.	JAMA 2014 311: 1503–1514 J Am Coll Cardiol 2015, 66: 791–800.
NOTION	2014	low	CoreValve	SE	no significant difference between TAVR and SAVR was found for the composite rate of death from any cause, stroke, or MI after 1 year.	J Am Coll Cardiol 2015, 65: 2184–2194
PARTNER 2A	2015	intermediate	SAPIEN XT	SE	in intermediate-risk patients, TAVR was similar to surgical aortic valve replacement with respect to the primary end point of death or disabling stroke.	N Engl J Med 2016, 374: 1609–1620
SURTAVI	2018	intermediate	CoreValve/Evolut R	SE	TAVR was a noninferior alternative to surgery in patients with severe aortic stenosis at intermediate surgical risk, with a different pattern of adverse events associated with each procedure.	N Engl J Med 2017, 376: 1321–1331
PARTNER 3	2019	low	Edwards Lifescience SAPIEN 3	BE	among patients with severe aortic stenosis who were at low surgical risk, the rate of the composite of death, stroke, or re-hospitalization at 1 year was significantly lower with TAVR than with surgery.	N Engl J Med 2019, 80: 1695–1705

► **Table 1** (Continuation)

trial	year*	surgical risk	investigated device	type	acquired knowledge	reference publication
US Evolut R LR	2019	low	Evolut R, Evolut Pro, CoreValve	SE	in patients with severe aortic stenosis who were at low surgical risk, TAVR with a self-expanding supraannular bio-prosthesis was not inferior to surgery with respect to the composite end point of death or disabling stroke at 24 months.	N Engl J Med 2019, 380: 1706–1715.

BE: balloon-expandable; SE: self-expandable.

* Year indicates primary outcome reached.



► **Fig. 1** Evolution of surgical vs. transcatheter aortic valve replacement in Germany. Since registration began, the number of TAVI procedures has increased thirty-fold, while the number of surgical valve replacement (SAVR) procedures (either isolated or combined with coronary artery bypass graft) declined with 23 % over the same period. After 2015, the number of TAVI procedures has surpassed its surgical counterpart. Currently, TAVI has become the standard of care in patients over 80 years in many German centers. Data from reference 5. SAVR: surgical aortic valve replacement; CABG: coronary artery bypass graft.

surgeons, and radiologists. A recent study calculated, based on epidemiological data and decision-making studies, that there are about 115 000 and 58 000 annual candidates for TAVI in the European Union and North America, respectively [11]. This grand total of about 180 000 patients annually could increase up to 270 000 if TAVI indications were to expand to include low-risk patients. However, while recent trials provide increasing evidence to eventually potentially justify such a move (► **Table 1**) [12–14], important questions still remain unresolved, including regarding the long-term performance of THVs.

The Heart Team and the radiologist

Determining the optimal treatment course for a frail patient with symptomatic severe AS and multiple co-morbidities poses a complex problem, which is best served by a multidisciplinary approach. The creation of “Heart Teams” in specialized centers, composed of members of different relevant subspecialties, constitutes a further streamlining and optimization of the process to evaluate all available clinical and imaging information and select the most appropriate therapy for a particular patient [15]. However, despite the cornerstone role that radiology (most particularly computed tomography) plays in the pre-procedural assessment of a TAVI candidate, the radiologist is rarely mentioned by

name. Instead, many papers and statements use the more generic term “imaging specialist”. Therefore, to further promote and reconfirm the important role that the radiologist has in the decision-making process, the European Society of Cardiovascular Radiology (ESCR) recently published a consensus statement supporting the formal inclusion and recognition of radiologists in the composition of a Heart Team [16].

A brief review of relevant anatomy and required measurements

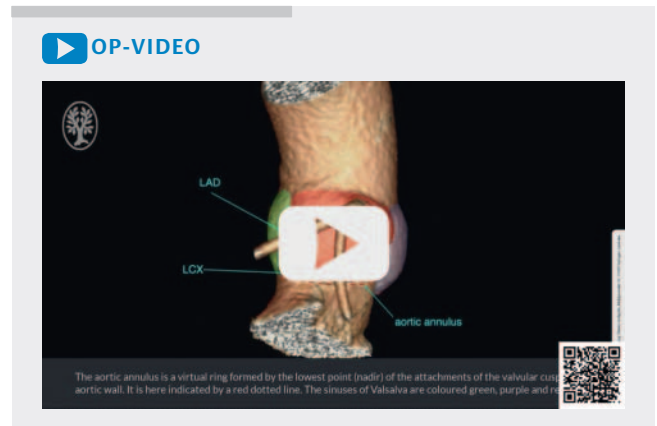The analysis of a pre-procedural TAVI CT examination is an extensive process, with many detailed measurements required at different anatomical levels to consider many parameters that may influence both peri- and post-procedural safety and final patient eligibility. A detailed description of all measurements is beyond the scope of this paper. Nevertheless, some important key points will now be briefly reviewed.

The value of three-dimensional imaging

Many excellent reviews and consensus documents describing the radiological anatomy of the aortic root and its components have already been published [16–18]. A supplemental movie (▶ **Video 1**) to this paper recapitulates the most important landmark structures using computed tomography (CT). It further illustrates the varying cross-sectional contour of the aortic root extending from the sinotubular junction to the so-called aortic annulus. Combined with the complex three-dimensional morphology of the aortic valve, it is easy to understand the benefits of using a true 3D imaging modality such as CT to correctly visualize the annular plane and subsequently accurately obtain the required measurements. Therefore, while echocardiography was the main imaging modality in the initial trials validating the clinical use of TAVI, CT has in the meantime become a prime imaging modality for anatomical assessment of a TAVI candidate, forming an essential component of any modern annular sizing investigation. Given the fundamentally different nature of CT and ultrasound (US), respective measurements on these imaging modalities are not interchangeable or comparable [19]. Finally, while magnetic resonance imaging (MRI) can obtain a 3D acquisition of the aortic root, it remains technically more challenging, less practical, and therefore is only used in selected cases.

The aortic annulus

One of the most coveted pieces of information in a pre-procedural assessment is the dimensions of the aortic annulus, as it forms the anchoring site of both balloon- and self-expandable THVs. However, the annulus is not a real anatomical structure, but rather a virtual ring formed by the lowest point (nadir) of the attachment of the valvular cusps to the aortic wall (▶ **Fig. 2**). Its cross-sectional contour has mostly an elliptic shape in diastole but tends to become rounder during systole [20]. Given this time-dependent variation, annular measurements must be performed in the systolic phase as it is associated with the largest annular dimensions. However, when systolic image quality is poor, other timepoints in the cardiac cycle are acceptable when delivering more reliable



▶ **Video 1** Brief overview of relevant anatomical landmarks on CT in the pre-procedural assessment.

measurements [16]. The most commonly proposed measurements are the annular cross-sectional short- and long-axis diameter, the annular perimeter, and the annular area (▶ **Fig. 3**).

Aortic valve cuspidity

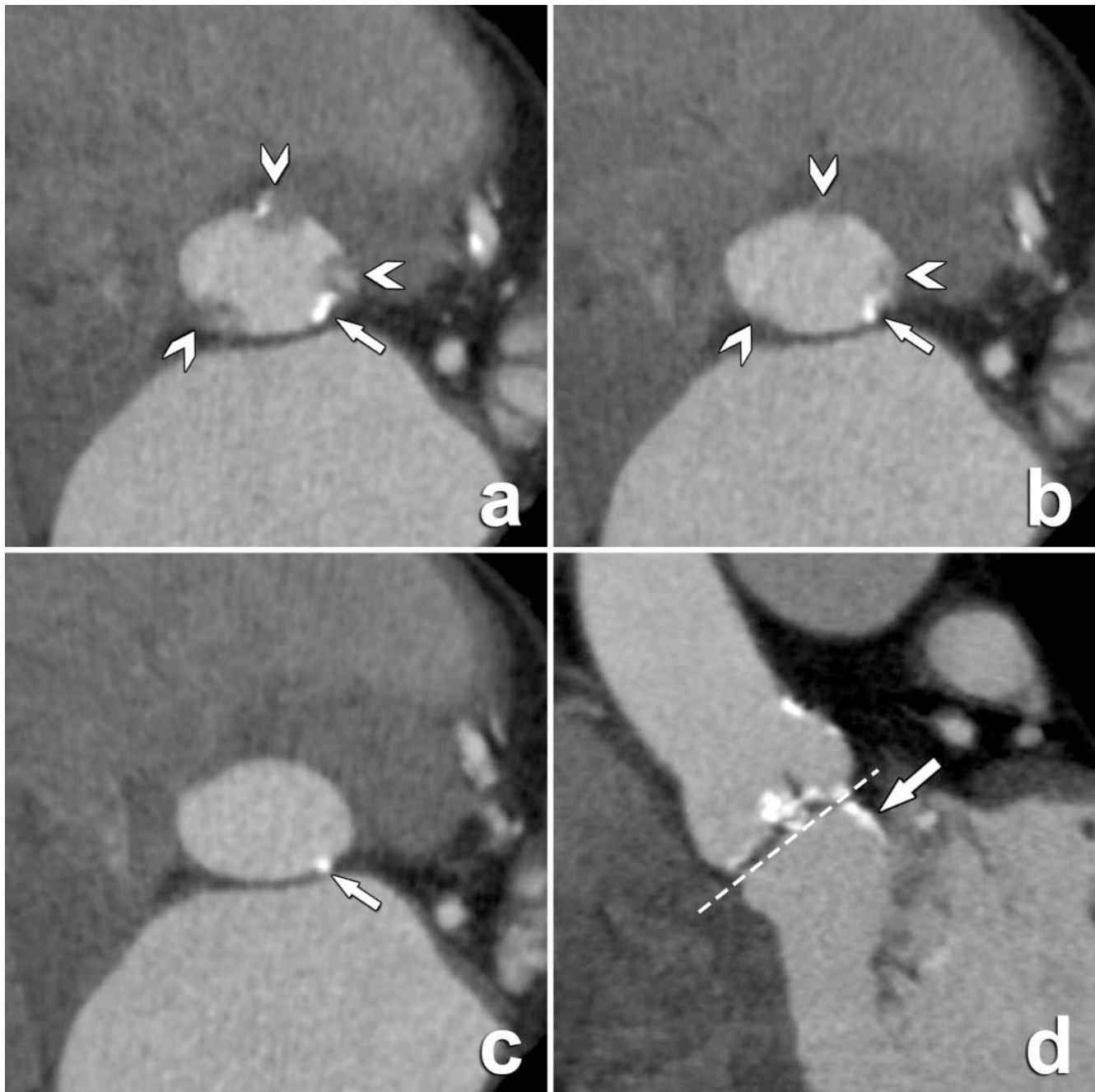
Recently, the cuspidity of the aortic valve has gained increasing attention. The majority of the normal population has a tricuspid aortic valve. However, a bicuspid aortic valve (BAV) remains the most common congenital heart abnormality in humans and is a well-known risk factor for AS, leading to premature valve degeneration in comparably younger patients [21]. A prevalence of up to 50% has been reported in surgical aortic valve replacements due to AS [22].

Historically, the randomized clinical trials validating the use of TAVI have largely excluded patients with BAVs, with its presence being considered a relative contraindication in previous guidelines [23, 24]. The existence of a BAV, while now no longer considered a formal contraindication, still poses particular challenges (▶ **Table 2**) [12, 25–28]. However, recent studies [25, 29] indicate an improved safety profile and efficacy using newer-generation devices, providing cumulative evidence for further potential formal inclusion of patients with BAVs in future TAVI guidelines and indications.

Given the mentioned procedural and prognostic implications, the cuspidity of the aortic valve must therefore be clearly mentioned in the radiology report.

Aortic valve leaflet calcifications

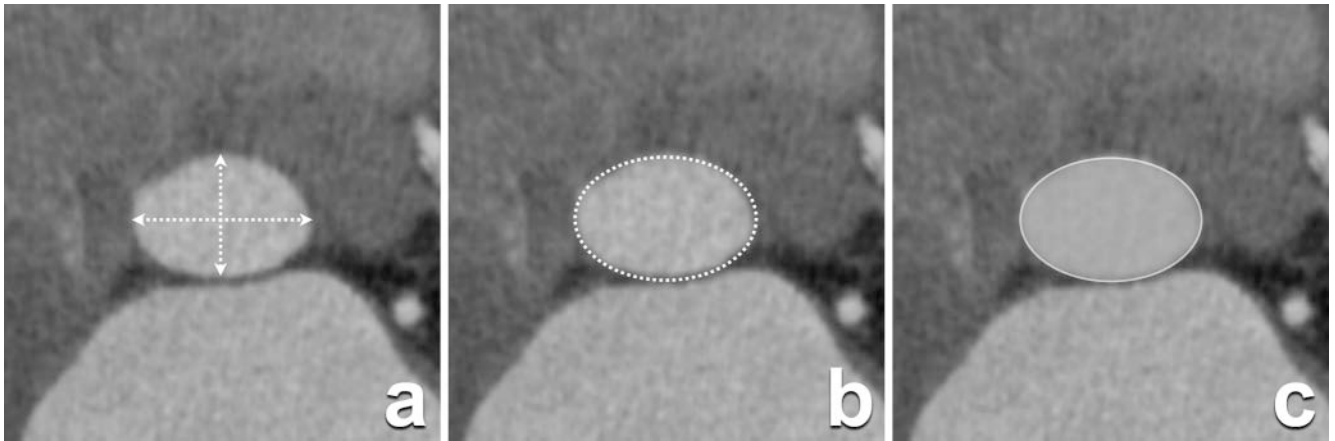
Almost invariably, severe AS is associated with extensive leaflet calcifications. Both calcified and non-calcified leaflet components will be displaced during device deployment, crushed to variable degrees between the TVH and the aortic root wall (▶ **Fig. 4**). A qualitative description of leaflet calcifications in the radiology report is required, given the association with complications such as paravalvular leakage, THV dislodgement, coronary ostia obstruction, annular rupture, calcific embolism, potential conduction disturbances, and stroke [30–32]. We recommend scoring the amount of valvular calcification (mild to severe), the distribution



► **Fig. 2** Double-oblique in-plane and perpendicular images through the aortic root near and at the annular level. **a** The nearly most basal portion of the aortic valve leaflets (arrowheads) is shown. Note also a nonrelated small calcification (arrow). **b** In-plane image located at a level even closer to the annular plane, with the leaflet insertions now just nearly visible (arrowheads). **c** In-plane image at the annular plane, showing the virtual aortic annulus having an oval contour on cross-sectional imaging. **d** The aforementioned calcification can be seen extending to a sub-valvular level (arrow) in this perpendicular image, below the annular plane (dashed line).

(focal vs. diffuse) and the location (leaflet edges, commissures, and attachment sites). In addition, the absence of prominent leaflet calcifications needs to be specifically mentioned, as some authors argue that some degree of calcification may be required for stable anchoring of the THV [31]. Subvalvular calcifications can be scored in the same manner as their supra-valvular counterparts (amount, distribution, and location).

Several studies have shown a clear correlation between the amount of leaflet calcifications and the likelihood of having severe AS, hereby also providing additional prognostic information over traditional risk factors [33, 34]. Gender differences have also been noted, with women having more severe AS for the same amount of valvular calcium load compared to men [35]. While the exact pathophysiology for this discrepancy remains to be fully understood, some investigators point to a more prominent



► **Fig. 3** Double-oblique in-plane image at the annular plane. Many (performed and derived) measurements are possible. The most commonly obtained measurements in the annular plane are shown. **a** Cross-sectional long- and short-axis diameter. **b** Annular perimeter. **c** Annular area.

► **Table 2** Challenges posed by bicuspid aortic valves in TAVI. THV: transcatheter heart valve.

challenges of bicuspid aortic valves in TAVI

constitutional asymmetry of the aortic valve leaflets and severe calcifications, potentially contributing to more frequent and severe paravalvular leakage due to more complicated positioning and deployment of the THV

risk of annular rupture or coronary ostial occlusion

presence of BAV-associated aortopathy with increased risk of complications, including aortic dissection

younger patient population, increasing concerns on long-term durability and performance of THVs

increased risk for post-procedural permanent pacemaker need, independently of type of THV

BAV: bicuspid aortic valve.

► **Table 3** Overview of currently available access routes for TAVI. The transapical approach is currently reserved for balloon-expandable THV.

access sites

transfemoral

transapical

transsubclavian/brachiocephalic artery

transcarotid

transaortic

transcaval

transseptal

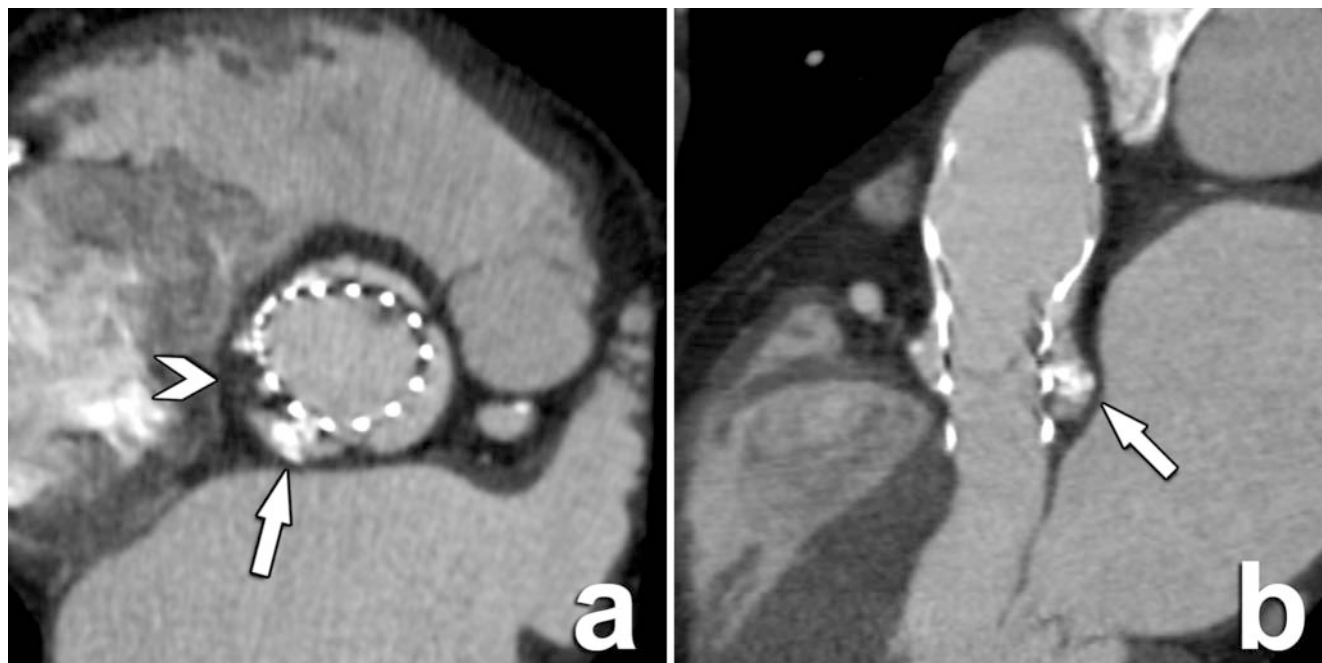THV: transcatheter heart valve.

fraction of fibrosis in stenotic aortic valves in women [36]. Combining these new insights with the clear need for diagnostic aid in cases of the so-called low-flow/low-gradient AS (in which echocardiography is unable to deliver a conclusive diagnosis of severe AS), the quantification of aortic valve leaflet calcifications with CT has now become an established diagnostic tool [15]. This quantification is executed using the same Agatston score method as for calcifications of the coronary arteries. However, this quantification is not to be routinely performed and should still be reserved for the mentioned low-flow/low-gradient AS with inconclusive echocardiography. Finally, quantification of aortic leaflet calcifications may in practice be more difficult to perform than expected, with, e.g., a sometimes unclear distinction between calcifications of the aortic valve leaflets and adjacent mitral annulus calcifications.

Access route patency

Besides the aortic root anatomy, the patency of the transcatheter access route is a prerequisite for safe delivery of the THV. To increase the number of patients eligible for a TAVI procedure, the number of possible access routes has been steadily expanded over the years. An overview of the currently available access routes can be found in ► **Table 3**. For the current Medtronic Evolut R and Edwards Lifescience SAPIEN 3 series, a minimal luminal diameter of 5.5 mm is needed for their largest THV (29 mm SAPIEN 3 and 34 mm Evolut R). All other smaller sizes require a minimum luminal diameter of 5 mm for safe passage of the THV. We suggest using a uniform scan and reconstruction protocol and routinely evaluating the most common access pathways.

Differences exist between the types and models of THVs and the required characteristics of the different access sites. As new devices are continuously being developed and introduced, access route requirements (like minimal luminal diameter needed for unobstructive passage) change accordingly, always with the aim of lowering the anatomical threshold for procedural eligibility.



▶ Fig. 4 Double-oblique in-plane and perpendicular images through the aortic sinus after deployment of a self-expandable Medtronic CoreValve. **a** Displacement and crushing of both native non-calcified (arrowhead) and calcified (arrow) leaflet components between the expanding THV and the wall of the aortic sinus are illustrated in this in-plane image. **b** To prevent regional obstruction of the deployment of the THV, manufacturers provide device-specific guidelines regarding the required dimensions of the aortic sinus, which acts as a reservoir for these displaced components. This function of the aortic sinus is clearly illustrated here, where the aortic sinus is accommodating displaced extensive calcifications (arrow), thereby not influencing THV expansion. THV: transcatheter heart valve.

The transapical approach is currently only available for balloon-expandable valves.

Despite the increasing array of options, the transfemoral access remains the preferred route whenever possible according to international guidelines [15, 37]. Risk factors for complications include circumferential atherosclerosis, occlusive vascular disease, small native vessel diameter, dissections, presence of stents, and prominent vessel tortuosity. These risk factors, however, also apply to all access sites. When transfemoral access is not feasible (15–25%), other access sites can be considered, with the final choice for an alternate access depending on anatomical feasibility and local expertise [38, 39].

Valve-in-valve

The valve-in-valve technique is currently a niche application of TAVI used to treat degenerated surgical bioprosthetic aortic valves [40, 41]. During this procedure, a transcatheter valve is deployed within the in situ surgical aortic valve prosthesis, effectively replacing its function.

Given the different circumstances, the required pre-procedural CT measurements are different than in the case of native aortic valves. The presence of the surgical valve will determine the maximum size of the THV that can be implanted. While this dimension can be obtained from the surgical report, it can also be derived using CT [42]. An important consideration in valve-in-valve procedures is the increased risk for coronary obstruction, which can be decreased using both procedural modifications and CT-based pre-procedural simulation techniques [42–44].

While valve-in-valve is not widely performed today, its role may increase in the future as it could also be used to replace a failing transcatheter aortic valve. This may become more relevant as there is a tendency to treat younger patients with THVs in which case life expectancy may exceed valve durability. Recent studies show the potential for the replacement of a THV with another THV with similar procedural safety or mortality compared with the current valve-in-valve procedure to replace a bioprosthetic surgical valve [45].

How to scan a TAVI candidate

Many reviews have explained in detail the technical requisites of a pre-procedural CT and MRI examination [17, 18, 46]. Recently, the ESCR published an open-access consensus statement with vendor-specific CT and MRI protocols, which can be used for further reference [16]. In this review, we will concentrate on three specific issues regarding the CT examination: the need for pre-medicating a TAVI candidate prior to the CT examination, the influence of CT contrast on renal function in this population, and the delivered radiation exposure. Finally, the use of MRI as opposed to CT will be briefly discussed.

Pre-medication

Given the inherent motion of the heart, the use of pre-medication during the preparation of a patient for a routine cardiac CT examination is not uncommon. Here, administration of medication

(either orally or intravenously) has two common goals: lowering the heart rate to achieve optimal diagnostic motion-free image quality and obtaining a temporal dilatation of the coronary arteries for better visualization and stenosis detection [47, 48].

However, the current TAVI population has quite different characteristics. Firstly, it is composed of much elderly individuals with a higher-than-average frailty and multiple co-morbidities. Therefore, as they may react differently to the usual drugs, the use of medication with the intent of increasing CT image quality must be approached with caution and in concordance with the referring physician. Some centers and societies therefore opt to routinely abstain from any routine pre-procedural CT medication in TAVI candidates [16]. Furthermore, as the primary target is not evaluation of the coronary arteries but of the aortic root and its components, less strict heart rate control may be tolerated, especially when high-end CT equipment is available [49, 50].

In conclusion, the use of pre-medication to improve image quality is not routinely recommended.

Iodinated contrast volume

Most commonly, a TAVI CT examination is executed to obtain information on both the dimensions and characteristics of the aortic root (performed using ECG-gating) as well on the patency of the different possible access routes [17]. This combined approach, often performed during a single examination, inherently implies a large anatomical scan range and matching dose of contrast volume. However, many patients already have depressed renal function, potentially further compromised by other required examinations preceding the TAVI procedure (e. g., in many instances including a conventional angiography of the coronary arteries in the absence of recent information regarding their status). Therefore, any measure that can be implemented to reduce the volume of iodinated and potentially nephrotoxic contrast product during the CT examination must be exploited to its fullest capacity. Many investigators have addressed this issue, reporting that the speed and performance of the latest generation of CT scanners can achieve high diagnostic results while significantly limiting the required amount of contrast volume [49, 51]. Some authors have also reported encouraging results on the concomitant evaluation of the coronary arteries during the same CT examination [50, 52]. While it can be assumed that the success of such an approach is inherently linked to the experience of the center performing the examination and the available equipment, if confirmed in future studies it further represents an additional example of the increasing value of CT and its ability to at least partially replace other examinations and as such their contrast use.

In summary, an effort should always be made to reduce the contrast volume load according to the performance of the available equipment.

Radiation exposure

While radiation exposure must always remain a point of focus, one can pragmatically defend the notion that given the very advanced age of a typical TAVI candidate and the dismal short-term prognosis of an untreated symptomatic severe AS, aggressive reduction of radiation exposure is currently not a primary concern in

this population. However, as the transcatheter approach for treating valvular heart disease expands to other valves, and within the aortic valve to other indications and population groups, it can be expected that the mean patient age will further decrease [15, 53–55]. Therefore, with an increased associated life expectancy, together with a not yet exactly defined potential role of CT in the management of manifestations such as subclinical valve leaflet thrombosis, radiation exposure and the efforts to reduce it will only gain in importance. Nevertheless, technology advances and the introduction of novel noise reduction techniques can further help to maintain the associated radiation dose within acceptable limits [56, 57].

MR imaging

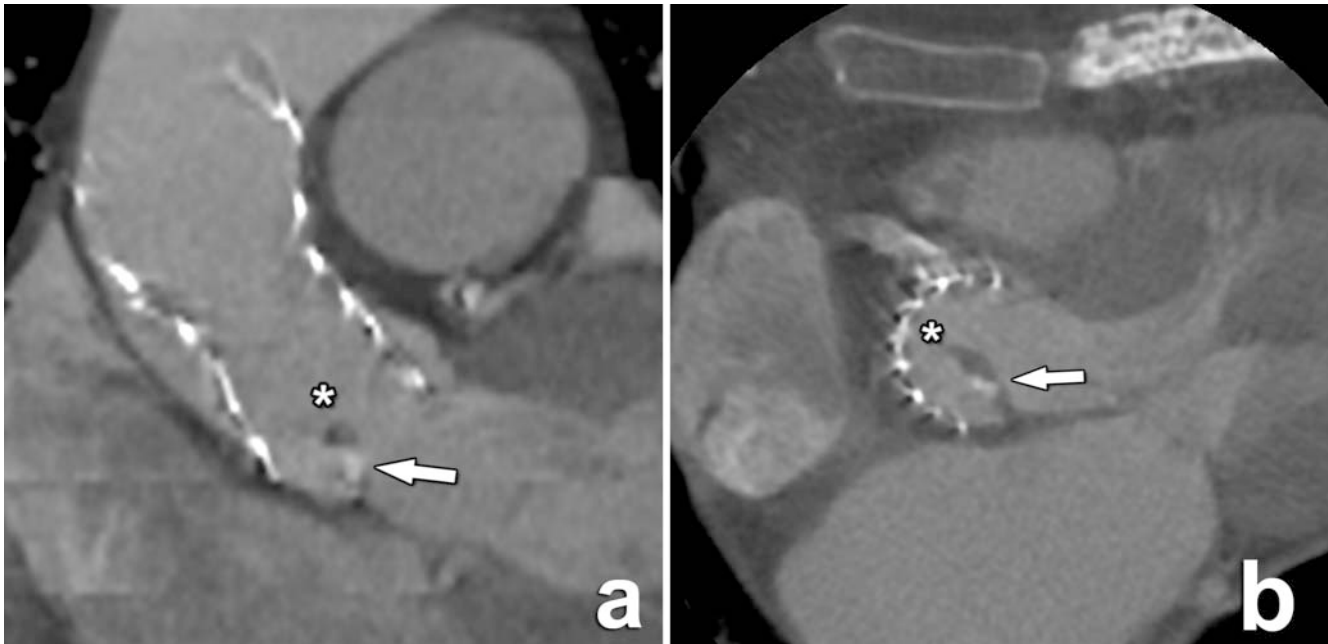Given its fundamentally different nature, CT is much better suited for pre-TAVI anatomical evaluation than MRI. MRI can, however, be of value in certain circumstances, since it is potentially able to perform the annular planimetry and obtain the different necessary measurements with comparable accuracy to that of CT, even without intravenous contrast administration [58, 59]. As such, its use may be warranted in patients who have formal contraindications for iodinated contrast.

However, the use of MRI is far less widespread than CT for annular planimetry, despite the absence of radiation exposure and the use of a far less potentially toxic contrast medium. The reasons include a technically more demanding and longer examination, the commonly longer waiting lists compared with CT, as well as the less detailed evaluation of calcifications (which are an important factor to consider for procedural safety), among other things. Some authors, therefore, propose performing an MRI examination for obtaining aortic root measurements, followed by a non-enhanced CT examination for evaluation of calcifications.

A more interesting role for MRI may be the pre- and post-procedural evaluation of cardiac function, especially left ventricular remodeling, the pattern and magnitude of which are influenced by many factors [60]. MRI may also provide additional prognostic information, as delayed myocardial enhancement indicating fibrosis has been shown to be an independent predictor of mortality after both surgical and transcatheter aortic valve replacement [61]. Consequently, using MRI to assess the presence of both interstitial and replacement fibrosis may provide better insight into the post-procedural prognosis independent of other risk factors [62–65].

TAVI outcomes: early and late complications after TAVI

Despite the obvious increase in and clinical success of TAVI procedures in the last decade, different challenges remain for the future. Some of these potential complications arise early in the post-operative period, while other manifest only years afterwards. In chronological order of appearance, we will discuss paravalvular aortic regurgitation, prosthetic heart valve thrombosis and endocarditis, and finally structural valve dysfunction.



► **Fig. 5** THV dislocation in a patient with persistent elevated but further unexplained gradients on echocardiography after TAVI. **a** An angulated and slightly displaced Medtronic CoreValve unable to displace all native aortic valve material is shown in this perpendicular image. **b** A partially calcified and thickened native aortic valve leaflet protruding into the inflow portion of the THV (asterisk) remains in place in this axial image. THV: transcatheter heart valve.

Paravalvular aortic regurgitation

Paravalvular aortic regurgitation (PAR) is defined as the postprocedural regurgitant leakage of blood around the attachment sites of the THV. While the causes are multifactorial, it is at least in part secondary to suboptimal patient-prosthesis size matching, as an undersized or incorrectly positioned THV can lead to incomplete sealing at the attachment sites.

Some series indicate that about one in nine patients develops moderate to severe PAR after the procedure [66]. The clinical significance of PAR must not be underestimated, as it is a known and independent factor for late all-cause mortality [67, 68]. Therefore, as even moderate PAR has significant impact on prognosis, significant efforts have been devoted to optimizing sizing algorithms using different methods. It is in this respect that the integration of CT-based annular sizing in the pre-procedural work-up has subsequently evolved to one of the most important cornerstones to achieve optimal procedural and clinical success.

The main imaging tool for post-procedural and further life-long follow-up of TAVI patients remains echocardiography, delivering both anatomical and functional information in one widely available and relatively cheap imaging examination [15]. As such, it is the primary indicated method for the detection and follow-up of PAR. Despite the clear advantages that CT has in the pre-procedural anatomical assessment, it remains a morphology-based imaging modality, and therefore is not indicated for functional THV evaluation. Even in cases where CT produces very suggestive imaging findings for PAR, extreme caution must be exerted to not extrapolate these findings to functional implications. Displaced valve leaflet calcifications, while potentially inhibiting the regional expansion of a THV and therefore compromising its function, can

also have an additional positive sealing function. The relation between leaflet calcifications and the final functional result after THV deployment is therefore more complex than initially thought.

Conversely, CT can have a role as a secondary imaging tool in cases when PAR has been established based on clinical and echocardiography findings, although without a clear etiology. In such circumstances, CT can easily depict an incorrectly positioned or migrated THV, therefore delivering important information for further therapeutic interventions in selected cases (► **Fig. 5**). Consequently, in our institution we don't routinely perform post-TAVI CT examinations, with its use being determined on a case-by-case basis.

MRI, which like echocardiography can deliver both morphological and functional information, is by nature better suited than CT to assess PAR severity, as reported by several investigators [69–71]. However, comparison of MRI and echocardiography results is not straightforward, as several studies have used different reference standards and PAR severity grading definitions, with MRI studies reporting different rates of severe AS [72]. Therefore, similarly to the sizing comparison between CT and echocardiography, comparison between MRI and echocardiography results for PAR must be interpreted with the necessary caution. Regardless of these issues, investigators have shown that MRI-derived aortic regurgitation values are correlated with clinical outcomes, with MRI-detected moderate to severe PAR leading to worse outcomes at the 24-month follow-up [73], thus indicating a role for MRI in patients next to echocardiography in selected patients. Whether new technologies like analysis of transvalvular and ascending aorta 4D flow patterns will lead to clinically relevant consequences is currently still under investigation [74, 75]. Finally, the prac-

tical use of MRI in the postoperative period may also be influenced by an existing and post-procedural raised prevalence of implanted cardiovascular electronic devices in TAVI patients (► **Fig. 6**) [72].

PHV endocarditis

Infective endocarditis is a rare but severe form of valvular heart disease, characterized by an inflamed endocardium and valve leading to the development of vegetations, mycotic aneurysms, and septic emboli. Its epidemiological profile has evolved in recent years, influenced by the increasing use of invasive procedures (including the use of heart valve prostheses) and hence the risk for bacteremia [76, 77]. Specifically, prosthetic heart valve endocarditis (PVE) is a recognized life-threatening complication, affecting up to 5% of patients annually after valve implantation, with a reported 1-year mortality of up to 50% [78]. Particularly in this subgroup, diagnosis is often difficult, with a highly variable clinical history and presentation [76]. While echocardiography and blood cultures remain a cornerstone of diagnosis according to the modified Duke criteria of 2000, they have a reported lower sensitivity and specificity for the diagnosis of PVE [79]. This is unfortunate, as a timely and definitive diagnosis is necessary to be able to reach major clinical decisions like potential reoperation with high confidence.

It is in this respect that clinical guidelines have been recently updated to include relevant contributions made by contemporary imaging modalities like CT (► **Fig. 6**) and ¹⁸F-fluorodeoxyglucose (FDG) positron-emission tomography (PET)/CT [37, 76, 80–82].

While a more detailed discussion is beyond the scope of this paper, it is important to realize that even with these modern evaluation tools, the diagnosis of PVE remains a challenging task, best undertaken in specialized centers with dedicated “Endocarditis Teams” composed of specialists with different medical specialties.

Subclinical leaflet thrombosis

While the use of CT was not integrated in the pre-procedural workflow of the initial trials which led to the validation of TAVI clinical use, it soon became a standard imaging modality as its advantages became clear. This integration led to some unanticipated findings, like the prevalence of reduced leaflet motion (RLM, sometimes also indicated as hypoattenuation-affecting motion or HAM) and subclinical valve thrombosis in both surgical and THV patients with unchanged mean gradients on echocardiography [83, 84]. This so-called hypoattenuated leaflet thickening (HALT) appeared in various degrees, with no evident clinical correlation and unremarkable echocardiography findings. While RLM appeared in some series in both surgical and bioprosthetic aortic valves with a total of 11.9%, it was more common in TAVI patients (13.4%) versus surgical valves (3.6%), with a more severe motion reduction and pronounced leaflet thickening in the TAVI population [84]. Additional studies also revealed that the prevalence of RLM and HALT differed between types of valves, with, e. g., the Perceval sutureless valve reported to be more affected in earlier studies (► **Fig. 7**) [85].

Evidently, questions were raised as to how these subclinical imaging findings translate to a need for further optimization of medical anticoagulant therapy, and regarding their impact on

prognosis and incidence of thrombo-embolic events like stroke. A meta-analysis in 2018 indicated that, while there is an overall incidence of HALT with or without RLM of about 15%, there was no significant association with the presence of stroke, transient ischemic attack (TIA), or the combined stroke/TIA endpoint [86]. However, a more recent meta-analysis did find an increased stroke risk [87]. Most importantly, both studies indicated a need for more research. This need for more insight is further illustrated by the fact that investigators have noted that subclinical leaflet thrombosis can in some patients regress without anticoagulation [88]. Therefore, this is currently a field of intense ongoing investigation, with recent studies further contributing to the debate and our understanding on how to use and optimize antithrombotic therapy in post-TAVI patients [89, 90]. Regarding CT imaging, a systematic methodology for the evaluation of subclinical leaflet thrombosis has been suggested to reach standardization of reporting [91].

Structural valve degeneration

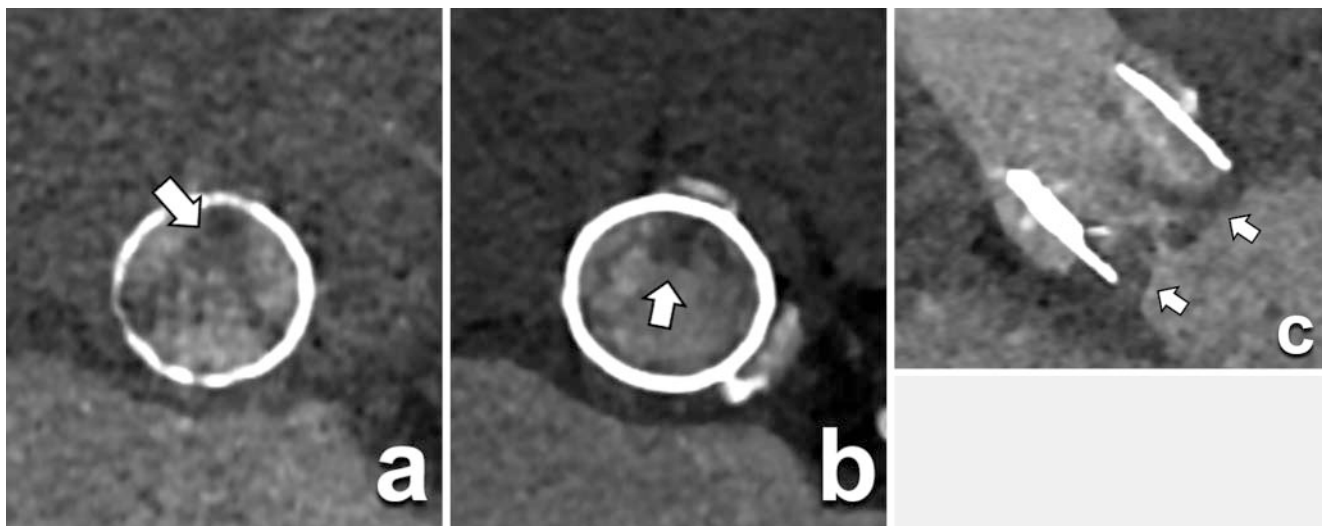
The prevalence of RLM and HALT in both surgical and especially THV patients also raises questions regarding the longevity of these devices. Currently, the vast majority of patients who receive a THV for severe aortic valve stenosis are of advanced to very advanced age. However, one can reasonably expect that the mean age of THV recipients will drop as current and future trials continue to confirm the at least non-inferiority and acceptable safety profile of a transcatheter versus a surgical approach to replace a diseased aortic valve in other risk populations, leading to expanding indications and a lower risk profile of TAVI candidates.

It is therefore crucial to fully understand all contributing factors to structural valve degeneration (SVD). To facilitate comparison across centers and trials, a common definition of SVD has been proposed in a consensus document supported by different societies [92].

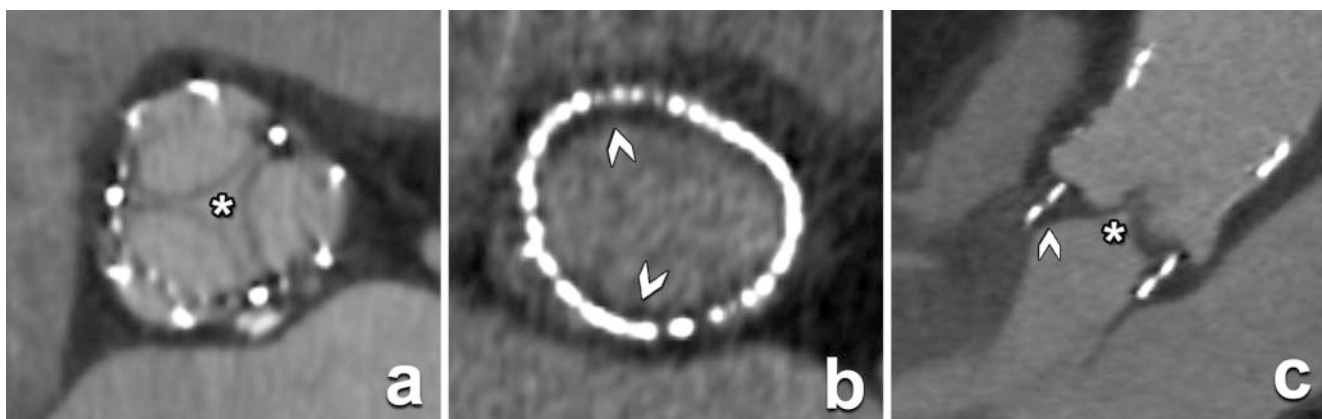
Data from the FRANCE-2 registry have indicated that while the all-cause mortality was about 61%, the majority of cardiovascular events occurred in the first month after valve implantation, with a low rate of clinical events and a low level of SVD after 1 year [93]. A multicentric French study also reported low rates of SVD (10.8%) and bioprosthetic valve failure (1.9%) in a 7-year follow-up study [94]. However, the authors also noted that long-term assessment of SVD is limited by the poor survival of the investigated population, with only a reported 19% survival after 7 years.

On the etiology of SVD, histological analysis of explanted specimens revealed that thrombus was found in all explanted valves, both on the aortic and ventricular sides [95]. Leaflet thickening correlated with the duration of THV implantation, with a progression independent of cardiovascular risk factors and anticoagulation therapy. Based on their findings, the authors postulated a sequence of thrombus, fibrosis, and calcification as a pathway to SVD.

This and other discoveries may help us not only detect the presence of SVD in its earliest stages, but also provide anchor points for targeted therapies on different components of the pathophysiological process. Very promising studies concerning early detection of SVD have been concentrating on the use of 18F-



► **Fig. 6** CT images in-plane and perpendicular to a THV (Lotus) in the aortic position in an 81-year-old patient that was admitted with fever and blood cultures positive for streptococcus. **a** Irregular thickening of the valve leaflets in this in-plane image can be seen (arrow). **b** In this in-plane image on a subvalvular level, hypodense structures (arrow) that are compatible with vegetations are depicted. **c** The perpendicular image clearly shows the thickened leaflets (arrows). THV: transcatheter heart valve.



► **Fig. 7** Subclinical hypoattenuating leaflet thrombosis in a patient after receiving a sutureless Perceval PHV, with no transvalvular gradient on echocardiography. **a** In-plane CT image shows clear thickening of the PHV leaflets (asterisk). **b** In-plane image showing a semi-circumferential non-continuous low-density structure against the luminal side of the PHV, representing a thrombus (arrowheads). **c** Perpendicular image showing thickened leaflets (asterisk) and peripheral thrombus (arrowheads). The clinical significance of such findings cannot be determined with imaging alone and must be cautiously correlated with all other available imaging and clinical data. PHV: prosthetic heart valve.

Fluoride PET-CTA, providing striking signs of SVD before hemodynamic deterioration [96].

In conclusion, it can be stated that there is no dominant imaging modality that can cover all aspects of post-procedural TAVI surveillance, but that different modalities cover different aspects at different time points after the procedure. As these imaging modalities are spread across different medical specialties (radiology, cardiology, nuclear medicine), it is obvious that the often-mentioned but not always properly implemented principle of multidisciplinary cooperation will provide the best platform for patient care, which is best executed within the Heart Valve team.

Choice of imaging modality after TAVI

Despite all of the mentioned advances in the use of CT, MRI and nuclear imaging, echocardiography remains the main imaging modality for the follow-up of a patient after TAVI. Its ability to provide morphological and functional information in a single examination, without the use of intravenous contrast material or radiation exposure, is invaluable for routine clinical follow-up.

At this moment, there are no guidelines regarding the use of CT or MR imaging after the procedure on a routine basis. Their application is reserved for selected cases when echocardiography is inconclusive. As such, routine use of these imaging modalities in uncomplicated cases is not recommended. Nevertheless, CT is the current imaging modality of choice over echocardiography to

detect subclinical leaflet thrombosis, an important entity with a clinical impact that is not yet clear.

Conclusion

Once again, radiologists find themselves at the intersection of different medical specialties all striving for optimal use and implementation of a transformative technique like transcatheter replacement of a diseased aortic valve. It represents an opportunity to further promote radiologists as clinically oriented and patient-centered individuals, providing essential information required for procedural success and cooperating with other colleagues for the well-being of the patient. Therefore, integration of a radiologist within the Heart Valve team of any center offering TAVI is essential for the optimization of patient care, and for the standing of radiologists within the medical profession. It is, as such, the duty of every radiologist to be familiar with this procedure, the required information to be provided, and the indications and limitations for post-procedural surveillance with CT and MRI.

Conflict of Interest

The authors declare that they have no conflict of interest.

References

- [1] Cribier A, Eltchaninoff H, Bash A et al. Percutaneous Transcatheter Implantation of an Aortic Valve Prosthesis for Calcific Aortic Stenosis. *Circulation* 2002; 106: 3006–3008
- [2] Mack MJ, Leon MB, Smith CR et al. 5-year outcomes of transcatheter aortic valve replacement or surgical aortic valve replacement for high surgical risk patients with aortic stenosis (PARTNER 1): a randomised controlled trial. *Lancet* 2015; 385: 2477–2484
- [3] Kapadia SR, Leon MB, Makkar RR et al. 5-year outcomes of transcatheter aortic valve replacement compared with standard treatment for patients with inoperable aortic stenosis (PARTNER 1): a randomised controlled trial. *Lancet* 2015; 385: 2485–2491
- [4] Salgado RA, Budde RPJ, Leiner T et al. Transcatheter aortic valve replacement: postoperative CT findings of Sapien and CoreValve transcatheter heart valves. *Radiographics Rev Publ Radiological Soc North Am Inc* 2014; 34: 1517–36
- [5] Institut für Transparenz und Qualität im Gesundheitswesen (IQTIG). Undefined n.d.
- [6] Eggebrecht H, Mehta RH. Transcatheter aortic valve implantation (TAVI) in Germany: more than 100000 procedures and now the standard of care for the elderly. *Eurointervention* 2019; 14: e1549–e1552
- [7] Auffret V, Lefevre T, Belle EV et al. Temporal Trends in Transcatheter Aortic Valve Replacement in France FRANCE 2 to FRANCE TAVI. *J Am Coll Cardiol* 2017; 70: 42–55
- [8] Ludman PF. UK TAVI registry. *Heart* 2019; 105: s2
- [9] Lutz M, Messika-Zeitoun D, Rudolph TK et al. Differences in the presentation and management of patients with severe aortic stenosis in different European centres. *Open Hear* 2020; 7: e001345
- [10] Landes U, Barsheshet A, Finkelstein A et al. Temporal trends in transcatheter aortic valve implantation, 2008–2014: patient characteristics, procedural issues, and clinical outcome. *Clin Cardiol* 2017; 40: 82–88
- [11] Durko AP, Osnabrugge RL, Mieghem NMV et al. Annual number of candidates for transcatheter aortic valve implantation per country: current estimates and future projections. *Eur Heart J* 2018; 39: 2635–2642
- [12] Rahhab Z, Faquir NE, Tchetché D et al. Expanding the indications for transcatheter aortic valve implantation. *Nat Rev Cardiol* 2020; 17: 75–84
- [13] Mack MJ, Leon MB, Thourani VH et al. Transcatheter Aortic-Valve Replacement with a Balloon-Expandable Valve in Low-Risk Patients. *New Engl J Med* 2019; 380: 1695–1705
- [14] Kolte D, Vlahakes GJ, Palacios IF et al. Transcatheter Versus Surgical Aortic Valve Replacement in Low-Risk Patients. *J Am Coll Cardiol* 2019; 74: 1532–1540
- [15] Baumgartner H, Falk V, Bax JJ et al. 2017 ESC/EACTS Guidelines for the management of valvular heart disease: The Task Force for the Management of Valvular Heart Disease of the European Society of Cardiology (ESC) and the European Association for Cardio-Thoracic Surgery (EACTS). *European Heart Journal* 2017; 38: 2739–2791
- [16] Franccone M, Budde RPJ, Bremerich J et al. CT and MR imaging prior to transcatheter aortic valve implantation: standardisation of scanning protocols, measurements and reporting – a consensus document by the European Society of Cardiovascular Radiology (ESCR). *Eur Radiol* 2020; 30: 2627–2650
- [17] Salgado RA, Leipsic JA, Shivalkar B et al. Preprocedural CT Evaluation of Transcatheter Aortic Valve Replacement: What the Radiologist Needs to Know. *Radiographics* 2014; 34: 1491–1514
- [18] Blanke P, Weir-McCall JR, Achenbach S et al. Computed tomography imaging in the context of transcatheter aortic valve implantation (TAVI) / transcatheter aortic valve replacement (TAVR): An expert consensus document of the Society of Cardiovascular Computed Tomography. *J Cardiovasc Comput* 2019; 13: 1–20
- [19] Tomasz P, Mikolaj B, Maciej B et al. A comparison of aortic root measurements by echocardiography and computed tomography. *J Thorac Cardiovasc Surg* 2018; 157: 479–486
- [20] Hamdan A, Guetta V, Konen E et al. Deformation Dynamics and Mechanical Properties of the Aortic Annulus by 4-Dimensional Computed Tomography Insights Into the Functional Anatomy of the Aortic Valve Complex and Implications for Transcatheter Aortic Valve Therapy. *J Am Coll Cardiol* 2012; 59: 119–127
- [21] Michelena HI, Prakash SK, Corte AD et al. Bicuspid Aortic Valve. *Circulation* 2014; 129: 2691–2704
- [22] Roberts WC, Ko JM, Garner WL et al. Valve Structure and Survival in Octogenarians Having Aortic Valve Replacement for Aortic Stenosis (± Aortic Regurgitation) With Versus Without Coronary Artery Bypass Grafting at a Single US Medical Center (1993 to 2005). *Am J Cardiol* 2007; 100: 489–495
- [23] Holmes DR, Mack MJ, Kaul S et al. 2012 ACCF/AATS/SCAI/STS Expert Consensus Document on Transcatheter Aortic Valve Replacement. *J Am Coll Cardiol* 2012; 59: 1200–1254
- [24] Members AF, Vahanian A, Alfieri O et al. Guidelines on the management of valvular heart disease (version 2012) The Joint Task Force on the Management of Valvular Heart Disease of the European Society of Cardiology (ESC) and the European Association for Cardio-Thoracic Surgery (EACTS). *Eur Heart J* 2012; 33: 2451–2496
- [25] Ueshima D, Fovino LN, Brener SJ et al. Transcatheter aortic valve replacement for bicuspid aortic valve stenosis with first- and new-generation bioprostheses: A systematic review and meta-analysis. *Int J Cardiol* 2019; 298: 76–82
- [26] Jilaihawi H, Chen M, Webb J et al. A Bicuspid Aortic Valve Imaging Classification for the TAVR Era. *Jacc Cardiovasc Imaging* 2016; 9: 1145–1158
- [27] Zhao ZG, Jilaihawi H, Feng Y et al. Transcatheter aortic valve implantation in bicuspid anatomy. *Nat Rev Cardiol* 2015; 12: 123–128
- [28] Mylotte D, Lefevre T, Søndergaard L et al. Transcatheter Aortic Valve Replacement in Bicuspid Aortic Valve Disease. *J Am Coll Cardiol* 2014; 64: 2330–2339
- [29] Yoon SH, Lefevre T, Ahn JM et al. Transcatheter Aortic Valve Replacement With Early- and New-Generation Devices in Bicuspid Aortic Valve Stenosis. *J Am Coll Cardiol* 2016; 68: 1195–1205

- [30] Ewe SH, Ng ACT, Schuijf JD et al. Location and Severity of Aortic Valve Calcium and Implications for Aortic Regurgitation After Transcatheter Aortic Valve Implantation. *Am J Cardiol* 2011; 108: 1470–1477
- [31] Pio SM, Bax J, Delgado V. How valvular calcification can affect the outcomes of transcatheter aortic valve implantation. *Expert Rev Med Devic* 2020; 17: 1–12
- [32] Fujita B, Kütting M, Seiffert M et al. Calcium distribution patterns of the aortic valve as a risk factor for the need of permanent pacemaker implantation after transcatheter aortic valve implantation. *European Hear J – Cardiovasc Imaging* 2016; 17: 1385–1393
- [33] Clavel MA, Pibarot P, Messika-Zeitoun D et al. Impact of Aortic Valve Calcification, as Measured by MDCT, on Survival in Patients With Aortic Stenosis Results of an International Registry Study. *J Am Coll Cardiol* 2014; 64: 1202–1213
- [34] Pawade T, Clavel MA, Tribouilloy C et al. Computed Tomography Aortic Valve Calcium Scoring in Patients With Aortic Stenosis. *Circulation: Cardiovascular Imaging* 2018; 11: e007146
- [35] Aggarwal SR, Clavel MA, Messika-Zeitoun D et al. Sex Differences in Aortic Valve Calcification Measured by Multidetector Computed Tomography in Aortic Stenosis. *Circulation Cardiovasc Imaging* 2018; 6: 40–47
- [36] Simard L, Côté N, Dagenais F et al. Sex-Related Discordance Between Aortic Valve Calcification and Hemodynamic Severity of Aortic Stenosis. *Circulation Research* 2017; 120: 681–691
- [37] Nishimura RA, Otto CM, Bonow RO et al. 2017 AHA/ACC Focused Update of the 2014 AHA/ACC Guideline for the Management of Patients With Valvular Heart Disease A Report of the American College of Cardiology/American Heart Association Task Force on Clinical Practice Guidelines. *J Am Coll Cardiol* 2017; 70: 252–289
- [38] Overtchouk P, Modine T. A comparison of alternative access routes for transcatheter aortic valve implantation. *Expert Rev Cardiovasc Ther* 2018; 16: 749–756
- [39] Overtchouk P, France CHR, Lille U et al. Alternate Access for TAVI: Stay Clear of the Chest. *Interventional Cardiol Rev* 2018; 13: 145
- [40] Webb JG, Dvir D. Transcatheter Aortic Valve Replacement for Bioprosthetic Aortic Valve Failure. *Circulation* 2013; 127: 2542–2550
- [41] Nalluri N, Atti V, Munir AB et al. Valve in valve transcatheter aortic valve implantation (ViV-TAVI) versus redo – Surgical aortic valve replacement (redo-SAVR): A systematic review and meta-analysis. *J Interv Cardiol* 2018; 31: 661–671
- [42] Blanke P, Soon J, Dvir D et al. Computed tomography assessment for transcatheter aortic valve in valve implantation: The vancouver approach to predict anatomical risk for coronary obstruction and other considerations. *J Cardiovasc Comput* 2016; 10: 491–499
- [43] Lederman RJ, Babaliaros VC, Rogers T et al. Preventing Coronary Obstruction During Transcatheter Aortic Valve Replacement From Computed Tomography to BASILICA. *Jacc Cardiovasc Interventions* 2019; 12: 1197–1216
- [44] Khan JM, Greenbaum AB, Babaliaros VC et al. The BASILICA Trial Prospective Multicenter Investigation of Intentional Leaflet Laceration to Prevent TAVR Coronary Obstruction. *Jacc Cardiovasc Interventions* 2019; 12: 1240–1252
- [45] Landes U, Sathananthan J, Witberg G et al. Transcatheter Replacement of Transcatheter Versus Surgically Implanted Aortic Valve Bioprostheses. *J Am Coll Cardiol* 2021; 77: 1–14
- [46] Chaturvedi A, Hobbs SK, Ling FS et al. MRI evaluation prior to Transcatheter Aortic Valve Implantation (TAVI): When to acquire and how to interpret. *Insights Imaging* 2016; 7: 245–254
- [47] Pannu HK, Alvarez W, Fishman EK. β -Blockers for Cardiac CT: A Primer for the Radiologist. *Am J Roentgenol* 2006; 186: S341–S345
- [48] McParland P, Nicol ED, Harden SP. Cardiac drugs used in cross-sectional cardiac imaging: what the radiologist needs to know. *Clin Radiol* 2010; 65: 677–684
- [49] Annoni AD, Andreini D, Pontone G et al. CT angiography prior to TAVI procedure using third-generation scanner with wide volume coverage: feasibility, renal safety and diagnostic accuracy for coronary tree. *Br J Radiology* 2018; 91: 20180196
- [50] Schicchi N, Fogante M, Pirani PE et al. Third generation dual source CT with ultra-high pitch protocol for TAVI planning and coronary tree assessment: feasibility, image quality and diagnostic performance. *Eur J Radiol* 2019; 122: 108749
- [51] Bittner DO, Arnold M, Klinghammer L et al. Contrast volume reduction using third generation dual source computed tomography for the evaluation of patients prior to transcatheter aortic valve implantation. *Eur Radiol* 2016; 26: 4497–4504
- [52] Gohmann RF, Lauten P, Seitz P et al. Combined Coronary CT-Angiography and TAVI-Planning: A Contrast-Neutral Routine Approach for Ruling-Out Significant Coronary Artery Disease. *J Clin Medicine* 2020; 9: 1623
- [53] Puri R, Chamandi C, Rodriguez-Gabella T et al. Future of transcatheter aortic valve implantation – evolving clinical indications. *Nat Rev Cardiol* 2018; 15: 57–65
- [54] Taramasso M, Pozzoli A, Latib A et al. New devices for TAVI: technologies and initial clinical experiences. *Nat Rev Cardiol* 2014; 11: 157–167
- [55] Wilson R, McNabney C, Weir-McCall JR et al. Transcatheter Aortic and Mitral Valve Replacements. *Radiologic Clinics of North America* 2018; 57: 165–178
- [56] Lell MM, Kachelrieß M. Recent and Upcoming Technological Developments in Computed Tomography: High Speed, Low Dose, Deep Learning, Multienergy. *Invest Radiol* 2020; 55: 8–19
- [57] Franzesi CRT, Ippolito D, Riva L et al. Diagnostic value of iterative reconstruction algorithm in low kV CT angiography (CTA) with low contrast medium volume for transcatheter aortic valve implantation (TAVI) planning: image quality and radiation dose exposure. *Br J Radiology* 2018; 91: 20170802
- [58] Mayr A, Klug G, Reinstadler SJ et al. Is MRI equivalent to CT in the guidance of TAVR? A pilot study. *Eur Radiol* 2018; 28: 4625–4634
- [59] Ruile P, Blanke P, Krauss T et al. Pre-procedural assessment of aortic annulus dimensions for transcatheter aortic valve replacement: comparison of a non-contrast 3D MRA protocol with contrast-enhanced cardiac dual-source CT angiography. *European Hear J – Cardiovasc Imaging* 2016; 17: 458–466
- [60] Lindman BR, Clavel MA, Mathieu P et al. Calcific aortic stenosis. *Nat Rev Dis Primers* 2016; 2: nrdp20166
- [61] Barone-Rochette G, Piérard S, de Ravenstein CDM et al. Prognostic Significance of LGE by CMR in Aortic Stenosis Patients Undergoing Valve Replacement. *J Am Coll Cardiol* 2014; 64: 144–154
- [62] Podlesnikar T, Delgado V, Bax JJ. Cardiovascular magnetic resonance imaging to assess myocardial fibrosis in valvular heart disease. *Int J Cardiovasc Imaging* 2018; 34: 97–112
- [63] Calin A, Mateescu AD, Popescu AC et al. Role of advanced left ventricular imaging in adults with aortic stenosis. *Heart* 2020; 106: 962–969
- [64] Backhaus SJ, Lange T, Beuthner BE et al. Real-time cardiovascular magnetic resonance T1 and extracellular volume fraction mapping for tissue characterisation in aortic stenosis. *J Cardiovasc Magn Reson* 2020; 22: 46
- [65] Puls M, Beuthner BE, Topci R et al. Impact of myocardial fibrosis on left ventricular remodelling, recovery, and outcome after transcatheter aortic valve implantation in different haemodynamic subtypes of severe aortic stenosis. *Eur Heart J* 2020; 41: 1903–1914
- [66] Leon MB, Smith CR, Mack M et al. Transcatheter Aortic-Valve Implantation for Aortic Stenosis in Patients Who Cannot Undergo Surgery. *New Engl J Medicine* 2010; 363: 1597–1607
- [67] Tamburino C, Capodanno D, Ramondo A et al. Incidence and Predictors of Early and Late Mortality After Transcatheter Aortic Valve Implantation in 663 Patients With Severe Aortic Stenosis. *Circulation* 2011; 123: 299–308

- [68] Kodali SK, Williams MR, Smith CR et al. Two-Year Outcomes after Transcatheter or Surgical Aortic-Valve Replacement. *New Engl J Medicine* 2012; 366: 1686–1695
- [69] Salaun E, Jacquier A, Theron A et al. Value of CMR in quantification of paravalvular aortic regurgitation after TAVI. *European Hear J – Cardio-vasc Imaging* 2016; 17: 41–50
- [70] Crouch G, Tully PJ, Bennetts J et al. Quantitative assessment of paravalvular regurgitation following transcatheter aortic valve replacement. *J Cardio Magn Reson* 2015; 17: 32
- [71] Ribeiro HB, Ven FL, Larose É et al. Cardiac magnetic resonance versus transthoracic echocardiography for the assessment and quantification of aortic regurgitation in patients undergoing transcatheter aortic valve implantation. *Heart* 2014; 100: 1924
- [72] Abdelghani M, Soliman Oll, Schultz C et al. Adjudicating paravalvular leaks of transcatheter aortic valves: a critical appraisal. *Eur Heart J* 2016; 37: 2627–2644
- [73] Ribeiro HB, Orwat S, Hayek SS et al. Cardiovascular Magnetic Resonance to Evaluate Aortic Regurgitation After Transcatheter Aortic Valve Replacement. *J Am Coll Cardiol* 2016; 68: 577–585
- [74] Archer GT, Elhawaz A, Barker N et al. Validation of four-dimensional flow cardiovascular magnetic resonance for aortic stenosis assessment. *Sci Rep-Uk* 2020; 10: 10569
- [75] Trauzeddel RF, Löbe U, Barker A] et al. Blood flow characteristics in the ascending aorta after TAVI compared to surgical aortic valve replacement. *Int J Cardiovasc Imaging* 2016; 32: 461–467
- [76] Habib G, Lancellotti P, Antunes MJ et al. 2015 ESC Guidelines for the management of infective endocarditis The Task Force for the Management of Infective Endocarditis of the European Society of Cardiology (ESC) Endorsed by: European Association for Cardio-Thoracic Surgery (EACTS), the European Association of Nuclear Medicine (EANM). *Eur Heart J* 2015; 36: 3075–3128
- [77] Habib G, Erba PA, lung B et al. Clinical presentation, aetiology and outcome of infective endocarditis. Results of the ESC-EORP EURO-ENDO (European infective endocarditis) registry: a prospective cohort study. *Eur Heart J* 2019; 40: 3222–3232
- [78] Sohail MR, Martin KR, Wilson WR et al. Medical Versus Surgical Management of Staphylococcus aureus Prosthetic Valve Endocarditis. *Am J Medicine* 2006; 119: 147–154
- [79] Habib G, Derumeaux G, Avierinos JF et al. Value and limitations of the duke criteria for the diagnosis of infective endocarditis. *J Am Coll Cardiol* 1999; 33: 2023–2029
- [80] Habets J, Tanis W, Reitsma JB et al. Are novel non-invasive imaging techniques needed in patients with suspected prosthetic heart valve endocarditis? A systematic review and meta-analysis. *Eur Radiol* 2015; 25: 2125–2133
- [81] Swart LE, Gomes A, Scholtens AM et al. Improving the Diagnostic Performance of 18F-Fluorodeoxyglucose Positron-Emission Tomography/Computed Tomography in Prosthetic Heart Valve Endocarditis. *Circulation* 2018; 138: CIRCULATIONAHA.118.035032
- [82] Swart LE, Scholtens AM, Tanis W et al. 18F-fluorodeoxyglucose positron emission/computed tomography and computed tomography angiography in prosthetic heart valve endocarditis: from guidelines to clinical practice. *Eur Heart J* 2018; 39: 3739–3749
- [83] Makkar RR, Fontana G, Jilaihawi H et al. Possible Subclinical Leaflet Thrombosis in Bioprosthetic Aortic Valves. *New Engl J Medicine* 2015; 373: 2015–2024
- [84] Chakravarty T, Søndergaard L, Friedman J et al. Subclinical leaflet thrombosis in surgical and transcatheter bioprosthetic aortic valves: an observational study. *The Lancet* 2017; 389: 2383–2392
- [85] Dalén M, Sartipy U, Cederlund K et al. Hypo-Attenuated Leaflet Thickening and Reduced Leaflet Motion in Sutureless Bioprosthetic Aortic Valves. *Journal of the American Heart Association* 2017; 6: e005251
- [86] Kalra A, Raza S, Puri R et al. Subclinical Leaflet Thrombosis and Clinical Outcomes after TAVR: A Systematic Review and Meta-Analysis. *Structural Heart* 2018; 2: 223–228
- [87] Woldendorp K, Doyle MP, Black D et al. Subclinical valve thrombosis in transcatheter aortic valve implantation: A systematic review and meta-analysis. *J Thorac Cardiovasc Surg* 2020; 162: 1491–1499
- [88] Søndergaard L, Backer O, Kofoed KF et al. Natural history of subclinical leaflet thrombosis affecting motion in bioprosthetic aortic valves. *European Heart Journal* 2017; 38: 2201–2207
- [89] Nijenhuis VJ, Brouwer J, Søndergaard L et al. Antithrombotic therapy in patients undergoing transcatheter aortic valve implantation. *Heart* 2019; 105: 742
- [90] Nijenhuis VJ, Brouwer J, Delewi R et al. Anticoagulation with or without Clopidogrel after Transcatheter Aortic-Valve Implantation. *New Engl J Med* 2020; 382: 1696–1707
- [91] Jilaihawi H, Asch FM, Manasse E et al. Systematic CT Methodology for the Evaluation of Subclinical Leaflet Thrombosis. *JACC. Cardiovascular Imaging* 2017; 10: 461–470
- [92] Capodanno D, Petronio AS, Prendergast B et al. Standardized definitions of structural deterioration and valve failure in assessing long-term durability of transcatheter and surgical aortic bioprosthetic valves: a consensus statement from the European Association of Percutaneous Cardiovascular Interventions (EAPCI) endorsed by the European Society of Cardiology (ESC) and the European Association for Cardio-Thoracic Surgery (EACTS). *Eur J Cardio-Thorac* 2017; 52: 408–417
- [93] Didier R, Eltchaninoff H, Donzeau-Gouge P et al. Five-Year Clinical Outcome and Valve Durability After Transcatheter Aortic Valve Replacement in High-Risk Patients. *Circulation* 2018; 138: 2597–2607
- [94] Durand E, Sokoloff A, Urena-Alcazar M et al. Assessment of Long-Term Structural Deterioration of Transcatheter Aortic Bioprosthetic Valves Using the New European Definition. *Circulation Cardiovasc Interventions* 2019; 12: e007597
- [95] Sellers SL, Turner CT, Sathananthan J et al. Transcatheter Aortic Heart Valves Histological Analysis Providing Insight to Leaflet Thickening and Structural Valve Degeneration. *JACC: Cardiovascular Imaging* 2018; 12: 135–145
- [96] Carlidge TRG, Doris MK, Sellers SL et al. Detection and Prediction of Bioprosthetic Aortic Valve Degeneration. *J Am Coll Cardiol* 2019; 73: 1107–1119