



Anti-inflammatory effect of pregabalin on acetic acid-induced colitis in the rats

Azadeh Motavallian^{1,2,*}, Ehsan Zamani^{1,*}, Saba Bouzari¹, Farzam Rezaeyan¹,
Paridokht Karimian³, and Mehdi Evazalipour⁴

¹Department of Pharmacology and Toxicology, School of Pharmacy, Guilan University of Medical Sciences, Rasht, I.R. Iran.

²Department of Gastroenterology and Hepatology, Erasmus University Medical Center, Rotterdam, Netherlands.

³Department of Pathology and Histology, School of Medicine, Guilan University of Medical Sciences, Rasht, I.R. Iran.

⁴Department of Pharmaceutical Biotechnology, School of Pharmacy, Guilan University of Medical Sciences, Rasht, I.R. Iran.

Abstract

Background and purpose: Inflammatory bowel disease (IBD) is a chronic gastrointestinal disease characterized by the inflammation of the intestine. The available medicinal treatments for IBD are not efficacious enough since they exert various adverse effects. Therefore, the search for new therapeutic agents should be continued. The present study aimed to assess the anti-inflammatory effects of pregabalin on acetic acid-induced colitis in rats.

Experimental approach: Using 2 mL of 3% acetic acid solution, colitis was intra-rectally induced in rats. Animals were randomly divided into 6 groups including the normal group, colitis control group, pregabalin treatment groups (30, 50, and 100 mg/kg; i.p., respectively), and dexamethasone treatment group (1 mg/kg; i.p.). Macroscopic, microscopic, and biochemical (myeloperoxidase, tumor necrosis factor-alpha, interleukin-6, and interleukin-1 beta) examinations were used to evaluate the efficacy of pregabalin in the inflamed colon.

Findings/Results: All the applied doses of pregabalin significantly decreased the severity of macroscopic and microscopic colonic damages including ulcer severity, ulcer area, percentage of necrosis, and total colitis index compared to the colitis control group. These results were confirmed by the reduced colonic concentration of tumor necrosis factor-alpha, interleukin-6, interleukin-1 beta, and myeloperoxidase activity.

Conclusion and implications: Results of this study indicated that pregabalin administration has beneficial effects upon the treatment of experimental colitis, which might be partly due to its anti-inflammatory properties.

Keywords: Experimental colitis; Pregabalin; Pro-inflammatory cytokines; Rat.

INTRODUCTION

Inflammatory bowel disease (IBD) including Crohn's disease and ulcerative colitis (UC) causes chronic relapsing intestinal inflammation. Patients with IBD are at an increased risk of colorectal cancer secondary to long-standing gastrointestinal (GI) inflammation (1). Although the etiology of IBD remains unclear, the disease is likely to result from an imbalance of the GI normal flora, over-stimulation of the GI immune system, and

environmental factors (2). Previous literature has revealed disturbances in the regulation of both production and liberation of pro-inflammatory cytokines such as tumor necrosis factor-alpha (TNF- α), interleukin-6 (IL-6), and IL-1 β can gradually lead to the inflammation associated with IBD and cause ulceration of the GI tract, as well as dysentery, abdominal pain, hyperthermia, and weight loss (2).

*Corresponding authors:

A. Motavallian, Tel: +98-1333486477, Fax: +98-1333486475
Email: motavallian@gums.ac.ir; a.motavallian@erasmusmc.nl
E. Zamani, Tel: +98-1333486473, Fax: +98-1333486475
Email: zamani.ehsan@gums.ac.ir

Access this article online



Website: <http://rps.mui.ac.ir>

DOI: 10.4103/1735-5362.329924

Medicinal treatments show no proven effective cures and a high incidence of adverse effects in the treatment of IBD (3). Therefore, it is important to develop new medicines effective in treating the disease.

Gamma-aminobutyric acid (GABA), mainly recognized as a crucial inhibitory neurotransmitter, is widely liberated in the central nervous system (4). GABA has an important role in the regulation of motility, secretion, and immunity of the GI tract and exists in endocrine-like cells of the GI system and neurons of the myenteric plexus. Thus, activities of an endocrine mediator are also expected from GABA (4).

There is evidence to suggest that GABA serves a crucial role in regulating the “neuroimmune dialogue” between the mucosal immune system and nervous system of GI in IBD (5). Reduced serum levels of GABA in the colonic mucosa of patients with IBD indicate a relationship between GABA and the pathogenesis of the disease (6). It seems that the inflammation and ulceration of the GI wall at least partly might be preventable by targeting the neuroimmune dialogue between the immune system of the intestine and GABA (6).

Understanding the pathophysiology of IBD is essential and therefore various experimental IBD models have been developed to resemble the inflammatory condition of the GI tract during IBD. Acetic acid-induced colitis can mimic human UC due to an excessive increase in the liberation of pro-inflammatory cytokines and oxygen-derived free radicals (7).

Pregabalin belongs to a new generation of anti-epileptic drugs called gabapentinoids and has many clinical indications including treatment of partial seizures, alleviating fibromyalgia, and neuropathic pain (8). Although pregabalin is structurally similar to GABA, neither does it bind to GABA receptors nor has any effects on its reuptake. It is believed that gabapentinoids bind to alpha 2 delta ($\alpha 2\delta$) voltage-gated calcium channels (9) and by regulating the influx of calcium into nerve terminals, the liberation of various neurotransmitters such as glutamate, GABA, serotonin, noradrenaline, and substance P is modulated (10,11).

Moreover, it has been shown that pregabalin is capable of inhibiting the secretion of pro-inflammatory cytokines, *in vivo* and *in vitro*, which may extend its immunomodulatory effect in neuroinflammatory conditions such as neuropathic pain conditions, fibromyalgia, and psychiatric disorders (12). To the best of our knowledge, no pharmacological studies have investigated the effects of pregabalin in IBD. This study was designed to evaluate the potential anti-inflammatory effect of pregabalin on an experimental model of colitis.

MATERIALS AND METHODS

Animals

Male Wistar rats (250 ± 20 g, 12-week old) bred in the Animal House of Guilan University of Medical Sciences were used in the present study. The animals were classified into 6 groups and caged under standard housing conditions with a 12/12-h light/dark cycle at 22 ± 2 °C, with access to food and water *ad libitum*. The experimental protocols used in the study were approved by the Ethics Committee of Guilan University of Medical Sciences in accordance with the National Institute of Health Guide for the Care and Use of Laboratory Animals (Ethics No. IR.GUMS.REC.1398.063).

Chemicals

Pregabalin and dexamethasone were purchased from Iran Hormone Pharmaceutical Co. (Iran) and Sobhan Daru Co. (Iran), respectively. Formalin solution (35%), glacial acetic acid, and diethyl ether oxide produced by Merck (Darmstadt, Germany) were used. Colonic levels of proinflammatory cytokines were measured by enzyme-linked immunosorbent assay (ELISA) kits (ZellBio, GmbH, Germany).

Treatment schedule

After a random division of animals into six groups ($n = 6$), the animals were intra-rectally instilled with normal saline (normal group) or acetic acid 3% (colitis control group and treatment groups). Sterile 0.9% saline, dexamethasone (1 mg/kg), and pregabalin (30, 50, and 100 mg/kg) were administered intraperitoneally (i.p.) 24 h before the induction

of colitis and daily afterward to the colitis control group, the dexamethasone, and the pregabalin groups, respectively. The animals were sacrificed three days after the induction of colitis. Dosage selection was specified based on previous studies (13-15).

Induction of colitis

Each animal fasted for 36 h with free access to water. We used a method introduced by Mahdavi *et al.* to induce colitis (16). Animals were lightly anesthetized with ether. Then, a polyethylene catheter was inserted into the rectum, 8 cm distal to the anus, and colitis was induced by an intracolonic single instillation of 2 mL of acetic acid 3% in normal saline (v/v). The normal group received an equivalent volume of normal saline. To avoid anal leakage, the animals were oriented head-down in a vertical position for 2-3 min and subsequently returned to their cages with free access to food and water.

Macroscopic assessment

Animals' body weight and body weight loss percentages were assessed during the experiment. The animals were euthanized 72 h after colitis induction, and the abdomens were then opened. An 8-cm portion of the distal colon of each animal was removed and gently washed with normal saline. After weighing each segment, the weight/length ratio of each sample was calculated. Ulcer severity, the surface area of the ulcers, and the percentage of necrosis were determined as previously described by Motavallian Naeini *et al.* (17). The colon was then sectioned into 4 segments of which 3 were instantly frozen in liquid nitrogen for biochemical analysis and the other one was fixed in a 10% buffered formalin solution for histopathologic evaluation.

Microscopic histopathologic assessment

As mentioned earlier, one of the colonic segments was fixed in a 10% buffered formalin solution. After dehydrating each segment, we embedded it in paraffin and cut it into 4 μm -thick portions. These portions were subsequently stained with hematoxylin and eosin (H&E) and analyzed by an experienced pathologist blinded to experimental groups.

The total colitis index was calculated by summing 3 sub-scores (inflammation severity, inflammation extent, crypt damage) according to the criteria described by Cooper *et al.* (18) and Dieleman *et al.* (19)

Evaluation of colonic myeloperoxidase activity

According to the method introduced by Motavallian *et al.* (17), myeloperoxidase (MPO) activity was measured to evaluate the extent of neutrophil infiltration into colonic tissue during acetic acid-induced colon damage. Results were reported as changes in absorbance/min/mg of the wet tissue.

Assessment of pro-inflammatory cytokines in colon

The levels of TNF- α , IL-1 β , and IL-6 of colon tissue were measured using ELISA assays as described previously by Nacife *et al.* (20).

Statistical analysis

The statistical analysis was carried out using the SPSS statistical package (version 17). Parametric data, expressed as mean \pm SEM, were analyzed by one-way analysis of variance (ANOVA) followed by Tukey post hoc test. Furthermore, Non-parametric data, presented as median (range), was analyzed using the Kruskal-Wallis test and post hoc Mann-Whitney U test. A *P* value < 0.05 was considered statistically significant.

RESULTS

Pregabalin reduces body weight loss percentage and colonic macroscopic injuries in experimental colitis

While the mucosal appearance of the colon tissue remained quite intact in the normal group, there were severe macroscopic damages including inflammation, deep ulceration, necrosis, and thickened colon wall in the colitis control group. Moreover, after four days of induction of colitis, animals in the colitis control and the treatment groups lost a significant amount of weight, compared with the normal group. Although the same manner was observed in the treatment groups,

bodyweight loss percentage was significantly lower in dexamethasone- (1 mg/kg) and pregabalin- (30, 50, and 100 mg/kg) treated animals in comparison with the colitis control group (Table 1). In contrast to the colitis control group, there was a significant decrease in ulcer severity and ulcer area in dexamethasone- (1 mg/kg) and pregabalin- (30, 50, and 100 mg/kg) treated rats.

As depicted in Table 1, the colonic weight/length ratio in pregabalin groups was considerably diminished, in comparison with the colitis control group. As expected, colon samples of dexamethasone-treated rats demonstrated quite a low weight/length ratio as well. In addition, the calculated percentage of necrosis of the samples extracted from rats receiving pregabalin and dexamethasone was significantly lower than that in the colitis-control group.

Pregabalin reduces colonic microscopic injuries in experimental colitis

As illustrated by Fig. 1, high transmural inflammation and/or diffuse necrosis and formation of granulomas and the infiltration of neutrophils into colon walls indicated extensive tissue damage in the acetic acid-control group. By contrast, colon mucosa remained intact and the architecture of epithelium did not exhibit any signs of distortion in the normal group. Treatment with dexamethasone and pregabalin exhibited a significant decrease in total colitis

index (crypt damage, severity of inflammation, and extent of inflammation) of damaged colons, in comparison with that in the colitis control group (Table 1). Moreover, infiltration of inflammatory cells in lamina propria was reduced in the treatment groups and re-epithelization of the mucosal layer was observed in the aforementioned groups.

Pregabalin reduces MPO activity and proinflammatory cytokines levels in inflamed colonic tissues

As shown in Table 2, the colitis control group showed a considerable increase in MPO activity compared to the normal group and this result was supported by the observed massive neutrophil infiltration in colon samples of the colitis control group. This parameter was significantly reduced in rats receiving dexamethasone or pregabalin.

As can be observed in Table 2, the contents of TNF- α , IL-1 β , and IL-6 significantly increased in the colitis control group, as compared with those of the normal group. Treatment with dexamethasone or pregabalin significantly reduced the content of TNF- α in the examined specimens. The level of IL-6 in the animals treated with dexamethasone and pregabalin was significantly reduced, as compared to the colitis control group. Moreover, treatment with dexamethasone and pregabalin caused a significant reduction in the content of IL-1 β in colonic tissues.

Table 1. Effects of pregabalin (30, 50, and 100 mg/kg, i.p.) on macroscopic and histologic parameters of acetic acid-induced colitis in rats. All data are presented as means \pm SEM (n = 6) and analyzed by ANOVA followed by Tukey post hoc test except for the data of ulcer severity which have been expressed as median (minimum-maximum values) and analyzed by Kruskal-Wallis non-parametric test

Groups	Colonic weight /length (g/cm)	Body weight loss after 4 days (%)	Ulcer severity (0-15)	Total colitis index (0-10)	Ulcer area (cm ²)	Necrosis (%)
Normal	0.09 \pm 0.01	-2.63 \pm 0.52	0	0	0	0
Colitis control	0.27 \pm 0.01	10.01 \pm 0.87	11 (9-14)	9 \pm 0.25	5.86 \pm 0.33	53.3 \pm 2.23
Dexamethasone	0.19 \pm 0.01**	5.13 \pm 0.41**	4.5 (3-7)*	5.5 \pm 0.84**	2.43 \pm 0.4***	22.88 \pm 6.03**
Pregabalin (30 mg/kg)	0.21 \pm 0.01*	6.47 \pm 0.47 *	5.5 (4-8)	6.3 \pm 0.61*	3.41 \pm 0.54*	31.65 \pm 4.37*
Pregabalin (50 mg/kg)	0.20 \pm 0.01*	6.55 \pm 0.86*	5 (3-7)*	6 \pm 0.51*	2.94 \pm 0.65**	28.98 \pm 7.04**
Pregabalin (100 mg/kg)	0.19 \pm 0.01**	4.73 \pm 1.22**	5 (3-7)*	5.6 \pm 0.76**	2.60 \pm 0.60**	26.66 \pm 6.03**

* $P < 0.05$, ** $P < 0.01$, and *** $P < 0.001$ indicate significant difference compared to the colitis-control group.

Table 2. Colonic levels of Interleukins 6 and 1 β , tumor necrosis factor α , and myeloperoxidase activity in rats with induced colitis after three consecutive days of the treatments quantified by ELISA. Data are presented as mean \pm SEM, (n = 6).

Group	Interleukin 6	Interleukin 1 β	Tumor necrosis factor α	Myeloperoxidase activity
Normal	26.18 \pm 1.69***	3.73 \pm 0.16***	2.75 \pm 0.2***	1.21 \pm 0.13***
Colitis control	78.96 \pm 2.86	12.65 \pm 0.34	6.00 \pm 0.24	3.7 \pm 0.24
Dexamethasone	59.56 \pm 2.8***	9.71 \pm 0.46***	3.9 \pm 0.17***	2.03 \pm 0.21***
Pregabalin (30 mg/kg)	64.88 \pm 2.7**	10.58 \pm 0.42*	4.5 \pm 0.28**	2.44 \pm 0.3**
Pregabalin (50 mg/kg)	67.63 \pm 2.13*	10.71 \pm 0.47*	4.5 \pm 0.25**	2.77 \pm 0.13*
Pregabalin (100 mg/kg)	59.68 \pm 2.82***	9.93 \pm 0.53**	4.1 \pm 0.30***	2.07 \pm 0.19***

* $P < 0.05$, ** $P < 0.01$, and *** $P < 0.001$ indicate significant differences compared to the colitis-control group.

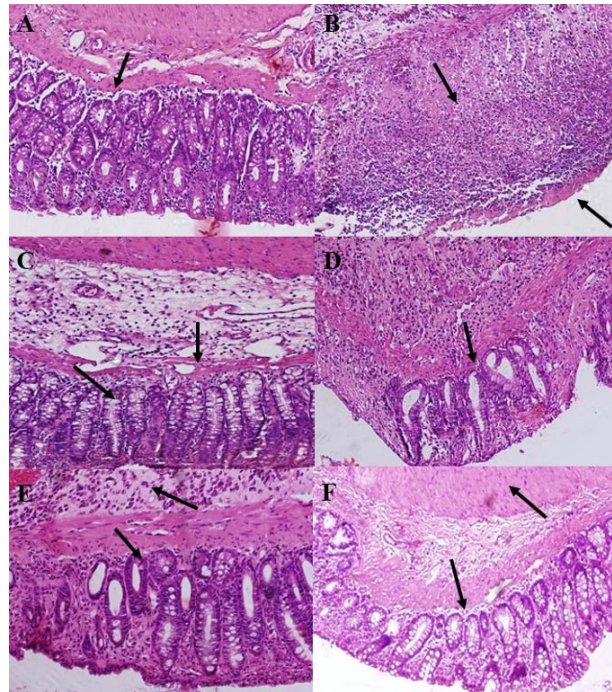


Fig. 1. Microscopic presentation of the colon in acetic acid-induced colitis in rats (hematoxylin and eosin staining). (A) Normal group: normal mucus layer and crypts; (B) acetic acid control group: destruction of epithelium, architectural deformity of the crypts and infiltration of inflammatory cells; (C) dexamethasone (1 mg/kg): mild to moderate inflammation of mucosa and submucosa and mucosal inflammatory cell infiltrates; (D-F) pregabalin (30, 50, and 100 mg/kg, respectively): epithelial regeneration and reduction in the number of inflammatory cells in lamina propria.

DISCUSSION

In the present study, we demonstrated that administration of pregabalin in all of the doses (30, 50, and 100 mg/kg) produced noticeable anti-inflammatory effects on acetic acid-induced colitis in the rats. Pregabalin acts by suppressing MPO activity and key pro-inflammatory cytokines which are involved in the pathology of UC and improve morphological features such as macroscopic and microscopic lesion scores and wet weight length ratio during colitis.

Recently, the need for realizing the pathophysiology of IBD has been increasing by using several experimental animal models of UC. Acetic acid-induced colitis in rats has widely been demonstrated to share similarities with human IBD regarding the involved inflammatory mediators and pathophysiology (7). Following intra-rectal administration, acetic acid decreases the integrity of the GI tract wall leading to transmural inflammation, ulceration, necrosis, and an increase in its permeability. These consequences progressively lead to neutrophil infiltration,

activation of lipid peroxidase and cyclooxygenase pathways, and liberation of pro-inflammatory cytokines thus demonstrating the characteristics of human IBD (7). Recent investigations have intensely emphasized the critical role of inflammatory cytokines such as IL-6, IL-1 β , and TNF- α in the pathogenesis of IBD and their downstream inflammatory cascade (2). The high level of cytokines in our animal model of colitis was in agreement with findings of the previous investigations exhibiting the high pro-inflammatory cytokines contents in experimental colitis. Furthermore, we demonstrated that MPO activity was increased after the induction of the colitis in rats, which is expected to be similar in human colitis.

Pregabalin, as a gabapentinoid, was initially developed as adjunctive therapy in partial seizures but now is widely used in the treatment of neuropathies ascribed to diabetes, injuries of the spinal cord, and herpes simplex infection (8). Pregabalin attenuates inflammation by suppressing the action of pro-inflammatory cytokines (12), limiting the damages after oxidative stress (21), and inhibiting neutrophil recruitment (22). In a study performed by Yamaguchi *et al.* the concentrations of IL-6 and IL-8 were diminished in human glioblastoma cells following the administration of pregabalin, by the regulation of substance P (SP)-mediated neurokinin-1 receptor (NK1R) response. The latter is the consequence of inhibition of nuclear factor kappa B (NF- κ B) and p38 mitogen-activated protein kinase due to the decreased liberation of SP (23). In addition, Abu-rish *et al.* demonstrated the peripheral anti-inflammatory properties of pregabalin on cytokine secretion and spleen inflammation in lipopolysaccharide/concanavalin A-induced murine models of inflammation (12). Although Diop *et al.* noted the antiallodynic activity of pregabalin in trinitrobenzene sulfonic acid-induced colonic allodynia, they reported that subcutaneous injection of pregabalin at 200 mg/kg did not decrease MPO activity in the inflamed colon (24). In contrast to their findings, our results showed that even the lower doses of pregabalin significantly decreased neutrophil infiltration in experimental colitis. It seems that different pharmacokinetic properties

of pregabalin following i.p. and subcutaneous routes of administration might be responsible for the different results.

The N-methyl-D-aspartate receptor (NMDA) is an ion channel protein in nerve cells that binds to glutamate. These receptors have also been proven to be present in the enteric nervous system (25). In addition, overexpression of NMDA receptors has been demonstrated following colonic inflammation (26). By binding to these receptors, glutamate results in reactive oxygen species accumulation, NF- κ B activation and augmented levels of pro-inflammatory cytokines such as TNF- α and IL-1 β (27). NMDA receptor antagonist therapy successfully normalizes the microcirculation and bowel movements in experimental colitis (28). Kato *et al.* reported that pregabalin treatment can attenuate NMDA receptor-mediated synaptic transmission in neuropathic mice (29). Considering the inhibitory effect of pregabalin in the release of glutamate and its effect on NMDA receptors, it seems that pregabalin might be able to attenuate experimental colitis, at least partly through its effect on NMDA receptors signaling pathways.

Cyclooxygenase-2 overexpression has been reported previously in the inflamed, non-dysplastic mucosa in IBD patients (30,31). Pregabalin, through inhibition of NF- κ B and its target genes such as cyclooxygenase-2, decreases vascular permeability, leukocyte recruitment, and release of pro-inflammatory cytokines (32). Based on the aforementioned studies, it seems that several mechanisms might be involved in the anti-inflammatory properties of pregabalin; nevertheless, further investigations are required to explain the precise pathways.

Although acetic acid is a reliable model of induction of colitis which mimics the pathological characteristics of human IBD, some limitations like the involvement of non-specific immunity lie in the model (7). Thus, further research is required to evaluate the effects of this drug following a longer period of experiment and other routes of administration in both acute and chronic animal models of colitis.

CONCLUSION

In conclusion, the findings of this study confirmed that pregabalin has a profitable effect in the treatment of experimental colitis at least partly through reducing pro-inflammatory cytokines and MPO activity. The anti-inflammatory activity of pregabalin in an experimental model of UC corroborates findings concerning the clinical efficacy of the drug as an analgesic agent in patients with acute inflammatory pain and visceral hypersensitivity in IBS (33). Due to the low incidence of the adverse effect of pregabalin, it is expected that pregabalin might be beneficial in the therapy of human colitis. However, further research is needed to evaluate the efficacy of this drug in patients with IBD.

Acknowledgements

The research was financially supported by the Vice Chancellery of Research of Guilan University of Medical Sciences, Rasht, Iran through Grant No. 178-150.

Conflict of interest statement

The authors declared no conflict of interest in this study.

Authors' contribution

A. Motavallian contributed to data collection, data analyses, and drafting the manuscript; S. Buzari and F. Rezaeyan contributed to data collection and drafting the manuscript; E. Zamani contributed to the statistical analysis and drafting the manuscript; P. Karimian and M. Evazalipour contributed to the data collection and drafting the manuscript. All authors read and approved the final manuscript.

REFERENCES

- Axelrad JE, Lichtiger S, Yajnik V. Inflammatory bowel disease and cancer: the role of inflammation, immunosuppression, and cancer treatment. *World J Gastroenterol.* 2016;22(20):4794-4801. DOI: 10.3748/wjg.v22.i20.4794.
- Strober W, Fuss IJ. Proinflammatory cytokines in the pathogenesis of inflammatory bowel diseases. *Gastroenterology.* 2011;140(6):1756-1767. DOI: 10.1053/j.gastro.2011.02.016.
- Braus NA, Elliott DE. Advances in the pathogenesis and treatment of IBD. *Clin Immunol.* 2009;132(1):1-9. DOI: 10.1016/j.clim.2009.02.006.
- Ma X, Sun Q, Sun X, Chen D, Wei C, Yu X, *et al.* Activation of GABA(A) receptors in colon epithelium exacerbates acute colitis. *Front Immunol.* 2018;9:987-1004. DOI: 10.3389/fimmu.2018.00987.
- Zizzo MG, Serio R. Therapeutic potential of the gabaergic system in ulcerative colitis: current status and perspectives. *Dig Dis Sci.* 2017;62(10):2780. DOI: 10.1007/s10620-017-4709-5.
- Aggarwal S, Ahuja V, Paul J. Attenuated GABAergic signaling in intestinal epithelium contributes to pathogenesis of ulcerative colitis. *Dig Dis Sci.* 2017;62(10):2768-2779. DOI: 10.1007/s10620-017-4662-3.
- Sanei MH, Hadizadeh F, Adibi P, Alavi SA. Inflammatory cells' role in acetic acid-induced colitis. *Adv Biomed Res.* 2014;3:193. DOI: 10.4103/2277-9175.140666.
- Manjushree N, Chakraborty A, Shashidhar K, Narayanaswamy S. A review of the drug pregabalin. *Int J Basic Clin Pharmacol.* 2015;4(4):601-605. DOI: 10.18203/2319-2003.ijbcp20150359.
- Sills GJ. The mechanisms of action of gabapentin and pregabalin. *Curr Opin Pharmacol.* 2006;6(1):108-113. DOI: 10.1016/j.coph.2005.11.003.
- Marks DM, Patkar AA, Masand PS, Pae CU. Does pregabalin have neuropsychotropic effects?: A short perspective. *Psychiatry Investig.* 2009;6(2):55-58. DOI: 10.4306/pi.2009.6.2.55.
- Kumar N, Laferriere A, Yu JS, Leavitt A, Coderre TJ. Evidence that pregabalin reduces neuropathic pain by inhibiting the spinal release of glutamate. *J Neurochem.* 2010;113(2):552-561. DOI: 10.1111/j.1471-4159.2010.06625.x.
- Abu-rish EY, Mansour AT, Mansour HT, Dahabiyeh LA, Aleidi SM, Bustanji Y. Pregabalin inhibits *in vivo* and *in vitro* cytokine secretion and attenuates spleen inflammation in lipopolysaccharide/Concanavalin A-induced murine models of inflammation. *Sci Rep.* 2020;10(1):4007-4017. DOI: 10.1038/s41598-020-61006-1.
- Nunes EA, Canever L, Oliveira LD, Luca R, Quevedo J, Zugno A, *et al.* Effects of pregabalin on behavioral alterations induced by ketamine in rats. *Braz J Psychiatry.* 2012;34(3):329-333. DOI: 10.1016/j.rbp.2012.02.005.
- Salimzade A, Hosseini-Sharifabad A, Rabbani M. Comparative effects of chronic administrations of gabapentin, pregabalin and baclofen on rat memory using object recognition test. *Res Pharm Sci.* 2017;12(3):204-210. DOI: 10.4103/1735-5362.207201.
- Motavallian A, Minaiyan M, Rabbani M, Mahzouni P, Andalib S. Anti-inflammatory effects of alosetron mediated through 5-HT(3) receptors on experimental colitis. *Res Pharm Sci.* 2019;14(3):228-236. DOI: 10.4103/1735-5362.258489.
- Mahdavi NS, Talebi A, Minaiyan M. Ameliorative effect of galantamine on acetic acid-induced colitis in rats. *Res Pharm Sci.* 2019;14(5):391-399. DOI: 10.4103/1735-5362.268199.

17. Motavallian-Naeini A, Minaiyan M, Rabbani M, Mahzuni P. Anti-inflammatory effect of ondansetron through 5-HT₃ receptors on TNBS-induced colitis in rat. *EXCLI J*. 2012;11:30-44. PMID: 27350767.
18. Cooper H, Murthy S, Shah RS, Sedergran DJ. Clinicopathologic study of dextran sulfate sodium experimental murine colitis. *Lab Invest*. 1993;69(2):238-249. PMID: 8350599.
19. Dieleman LA, Palmén MJ, Akol H, Bloemena E, Pena AS, Meuwissen SG. Chronic experimental colitis induced by dextran sulfate sodium (DSS) is characterized by Th1 and Th2 cytokines. *Clin Exp Immunol*. 1998;114(3):385-391. DOI: 10.1046/j.1365-2249.1998.00728.x.
20. Nacife VP, Soeiro MN, Gomes RN, D'Avila H, Castro-Faria Neto HC, Meirelles MN. Morphological and biochemical characterization of macrophages activated by carrageenan and lipopolysaccharide *in vivo*. *Cell Struct Funct*. 2004;29(2):27-34. DOI: 10.1247/csf.29.27.
21. Aşçı S, Demirci S, Aşçı H, Doğuç DK, Onaran İ. Neuroprotective effects of pregabalin on cerebral ischemia and reperfusion. *Balkan Med J*. 2016;33(2):221-227. DOI: 10.5152/balkanmedj.2015.15742.
22. Kilic FS, Kaygisiz B, Aydin S, Yildirim C, Karimkhani H, Oner S. Pregabalin attenuates carrageenan-induced acute inflammation in rats by inhibiting proinflammatory cytokine levels. *Eurasian J Med*. 2018;50(3):156-159. DOI: 10.5152/eurasianjmed.2018.17261.
23. Yamaguchi K, Kumakura S, Someya A, Iseki M, Inada E, Nagaoka I. Anti-inflammatory actions of gabapentin and pregabalin on the substance P-induced mitogen-activated protein kinase activation in U373 MG human glioblastoma astrocytoma cells. *Mol Med Rep*. 2017;16(5):6109-6115. DOI: 10.3892/mmr.2017.7368.
24. Diop L, Raymond F, Fargeau H, Petoux F, Chovet M, Doherty AM. Pregabalin (CI-1008) inhibits the trinitrobenzene sulfonic acid-induced chronic colonic allodynia in the rat. *J Pharmacol Exp Ther*. 2002;302(3):1013-1022. DOI: 10.1124/jpet.302.3.1013.
25. Zhou Q, Nicholas Verne G. NMDA Receptors and colitis: basic science and clinical implications. *Rev Analg*. 2008;10(1):33-43. DOI: 10.3727/154296108783994013.
26. Zhou Q, Caudle RM, Price DD, Del Valle-Pinero AY, Verne GN. Selective up-regulation of NMDA-NR1 receptor expression in myenteric plexus after TNBS induced colitis in rats. *Mol Pain*. 2006;2(1):3-12. DOI: 10.1186/1744-8069-2-3.
27. Ma T, Cheng Q, Chen C, Luo Z, Feng D. Excessive activation of NMDA receptors in the pathogenesis of multiple peripheral organs *via* mitochondrial dysfunction, oxidative stress, and inflammation. *SN Compr Clin Med*. 2020;2(5):551-569. DOI: 10.1007/s42399-020-00298-w.
28. Érces D, Varga G, Fazekas B, Kovács T, Tókécs T, Tiszlavicz L, *et al.* N-methyl-D-aspartate receptor antagonist therapy suppresses colon motility and inflammatory activation six days after the onset of experimental colitis in rats. *Eur J Pharmacol*. 2012;691(1-3):225-234. DOI: 10.1016/j.ejphar.2012.06.044.
29. Kato E, Matsuzawa R, Kobayashi S, Fukushima T, Maekawa M, Hori Y. Effects of pregabalin on spinal d-serine content and NMDA receptor-mediated synaptic transmission in mice with neuropathic pain. *Neurosci Lett*. 2017;636:270-275. DOI: 10.1016/j.neulet.2016.10.053.
30. Hamilton MJ, Frei SM, Stevens RL. The multifaceted mast cell in inflammatory bowel disease. *Inflamm Bowel Dis*. 2014;20(12):2364-2378. DOI: 10.1097/MIB.0000000000000142.
31. Reddy ST, Wadleigh DJ, Herschman HR. Transcriptional regulation of the cyclooxygenase-2 gene in activated mast cells. *J Biol Chem*. 2000;275(5):3107-3113. DOI: 10.1074/jbc.275.5.3107.
32. Park S, Ahn ES, Han DW, Lee JH, Min KT, Kim H, Hong YW. Pregabalin and gabapentin inhibit substance P-induced NF- κ B activation in neuroblastoma and glioma cells. *J Cell Biochem*. 2008;105(2):414-423. DOI: 10.1002/jcb.21837.
33. Saito YA, Almazar AE, Tilkes KE, Choung RS, Van Norstrand MD, Schleck CD, *et al.* Randomised clinical trial: pregabalin vs placebo for irritable bowel syndrome. *Aliment Pharmacol Ther*. 2019;49(4):389-397. DOI: 10.1111/apt.15077.