

# EUR Research Information Portal

## Intrahepatic immune response in chronic viral hepatitis

### Publication status and date:

Published: 22/12/2004

### Document Version

Publisher's PDF, also known as Version of record

### Citation for the published version (APA):

Tang, T.J. (2004). *Intrahepatic immune response in chronic viral hepatitis*. [Doctoral Thesis, Erasmus University Rotterdam]. Erasmus Universiteit Rotterdam (EUR).

[Link to publication on the EUR Research Information Portal](#)

### Terms and Conditions of Use

Except as permitted by the applicable copyright law, you may not reproduce or make this material available to any third party without the prior written permission from the copyright holder(s). Copyright law allows the following uses of this material without prior permission:

- you may download, save and print a copy of this material for your personal use only;
- you may share the EUR portal link to this material.

In case the material is published with an open access license (e.g. a Creative Commons (CC) license), other uses may be allowed. Please check the terms and conditions of the specific license.

### Take-down policy

If you believe that this material infringes your copyright and/or any other intellectual property rights, you may request its removal by contacting us at the following email address: [openaccess.library@eur.nl](mailto:openaccess.library@eur.nl). Please provide us with all the relevant information, including the reasons why you believe any of your rights have been infringed. In case of a legitimate complaint, we will make the material inaccessible and/or remove it from the website.

**INTRAHEPATIC IMMUNE RESPONSE  
IN CHRONIC VIRAL HEPATITIS**

**An immunohistochemical study**

**T. J. Tang**



**INTRAHEPATIC IMMUNE RESPONSE  
IN CHRONIC VIRAL HEPATITIS**

**An immunohistochemical study**

**T. J. Tang**

ISBN 90-8559-016-7

Printed by Optima Grafische Communicatie, Rotterdam, The Netherlands

This study was performed at the department of Gastroenterology and Hepatology of the Erasmus MC, University Hospital Rotterdam, the Netherlands. Financial support for this thesis was kindly given by the department of Gastroenterology and Hepatology of Erasmus MC, AstraZeneca, Bristol-Myers Squibb, GlaxoSmithKline, Janssen-Cilag, Nederlandse Vereniging voor Hepatologie, Roche, Tramedico and Schering Plough.

© T.J. Tang, The Netherlands, 2004. All rights reserved.

No part of this thesis may be reproduced or transmitted, in any form or by any means, without prior written permission of the author.

# **Intrahepatic Immune Response in Chronic Viral Hepatitis**

## **An immunohistochemical study**

*Intrahepatische Immuun Respons in Chronische Virale Hepatitis*  
*Een immunohistochemische studie*

### **PROEFSCHRIFT**

ter verkrijging van de graad van doctor  
aan de Erasmus Universiteit Rotterdam  
op gezag van de Rector Magnificus  
Prof.dr. S.W.J. Lamberts  
en volgens besluit van het College voor Promoties.

De openbare verdediging zal plaatsvinden op  
woensdag 22 december 2004 om 15.45 uur

door

**Thjon-Ji Tang**

geboren te Rotterdam

## **PROMOTIECOMMISSIE**

Promotor: Prof.dr. S.W. Schalm

Overige leden: Prof.dr. H. A. Drexhage  
Prof.dr. A. D. M. E. Osterhaus  
Prof. J. H. P. Wilson

Copromotoren: Dr. H. L. A. Janssen  
Dr. J. Kwekkeboom

*voor Sahn  
voor mijn ouders*





## **CONTENTS**

Chapter 1	Introduction	<b>9</b>
Chapter 2	The role of intrahepatic immune effector cells in inflammatory liver injury and viral control during chronic hepatitis B infection	<b>23</b>
Chapter 3	Intrahepatic CD8 T-lymphocytes and HBV core expression in relation to response to antiviral therapy for chronic hepatitis B patients	<b>41</b>
Chapter 4	The intrahepatic immune response during chronic hepatitis B infection can be monitored by the fine-needle aspiration biopsy technique	<b>57</b>
Chapter 5	Intrahepatic CD8 T-lymphocyte response is important for therapy-induced viral clearance in chronic hepatitis B patients	<b>67</b>
Chapter 6	Monitoring intrahepatic CD8 <sup>+</sup> T-cells by fine-needle aspiration cytology in chronic hepatitis C infection	<b>85</b>
Chapter 7	Reduced numbers of mature myeloid dendritic cells in hepatic lymph nodes of patients with chronic HBV- or HCV-infection	<b>99</b>
Chapter 8	Summary and conclusions	<b>115</b>
	Samenvatting en conclusies	<b>121</b>
	Appendix	<b>127</b>
	Dankwoord	<b>137</b>
	Curriculum vitae	<b>139</b>
	Bibliography	<b>141</b>
	Abbreviations	<b>143</b>



# Chapter 1

## Introduction



## Hepatitis B virus

The hepatitis B virus (HBV) is a 42 nm viral particle and belongs to a family of closely related DNA viruses called the hepadnaviruses [1-2]. All the hepadnaviruses have similar hepatotropism and life cycles in their hosts [3]. It is an enveloped small circular, partially double stranded DNA virus.

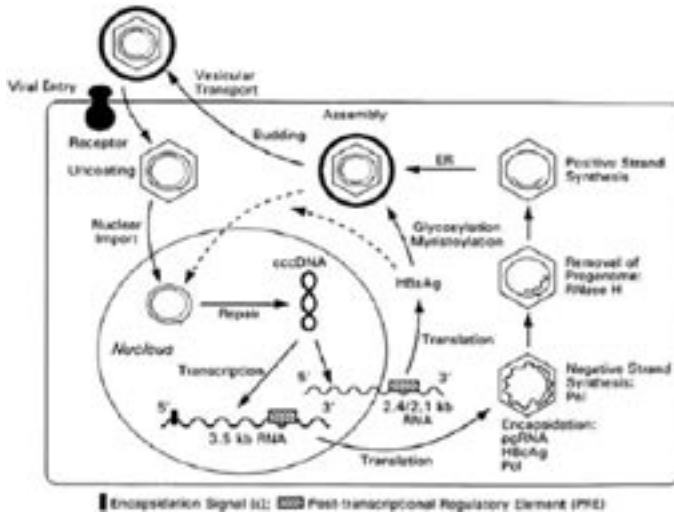
The viral genome has a length of approximately 3200 base pairs that encodes four open reading frames (ORF). These are the pre-Surface (pre-S) and Surface (S) gene, the pre-Core (pre-C) and Core (C) gene, the X-gene and the Polymerase (P)-gene. The pre-S and pre-C genes are upstream regions of the S and C genes [2]. The viral envelope encoded by the S gene contains three distinct configurations synthesized in all infected persons, termed the large, middle and major envelope proteins, which are produced by beginning transcription at, respectively, the pre-S1, pre-S2 or the S gene. The pre-S1 and pre-S2 represent two of the more immunogenic portions of hepatitis B surface antigen (HBsAg) [4]. The development of cellular and humoral immunity to HBsAg is protective [5], and recombinant HBsAg provides the basis for the HBV vaccines currently available. The hepatitis B core antigen (HBcAg) is the nucleocapsid that encloses the viral DNA. When HBcAg-derived peptides are presented by MHC-molecules present on the surface of hepatocytes, they can initiate a cellular immune response that is important for viral clearance [6].

A signal sequence in the pre-C region of the genome is thought to guide the HBcAg precursor to the endoplasmic reticulum of the hepatocyte, where the hepatitis e antigen (HBeAg) polypeptide is produced by cleavage of the p25 precursor in its basic C-terminal region. Subsequently, it is exported from the liver and serves as marker of active viral replication [7]. HBeAg may act as a tolerogen, since its presence in the circulation has been associated with a diminished cellular immune response. This may be due to its close resemblance to HBcAg, the main target of the immune response [8-10].

The longest open reading frame of the HBV genome is the P-gene, which overlaps the other genes. The P-gene encodes the HBV DNA polymerase, which also serves a reverse-transcriptase function, since replication requires RNA intermediates.

The X-gene is the smallest HBV open reading frame and encodes two proteins that serve as transcriptional transactivators, enhancing the transcription as well as the replication of HBV.

Hepatocytes are the primary replication site for HBV. Following receptor binding of HBV particles, the virions enter the hepatocyte and deliver their nucleocapsids to the cytoplasm. These then translocate to the nucleus of the hepatocyte, where the virus DNA is repaired and converted to covalent closed circular DNA (cccDNA). Host RNA polymerase then transcribes the cccDNA, and the resulting RNA's are translated. Viral pregenomic RNA's are packaged in the cytoplasm into core particles with one HBV polymerase protein. Within this complex DNA synthesis is started: a minus DNA strand will be formed and subsequently the plus strand is synthesized. Small, middle and large HBsAg transcripts are transported to the endoplasmic



**Figure 1.** HBV replication in hepatocyte

reticulum to envelop the core particles. The enveloped virions are subsequently secreted via the vesicular transport system into serum.

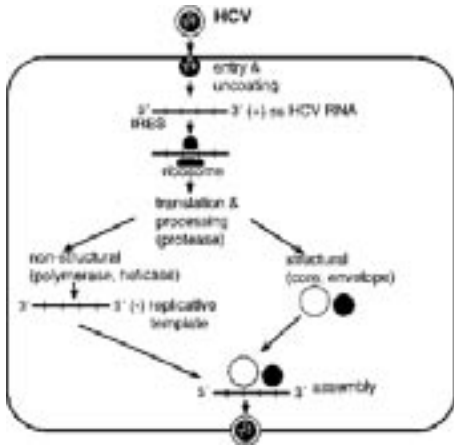
### Hepatitis C virus

The genetically complex hepatitis C virus (HCV) is an RNA-virus, and has recently been classified as a Hepacivirus of the Flaviviridae family [11-12]. It is approximately 50 nm in diameter and the 9.6 kb single-stranded, positive sense RNA genome encodes a single polyprotein of about 3010 aminoacids in length, which is processed by proteases into structural (S; at least three) and nonstructural (NS) (six) proteins.

HCV is classified into 6 major genotypes and several subtypes [13], having possible significance in both the route of transmission and the histological activity of viral hepatitis [14-15]. A specific characteristic of the HCV is the high variability of its nucleotide sequence. The viral RNA-dependent RNA polymerase is mainly responsible for this inaccuracy, which leads to formation of quasispecies [12].

HCV attaches to the cell surface of hepatocytes mainly binding of HCV envelope protein E2 to CD81 expressed on hepatocytes, which is a putative HCV receptor that belongs to the tetraspanin family [16]. Attachment is followed by entry into the cell. HCV replicates in the cytoplasm of the hepatocytes. The virus is uncoated, exposing the positive-strand RNA genome.

After translation, a single large polyprotein is produced, which is to be cleaved into S and NS proteins. The positive-strand serves as a template for generating a negative-strand RNA, which after binding to the NS proteins forms a replicating complex producing further positive-strand RNA. Subsequently, final viral assembly occurs in the Golgi-cisternae with a covering by a lipid envelope followed by secretion [17].



**Figure 2.** HCV replication in hepatocyte

### Immunopathogenesis of chronic hepatitis B and C

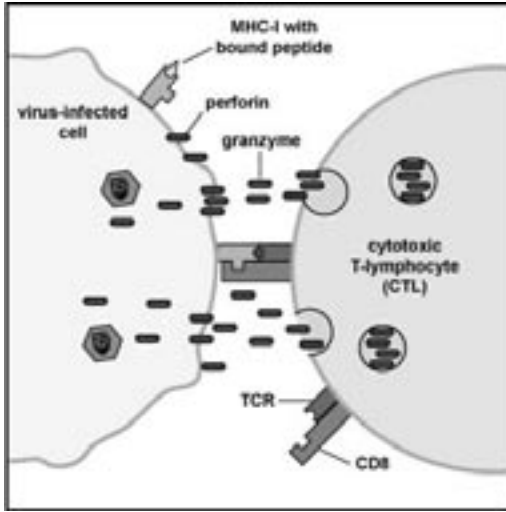
HBV and HCV are the two major causes of chronic liver inflammation worldwide [18, 19]. Both viruses are preferentially hepatotropic, but not directly cytopathic. Approximately 5 to 10 % of adults infected by HBV develop a chronic infection, whereas more than 70 % of patients become persistently infected with HCV. Chronic hepatitis B and C virus infection is a serious clinical problem because of its global distribution and serious complications [20, 21]. It is defined as persistence of HBV or HCV replication for more than 6 months after the initial acute infection. Inoculation with the virus causes hepatocellular inflammation and necrosis which ranges in severity from asymptomatic infection to severe symptomatic infection with progressive or even fatal illness. In patients who develop a chronic hepatitis B or C there is an increased risk of liver cirrhosis, portal hypertension and hepatocellular carcinoma [22-23].

### The T-cell response against HBV and HCV

It is still not clear why certain patients develop a chronic hepatitis B or C infection, while others clear these viruses after an acute infection. The inability to mount an efficient T-helper and cytotoxic T-cell responses against the virus is thought to play a key role in the course and outcome of hepatitis B or C in terms of liver damage and viral control resulting into chronicity. In patients with self-limited HBV-infection, the CD8<sup>+</sup> cytotoxic response to viral antigens is strong and multispecific, whereas this response is weak or undetectable in chronically infected patients [24-30], except during acute exacerbations or interferon alpha-induced viral clearance [31, 32].

Despite a strong T-cell response to HBV during acute viral hepatitis very low levels of virus remain present in the circulation for several decades following complete resolution of disease [33]. In addition, HBV-specific cytotoxic T-lymphocytes (CTLs) remain present in the circulation





**Figure 3.** A cytotoxic T-lymphocyte (CTL), by way of its TCR and CD8, can bind to MHC-I epitope on a virus-infected and cause apoptosis by way of perforins and granzymes. In addition, a Fas ligand (FasL) on the CTL can bind to a Fas molecule on the virus-infected cell and activate the enzymes that lead to apoptosis of the infected cell by means of destruction of its structural cytoskeleton proteins and by chromosomal degradation.

suggesting that after clinical recovery equilibrium between HBV and the host immune system is established [34].

In contrast, chronically HCV infected patients do mount a polyclonal and multispecific CTL response to several HCV-encoded proteins [35-39], but probably not strong enough qualitatively and quantitatively. The establishment of a chronic HCV infection leads to a lower number of circulating and intrahepatic virus-specific CD8+ and CD4+ T-cell [40, 41] and to a defective CD8 T-cell function [42], which is probably maintained by the prolonged exposure to viral antigens or immunosuppression, by viral gene products [43, 44].

It is thought that liver damage is the direct consequence of lysis of infected hepatocytes, mediated by a cellular response to epitopes of HBV and HCV proteins, presented on the surface on the hepatocyte. HLA class I restricted CD8 T-cells recognize HBV or HCV peptide fragments derived from intracellular processing and presented on the hepatocyte surface by class I molecules.

This process leads to direct hepatocyte killing by the CD8 CTL, probably mediated by Fas Ligand- and/or perforin/granzyme-, pathways, resulting in apoptosis. However, recent studies suggest that CTLs may inhibit viral replication and inactivate HBV without killing the infected hepatocyte. In an HBV transgenic mouse model it has been clearly shown that HBV replication is completely abolished in the hepatocytes by secretion of the antiviral cytokines IFN gamma and TNF alpha by CTL [45-47].

It has been postulated that the HBV and HCV specific immune response is too weak to eliminate the virus from all infected hepatocytes during a chronic infection, but sufficiently strong to cause persistent liver damage. The low level of virus specific CD8 T-cells in the circulation of chronically infected patients suggest that HBV- and HCV-specific CTLs are preferentially sequestered in the liver [48, 49]. As HBV and HCV are localized and replicate mainly in the liver, the immune effector response to these viruses is assumed to be compartmentalized in this organ.

### The innate immune response against HBV and HCV

The full development of an efficient antiviral adaptive immune response requires a proper activation of components of innate immune response. Natural killer (NK), NK-T cells and proper dendritic cells are all necessary both to control the virus replication immediately after infection, as well as to deliver the necessary signals that lead to activation of the adaptive response [50]. In a transgenic mouse model of HBV infection it has been found that in the early containment of acute HBV infection NK-T cell activation inhibits virus replication by the production of IFN gamma [51-53]. Furthermore, a rapid drop in viral replication was observed early after acute infection of chimpanzees when only resident NK and NK-T cells producing IFN gamma were present in the liver [54]. In a study of the incubation phase of acutely infected patients, an increase of circulating NK-cells was observed preceding the decline of HBV replication, and is followed by the appearance of HBV specific CD8 T-cells, when viral replication had already dropped [55].

The coexistence of HCV replication with the absence of liver inflammation in the first 4-6 weeks after HCV infection is indicative for a minimal contribution of NK and NK-T cells to the acute phase of HCV-induced hepatitis, because IFN gamma production by these cells mediates the recruitment of inflammatory cells [56, 57]. Among the intrahepatic cellular infiltrates in chronic HCV patients, there is an enrichment of NK cells, NKT cells that may play an important role in maintaining chronic liver damage [58, 59].

Dendritic cells (DCs) comprise an essential component of the immune system. These cells are the most potent antigen presenting cells (APCs) capable of activating naive T cells and are crucial for triggering the antigen-specific immune response. DCs are the initiators and modulators of the helper- and cytotoxic T-cell responses. In infected liver tissue, DCs are thought to be present in an immature state. These immature DCs can take up viral particles by phagocytosis. The antigens are processed to peptides following their internalization into DCs, resulting in the formation of MHC class I and MHC class II-peptide complexes expressed on the surface of DCs. Viruses, or virus-infected cells deliver signals that lead to a proper maturation of DCs and stimulate their migration to regional lymphoid organs, where they can induce the clonal expansion of antigen-specific lymphocytes.

Here, helper T-cells are activated and provide help (a.o. by cytokine secretion) for naive cytotoxic T-lymphocytes to differentiate into effector cells. These will then migrate to the target

organ to kill the virus-infected hepatocytes or to inhibit viral replication [60, 61]. A recent study indicated that DCs generated in vitro from monocytes of patients with chronic HBV-infection had impaired T-cell stimulatory capacity [62]. Similar findings have been reported for patients with chronic HCV-infection [63]. These findings suggest that alterations of DC function and/or maturation during a primary HBV or HCV infection could contribute to a delayed appearance of HBV or HCV specific CD8 T-cells after infection.

### Fine needle aspiration biopsy

Until now, studies of the intrahepatic cellular immune responses involved in viral clearance have been hampered by the difficulty of frequent sampling of the intrahepatic compartment in humans, especially to investigate the intrahepatic immune response during therapy. The cytological fine-needle aspiration biopsy (FNAB) procedure represents an a-traumatic alternative for the invasive tissue biopsy, and it can be used for frequent monitoring of the intrahepatic compartment. This technique was originally developed for the diagnosis of acute rejection after kidney transplantation [64] and has been used for monitoring rejection in liver transplants for many years [65-68]. Studies of the CD8 mediated T-cell response has been restricted to a few immuno-dominant epitopes HBV and HCV. In the present study we have introduced this technique for investigating the intrahepatic immune response during chronic HBV or HCV infections.

### Immune modulating therapy in chronic hepatitis B and C

For treatment of chronic hepatitis B there are three approved drugs: alpha interferon, lamivudine and adefovir dipivoxil. Alpha-interferon acts primarily as an immunomodulator of the host immune system against viral infection [69]. It enhances expression of HLA class I antigens, and HBsAg on the hepatocytes, which will improve the NK cell and CTL mediated killing of infected hepatocytes [70]. In addition, it inhibits viral RNA pregenomic packaging into core particles and it blocks the entry and uncoating of the virus into uninfected hepatocytes [71]. Alpha interferon therapy can result in loss of serum HBeAg in 20 to 40% of the patients. This response is sustained in 80-90% of the patients resulting in loss of HBsAg in the years following completion of therapy [72, 73]. The main limitations of alpha interferon are the need for subcutaneous administration, the frequency of side effects and the limited efficacy.

Lamivudine and adefovir dipivoxil, in contrast, are potent and effective inhibitors of HBV DNA polymerase activity resulting in suppression of HBV DNA, normalization of ALT levels and improvement of liver histology in the majority of patients [74, 75]. Both agents are administered orally and have few side effects. Suppression of HBV DNA and HBeAg seroconversion occurs between 15-40 % of patients [76-78]. However, relapse is common when therapy is discontinued. Persistence of ccc-DNA in the nuclei of the hepatocytes during therapy may be responsible for this relapse of viral replication [79]. It has been reported that both lamivudine and adefovir dipivoxil therapy may restore the CD4 and CD8 T-cell reactivity to HBeAg and HBcAg by a strong

HBV DNA reduction [80-81]. Lamivudine therapy restored the T-cell response in HBeAg<sup>+</sup> chronic HBV patients till the sixth month of treatment, followed by a decline despite the differences in viral responsiveness to treatment [82].

For chronic hepatitis C, the only therapy available until recently was pegylated-interferon alpha treatment, which resulted in sustained remission in a minority of patients [83]. Two major multicenter studies have established that the combination interferon alpha and ribivirin markedly increased the sustained response rate in previously untreated chronic HCV patients [84-86]. Ribavirin, a nucleoside analogue, inhibits viral replication and is administered orally. However, monotherapy ribivirin has no significant effect on HCV replication, despite reducing the levels of liver enzymes [87].

## **OBJECTIVES OF THE STUDY**

To investigate the intrahepatic immune response in chronic hepatitis B and C patients, in relation to inflammatory liver injury, viral replication and spontaneous or treatment-induced viral control.

## REFERENCES

1. Tiollais P, Pourcel C, Dejean A. The hepatitis B virus. *Nature* 1985;317:489-495
2. Lau JY, Wright TL. Molecular virology and pathogenesis of hepatitis B. *Lancet* 1993;342:1335-1340
3. Mutchnick MG. Acute and chronic hepatitis B. In: Feldman M, Madrey WC, eds. *The liver*. Philadelphia: Current Medicine, 1996;4.1-4.24
4. Le Seyec J, Chouteau P, Cannie I, Guguen-Guillouzo C, Gripon P. Infection process of the hepatitis B virus depends on the presence of a defined sequence in the pre-S1 domain. *J Virol* 1999;73:2052-2057
5. Milich DR, McLachlan A. The nucleocapsid of hepatitis B virus is both a T-cell-independent and a T-cell dependent antigen. *Science* 1986;234:1398-1401
6. Chisari FV, Ferrari C. Hepatitis B virus immunopathogenesis. *Ann Rev Immunol* 1995;13:29-60
7. Magnius LO, Espmark JA. New specificities in Australia antigen positive sera distinct from the Le Bouvier determinants. *J Immunol* 1972;109:1017-1021
8. Reifenberg K, Deuschle T, Wild J, Hanano R, Gastrock-Balitsch I, Schirmbeck R, *et al*. The hepatitis B virus e antigen cannot pass the murine placenta efficiently and does not induce CTL immune tolerance in H-2b mice in utero. *Virology* 1998;243:45-53
9. Milich DR, Chen M, Hughes JL, Jones JE. The secreted hepatitis B precore antigen can modulate the immune response to the nucleocapsid: a mechanism for persistence. *J Immunol* 198;160:2013-2021
10. Milich DR, Schodel F, Hughes JL, Jones JE, Peterson DL. The hepatitis B virus core and e antigens elicit different Th cell subsets: antigen structure can affect Th cell phenotype. *J Virol* 1997;71:2192-2201
11. Shimotohno K. Hepatitis C virus and its pathogenesis. *Semin Cancer Biol* 2000;10:233-240
12. Chang M, Williams O, Mittler J, Quiñtanilla A, Carithers RL, Perkins J, Corey L, Gretch DR. Dynamics of hepatitis C virus replication in human liver. *Am J Pathol* 2003;163:433-444
13. Bartenschlager R, Lohrman V. Replication of hepatitis C virus. *J Gen Virol* 2000;81:1631-1648
14. Mihm S, Fayyazi A, Hartmann H, Ramadori G. Analysis of histopathological manifestations of chronic hepatitis C virus infection with respect to virus genotype. *Hepatology* 1997;25:735-739
15. Ramalho F, Costa A, Pires A, Cabrita P, Serejo F, Correia AP, *et al*. Correlation of genotypes and route of transmission with histologic activity and disease stage in chronic hepatitis C. *Dig Dis Sci* 2000;45:182-187
16. Pileri P, Uematsu Y, Campagnoli S, Galli G, Falugi F, Petracca R, *et al*. Binding of hepatitis C virus to CD81. *Science* 1998;282:938-941
17. De Vos R, Verslype C, Depla E, Fevery J, van Damme B, Desmet V, *et al*. Ultrastructural visualization of hepatitis C virus components in human and primate liver biopsies. *J Hepatol* 2002;370-379
18. Lok AS, McMahon BJ. Chronic hepatitis B. *Hepatology* 2001;34:1225-1241
19. Lauer GM, Walker BD. Hepatitis C virus infection. *N Engl J Med* 2001;345:41-52
20. Rozario R, Ramakrishna B. Histopathological study of chronic hepatitis B and C: a comparison of two scoring systems. *J Hepatol* 2003;38:223-229
21. WHO Global surveillance and control of hepatitis C. Report of a WHO consultation organized in collaboration with the Viral Hepatitis Prevention Board, Antwerp, Belgium. *J Viral Hepatol* 1999;6: 35-47
22. Fattovich G. Natural course and prognosis of chronic hepatitis type B. *Viral Hep Rev* 1996;2: 263-276
23. Alter MJ, Margolis K, Krawczynski FN, Judson FN, Mares A, Alexander WJ, *et al*. The natural history of community-acquired hepatitis C in the United States. The Sentinel Counties chronic non-A, non-B Hepatitis Study Team. *N Engl J Med* 1992;327:1899-1905
24. Ferrari C, Penna A, Bertoletti A, Valli A, Antoni AD, Giuberti T, *et al*. Cellular immune response to hepatitis B virus encoded antigens in acute and chronic hepatitis B virus infection. *J Immunol* 1990;145:3442-3449
25. Jung MC, Spengler U, Schraut W, Hoffmann R, Zchoval R, Eisenburg J, *et al*. Hepatitis B virus antigen-specific T-cell activation in patients with acute and chronic hepatitis B. *J Hepatol* 1991;13:310-317

26. Penna A, Artini M, Cavalli A, et al. Long lasting memory T cell responses following self-limited acute hepatitis B. *J Clin Invest* 1996;98:1185-1194
27. Penna A, Del Prete G, Cavalli A, et al. Predominant T-helper 1 cytokine profile of hepatitis B virus nucleocapsid-specific T cells in acute self-limited hepatitis B. *Hepatology* 1997;25:1022-1027
28. Reherrmann B, Fowler P, Sidney, Person J, Redeker A, Brown M, et al. The cytotoxic T lymphocyte response to multiple hepatitis B virus polymerase epitopes during and after acute viral hepatitis. *J Exp Med* 1995;181:1047-1058
29. Penna A, Chisari FV, Bertoletti AB, et al. Cytotoxic T lymphocytes recognize an HLA-A2 restricted epitope within the hepatitis B virus nucleocapsid antigen. *J Exp Med* 1991;174:1565-1570
30. Jung M, Harmann B, Gerlach J. Virus-specific lymphokine production differs quantitatively but not qualitatively in acute and chronic hepatitis B infection. *Virology* 1999;261:165-172
31. Tsai SL, Chen PJ, Lai MY, et al. Acute exacerbations of chronic type B hepatitis are accompanied by increased T cell responses to hepatitis B core and e antigens. Implications for hepatitis B e antigen seroconversion. *J Clin Invest* 1992;89:87-96
32. Reherrmann B, Lau D, Hoofnagle JH, Chisari FV. Cytotoxic T lymphocyte responsiveness after resolution of chronic hepatitis B virus infection. *J Clin Invest* 1996;97:1655-1665
33. Michalak TI, Pasquinelli C, Guilhot S, Chisari FV. Hepatitis B virus persistence after recovery from acute viral hepatitis. *J Clin Invest* 1994;93:230-239
34. Reherrmann B, Ferrari C, Pasquinelli C et al. The hepatitis B virus persists for decades after recovery from acute viral hepatitis despite active maintenance of a cytotoxic T lymphocyte response. *Nature Med* 1996;2:1104-1108
35. Cerny A, McHutchison JG, Pasquinelli C, Brown ME, Brothers MA, Grabscheid B, et al. Cytotoxic T lymphocyte response to hepatitis C virus-derived peptides containing the HLA A2.1 binding motif. *J Clin Invest* 1995;95:521-530
36. Koziel MJ, Dudley D, Wong JT, Dienstag J, Houghton M, Ralston R, et al. Intrahepatic cytotoxic T lymphocytes specific for hepatitis C virus in persons with chronic hepatitis. *J Immunol* 1992;149:3339-3344
37. Thimme R, Oldach D, Chang KM, Steiger C, Ray SC, Chisari FV. Determinants of viral clearance and persistence during acute hepatitis C virus infection. *J Med Exp* 2001;194:1395-1406
38. Lechner F, Wong D, Dunbar P, Chapman R, Chung RT, Dohrenwend P, et al. Analysis of successful immune responses in person infected with hepatitis C virus. *J Med Exp* 2000;191:1499-1512
39. Lechmann M, Ihlenfeldt HG, Braunschweiger I, Giers G, Jung G, Matz B, et al. T- and B-cell responses to different hepatitis C virus antigens in patients with chronic hepatitis C infection in healthy anti-hepatitis C virus-positive blood donors without viraemia. *Hepatology* 1996;24:790-795
40. He XS, Reherrmann B, Lopez-Labrador FX, Boisvert J, Cheung R, Mumm J, et al. Quantitative analysis of hepatitis C virus-positive CD8+ T cells in peripheral blood and liver using peptide-MHC tetramers. *Proc Natl Acad Sci USA* 1999;96:5692-5697
41. Reherrmann B, Chang KM, McHutchison JG, Kokka R, Houghton M, Chisari FV. Quantitative analysis of the peripheral blood cytotoxic T lymphocyte response in patients with chronic hepatitis C virus infection. *J Clin Invest* 1996;98:1432-1440
42. Wedemeyer H, He XS, Nascimbeni M, Davis AR, Greenberg HB, Hoofnagle JH, et al. Impaired effector function of hepatitis C virus-specific CD8+ T cells in chronic hepatitis C virus infection. *J Immunol* 2002;169:3447-3458
43. Welsh R. Assessing CD8 T cell number and dysfunction in the presence of antigen. *J Exp Med* 2001;193:F19-F22
44. Large M, Kittlesen D, Hahn Y. Suppression of host immune response by the core protein of hepatitis C: possible implications for hepatitis C virus persistence. *J Immunol* 1999;162:931-938
45. Guidotti LG, Ishikawa T, Hobbs MV, Matzke B, Schreiber R, Chisari FV. Intracellular inactivation of hepatitis B virus by cytotoxic T lymphocytes. *Immunity* 1996;4:25-36
46. Guidotti LG, Borrow P, Hobbs MV, Matzke B, Gresser I, Oldstone MB, et al. Viral cross talk: intracellular inactivation of the hepatitis B virus during an unrelated viral infection of the liver. *Proc Natl Acad Sci USA* 1996;93:4589-4594
47. Guidotti LG, Chisari FV. Cytokine-mediated control of viral infections. *Virology* 2000;273:221-227
48. Maini MK, Boni C, Lee CK. The role of virus-specific CD8+ cells in liver damage and viral control during persistent hepatitis B (HBV) infection. *J Exp Med* 2000;191:1269-1280

49. Minutello MA, Pileri P, Unutmaz D, Censini S, Kuo G, Houghton M, *et al*. Compartmentalization of T-lymphocytes to the site of the disease: intrahepatic CD4+ T cells specific for the protein NS4 of hepatitis C virus in patients with chronic hepatitis C. *J Exp Med* 1993;178:17-26
50. Biron C. Initial and innate responses to viral infections-pattern setting in immunity or disease. *Curr Opin Microbiol* 1999;2:374-381
51. Kakimi K, Guidotti LG, Koezuka Y, Chisari FV. Natural killer T cell activation inhibits hepatitis B virus replication in vivo. *J Exp Med* 2000;192:921-930
52. Kakimi K, Lane TE, Chisari FV, Guidotti LG. Cutting edge: inhibition of hepatitis B virus replication by activated NK T cells does not require inflammatory cell recruitment to the liver. *J Immunol* 2001;167:6701-6705
53. Baron JL, Gardiner L, Nishimura S, Shinkai K, Locksley R, Ganem D. Activation of a nonclassical NKT cell subset in a transgenic mouse model of hepatitis B virus infection. *Immunity* 2002;16:583-594
54. Guidotti LG, Rochford R, Chung J, Shapiro M, Purcell R, Chisari FV. Viral clearance without destruction of infected cells during acute HBV infection. *Science* 1999;284:825-829
55. Webster G, Reigat S, Maini MK, Whalley SA, Ogg GS, King A, *et al*. Incubation phase of acute hepatitis B in man: dynamic of cellular immune mechanism. *Hepatology* 2000;32:1117-1124
56. Thimme R, Oldach D, Chang KM, Steiger C, Ray SC, Chisari FV. Determinants of viral clearance and persistence during acute hepatitis C virus infection. *J Exp Med* 2001;194:1395-1406
57. Bassett SE, Guerra B, Brasky K, Miskovsky E, Houghton M, Klimpel GR, Lanford RE. Protective immune response to hepatitis C virus in chimpanzees rechallenged following clearance of primary infection. *Hepatology* 2001;33:1479-1487
58. Nuti S, Rosa D, Valiante NM, Saletti G, Caratozzolo M, Dellabonna P, *et al*. Dynamics of intrahepatic lymphocytes in chronic hepatitis C: enrichment for Va24+ T cells and rapid elimination of effector cells by apoptosis. *Eur J Immunol* 1998;28:3448-3455
59. Valiante NM, D'Andrea A, Crotta S, Lechner F, Klenerman P, Nuti S, *et al*. Life, activation and death of intrahepatic lymphocytes in chronic hepatitis C. *Immunol Rev* 2000;174:77-89
60. Steinman RM. The dendritic cell system and its role in immunogenicity. *Annu Rev Immunol* 1991;9:271-296
61. Banchereau J, Steinman RM. Dendritic cells and the control of immunity. *Nature* 1998;392:245-252
62. Beckebaum S, Cicinnati VR, Dworacki G, Muller-Berghaus J, Stolz D, Harnaha J, *et al*. Reduction in the circulating pDC1/pDC2 ratio and impaired function of ex vivo-generated DC1 in chronic hepatitis B infection. *Clin Immunol* 2002;104:138-150
63. Auffermann-Gretzinger S, Keeffe EB, Levy S. Impaired dendritic cell maturation in patients with chronic, but not resolved hepatitis C virus infection. *Blood* 2001;97:3171-3176
64. Hayry PJ. Fine-needle aspiration biopsy in renal transplantation. *Kidney Int* 1989;36:130-141
65. Von Willebrand E, Lautenschlager I. Fine Needle Aspiration Cytology in Kidney, Liver, and Pancreas allografts. In: Solez K, Racusen LC, Billingham ME, eds. *Solid organ transplant rejection*. New York: Marcel Dekker; 1996. pp. 303-325
66. Kirby RM, Young JA, Hubscher SG, Elias E, McMaster P. The accuracy of aspiration cytology in the diagnosis of rejection following orthotopic liver transplantation. *Transplant Int* 1988;1:119-126
67. Kuijf ML, Kwekkeboom J, Kuijpers MA, Willems M, Zondervan PE, Niesters HG, *et al*. Granzyme expression in fine-needle aspirates from liver allografts is increased during acute rejection. *Liver Transp* 2002;8:952-956
68. Kwekkeboom J, Zondervan PE, Kuijpers MA, Tilanus HW, Metselaar HJ. Fine-needle aspiration cytology in the diagnosis of acute rejection after liver transplantation. *Br J Surg* 2003;90:246-247
69. Foster GR. Interferons in host defense. *Semin Liver Dis* 197;17:287-295
70. Thomas HC. Pathogenesis of chronic hepatitis B infection and mechanisms of action of antiviral compounds. *Viral hepatitis and liver diseases* ed. By Hollinger FB, Lemon SM 1990;612-615
71. Peters M. Mechanisms of action of interferons. *Semin Liv Dis* 1989;9:235-239
72. Niederau C, Heintges T, Lange S, Goldmann G, Niederau CM, Mohr L, *et al*. Long-term follow-up of HBeAg positive patients treated with interferon alpha for chronic hepatitis B. *N Engl J Med* 1996;334:1422-1427
73. Carreno V, Castillo I, Molina J, Porres JC, Bartolome J. Long-term follow-up of hepatitis B chronic carriers who responded to interferon therapy. *J Hepatol* 1992;15:102-106



74. Lai CL, Chien RN, Leung NW, Chang TT, Guan R, Tai DI, *et al.* A one year trial of lamivudine for chronic hepatitis B. *N Engl J Med* 1998;339:61-68
75. Torresi J, Locarnini S. Antiviral chemotherapy for the treatment of hepatitis B virus infections. *Gastroenterology* 2000;118:S83-S103
76. Dienstag JL, Schiff ER, Wright TL, Perrillo RP, Hann HW, Goodman Z, *et al.* Lamivudine as initial treatment for chronic hepatitis B in the United States. *N Engl J Med* 1999;341:1256-1263
77. Schalm SW, Heathcote J, Cianciara J, Farrell G, Sherman M, Willems B, *et al.* Lamivudine and alpha interferon combination treatment of patients with chronic hepatitis B infection: a randomized trial. *Gut* 2000;46:562-568
78. Heathcote E, Jeffers L, Wright T, Sherman M, Perrillo RP, Sacks S, *et al.* Loss of HBV DNA and HBeAg and seroconversion following short-term (12 weeks) adefovir dipivoxil therapy in chronic hepatitis B: two placebo-controlled studies. *Hepatology* 1998;28:317A
79. Moraleda G, Saputelli J, Aldrich CE, Averett D, Condreay L, Mason W. Lack of effect of antiviral therapy in nondividing hepatocyte cultures on the closed circular DNA of woodchuck hepatitis virus. *J Virol* 1997;9392-9399
80. Boni C, Bertoletti A, Penna A, Cavalli A, Pilli M, Urbani S, *et al.* Lamivudine treatment can restore T cell responsiveness in chronic hepatitis B. *J Clin Invest* 1998;1:968-975
81. Cooksley H, Chokshi S, Wedemeyer H, Andreone P, Gilson R, Warnes T, *et al.* Hepatitis B virus-specific T-cell reactivity during adefovir dipivoxil (ADV) treatment: a multicentre, controlled study. *J of Hepat* 2002;36 Suppl 1:A647
82. Boni C, Penna A, Bertoletti A, Lamonaca V, Rapti I, Missale G, *et al.* Transient restoration of anti-viral T cell responses induced by lamivudine therapy in chronic hepatitis B. *J Hepatol.* 2003;39:595-605
83. Hoofnagle JH, Di Bisceglie AM. The treatment of chronic viral hepatitis. *N Engl J Med* 1997;336:347-356
84. McHutchison JG, Gordon SC, Schiff ER, Schiffman ML, Lee WM, Rustgi VK, *et al.* Interferon alpha-2b alone or in combination with ribavirin as initial treatment for chronic hepatitis C. Hepatitis Interventional Therapy Group. *N Engl J Med* 1998;339:1485-1492
85. Poynard T, Marcellin P, Lee SS, Niederau C, Minuk GS, Ideo G, *et al.* Randomised trial of interferon a2b plus ribavirin for 48 weeks or for 24 weeks versus interferon a2b plus placebo for 48 weeks for treatment of chronic infection with hepatitis C virus. *Lancet* 1998;352:1426-1432
86. Hadziyannis SJ, Sette H Jr, Morgan TR, Balan V, Diago M, Marcellin P, *et al.* PEGASYS International Study Group Peginterferon-alpha2a and ribavirin combination therapy in chronic hepatitis C: a randomized study of treatment duration and ribavirin dose. *Ann Intern Med.* 2004;140:346-355
87. Bodenheimer HCJ, Lindsay KL, Davis GL, Lewis JH, Thung SN, Seeff LB. Tolerance and efficacy of oral ribivirin treatment of chronic hepatitis C: a multicenter trial. *Hepatology* 1997;26:473-477

# Chapter 2

## **The role of intrahepatic immune effector cells in inflammatory liver injury and viral control during chronic hepatitis B infection**

T.J. Tang<sup>1</sup>, J. Kwekkeboom<sup>1</sup>, J.D. Laman<sup>2</sup>, H.G.M. Niesters<sup>3</sup>, P.E. Zondervan<sup>4</sup>, R.A. de Man<sup>1</sup>, S.W. Schalm<sup>1</sup>, H.L.A. Janssen<sup>1</sup>

Departments of <sup>1</sup>Gastroenterology and Hepatology, <sup>2</sup>Immunology, <sup>3</sup>Virology and <sup>4</sup>Pathology  
Erasmus MC, University Medical Center Rotterdam, The Netherlands

Journal of Viral Hepatitis 2003;10:159-167



## ABSTRACT

Cytotoxic T lymphocytes (CTL) and Kupffer cells play an important role in the immune control of hepatitis B virus (HBV), but also may induce liver injury during infection. We investigated the intrahepatic immune response in liver biopsies of chronic HBV patients in relation to inflammatory liver injury and viral control.

Forty-seven liver biopsies of chronic HBV patients with a varying degree of inflammation (ALT values) were selected. Acute hepatitis and normal liver specimens served as controls. Immune effector cells, cytotoxic effector molecules and cytokine producing cells were quantified after immunohistochemical staining in lobular and portal areas of the biopsies.

Intralobular number of CD8+ T-lymphocytes was significantly decreased in biopsies of patients with high ALT ( $r=-0.54$ ;  $p<0.001$ ). Higher ALT-values were correlated with increased numbers of granzyme+ cells in portal areas ( $r=0.65$ ;  $p<0.001$ ) and higher numbers of intralobular Fas-L+ cells ( $r=0.32$ ;  $p=0.05$ ). Fas-L was expressed on Kupffer- and lymphoid cells. More intralobular CD8+ T-lymphocytes were found in HBeAg- than in HBeAg+ patients ( $p=0.002$ ). But IFN- $\gamma$  and TNF- $\alpha$  producing cells were observed sporadically in chronic HBV patients.

In chronic HBV infection, low viral replication and HBeAg negativity is related to increased presence of intralobular CD8+ T-lymphocytes. Persistence of the virus may be due to the absence of cells producing anti-viral cytokines in the liver. Inflammatory liver injury during chronic HBV infection is probably not the result of increased numbers of infiltrating CD8+ T-lymphocytes, but of Fas-L expression by Kupffer cells and increased cytolytic activity of cells in portal areas.

## INTRODUCTION

Hepatitis B virus (HBV) is a non-cytopathic DNA virus that causes chronic hepatitis in 10% of infected adults. Chronic hepatitis may lead to liver cirrhosis or hepatocellular carcinoma [1]. Clearance of HBV during acute hepatitis is associated with a strong cytotoxic T lymphocyte (CTL) response to the viral proteins [2, 3]. This, together with the knowledge that adoptive transfer of virus-specific CD8+ T-lymphocytes can inhibit HBV-replication in HBV-transgenic mice [4], indicates that the CTL-response plays an important role in immune control of HBV. The mechanism by which CD8+ T-lymphocytes eliminate the virus from the liver is unclear. In general CTLs can inhibit viral infection by cytolysis of virus-infected cells through Fas-Ligand-Fas interaction and the granzyme/perforin pathway or by secretion of antiviral cytokines. Experiments with HBV transgenic mice suggest that non-cytolytic mechanisms are responsible for HBV clearance [5]. In these mice, intrahepatic secretion of antiviral cytokines, such as IFN- $\gamma$  and TNF- $\alpha$  by CTLs and Kupffer cells can interrupt the HBV life cycle without lysis of infected hepatocytes. The rapid reduction of HBV-DNA before hepatocellular damage in acute infections in chimpanzees [6] and humans [3] suggest that a similar non-cytolytic mechanism is, at least in part, responsible for inhibition of viral replication during natural infection. The liver injury following inhibition of viral replication during acute infection is thought to be the consequence of an inflammatory response which is mediated by antigen non-specific CD8+ T-lymphocytes, but initiated by HBV-specific CD8+ T-lymphocytes [7]. Currently, little is known about the mechanisms of immune control of HBV and liver damage during chronic infection with the virus. Although peripheral CTL responses are weak during chronic infection [8], hepatocellular injury, as reflected in elevated ALT-levels, is frequently observed. Recently, HBV-specific CD8+ T-lymphocytes have been demonstrated in the liver during chronic infection, but there was no relation between their number and the occurrence of hepatocellular injury nor with the extent of immune control of the virus [9]. The role of other possible effector cells, such as natural killer (NK) cells, and plasmacytoid dendritic cells, which are the principal IFN- $\alpha$  producers [10], in immune control and hepatocyte injury during HBV-infection is as yet unknown. Our aim was to investigate which intrahepatic immune effector cells and which immune effector mechanisms are related to immune control of HBV and liver damage during chronic HBV-infection. For this purpose, we quantitated immune effector cells (CD8+ T-lymphocyte, NK-cells and plasmacytoid dendritic cells) and cells expressing cytotoxic effector molecules (granzyme and Fas-Ligand) or antiviral cytokines (TNF- $\alpha$  and IFN- $\gamma$ ) in liver biopsies of patients chronically infected with HBV.

## MATERIAL AND METHODS

### Patients and liver biopsy specimens

Liver biopsies of chronic hepatitis B patients (n=47) formed the basis of this study. The biopsies were diagnostic pretreatment biopsies from patients, which were HBsAg positive for more than 6 months. Patients treated with any antiviral therapy were excluded. Patients with a co-infection of hepatitis C, hepatitis D and patients with a pre-core mutant in the HBV genome were also excluded. To obtain a wide range of inflammatory activity in the biopsies, chronic HBV patients with low to severe liver inflammation were included (range ALT 11-426)

Subsequently, the patients were stratified according to HBeAg positivity and negativity.

In addition, liver biopsies of 3 patients with acute and fulminant HBV infection obtained after hepatectomy for transplantation and of 2 patients with acute non-viral hepatitis (aetiology unknown) were investigated. Normal liver tissue (n=4) was obtained during the resection of hepatic malignancies. Liver biopsies were performed in accordance with a standard protocol in which a 14-gauge Tru-Cut biopsy needle (diameter 2.1 mm) is used to puncture the right lobe of the liver. One part of the liver specimen was fixed in phosphate-buffered formaline and embedded in paraffin and a second part of the same specimen was collected in Histocon (Polysciences Inc, Warrington PA) and rapidly frozen in isopentane cooled in liquid nitrogen, and stored at -80°C.

### Virological assessments

HBsAg, HBeAg, anti-HBe, anti-HCV and anti-HDV were quantitatively determined by IMX (Abbot Laboratories, North Chicago, IL). HBV-DNA in sera was measured by Hybrid Capture II microplate assay, Digene Corporation, Gaithersburg, U.S.A. Analysis of pre-core mutants was performed by a ABI PRISM 3100 genetic analyser with a Big Dye Terminator v3.0 Cycle Sequencing kit (both from Applied Biosystems, Nieuwerkerk a/d IJssel, The Netherlands).

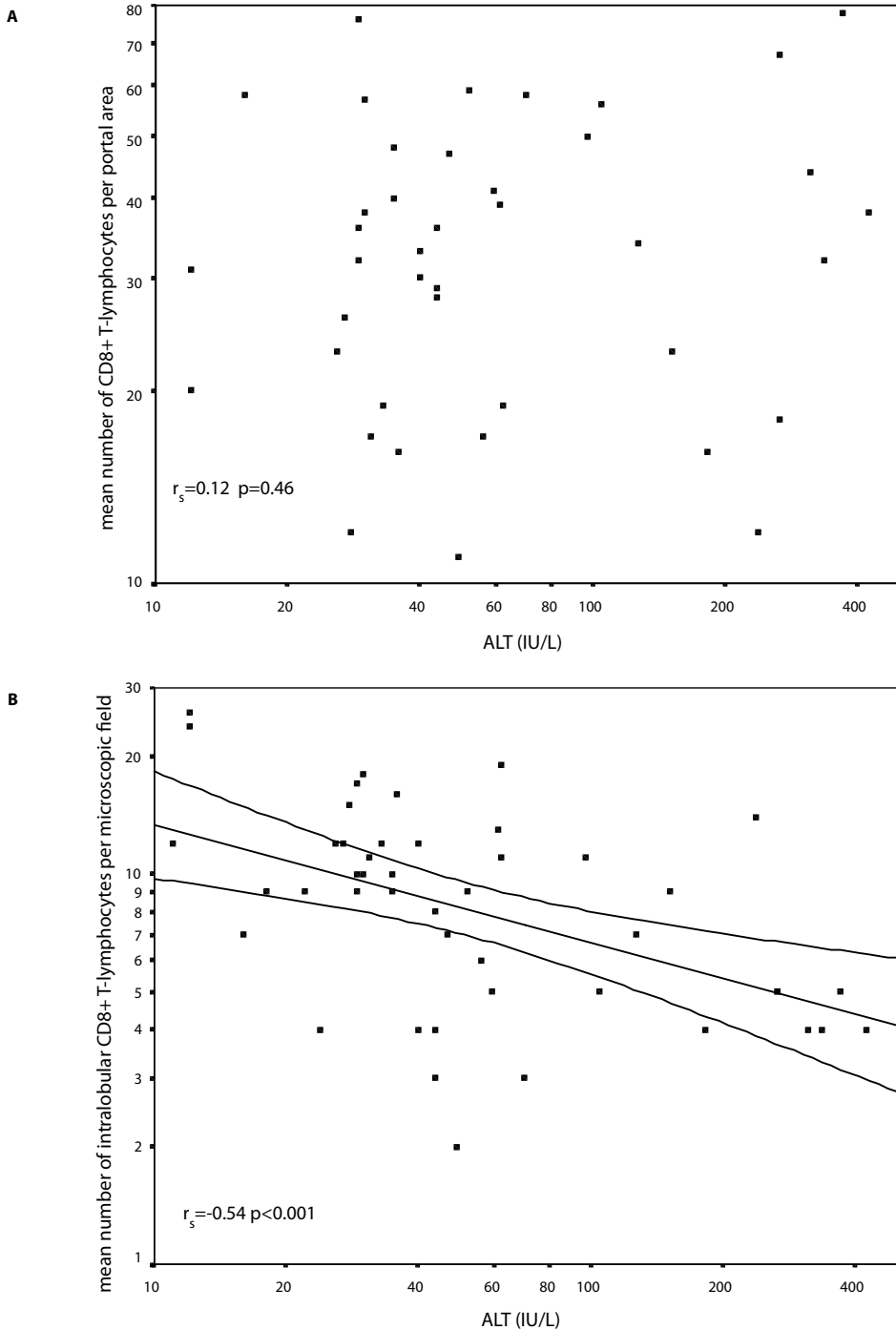
### Antibodies

CD8 (clone C8/14415) and CD68 (clone PG-M1) mAb were purchased from DAKO, Glostrup, Denmark. CD56 (clone N901) was obtained from Beckman Coulter, Hialeah FL. CD123 (clone

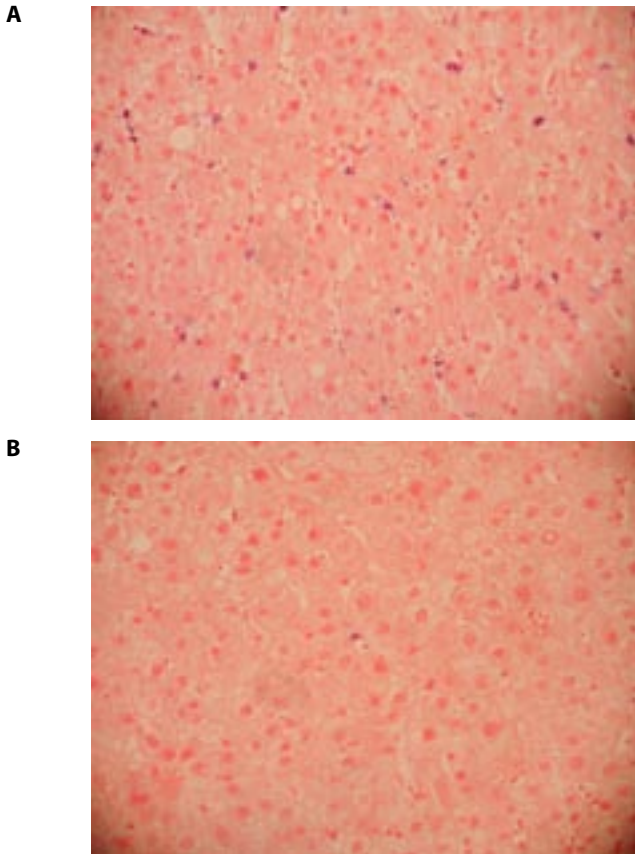
**Table 1.** Patient characteristics with chronic hepatitis B at time of liver biopsy (n=47)

Variables	
Age (years)*	32 (18-70)
Sex (male / female)	27 / 20
ALT (IU/L)*	44 (11-426)
HBV DNA (geq/L)*	1.4E7 (1.0E3 - 9.8E9)
HBeAg + / -	27 / 20
Race (Caucasian/Oriental/Black)	27 / 11 / 9

\*median (range)



**Figure 1.** Mean total numbers of CD8+ T-lymphocytes in portal areas (a) and mean density of CD8+ T-lymphocytes in lobuli (b) of individual liver biopsies of chronic HBV patients in relation to ALT (lines depicted mark the mean of 95% confident interval)



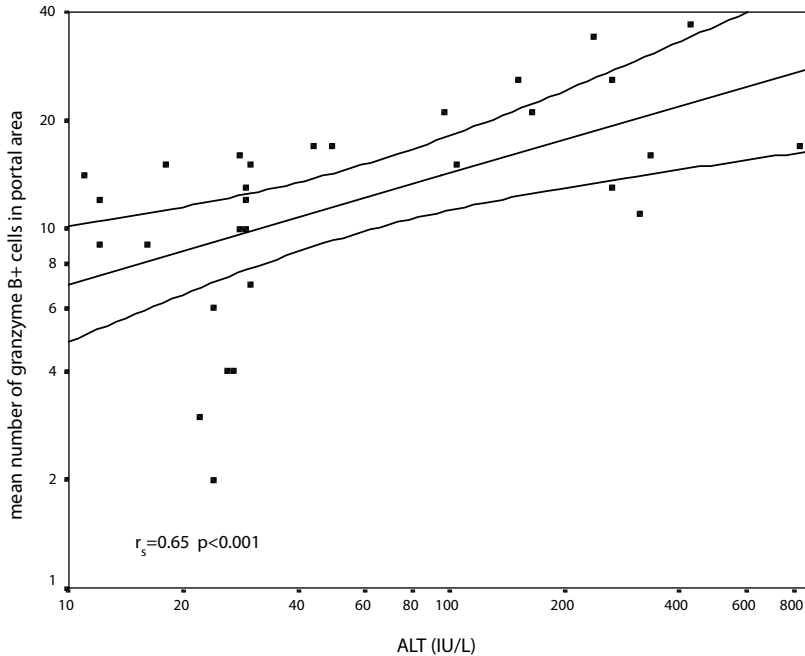
**Figure 2.** Liver biopsy sections immunohistochemically stained with CD8 mAb from chronic HBV patient with normal (A) and raised ALT (B) ( $\times 400$ )

9F5), and CD178 mAb (clone NOK1) were purchased from BD-Pharmingen, San Jose CA. CD178 (clone 5G51) was from Alexis Corporation, San Diego CA. Anti-granzyme mAb (clone B7) was kindly provided by professor C.E. Hack of the Central Laboratory of the Red Cross Blood Transfusion Service, Amsterdam, The Netherlands. MD-2, a mouse mAb specific for IFN- $\gamma$  and mAb 61E71, recognizing human TNF- $\alpha$ , were purchased from U-Cytech, Utrecht, The Netherlands.

### Immunohistochemistry

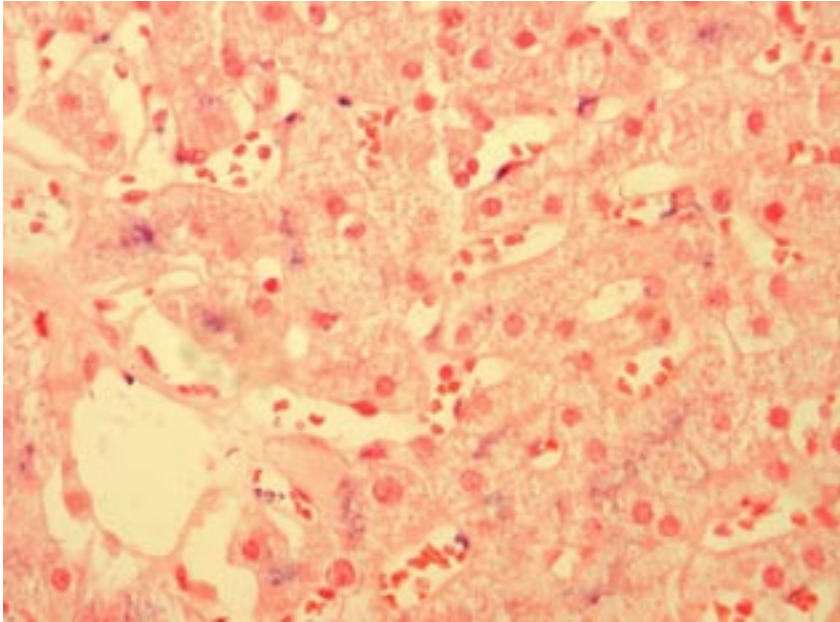
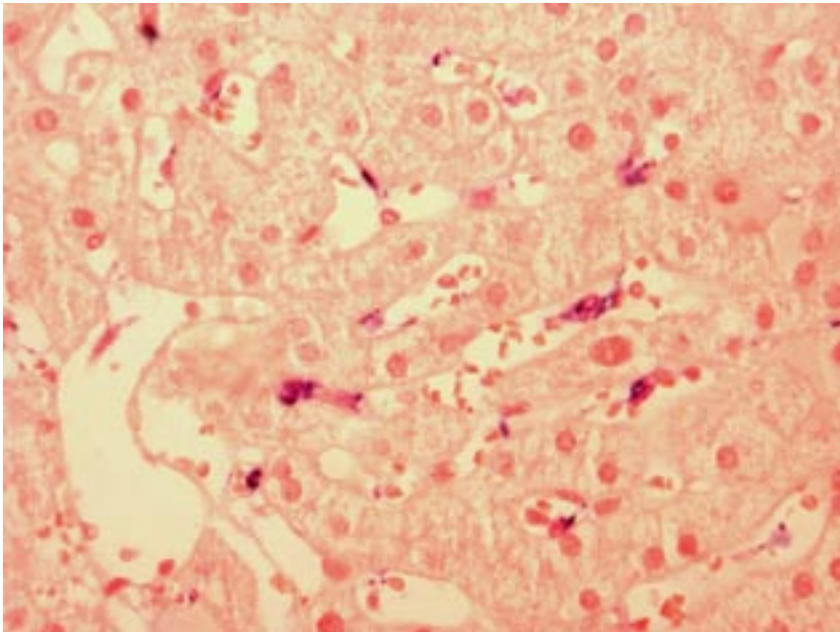
The distribution of CD8 and CD68 positive cells in the liver was visualized in formalin-fixed, paraffin-embedded liver specimens. The liver sections were firstly deparaffinized with xylene (Lab Scan Ltd, Dublin, Ireland) and ethanol (Merck, Darmstadt, Germany) and thereafter antigen retrieval was performed by temperature-controlled incubation at 99°C in citrate buffer (pH 6.0) in a microwave oven for 15 minutes. Incubation with CD8 and CD68 mAb was done



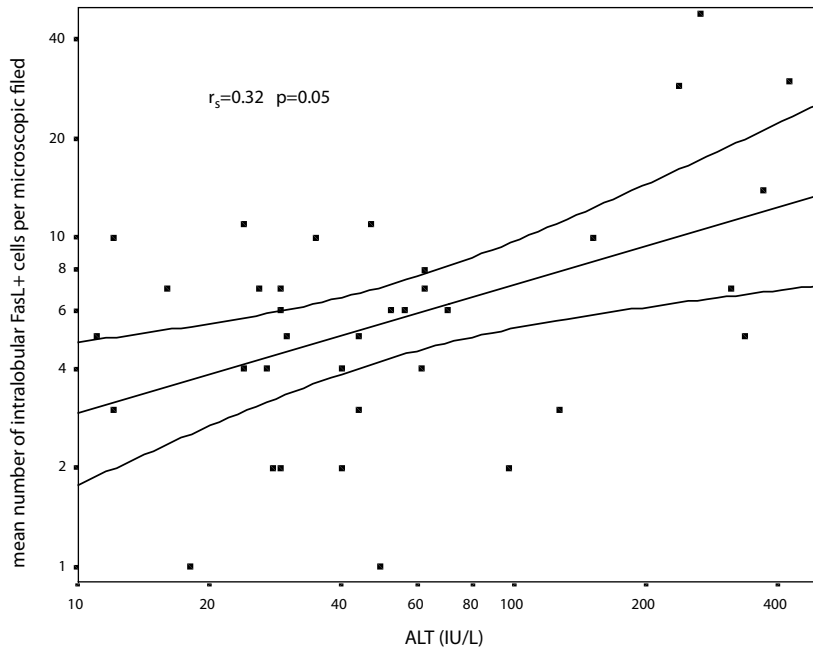


**Figure 3.** Mean numbers of granzyme positive cells in portal areas in relation to ALT

for 1 hour at room temperature. Slides were washed with TBS (Tris buffered saline) pH 7.3 supplemented with 0.1% Tween-20. Detection of CD8 positive cells was performed with goat anti-mouse immunoglobulins (GAM, DAKO) for one hour followed by alkaline-phosphatase-anti-alkaline phosphatase complex (APAAP, Serotec, UK). CD68 positive cells were detected by secondary biotinylated rabbit anti-mouse antibody (RAM-bio, DAKO), after incubation with avidin-biotin blocking solution (DAKO) followed by streptavidine-alkaline phosphatase (DAKO). Visualization was performed by incubation in Fast Blue salt / naphthol AS-BI phosphate solution supplemented with levamisole (all from Sigma-Aldrich Chemie, Steinheim, Germany). The liver specimens were counterstained with Nuclear Fast Red (Fluka Chemie, Buchs, Switzerland). Staining of CD56, CD178, CD123 and granzyme B was performed on frozen sections. The slides were fixed in 4% paraformaldehyde in phosphate-buffered saline pH 7.3. Unspecific antibody binding was prevented by preincubation with TBS supplemented with 10% normal goat serum and 10% normal human plasma. Sections were incubated with primary antibodies overnight. Detection of primary antibody was performed with the GAM-APAAP procedure. For cytokine detection cryostat sections were kept overnight at room temperature in a box with humidified atmosphere. Thereafter sections were air-dried for one hour and fixed for 10 minutes in fresh acetone, containing 0.02%  $H_2O_2$ . Slides were incubated overnight at 4°C with the primary antibodies and subsequently for 30 minutes at room temperature with RAM-bio and avidin-biotin-HRP complexes, which were added together for 15 minutes. Histochemical revelation

**A****B**

**Figure 4.** Consecutive liver biopsy sections immunohistochemically stained with Fas-L mAb (a) or CD68 mAb (b), showing that Fas-L is expressed predominantly on Kupffer cells ( $\times 400$ )

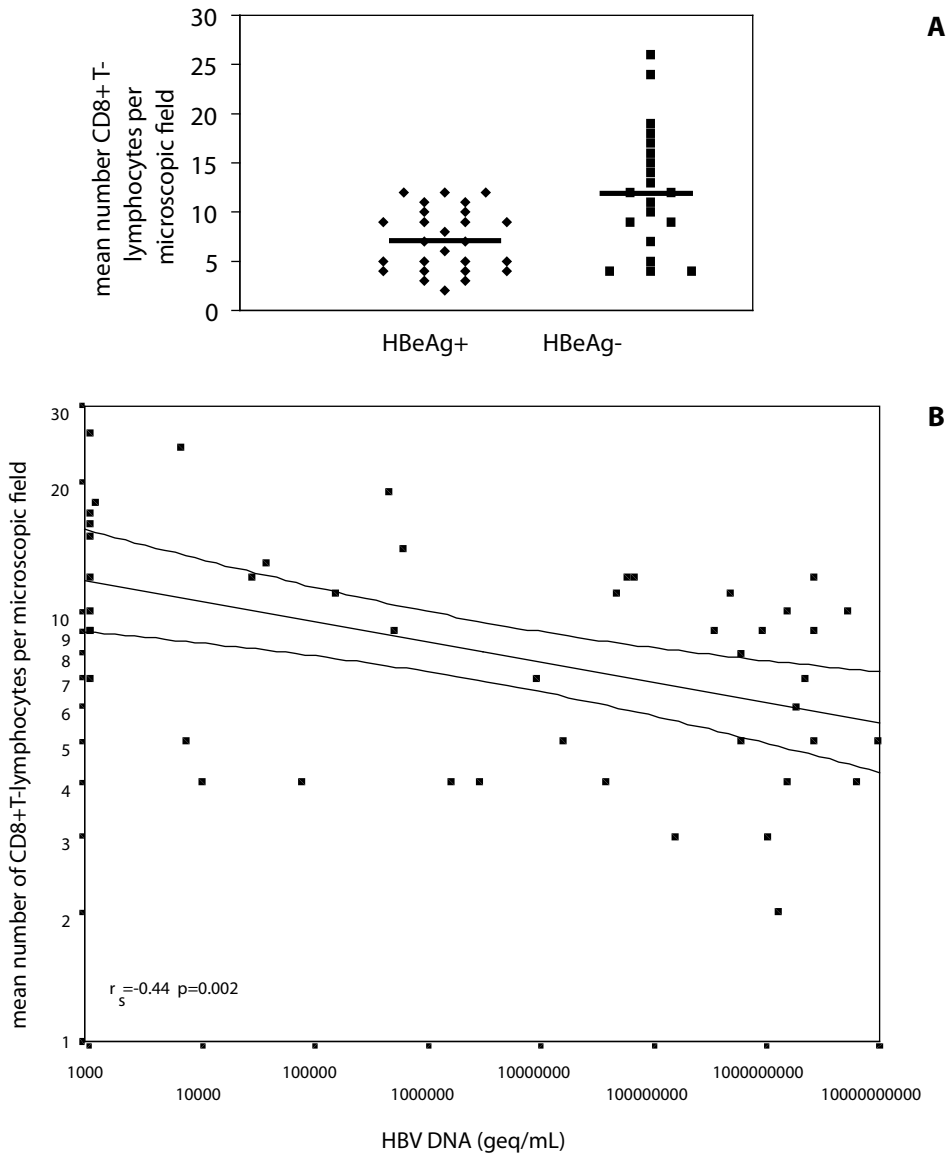


**Figure 5.** Intralobular density of Fas-L expressing cells in individual liver biopsies in relation to ALT

of HRP was performed with 3-amino-9-ethylcarbazole (AEC). Slides were counterstained with hematoxylin for 10 seconds and mounted in glycerol. Optimal dilutions of all antibodies were determined by preliminary experiments on tonsil sections, and on activated peripheral blood mononuclear cells (for CD178 antibodies). Negative controls were performed either by replacement of the primary mAb by an isotype matched control mAb or by leaving out the primary antibody. In each experiment positive control stainings were performed on tonsil tissue or activated mononuclear cells. Sections were examined only when tonsil tissue showed the expected staining pattern and when the negative control staining was negative.

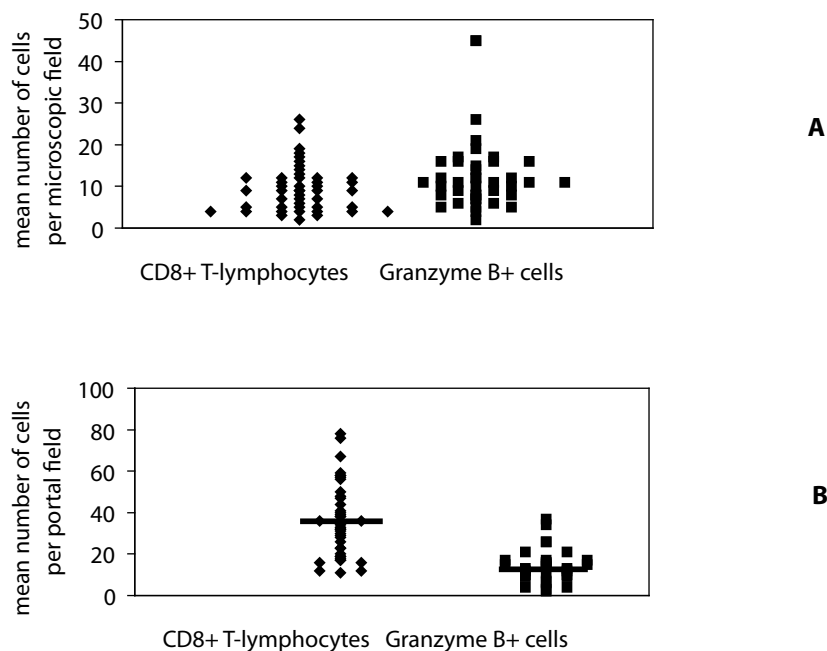
#### Quantification and statistical analysis

The liver specimens were microscopically examined at 400 times magnification using a Zeiss Axioscop. In every specimen 4-5 fields were randomly selected in liver lobuli to count the positive cells, after which the mean was taken for analysis. In portal areas the total numbers of positive cells per infiltrate were counted in at least four infiltrates per section. In addition, the mean numbers of CD8+ T-lymphocytes per  $10,000 \mu\text{m}^2$  in portal areas were calculated using a computer video-image analysis program (KS 400, Kontron Elektronik, GmbH, Eching, Germany). For each portal area, color video images of  $512 \times 512$  pixels with a resolution of  $0.4348 \mu\text{m}$  per pixel were recorded. All the results were counted by one investigator (T.J.T.) blinded for the virological and biochemical conditions of the patients. Data are expressed as mean  $\pm$  standard deviation, unless otherwise indicated. Differences between groups were compared



**Figure 6.** Relation between density of intralobular CD8+ T-lymphocytes and HBeAg status (a) and HBV-DNA (b). ( Medians are indicated by a line)

using the Mann-Whitney test. Spearman's correlation coefficients ( $r_s$ ) were used to investigate correlations. Linear regression lines in various plots were calculated using the least-squares method after logarithmic transformation of both axes. A p-value of  $< 0.05$  was considered statistically significant.



**Figure 7.** Density of CD8+ T-lymphocytes versus granzyme-positive cells intralobular (a) and numbers of CD8+ T-lymphocytes versus granzyme-positive cells in portal areas

## RESULTS

### Characteristics of patients

The initial patient characteristics are presented in Table 1. Forty-seven biopsies of chronic HBV patients were investigated. The median age was 32 years (range 18-70); 57% of the patients were male. Fifty-seven percent (n=27) were HBeAg positive. The distribution of race was 27 (57.4%) Caucasians, 11 (23.4%) Orientals and 9 (19.2%) Blacks.

### Intrahepatic CD8+ T-lymphocytes in relation to hepatic inflammatory activity

CD8+ T-lymphocytes were seen both in the portal areas and in the hepatic lobules. There was no correlation between the total numbers of the CD8+ T-lymphocytes in portal infiltrates and serum ALT values ( $r_s=0.12$ ;  $p=0.46$ ) (Fig. 1a). Even when the density of CD8+ T-lymphocytes in portal areas (i.e. per 10,000  $\mu m^2$ ) were calculated by video-image analysis, no correlation was found ( $r_s=-0.29$ ;  $p=0.06$ ). However, an inverse correlation was found between the intralobular density of CD8+ T-lymphocytes and serum ALT values. Patients with high ALT values had lower numbers of CD8+ T-lymphocytes between the parenchymal cells ( $r_s=-0.54$ ;  $p<0.001$ ) (Fig. 1b, Fig. 2). A significant correlation between serum ALT and HBV-DNA was found ( $r_s=0.41$ ;  $p=0.003$ ).

### Cytotoxic effector molecules in relation to hepatic inflammatory activity

To investigate which mechanism might cause inflammatory liver injury observed in chronic HBV-patients, biopsy sections were stained for the cytotoxic granule protease granzyme B and for CD178 (Fas-Ligand) expression. Granzyme B positive cells were observed in the portal and lobular fields of the biopsies from chronic HBV patients. A significant positive correlation was observed between serum ALT and the numbers of granzyme B positive cells in portal infiltrates and serum ALT values ( $r_s=0.65$ ;  $p<0.001$ ) (Fig. 3), but not with the density of granzyme B+ cells in the lobular fields ( $r_s=0.23$ ;  $p=0.15$ ).

Expression of Fas-L was observed in all biopsies of chronic HBV patients, predominantly in lobular areas. In contrast, no expression of Fas-L was found in normal livers. Clone NOK-1 confirmed the results obtained by clone 5G51. Fas-L-expressing cells were morphologically distinguishable as Kupffer cells and other lymphoid cells. Staining of two serial slides of one specimen with CD68 and anti-Fas-L confirmed Fas-L expression on Kupffer cells (Fig. 4). The density of Fas-L positive cells between the parenchymal cells was significantly higher in biopsies taken during episodes of increased inflammatory liver injury ( $r_s=0.32$ ;  $p=0.05$ ) (Fig. 5).

### Intrahepatic CD8+ T-lymphocytes in relation to viral replication

The relation between immune effector cells and viral control was studied in 47 biopsies. These biopsies were from 27 HBeAg positive patients and 20 HBeAg negative patients. The numbers of CD8+ T-lymphocytes in the portal areas were equal in the HBeAg positive and in the HBeAg negative groups. However, in the HBeAg negative patients the density of CD8+ T-lymphocytes in the intralobular areas was higher compared to HBeAg positive patients ( $p=0.002$ ) (Fig. 6a). A inverse correlation was found between serum HBV-DNA and intralobular CD8+ T-lymphocytes ( $r_s=-0.44$ ;  $p=0.002$ ) (Fig. 6b).

The immune effector molecules granzyme B and Fas-L revealed no correlation with HBeAg status (data not shown). In all patients the numbers of CD8+ T-lymphocytes ( $10 \pm 5$ ) and granzyme B positive cells ( $13 \pm 9$ ) in the hepatic lobules were equal (Fig. 7a), whereas the portal fields contained significantly more CD8+ T-lymphocytes ( $37 \pm 19$ ) than granzyme B positive cells ( $14 \pm 8$ ;  $p=0.001$ ) (Fig. 7b). This suggests that all intralobular CD8+ T-lymphocytes have an activated cytolytic system, in contrast to those in portal infiltrates.

### Other immune effector cells

NK/NKT (CD56 positive) cells were rare in all groups ( $< 5$  per microscopic field), both in portal and lobular areas. The number of NK/NKT cells in biopsies of chronic HBV patients was equal to normal liver. No difference in numbers of NK/NKT cells was seen in the portal areas or hepatic lobules in patients with different ALT, HBeAg status or HBV-DNA (data not shown).

Monocytes and macrophages, including Kupffer cells (CD68+ cells) were abundant and equally present among the groups with different ALT values. CD68 positive cells were mainly present within the sinusoids, but some CD68 positive cells were also found in the portal areas

(data not shown). Plasmacytoid dendritic cells (CD123 expression) were scarcely observed intralobularly ( $2.0 \pm 1.5$ ) and minimally enhanced in comparison with normal liver ( $0.6 \pm 0.8$ ).

### Expression of anti-viral cytokines

IFN- $\gamma$  expression was sporadically present in all chronic HBV-infected patients ( $1.0 \pm 2.7$  positive cells per microscopic field). However, in fulminant HBV-infection ( $n=3$ ), many IFN- $\gamma$  positive cells were detected throughout the biopsy. In these biopsies the architecture of liver tissue was severely disturbed; thus lobular and portal area could not be differentiated. In two patients with acute non-viral hepatitis we also found a strong expression of IFN- $\gamma$ , particularly in the portal areas. Cells expressing TNF- $\alpha$  were also scarce or absent in chronic patients ( $0.1 \pm 0.8$  positive cells per microscopic field). In patients exhibiting IFN- $\gamma$  positive cells, TNF- $\alpha$  positive cells were observed as well. Again, many TNF- $\alpha$  positive cells were observed in the acute viral hepatitis biopsies. Both patients with acute non-viral hepatitis revealed clearly positive cells too, but lower in number. They were particularly localized in the portal infiltrates.

## DISCUSSION

In this study we investigated the occurrence of intrahepatic immune effector cells, cytotoxic effector molecules and IFN- $\gamma$  and TNF- $\alpha$  expressing cells in relation to inflammatory liver injury and viral control during chronic hepatitis B infection. The presence of intralobular CD8+ T-lymphocytes was most prominent in patients with normal to moderately elevated ALT and less noticeable in patients with high ALT values. This result extends the observations by Maini et al, who reported that a patient chronically infected with HBV with high ALT had lower number of CD8+ T-lymphocytes intralobular in comparison to a patient with normal liver enzymes. By contrast, in patients with elevated liver enzymes the absolute numbers of intrahepatic HBV-specific CD8+ T-lymphocytes were similar to patients without liver damage (9). Together these observations indicate that increased numbers of HBV specific or non-specific CD8+ T-lymphocytes infiltrating the liver parenchyma do not cause inflammatory liver injury during chronic HBV-infection.

We found a higher density of intralobular CD8+ T-lymphocytes in patients with HBeAg-negativity and low HBV-DNA. This may indicate CD8+ T-lymphocytes are important for immune control of viral replication. Although we have not determined whether the intralobular CD8+ T-lymphocytes were HBV specific, they were all in an activated state (Fig 7), probably capable of attacking virus-infected cells.

Fas-L expression was found in all chronic HBV-biopsies, but was absent in normal livers. This is in agreement with the observations of Galle et al., who described the primary involvement of Fas-L in hepatitis B related hepatocellular damage [11]. In our study, Fas-L expression was not only found in portal infiltrates, but predominantly in the lobuli. The localization and

morphology of the Fas-L expression resembled to a Kupffer cell staining with CD68. Although human Kupffer cells were not known to express Fas-L, it has been reported that IFN- $\gamma$  treatment can induce Fas-L messenger RNA in Kupffer cells in rats [12]. In our study, Fas-L expression in the lobuli was clearly upregulated in biopsies taken during episodes of increased ALT, suggesting a causative role for Fas-L on Kupffer cells in hepatocyte damage. Data from other studies show an upregulation of Fas-L expression by the human immunodeficiency virus in human macrophages, which mediates apoptosis of uninfected T-lymphocytes, suggesting that this could be also the case in a chronic HBV infection [13-14]. In addition to increased intralobular Fas-L expression, a significant positive correlation between granzyme expression in portal infiltrates and inflammatory liver injury was found. Since numbers of CD8+ T-lymphocytes in portal infiltrates were not increased in patients with high ALT, this suggests that activation of cytotoxic capacity of CD8+ T-lymphocytes in infiltrates may be involved in inflammatory injury.

CD56 positive (NK/NKT) cells were rare in all our specimens. The number of these cells in the lobuli did not correlate with liver damage or viral control. This does not imply that NK/NKT cells do not play any role in the anti-viral immune response, but their role during chronic infection is probably limited. These cells may be important for viral control in an early phase of acute infection [6]. A previous study has described NK/NKT cells inhibiting HBV replication by secreting antiviral cytokines after activation by injection of  $\alpha$ -galactosylceramide, a glycolipid antigen, in HBV transgenic mice [15] and it was recently reported that inhibition of HBV replication by activated NKT cells did not require recruitment of inflammatory cells to the liver [16].

By which mechanism the CD8+ T-lymphocytes control virus infection remains unclear. Studies using a transgenic mouse model of hepatitis B virus infection have demonstrated that virus-specific CD8+ T-lymphocytes can abolish HBV gene expression and replication in the liver by secretion of IFN- $\gamma$  and TNF- $\alpha$  without killing the hepatocytes [4, 5, 6, 17]. We found only few IFN- $\gamma$  and TNF- $\alpha$  producing cells in the biopsies taken during chronic HBV infection. This might be due to the insensitivity of the immunohistochemical detection method since cytokines are secreted and do not accumulate in the cell. However, we do not favour this explanation, since many IFN- $\gamma$  and TNF- $\alpha$ -positive cells were observed in liver biopsies taken during acute HBV-infection and clear expression was detected in liver biopsies from acute viral and non-viral hepatitis patients. These results suggest that cells producing high amounts of IFN- $\gamma$  and TNF- $\alpha$  are not present during chronic HBV-infection. The failure of prominent intrahepatic cytokine production observed in this study could therefore explain the viral persistence, even in those patients in which replication was suppressed. This failure was not due to a resting state of intrahepatic CD8+ T-lymphocytes.

CD8+ T-lymphocytes and NK-cells, once activated use the same the same lytic pathway for mediating target cell death. The equal numbers of intralobular granzyme B positive cells and CD8+ T-lymphocytes suggest that these CD8+ T-lymphocytes were activated. We cannot exclude prior release by the granzyme-negative expression of lymphocytes due to cell activation, but it



is widely accepted that once lytic granules mobilization has been initiated in the effector cell, it reflects the activated status of a CD8 T-lymphocyte toward a target cell [18].

CD123 expressing plasmacytoid dendritic cells were hardly increased in chronic HBV liver biopsies compared to normal liver tissue indicating that these IFN- $\alpha$  producers are not implicated in control of HBV replication during chronic infection. Donaghy et al reported that increasing viral load was correlated with depletion of myeloid and plasmacytoid DCs in blood of patients with an HIV-1 infection. It was suggested that disease progression was due to the loss of both DC populations in HIV infection [19]. The important function of PDCs was clearly demonstrated by Cella et al who showed that human PDCs stimulated with influenza virus and CD40-Ligand in vitro could not only produced IFN- $\alpha$ , but also efficiently induce a Th1 response. [20]. Possibly, chronicity of HBV-infection may, in addition to absence of IFN- $\gamma$  and TNF- $\alpha$  producing cells, be due to a paucity of IFN- $\alpha$  producing cells in the infected liver.

In conclusion, low HBV replication and HBeAg negativity is associated with a larger number of intralobular CD8+ T-lymphocytes. Intralobular CD8+ T-lymphocytes were all activated cells and contained granzyme B, a marker of the lytic pathway, but did not produce high levels of cytokines. Increased Fas-L expression on Kupffer cells and increased cytolytic activity of cells in portal infiltrates among patients with severe liver inflammation appears to play a major role in the pathophysiology of liver injury during chronic HBV infection.

## ACKNOWLEDGEMENTS

The authors would like to acknowledge S. Mancham, A. Herscheid (Dept. of Gastroenterology and Hepatology), M. van Meurs (Dept. of Immunology), W.C.J. Hop (Dept. of Epidemiology and Biostatistics) and L. Nelemans (Dept. of Pathology) for their assistance in this study.

## REFERENCES

1. Chisari FV, Ferrari C. 1995. Hepatitis B virus immunopathogenesis. *Ann Rev Immunol* 13: 29-60
2. Reherrmann B, Fowler P, Sidney J, Person J, Redeker R, Brown M, *et al.* The cytotoxic T lymphocyte response to multiple hepatitis B virus polymerase epitopes during and after acute viral hepatitis. *J Exp Med* 1995;181: 1047-1058
3. Webster GJ, Reignat S, Maini MK, Whalley SA, Ogg GS, King A, *et al.* Incubation phase of acute hepatitis B in man: dynamic of cellular immune mechanisms. *Hepatology* 2000;32: 1117-1124
4. Guidotti LG, Ishikawa T, Hobbs MV, Matzke B, Schreiber R, Chisari FV. Intracellular inactivation of the hepatitis B virus by cytotoxic T lymphocytes. *Immunity* 1996;4: 25-36
5. Guidotti LG, Ando K, Hobbs MV, Ishikawa T, Runkel L, Schreiber RD, *et al.* Cytotoxic T lymphocytes inhibit hepatitis B virus gene expression by a noncytolytic mechanism in transgenic mice. *Proc Natl Acad Sci USA* 1994;91: 3764-3768
6. Guidotti LG, Rochford R, Chung J, Shapiro M, Purcell R, Chisari FV. Viral clearance without destruction of infected cells during acute HBV infection. *Science* 1999;284: 825-829
7. Ando K, Moriyama T, Guidotti LG, Wirth S, Schreiber RD, Schlicht HJ, *et al.* Mechanisms of class I restricted immunopathology. A transgenic mouse model of fulminant hepatitis. *J Exp Med* 1993;178: 1541-1554
8. Bertoletti A, Constanzo A, Chisari FV, Levrero M, Artini M, Sette A, *et al.* Cytotoxic T lymphocyte response to a wild-type hepatitis B virus epitope in patients chronically infected by variants viruses carrying substitutions within the epitope. *J Exp Med* 1994;180: 933-943
9. Maini MK, Boni C, Lee CK, Larrubia JR, Reignat S, Ogg GS, *et al.* The role of virus-specific CD8(+) cells in liver damage and viral control during persistent hepatitis B virus infection. *J Exp Med* 2000;191: 1269-1280
10. Siegal FP, Kadowaki N, Shodell M, Fitzgerald-Bocarsly PA, Shah K, Ho S, *et al.* The nature of the principal type 1 interferon-producing cells in human blood. *Science* 1999;284: 1835-1837
11. Galle PR, Hofmann WJ, Walczak H, Otto G, Stremmel W, Krammer PH, *et al.* Involvement of the CD95 (APO-1/Fas) receptor and ligand in liver damage. *J Exp Med* 1995;182: 1223-1230
12. Muschen M, Warskulat U, Peters-Regehr T, Bode JG, Kubitz R, Haussinger D. Involvement of CD95 (Apo-1/Fas) ligand expressed by rat Kupffer cells in hepatic immunoregulation. *Gastroenterology* 1999;116: 666-677
13. Badley AD, McElhinny JA, Leibson PJ, Lynch DH, Alderson MR, Paya CV. Upregulation of Fas ligand expression by human immunodeficiency virus in human macrophages mediates apoptosis of uninfected T lymphocytes. *J Virol* 1996;70: 199-206
14. Dockrell DH, Badley AD, Villacian JS, Heppelmann CJ, Algeciras A, Ziesmer S, *et al.* The expression of Fas Ligand by macrophages and its upregulation by human immunodeficiency virus infection. *J Clin Invest* 1998;101: 2394-2405
15. Kakimi K, Guidotti LG, Koezuka Y, Chisari FV. Natural killer T cell activation inhibits hepatitis B virus replication in vivo. *J Exp Med* 2000;192: 921-930
16. Kakimi K, Lane TE, Chisari FV, Guidotti LG. Cutting edge: Inhibition of hepatitis B virus replication by activated NK T cells does not require inflammatory cell recruitment to the liver. *J Immunol* 2001;167: 6701-6705
17. Guidotti LG, Chisari FV. To kill or to cure: options in host defense against viral infection. *Curr Opin Immunol* 1996;8: 478-483
18. Griffiths GM, Mueller C. Expression of perforin and granzymes in vivo: potential diagnostics markers for activated cytotoxic cells. *Immunol Today* 1991;12: 415-419
19. Donaghy H, Pozniak A, Gazzard B, Quazi N, Gilmour J, Gotch F, *et al.* Loss of blood CD11c(+) myeloid and CD11c(-) plasmacytoid dendritic cells in patients with HIV-1 infection correlates with HIV-1 RNA virus load. *Blood* 2001;98: 2574-2576
20. Cella M, Facchetti F, Lanzavecchia A, Colonna M. Plasmacytoid dendritic cells activated by influenza virus and CD40L drive a potent Th1 polarization. *Nat Immunol* 2000;1: 305-310

# Chapter 3

## **Intrahepatic CD8 T-lymphocytes and HBV core expression in relation to response to antiviral therapy for chronic hepatitis B patients**

T.J. Tang<sup>1</sup>, R.A. de Man<sup>1</sup>, J.G. Kusters<sup>1</sup>, J. Kwekkeboom<sup>1</sup>, W.C.J. Hop<sup>2</sup>, R.G. van der Molen<sup>1</sup>, S.W. Schalm<sup>1</sup>, H.L.A. Janssen<sup>1</sup>

Departments of <sup>1</sup>Gastroenterology and Hepatology, <sup>2</sup>Epidemiology and Biostatistics  
Erasmus MC, University Medical Center Rotterdam, The Netherlands

J Med Virol 2004;72:215-22



## ABSTRACT

Recognition of HBV-infected hepatocytes by CD8 T-lymphocytes is important for viral clearance. Expression of hepatitis B core antigen (HBcAg) in HBV-infected hepatocytes can trigger this antiviral T-cell response. The intrahepatic CD8 T-lymphocytes and HBcAg expression were investigated in relation to response to antiviral therapy.

Forty chronic HBeAg-positive patients treated with either lamivudine (n=20) or interferon-alpha (n=20) were investigated. Ten patients from each treatment group exhibited a response. Liver biopsies were carried out before and after therapy. CD8 T-lymphocytes and HBcAg expression were detected by immunohistochemistry. The number of pretreatment intrahepatic CD8 T-lymphocytes was significantly higher in responders ( $p=0.008$ ). In responders baseline nuclear HBcAg expression tended to be lower ( $p=0.09$ ). Cytoplasmic expression was not significantly different between responders and non-responders ( $p=0.46$ ). The number of CD8 T-lymphocytes correlated with cytoplasmic HBcAg ( $r_s=0.31$ ;  $p=0.04$ ); CD8 T-lymphocytes were situated in clusters of hepatocytes with cytoplasmic HBcAg. Longitudinal analysis showed a significant reduction of CD8 T-lymphocytes after treatment in responders ( $p<0.001$ ). Multivariate analysis revealed pretreatment CD8 T-lymphocytes and age as independent prognostic factors for response (n=40). The number of pretreatment CD8 T-lymphocytes was the only independent prognostic indicator for response to interferon-alpha ( $p=0.03$ ); it was of borderline significance for lamivudine therapy ( $p=0.06$ ).

It is concluded that the number of pretreatment intrahepatic CD8 T-lymphocytes is an important predictor of response to HBV therapy with either interferon-alpha or lamivudine. Response to therapy led to a significant reduction of intrahepatic CD8 T-lymphocytes. Co-localisation of CD8 T-lymphocytes and HBcAg-positive hepatocytes suggests antiviral activity predominantly at the site of maximum HBV replication.

## INTRODUCTION

More than one-third of the global population has been infected with the hepatitis B virus (HBV) and approximately 350 million people are chronic carriers of HBV. These patients have an increased risk of developing liver cirrhosis and hepatocellular carcinoma [1]. Spontaneous remission with effective control of viral replication occurs in a small number of patients during the natural history of chronic HBV infection. These remissions are the desired result of antiviral treatment for chronic HBV. The drugs interferon-alpha and lamivudine are used to treat chronic HBV infection, but only a small number of patients (20-30%) achieve a sustained response to these antiviral agents [2, 3]. Recent studies provide substantial evidence that the host antiviral immune response, in particular the intrahepatic immune response, to HBV-antigens is the main determinant of the outcome of HBV infection [4]. Hepatitis B core antigen (HBcAg) in the infected liver is associated with active viral replication [5, 6]. During an active and ongoing hepatitis, HBcAg is localized predominantly in the cytoplasm of the infected hepatocyte. However, in patients with no or minimal inflammatory activity, HBcAg is found mainly in the nucleus. These findings have led to the hypothesis that infected hepatocytes with a cytoplasmic or membraneous HBcAg expression trigger CD8 T-lymphocytes, resulting in cytolysis of infected hepatocytes [7]. We investigated the predictive value of the number of CD8 T-lymphocytes and HBcAg expression in the liver in relation to response to antiviral therapy for chronic HBV patients.

## MATERIAL AND METHODS

### Patients and controls

Forty patients with chronic hepatitis B (HBsAg, HBeAg and HBV-DNA positive for more than 6 months) were studied. Twenty patients received interferon-alpha (Intron A, 10 MU thrice weekly subcutaneously for 32 weeks) and 20 patients received lamivudine therapy (100 mg/day po for 11 to 169 weeks). To achieve optimal data on the mechanism of response to antiviral therapy for both regimens we selected a population with 50% response in both treatment groups. A control group comprised 5 healthy subjects without evidence of exposure to the HBV virus (i.e. HBsAg and anti-HB core negative). The definition of response consisted of HBeAg negativity and HBV-DNA levels below the detection limit ( $<1.0 \text{ E5 HBV-DNA copies/mL}$ ) at the end of therapy. All patients were negative for antibodies against human immune deficiency virus (HIV), hepatitis C and hepatitis D. A liver biopsy was obtained before therapy and at the end of treatment. The liver specimens were fixed in phosphate-buffered formalin and embedded in paraffin. The study was approved by the Medical Ethical Committee of the Erasmus Medical Center and written informed consent was obtained prior to therapy.

### Virological assessments

HBsAg, HBeAg, anti-HBe, anti-HIV, anti-HCV and anti-HDV were determined quantitatively by IMX (Abbott Laboratories, North Chicago, IL) according to the manufacturer's instructions. HBV-DNA level in sera was measured by Hybrid Capture II microplate assay (Digene Corporation, Gaithersburg, U.S.A.), as described by the manufacturer.

### Detection of CD8 T-lymphocytes and HBcAg in the liver

CD8 T-lymphocytes and HBcAg expression in hepatocytes were examined by immunohistochemical double stain with CD8 mAb (clone C8/14415) and rabbit anti-HBcAg from DAKO, Glostrup Denmark. The liver sections were first deparaffinized with xylene (Lab Scan Ltd, Dublin, Ireland) and ethanol (Merck, Darmstadt, Germany). The antigen retrieval was performed by temperature-controlled incubation at 99°C in citrate buffer (pH 6.0) in a microwave oven, followed by incubation with CD8 mAb. The liver specimens were incubated with goat anti-mouse immunoglobulins (GAM, DAKO), followed by alkaline-phosphatase-anti-alkaline phosphatase complex (APAAP, Serotec, UK). Subsequently, the specimens were incubated with rabbit anti-HBcAg. Hepatic HBcAg expression was detected by an immunoperoxidase kit (En Vision HRP system, DAKO). The order of revealing the two antigens was initial incubation with diaminobenzidine for the HBcAg expression and secondly with Fast Blue salt / naphthol AS-BI phosphate solution supplemented with levamisole (all from Sigma-Aldrich Chemie, Steinheim, Germany) for the visualization of CD8 T-lymphocytes. Negative controls were performed by replacement of the primary mAb by an isotype-matched control mAb.

### Quantitation and statistical analysis

The liver specimens were examined microscopically (Zeiss Axioscop) at 400X. In every specimen 10 fields were selected at random in liver lobuli to count the CD8 T-lymphocytes and hepatocytes with HBV core expression (nuclear and cytoplasmatic). The mean of all counts was used for analysis. All results were counted by one investigator (T.J.T.), who was blinded for response and treatment regimen of the patients. Statistical analysis of differences between groups was performed with the Mann-Whitney *U* test. Pretreatment and posttreatment levels within each group were compared using the Wilcoxon signed rank test. Spearman's correlation coefficients ( $r_s$ ) were used to investigate correlations. Univariate analysis was conducted to investigate the presence of covariation of response with baseline variables. Variables that were statistically significant (two sided,  $p < 0.05$ ) or exhibited a marginal association ( $p \leq 0.10$ ) according to univariate analysis were subsequently introduced into multivariate analysis, which was assessed by logistic regression analysis. SPSS 9.0 for Windows (SPSS, Chicago, IL) was used for all statistical analysis. In all analyses a *p*-value of  $< 0.05$  was considered statistically significant. Data are expressed as median (range), unless indicated otherwise.



## RESULTS

### Patient characteristics

Baseline characteristics of responders and non-responders are shown in Table 1. Responders had lower levels of hepatitis B virus DNA than non-responders. The distribution of gender, age, race and serum alanine aminotransferase levels and race was not significantly different between responders and non-responders.

**Table 1.** Baseline characteristics

	All patients (n=40)	Responders (n=20)	Non-responders (n=20)	p-value: response vs. non-response
Sex (male/female)	34 / 6	17 / 3	17 / 3	n.s.
Age (years)*	28 (16-64)	34 (15-64)	25 (16-61)	0.08
ALT (units/L)*	79(20-786)	84 (20-786)	76(31-244)	0.43
HBV-DNA (geq/mL)*	3.0 E8 (6.6 E5-1.4 E10)	1.3 E8 (6.6 E5-3.5 E9)	5.4 E8 (1.5 E6-1.4 E10)	0.01
Race (C/ A/ B)**	29/ 9/ 2	17/ 2/ 1	12/ 7/ 1	n.s.

\* median (range)

\*\* C=caucasians A=asians B= Africans

### Pretreatment intrahepatic CD8 T-lymphocytes and HBcAg in relation to treatment response

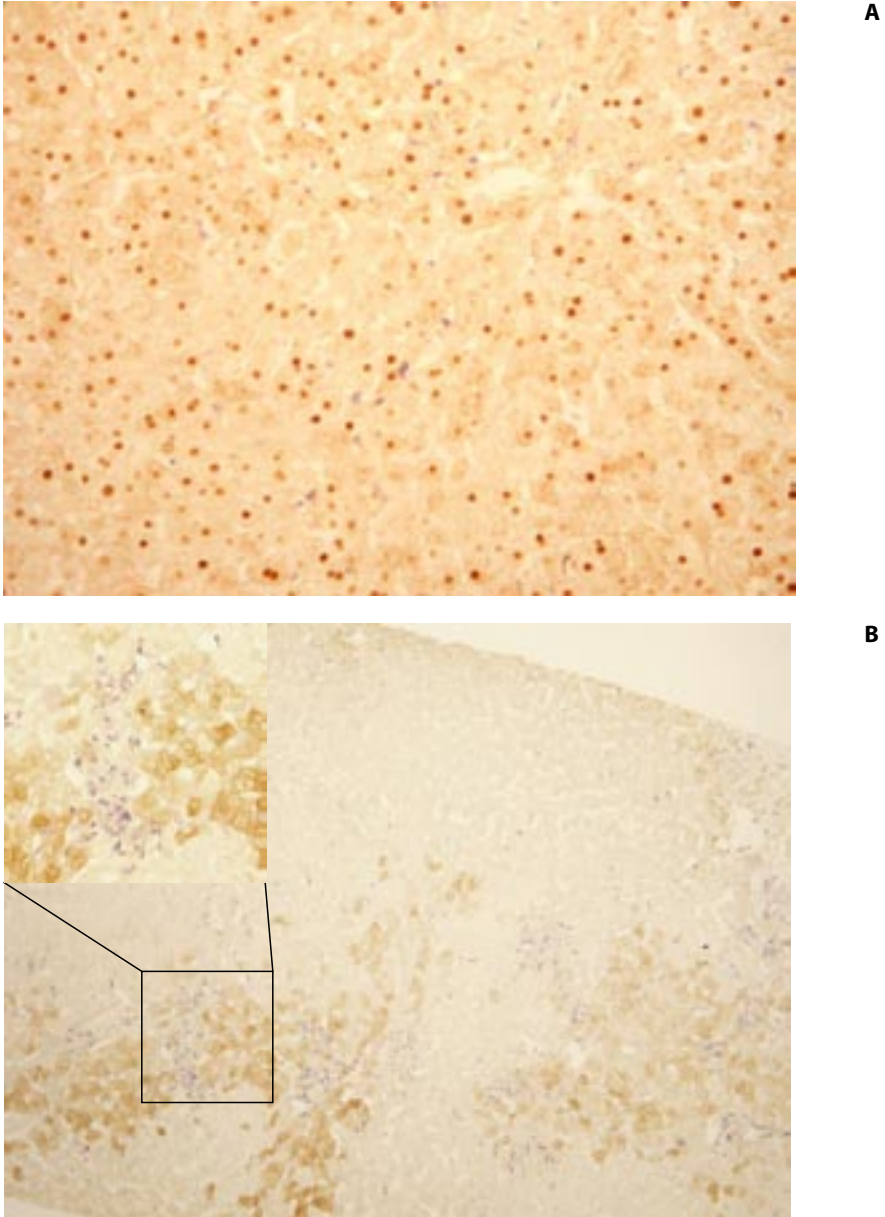
Pretreatment numbers of CD8 T-lymphocytes were significantly higher in responders than in non-responders ( $p=0.008$ ) (Table 2). The number of hepatocytes with nuclear HBcAg expression tended to be lower in responders than in non-responders ( $p=0.09$ ) (Table 2). No correlation was observed between the number of CD8 T-lymphocytes and nuclear expression of HBcAg in hepatocytes ( $r_s=0.23$ ;  $p=0.13$ ). Median cytoplasmic expression of HBcAg was 2.5 (range 0-29) in responders vs. 1.5 (range 0-21) in non-responders ( $p=0.46$ ). A significant correlation between numbers of CD8 T-lymphocytes and hepatocytes with cytoplasmic expression of HBcAg was observed ( $r_s=0.32$ ;  $p=0.04$ ). Furthermore, these CD8 T-lymphocytes were situated predominantly within the vicinity of hepatocytes with cytoplasmic HBcAg expression. Nuclear and cytoplasmic HBcAg expression in relation to CD8 T-lymphocytes are shown in figure 1.

**Table 2.** Expression of CD8 T-lymphocytes and HBcAg in pre-treatment biopsy

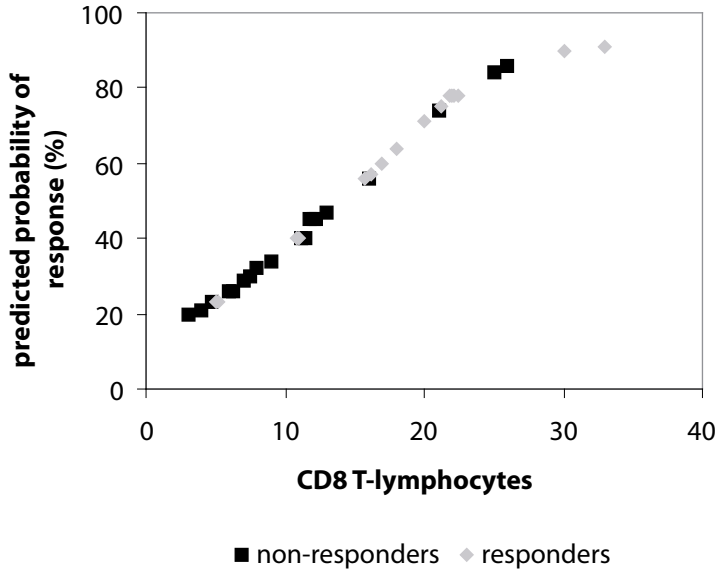
	All patients (n=40)	Responders (n=20)	Non-responders (n=20)	p-value: response vs. non-response
Number CD8 T-lymphocytes*	12.0 (3-31)	15.5 (5-31)	9.5 (3-26)	0.008
Number nuclear HBcAg hepatocytes*	8.0 (0-49)	4.0 (0-45)	12.5 ( 1-49)	0.09
Number cytoplasmic HBcAg hepatocytes*	2.0 (0-33)	2.5 (0-33)	1.5 (0-21)	0.46

median (range)

\* per microscopic field



**Figure 1.** Immuno double-stain of HBCAg and CD8 T-lymphocytes (brown=HBCAg; CD8 T-lymphocytes=blue). Scattered nuclear expression of HBCAg and CD8 T-lymphocytes (original magnification  $\times 200$ ) (A). Clustered cytoplasmic expression of HBCAg (original magnification  $\times 100$ ) and co-localisation of cytoplasmic HBCAg and CD8 T-lymphocytes (inserted left, original magnification  $\times 200$ ) (B).



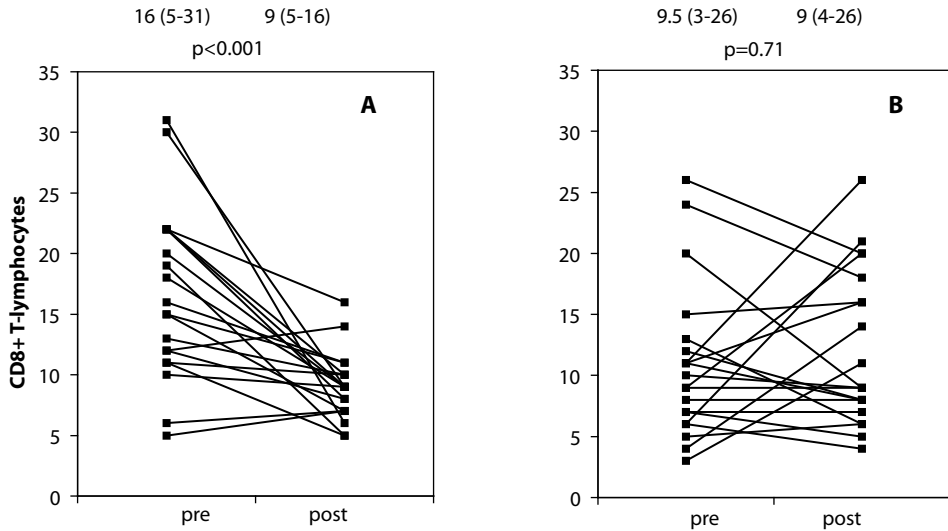
**Figure 2.** The predicted probability of subsequent response to therapy displayed as a function of the number of CD8 T-lymphocytes per lobular field in biopsies taken before treatment. The curve is based on logistic regression modeling of pretreatment CD8 T-lymphocytes. Individual datapoints of responders and non-responders are depicted.

**Table 3.** Results of multivariate analysis (n=40)

	Odds ratio	95% CI	p-value
Age	1.08	1.01-1.15	0.02
CD8 T-lymphocytes	1.20	1.05-1.37	0.007

CI: confidence interval

Univariate analysis of the pretreatment co-variables of response - age ( $p=0.08$ ), ALT level ( $p=0.43$ ), HBV-DNA level ( $p=0.01$ ), CD8 T-lymphocytes ( $p=0.008$ ), nuclear HBcAg expression ( $p=0.09$ ) and cytoplasmic HBcAg expression ( $p=0.46$ ) - revealed only CD8 T-lymphocytes as a significant predictor of response (Table 1 and 2). In multivariate analysis, age ( $p=0.02$ ) and pretreatment number of CD8 T-lymphocytes ( $p=0.007$ ) emerged as independent variables of significance for response (Table 3). The predicted probability of subsequent response to antiviral therapy according to the regression modeling of the pretreatment numbers of CD8 T-lymphocytes is shown in figure 2. Serum ALT did not emerge as predictor for response while CD8 T-lymphocytes was identified as a strong predictor. However, serum ALT and the quantity of CD8 T-lymphocytes did correlate significantly ( $r_s=0.45$ ,  $p=0.004$ ), indicating that these two variables were both associated with active liver disease.



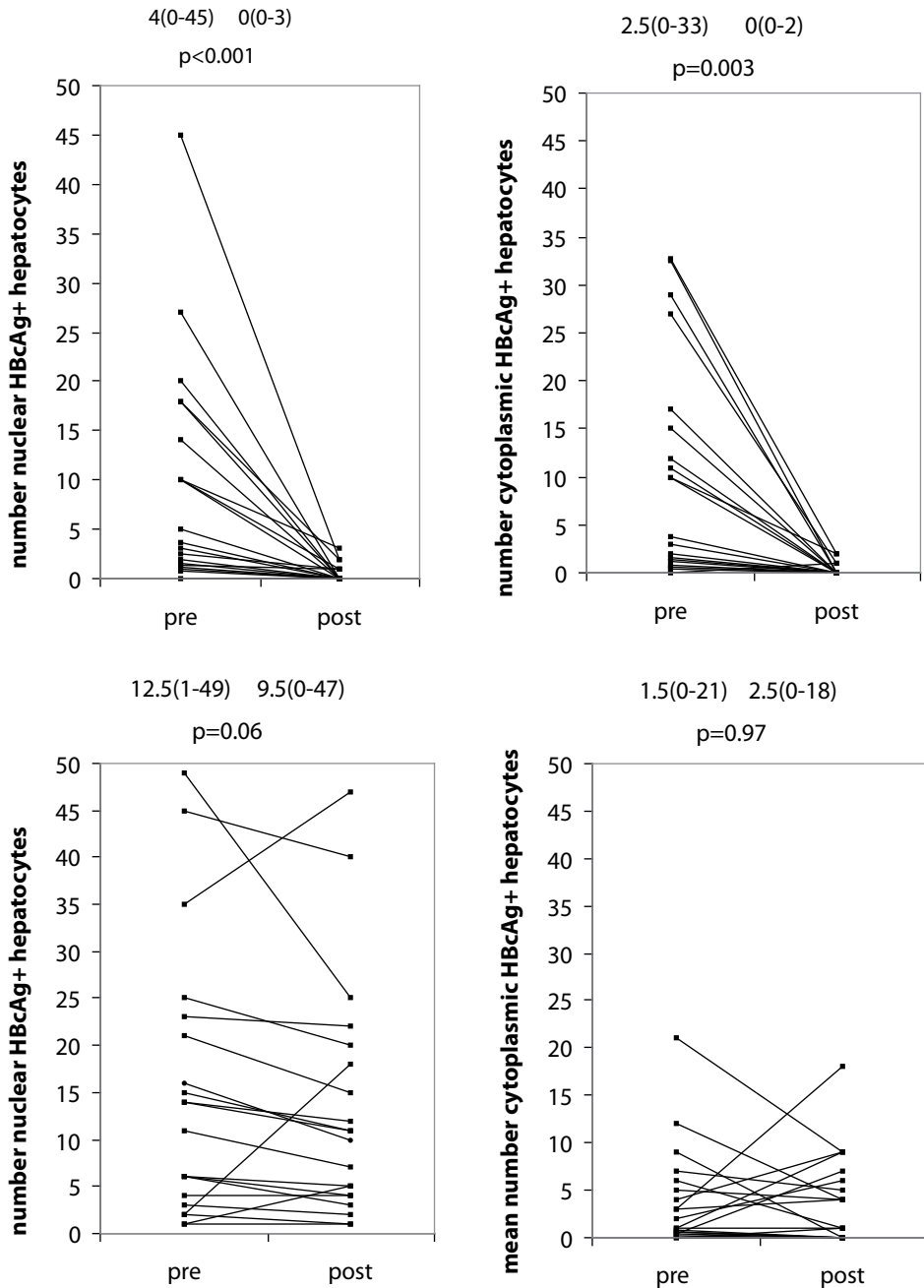
**Figure 3.** Densities of intralobular CD8 T-lymphocytes in serial liver biopsy specimens before therapy and at the end of treatment of responders (A) and non-responders (B). Median and ranges are depicted at the top.

#### Alteration of intrahepatic CD8 T-lymphocytes and HBcAg during antiviral treatment

Longitudinal analysis of pretreatment and posttreatment biopsies from the responders showed a significant reduction of CD8 T-lymphocytes ( $p<0.001$ ) (Fig. 3a), while the numbers of CD8 T-lymphocytes remained unchanged in the non-responders ( $p=0.71$ ) (Fig. 3b). Nuclear expression ( $p<0.001$ ) and cytoplasmic expression ( $p=0.003$ ) of HBcAg in the hepatocytes decreased significantly in the responders (Fig 4a and Fig. 4b). In contrast, no significant reduction of nuclear ( $p=0.06$ ) or cytoplasmic ( $p=0.97$ ) expression of HBcAg was observed in the non-responders (Fig. 4c and Fig. 4d)

#### Interferon-alpha and lamivudine treatment: subgroup analysis for intrahepatic CD8 T-lymphocytes and HBcAg

Age, sex, race, and serum values for ALT and HBV-DNA did not differ across the treatment groups. Pretreatment densities of CD8 T-lymphocytes and HBcAg were also comparable between treatment groups and alteration during therapy did not differ significantly between patients treated with interferon-alpha and lamivudine (data not shown). The response rate 6 months after discontinuation of therapy was 70% for interferon-alpha and 10% for lamivudine. This difference in sustained response could be explained by a state of immune control induced by interferon-alpha, but not lamivudine. Therefore, we hypothesized that the immune modifying effect of interferon-alpha might have led to a different pattern in CD8 response than the predominantly antiviral effect of lamivudine. However, in both treatment groups pretreatment CD8 T-lymphocytes were higher in responders than in non-responders and during therapy a



**Figure 4.** Serial liver biopsy specimens before therapy and at the end of treatment of responders in relation to nuclear (A) and cytoplasmic expression (B) of HBcore and non-responders in relation to nuclear (C) and cytoplasmic expression (D) of HBcAg. Median and ranges are depicted at the top.

similar reduction in CD8 T-lymphocytes was found for interferon-alpha and lamivudine treated patients: In interferon-alpha responders median CD8 T-lymphocyte number was 13.5 (range 5-31) before treatment and 8.5 (range 5-11) after treatment ( $p=0.01$ ); in non-responders the median number of CD8 T-lymphocytes remained about the same (pretreatment 7.5 (range 3-15) vs. posttreatment 10.0 (range 5-21);  $p=0.56$ ). In lamivudine responders median numbers of CD8 T-lymphocytes decreased from 19 (range 5-30) pretreatment to 9.5 (range 7-16) ( $p=0.01$ ) posttreatment; in lamivudine non-responders median CD8 T-lymphocytes were comparable before and after treatment (pretreatment 11.5 (range 5-26) vs. posttreatment 9 (range 4-26);  $p=0.28$ ).

Univariate analysis for baseline characteristics of patients treated with interferon-alpha showed that the number pretreatment CD8 T-lymphocytes ( $p=0.03$ ) was the only predictor of response. Age, HBV-DNA, serum ALT level, nuclear HBcAg and cytoplasmic HBcAg did not emerge as predictors of response. After multivariate analyses pretreatment CD8 T-lymphocytes remained the only independent prognostic indicator of response. In the lamivudine-treated patients, univariate analysis did not yield any significant predictors of response. In the multivariate analysis age ( $p=0.05$ ) and pretreatment CD8 T-lymphocytes ( $p=0.06$ ) were borderline independent indicators of response.

## DISCUSSION

In the present study intrahepatic CD8 T-lymphocytes were strongly associated with response to antiviral therapy in two different ways. Firstly, the pretreatment number of intrahepatic CD8 T-lymphocytes was higher in responders than in non-responders and, secondly, intrahepatic CD8 T-lymphocytes decreased significantly during therapy in responders whereas they remained unchanged in non-responders. Both phenomena were found in patients treated with either interferon-alpha or lamivudine.

The importance of CD8 T-lymphocytes has been well documented in acute HBV infection where a strong CD8 T-lymphocyte response is associated with viral clearance [8, 9]. It is generally acknowledged that this CD8 T-lymphocyte response is antigen specific, present in the liver, and able to clear HBV infection by cytolytic and noncytolytic effector functions [10]. The CD8 T-lymphocytes are specific for a range of different epitopes within HBV core, polymerase and envelope proteins [11, 12]. In contrast to acute HBV infection, chronic HBV carriers exhibit a weak peripheral CD8 T-lymphocyte response [13, 14]. A recent study demonstrated the existence of HBV-specific CD8 T-lymphocytes in the liver of chronic HBV carriers, but there appeared no relation between their number and the occurrence of hepatocellular injury [15]. However, these authors observed that the total numbers of CD8 T-lymphocytes (either HBV-specific or non-specific) was increased in liver biopsies of patients with hepatocellular injury, which is in agreement with the present observation that numbers of intrahepatic CD8 T-

lymphocytes are positively correlated with ALT values. Since in their study the patients groups with high and low viremia strongly differed in ALT-values, no definitive conclusion could be drawn on the relation between total or HBV-specific CD8 T-lymphocytes and immune control of viral replication. Our study in which responders and non-responders did not differ in ALT-value, allowed to investigate the relation between total intrahepatic CD8 T-lymphocytes and response to therapy independently of the extent of hepatocellular inflammation. We found that the total numbers of intrahepatic CD8 T-lymphocytes was higher in pre-treatment liver biopsies of responders as compared to non-responders. It remains to be established, however, whether this difference reflects as difference in the quantity of virus-specific T-lymphocytes. Also non-HBV specific bystander T-lymphocytes may contribute to clearance of the virus, e.g. by secretion of antiviral cytokines. In the current study we did not investigate the cytolytic and antiviral effector mechanisms expressed by CD8 T-lymphocytes, but previous studies have shown that CD8 T-lymphocytes can induce inflammatory liver injury by induction of apoptosis, mediated by Fas Ligand and cytolytic granzyme molecules [16, 17].

In the setting of antiviral treatment little is known about the intrahepatic response of CD8 T-lymphocytes. It is possible that responders have a pre-existent T-cell response, which is unable to clear the virus completely. Viral clearance can be achieved either by boosting the immune response with an immunomodulator or by lowering the viral load. Additional factors such as HBV genotype and viral mutations may have an effect on the establishment of viral control. Several antiviral regimens are targeted to boost the HBV-specific CD8 T-cell response, either by immune modulation or by inhibition of viral replication. For guidance of antiviral management, our results showed that the number of intrahepatic CD8 T-lymphocytes could be helpful to predict subsequent response to antiviral therapy. However, it should not be interpreted as proof that low numbers of CD8 T-lymphocytes have no prognostic value for response. Other strong predictors of response, such as serum ALT and HBV-DNA, should also be assessed to determine the optimum therapeutic regimens for chronic HBV patients [18, 19]. Furthermore, it should be mentioned that since the number of patients is relatively small, the factors found to be predictive of response by means of multivariate analysis can only be considered as probable.

Subgroup analysis revealed that the number of pretreatment intrahepatic CD8 T-lymphocytes was the only prognostic indicator for response to interferon-alpha therapy, while it emerged as a borderline independent indicator for response to lamivudine therapy. Interestingly, the 6-month response rate after discontinuation of therapy was 70% for interferon-treated patients and 10% for lamivudine-treated patients. This suggests that inhibition of viral replication by lamivudine alone does not result in HBV elimination and interferon-alpha-induced immune reactivity is required for complete control [20-22]. The quantity and response of intrahepatic CD8 T-lymphocytes cannot explain this difference in response pattern, as these were similar for patients treated with lamivudine or interferon-alpha. In peripheral blood Marinou et al. compared T-cell responses in chronic HBV patients during interferon-alpha therapy and combined interferon-alpha-lamivudine in patients who did not respond previously to interferon-alpha monotherapy.

They observed no difference in T-cell response during interferon-alpha monotherapy and during combination, and concluded that significant inhibition of viral replication by lamivudine did not restore the hyporesponsiveness in chronic HBV [23]. In contrast, Boni et al. reported that in chronic HBV patients undergoing lamivudine treatment, reduction in viral load allows repopulation of functionally active HBV specific CD8 T-lymphocytes in peripheral blood [24]. A possible explanation of these contradictory data could be a difference in duration of infection in both studies. To further dissect the difference in response mechanism between interferon-alpha and nucleoside analogues we are currently investigating the function and HBV specificity of intrahepatic CD8 T-lymphocytes during therapy with antiviral agents.

The presence of HBcAg in the infected hepatocytes is associated with active replication. In our study serum HBV-DNA level correlated with nuclear ( $r_s=0.45$ ;  $p=0.004$ ) but not cytoplasmic expression of HBcAg ( $r_s=0.17$ ;  $p=0.29$ ). HBcAg expression is found predominantly in the nucleus of patients with minimal hepatitis activity, while HBcAg is prominent in the cytoplasm of patients with active and ongoing hepatitis [7, 25-27]. In our responders we not only observed a significant reduction of intrahepatic numbers of CD8 T-lymphocytes but also an almost complete disappearance of HBcAg-infected hepatocytes at the end of therapy. Patients with predominant cytoplasmic HBcAg expression had higher levels of CD8 T-lymphocytes in the lobular fields ( $p=0.04$ ). Moreover, these CD8 T-lymphocytes were situated predominantly in hepatocyte clusters with HBcAg expression in the cytoplasm. Both the combined reduction of CD8 T-lymphocytes and HBcAg-positive hepatocytes after successful antiviral therapy as well as the co-localisation of CD8 T-lymphocytes and HBcAg-positive hepatocytes within the liver parenchyma indicate that responders have higher numbers of intrahepatic CD8 T-lymphocytes able to exert antiviral activity at the site of maximum replication. An efficient immunological response will result in a lowering of the viral load and, consequently, CD8 T-lymphocytes numbers would fall with the decrease of HBcAg-infected hepatocytes. Further studies are needed to elucidate whether the CD8 T-lymphocytes present in the lobular fields at the end of therapy could be primarily HBV-specific. HBV-specific CD8 T-lymphocytes can persist long after recovery of HBV-infection, despite low levels of HBV DNA [28].

In conclusion, immunohistochemical analyses of a series of patients with chronic hepatitis B infection treated with antiviral therapy revealed that responders exhibit an increased pretreatment number of intrahepatic CD8 T-lymphocytes. The pretreatment number of intrahepatic CD8 T-cells was found to be an independent predictor of response for therapy with interferon-alpha or lamivudine. Co-localisation of intrahepatic CD8 T-lymphocytes and HBcAg-infected hepatocytes suggests that CD8 T-lymphocytes are able to expand and exert antiviral activity at the site of maximum HBV replication in the liver.



## **ACKNOWLEDGEMENTS**

The authors thank Annemiek van der Eijk for recruiting the lamivudine-treated patients and Shanta Mancham for technical assistance (both Department of Gastroenterology and Hepatology, Erasmus MC), and Luc Nelemans, Department of Pathology, Erasmus MC, for processing the paraffin slides. We also thank Suzan Pas and dr. H.G.M. Niesters, Department of Virology, Erasmus MC, for the determination of the HBV-DNA levels in serum.

## REFERENCES

1. Kane M. Global programme for control of hepatitis B infection. *Vaccine* 1995; 13:547-49
2. Dienstag JL, Schiff ER, Wright TL, Perrillo RP, Hann HW, Goodman Z, *et al.* Lamivudine as initial treatment for chronic hepatitis B in the United States. *N Engl J Med* 1999;341:1256-1263
3. Hoofnagle JH, Peters M, Mullen KD, Jones DB, Rustgi V, Di Bisceglie A, *et al.* Randomized, controlled trial of recombinant human  $\alpha$ -interferon in patients with chronic hepatitis B. *Gastroenterology* 1988;95:1318-1325
4. Rehermann B. Intrahepatic T-cells in hepatitis B: viral control versus liver cell injury. *J Exp Med* 2000;191:1263-1268
5. Hadziyannis SJ, Lieberman HM, Karvountzis GG, Shafritz DA. Analysis of liver disease, nuclear HBcAg, viral replication, and hepatitis B virus DNA in liver and serum of HBeAg vs anti-HBe positive carriers of hepatitis B virus. *Hepatology* 1983;3:656-662.
6. Huang SN, Neurath AR. Immunohistologic demonstration of hepatitis B viral antigens in liver with reference to its significance in liver injury. *Lab invest* 1979;40:1-17.
7. Chu CM, Liaw YF. Intrahepatic distribution of hepatitis B surface and core antigens in chronic hepatitis B virus infection. Hepatocyte with cytoplasmic / membranous hepatitis B core antigen as a possible target for immune hepatocytolysis. *Gastroenterology* 1987;92:220-225.
8. Rehermann B, Fowler P, Sidney J, Person J, Redeker A, Brown M, *et al.* The cytotoxic T lymphocyte response to multiple hepatitis B virus polymerase epitopes during and after acute viral hepatitis. *J Exp Med* 1995;181:1047-1058.
9. Webster GJ, Reignat S, Maini MK, Whalley SA, Ogg GS, King A, *et al.* Incubation phase of acute hepatitis B in man: dynamic of cellular immune mechanisms. *Hepatology* 2000;32:1117-1124.
10. Guidotti LG, Chisari FV. To kill or to cure: options in host defense against viral infection. *Curr Opin Immunol* 1996;8:478-483.
11. Chisari FV, Ferrari C. Hepatitis B virus immunopathogenesis. *Annu Rev Immunol* 1995;13:29-60.
12. Bertoletti A, Chisari FV, Penna A, Guilhot S, Galati L, Missale G, *et al.* Definition of a minimal optimal cytotoxic T-cell epitope within the hepatitis B virus nucleocapsid protein. *J Virol* 1993;67:2376-2380.
13. Bertoletti A, Constanzo A, Chisari FV, Levrero M, Artini M, Sette A, Penna A, *et al.* Cytotoxic T lymphocyte response to a wild-type hepatitis B virus epitope in patients chronically infected by variant viruses carrying substitutions within the epitope. *J Exp Med* 1994;180:933-943.
14. Nayarsina R, Fowler P, Guilhot S, Missale G, Cerny A, Schlicht HJ, *et al.* HLA A2 restricted cytotoxic T-lymphocyte responses to multiple hepatitis B surface antigen epitopes during hepatitis B virus infection. *J Immunol* 1993;150:4659-4671.
15. Maini MK, Boni C, Lee CK, Larrubia JR, Reignat S, Ogg GS, *et al.* The role of virus-specific CD8(+) cells in liver damage and viral control during persistent hepatitis B virus infection. *J Exp Med* 2000; 191:1269-80.
16. Galle PR, Hofmann WJ, Walczak H, Schaller H, Otto G, Stremmel W, *et al.* Involvement of the CD95 (APO-1/Fas) receptor and ligand in liver damage. *J Exp Med* 1995;182:1223-1230.
17. Griffiths GM, Mueller C. Expression of perforin and granzymes in vivo: potential diagnostics markers for activated cytotoxic cells. *Immunol Today* 1991;12:415-419.
18. Nair S, Perrillo RP. Serum alanine aminotransferase flares during interferon treatment of chronic hepatitis B: is sustained clearance of HBV DNA dependent on levels of pretreatment viremia? *Hepatology* 2001;34:1021-1026.
19. Perrillo RP, Schiff ER, Davis GL, Bodenheimer HC Jr, Lindsay K, Payne J, *et al.* A randomized, controlled trial of interferon alfa-2b alone and after prednisone withdrawal for the treatment of chronic hepatitis B. The Hepatitis Interventional Therapy Group. *N Engl J Med* 1990;323:295-301.
20. Peters M. Mechanisms of action of interferons. *Semin Liver Dis* 1989;9:235-239.
21. Chen LK, Mathieu-Mahul D, Bach FH, Dausset J, Bensussan A, Sasportes M. Recombinant interferon alpha can induce rearrangement of T cell antigen receptor alpha genes and maturation to cytotoxicity in T-lymphocytes clones in vitro. *Proc Natl Acad Sci USA* 1986;83:4887-4889.
22. Billiau A. The mode of actions of interferons in viral infections and their possible role in the control of hepatitis B. *J Hepatol* 1986;3:5171-179.

23. Marinos G, Naoumov NV, Williams R. Impact of complete inhibition of viral replication on the cellular immune response in chronic hepatitis B virus infection. *Hepatology* 1996;24:991-995.
24. Boni C, Penna A, Ogg GS, Bertoletti A, Pilli M, Cavallo C, *et al.* Lamivudine treatment can overcome cytotoxic T-cell hyporesponsiveness in chronic hepatitis B: new perspectives for immune therapy. *Hepatology* 2001;33:963-971.
25. Yoo JY, Howard R, Waggoner JG, Hoofnagle JH. Peroxidase-antiperoxidase detection of hepatitis B surface and core antigen in liver biopsy specimens from patients with chronic type B hepatitis. *J Med Virol* 1987;23:273-281.
26. Hsu HC, Su IJ, Lai MY, Chen DS, Chang MH, Chuang SM, *et al.* Biologic and prognostic significance of hepatocyte hepatitis B core antigen expression in the natural course of chronic hepatitis B virus infection. *J Hepatol* 1987;5:45-50.
27. Chu CM, Liaw YF. Immunohistological study of intrahepatic expression of hepatitis B core and E antigens in chronic type B hepatitis. *J Clin Pathol* 1992;45:791-795.
28. Rehermann B, Ferrari C, Pasquinelli C, Chisari FV. The hepatitis B virus persists for decades after patient's recovery from acute viral hepatitis despite active maintenance of a cytotoxic T-lymphocyte response. *Nat Med* 1996; 2:1104-1108

# Chapter 4

## **The intrahepatic immune response during chronic hepatitis B infection can be monitored by the Fine-Needle Aspiration Biopsy technique**

T.J. Tang, H.L.A. Janssen, J.G. Kusters, R.A. de Man, S.W. Schalm, J. Kwekkeboom

Department of Gastroenterology and Hepatology  
Erasmus MC, University Medical Center Rotterdam, The Netherlands

FEMS Immunol Med Microbiol 2003;39:69-72



**ABSTRACT**

Frequent analysis of the intrahepatic cellular immune response during chronic hepatitis B infection is not feasible with the liver tissue biopsy technique, due to its risk profile and patient discomfort. We investigated whether the relatively safe and patient-friendly cytological Fine-Needle Aspiration Biopsy technique (FNAB) is suited for this purpose. FNABs taken during hepatitis flares in three chronic hepatitis B patients treated with IFN- $\alpha$ , showed significant increments of CD8<sup>+</sup>-lymphocytes compared with the FNABs taken before and after the flares. No increments were observed in peripheral blood. The increments of intrahepatic CD8<sup>+</sup>-lymphocytes detected by the FNAB were related to anti-viral immune reactivity, since they coincided with significant serum HBV-DNA level reductions and in two of three patients with HBeAg seroconversion. In conclusion, the FNAB-technique is suited to investigate the intrahepatic immune response during chronic hepatitis B infection on a frequent basis.



## INTRODUCTION

Hepatitis B virus (HBV) is a non-cytopathic DNA virus that causes chronic hepatitis in 10% of infected adults. Chronic hepatitis may ultimately lead to liver cirrhosis or hepatocellular carcinoma. Successful treatment regimens for chronic hepatitis B virus (HBV) infection consist of immune-modulation with interferon- $\alpha$  or direct inhibition of viral replication with nucleoside analogues. However, only part of the patients respond to these treatments with sustained control of the virus. It is at present unknown why some patients respond and others do not. During acute hepatitis the virus is thought to be eliminated by an HBV-specific cytotoxic T-lymphocyte (CTL) response, which is detectable in peripheral blood [1, 2]. However, during chronic infection, few anti-viral CTLs can be detected in the circulation [3], since they are compartmentalized to the liver [4]. It has been hypothesized that differences in the intrahepatic immune response are responsible for differences in outcome of antiviral therapy [5].

Several investigators have correlated intrahepatic CD8 T-lymphocytes to liver inflammation in tissue biopsies obtained during acute and chronic hepatitis B infections [6-8]. However, studies with longitudinal analysis of the cellular immune response in the liver during de novo infection or treatment of chronic hepatitis B infection have not been performed yet, due to the invasiveness and related patient discomfort of the liver tissue biopsy.

Since the early eighties, the cytological Fine-Needle Aspiration Biopsy (FNAB) has been used for monitoring rejection activity after liver transplantation [9]. Here, we investigated whether the FNAB technique is suited for monitoring the intrahepatic immune response during acute exacerbations of hepatitis during antiviral therapy for chronic HBV-infection.

## MATERIAL AND METHODS

### Patients

FNABs from three chronic HBeAg<sup>+</sup> HBV-infected patients, who had acute hepatitis exacerbations (defined as an increase of serum alanine transaminase (ALT) to above 10 times upper limit of normal) during a 12-month therapy with pegylated-interferon (100  $\mu$ g s.c. per week) were investigated in this study. Patient 1 was a female and 33 years of age, patient 2 a male and 29 years of age, patient 3 a male and 42 years of age. All three were included in a clinical study in which FNABs and peripheral blood specimens were obtained at the start of therapy and at weeks 2, 8 and 52 (end of therapy) to study the intrahepatic immune response. In addition, FNABs were performed during hepatitis flares. The study was approved by the local Medical Ethical Committee, and all subjects gave written informed consent.



## FNAB-procedure

The FNABs were performed using a 25 Gauge needle (diameter 0.5 mm) and therefore much better tolerated than core biopsies (14 Gauge, 2.0 mm). The needle was inserted in the eighth or ninth right intercostal space without any anaesthesia. A syringe with culture medium was attached to the biopsy needle and a specimen was obtained from the liver through aspiration caused by negative pressure in the syringe by making a short to-and-fro movement. In addition, heparinized peripheral blood was obtained by venapuncture. In total, two FNABs and one sample of peripheral blood were collected per visit. FNAB and blood cells were centrifuged on to glass slides using a cytocentrifuge. One cytopspin preparation of each specimen was stained according to the May-Grünwald-Giemsa procedure. The FNABs were considered to be representative if the aspirate contained at least seven hepatocytes per 100 leucocytes [10, 11]. If both FNABs were representative, the specimen with the highest hepatocyte/leukocyte ratio was used in the study.

## Immunocytochemistry

Cytopspin specimens of FNAB and peripheral blood were immunocytochemically stained with mouse antibodies specific for CD4<sup>+</sup> T-lymphocytes (clone SK3, B&D, San Jose, CA), CD8<sup>+</sup> T-lymphocytes (clone MEM-31, Monosan, Uden, the Netherlands), B-lymphocytes (CD19, clone HD-37, DAKO, Glostrup, Denmark), NK/NKT cell (CD56, clone N901 from Beckman Coulter, Hialeah, FL) and plasmacytoid dendritic cells (CD123, clone 9F5, from BD-Pharmingen, San Jose CA), as described in [12]. Briefly, the slides of FNAB and blood specimens were fixed in 4% paraformaldehyde in phosphate-buffered saline pH 7.3. Unspecific antibody binding was reduced by preincubation with TBS (Tris-buffered saline; pH 7.3) supplemented with 10% normal goat serum and 10% normal human plasma. Sections were incubated with primary antibodies or with isotype-matched control antibodies overnight at 4°C, and afterwards washed with TBS supplemented with 0.1% Tween-20. Detection of positive cells was performed with goat anti-mouse immunoglobulins (GAM, DAKO) for one hour followed by alkaline-phosphatase-anti-alkaline phosphatase complex (APAAP, Serotec, Oxford, UK). Visualization was performed by incubation in Fast Blue salt / naphtol AS-BI phosphate solution supplemented with levamisole (all from Sigma-Aldrich Chemie, Steinheim, Germany). The slides were counterstained with Nuclear Fast Red (Fluka Chemie, Buchs, Switzerland). Numbers of positive cells in immunocytochemical stains were quantified per 1000 leucocytes.

## Virological assessment

Quantitative determination of HBV-DNA was performed by a TaqMan assay, which allowed the accurate determination down to 373 geq/ml in serum. The assay was calibrated using EUROHEP standards [13].

## RESULTS AND DISCUSSION

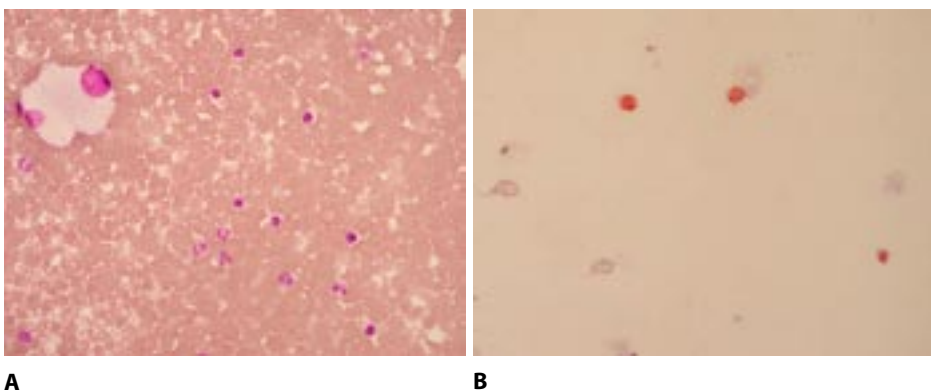
Numbers of CD8<sup>+</sup> T-lymphocytes are elevated in FNAB but not in peripheral blood during hepatitis exacerbations

The hepatitis flares during therapy in the three selected patients occurred at 17, 28 or 48 weeks after start of therapy. In addition, patient 1 experienced a post-treatment flare at week 73. As is shown in Figure 1A, the FNABs obtained during the hepatitis flares contained many lymphocytes. Figure 1B shows an immunocytochemical CD8-stain of a FNAB cytospin.

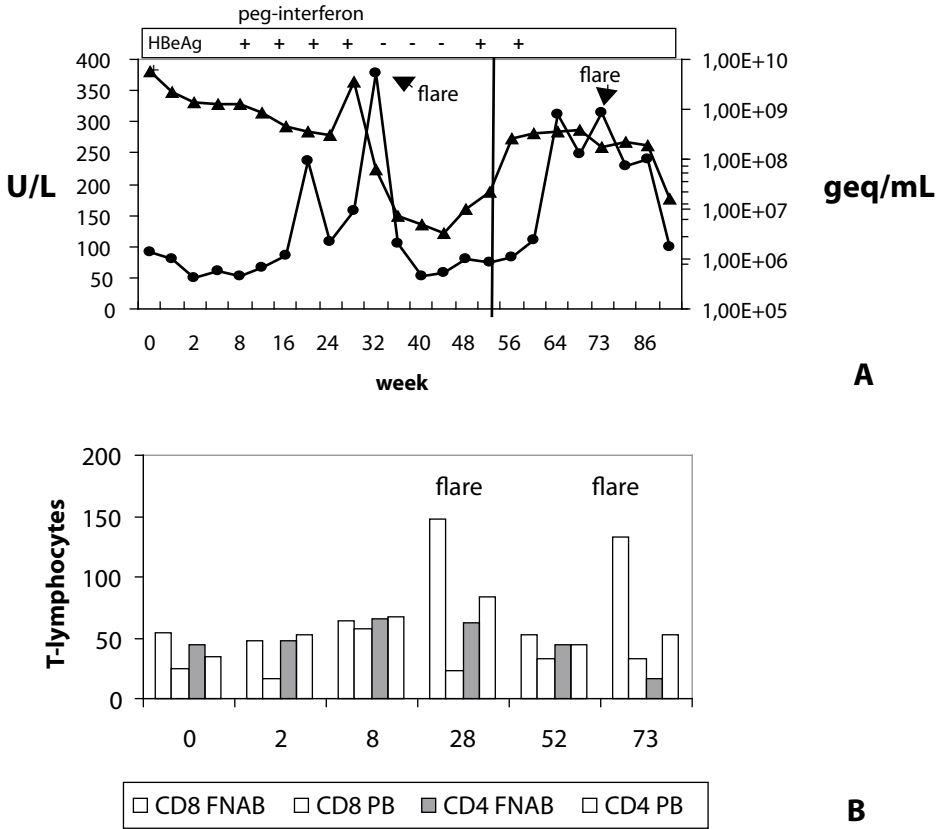
Quantification of immunocytochemically stained leukocytes in FNAB- and peripheral blood cytospin preparations obtained during and after therapy from patient 1 showed that during hepatitis flares the relative numbers of CD8<sup>+</sup> T-lymphocytes increased in the FNABs, but not in peripheral blood specimens (Figure 2). A comparable increase of CD8<sup>+</sup> T-lymphocytes was observed during the hepatitis flares in the two other patients (Figure 3). In addition to the increase in CD8<sup>+</sup> T-lymphocytes, an elevated number of CD4<sup>+</sup> T-cells was observed in the FNAB taken during the hepatitis flare in patient 3 (Figure 3B). Such a clear CD4<sup>+</sup> T-cell increase was not found in the other two patients. No increments of CD19<sup>+</sup>, CD56<sup>+</sup> or CD123<sup>+</sup> cells were observed during the hepatitis flares in any of the patients (data not shown).

The intrahepatic cellular immune response detected by the FNAB-technique reflects anti-viral immune reactivity.

The increments of CD8<sup>+</sup> T-lymphocytes in FNABs during the hepatitis flares coincided in all three patients with a reduction in HBV-DNA level of at least 2 logs (Figure 2 and 3A). As is shown in Figure 2, the CD8<sup>+</sup> T-lymphocyte increment in the FNAB during the first flare in patient 1 was followed by HBeAg seroconversion. Unfortunately, HBeAg reactivation was observed after



**Figure 1.** A: May-Grünwald-Giemsa-stained cytospin preparation of a FNAB obtained during a hepatitis flare containing many lymphocytes. The large cells are hepatocytes. B: Immunocytochemical CD8-stain (red) of a FNAB cytospin preparation obtained during a hepatitis flare.

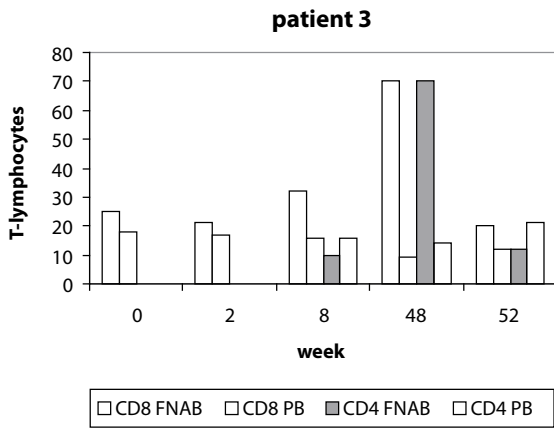
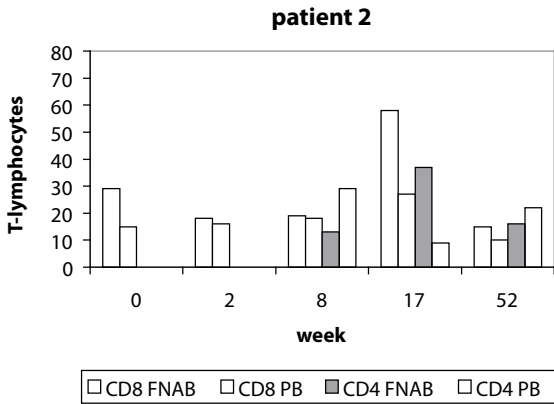
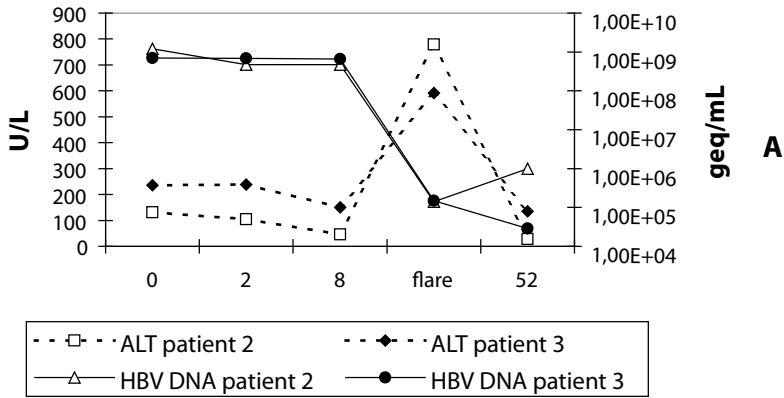


**Figure 2.** Course of ALT (U/L), HBV-DNA (genome equivalents/mL), and HBeAg positivity (panel A), and of the number of CD8+ and CD4+ T-lymphocytes in FNAB and peripheral blood per 1000 leucocytes (panel B) in patient 1 during and after IFN- $\alpha$  therapy.

cessation of therapy. In patient 2 the hepatitis flare was not followed by HBeAg seroconversion, while in patient 3 it was followed by sustained seroconversion. Interestingly, this was the only patient which showed, in addition to an increase of CD8<sup>+</sup> T-cells, also an increment of CD4<sup>+</sup> T-helper cells in the FNAB during the flare. Apparently, elevations of intrahepatic lymphocytes detected by the FNAB-technique reflected anti-viral immune reactivity.

Until now about 450 FNABs have been performed in our center in liver transplant recipients and in patients with chronic liver diseases and no complications were observed. The reported patient discomfort was comparable to a venepuncture. Other investigators have reported similar results in liver transplant recipients [10].

In conclusion, our results show that the FNAB-technique allows investigation of the intrahepatic cellular immune activity during antiviral therapy of chronic hepatitis B infection at a regular basis.



**Figure 3.** A: Course of ALT (IU/L) and HBV-DNA (genome equivalents/mL) of patient 2 and 3 during IFN- $\alpha$  therapy. B: Numbers of CD8+ and CD4+ T-cells per 1000 leukocytes in FNAB and peripheral blood samples obtained during IFN- $\alpha$  therapy of patients 2 and 3 (CD4 data were not obtained at weeks 0 and 2 in these patients).

## REFERENCES

1. Rehermann B, Fowler P, Sidney J, Person J, Redeker A, Brown M, *et al.* The cytotoxic T lymphocyte response to multiple hepatitis B virus polymerase epitopes during and after acute viral hepatitis. *J Exp Med* 1995;181:1047-1058
2. Maini MK, Boni C, Ogg GS, King AS, Reignat S, Lee CK, *et al.* Direct ex vivo analysis of hepatitis B virus-specific CD8(+) T cells associated with the control of infection. *Gastroenterology* 1999;117:1386-1396
3. Bertolotti A, Costanzo A, Chisari FV, Levrero M, Artini M, Sette A, *et al.* Cytotoxic T lymphocyte response to a wild type hepatitis B virus epitope in patients chronically infected by variant viruses carrying substitutions within the epitope. *J Exp Med* 1994;180:933-943
4. Maini MK, Boni C, Lee CK, Larrubia JR, Reignat S, Ogg GS, *et al.* The role of virus-specific CD8(+) cells in liver damage and viral control during persistent hepatitis B virus infection. *J Exp Med* 2000;191:1269-1280
5. Rehermann B. Intrahepatic T cells in hepatitis B: viral control versus liver cell injury. *J Exp Med* 2000;191:1263-1268
6. Colucci G, Colombo M, Del Ninno E, Paronetto F. In situ characterization by monoclonal antibodies of the mononuclear cell infiltrate in chronic active hepatitis. *Gastroenterology* 1983;85:1138-1145
7. Pape GR, Rieber EP, Eisenburg J, Hoffmann R, Balch CM, Paumgartner G, *et al.* Involvement of the cytotoxic/suppressor T-cell subset in liver tissue injury of patients with acute and chronic liver diseases. *Gastroenterology* 1983;85:657-662
8. Montano L, Aranguibel F, Boffill M, Goodall AH, Janossy G, Thomas HC. An analysis of the composition of the inflammatory infiltrate in autoimmune and hepatitis B virus-induced chronic liver disease. *Hepatology* 1983;3:292-296.
9. Lautenschlager I, Hockerstedt K, Ahonen J, Eklund B, Isoniemi H, Korsback C, *et al.* Fine-needle aspiration biopsy in the monitoring of liver allografts. II. Applications to human liver allografts. *Transplantation* 1988;46:47-53
10. Lautenschlager I, Hockerstedt K, Hayry P. Fine-needle aspiration biopsy in the monitoring of liver allografts. *Transpl Int* 1991;4, 54-61
11. Kwekkeboom J, Zondervan PE, Kuijpers MA, Tilanus HW, Metselaar HJ. Fine-needle aspiration cytology in the diagnosis of acute rejection after liver transplantation. *Br J Surg* 2003;90:246-247
12. Kuijf ML, Kwekkeboom J, Kuijpers MA, Willems M, Zondervan PE, Niesters HG, *et al.* Granzyme expression in fine-needle aspirates from liver allografts is increased during acute rejection. *Liver Transpl* 2002; 8:952-956
13. Pas SD, Fries E, De Man RA, Osterhaus AD, Niesters HG. Development of a quantitative real-time detection assay for hepatitis B virus DNA and comparison with two commercial assays. *J Clin Microbiol* 2000;38:2897-2901

# Chapter 5

## **Intrahepatic CD8+ T-lymphocyte response is important for therapy-induced viral clearance in chronic hepatitis B infection**

T.J. Tang, J. Kwekkeboom, S. Mancham, R.S. Binda, R.A. de Man, S.W. Schalm, J.G. Kusters, H.L.A. Janssen

Department of Gastroenterology and Hepatology  
Erasmus MC, University Medical Center Rotterdam, The Netherlands

Submitted for publication



## ABSTRACT

**Background/Aim:** To determine whether NK-cells and CD8+ T-lymphocytes contribute to HBV clearance during antiviral therapy, we performed a longitudinal analysis of intrahepatic immune cells during interferon- $\alpha$  therapy of chronic HBV patients using the FNAB technique.

**Methods:** Twenty chronic HBeAg+ patients were treated with pegylated  $\alpha$ -interferon combined with lamivudine or placebo for 52 weeks. FNAB and blood specimens were obtained at week 0, 2, 8 and 52. CD56+ cells, CD8+ T-lymphocytes, interferon gamma (IFN $\gamma$ ) and granzyme B (GrB) were immunocytochemically quantified.

**Results:** The relative numbers of CD56+ cells and CD8+ T-lymphocytes were significantly higher in FNAB compared to blood at all time-points. About 55% of CD8+ T-lymphocytes in FNAB expressed GrB and about 9% IFN $\gamma$ . Responders (n=9) exhibited a significant increase in intrahepatic CD8+, CD8+GrB+, and CD8+IFN $\gamma$ + T-lymphocytes and a decrease in intrahepatic CD56+ cells during the first weeks of therapy. In non-responders (n=11) no changes in CD8+ T-lymphocytes and an increase in intrahepatic CD56+ cells were observed during therapy.

**Conclusion:** The intrahepatic CD8+ T-lymphocyte, but not the NK/NKT-cell response, is important for HBV clearance during interferon- $\alpha$  therapy, and the antiviral effect may be mediated by both cytolytic and non-cytolytic mechanisms.



## INTRODUCTION

Hepatitis B virus (HBV) infection is a common disease in humans. It is estimated that more than a third of the world's population has been infected and that about 350 million persons are persistent carriers of HBV [1]. Chronic hepatitis B may progress to cirrhosis, liver failure and hepatocellular carcinoma [2]. The pathogenetic mechanisms responsible for acute and chronic hepatitis B have only partly been clarified. Several studies have shown that the CD4+ and CD8+ T-lymphocyte responses to HBV antigens in peripheral blood are strong and multispecific in patients with acute hepatitis B [3-4], whereas these responses are weak or even absent in chronically infected patients [5-6]. Animal studies demonstrated that CD8+ T-lymphocytes are the main effector cells responsible for viral clearance during acute infection [7]. Experiments with HBV transgenic mice have shown that, in addition to causing viral hepatitis, HBV-specific CD8+ T-lymphocytes can inhibit viral replication by a non-cytolytic mechanism, mediated primarily by IFN $\gamma$  synthesis [8]. Acute HBV infections in chimpanzees [9] and humans [4] revealed that non-cytolytic inhibition of viral replication also contributes to viral clearance during natural infections.

Antiviral therapy with interferon- $\alpha$  (IFN $\alpha$ ) can induce sustained response rates in between 25 to 40 percent of chronic hepatitis B patients [10-13]. However, it remains unknown why only a part of the chronic HBV patients respond to IFN $\alpha$  therapy. No difference between responders and non-responders to IFN $\alpha$  therapy was observed in the HBV specific CD4+ T-lymphocyte response in the circulation [14]. During lamivudine therapy, frequencies of HBV-specific CD4+ and CD8+ T-lymphocytes rise transiently both in responders and non-responders to therapy [15].

The frequencies of HBV specific CD8+ T-lymphocytes in the circulation of chronically infected patients are very low. However, much higher numbers have been found in liver biopsies of patients with persistent infection, especially in patients with low viral load [16]. This suggests that intrahepatic CD8+ T-lymphocytes may contribute to control of HBV-replication in chronically infected patients. Frequent monitoring of the intrahepatic immune response in chronic HBV patients during antiviral therapy may clarify the intrahepatic cellular mechanisms involved in therapy-induced clearance. The core-needle biopsy is not suited for this purpose due to its risk of complications and pain. In contrast, the cytological fine-needle aspiration biopsy (FNAB) procedure represents a safe and atraumatic alternative. This technique was originally developed for the diagnosis of acute rejection after kidney- and liver transplantation [17-19]. Recently, we found that this technique is suited for the detection of intrahepatic cellular immune responses in patients with chronic viral hepatitis [20, 21].

The aim of the present study was to establish which type of intrahepatic cellular immune response contributes to the clearance of HBV during therapy with pegylated IFN $\alpha$  therapy in chronically infected patients. For this purpose we performed multiple FNABs during the course of therapy, and assessed whether alterations in intrahepatic CD56+ NK and NKT-cells, and in

CD8+ T-lymphocytes containing the cytotoxic protease granzyme B or the antiviral cytokine IFN $\gamma$ , were related to viral clearance.

## PATIENTS AND METHODS

### Patients

Twenty HBeAg-positive chronic hepatitis B patients (fourteen men and six females) were included in this study. The study was a site-specific ancillary study of a global randomized controlled trial [22]. Only patients from our liver unit in Rotterdam were enrolled. The Medical Ethical Committee of the Erasmus MC approved the study and written informed consent was obtained from each patient who entered the study.

Patients with a co-infection of hepatitis C, hepatitis D and patients with a pre-core mutant in the HBV genome were excluded. The patients were randomized to receive either pegylated  $\alpha$ -interferon 2b (Peg-IFN $\alpha$ ; 100 mg sc per week) and lamivudine (100mg po per day) or Peg-IFN $\alpha$  and placebo, for a period of 52 weeks. After 32 weeks the dose of Peg-IFN $\alpha$  was reduced to 50 mg per week. The criteria for treatment response in this study were HBeAg seroconversion (loss of serum HBeAg) and serum HBV DNA below 1.0 E5 genome equivalents per mL at the end of therapy. All other patients were defined as non-responders.

### Fine needle aspiration biopsy procedure

In order to study the intrahepatic immune response we performed FNAB at the start of therapy and at weeks 2, 8 and 52 (end of therapy). Week 2 and 8 were chosen because IFN-induced immune reactivity, as indicated by flares, occurs most frequently during the first 12 weeks of therapy [23, 24]. In addition, FNABs were performed during all ALT-flares (ALT above 10 times upper limit of normal). The FNABs were performed using a 25 Gauge needle (diameter 0.5 mm), as described in reference 21. In addition to the FNAB, peripheral blood (PB) was obtained by a venepuncture. Cytospin slides were made from the FNAB and blood specimens. One cytopsin slide of each FNAB-specimen was stained according to the May-Grünwald-Giemsa procedure, and used to examine its content of hepatocytes. The FNABs were considered to be representative if the aspirate contained at least 7 hepatocytes per 100 inflammatory leucocytes according to a May-Grünwald- Giemsa stain [19, 25]. The other slides were stored at  $-20^{\circ}\text{C}$  for immunocytochemistry.

### Virological assessments

HBsAg, HBeAg, anti-HBe, anti-HCV and anti-HDV were quantitatively determined by IMX (Abbot Laboratories, North Chicago, IL). For the quantitative determination of HBV-DNA an in-house TaqMan assay was used. This assay allowed an accurate determination down to 373 geq/ml. The assay was calibrated using EUROHEP standards [26, 27]. Analysis of pre-core mutants

was performed by an ABI PRISM 3100 genetic analyzer with a Big Dye Terminator v3.0 Cycle Sequencing kit (both from Applied Biosystems, Nieuwerkerk a/d IJssel, The Netherlands).

### Immunocytochemistry

Cytospin specimens of FNAB and peripheral blood were immunocytochemically double-stained with CD8 MoAb (CD8-FITC, clone DK25, DAKO, Glostrup, Denmark) and anti-granzyme B (GrB) MoAb (clone B7, kindly provided by professor C.E. Hack, CLB, Amsterdam, the Netherlands), or anti-IFN $\gamma$  MoAb (clone MD-2, U-Cytech, Utrecht, the Netherlands). Additionally, cytospins were single-stained for CD8+ T-lymphocytes (CD8, clone MEM-31, Monosan, Uden, The Netherlands), or NK/NKT cells (CD56, clone N901, Beckman Coulter, Hialeah, FL). Cytospin slides were fixed in 4% paraformaldehyde in phosphate-buffered saline (pH 7.3). For detection of intracellular IFN $\gamma$ , the cells were permeabilized with 0.1% saponine (Merck, Darmstadt, Germany) in Tris-buffered saline pH 7.4 (TBS) for 15' at room temperature, and saponine was added in all further incubation steps. Endogenous peroxidase activity was reduced by incubating the slides with citric acid phosphate (pH 5.8) supplemented with 0.05% hydrogen peroxide (Fluka Chemie, Buchs, Switzerland) and 0.1% sodium azide, and non-specific antibody binding was reduced by preincubation with TBS supplemented with 10% normal rabbit serum and 10% normal human plasma. Subsequently, sections were incubated with anti-GrB or anti-IFN $\gamma$  MoAb overnight. For detection of IFN $\gamma$ , endogenous biotin was blocked using the biotin-blocking system from DAKO, after which the slides were incubated with biotinylated rabbit anti-mouse immunoglobulins (RAM-bio, DAKO) followed by alkaline phosphatase (AP)-conjugated streptavidine (DAKO). GrB was detected with rabbit anti-mouse immunoglobulins (DAKO) and AP-anti-AP complex (APAAP, Serotec, Oxford, UK) [28]. Thereafter, the slides were consecutively incubated with 10% mouse serum (DAKO), with FITC-conjugated CD8 MoAb, and with peroxidase (PO)-conjugated rabbit anti-FITC immunoglobulins (DAKO). Binding of CD8 or CD56 MoAb in single-stains was detected with rabbit anti-mouse immunoglobulins and APAAP. Visualization of AP was performed by incubation in Fast Blue salt / naphthol AS-BI phosphate solution supplemented with levamisole (all from Sigma-Aldrich Chemie, Steinheim, Germany), giving a blue precipitate. Revelation of PO was performed with 3-amino-9-ethylcarbazole (AEC) giving a red precipitate. The optimal dilution of the anti-IFN $\gamma$  MoAb was established by titration on cytospins slides of peripheral blood mononuclear cells either or not activated by PMA and ionomycin in the presence of Brefeldin. The concentration giving maximal staining of stimulated cells and no staining of non-stimulated cells was used.

### Quantification and statistical analysis

The cytospin slides of FNAB and PB specimens were examined microscopically at a magnification of 400x, and single CD8+ T-lymphocytes, CD8+GrB+, CD8+IFN $\gamma$ +, and CD56+ cells were quantified. The total number of leucocytes was assessed by counting the leucocytes in 6 microscopic fields of 400 $\times$  magnification, and multiplying the mean number per high-

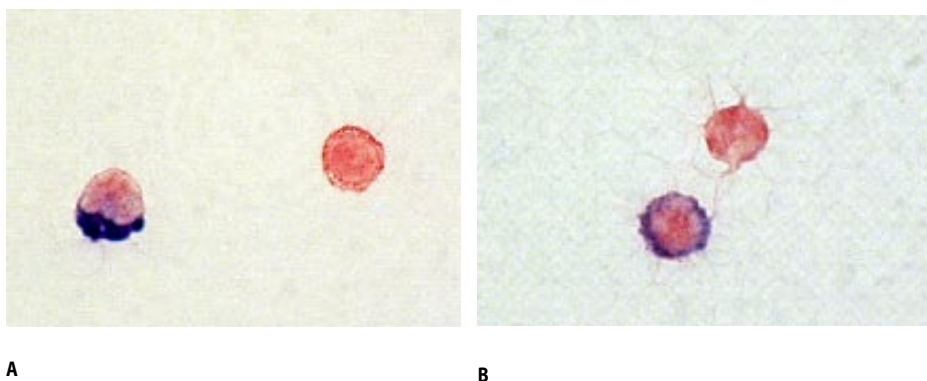
**Table 1.** Baseline characteristics of study patients

Characteristic (n=20)	n (%)
Age (years) *	33 (19-57)
Male	14 (70)
Ethnicity	
White	11 (55)
Asian	8 (40)
Other	1 (5)
Route of transmission	7 (35)
Perinatal	5 (25)
Sexual	1 (5)
Parenteral	7 (35)
Unknown	
HBV DNA (geq/mL) *	1.5 E9 (1.6 E8- 9.1 E9)
ALT (IU/L) *	132 (47-394)
Cirrhosis	3 (15)
Previous IFN $\alpha$ treatment	2 (10)

HBV: hepatitis B virus; ALT: alanine aminotransferase; IFN: interferon

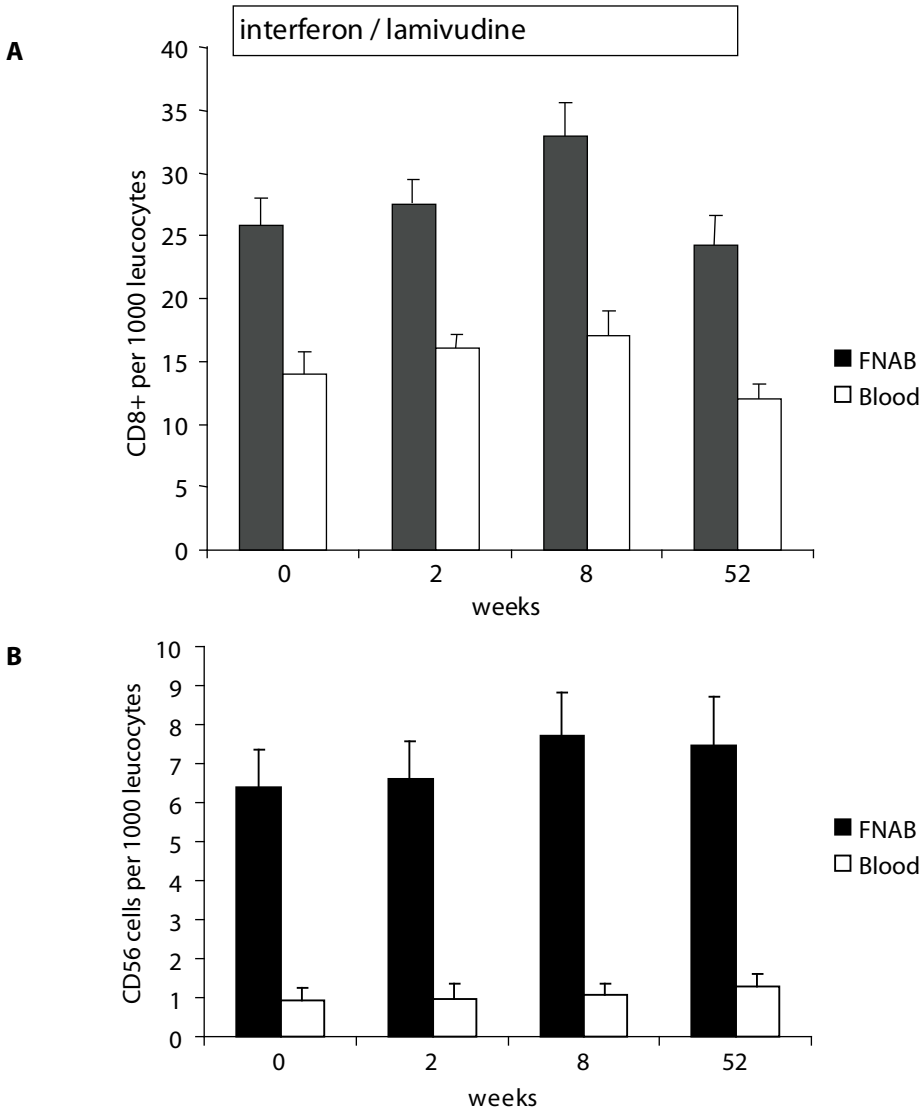
\*Median (range)

power fields with 104 (i.e. the total number of high-power fields in one cytopsin). Countings were performed by one single investigator (T.J.T), who was blinded for response and treatment regimen of the patients. For analysis, CD8+, CD8+GrB+, CD8+IFN $\gamma$ +, and CD56+ cells were expressed per 1000 leucocytes. Mean numbers of CD8+ T-lymphocytes were calculated from the numbers obtained in three different slides stained for CD8 (i.e. the double-stains of CD8+GrB+, CD8+IFN $\gamma$ + and the single-stain for CD8). When the intervariability exceeded 20% of the mean margin, recounts were done. Data of groups of patients are expressed as mean  $\pm$  SEM, unless otherwise indicated. Differences between responders and nonresponders, and differences between types of therapy were analyzed by the Mann-Whitney U test. Differences

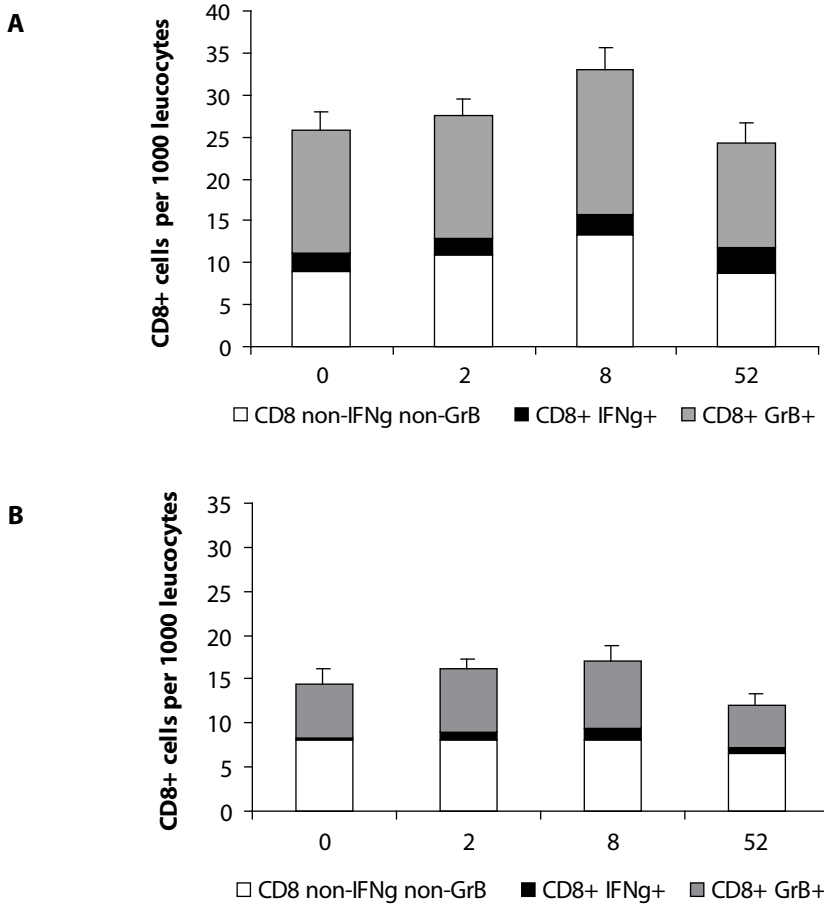


**Figure 1.** Immunocytochemical double-stains of CD8 and GrB (A) ( $\times 1000$ ) and of CD8 and IFN $\gamma$  (B) ( $\times 600$ ) on FNAB cytopspins. Single CD8+ T-lymphocytes are red/orange, and double stained CD8+ T-lymphocytes have an additional blue stain in the cytoplasm.

between paired samples were investigated by the Wilcoxon signed-rank test. A p-value of < 0.05 was considered statistically significant.



**Figure 2.** The numbers of CD8+ T-lymphocytes (A) and CD56+ cells (B) per 1000 leucocytes in FNAB versus peripheral blood. The relative numbers of CD8+ T-lymphocytes and CD56+ cells in FNAB were elevated compared to blood at each timepoint.

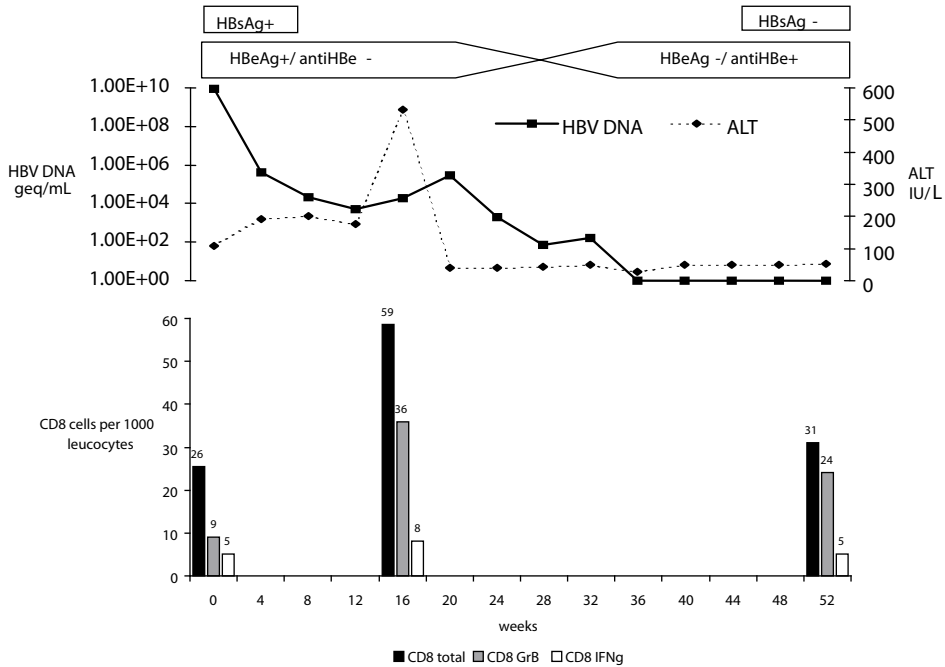


**Figure 3.** Granzyme B and IFNg-expression in CD8+ T-lymphocytes in FNAB (A) and in peripheral blood (B). Depicted are the proportions of CD8+ T-lymphocytes expressing GrB or IFNg.

## RESULTS

### Patient characteristics

Patient characteristics at baseline are shown in table 1. Eleven patients (55%) were randomized to Peg-IFN $\alpha$  plus lamivudine and 9 patients (45%) to Peg-IFN $\alpha$  plus placebo. All included patients completed the entire period of therapy. From all scheduled time-points FNABs were obtained successfully. A total of 5 flares were detected. In four of these 5 flares patients consented to undergo a FNAB. No complications or pain were observed during or after FNAB.



**Figure 4.** Relative numbers of CD8+, CD8+GrB+ and CD8+IFN $\gamma$ + T-cells in FNAB during a hepatitis flare in the patient with HBsAg seroconversion.

### CD8+ T-lymphocytes and NK/NKT-cells during therapy

Figure 1 shows immunocytochemical stains of FNAB cytospin slides for CD8 (red) and GrB (blue) (A), and for CD8 (red) and IFN $\gamma$  (blue) (B).

The proportions of CD8+ T-lymphocytes within the leucocytes were significantly elevated in the FNAB compared with PB at all time points ( $28 \pm 1.8$  vs.  $16 \pm 1.5$ ,  $p=0.02$ ) (figure 2A). Compared to baseline, a small increase in the relative numbers of CD8+ T-lymphocytes was observed in FNAB, but not in PB, at week 8 of therapy; however this difference just failed to reach statistical significance (week 0 vs. week 8: FNAB  $25.8 \pm 2.2$  vs.  $32.9 \pm 2.7$ ,  $p=0.08$ ). As is shown in figure 3, both in FNAB and PB large proportions of CD8+ T-lymphocytes expressed GrB; these proportions tended to be higher in FNAB (median 55%, range 46% to 61%) than in PB (median 44%, range 38% to 47%, FNAB vs. PB;  $p=0.11$ ). Much smaller proportions of CD8+ T-lymphocytes expressed IFN $\gamma$ ; also this proportion tended to be higher in FNAB (median 9%, range 7% to 12%) than in PB (median 5%, range 3% to 7%, FNAB vs. PB;  $p=0.14$ ).

Both in FNAB and in PB the proportions of CD8+ T-lymphocytes expressing GrB or IFN $\gamma$  showed no statistical difference between different time-points of therapy. Similar to CD8+ T-lymphocytes, the relative numbers of CD56+ NK/NKT-cells were significantly higher in FNAB than in blood at all time point ( $7.0 \pm 0.3$  vs.  $1.2 \pm 0.2$ ,  $p=0.03$ ) (figure 2B). No differences were observed between the two therapy regimens regarding relative numbers of CD8+, CD8+GrB+,

**Table 2.** Baseline characteristics of responders versus nonresponders

Characteristic	responders (n=9) n (%)	non-responders (n=11) n (%)
Age *	36 (19-45)	31 (21-57)
Male	7 (78)	7 (64)
Asians	4 (44)	4 (36)
HBV DNA (geq/mL) *	2.0 E9 (2.3 E8 - 9.1 E9)	1.2 E9 (1.6 E8 - 5.7 E9)
ALT (IU/L) *	164 (109-236)	86 (47-394)
Cirrhosis	3 (33)	0
Previous IFNα treatment	0	2 (18)

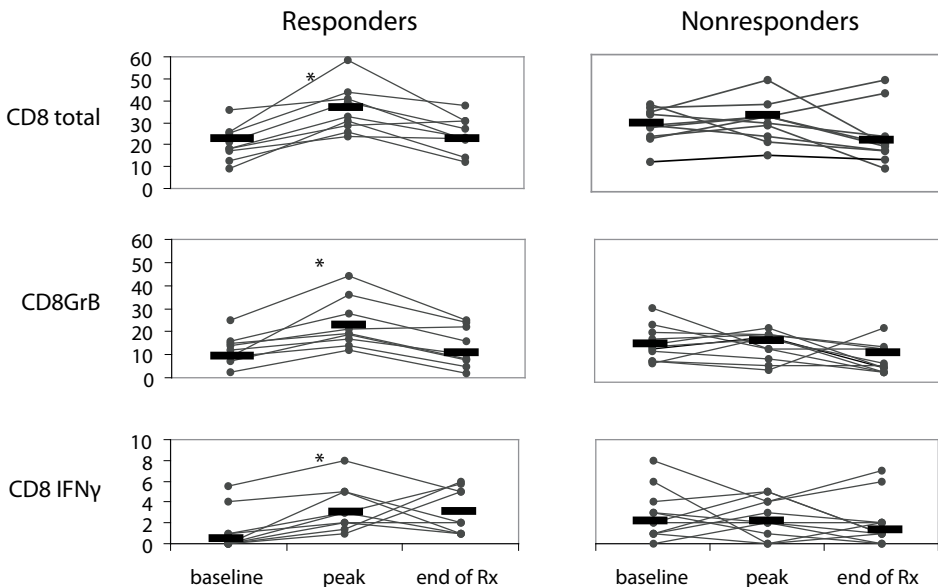
HBV: hepatitis B virus; ALT: alanine aminotransferase; IFN: interferon

\* Median (range)

CD8+IFNγ+ T-lymphocytes, or CD56+ NK/NKT-cells during therapy (data not shown). Therefore the treatment groups were combined for further analysis.

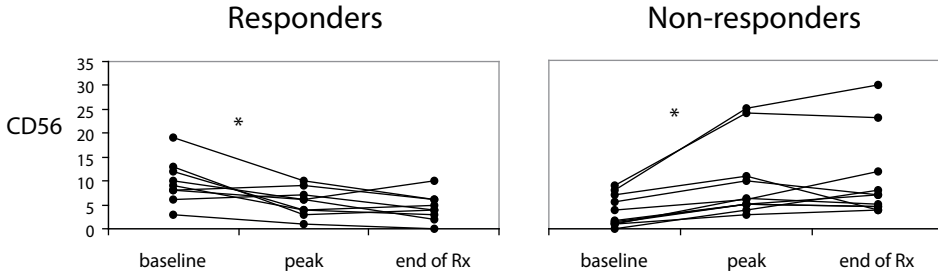
### CD8+ T-lymphocytes in ALT-flares during therapy

In all four patients who exhibited an exacerbation of inflammatory activity (ALT-flare) during therapy the relative numbers of CD8+ T-lymphocytes were elevated during the flare as



**Figure 5.** The course of the relative numbers of total CD8+ T-lymphocytes, CD8+GrB+ T-lymphocytes and CD8+IFNγ+ T-lymphocytes before, during and at the end of therapy in FNAB of responders (right panels) and non-responders (left panels). The values during therapy which are depicted are the peak value observed either at week 2 or week 8 of therapy. Means are depicted with bars. (\* = baseline vs. peak: p < 0.05)





**Figure 6.** Course of CD56+ cells before, during and at the end of therapy in FNAB of responders (right panel) and non-responders (left panel). The values during therapy which are depicted are the values corresponding with the peak values of CD8+T-lymphocytes observed either at week 2 or week 8 of therapy. Means are depicted with bars. (\* : baseline vs. peak:  $p < 0.05$ ).

compared to baseline (baseline vs. flare:  $26.1 \pm 3.8$  vs.  $44.4 \pm 10.2$ ,  $p=0.06$ ). Both the numbers of CD8+GrB+ T-lymphocytes (baseline vs. flare:  $16.5 \pm 7.1$  vs.  $27.8 \pm 6.8$ ,  $p=0.07$ ) and the number of CD8+IFNg+ T-lymphocytes (baseline vs. flare:  $2.0 \pm 1.9$  vs.  $4.6 \pm 2.3$ ,  $p=0.06$ ) showed an increase during the flares. No elevations of CD8+ T-lymphocytes in blood were detected during flares (data not shown). One patient exhibiting a flare became HBsAg-negative and produced anti-HBs. This patient had the most vigorous CD8+ T-lymphocyte response (figure 4).

#### Clinical features in relation to response to therapy

Response to treatment was observed in 9 of the 20 patients (45%). Three of 9 (33%) patients treated with Peg-IFN $\alpha$  plus placebo responded to the therapy and 6 of 11 (55%) treated with combination therapy. One patient treated with combination therapy became negative for HBsAg (5%). Differences in pre-treatment characteristics between responders and non-responders are shown in table 2. The pre-treatment serum ALT was higher in the response group ( $p=0.05$ ). Pre-treatment HBV-DNA did not differ between responders and non-responders.

#### CD8+ T-lymphocytes in relation to response

During treatment responders exhibited a significant increase of total CD8+ T-lymphocytes in FNAB (baseline vs. peak  $20.2 \pm 2.2$  vs.  $36.2 \pm 2.1$ ,  $p=0.008$ ), which was not observed in non-responders (baseline vs. peak  $28.4 \pm 2.2$  vs.  $30.0 \pm 2.6$ ,  $p=0.64$ ) (figure 5). During this increase of CD8+ T-lymphocytes in responders both CD8+GrB+ T-lymphocytes (baseline vs. peak  $12.1 \pm 2.1$  vs.  $23.3 \pm 3.6$ ,  $p=0.008$ ) and of CD8+IFNg+ T-lymphocytes (baseline vs. peak  $1.2 \pm 0.6$  vs.  $3.4 \pm 0.7$ ,  $p=0.07$ ) were significantly elevated. In non-responders no increases of CD8+GrB+ (baseline vs. peak  $15.4 \pm 1.7$  vs.  $16.1 \pm 2.1$ ,  $p=0.93$ ) and or CD8+IFNg+ T-lymphocytes (baseline vs. peak  $2.8 \pm 0.72$  vs.  $2.5 \pm 0.54$ ,  $p=0.96$ ) were observed during therapy.

### NK cell response in relation to response

The pre-treatment numbers of NK/NKT-cells in FNAB were significantly higher in responders compared to non-responders ( $9.7 \pm 1.5$  vs.  $3.6 \pm 0.9$ ,  $p=0.004$ ). During treatment, responders showed a decrease of NK/NKT-cells in FNAB (baseline vs. peak  $9.7 \pm 1.5$  vs.  $5.5 \pm 2.8$ ;  $p=0.02$ ). In contrast, non-responders exhibited an increase of NK/NKT-cells in FNAB (baseline vs. peak  $3.6 \pm 0.9$  vs.  $9.5 \pm 2.3$ ;  $p=0.003$ ) (Figure 6).

## DISCUSSION

This study is the first description of the longitudinal course of the intrahepatic cellular immune response during anti-viral therapy with IFN $\alpha$  of patients with chronic HBV-infection. We demonstrate that the FNAB-technique enables sequential monitoring of the intrahepatic inflammatory response during antiviral therapy. Two results show that the leukocytes in FNAB were indeed derived from the liver: First, by the higher relative numbers of CD8+ T-lymphocytes and CD56+ cells in FNAB-specimens compared to PB, which is in accordance with the high proportions of these cells among liver lymphocytes [29]. Secondly, the elevations of these immune cells in FNAB, but not in PB during hepatitis flares.

Using this technique, we observed that the response to antiviral therapy with a Peg-IFN $\alpha$ -based regimen was associated with significant increases of CD8+, CD8+GrB+, and CD8+IFN $\gamma$ + T-lymphocytes, but not of CD56+ cells, in the liver. These results provide the first in vivo evidence that intrahepatic CD8+ T-lymphocyte reactivity is vital for successful antiviral therapy of chronic hepatitis B patients, and that both cytotoxic activity and secretion of antiviral cytokines are important for therapy-induced viral elimination.

Published studies in patients with chronic HBV treated with IFN $\alpha$  monotherapy [14], lamivudine [15], or with combination therapy IFN $\alpha$  and lamivudine [30] all show that antiviral therapy enhances the frequencies of HBV-specific T-lymphocytes in the circulation. However, in these studies no differences in peripheral T-lymphocyte responses were found between responders and non-responders to therapy. The only immunological differences between responders and non-responders to anti-viral therapy in these studies were higher peaks in serum levels of IL-12 and Th-1 cytokines in responders [30]. In accordance with this study, Cooksley et al recently reported in an abstract a stronger increase in the ratio of IFN- $\gamma$ /IL-10 producing HBV-specific CD4+ T-cells producing in peripheral blood in responders compared to non-responders during therapy with adefovir dipivoxil [31]. Although we did not study IL-12 production and T-helper activity in our study, the increase of intrahepatic CD8+ T-lymphocytes, and especially of IFN $\gamma$ -producing CD8+ T-lymphocytes, during therapy in the responders could be the result of IL-12 promoting T-helper type 1 and CD8+ T-lymphocyte differentiation.

In our study, the total CD8+ T-lymphocyte elevations correlated with increases of the serum ALT flares (data not shown). This may be due to the intrahepatic accumulations of CD8+ T-

lymphocytes containing GrB, which is a major effector molecule in the cytolytic elimination of HBV-infected hepatocytes [32]. In addition to the increase in CD8+ T-lymphocytes expressing GrB, response to treatment was also associated with an elevation of CD8+ T-lymphocytes expressing IFN $\gamma$ . This suggests that not only cytolytic, but also non-cytolytic mechanisms are involved in therapy-induced viral clearance of chronic HBV infection.

Although we did not investigate whether the intrahepatic CD8+ T-lymphocytes were HBV-specific, it is generally acknowledged that a proportion of the CD8+ T-lymphocytes present in the HBV-infected liver are HBV-specific, and that also bystander CD8+ T-lymphocytes contribute to the clearance of HBV [33]. A recent study showed that hepatocellular injury was associated with total numbers of intrahepatic CD8+ T-lymphocytes but not with HBV-specific CD8+ T-lymphocytes [16].

The liver contains many NK and NKT-cells [29]. NK cells are believed to play an important role in the host defense in the earliest course of HBV infection [34], and increased numbers of circulating NK-cells have been observed immediately after HBV-infection [4]. Interestingly, in responders we observed higher relative numbers of CD56+ cells in pre-treatment FNAB as compared to non-responders. Since liver NK/NKT-cells are thought to be able to recruit T-cells to the liver [29], the enhanced numbers in responders may have been responsible for the intrahepatic accumulation of CD8+ T-lymphocytes during therapy. After starting anti-viral therapy the numbers of CD56+ cells increased in non-responders, while they decreased in responders, suggesting that with or without lamivudine IFN $\alpha$  therapy stimulates the NK cell response in non-responders, while in responders the CD8+ T-lymphocyte response inhibits NK cell activation [35].

In conclusion, responders to Peg-IFN $\alpha$ -based antiviral therapy are characterized by a prominent intrahepatic CD8+ T-lymphocyte response. Elevations of both GrB+ and IFN $\gamma$ + CD8+ T-lymphocytes indicate that cytolytic and noncytolytic mechanisms contribute to viral elimination.

## **ACKNOWLEDGEMENTS**

We thank drs. M. van Zonneveld and A.B. van Nunen for logistical assistance and drs. J.T. Brouwer and H.J. Metselaar for practical support.

## REFERENCES

1. Realdi G, Fattovich G, Hadziyannis S, Schalm SW, Almasio P, Sanchez-Tapias J, *et al.* Survival and prognostic factors in 366 patients with compensated cirrhosis type B: a multicenter study. *J Hepatol* 1994;21:656-666
2. Perillo RP. Hepatitis B: transmission and natural history. *Gut* 1993;34:548-49
3. Rehmann B, Fowler P, Sidney J, Person J, Redeker A, Brown M, *et al.* The cytotoxic T lymphocyte response to multiple hepatitis B virus polymerase epitopes during and after acute viral hepatitis. *J Exp Med* 1995;181:1047-1058
4. Webster GJ, Reignat S, Maini MK, Whalley SA, Ogg GS, King A, *et al.* Incubation phase of acute hepatitis B in man: dynamic of cellular immune mechanisms. *Hepatology* 2000;32:1117-1124
5. Bertoletti A, Constanzo A, Chisari FV, Levrero M, Artini M, Sette A, *et al.* Cytotoxic T lymphocyte response to a wild-type hepatitis B virus epitope in patients chronically infected by variants viruses carrying substitutions within the epitope. *J Exp Med* 1994;180:933-943
6. Nayarsina R, Fowler P, Guilhot S, Missale G, Cerny A, Schlicht HJ, *et al.* HLA A2 restricted cytotoxic T-lymphocyte responses to multiple hepatitis B surface antigen epitopes during hepatitis B virus infection. *J Immunol* 1993;150:4659-4671
7. Thimme R, Wieland S, Steiger C, Ghreyab J, Reimann KA, Purcell RH, *et al.* CD8(+) T cells mediate viral clearance and disease pathogenesis during acute hepatitis B virus infection. *J Virol* ;77:68-76
8. Guidotti LG, Ando K, Hobbs MV, Ishikawa T, Runkel RD, Schreiber RD, *et al.* Cytotoxic T lymphocytes inhibits hepatitis B virus gene expression by a noncytolytic mechanism in transgenic mice. *Proc Natl Acad Sci USA* 1994;91:3764-3768
9. Guidotti LG, Rocheford R, Chung L, Shapiro M, Purcell R, Chisari FV. Viral clearance without destruction of infected cells during acute HBV infection. *Science* 1999;284:825-829
10. Krogsgaard K, Bindslev N, Christensen E, Craxi A, Schlichting P, Schalm SW, *et al.* The treatment effect of alpha interferon in chronic hepatitis B is independent of pre-treatment variables. Results based on individual patient data from 10 clinical controlled trials. European Concerted Action on Viral Hepatitis (EUROHEP). *J Hepatol* 1994;21:646-655
11. Wong DK, Cheung AM, O'Rourke K, Naylor C, Detsky A, Heathcote J. Effect of alpha-interferon treatment in patients with hepatitis B e antigen-positive chronic hepatitis B. A meta-analysis. *Ann Intern Med* 1993;119:312-323
12. Nevens F, Main J, Honkoop P, Tyrrell DL, Barber J, Sullivan MT, *et al.* Lamivudine therapy for chronic hepatitis B: a six-month randomized dose-ranging study. *Gastroenterology* 1997;113:1258-1263
13. Dienstag JL, Schiff ER, Wright TL, Perillo RP, Hann HW, Goodman Z, *et al.* Lamivudine as initial treatment for chronic hepatitis B in the United States. *N Engl J Med* 1999;341:1256-1263
14. Rossol S, Marinos G, Carucci P, Singer MV, Williams R, Naoumov NV. Interleukin-12 induction of Th1 cytokines is important for viral clearance in chronic hepatitis B. *J Clin Invest* 1997;99:3025-3033
15. Boni C, Penna A, Bertoletti A, Lamonaca V, Rapti I, Missale G, *et al.* Transient restoration of anti-viral T cell responses induced by lamivudine therapy in chronic hepatitis B. *Hepatology* 2003;39:595-605
16. Maini MK, Boni C, Lee CK, Larrubia JR, Reignat S, Ogg GS, *et al.* The role of virus-specific CD8 (+) cells in liver damage and viral control during persistent hepatitis B virus infection. *J Exp Med* 2000;191:1269-1280
17. Häyry P, Wilebrand E von. Practical guidelines for fine needle aspiration biopsy of human renal allografts. *Ann Clin Res* 1981;13:288-306
18. Lautenschlager I, Höckerstedt K, Ahonen J, Eklund B, Isoniemi H, Korsback C, *et al.* Fine-needle aspiration biopsy in the monitoring of liver allografts. *Transplantation* 1988;46:47-53
19. Kwekkeboom J, Zondervan PE, Kuijpers MA, Tilanus HW, Metselaar HJ. Fine-needle aspiration cytology in the diagnosis of acute rejection after liver transplantation. *Br J Surg* 2003;90:246-247
20. Tang TJ, Vrolijk JM, Kwekkeboom J, Haagmans BL, Herscheid AJ, Kusters JG, *et al.* Monitoring intrahepatic CD8+ T-cells by fine-needle aspiration cytology in chronic hepatitis C infection. *J Viral Hepat* 2004;11:342-348
21. Tang TJ, Janssen HL, Kusters JG, de Man RA, Schalm SW, Kwekkeboom J. The intrahepatic immune response during chronic hepatitis B infection can be monitored by the fine-needle aspiration biopsy technique. *FEMS Immunol Med Microbiol* 2003;39:69-72

22. Janssen HL, Senturk H, Zeuzem S, Akarca U, Cakaloglu Y, Simon K, et al. Peginterferon alfa-2b and lamivudine combination therapy compared with peginterferon alfa-2b for chronic HBeAg-positive hepatitis B: a randomized controlled trial in 307 patients. *Hepatology* 2003;38:1323
23. Nair S, Perrillo RP. Serum alanine aminotransferase flares during interferon treatment of chronic hepatitis B: is sustained clearance of HBV DNA dependent on levels of pretreatment viremia. *Hepatology* 2001;34:1021-1026
24. Janssen HL, Gerken G, Carreno V, Marcellin P, Naoumov NV, Craxi A, et al. Interferon alfa for chronic hepatitis B infection: increased efficacy of prolonged treatment. The European Concerted Action on Viral Hepatitis (EUROHEP). *Hepatology* 1999;30:238-243
25. Lautenschlager I, Hockerstedt K, Häyry P. Fine-needle aspiration biopsy in the monitoring of liver allografts. *Transpl Int* 1991;4:54-61
26. Heermann KH, Gerlich WH, Chudy M, Schaefer S, Thomssen R. Quantitative detection of hepatitis B virus DNA in two intern reference plasma preparation. Eurohep Pathobiology group. *J Clin Microbiol* 1999;37:68-73
27. Pas SD, Fries E, de Man RA, Osterhaus AD, Niesters HG. Development of a quantitative real-time detection assay for hepatitis B virus DNA and comparison with two commercial assays. *J Clin Microbiol* 2000;38:2897-2901
28. Kuijff ML, kwekkeboom J, Kuijpers MA, Willems M, Zondervan PE, Niesters HG, et al. Granzyme expression in fine-needle aspirates from liver allografts is increased during acute rejection. *Liver Transpl.* 2002;8:952-6.
29. Crispe IN. Hepatic T cells and liver tolerance. *Nat Rev Immunol.* 2003;3:51-62
30. Marinos G, Naoumov NV, Williams R. Impact of complete inhibition of viral replication on the cellular immune response in chronic hepatitis B virus infection. *Hepatology* 1996;24:991-995.
31. Cooksley H, Chokshi S, Wedemeyer CH, Andreone P, Gilson R, Warnes T, et al. Hepatitis B virus-specific T-cell reactivity during adefovir dipivoxil (ADV) treatment: a multicenter, controlled study. *J Hepatol* 2002;36:S1 A 16.
32. Tang TJ, Kwekkeboom J, Laman JD, Niesters HG, Zondervan PE, de Man RA, et al. The role of intrahepatic immune effector cells in inflammatory liver injury and viral control during chronic hepatitis B infection. *J Viral Hepat* 2003;10:159-67
33. Guidotti LG, Chisari FV. To kill or to cure: options in host defense against viral infection. *Curr Opin Immunol* 1996;8:478-483
34. Kakimi K, Guidotti LG, Koezuka Y, Chisari FV. Natural killer T cell activation inhibits hepatitis B virus replication in vivo. *J Exp Med.* 2000;192:921-930
35. Biron CA. Activation and function of natural killer cell responses during viral infections. *Curr Opin Immunol* 1997;9:24-34



# Chapter 6

## **Monitoring intrahepatic CD8<sup>+</sup> T-cells by fine-needle aspiration cytology in chronic hepatitis C infection**

T.J. Tang\*, J.M. Vrolijk\*, J. Kwekkeboom, B.L. Haagmans<sup>#</sup>, A.J. Herscheid, J.G. Kusters, H.L.A. Janssen, J.T. Brouwer, S.W. Schalm

\* Both authors contributed equally to the study.

Department of Gastroenterology and Hepatology, <sup>#</sup>Institute of Virology  
Erasmus MC, University Medical Center Rotterdam, The Netherlands





**ABSTRACT**

Infection of the liver with hepatitis C virus causes compartmentalization of CD8<sup>+</sup> cytotoxic T-cells to the site of disease. These cells are thought to be involved in viral clearance during interferon therapy. The repetitive analysis of the intrahepatic immune response is hampered by the difficulty to obtain the intrahepatic T-cells. The fine needle aspiration biopsy (FNAB) technique was evaluated for its use to obtain liver-derived CD8<sup>+</sup> T-cells in a minimally invasive way. In 26 chronic HCV-patients who were evaluated for Peg-interferon and ribavirin combination therapy, pre-treatment FNABs and peripheral blood specimens were obtained simultaneously with liver tissue biopsies, and CD3<sup>+</sup> and CD8<sup>+</sup> T-cells were quantified by immunocytochemistry. The CD8<sup>+</sup>/CD3<sup>+</sup> ratio was significantly higher in the FNABs than in peripheral blood ( $p < 0.01$ ), and similar to those in portal areas in the tissue biopsies. A significant correlation was observed between numbers of CD3<sup>+</sup>CD8<sup>+</sup> T-lymphocytes in the FNABs and the numbers of CD8<sup>+</sup> cells in the lobular fields or in the portal tracts of the liver tissue biopsies, but not with CD3<sup>+</sup>CD8<sup>+</sup> T-lymphocytes in peripheral blood. Finally, the ratio of CD8<sup>+</sup>/CD3<sup>+</sup> T-lymphocytes in FNABs was significantly higher in those patients who responded rapidly to therapy as compared to slow responders at 4 weeks of treatment ( $p = 0.02$ ). These findings demonstrate that the intrahepatic T-cell composition is reflected in FNABs, and that the FNAB-technique can be used for predicting early virological response to therapy of patients chronically infected with HCV.

## INTRODUCTION

In chronic hepatitis C infection, virus-specific T-cells are predominantly found in the liver and are almost absent in peripheral blood [1-2]. Intrahepatic localization of CD8<sup>+</sup> hepatitis C virus (HCV) specific cytotoxic T-cells is thought to be crucial to control acute hepatitis C infection [3] and also augment inhibition of viral replication and clearance of infected hepatocytes when chronic hepatitis C patients are treated with interferon- $\alpha$  and ribavirin [4-6]. Both total as well as virus-specific intrahepatic CD8<sup>+</sup> T-cell numbers in pretreatment liver tissue biopsies as determined by respectively quantitative immunohistochemistry [7] or tested in vitro against target cells [4] are associated with virological response to interferon- $\alpha$  therapy. To study intrahepatic T-cell kinetics during acute or therapy of chronic infection, the cellular immune status in the liver should be monitored on a repetitive basis. The liver tissue biopsy technique is the golden standard for obtaining liver tissue. Unfortunately, the biopsy procedure is accompanied with considerable patient discomfort. Therefore we investigated the feasibility of a less invasive and traumatic fine-needle aspiration biopsy (FNAB) technique as a tool for monitoring the cellular immune status in the liver during chronic HCV-infection. Since the early eighties, the FNAB has been used for monitoring rejection activity after liver transplantation [8-9]. The FNAB is performed with a 25 Gauge needle (diameter 0.5mm) and therefore hardly traumatic. Our aim was to investigate whether intrahepatic T-cells as determined by quantitative immunohistochemistry (CD3<sup>+</sup> and CD8<sup>+</sup> cells) in liver tissue biopsies are reflected in FNABs, and whether intrahepatic T-cells assessed by FNAB could be used to predict response to interferon- $\alpha$  therapy.

## METHODS

### Patients

The study group consisted of patients from a single hospital, who were screened for participation in a multicenter clinical study in which the efficacy of treatment with Peg-interferon- $\alpha$ 2a 180mcg per week (Pegasys, Roche, Basel, Switzerland) in combination with 1000-1200mg ribavirin (Copegus, Roche) was evaluated. A liver biopsy was part of the evaluation. Standard inclusion and exclusion criteria were used. In brief, all patients were interferon-naive, anti-HCV antibody positive and had detectable HCV RNA by PCR and elevated serum alanine aminotransferase levels (>30 U/l) for at least 6 months on at least two occasions. Patients with decompensated liver disease, co-infection with hepatitis B or human immunodeficiency virus, alcohol abuse or any other relevant comorbidity were excluded. Within two months after the liver biopsy, treatment was started when indicated according to the current treatment consensus [10]. The study was in accordance with the Helsinki Declaration of 1975 and approved by the in-house medical-ethical committee. All patients gave written informed consent for participation.

### Fine-needle aspiration and liver tissue biopsies

Pre-treatment two FNABs were obtained. The full details of this procedure are described elsewhere [11-12]. Briefly, a mandarin containing 25-gauge needle (diameter 0.5 mm) is punctured in the 8th or 9th right intercostal space. After removal of the mandarin, liver cells are aspirated by negative pressure into a syringe filled with culture medium. Blood was collected in 4 mL EDTA plasma tubes (Vacutainer Systems, Plymouth, England). FNABs and blood cells were centrifuged on to glass slides using a cytocentrifuge. One cytospin preparation of each specimen was stained according to the May-Grünwald-Giemsa procedure. FNABs were considered to be representative if the aspirate contained at least seven hepatocytes per 100 leukocytes. If both FNABs were representative, the specimen with the highest hepatocyte/leukocyte ratio was used in the study.

Directly after the FNAB procedure, a liver tissue biopsy was obtained percutaneously with a 14 Gauge Tru-cut needle. The liver specimen was fixed in phosphate-buffered formalin and embedded in paraffin.

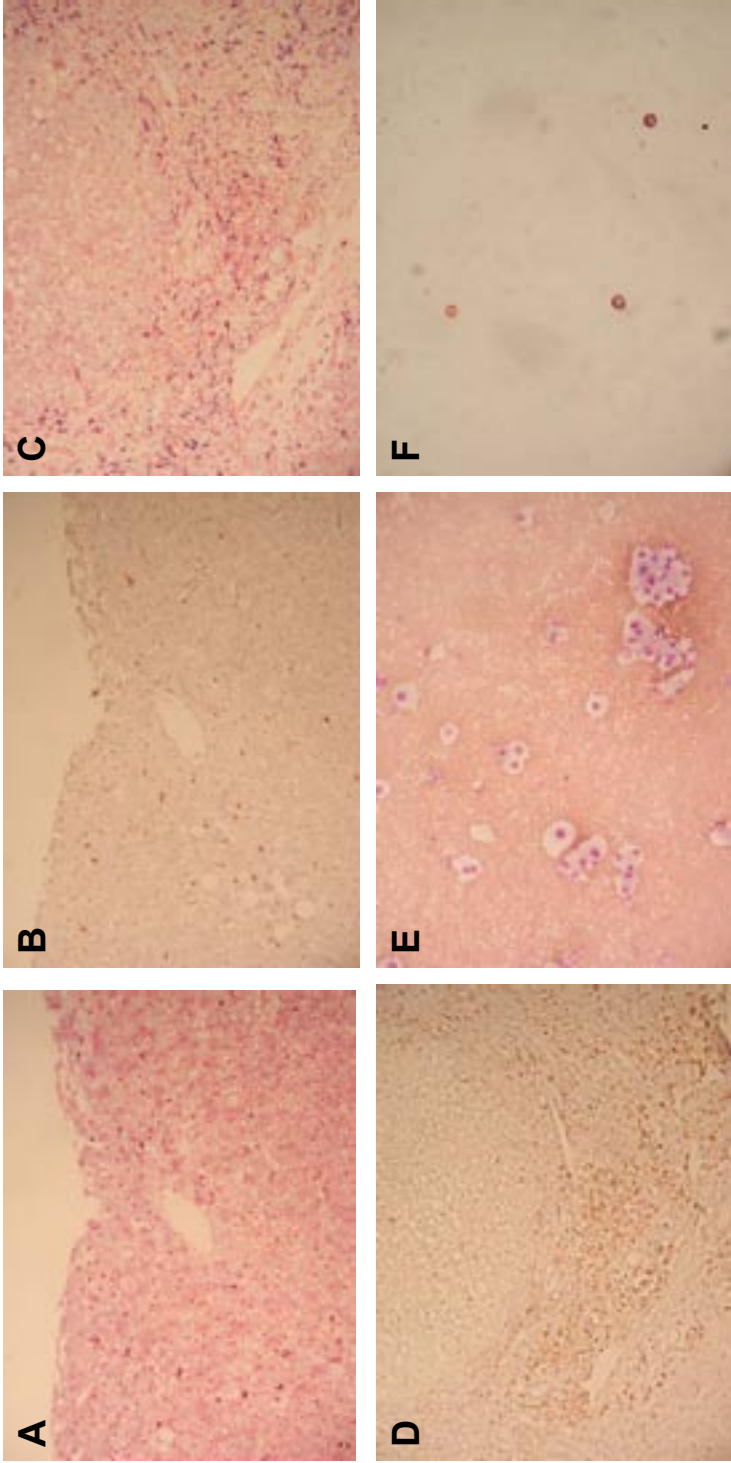
### Immunocytochemistry fine-needle aspiration biopsies

CD3<sup>+</sup> and CD8<sup>+</sup> cells present on cytospin slides were visualized by an immunocytological double stain technique. The slides were fixed in 4% paraformaldehyde in phosphate-buffered saline pH 7.3. Subsequently, endogenous peroxidase was blocked by incubation with citric acid buffer pH 5.8 supplemented with 0.03% hydrogen peroxide containing 0.2% (w/v) sodium azide for 15 seconds. To reduce aspecific antibody binding, slides were incubated with TBS supplemented with 10% normal rabbit serum (Life Technologies, Inc, Gaithersburg, USA) and 10% normal human plasma (CLB). Subsequently, the slides were incubated overnight at 4°C with CD8 mAb (clone C8/144B, DAKO, Glostrup, Denmark). Detection of primary antibody was performed with rabbit-anti-mouse immunoglobulins (RAM, DAKO) for one hour followed by alkaline-phosphatase-anti-alkaline phosphatase complex (APAAP, Serotec, Oxford, UK).

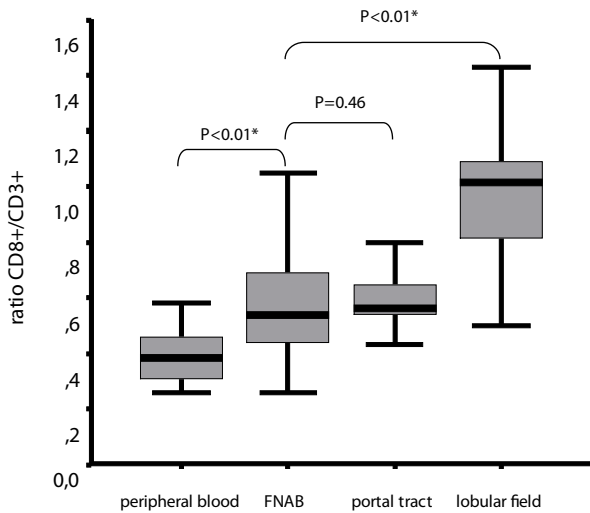
At the end of day 2, the slides were incubated overnight with the second primary mAb CD3-FITC (clone UCHT1, Immunotech, Marseille, France) at 4°C. At day 3, one hour incubation of rabbit-anti FITC-HRP (DAKO) was used to detect CD3. Visualization was performed by incubation of the slides firstly in Fast Blue salt / naphthol AS-BI followed by 3-amino-9-ethylcarbazole (AEC). Slides were counterstained with methylgreen 1% for 10 seconds and mounted in glycerol. Negative controls were either performed by replacement of the primary mAb by an isotype matched control mAb or by leaving out the primary antibody.

### Immunohistochemistry liver tissue biopsies

The distribution of CD3<sup>+</sup> and CD8<sup>+</sup> cells in the liver was visualized in consecutive sections of formalin-fixed, paraffin-embedded liver specimens. The liver sections were firstly deparaffinized with xylene (Lab Scan Ltd, Dublin, Ireland) and ethanol (Merck, Darmstadt, Germany). Thereafter antigen retrieval was performed by a 15 minutes incubation at 99°C in citrate buffer (pH 6.0)



**Figure 1.** Immunohistochemical CD8 (A) and CD3 (B) stainings of lobular fields and CD8 (C) and CD3 (D) stainings of portal tracts in consecutive slides of a formalin-fixed and paraffin-embedded liver tissue biopsy. Fine-needle aspiration biopsy preparations stained with May-Grunwald-Giemsa solution (E), or immunocytochemically for CD3 (red) and CD8 (blue) (F).



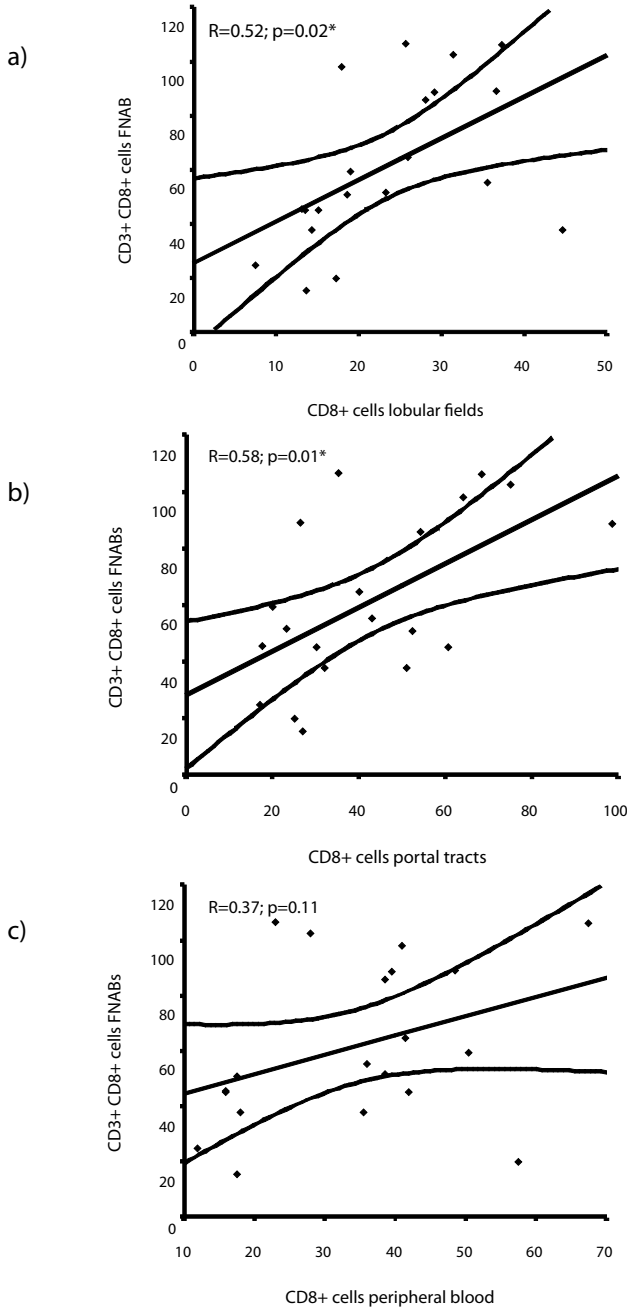
**Figure 2.** The median CD8+/CD3+ ratio in peripheral blood, FNABs, portal tract and lobular fields. The upper and lower limits of the boxes and the middle line across the boxes indicate the 75th and 25th percentiles and the median (the 50th percentile), respectively. The length of the box is thus the interquartile range; the box represents 50% of the data. The upper and lower horizontal bars indicate the 90th and 10th percentiles, respectively.

under intermittent microwave exposure. Overnight, the paraffin slides were incubated with CD3mAb (clone F7.2.38, DAKO) and CD8mAb (clone C8/14415, DAKO) at 4°C. Slides were washed with Tris-buffered saline (TBS) pH 7.3 supplemented with 0.1% Tween-20. CD3 expression was demonstrated by a goat anti-mouse Ig conjugated to a peroxidase labeled polymer (En Vision HRP system, DAKO) and CD8 antigen was detected with the RAM-APAAP procedure. Histochemical revelation was performed by incubation with diaminobenzidine (DAB) or Fast Blue salt / naphthol AS-BI phosphate. Negative controls were performed by replacement of the primary mAb by an isotype-matched control mAb. Slides were counterstained in case of DAB staining with Mayer's solution (Merck) or in case of Fast Blue staining with nuclear Fast Red (Fluka Chemie, Buchs, Switzerland)

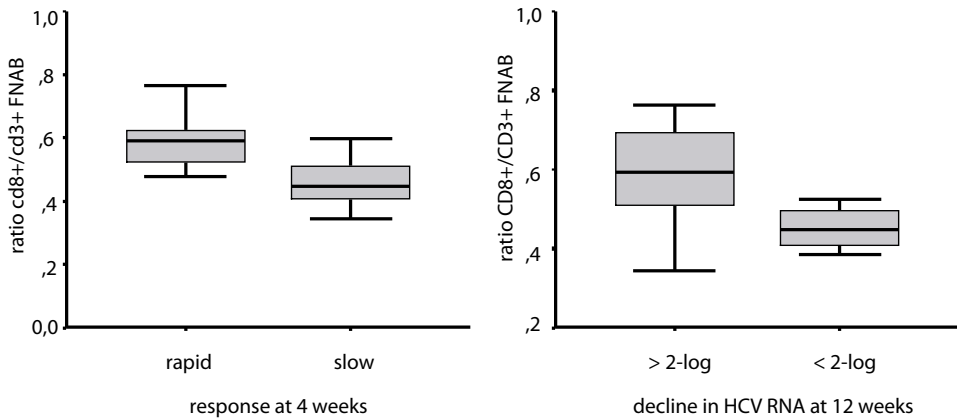
#### Quantification of Immunohisto- and Immunocytochemistry positive cells

Two investigators independently examined and counted CD3+ and CD8+ cells in all consecutive liver tissue biopsy slides, and CD3+CD8+ and CD3+CD8- cells in FNAB and peripheral blood cytopsin preparations microscopically at a magnification of 400x. FNAB cytopsin preparations and tissue biopsy sections were examined independently and in separate sessions. The investigators were blinded to the virological and clinical biochemical conditions of the patients. In every paraffin biopsy slide 8 microscopic fields within the liver lobuli were randomly selected to count CD3+ or CD8+ T-lymphocytes. In addition at least 3 portal tracts were counted.

Since the numbers of leukocytes on individual cytopsin preparations may vary, the numbers



**Figure 3.** Variations in numbers of CD8+ T-lymphocytes in the liver tissue biopsies were reflected in the FNAB.



**Figure 4.** In FNABs a significantly higher median CD8+/CD3+ T-lymphocyte ratio was found in “rapid responders” than in “slow responders” at 4 weeks of treatment ( $p=0.02$ )(A). At 12 weeks the CD8+/CD3+ T-lymphocyte ratio was lower in patients who did not have a 2-log drop with borderline significance (B). For explanation on boxes and lines see figure 2.

of positive cells counted were normalized to the number of leukocytes. For that purpose, in every FNAB cytopsin preparation, 6 microscopic fields were randomly selected to count the number of leukocytes. The count was multiplied with 104 (total number of high power fields in a cytopsin slide) to obtain the total number of leukocytes per cytopsin slide. For analysis, the numbers of positive cells were expressed per 1000 leukocytes.

#### Virological assessments

A quantitative HCV RNA assay was performed to assess viremia (Cobas Amplicor HCV test, Roche Diagnostics, Almere, The Netherlands) within one week before or after the liver biopsy. In addition these tests were performed at the start of treatment and at 4 and 12 weeks during treatment.

#### Statistical analysis

Data are expressed as mean  $\pm$  standard deviation, unless otherwise indicated. Pearson's correlation coefficients ( $r$ ) were used to investigate the correlation between liver, peripheral blood and FNAB cell counts. Mann-Whitney tests were performed to investigate differences in CD3+/CD8+ ratios between FNAB, peripheral blood and liver tissue biopsies, and between treatment response groups. P-values ( $p$ ) of  $< 0.05$  (two sided) were considered to be statistically significant.



## RESULTS

### Patients

Twenty-six patients with chronic hepatitis C who underwent a FNAB and a liver tissue biopsy in the evaluation for the necessity of antiviral treatment were included in this study. According to the most recent treatment consensus [10] therapy was indicated and sequentially started in 23 patients. There was no indication for treatment in 2 patients, 1 patient was lost prior to therapy for further follow-up.

### Relation between T-cells in liver FNAB, liver tissue biopsy and peripheral blood

CD8<sup>+</sup> and CD3<sup>+</sup> T-cells were immunocytochemically detected in FNABs, liver tissue biopsies, and peripheral blood specimens (Figure 1). In peripheral blood, about forty percent of the CD3<sup>+</sup> T-cells were cytotoxic T-cells bearing the CD8 marker. In contrast in the liver, both in the portal tracts as well as intralobular, the CD8<sup>+</sup>/CD3<sup>+</sup> ratio's were significantly higher (both  $p < 0.01$ ; figure 2).

FNABs are cytological aspirates and will therefore contain liver-derived as well as blood-derived leukocytes. To investigate whether the leukocytes in FNABs reflect intrahepatic inflammatory cells, we first compared the CD8<sup>+</sup>/CD3<sup>+</sup> ratios found in FNAB, liver tissue biopsies, and blood. The CD8<sup>+</sup>/CD3<sup>+</sup> ratio in the FNAB was significantly higher than that in peripheral blood ( $p < 0.01$ ), significantly lower than that in the lobular fields ( $p < 0.01$ ), but not different from that in portal tracts of the liver tissue biopsies ( $p = 0.46$ ), indicating that T-lymphocytes in FNAB originate primarily from the liver (Figure 2). The difference in CD8<sup>+</sup>/CD3<sup>+</sup> between lobular fields and

FNAB may be due to the fact that in the liver the majority of both the CD8<sup>+</sup> and CD3<sup>+</sup> cells were present in the portal tracts (Figure 1). Next, we investigated whether variations in numbers of CD8<sup>+</sup> T-lymphocytes in the liver were reflected in the FNAB. Significant correlations between the numbers of CD8<sup>+</sup> cells in the lobular fields ( $r = 0.52$ ,  $p = 0.02$ ; figure 3a) or in the portal tracts ( $r = 0.58$ ,  $p = 0.01$ ; figure 3b) with the numbers of CD8<sup>+</sup>CD3<sup>+</sup> T-lymphocytes in the FNAB (expressed as number per thousand leukocytes) were found. CD3<sup>+</sup>CD8<sup>+</sup> T-lymphocytes in the FNAB did not correlate with CD3<sup>+</sup>CD8<sup>+</sup> T-lymphocytes from peripheral blood ( $r = 0.37$ ,  $p = 0.11$ ; figure 3c).

The numbers of CD3<sup>+</sup> T-lymphocytes in the FNAB were also correlated with CD3<sup>+</sup> T-cells in the portal tracts ( $r = 0.47$ ,  $p = 0.04$ ), but in addition these were weakly associated with those in lobular fields ( $r = 0.40$ ,  $p = 0.08$ ) and peripheral blood ( $r = 0.38$ ,  $p = 0.06$ ), indicating that CD3<sup>+</sup> T-lymphocytes in FNAB originate both from liver and blood.

### T-cells in pretreatment FNAB in relation to response

T-cell parameters in FNAB, liver tissue biopsy and peripheral blood as well as treatment data such as HCV RNA levels at baseline and at 4 and 12 weeks of treatment and were available in 20 out of 23 treated patients. In order to investigate differences between treatment response

groups we divided the patients on treatment into two groups according to the decline in HCV RNA at 4 and 12 weeks of therapy. The average decline in HCV RNA within the first month of treatment was 2.7-log (range: 0.45-5.27). Patients who had a serum HCV RNA decline of less than 2.7-log within this period were considered "slow responders" (n=7) and those with a decline of more than 2.7-log as "rapid responders" (n=13). The relative numbers of CD8<sup>+</sup> T-cells were not associated to response (p=0.94), but the ratio of CD8<sup>+</sup>/CD3<sup>+</sup> T-lymphocytes in FNABs was significantly higher in responders than in non-responders (p=0.02; figure 4a). At 12 weeks of therapy 4 patients did not have at least a 2-log drop of HCV RNA. All 4 were "slow responders" at week 4. In these patients the CD8<sup>+</sup>/CD3<sup>+</sup> T-lymphocytes ratio in FNABs was lower compared to the group with more than 2-log decline, although with borderline significance (p=0.06; figure 4b).

## DISCUSSION

In the present study we investigated whether the minimal invasive fine needle aspiration biopsy (FNAB) technique could be used as a tool to monitor CD8<sup>+</sup> T-lymphocytes in the liver during chronic HCV-infection. Comparison of the ratio's and numbers of CD8<sup>+</sup> and CD3<sup>+</sup> T-cells in simultaneously obtained FNABs, liver tissue biopsies and peripheral blood specimens showed that CD8<sup>+</sup> T-cells in FNABs were primarily liver-derived. Since, in contrast to circulating T-cells, the majority of intrahepatic T-cells are CD8<sup>+</sup> T-cells [13-14], first the CD8<sup>+</sup>/CD3<sup>+</sup> ratio's in the three sources were compared. In the FNABs these were similar to those in portal tract, where the majority of the intrahepatic CD8<sup>+</sup> T-cells reside, but different from that in the blood samples. Second, the relative numbers of CD3<sup>+</sup>CD8<sup>+</sup> T-cells in the FNABs correlated significantly with the absolute CD8<sup>+</sup> T-cell numbers in the lobular fields and the portal tracts of simultaneously obtained liver tissue biopsies, while there was no correlation with numbers in peripheral blood. On the other hand, variations in numbers of CD3<sup>+</sup> T-lymphocytes in the FNABs were associated with variations in both peripheral blood and liver tissue biopsies, indicating that CD3<sup>+</sup> cells in the FNABs originated from the liver and blood. Recently we found that numbers of CD8<sup>+</sup> T-cells in portal tracts of pre-treatment liver tissue biopsies were associated to the occurrence of response of HCV-infection on interferon- $\alpha$  therapy [7]. To investigate whether quantification of T-cells in FNABs showed association with early virological response during therapy, the patients were divided into two response groups according to their individual decline in HCV RNA within the first 4 treatment weeks. We choose the average decline of HCV-RNA within the first month as value to divide the patients into "rapid" and "slow" responders. According to this limit, a significantly higher FNAB CD8<sup>+</sup>/CD3<sup>+</sup> T-lymphocyte ratio was found in "rapid responders" than in "slow responders".

For 12 weeks of therapy, a drop in HCV RNA of at least 2-log recently proved to be essential for obtaining a sustained virological response recently [15]. Dividing our patients according to

this limit, a borderline significant lower CD8<sup>+</sup>/CD3<sup>+</sup> T-lymphocyte ratio was found in patients who did not have at least a 2-log drop of HCV RNA as compared to the other patients. Therefore, whether the CD8/CD3 ratio in pretreatment FNAB is predictive for long-term virological response to therapy needs to be investigated in a larger patient population.

It is not allowed to compare the present finding directly to our previous finding on the association between the numbers of CD8<sup>+</sup> T-cells in pre-treatment liver biopsies and response to anti-HCV therapy [7], since absolute numbers of cells cannot be measured in FNABS and the therapies in both studies are different. In the previous study the patients were treated with interferon- $\alpha$  and in the present study with Peg-interferon. The determining role of the immune system in obtaining a sustained response is probably much smaller in Peg-interferon therapy because of the long lasting and constant antiviral pressure and the relatively high dose when compared to 3 MU t.i.w of conventional interferon- $\alpha$  therapy.

In conclusion, we demonstrated that differences in numbers of intrahepatic CD8<sup>+</sup> T-cells during chronic HCV-infection are reflected in FNABs, and that there is an association between the composition of the T-cell population contained in pre-treatment FNABs and early response to subsequent anti-viral therapy. We therefore postulate that the FNAB-technique can be used as a tool for monitoring the cellular immune status in the liver during chronic HCV-infection on a frequent basis.

## REFERENCES

1. Minutello MA, Pileri P, Unutmaz D, Censini S, Kuo G, Houghton M, *et al.* Compartmentalization of T lymphocytes to the site of disease: intrahepatic CD4+ T cells specific for the protein NS4 of hepatitis C virus in patients with chronic hepatitis C. *J Exp Med* 1993;178:17-25
2. He XS, Rehermann B, Lopez-Labrador FX, Boisvert J, Cheung R, Mumm J, *et al.* Quantitative analysis of hepatitis C virus-specific CD8 (+) T cells in peripheral blood and liver using peptide-MHC tetramers. *Proc Natl Acad Sci U S A* 1999;96:5692-5697
3. Cooper S, Erickson AL, Adams EJ, Kansopon J, Weiner AJ, Chien DY, *et al.* Analysis of a successful immune response against hepatitis C virus. *Immunity* 1999;10:439-449
4. Nelson DR, Marousis CG, Ohno T, Davis GL, Lau JY. Intrahepatic hepatitis C virus-specific cytotoxic T lymphocyte activity and response to interferon alfa therapy in chronic hepatitis C. *Hepatology* 1998;28:225-230
5. Lohr HF, Gerken G, Roth M, Weyer S, Schlaak JF, Meyer zum Buschenfelde KH. The cellular immune responses induced in the follow-up of interferon-alpha treated patients with chronic hepatitis C may determine the therapy outcome. *J Hepatol* 1998;29:524-532
6. Cramp ME, Carucci P, Rossol S, Chokshi S, Maertens G, Williams R, *et al.* Hepatitis C virus (HCV) specific immune responses in anti-HCV positive patients without hepatitis C viraemia. *Gut* 1999;44:424-429
7. Vrolijk JM, Kwekkeboom J, Janssen HL, Hansen BE, Zondervan PE, Osterhaus AD, *et al.* Pretreatment Intrahepatic CD8+ Cell Count Correlates with Virological Response to Antiviral Therapy in Chronic Hepatitis C Virus Infection. *J Infect Dis* 2003;188:1528-1532
8. Lautenschlager I, Hockerstedt K, Ahonen J, Eklund B, Isoniemi H, Korsback C, *et al.* Fine-needle aspiration biopsy in the monitoring of liver allografts. II. Applications to human liver allografts. *Transplantation* 1988;46:47-53
9. Lautenschlager I, Hockerstedt K, Hayry P. Fine-needle aspiration biopsy in the monitoring of liver allografts. *Transpl Int* 1991;4:54-61
10. National Institutes of Health Consensus Development Conference Statement: Management of hepatitis C: 2002--June 10-12, 2002. *Hepatology* 2002;36:53-20
11. Kwekkeboom J, Zondervan PE, Kuijpers MA, Tilanus HW, Metselaar HJ. Fine-needle aspiration cytology in the diagnosis of acute rejection after liver transplantation. *Br J Surg* 2003;90:246-247
12. Kuijff ML, Kwekkeboom J, Kuijpers MA, Willems M, Zondervan PE, Niesters HG, *et al.* Granzyme expression in fine-needle aspirates from liver allografts is increased during acute rejection. *Liver Transpl* 2002;8:952-956
13. Crispe IN. Hepatic T cells and liver tolerance. *Nat Rev Immunol* 2003;3:51-62
14. Mehal WZ, Azzaroli F, Crispe IN. Immunology of the healthy liver: old questions and new insights. *Gastroenterology* 2001;120:250-260
15. Fried MW, Shiffman ML, Reddy KR, Smith C, Marinos G, Goncalves FL, Jr., *et al.* Peginterferon alfa-2a plus ribavirin for chronic hepatitis C virus infection. *N Engl J Med* 2002;347:975-982



# Chapter 7

## **Reduced numbers of mature myeloid dendritic cells in hepatic lymph nodes of patients with chronic HBV- or HCV-infection**

T.J. Tang<sup>1</sup>, D. Vukosavljevic<sup>1</sup>, H.L.A. Janssen<sup>1</sup>, R.S. Binda<sup>1</sup>, S. Mancham<sup>1</sup>, H.W. Tilanus<sup>2</sup>,  
J.N.M. IJzermans<sup>2</sup>, S.W. Schalm<sup>1</sup>, H. Drexhage<sup>2</sup>, J. Kwekkeboom<sup>1</sup>

Departments of <sup>1</sup>Gastroenterology and Hepatology, <sup>2</sup>Surgery and <sup>3</sup>Immunology  
Erasmus MC, University Medical Center Rotterdam, The Netherlands

Submitted for publication



## ABSTRACT

Chronic carriers of hepatitis B virus (HBV) or hepatitis C virus (HCV) have impaired T-cell responses against these viruses. We hypothesized that this immunological deficit may be due to impaired presentation of viral antigens by liver-derived dendritic cells (DC) to T-cells in the hepatic lymph nodes (LN). To investigate whether the composition of the DC-population in hepatic LN is affected in these patients, we compared by quantitative immunohistochemistry the numbers of immature Langerhans-type myeloid DC (MDC), mature MDC, plasmacytoid DC (PDC), and IFN- $\alpha$ -producing cells in the paracortex of hepatic LN obtained during liver transplantation from chronic HBV-patients (n=8), chronic HCV-patients (n=5), patients with liver inflammation due to cholestatic liver diseases (n=10), and organ donors with non-inflamed livers (n=10). Hepatic LN from patients with chronic HBV- or HCV-infection contained significantly less mature MDC, but similar numbers of immature Langerhans-type MDC, PDC and IFN- $\alpha$  producing cells compared to hepatic LN from patients with cholestatic liver diseases. Hepatic LN from organ donors contained strongly variable numbers of all three DC-types. In conclusion, hepatic LN of patients with persistent HBV- or HCV-infection have reduced numbers of mature MDC in their T-cell areas. This may be one cause of the impaired anti-viral T-cell response in these patients.



## INTRODUCTION

Many individuals infected with hepatitis B virus (HBV) or hepatitis C virus (HCV) are unable to clear these viruses and develop a chronic carrier state. Effective control of these viruses during acute self-limiting infections is associated with vigorous and multi-specific antiviral T-helper (Th) and cytotoxic T-lymphocyte (CTL) responses. The virus-specific Th lymphocytes found during self-limiting infections are predominantly of the T-helper 1 type (Th1), producing cytokines which activate the cellular arm of the immune system. In contrast, in chronic carriers of these viruses, virus-specific T-cell responses are weak, and Th cells are often characterized by a type 2 cytokine response (recently reviewed in [1] and [2]). It is at present unclear why chronically infected patients are unable to mount adequate antiviral T-cell responses.

T-cell responses are initiated by antigen-presenting cells (APC) in secondary lymphoid tissues, especially in the lymph nodes (LN) to which the lymph of the infected tissue is draining. The most potent APC are myeloid dendritic cells (MDC). These DC are, in contrast to other APC, capable of activating naïve T-cells. MDC reside as immature sentinile cells in non-lymphoid tissues, specialized in recognition and uptake of pathogens. After antigen uptake MDC's migrate to the regional LN, and, dependent on the type of stimuli they have received, mature to APC with strong T-cell stimulatory capacity [3], or remain in a immature state capable of inducing T-cell tolerance [4, 5]. The second main DC-type are the plasmacytoid DC (PDC), which are able to produce high amounts of IFN- $\alpha$  upon stimulation by several viruses [6, 7]. This cytokine has pronounced direct anti-viral effects [8]. Upon activation, precursor-PDC differentiate into APC, which are, by producing IFN- $\alpha$ , able to drive the differentiation of naïve T-helper cells into the Th1 type direction [9, 10].

There are indications that the weak T-cell response during chronic HBV- and HCV-infections might be due to reduced numbers and impaired function of MDC. MDC cultured *in vitro* from monocytes of patients with chronic HCV- or HBV-infection were found to have a lower capacity to stimulate proliferation of allogeneic T-cells and a decreased capacity to produce the Th1-driving cytokine IL-12 compared to monocyte-derived MDC from healthy people [11-15]. In addition, patients with chronic HBV- or HCV-infection have lower numbers of circulating precursor-MDC compared to healthy individuals [14, 16]. However, the anatomical location where T-cell responses to these viruses are elicited is not the blood circulation, but the hepatic LN. Indeed, recently HBV-specific T-cells capable of reacting to viral antigenic peptides have been detected in hepatic LN from patients with chronic HBV-infection [17].

To start elucidating whether DC in hepatic LN of patients with chronic HBV- and HCV-infection are affected, we compared numbers of MDC, PDC, and IFN- $\alpha$ -producing cells in the T-cell areas of hepatic LN from patients with chronic HBV- or HCV-infection, inflammatory liver diseases due to a non-viral etiology, and of organ donors with non-inflamed livers.

**Table 1.** Patient and donor characteristics

	HBV (n=8)	HCV (n=5)	cholestatic disease (5 PBC, 5 PSC)	donors (n=10)	p- Value
gender (m/f)	7/1	3/2	5/5	5/5	0.32 <sup>2</sup>
age <sup>1</sup> (years)	51 (31-59)	57 (44-60)	47 (37-65)	53 (25-64)	0.77 <sup>3</sup>
Child-Pugh (A/B/C)	0/1/7	1/2/2	2/5/3	na	0.13 <sup>2</sup>
Pre-transplant/donation ALT (IU/ml) <sup>1</sup>	62 (29-590)	50 (35-332)	67 (23-131)	...	0.95 <sup>3,4</sup>
HBV-DNA/HCV-RNA (geq/ml)					
median	6.10 <sup>4</sup>	9.10 <sup>5</sup>	na	na	na
range	<1.10 <sup>3</sup> - 6.10 <sup>7</sup>	7.10 <sup>3</sup> - 6.10 <sup>6</sup>			
Hepatocellular Carcinoma	4/8	2/5	0/10	0/10	na
HBeAg+; treated with lamivudine	4/8	na	na	na	na

<sup>1</sup>median (range)<sup>2</sup>Fisher's exact test<sup>3</sup>Kruskal Wallis test<sup>4</sup>p-value for the 3 patient groups

na = not applicable

## MATERIAL AND METHODS

### Patients and lymph nodes

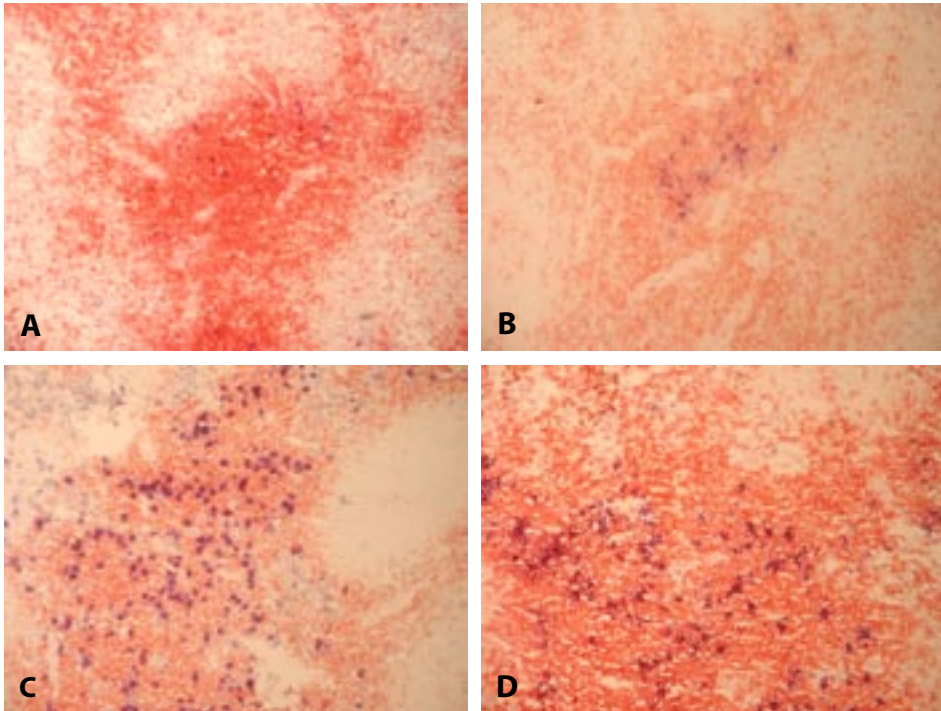
During liver transplantations, liver lymph-draining LN were obtained along the hepatoduodenal ligament [18] of patients with chronic HBV-infection (n=8), chronic HCV-infection (n=5), primary sclerosing cholangitis (PSC; n=5), or primary biliary cirrhosis (PBC; n=5) as indications for liver transplantation. In addition hepatic LN were obtained from cadaveric donor-livers (n=10). The LN were transported in University of Wisconsin solution to the laboratory and frozen in isopentane cooled in liquid nitrogen and stored at -80°C. The Medical Ethical Committee of the Erasmus Medical Center approved the study protocol.

### Detection of HBV DNA and HCV RNA

Serum HBV DNA and HCV RNA were quantitatively measured by real-time PCR-based assays (detection limits: HBV DNA  $1 \times 10^3$  geq/ml; HCV RNA 100 geq/ml; both manufactured by Roche Diagnostics, Almere, The Netherlands).

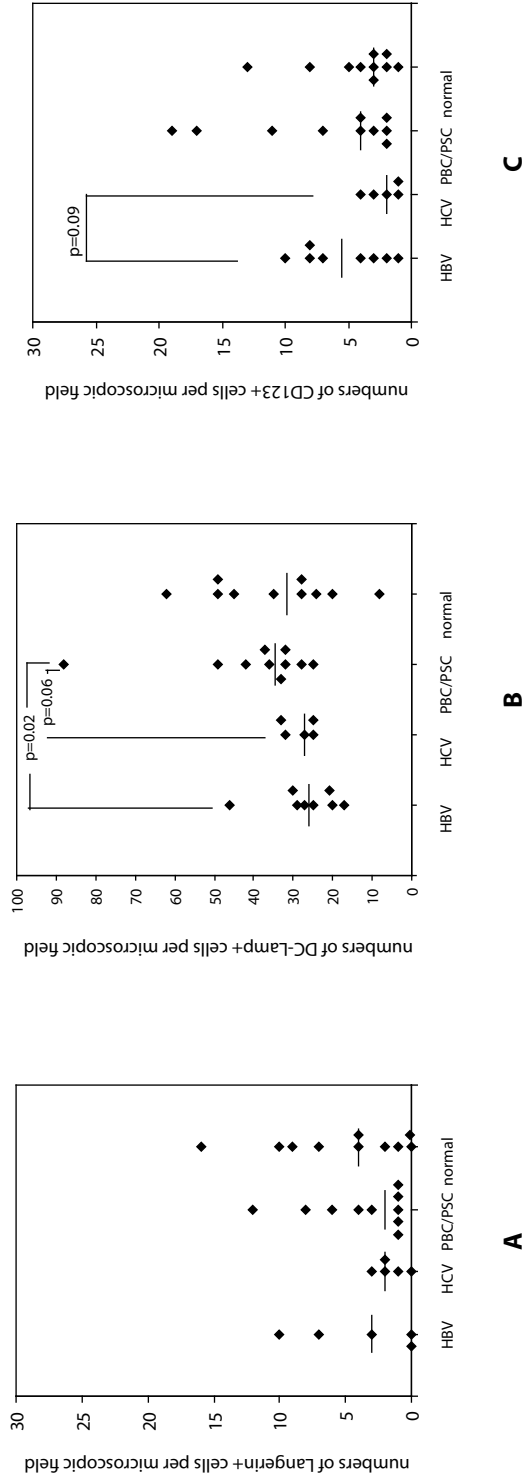
### Immunohistochemistry

To visualize DCs in the paracortex of LN, cryostat sections were double-stained for DC and T-cells. At three planes of each LN, consecutive 5 µm cryostat sections were cut. These were fixed in 4% paraformaldehyde (10 min), after which endogenous peroxidase was blocked by incubation in citric acid/phosphate buffer-solution (pH=5.8) supplemented with 0.05% H<sub>2</sub>O<sub>2</sub> and 0.2% NaN<sub>3</sub> (15 min, 20°C). Aspecific antibody binding was reduced by pre-incubation in Tris-Buffered Saline (TBS, pH=7.4) supplemented with 10% Normal Rabbit Serum (NRS) and



**Figure 1.** Cryosections of hepatic LN from patients with chronic HBV-infection (A), chronic HCV-infection (B), and PBC (C), and from an organ donor (D) immunohistochemically double-stained for T-cells (CD3) in red and for mature MDC (anti-DC-Lamp) in blue. The red-coloured areas represent the paracortex. Non-coloured areas are B-cell follicles or medulla. Note that HEVs are colourless too.

10% Normal Human Serum (NHS). Primary mAb were applied in optimal concentrations in TBS (pH 7.4) supplemented with 1% NHS for 18 h at 4°C. The mAb used were: anti-DC-LAMP (CD208; clone 104.G4 [19]), anti-Langerin (CD207; clone DCGM4 [20]), which were both generous gifts from Prof. S. Lebecque, Schering Plough Corporation, Dardilly, France, CD123 (Becton and Dickinson, Heidelberg, Germany), or isotype-matched control mAb (Dako, Glostrup, Denmark). Binding of anti-DC-LAMP and CD123 mAb was detected by incubation with Rabbit-anti-Mouse antibodies (Dako) diluted in TBS (pH 7.4) followed by Alkaline-Phosphatase-Anti-Alkaline Phosphatase antibody complex (APAAP, Serotec, UK). Anti-langerin was detected by biotinylated Rabbit-anti-Mouse antibodies and followed by Streptavidin-Alkaline Phosphatase (AP) (Dako). In this procedure, slides were blocked for endogenous biotin with DAKO Biotin Blocking System before applying the secondary antibody. Subsequently, all sections were incubated with 10% normal mouse serum (Dako, 30 min, 20°C) and subsequently with CD3-FITC (Beckman Coulter Immunotech, Marseille, France; 1h, 20°C), followed by Rabbit-anti-FITC-Peroxidase (PO) (Dako). To visualize IFN- $\alpha$  producing cells, PFA-fixed sections were incubated with anti-IFN- $\alpha$  mAb (UCytec, Utrecht, The Netherlands), followed by biotinylated Rabbit-anti-Mouse antibodies and



**Figure 2.** Numbers of Langerin+ cells (A), DC-Lamp+ cells (B), and CD123+ cells (C) in T-cell areas of hepatic LN from patients with inflamed livers due to chronic HBV-infection, chronic HCV-infection, auto-immune cholestatic diseases (PBC or PSC) and from organ donors with a non-inflamed liver. Numbers of the different DC-types were quantified per microscopic field of 630 times magnification as described in the Materials and Methods section. Each point represents one LN. Lines indicate median values for each group.



magnification of 630 times. Only brightly coloured cells were counted. For each LN, means were calculated from the numbers of DC counted in 18 microscopic fields distributed over the three sections by the two observers. Numbers of IFN- $\alpha$ -producing cells were counted in two sections of each LN. In each section four randomly selected microscopic fields of 200 times magnification were counted by two observers, and the mean of these counts were calculated.

*Statistical analysis:* Differences in continuous variables between the four study groups was tested by the Kruskal Wallis test for independent samples, and differences in discontinuous variables by the Fisher's exact test. Differences between pairs of groups were tested by the Mann-Whitney U test.

## RESULTS

### Patient characteristics

For this study hepatic LN were collected during liver transplantation procedures from patients with chronic HBV- or HCV-infection, and as control groups, from patients with auto-immune cholestatic diseases, and from liver-donors, i.e. individuals with non-inflamed livers. Patient- and donor characteristics are summarized in Table 1.

The groups did not differ in gender or age. All three patient groups had moderately enhanced serum ALT levels, indicating ongoing liver damage at the time of procurement of the LN, while the organ donors had normal ALT levels. The majority of the patients had decompensated liver cirrhosis, as indicated by the Child-Pugh scores. The Child-Pugh scores tended to be higher in the HBV-group as compared to the patients with HCV or cholestatic diseases, but this difference did not reach statistical significance. Four out of eight HBV-patients had antibodies against HBeAg, but all had active viral replication (HBV-DNA:  $5.10^4$  -  $6.10^7$  geq/ml) on the day of transplantation. The other four HBV-patients were HBeAg<sup>+</sup>, and had been treated for at least 2 months before transplantation with lamivudine. Nevertheless, in three of them HBV-DNA was still detectable in serum on the day of transplantation ( $4.10^3$  -  $6.10^4$  geq/ml). The five patients undergoing liver transplantation for chronic HCV-infection had not been treated for HCV for at least 16 months before transplantation, and all had active viral replication. The group of patients with auto-immune cholestatic diseases consisted of five patients with PBC and five with PSC.

### Comparison of numbers of DC in hepatic LN from patients with chronic HBV- or HCV-infection, patients with autoimmune liver diseases, and organ donors

Figure 1 shows cryosections of hepatic LN from patients with chronic HBV- (A), or HCV-infection (B), PBC (C), and an organ donor (D) immunohistochemically double-stained for T-cells (CD3) in red and for mature MDC (anti-DC-Lamp) in blue. The DC-Lamp<sup>+</sup>-cells are visible as blue cells in red-coloured T-cell areas, i.e. the paracortex. Likewise, Langerhans-type immature myeloid DC

were detected in the paracortex of the LN by staining with anti-Langerin mAb, and PDC with CD123 mAb (not shown).

The densities of the different DC-types in hepatic LN of the HBeAg+ HBV-patients, which had been treated with lamivudine before transplantation, were similar to those in LN of the HBeAg- patients which had not been treated for HBV. Therefore, these LN were combined into one group for analysis. Figure 2A shows that the densities of immature Langerhans-type MDC in hepatic LN did not differ between the groups. However, as shown in Figure 2B, the median density of mature MDC (DC-Lamp+ cells) in the paracortex of LN from chronic HBV-patients was about one quarter lower compared to that in LN from patients with liver inflammation due to cholestatic diseases ( $p=0.02$ ).

Moreover, despite of the limited number of LN from chronic HCV-patients, also in these LN a nearly significantly lower density of mature MDC was observed in comparison with LN from PBC and PSC patients ( $p=0.06$ ). When the data from the patients with HBV- and HCV-infection were taken together, the median density of mature MDC in the paracortex of their hepatic LN was 22% lower compared to that in LN from PBC and PSC patients ( $p=0.007$ ). Due to considerable variation in the densities of mature MDC in LN from organ donors, mature MDC-densities in hepatic LN of the patient groups did not differ significantly from those in the LN of the organ donors (combined HBV- and HCV-patients versus organ donors:  $p = 0.26$ ; cholestatic liver diseases versus organ donors:  $p = 0.56$ ).

In a previous study (Tanis et al, submitted) we found that hepatic LN, both from non-inflamed livers and from patients with auto-immune cholestatic diseases, have about four times less PDC in their paracortex as compared to muscle-and skin-lymph draining LN. Figure 2C shows that chronic HBV-infection does not result in an increase in CD123+ PDC-numbers in hepatic LN, while PDC-numbers tended to be further decreased in hepatic LN from chronic HCV-patients (HCV-group versus HBV-group:  $p = 0.09$ ).

### Comparison of numbers of IFN- $\alpha$ producing cells in hepatic LN from patients with chronic HBV- or HCV-infection, patients with autoimmune liver diseases, and organ donors

The main source of IFN- $\alpha$  in secondary lymphoid organs in vivo are PDC [9]. Immunohistochemical staining of LN-sections with an anti-IFN- $\alpha$  mAb showed that IFN- $\alpha$ -producing cells were mainly situated in the T-cell areas (Figure 3).

Microscopic quantification revealed that the numbers of IFN- $\alpha$  producing cells varied considerable within the study groups, but did not differ significantly between hepatic LN of the different study groups (Figure 4).

## DISCUSSION

Inflammatory components, like necrotic cells [21] and cytokines [22], stimulate the maturation of MDC. Therefore, we estimated that hepatic LN from patients with liver inflammation due to PBC or PSC would contain higher numbers of mature MDC compared to those of organ donors with non-inflamed livers. This was, however, not the case. Hepatic LN from organ donors showed a large variation in mature MDC-numbers. This variation may be due to the presence or absence of factors, like endotoxins absorbed from the gut [23], or cytokines released in the early phase of brain death [24], which stimulate the maturation and migration of liver MDC to the hepatic LN in organ donors. Indeed, in some cadaveric liver transplants Kupffer cells are activated and in others not [25]. Much less variation in DC-numbers was observed in the LN from the patient groups with inflamed livers, where continuous stimulation of hepatic DC may be assumed.

The present study shows that hepatic LN from patients with liver inflammation due to chronic HBV- or HCV-infection contained significantly less mature MDC in their T-cell areas as compared to hepatic LN from patients with liver inflammation due to PBC or PSC. Mature MDC are the most potent APC known. Moreover, hepatic LN are probably the primary sites where MDC present viral peptides derived from the infected hepatocytes to T-cells. We therefore propose that the reduced numbers of mature MDC in these LN may be one of the causes of the impaired anti-viral Th and CTL-responses, which are characteristic for patients with persistent HBV- or HCV-infection. Whether MDC in hepatic LN of chronic HBV- or HCV-patients are also functionally impaired, will be investigated in future studies in which MDC will be isolated from hepatic LN.

The presence of lower numbers of mature MDC in the hepatic LN of chronic HBV- or HCV-patients might be caused by an impairment in MDC-maturation in the liver of these patients. This possibility is suggested by the reduced maturation of monocyte-derived MDC from such patients observed *in vitro* [11-15]. If impaired maturation had occurred *in vivo*, increased numbers of immature MDC would be expected to be present in the hepatic LN of chronic HBV- and HCV-patients. However, we observed similar numbers of immature Langerin<sup>+</sup> MDC in hepatic LN of all patient groups and in the control group of organ donors. Langerin is a molecule specific for the epithelial immature MDC type, i.e. the Langerhans cell. We suppose that the Langerin<sup>+</sup> cells in the hepatic LN represent Langerhans cells immigrated from the Glisson capsule of the liver, like Langerin<sup>+</sup> cells in skin-lymph draining LN are considered to represent Langerhans cells immigrated from the skin [26]. At present no specific antibodies are available for the interstitial type of immature MDC [27], which is supposed to be present in the liver parenchyma. Therefore, in the present immunohistochemical study we could not determine whether increased numbers of immature interstitial-type liver MDC were present in the hepatic LN from chronic HBV- and HCV-patients. Such analysis can only be done by multi-parameter flow cytometry of LN cell suspensions.

The lower numbers of mature MDC in hepatic LN from chronic HBV- and HCV-patients may also be due to reduced availability of bone marrow-derived precursor-MDC in these patients.



Recently, it has indeed been reported that patients with chronic HBV- and HCV-infection have reduced numbers of circulating precursor-MDC in comparison with healthy individuals [14, 16].

PDC are the principal producers of the anti-viral cytokine IFN- $\alpha$ . Moreover, this cytokine can direct the differentiation of naïve Th cells into the Th1 direction. However, to influence the outcome of the T-helper response, IFN- $\alpha$  must be produced at the site where naïve T-cells are activated, i.e. in secondary lymphoid tissue. Several, but not all, viruses are able to induce IFN- $\alpha$  production by PDC *in vitro* [7, 9] and in lymphoid organs *in vivo* [28]. Here, we found that the numbers of IFN- $\alpha$  producing cells, as well as the numbers of PDC, were not increased in the hepatic LN of patients with chronic active HBV- or HCV-infection, compared with those from PBC- and PSC-patients and those of organ donors. Apparently, HBV- and HCV do not stimulate IFN- $\alpha$  production in hepatic LN *in vivo* in chronically infected patients. Whether this is due to inability of these viruses to trigger IFN- $\alpha$  production by PDC, or whether other factors present in chronic HBV- or HCV-patients inhibit the production of this cytokine, will be investigated in future studies. We have previously shown that hepatic LN contain few PDC compared with skin-muscle-lymph draining LN (Tanis et al, submitted). Possibly, the relative shortage of IFN- $\alpha$  producing PDC in hepatic LN is another cause of the impaired anti-viral Th and CTL-responses in chronic HBV- and HCV-patients.

In conclusion, this pilot study shows that hepatic LN in patients with persistent HBV- or HCV-infection have reduced numbers of mature MDC in their T-cell areas compared to hepatic LN of patients with liver inflammation due to auto-immune cholestatic diseases, and that the numbers of IFN- $\alpha$  producing PDC in hepatic LN are not enhanced during these chronic infections. These deficits in the DC-system of hepatic LN may be at least in part responsible for the impaired anti-viral Th and CTL responses found in these patients.

## **ACKNOWLEDGEMENT**

This study was financially supported by the Revolving Fund of the Erasmus MC. The authors thank Geert Kazemier for providing us with hepatic lymph nodes during liver transplant procedures, and Wilco Tanis and Geert Bezemer who participated as students in this project.

## REFERENCES

1. Jung MC, Pape GR. Immunology of hepatitis B infection. *Lancet Infect Dis* 2002;2:43-50
2. Bertoletti A, Ferrari C. Kinetics of the immune response during HBV and HCV infection. *Hepatology* 2003;38:4-13
3. Banchereau J, Steinman RM. Dendritic cells and the control of immunity. *Nature* 1998;392:245-252
4. Jonuleit H, Schmitt E, Steinbrink K, Enk AH. Dendritic cells as a tool to induce anergic and regulatory T cells. *Trends Immunol* 2001;22:394-400.
5. Steinman RM, Nussenzweig MC. Avoiding horror autotoxicus: the importance of dendritic cells in peripheral T cell tolerance. *Proc Natl Acad Sci U S A* 2002;99:351-358
6. Cella M, Jarrossay D, Facchetti F, Allebardi O, Nakajima H, Lanzavecchia A, *et al.* Plasmacytoid monocytes migrate to inflamed lymph nodes and produce large amounts of type I interferon. *Nat Med* 1999;5:919-923
7. Siegal FP, Kadowaki N, Shodell M, Fitzgerald-Bocarsly PA, Shah K, Ho S, *et al.* The nature of the principal type 1 interferon-producing cells in human blood. *Science* 1999;284:1835-1837
8. Katze MG, He Y, Gale M, Jr. Viruses and interferon: a fight for supremacy. *Nat Rev Immunol* 2002;2:675-687
9. Cella M, Facchetti F, Lanzavecchia A, Colonna M. Plasmacytoid dendritic cells activated by influenza virus and CD40L drive a potent TH1 polarization. *Nat Immunol* 2000;1:305-310
10. Kadowaki N, Antonenko S, Lau JY, Liu YJ. Natural interferon alpha/beta-producing cells link innate and adaptive immunity. *J Exp Med* 2000;192:219-226
11. Kanto T, Hayashi N, Takehara T, Tatsumi T, Kuzushita N, Ito A, *et al.* Impaired allostimulatory capacity of peripheral blood dendritic cells recovered from hepatitis C virus-infected individuals. *J Immunol* 1999;162:5584-5591
12. Bain C, Fatmi A, Zoulim F, Zarski JP, Treppe C, Inchauspe G. Impaired allostimulatory function of dendritic cells in chronic hepatitis C infection. *Gastroenterology* 2001;120:512-524
13. Auffermann-Gretzinger S, Keeffe EB, Levy S. Impaired dendritic cell maturation in patients with chronic, but not resolved, hepatitis C virus infection. *Blood* 2001;97:3171-3176
14. Beckebaum S, Cicinnati VR, Dworacki G, Muller-Berghaus J, Stolz D, Harnaha J, *et al.* Reduction in the circulating pDC1/pDC2 ratio and impaired function of ex vivo-generated DC1 in chronic hepatitis B infection. *Clin Immunol* 2002;104:138-150
15. Arima S, Akbar SM, Michitaka K, Horiike N, Nuriya H, Kohara M, *et al.* Impaired function of antigen-presenting dendritic cells in patients with chronic hepatitis B: Localization of HBV DNA and HBV RNA in blood DC by in situ hybridization. *Int J Mol Med* 2003;11:169-174
16. Kunitani H, Shimizu Y, Murata H, Higuchi K, Watanabe A. Phenotypic analysis of circulating and intrahepatic dendritic cell subsets in patients with chronic liver diseases. *J Hepatol* 2002;36:734-741
17. Malacarne F, Webster GJ, Reignat S, Gotto J, Behboudi S, Burroughs AK, *et al.* Tracking the source of the hepatitis B virus-specific CD8 T cells during lamivudine treatment. *J Infect Dis* 2003;187:679-682
18. Scheurlein H KF. The anatomy of the liver. In: Kockerling F SS, editor. *Liver Surgery: Operative techniques and avoidance of complications*. Heidelberg: J.A. Barth; 2001. p. 9-38
19. de Saint-Vis B, Vincent J, Vandenabeele S, Vanbervliet B, Pin JJ, Ait-Yahia S, *et al.* A novel lysosome-associated membrane glycoprotein, DC-LAMP, induced upon DC maturation, is transiently expressed in MHC class II compartment. *Immunity* 1998;9:325-336
20. Valladeau J, Duvert-Frances V, Pin JJ, Dezutter-Damboyant C, Vincent C, Massacrier C, *et al.* The monoclonal antibody DCGM4 recognizes Langerin, a protein specific of Langerhans cells, and is rapidly internalized from the cell surface. *Eur J Immunol* 1999;29:2695-2704
21. Sauter B, Albert ML, Francisco L, Larsson M, Somersan S, Bhardwaj N. Consequences of cell death: exposure to necrotic tumor cells, but not primary tissue cells or apoptotic cells, induces the maturation of immunostimulatory dendritic cells. *J Exp Med* 2000;191:423-434
22. Snijders A, Kalinski P, Hilkens CM, Kapsenberg ML. High-level IL-12 production by human dendritic cells requires two signals. *Int Immunol* 1998;10:1593-1598

23. van Goor H, Rosman C, Grond J, Kooi K, Wubbels GH, Bleichrodt RP. Translocation of bacteria and endotoxin in organ donors. *Arch Surg* 1994;129:1063-1066
24. Amado JA, Lopez-Espadas F, Vazquez-Barquero A, Salas E, Riancho JA, Lopez-Cordovilla JJ, *et al.* Blood levels of cytokines in brain-dead patients: relationship with circulating hormones and acute-phase reactants. *Metabolism* 1995;44:812-816
25. Kwekkeboom J, Kuijpers MA, Bruyneel B, Mancham S, de Baar-Heesakkers E, IJzermans JN, *et al.* Expression of CD80 on Kupffer cells is enhanced in cadaveric liver transplants. *Clin Exp Immunol* 2003;132:345-351
26. Geissmann F, Dieu-Nosjean MC, Dezutter C, Valladeau J, Kayal S, Leborgne M, *et al.* Accumulation of immature Langerhans cells in human lymph nodes draining chronically inflamed skin. *J Exp Med* 2002;196:417-430
27. Woltman AM, van Kooten C. Functional modulation of dendritic cells to suppress adaptive immune responses. *J Leukoc Biol* 2003;73:428-441
28. Dalod M, Salazar-Mather TP, Malmgaard L, Lewis C, Asselin-Pasturel C, Briere F, *et al.* Interferon alpha/beta and interleukin 12 responses to viral infections: pathways regulating dendritic cell cytokine expression in vivo. *J Exp Med* 2002;195:517-528



# **Chapter 8**

**Summary and conclusions**

**Samenvatting en conclusies**

**Appendix**

**Dankwoord**

**Curriculum vitae**

**Bibliography**

**Abbreviations**



## SUMMARY AND CONCLUSIONS

### Intrahepatic immune response in chronic hepatitis B infection (chapter 2 and 3)

More than a third of the world's population has been infected with hepatitis B virus (HBV) and it is estimated that there are 350 million persistent carriers of HBV worldwide, 25% of whom have active chronic liver disease and cirrhosis, which could progress to hepatocellular carcinoma. The annual mortality rate is approximately one million people worldwide, which makes it a major global health concern.

It is not clearly known how an individual develops a chronic hepatitis carrier state; however, a defective immune response of the host is thought to play a critical role in the underlying pathogenetic mechanism. HBV clearance is associated with co-ordinated activation of both the cellular and humoral arms of the adaptive immune response that ultimately control the virus. A proper activation of the innate response is necessary for full development of an efficient anti-viral adaptive immune response. The earliest responses are non-specific and include type I IFN, NK and NK-T cells, non-specific activation of Kupffer cells and proper dendritic cell (DC) maturation. In addition of being a first line of defence against the virus, the innate immune response is necessary to deliver the signals to a proper adaptive response. The fundamental step of antiviral protective immunity is the elimination of intracellular virus by the cellular response. This has long been thought to require the immune destruction of infected hepatocytes by cytotoxic T-lymphocytes (CTL). Recent investigations have demonstrated that the cellular immune response can also purge HBV from infected hepatocytes without killing the infected cells, by secreting of antiviral cytokines (IFN gamma and TNF alpha) that inhibit viral gene expression and replication, thereby curing the HBV infection without destruction of the liver.

CD8+ CTLs are the main immune effector cells in the viral clearance. However, little is known about the immune mechanisms which control viral replication during chronic HBV-infection. A majority of chronically infected patients survive for several decades. In these patients apparently a balance emerges between liver injury and viral replication, indicating a phase of relative immune control. In addition to CTLs, cells of the innate immune response, such as macrophages, Kupffer cells, natural killer (NK) cells may contribute to control of the virus and to tissue injury. Most of the available information is based on studies on anti-viral T-cells in the circulation of patients. Since the infection is localized in the liver, we decided to study the intrahepatic immune response.

In chapter 2, we studied the immune balance between HBV and the chronically infected host. We performed a cross-sectional study in which we determined the associations between numbers of intrahepatic immune cells on the one hand and viral replication and liver damage on the other hand in patients with HBeAg<sup>+</sup> and HBeAg<sup>-</sup> chronic HBV-infection. We found that low HBV replication and HBeAg negativity were associated with increased numbers of intralobular CD8+ T-lymphocytes in liver biopsies. This suggests a prominent role of CTL in immune control of viral replication during chronic infection. We did not determine whether



these intrahepatic CD8 T-lymphocytes were HBV specific T-cells, but additional investigations showed an activated state of these cells, revealed by the presence of intracellular cytotoxic granule proteases granzymes A and B. In contrast to patients with fulminant HBV-infection, the intrahepatic CD8+ T-lymphocytes in the patients with chronic infection did almost not produce antiviral cytokines. The absence of intrahepatic cytokine production may be one of the causes of viral persistence in these patients. NK (CD56+) and plasmacytoid dendritic cells (CD123+), which are the principal producers of IFN $\alpha$ , were rare in the liver specimens, suggesting a limited role in chronic HBV infection. An interesting finding was the Fas-ligand upregulation on Kupffer cells in patients with inflammatory liver damage, suggesting a contribution of Kupffer cells to virus-induced liver injury.

In chapter 3, we investigated whether the pre-treatment numbers of intrahepatic CD8+ T-lymphocytes were related to response to anti-viral therapy in chronic HBV patients. We found firstly, that the pretreatment numbers of intrahepatic CD8+ T-cells were higher in responders than in nonresponders and, secondly, that the intrahepatic lobular CD8 T-cells decreased significantly in responders, but remain unchanged in nonresponders. These findings suggest that in responders, CD8+ T-cells infiltrated in the liver favour complete viral elimination during antiviral therapy. Further studies must be performed to investigate whether the CD8+ T-cells present in the lobular fields at the end of therapy are HBV-specific T-cells, controlling the virus. For guidance of antiviral management, our results demonstrate that the pretreatment numbers of CD8+ T-lymphocytes may predict response to antiviral therapy. Future studies must indicate whether this finding could have clinical implications for antiviral therapy.

The primary host immune attack against HBV is the cause of the liver injury, mediated by a cellular response to small epitopes of HBV proteins, especially HBcAg, presented on the surface of the hepatocyte. HLA-class I-restricted CD8+ cells recognize HBV peptide fragments derived from intracellular processing and presented on the hepatocyte surface by class I molecules. An interesting finding was that cytoplasmic HBcAg expression was significantly associated with higher number of intrahepatic CD8+ T-lymphocytes and that they were co-localized in the liver. This strongly suggests that these CD8+ T-cells exert antiviral activity at the site of maximal replication resulting in a complete disappearance of HBcAg-infected hepatocytes at the end of therapy.

#### The intrahepatic immune response during treatment of chronic HBV-patients as determined by Fine-Needle aspiration biopsies (chapter 4 and 5)

The intrahepatic cellular immune response during chronic HBV infection can be monitored occasionally, but not frequently with the traditional liver tissue biopsy technique, due to its risks and discomfort. Successful therapy for chronic HBV infection consists of immune modulation (interferon alpha) or direct inhibition of viral replication with nucleoside analogues. However, it is at present unknown why only part of chronic HBV patients responds to these treatments. Longitudinal investigations of the intrahepatic immune response during de novo infection or

treatment of chronic HBV infection have not been performed yet, because these were hampered by the lack of an alternative tool for the liver tissue biopsy. In chapter 4 we introduce the fine-needle aspiration biopsy (FNAB) as a low-risk and patient-friendly tool for frequent monitoring of the intrahepatic immune response during therapy of patients with chronic HBV-infection. The FNAB was sensitive and able to measure a significant CD8+ T-lymphocytes elevation in the liver during ALT flare-ups in three chronic HBV patients, compared to non-flare episodes during antiviral therapy. This elevation was associated in one patient with a sustained seroconversion, indicating that the T-lymphocytes collected by the FNAB-technique reflect antiviral immune reactivity.

Subsequently, we used the FNAB to investigate in a large cohort of chronic HBV patients which intrahepatic mechanisms of CD8+ T-cells were involved in viral clearance during antiviral therapy.

In chapter 5, intrahepatic CD8+ T-cells expressing granzymes and CD8+ T-cells secreting IFN gamma, representing the two pathways of anti-viral activity of CTLs were frequently determined in FNAB during antiviral therapy. The first conclusion we could draw was that there was a significant CD8 T-cell response in the liver, which was absent in peripheral blood during antiviral therapy. This supports the notion that the predominant immune response against HBV is at the site of replication and not in peripheral blood. Secondly, in responders to antiviral therapy, and not in non-responders, a significant elevation of intrahepatic CD8+ T-cells was observed during treatment. This treatment response was associated with elevations of CD8 T-lymphocytes containing granzyme B and CD8 T-lymphocytes expressing IFN gamma during antiviral therapy. It remains unclear whether this elevation of CD8+ T-lymphocytes is the result of recruitment of activated CD8 T-cells or expansion of locally resting T-cells that have recognized viral antigens. The major conclusions from this study was that a prominent intrahepatic CD8+ T-cell response was present in responders to antiviral therapy and not in nonresponders and that cytolytic and noncytolytic mechanisms were both involved in the response to antiviral therapy.

#### Intrahepatic immune response in relation to treatment of chronic HCV-infection as determined by FNAB (chapter 6)

More than seventy percent of adults infected by hepatitis C virus develop a chronic infection. Like for HBV-infection, it has been proposed that the ability to mount an efficient cellular immune response is the main mechanism responsible for HCV control, whereas a deficient immune response leads to chronicity. Based on our experience with the application of FNAB in chronic HBV patients, we validated the FNAB for detection of intrahepatic CD8+ T-cells in chronic HCV patients by comparison with liver tissue biopsies. Chapter 6 reports that we found increased relative numbers of CD8+ T-cells in the FNAB-specimens compared to peripheral blood, suggesting an increased activity of CD8+ T-cells at the site of infection. Subsequently, we questioned whether we could use this parameter for prediction for response of antiviral

therapy with interferon-alpha. In our study, significantly more CD8+CD3+ T-cells were observed in pre-treatment FNAB of “rapid responders compared to ‘slow responders” to interferon alpha therapy. This suggests a higher absolute number of HCV-specific CD8+ T-cells in the liver and prominent role of CD8+ T-cells in the cellular response to HCV in the ‘rapid responders’.

#### Crucial role for dendritic cells in viral control in chronic viral hepatitis (chapter 7)

Dendritic cells act as a link between the innate and adaptive immune response. Signals from the innate immune system often lead to a proper maturation of DCs, which are critical for triggering the antigen-specific immune response. The ability of DCs to induce T-cell responses is influenced by their tissue localization and the viral load. Activation of CD8 T-cells in lymph nodes draining lymph from the site of infection occurs very rapidly and is mediated by DCs. Chronic hepatitis B or hepatitis C patients have impaired T-cell responses against these viruses. Given the important role played by DCs in T-cell priming, we raised the hypothesis that this immunological deficit may be due to impaired presentation of viral antigens by liver derived dendritic cells to T-cells in the hepatic lymph nodes. This may be due to an alteration of the DC function and/or maturation induced by the high viral load or even by infection of the DCs by HBV or HCV. In chapter 7, we quantified myeloid DC and plasmacytoid DC in immunohistochemical stainings of hepatic lymph node sections obtained from liver transplant recipients. The major finding in this study was that hepatic lymph nodes from patients with chronic HBV- or HCV infection contained significantly less mature myeloid DC, but similar numbers of immature myeloid DCs, plasmacytoid DC and IFN $\alpha$  producing cells compared to hepatic lymph nodes of patients with liver inflammation due to cholestatic liver diseases. This finding strongly suggests that viral chronicity may be associated with reduced numbers of mature myeloid DCs in hepatic lymph nodes causing an impaired anti-viral T-cell response and subsequently a deficient intrahepatic immune response.

## SAMENVATTING EN CONCLUSIES

### De intrahepatische immuun respons bij een chronische hepatitis B infectie (hoofdstuk 2 en 3)

Meer dan een derde van de wereldbevolking is geïnfecteerd met het hepatitis B virus (HBV) en wereldwijd zijn er ongeveer 350 miljoen mensen die persisterende dragers van het HBV zijn; 25% daarvan hebben een actieve chronische leverziekte en cirrose, die kan leiden tot hepatocellulair carcinoma. De jaarlijkse mortaliteit wordt geschat op een miljoen mensen wereldwijd, waardoor HBV een mondiaal gezondheidsprobleem is. Het is nog onbekend hoe een individu na infectie zich ontwikkelt tot een chronische drager van het HBV; een defect in het immuun systeem van de gastheer lijkt een belangrijke rol te spelen in de onderliggende pathogenese. Klaring van het HBV is geassocieerd met een gecoördineerde activatie van de cellulaire als well als de humorale onderdelen van de specifieke immuun respons dat uiteindelijk het virus onder controle houdt. Een juiste activatie van de niet-specifieke immuun respons is noodzakelijk voor een volledige ontwikkeling van een efficiënte antivirale specifieke immune respons.

De vroege responsen zijn niet-specifiek en bestaan uit secretie van type I IFN, infiltratie van Natural Killer (NK) en Natural Killer-T (NK-T) cellen, maturatie van dendritische cellen (DC) en activatie van Kupffer cellen. De niet-specifieke immuun respons is het eerste verdedigingsmechanisme tegen het virus en is nodig om een effectieve specifieke immuun respons in gang te zetten. De essentiële stap van een beschermende antivirale immuun respons is de eliminatie van intracellulair virus door de cellulaire respons. Er werd lang aangenomen dat dit bereikt werd door vernietiging van geïnfecteerde hepatocyten door cytotoxische T-lymfocyten (CTL).

Recent onderzoek heeft uitgewezen dat de cellulaire immuun repons het HBV kan verwijderen uit geïnfecteerde hepatocyten zonder deze te beschadigen, namelijk door secretie van antivirale cytokinen (IFN $\gamma$  en TNF $\alpha$ ) die de virale genexpressie en replicatie inhiberen en daarbij de HBV infectie genezen zonder leverschade. CD8+ CTL's zijn de voornaamste immuun-effector cellen in deze virale klaring.

De meerderheid van chronisch geïnfecteerde patiënten hebben een overleving van enkele tientallen jaren. Er lijkt een balans te ontstaan tussen leverschade en virale replicatie in deze patiënten, wat aangeeft dat zij in een fase van relatieve immuun controle van het virus verkeren.

Naast de CTL's dragen cellen van het niet-specifieke immuunsysteem, zoals macrofagen, Kupffer cellen, NK- en NK-T cellen bij aan de controle van het virus en aan veroorzaken weefselschade. De meeste beschikbare gegevens betreffende de cellulaire immuun respons tegen HBV zijn verkregen door studies van antivirale T-cellen in de circulatie van chronische HBV patiënten. Omdat de primaire infectie gelokaliseerd is in de lever zelf, hebben wij besloten om de intrahepatische immuun respons te bestuderen.

In hoofdstuk 2 hebben wij de balans tussen HBV en het immuun systeem van de chronisch geïnfecteerde patiënt bestudeerd. Een cross-sectionele immunohistochemische studie werd uitgevoerd met lever biopsieën van HBeAg-positieve en negatieve chronische HBV-patiënten, waarin wij de verbanden hebben bestudeerd tussen de aantallen intrahepatische immuun cellen enerzijds en virale replicatie en leverschade anderzijds. Wij vonden dat lage HBV replicatie en HBeAg-negativiteit geassocieerd waren met een verhoogd aantal intralobulaire CD8+ T-lymfocyten in lever biopsies. Dit suggereert een prominente rol van CTL's in de immuun gemedieerde controle van virale replicatie tijdens een chronische infectie. Of deze intrahepatische CD8 T-lymfocyten HBV-specifieke T-lymfocyten waren, hebben wij niet onderzocht, maar aanvullend onderzoek heeft wel aangetoond dat deze cellen in een geactiveerde status waren, weergegeven door de aanwezigheid van intracellulaire cytotoxische proteasen Granzym A en B.

In tegenstelling tot patiënten met een fulminante HBV infectie, maakten de intrahepatische CD8T-lymfocyten in de patiënten met chronische infectie geen antivirale cytokines. Afwezigheid van intrahepatische cytokine productie kan één van de oorzaken zijn van virale persistentie in deze patiënten.

NK (CD56+) en plasmacytoïde dendritische cellen (CD123+), de voornaamste producenten van IFN $\alpha$ , waren zeldzaam in de lever biopsieën, wat suggereert dat ze een beperkte rol hebben in chronische HBV infectie. Een interessante bevinding was de opregulatie van Fas-Ligand op Kupffer cellen van patiënten met inflammatoire leverschade. Dit suggereert dat Kupffer cellen bijdragen aan de virus geïnduceerde lever schade.

In hoofdstuk 3 hebben wij onderzocht of de aantallen CD8+ T-lymfocyten die voorafgaand aan antivirale therapie met IFN $\alpha$ , aanwezig zijn in de lever van chronische HBV-patiënten, gerelateerd zijn aan de respons op deze therapie. Wij vonden allereerst, dat in lever biopsieën die genomen waren voorafgaand aan de behandeling, de aantallen intrahepatische CD8+ T-lymfocyten hoger bij waren responders dan bij nonresponders. Ten tweede, dat de CD8+ T-lymfocyten in de lever significant afnamen tijdens de therapie bij responders, maar stabiel bleven in aantal bij de nonresponders. De derde interessante bevinding was dat cytoplasmatisch HBcAg-expressie in hepatocyten significant was geassocieerd met hogere aantallen intrahepatische CD8+ T-lymfocyten in de biopsieën. CD8+ T-lymfocyten en cytoplasmatisch HBcAg vertoonden co-localisatie. Dit suggereert dat deze CD8+ T-lymfocyten hun antivirale activiteit uitoefenen op de plaats van maximale virus replicatie, en dat dit resulteert in complete eliminatie van met HBV geïnfecteerde hepatocyten aan het einde van therapie.

Deze bevindingen suggereren dat bij responders de voorafgaand aan therapie in de lever geïnfiltrerde CD8+ T-lymfocyten complete virale eliminatie begunstigen tijdens antivirale therapie. Vervolgstudies moeten uitwijzen of de CD8+ T-lymfocyten die intralobulair aanwezig zijn aan het einde van de therapie HBV-specifieke T-lymfocyten zijn die het virus controleren.

Met betrekking tot beleid voor antivirale therapie, laten onze resultaten zien dat aantallen intrahepatische CD8+ T-lymfocyten voorspellend zijn voor de kans op respons.

## De intrahepatische immuun respons bepaald met de Dunne-Naald aspiratie biopsie tijdens behandeling van chronische HBV patiënten (hoofdstuk 4 en 5)

De intrahepatische cellulaire immuun respons tijdens chronische HBV infectie kan met de traditionele lever biopsie techniek af en toe onderzocht worden, maar niet frequent vanwege de risico's en het ongemak. Succesvolle therapie voor chronische HBV infectie bestaat uit immuunmodulatie (interferon alfa) of directe inhibitie van virale replicatie met nucleoside analogen. Echter, het is tot op heden niet bekend waarom een deel van de chronische HBV patiënten niet respondeert op deze behandelingen. Longitudinaal onderzoek van de intrahepatische immuun respons tijdens de novo infectie of behandeling van een chronische HBV infectie is tot op heden nog niet uitgevoerd, omdat dit belemmerd werd door de afwezigheid van een alternatief voor de leverbiopsie.

In Hoofdstuk 4 introduceren wij de dunne naald aspiratie biopsie (fine-needle aspiration biopsie; FNAB) als een patiënt vriendelijker alternatief voor frequente monitoring van de intrahepatische immuun respons tijdens therapie bij patiënten met een chronische HBV infectie. Aan deze techniek zijn nagenoeg geen risico's verbonden. De FNAB-techniek bleek sensitief genoeg om een stijging van CD8+ T-lymfocyten in de lever te meten tijdens ALT-flares in drie chronische HBV patiënten. Bij één patiënt werd tevens een stijging van CD4+ T-helper lymfocyten in de FNAB waargenomen, die werd gevolgd door een blijvende HBeAg-seroconversie. Dit betekent dat de T-lymfocyten verkregen door middel van de FNAB-techniek antivirale activiteit weergeven tijdens de therapie.

Vervolgens pasten wij de FNAB-techniek toe in een groot cohort chronische HBV patiënten om te onderzoeken welke intrahepatische mechanismen van CD8+ T-lymfocyten betrokken zijn bij virale klaring tijdens antivirale therapie. In de studie beschreven in hoofdstuk 5 werden CD8+ T-lymfocyten met IFN $\gamma$  en granzymes gekwanificeerd in FNAB die longitudinaal tijdens antivirale therapie met IFN $\alpha$  werden genomen. Deze markers representeren de twee mechanismen van antivirale activiteit van CTL's. De eerste conclusie uit deze studie was dat er een significante stijging van CD8+ T-lymfocyten was in de lever, maar niet in perifeer bloed tijdens antivirale therapie. Dit gegeven ondersteunt het concept dat er een predominant immuun respons tegen HBV aanwezig is op de plaats van replicatie en niet in perifeer bloed. Ten tweede werd bij responders op antivirale therapie een significante stijging van het aantal CD8+ T-lymfocyten waargenomen in de FNAB tijdens behandeling, welke afwezig was bij non-responders. Deze therapie geïnduceerde respons bestond uit stijgingen van zowel CD8+ T-lymfocyten die granzyme B bevatten als CD8+ T-lymfocyten die IFN $\gamma$  tot expressie brachten. De voornaamste conclusies van deze studie waren dat er een prominente intrahepatische CD8+ T-lymfocyt respons aanwezig was bij responders op antivirale therapie en niet bij non-responders en dat zowel cytolytische als non-cytolytische mechanismen betrokken zijn bij de anti-virale respons tijdens therapie met IFN $\alpha$ .

## De intrahepatische immuun respons bepaald met FNAB in relatie tot behandeling van chronische HCV-infectie (hoofdstuk 6)

Meer dan zeventig procent van volwassenen die geïnfecteerd zijn met het hepatitis C virus (HCV) ontwikkelt een chronische infectie. Men heeft voorgesteld dat, evenals bij HBV-infectie, de opbouw van een efficiënte cellulaire immuun respons het voornaamste mechanisme is voor HCV controle en dat een deficiënte immuun respons leidt tot chroniciteit van de infectie. Op basis van onze ervaring met het gebruik van de FNAB-techniek bij chronische HBV patiënten, hebben wij de FNAB gevalideerd voor het detecteren van intrahepatische CD8+ T-lymfocyten bij chronische HCV patiënten, door vergelijking met materiaal verkregen middels een standaard lever biopsie.

Hoofdstuk 6 geeft weer dat de relatieve aantallen CD8+ T-lymfocyten in FNAB materiaal van patiënten met chronische HCV-infectie significant gecorreleerd waren met de aantallen CD8+ T-lymfocyten in lever biopsieën. In de tweede plaats vonden we dat de CD8+/CD3+ T-lymfocyt ratio in FNAB gelijk was aan die in portale gebieden van de lever, maar hoger dan in met perifeer bloed. Vervolgens hebben wij ons afgevraagd of we deze parameter kon worden gebruikt voor predictie van kans op respons op antivirale therapie met interferon alfa. In onze studie werd een significant hogere ratio CD8+/CD3+ T-lymfocyten geobserveerd in FNAB genomen voorafgaand aan behandeling bij "snelle responders" ten opzichte van "langzame responders" op interferon alfa therapie. Dit suggereert een prominente rol van CD8+ T-lymfocyten in de door therapie geïnduceerde respons tegen HCV bij "snelle responders".

## Cruciale rol voor dendritische cellen bij virale controle in chronische virale hepatitis (hoofdstuk 7)

Dendritische cellen fungeren als een verbinding tussen de niet-specifieke en specifieke immuun respons. Signalen vanuit het niet-specifieke immuun systeem dragen bij aan een adequate maturatie van DC's, die belangrijk is voor het initiëren van de antigeen-specifieke immuun respons. De mogelijkheid van DC's om T-cel responsen te induceren wordt beïnvloed door hun weefsel lokalisatie en waarschijnlijk ook door de virale load.

Activatie van CD8+ T-lymfocyten geschiedt in lymfe-drainerende lymfeklieren in de regio van infectie door DC's. Chronische hepatitis B en C patiënten hebben een verzwakte T-cel respons tegen deze virussen. Door de belangrijke rol van DC's in het proces van T-cel priming, vroegen we ons af of deze immunologische tekortkoming een gevolg is van een verzwakte presentatie van virale antigenen opgenomen door DC's in de lever aan de T-cellen in de hepatische lymfeklieren. Dit kan het gevolg zijn van een verandering in de functie en/of in de maturatie van DC's geïnduceerd door een hoge virale load of zelfs door infectie van de DC's zelf door HBV en HCV.

In hoofdstuk 7 hebben wij de myeloïde en plasmacytoïde DC's gekwantificeerd door middel van immunohistochemische kleuringen van hepatische lymfeklieren verkregen van levertransplantatie patiënten. De voornaamste bevinding in deze studie was dat hepatische lymfeklieren van patiënten met een chronische HBV en HCV infectie significant minder

mature myeloïde, maar hetzelfde aantal immature myeloïde, en plasmacytoïde DC's bevatten vergeleken met lymfeklieren van patiënten met inflammatie ten gevolge van cholestatische leverziekten. Tevens was het aantal IFN $\alpha$  producerende cellen gelijk. Dit resultaat suggereert sterk dat chroniciteit van deze virale infecties het gevolg is van verlaagde aantallen mature myeloïde DC's in hepatische lymfeklieren wat een verzwakte antivirale T-cel respons veroorzaakt en vervolgens een deficiënte immuun repons in de lever.



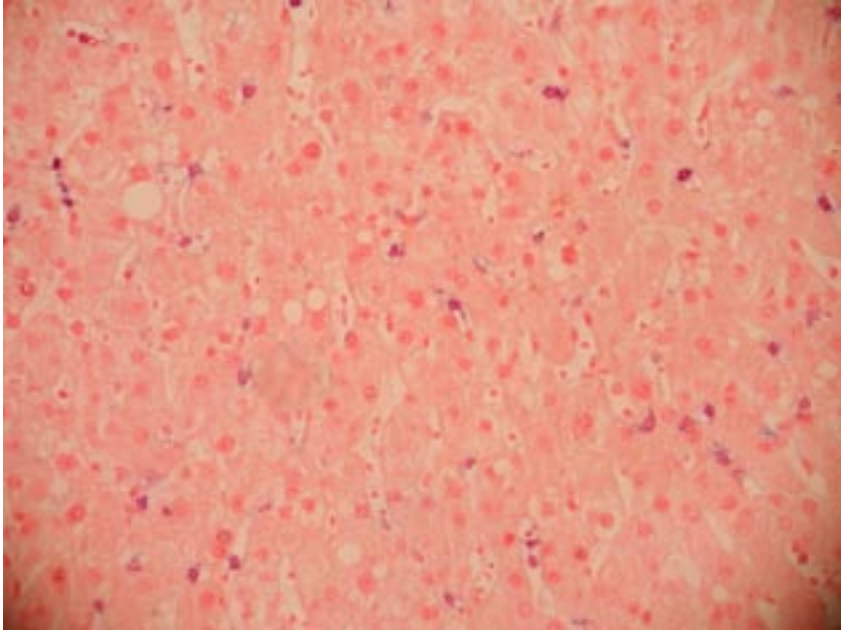


## Appendix

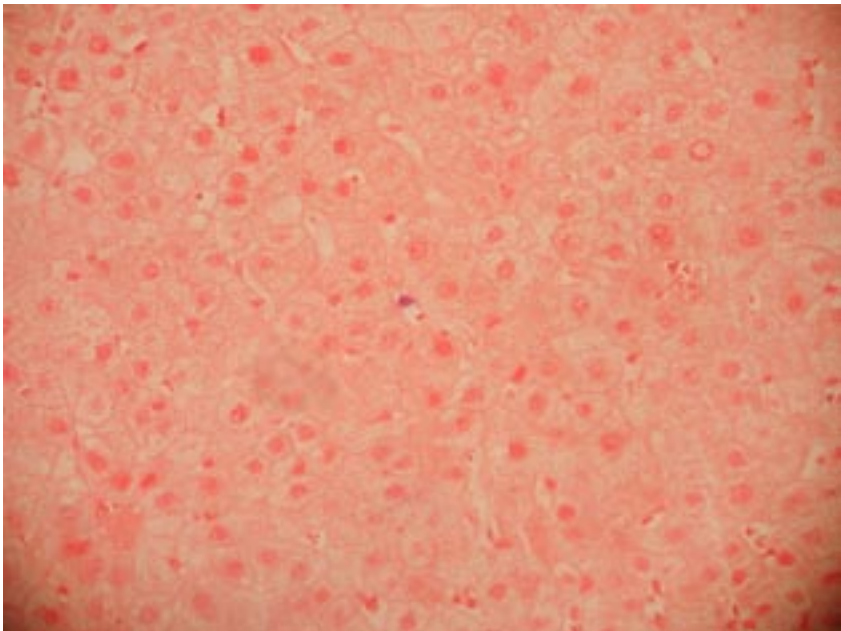


## CHAPTER 2

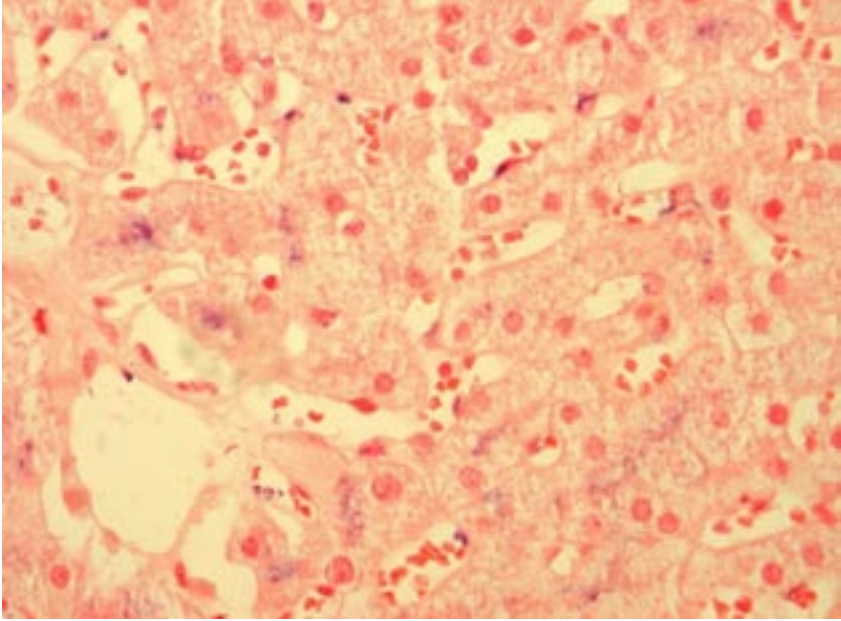
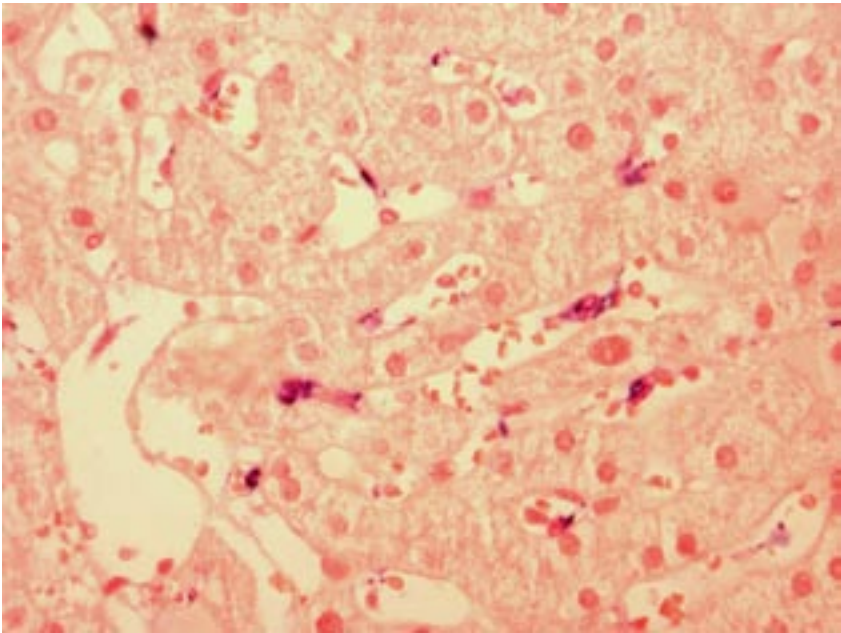
A



B

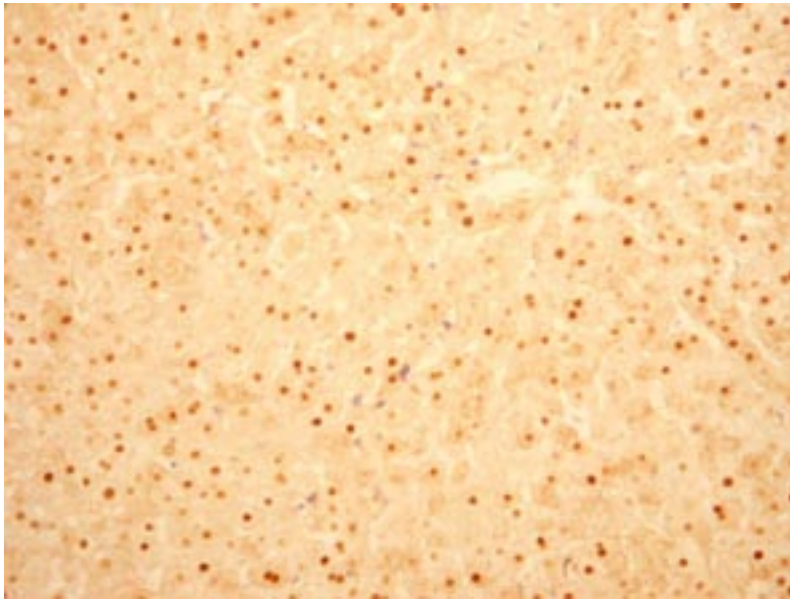


**Figure 2.** Liver biopsy sections immunohistochemically stained with CD8 mAb from chronic HBV patient with normal (A) and raised ALT (B) ( $\times 400$ )

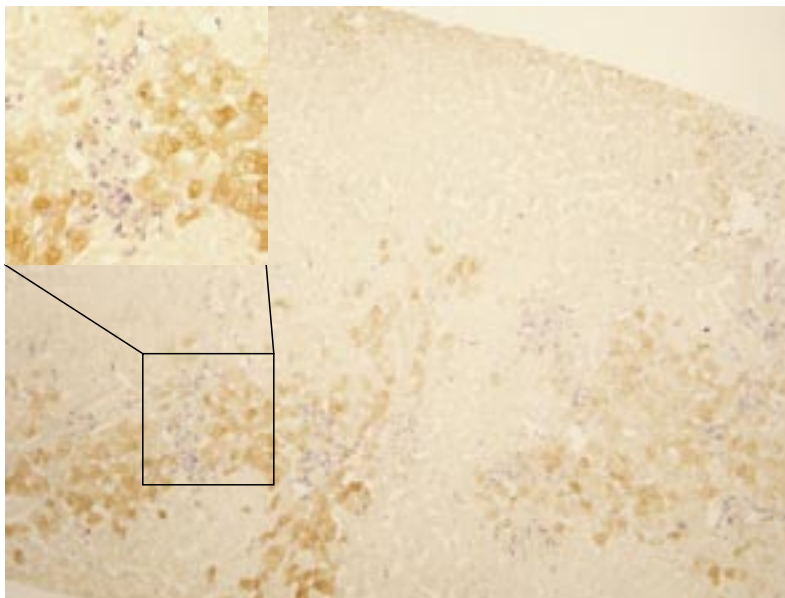
**A****B**

**Figure 4.** Consecutive liver biopsy sections immunohistochemically stained with Fas-L mAb (a) or CD68 mAb (b), showing that Fas-L is expressed predominantly on Kupffer cells ( $\times 400$ )

## CHAPTER 3



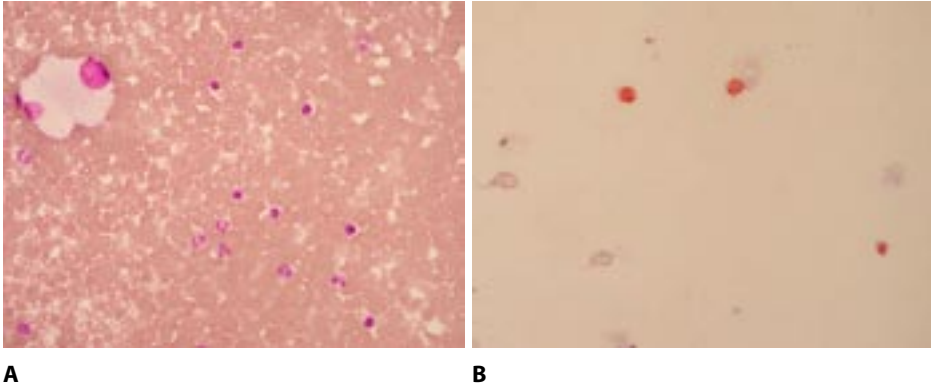
A



B

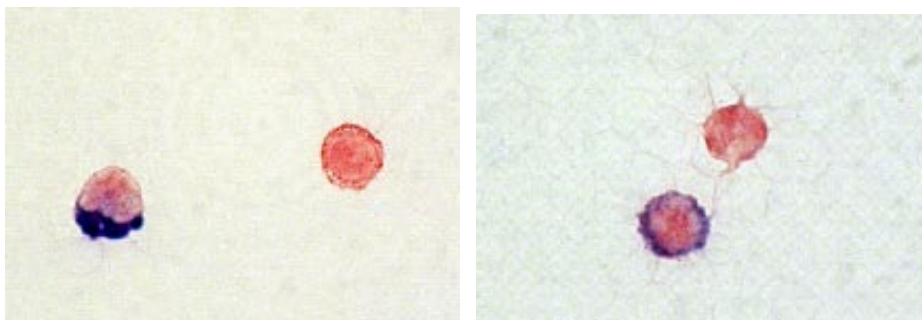
**Figure 1.** Immuno double-stain of HBcAg and CD8 T-lymphocytes (brown=HBcAg; CD8 T-lymphocytes=blue). Scattered nuclear expression of HBcAg and CD8 T-lymphocytes (original magnification  $\times 200$ ) (A). Clustered cytoplasmic expression of HBcAg (original magnification  $\times 100$ ) and co-localisation of cytoplasmic HBcAg and CD8 T-lymphocytes (inserted left, original magnification  $\times 200$ ) (B).

## CHAPTER 4



**Figure 1.** A: May-Grünwald-Giemsa-stained cytopsin preparation of a FNAB obtained during a hepatitis flare containing many lymphocytes. The large cells are hepatocytes. B: Immunocytochemical CD8-stain (red) of a FNAB cytopsin preparation obtained during a hepatitis flare.

## CHAPTER 5

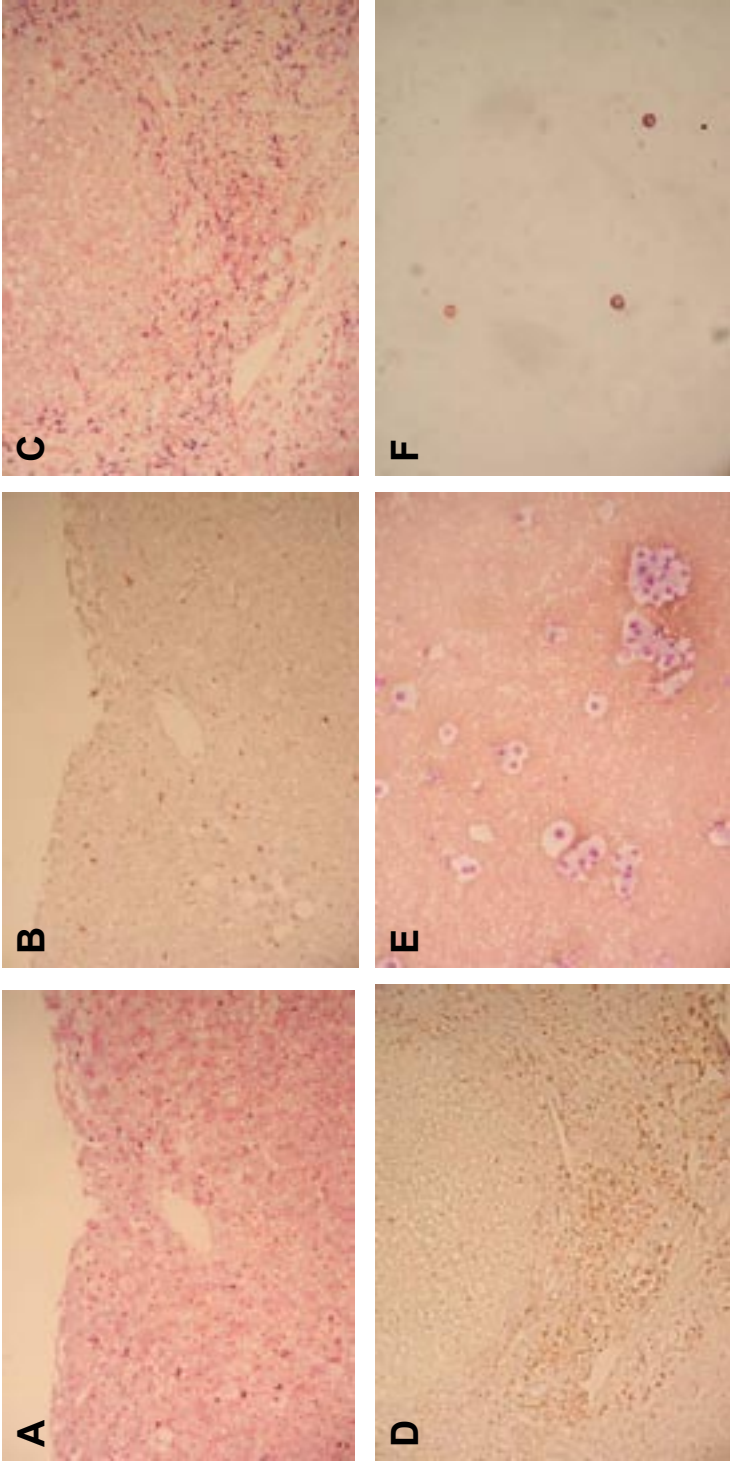


A

B

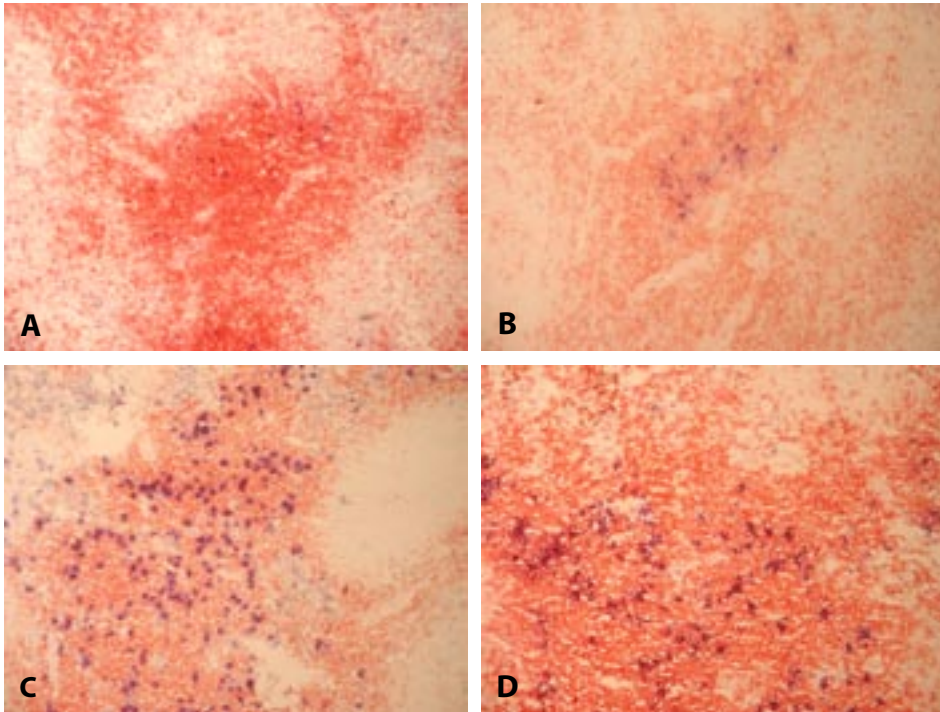
Figure 1. Immunocytochemical double-stains of CD8 and GrB (A) ( $\times 1000$ ) and of CD8 and IFNg (B) ( $\times 600$ ) on FNAB cytopins.



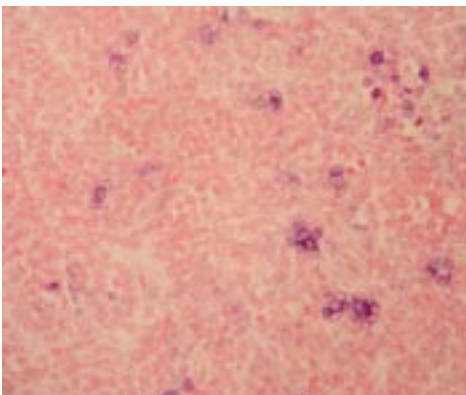


**Figure 1.** Immunohistochemical CD8 (A) and CD3 (B) stainings of lobular fields and CD8 (C) and CD3 (D) stainings of portal tracts in consecutive slides of a formalin-fixed and paraffin-embedded liver tissue biopsy. Fine-needle aspiration biopsy preparations stained with May-Grunwald-Giemsa solution (E), or immunocytochemically for CD3 (red) and CD8 (blue) (F).

## CHAPTER 7



**Figure 1.** Cryosections of hepatic LN from patients with chronic HBV-infection (A), chronic HCV-infection (B), and PBC (C), and from an organ donor (D) immunohistochemically double-stained for T-cells (CD3) in red and for mature MDC (anti-DC-Lamp) in blue. The red-coloured areas represent the paracortex. Non-coloured areas are B-cell follicles or medulla. Note that HEVs are colourless too.



**Figure 3.** Immunohistochemical staining of IFN- $\alpha$  in a hepatic LN of a PSC-patient.



## DANKWOORD

Dit proefschrift is tot stand gekomen in samenwerking met veel gemotiveerde mensen. Daarom zou ik graag een aantal mensen persoonlijk willen bedanken.

In de allereerste plaats gaat mijn dank uit naar Professor Schalm. Hij heeft mij de ruimte gegeven om basale research te verrichten op het gebied van virale hepatitis. Focus en visualisatie waren de kernwoorden van uw begeleiding.

Beste Harry, al heel vroeg heb je mij geïntroduceerd in de wetenschap. Een logisch vervolg was een promotieonderzoek onder jouw supervisie. Veel dank dat je mijn begeleider en mijn mentor bent geweest. Jouw enthousiasme en gedrevenheid de afgelopen jaren resulteerden vaak in werkbesprekingen 's avonds bij jouw thuis en in de weekenden, waarbij ik op een prettige manier kennis maakte met de familie Janssen. Ik zie er naar uit onze samenwerking voort te zetten.

Beste Jaap, veel dank dat je mijn begeleider bent geweest vanaf het begin tot aan het einde naast je drukke werkzaamheden op de transplantatiegeneeskunde. Jij hebt mij veel wetenschappelijk bijgebracht, maar daarnaast was je er altijd voor een intermezzo over de ups en downs die bij een onderzoek als dit horen.

Hans Kusters dank ik voor de interesse in mijn onderzoek en later als begeleider van enkele studies. Jij hebt de gave om het overzicht te houden in de stimulerende discussies tussen Harry en Jaap en na afloop de essentie voor mij in een korte zin samen te vatten.

Rob de Man dank ik hartelijk voor de adviezen en de initiatie van een studie beschreven in dit proefschrift.

Van Jon Laman kreeg ik de mogelijkheid om de eerste cytokinekleuringen uit te voeren op levermateriaal. Marjan van Meurs, bedankt voor je gastvrijheid op het laboratorium.

Bert Niesters en Suzan Pas waren onmisbaar in het kader van serologische nabepalingen voor mijn onderzoek, waarvoor dank.

Pieter Zondervan ben ik erkentelijk voor een cursus microscopisch beoordelen van hepatitis preparaten.

Luc Nelemans dank ik voor de grote hoeveelheid werk die hij heeft verzet in het snijden van de leverbiopten. Je weet nu waarvoor het materiaal heeft gediend.

Het secretariaat van de SLO wil ik bedanken voor alle administratieve handelingen die bij een promotieonderzoek horen. Marion dank ik voor alle werkzaamheden in het laatste traject.

Alle collega's van het laboratorium MDL dank ik hartelijk voor de jarenlange samenwerking en de prettige werksfeer: ik kom terug.

Mijn kamergenoten Rudy Sital, Dave Sprengers en Dorine Bax wil ik bedanken voor de gezellige tijd in ons "hok" L-477. We hebben samen veel gelachen, maar ook veel teleurstellingen gedeeld. Het gaat jullie goed!

Alle research-assistenten wil ik danken voor hun gezelschap en collegialiteit de afgelopen jaren en met name zal ik de culinaire avonden missen.

De medewerkers van de Clinical Research Unit en de scopieerafdeling: hartelijk dank voor alle medewerking ten aanzien van de afname van FNAB's en het extra FNAB bloedje.

Collega's uit het Albert Schweitzer Ziekenhuis dank ik voor hun steun en collegialiteit het afgelopen jaar. Ik hoef me nooit meer te verontschuldigen voor mijn afwezigheid op de woensdagmiddagen. Dr. A. C. M. van Vliet dank ik voor zijn medewerking.

Mijn ouders dank ik voor het vertrouwen die ze in mij hadden. Met een gedegen opvoeding ben ik de persoon geworden die ik nu ben.

Beste Dave en Mathieu, beide aanvankelijk mijn tegenpolen, maar later collega en vriend geworden. Bedankt dat jullie mijn paranimfen willen zijn op deze dag.

Lieve Sahn, met jouw steun en interesse heb ik dit proefschrift afgemaakt. Veel avonden en weekenden heb jij met mij doorgebracht achter de PC. Na deze beproeving hoop ik meer tijd te hebben om onze toekomstplannen te realiseren.

## CURRICULUM VITAE

De auteur van dit proefschrift werd geboren op 12 september 1969 te Rotterdam. Na het behalen van zijn V.W.O. diploma in 1989 aan de Libanon Scholen Gemeenschap in Rotterdam studeerde hij van 1990 tot en met 1999 geneeskunde aan de Erasmus Universiteit te Rotterdam. Zijn studie werd tijdelijk onderbroken voor een onderzoek op de afdeling Gastroenterologie van de Mayo Clinic (Rochester, Minnesota, U.S.A.) naar de voorspellende waarde van histologie in de overleving van patiënten met het Budd-Chiari syndroom (supervisie: dr. P.C. de Groen en dr. H. L. A. Janssen). Na terugkomst heeft hij zijn studie vervolgd en werd het artsexamen in 1999 afgelegd. Aansluitend aan het artsexamen werkte hij van 2000 tot en met 2003 als arts-onderzoeker op het laboratorium van de afdeling Maag-, Darm- en Leverziekten (hoofd dr. J.G. Kusters) van het Erasmus MC te Rotterdam. Onder dagelijkse leiding van dr. J. Kwekkeboom en dr. H. L. A. Janssen werden de experimenten beschreven in dit proefschrift verricht (promotor: Prof. dr. S.W. Schalm). In 2003 werd gestart met de opleiding tot Maag,- Darm- en Leverarts in het Albert Schweitzer ziekenhuis te Dordrecht (opleiders: dr. A. C. M. van Vliet, later Prof. dr. E. J. Kuipers). Hij is gehuwd met Sahn Yuen.



**BIBLIOGRAPHY**

- Tang TJ, Janssen HL, van der Vlies CH, de Man RA, Metselaar HJ, Tilanus HW, de Marie S. Aspergillus osteomyelitis after liver transplantation: conservative or surgical treatment? *Eur J Gastroenterol Hepatol* 2000;12:123-6
- Van der Vlies CH, Tang TJ, Niesters HG, Zondervan PE, Janssen HL, de Man RA. Acute hepatitis C infection: an indication for alfa interferon therapy? *Neth J Med* 2000;57:30-3.
- Tang TJ, Batts KP, de Groen PC, van Hoek B, Haagsma EB, Hop WC, Janssen HL. The prognostic value of histology in the assessment of patients with Budd-Chiari syndrome. *J Hepatol* 2001;35:338-43
- Tang TJ, Kwekkeboom J, Laman JD, Niesters HG, Zondervan PE, de Man RA, Schalm SW, Janssen HL. The role of intrahepatic immune effector cells in inflammatory liver injury and viral control during chronic hepatitis B infection. *J Viral Hepat* 2003;10:159-67
- Tang TJ, Janssen HL, Kusters JG, de Man RA, Schalm SW, Kwekkeboom J. The intrahepatic immune response during chronic hepatitis B infection can be monitored by the fine-needle aspiration biopsy technique. *FEMS Immunol Med Microbiol* 2003;39:69-72
- Tang TJ, de Man RA, Kusters JG, Kwekkeboom J, Hop WC, van der Molen RG, Schalm SW, Janssen HL. Intrahepatic CD8<sup>+</sup>T-lymphocytes and HBV core expression in relation to response to antiviral therapy for chronic hepatitis B patients. *J Med Virol* 2004;72:215-22
- Tang TJ, Vrolijk JM, Kwekkeboom J, Haagsma BL, Herscheid AJ, Kusters JG, Janssen HL, Brouwer JT, Schalm SW. Monitoring intrahepatic CD8<sup>+</sup> T-cells by fine-needle aspiration cytology in chronic hepatitis C infection. *J Viral Hepat* 2004;11:342-348





**ABBREVIATIONS**

ALT	alanine aminotransferase
anti-HBe	antibody against HBeAg
cccDNA	covalently closed circular DNA
CI	confidence interval
CTL	cytotoxic T lymphocyte
DC	dendritic cell
DNA	desoxyribonucleic acid
Fas-L	Fas-Ligand
FNAB	fine needle aspiration biopsy
Geq	genome equivalents
HBcAg	hepatitis B core antigen
HBeAg	hepatitis B envelop antigen
HBsAg	hepatitis B surface antigen
HBV	hepatitis B virus
HCV	hepatitis C virus
HDV	hepatitis D virus
HIV	human immunodeficiency virus
IFN- $\alpha$	interferon-alpha
IFN- $\gamma$	interferon-gamma
IL	interleukin
IU	international units
LN	lymph node
mAb	mouse antibody
MDC	myeloid dendritic cell
MU	mega-units
NK cell	natural killer cell
PB	peripheral blood
PBC	primary biliary cirrhosis
PCR	polymerase chain reaction
PDC	plasmacytoid dendritic cell
PEG	pegylated
PSC	primary sclerosing cholangitis
RNA	ribonucleic acid
SD	standard deviation
SEM	standard error of mean
TNF- $\alpha$	tumor necrosis factor-alpha

