

EUR Research Information Portal

Molecular and biological studies on *Madurella mycetomatis* infection in man and mice

Publication status and date:

Published: 17/12/2003

Document Version

Publisher's PDF, also known as Version of record

Citation for the published version (APA):

Ahmed, AOA. (2003). *Molecular and biological studies on Madurella mycetomatis infection in man and mice*. [Doctoral Thesis, Erasmus University Rotterdam]. Erasmus Universiteit Rotterdam (EUR).

[Link to publication on the EUR Research Information Portal](#)

Terms and Conditions of Use

Except as permitted by the applicable copyright law, you may not reproduce or make this material available to any third party without the prior written permission from the copyright holder(s). Copyright law allows the following uses of this material without prior permission:

- you may download, save and print a copy of this material for your personal use only;
- you may share the EUR portal link to this material.

In case the material is published with an open access license (e.g. a Creative Commons (CC) license), other uses may be allowed. Please check the terms and conditions of the specific license.

Take-down policy

If you believe that this material infringes your copyright and/or any other intellectual property rights, you may request its removal by contacting us at the following email address: openaccess.library@eur.nl. Please provide us with all the relevant information, including the reasons why you believe any of your rights have been infringed. In case of a legitimate complaint, we will make the material inaccessible and/or remove it from the website.

ISBN 90-77595-05-8

No part of this thesis may be reproduced or transmitted in any form or by any means, electronic or mechanical, including photocopying or recording or any information storage and retrieval system without permission in writing from the author (Abdalla O. A. Ahmed, Department of Medical Microbiology, Faculty of Medical Laboratory Sciences, University of Khartoum, P. O. Box 11081, Khartoum, Sudan.

Printed by: Optima Grafische Communicatie, Rotterdam, The Netherlands
Cover design: Abdalla Ahmed

Molecular and biological studies on
Madurella mycetomatis infection in man and mice

Madurella mycetomatis infecties in mensen en muizen,
moleculaire en biologische studies

Thesis

to obtain the degree of Doctor from the
Erasmus University Rotterdam
by command of the
Rector Magnificus

Prof.dr. S.W.J. Lamberts

and according to the decision of the Doctorate Board
The public defense shall be held on

Wednesday 17th of December 2003 at 15:45 hrs

by

Abdalla Osman Abdalla Ahmed
born in Delft

Doctoral Committee

Promoters:

Prof.dr. H.A. Verbrugh
Prof.dr. A.H. Fahal
Prof.dr. dr. A. van Belkum

Other members:

Prof.dr. R. de Groot
Prof.dr. H.A.M. Neumann
Prof.dr. R. Benner

The studies described in this thesis were performed at the Department of Medical Microbiology and Infectious Diseases, Erasmus MC, Rotterdam, The Netherlands; Institute for Endemic Diseases, University of Khartoum, Sudan and the Centraal Bureau voor Schimmel Cultures, Baarn, The Netherlands.

Research described in this thesis as well as printing of the thesis was financially supported by the Department of Medical Microbiology and Infectious Diseases, Erasmus MC, Rotterdam, The Netherlands.

To mycetoma patients

CONTENTS

	Page
<i>Chapter 1</i>	Mycetoma and <i>Madurella mycetomatis</i> infection 9
<i>Chapter 2</i>	Development of a Species-Specific PCR-Restriction Fragment Length Polymorphism Analysis Procedure for the Identification of <i>Madurella mycetomatis</i> 27
<i>Chapter 3</i>	Molecular Detection and Identification of Agents of Eumycetoma: a Detailed Report of Two Cases 37
<i>Chapter 4</i>	Environmental Occurrence of <i>Madurella mycetomatis</i> , the Major Agent of Human Eumycetoma in Sudan 45
<i>Chapter 5</i>	Phylogeny and Typification of <i>Madurella mycetomatis</i> , with a Comparison of Other Agents of Eumycetoma 57
<i>Chapter 6</i>	<i>Madurella mycetomatis</i> Strains from Mycetoma Lesions in Sudanese Patients are Clonal 73
<i>Chapter 7</i>	A murine Model of <i>Madurella mycetomatis</i> Eumycetoma 83
<i>Chapter 8</i>	Assessment of In Vitro Susceptibility of <i>Madurella mycetomatis</i> to Itraconazole and Amphotericin B by a Modified NCCLS Method and a Viability-based XTT assay. 99
<i>Chapter 9</i>	General Discussion 111
<i>Summary</i>	117
Samenvatting	
Acknowledgement	
Curriculum vitae	
List of publications	

Chapter 1

Mycetoma and *Madurella mycetomatis* infection

Abdalla O. A. Ahmed

THE DISEASE MYCETOMA

Mycetoma is a chronic granulomatous infection caused by either true fungi or actinomycetes. Fungal mycetoma is known as "eumycetoma" while bacterial mycetoma is known as "actinomycetoma". A subcutaneous mass and multiples sinuses draining pus, blood and grains characterize the mycetoma lesion. Grains or "sclerotia" are aggregates of the fungal hyphae or the bacterial filaments sometimes embedded in hard cement-like material. The morphological characteristics of the grains may give a clue about the species nature of the possible causative agents (9). It is suggested that the infection starts subcutaneously after traumatic inoculation of the microorganisms, which are thought to live as saprophytes in soil and perhaps other natural ecological niches. The mycetoma infection has a prolonged and indolent course. The infection progresses slowly over a long period of time without painful manifestation. The mycetoma lesion may ultimately extend to the deep tissues and bones, leading to deformity of the affected site and subsequent disability. Mycetoma infection is not self-curing and, if untreated, always leads to massive lesions, which at the end necessitate surgical amputation. The disease is severely debilitating, especially the lesions that arise in the extremities (25). The socio-economic consequences of the disease are severe.

The first case of mycetoma was reported by Dr. John Gill as "Madura foot" in a dispensary report of the Madras Medical Service of the British Army in India 1842 (61). The existence of the disease was confirmed by Colebrook more than a century later in 1946. The term "mycetoma" was first used by Vandyke Carter in 1860 (61). However, it is certain that mycetoma has a prolonged history. Heshkovitz *et al.* in 1992 presented a skeleton of a woman who lived during the Byzantine period (300- 600 AD) with pathological changes in the low extremities. This case was proposed to be the oldest known case of mycetoma, but was later re-diagnosed as a case of leprosy after the molecular analysis of the bones (37, 65).

EPIDEMIOLOGY AND ETIOLOGY OF MYCETOMA

Mycetoma has a worldwide distribution, which is, however, extremely uneven. Mycetoma is endemic in tropical and subtropical regions and the African continent seems to be the area of the highest prevalence (Figure 1). Worldwide, mycetoma prevails in the mycetoma belt that stretches between the latitudes of 15° South and 30° North (9, 44). The belt includes Sudan, Somalia, Senegal, India, Yemen, Mexico, Venezuela, Columbia, Argentina and other countries (44, 46, 50). In Africa, mycetoma is most frequently seen in Sudan, Senegal, Mauritania, Kenya, Niger, Nigeria, Ethiopia, Chad, Cameroon, Djibouti and Somalia (1, 2, 5, 11, 17, 18, 43, 64). In Sudan, Abbot noted the admission of 1231 mycetoma cases to out-patient clinics throughout the country within a period of two and a half years (1). Lynch in 1964 gave an estimation of 300 - 400 new cases per year in Sudan (43). It has been extensively reported in India (8, 64). In addition, mycetoma has been reported in many temperate regions as well. Most of those cases were immigrants who probably contracted the infection in their home countries. This usually complicates the clinical diagnosis of this mycosis since it is frequently unexpected (15). There were reports on mycetoma from the United States, Ceylon, Germany, Egypt, Turkey, Philippines, Japan, Lebanon, Thailand, Iran, The Netherlands and Saudi Arabia (12, 15, 22, 24, 30, 40, 67).

Areas where mycetoma prevails are relatively arid with a short rainy season of 4-6 months. Rainfall is 50 to 1000 mm per year, with a relative humidity of 60-80% and fairly constant temperatures of 30-37°C for 24 hours a day. This is followed by a dry season of 6-8 months with a relative humidity of 12-18%, day temperatures rising to 45-60°C. Temperatures may fall to 15-18°C during the night (49). This alteration in extreme weather conditions may be a prerequisite to the survival of the causative organism in its natural niche.

Geographical distribution of the mycetoma causative agents shows considerable variations, which could be explained on these and other environmental factors, especially the rainfall (9, 49, 50). Many microorganisms are capable of causing mycetoma (Table 1). The most prevalent etiological agent of eumycetoma worldwide is *Madurella mycetomatis* (52). Most of the mycetoma cases in Africa are eumycetoma caused by *M. mycetomatis*. In some parts of central Africa, including Sudan, *M. mycetomatis* causes more than 70% of all mycetoma infections (9, 32).

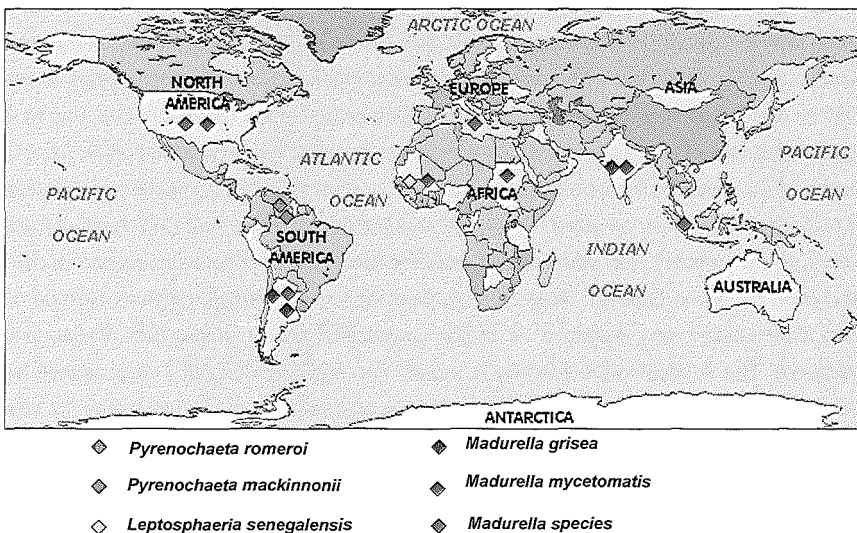


Figure 1: Map showing the geographical distribution of some eumycetoma agents.

SUSCEPTIBLE POPULATION AND RISK FACTORS

All people living in the endemic area can be infected, but the infection is more common in herdsmen, farmers and other field laborers who have direct and frequent contact with the open environment. Males are five times more often affected by mycetoma than females, even in areas where both sexes engage in out-door activities (9, 28, 52). Mycetoma is seen in all age groups, but it usually affects adults between 20 and 40 years old (9, 28). Mycetoma is not considered to be transmissible from person to person or from animal to person.

There are some conflicting reports about the role of the immune status of the susceptible population. Some investigators reported partial impairment of the cell-mediated immune response in patients

severely infected or not responding to medical treatment (48). In animals, some evidence supporting this hypothesis was reported, e.g. the more successful induction of mycetoma in athymic mice as opposed to immunocompetent mice (45). The more rapid progression of induced mycetoma in immunosuppressed goats in comparison to normal goats provided another pivotal evidence (33). In contrast, Bendl et al. did not observe a similar phenomenon (7). The humoral immune response has been evaluated by Wethered and his colleagues using an ELISA system (71). High IgM levels have been demonstrated in the majority of the patients with mycetoma due to *M. mycetomatis*, whereas low levels of IgA were detected in some of the patients (71). Sera from patients reacted better in ELISA in comparison to Western blots, indicating possible involvement of immunogenic polysaccharide antigens in *M. mycetomatis* infection (71). Immunoglobulin M and G and complement have been demonstrated on the surface of the grains and on the filaments inside the grains in case of actinomycetoma (21).

CLINICAL PRESENTATION

Mycetoma initially presents as a slowly progressive and painless subcutaneous swelling, sometimes in combination with a history of preceding trauma (9, 52). However, the incubation time before classical signs develop is not well-defined. The first symptoms may require several months to years to develop. Investigations are complicated by the fact that most of the patients tend to present late, due to lack of clinical symptoms, lack of accessible health care facilities, or due to fear of amputation (9, 52, 61).

The duration of the disease, the type of causative organism, the site of the infection and possibly the immune response of the host, all affect the clinical presentation of mycetoma (28). However, patients with a short disease history may present with massive lesions and severe destruction of the deep tissue and even bones. In contrast, others may present with minor localized lesions existing already for a long time without any evidence of major progressive tissue destruction (Fahal, personal communication). The subcutaneous swelling is usually firm and rounded but it may as well be soft, lobulated. It is rarely cystic, but often mobile. The subcutaneous nodule increases in size and secondary nodules may evolve as well (28). The nodules may suppurate and drain through multiple sinus tracts and these sinuses may close transiently after discharge during the active phase of the disease. Fresh adjacent sinuses may open while some of the old ones may heal completely. The nodules are connected with each other, through deep sterile abscesses and with the skin surface (9, 28).

Mycetoma can affect any body site, not only the feet and the lower limbs (figure 2). Most of the cases are usually seen in the feet (70%), followed by hands (12%), then legs and knee joints. In highly endemic areas other parts of the body may be involved as well. These include the arm, head and neck, thighs and the perineum. Rare sites such as the chest and abdominal walls, facial bones, mandible, paranasal sinuses, eyelid, vulva, orbit, scrotum and old surgical incisions may be affected (9, 28). Mycetoma spreads locally or through the lymphatic system and rarely haematogenously. Secondary nodules may arise in the affected area, sometimes in combination with lymphatic spread in some advanced cases. Secondary sites are seen more often in actinomycetoma than in eumycetoma (9). Mycetoma is usually painless in nature, and it has been suggested that the mycetoma lesion

produces substances that have an anesthetic effect (25). At a late stage of the disease the absence of pain may be due to nerve damage by the tense fibrous tissue reaction, endarteritis obliterans or poor vascularisation of the nerves alternatively. Pain at the end may be produced by invasion of the bone or it may be due to secondary bacterial infection (3, 28). As the mycetoma granuloma increases in size, the skin may become smooth, shiny and areas of hypo- or hyper-pigmentation may develop. Increased local hyperhidrosis was also seen in some of the patients (9, 25).

Table 1: Etiologic agents of eumycetoma and actinomycetoma grouped by appearance of typical intralesional grains.

Eumycotic mycetoma	Color of grains	Actinomycotic mycetoma	Color of grains
<i>Acremonium falciforme</i>	White	<i>Streptomyces somaliensis</i>	Yellow to brown
<i>Acremonium kiliense</i>	White	<i>Actinomadura madurae</i>	White to yellow or pink
<i>Acremonium recifei</i>	White	<i>Actinomadura pelletieri</i>	Red
<i>Cylindrocarpon cyanescens</i>	White	<i>Actinomyces israelii</i>	White to yellow
<i>Cylindrocarpon destructans</i>	White	<i>Nocardia asteroides</i>	White
<i>Pseudallescheria boydii</i>	White	<i>Nocardia brasiliensis</i>	White
<i>Fusarium oxysporum</i>	White	<i>Nocardia caviae</i>	White to yellow
<i>Fusarium solani</i>	White	<i>Nocardia farcinica</i>	White to yellow
<i>Fusarium moniliforme</i>	White	<i>Nocardia transvalensis</i>	White
<i>Hormonema</i> spp.	-	<i>Nocardia dassonvillei</i>	Cream
<i>Aspergillus flavus</i>	Green		
<i>Aspergillus nidulans</i>	White		
<i>Polycytella hominis</i>	White		
<i>Plenodomus avramii</i>	Black		
<i>Corynespora cassiicola</i>	Black		
<i>Curvularia geniculata</i>	Black		
<i>Curvularia lunata</i>	Black		
<i>Leptosphaeria senegalensis</i>	Black		
<i>Leptosphaeria thompkinsii</i>	Black		
<i>Madurella grisea</i>	Black		
<i>Pseudochaetosphaeronea larense</i>	Black		
<i>Pyrenochaeta mackinnonii</i>	Black		
<i>Pyrenochaeta romeroi</i>	Black		
<i>Madurella mycetomatis</i>	Black		
<i>Neotestudina rosatii</i>	White		
<i>Exophiala jeanselmei</i>	Black		
<i>Phialophora verrucosa</i>	Black		

* Based on references 32, 52, 58 and 61.

DIAGNOSIS OF MYCETOMA

The clinical triad of a subcutaneous mass, sinuses, and discharge containing grains observed in patients from an endemic area is diagnostic for mycetoma. Since a variety of other agents may cause mycetoma, it is important to identify the causative agent in order to develop a correct plan of treatment (reference 9 and table 2). However, the available strategies are few and with many limitations. Direct examination of grains may be useful in determining the type of mycetoma. Unlike fungal grains,

crushed bacterial grains show fine filaments, which can be stained according to Gram. Isolation of mycetoma agents can be difficult, especially in case of the actinomycetes. Culture requires deep surgical biopsies containing grains. Biopsies without grains are not suitable for diagnosis (20). The large numbers of causative organisms, the poor *in vitro* differentiation of fungi that cause mycetoma, complicate the identification process (15). Histopathology is useful for confirming the clinical diagnosis of mycetoma and in differentiation of most of bacterial causes of mycetoma (table 1). Histopathological examination is generally unable to differentiate fungi.

Few studies have focused on serology for early detection and monitoring patients under treatment (49, 55, 66). However, these tests are relatively crude and problems of cross reactivity between actinomycetes exist. Low sensitivity, and lack of standardized antigen preparations are the other remaining problems (personal observation). Fine needle aspiration cytology for mycetoma has also been described and is considered to be a useful technology (19). Radiology helps in the clinical diagnosis, especially in the follow-up of disease progression, development of a surgical strategy and for assessing the clinical cure (9, 28, 52).

MANAGEMENT OF MYCETOMA

Proper management of mycetoma strongly depends on the identification of the causative organism. Eumycetoma should be treated with adequate antifungal therapy and surgery. Actinomycetoma responds to antibacterial treatment and in a few cases surgery is indicated (9). Early cases are curable, but advanced cases are difficult to treat. Advanced mycetoma always requires long term antimicrobial treatment in combination with aggressive surgery (9, 27). The aim of surgery is complete excision of small, well-encapsulated lesions, or the reduction of the amount of infected tissue to be cured by chemotherapy. Surgery has some undesirable effects. In order to perform effective surgery one needs to undertake aggressive excision or debridement under general anaesthesia, which usually cripples the limb or otherwise leads to permanent disability. Performing surgery without a combination of effective medical treatment has a high rate of recurrence (up to 90%). Early cases with well-encapsulated lesions without bone involvement can be treated efficiently with surgery. In such cases, combination of medical treatment before and after surgery results in the most successful outcome (9, 27,52).

Figure 2: A: An early eumycetoma case; B: Eumycetoma lesion involving a lymph node containing numerous black grains; C: Massive mycetoma in the buttock; D: The second common site for mycetoma, the hand; E: Inguinal lymph node involvement after lymphatic spread; F and G: massive eumycetoma and actinomycetoma of the foot, respectively.

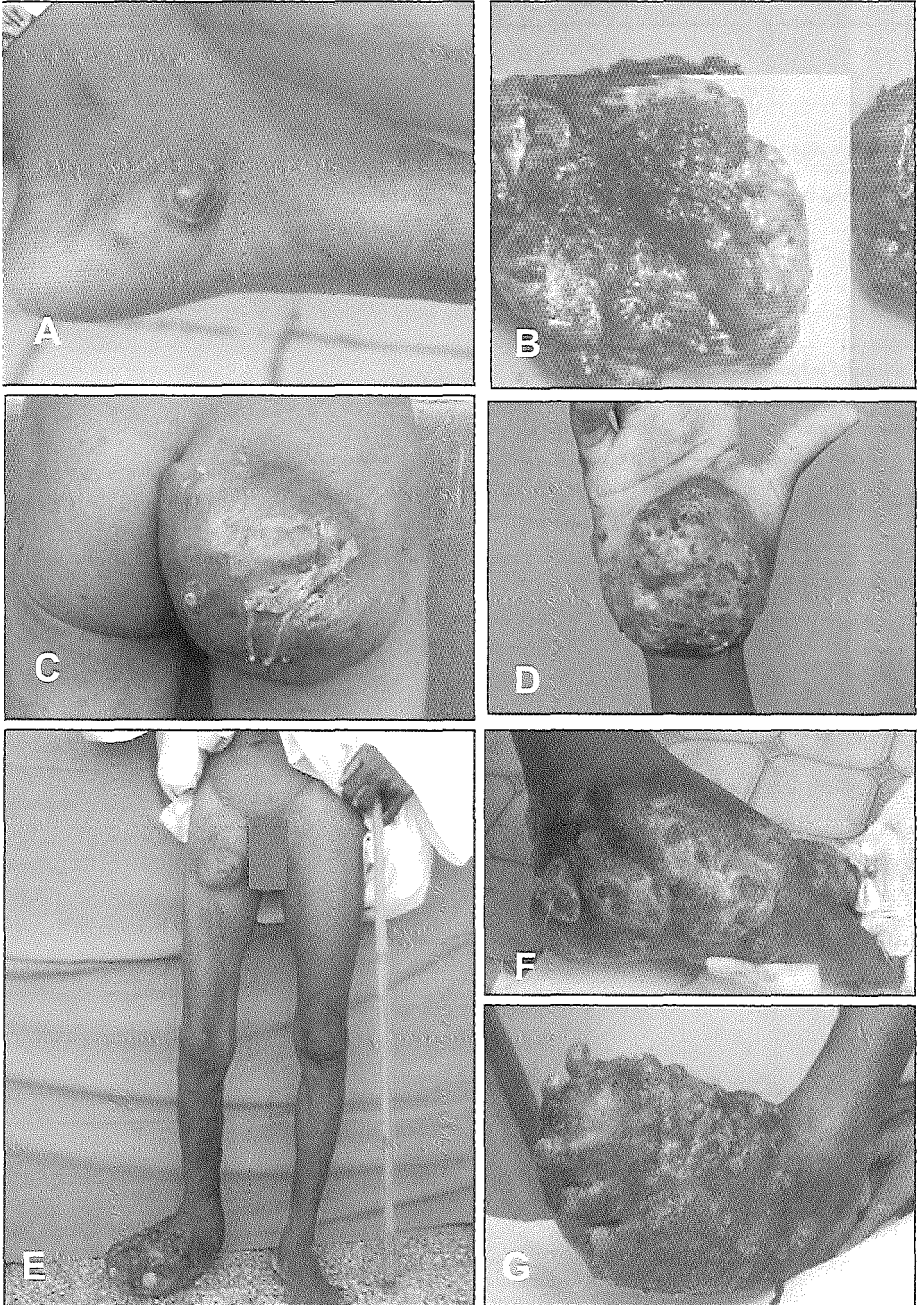


Table 2: The main clinical differences between eumycotic and actinomycotic mycetoma.

	Eumycetoma	Actinomycetoma
Causative agents	Fungi	Bacteria
Lesion characteristics	Well-encapsulated with a clear margin	Diffuse, no clear margin
Sinuses	Relatively few	Many
Color of grains	Different colors, but mostly white or black	Different colors, other than black
Course of infection	Slowly progressive	More inflammatory and rapid progression
Bone invasion	After a long time	Rapid
Cavities in X-ray	Small in number, but large in size with clear margins	Numerous, small in size (except in case of <i>Actinomadura madurae</i>) with unclear margins
Management		
Drug of choice	! Ketoconazole ! Itraconazole	! Dapsone + streptomycin ! Rifampicin or fansidar ! Amikacin + cotrimoxazole
Management of choice	! Both medical and surgical intervention required	! Only medical treatment is sufficient (in some advanced cases in combination with surgery)
Surgery only	! May cure small, well-encapsulated lesions ! Up to 90% recurrence in most cases	! Not indicated
Medical treatment only	! Partial cure or improvement ! Recommended before surgery to prevent local spread ! Needed after surgery to prevent recurrence	! Useful in most of cases
Most successful outcome	! Early diagnosis followed by adequate antifungal treatment in combination with surgery	! Early diagnosis followed by medical treatment for a sufficiently long period

THE GENUS *MADURELLA* AND ITS TWO SPECIES

The majority of the Sudanese eumycetoma are caused by the fungus *M. mycetomatis*. *Madurella* species in general are slow-growing fungi that produce dark colonies composed of a dense, melanized, and mostly sterile mycelium. *Madurella* species are well known agents of black-grain mycetoma. Two species are recognized, *M. mycetomatis* and *M. grisea* (16). Brumpt in 1905 replaced an organism described by Laveran 1902 as *Streptothrix mycetomi*, to the genus *Madurella*. The fungus was known as *Madurella mycetomi* for more than seven decades. In 1977, the British Research Council published Memorandum No. 23 (“Nomenclature of Fungi Pathogenic to Humans and Animals”) in which the name was corrected to *M. mycetomatis*. The name was corrected because the specific epithet must be in the genitive case (the *Madurella* of mycetoma). As the mycetoma is a Greek neuter noun, the correct citation is *mycetomatis* (41, 61).

In different culture media, *M. mycetomatis* shows various colonial morphologies (figure 3). The growth rate is moderate, and the colonies are white and woolly at first, becoming olivaceous, yellow, or brown, generally producing a brownish diffusible pigment. In poor media, sclerotia being 750 µm in diameter may develop (58). Colonies are mostly sterile, composed of dense melanized mycelium. No efficient sporulation has ever been observed. However, phialides with minute conidia in short chains and collarettes may be observed (16, 52, 58). Some investigators reported that better sporulation was observed when *M. mycetomatis* was cultured

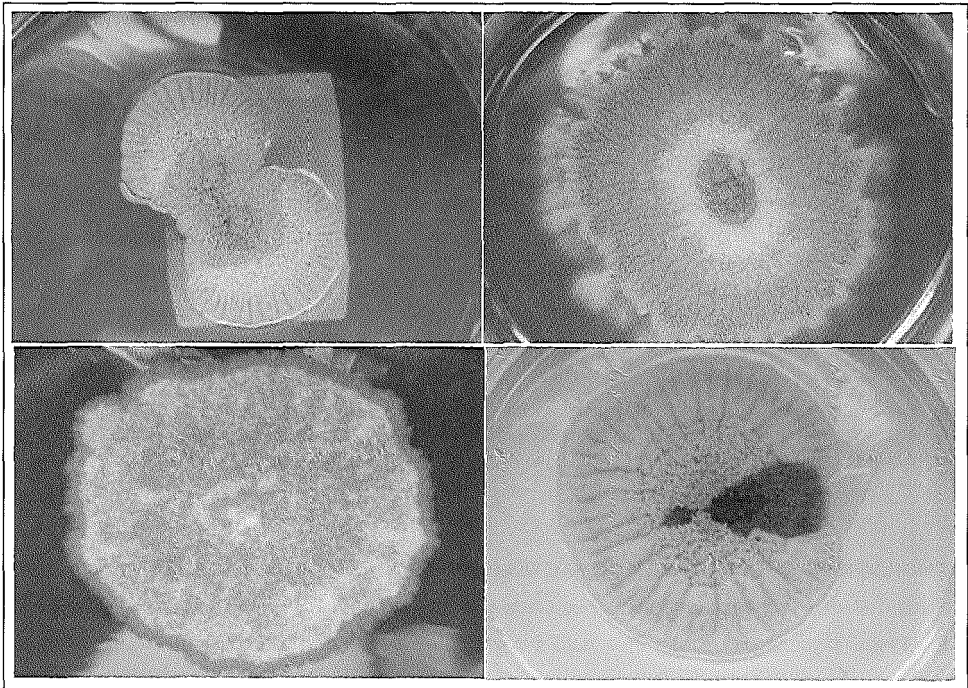


Figure 3: Cultures of *M. mycetomatis* clinical isolates on Sabouraud dextrose agar after 3 weeks incubation at 37° C.

in straw extract agar, wheat extract agar, soil extract agar, or water agar (41, 59). In most cases, the microscopic appearance of *M. mycetomatis* and *M. grisea* is quite similar. Both fungi show the sterile, dense by melanized mycelia. Some isolates of *M. grisea* were reported to form pycnidia. Such isolates are indistinguishable from *Pyrenochaeta mackinnonii* (58). Species-differentiation of *M. mycetomatis* and *M. grisea* can be made by differences in sugar assimilation and optimal growth temperature. *M. mycetomatis* assimilates lactose but not sucrose, while *M. grisea* assimilates the other way around. *M. mycetomatis* grows well at 37°C, while *M. grisea* does not grow at 37°C (growth obtained at 30°C) (16, 58). This may also explain the observed difference in virulence.

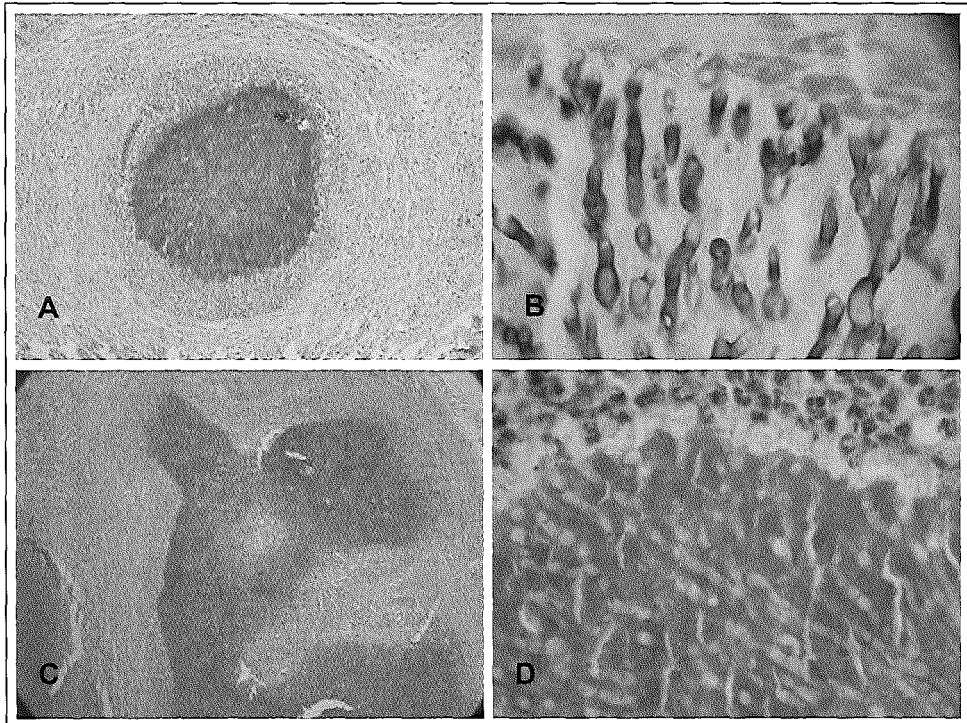


Figure 4: Histological sections of *M. mycetomatis* eumycetoma in a mammalian host. Slides A and C were stained with PAS staining (200x), slide C with Grocott methenamine silver stain (400x) and slide D with Hematoxylin and Eosin (350x).

PATHOLOGY OF *M. MYCETOMATIS* INFECTION AND ULTRASTRUCTURE OF THE LESION

In tissues, *M. mycetomatis* forms numerous black sclerotia (grains). Grains are vegetative aggregates of the fungal mycelia embedded in a hard brown matrix (reference 20 and figure 4). This matrix consists of extracellular cement that appears to be 1, 8-dihydroxynaphthalene melanin in combination with host tissue debris and a specific protein. This rigid matrix may act as a barrier protecting the fungus from the natural immunity of the host and antifungal agents (52). Melanin-like pigments in the

dimorphic fungal pathogen *Paracoccidioides brasiliensis* are detected in vitro and in vivo, suggesting a possible role in the pathogenesis of Paracoccidioidomycosis (31). The grains have different shapes and sizes. In stained sections, the grain is mostly rounded, oval or trilobed. Two types of grains are recognized, filamentous and, less commonly, vesicular ones. The filamentous type of grain consists of brown, septate and branched hyphae that may be slightly more swollen and thick towards the periphery of the colony (20, 26, 52). The vesicular type of grain, which is less common, has a cement-like matrix in the cortex and a central area filled with numerous vesicles (6-14 µm in diameter) and light-colored hyphae (58). Three types of tissue reactions around the grains have been described (26). In tissue reaction type 1, the grains are surrounded by three zones of inflammatory cells. An inner neutrophil zone immediately around the grain, an intermediate zone containing mainly macrophages, and an outer zone consisting of lymphocytes and plasma cells (20, 21, 26) (figure 4).

Studies on the ultrastructure of *M. mycetomatis* showed an elaborate development of mesosomes as the most striking ultrastructural feature (29). In tissue sections, the hyphae show a thick cell wall, which becomes thicker in the periphery of the grain (20, 25, 36). It appears that excessive production of polysaccharides in the fungal cell wall renders the fungus less susceptible to the action of antifungal agents and more resistant to the host immune system, due to possible interference with leukocyte interaction with specifically recognized cell wall antigens (35, 36, 70).

FUNGAL VIABILITY AND ANTIFUNGAL SUSCEPTIBILITY

The vegetative cells of *M. mycetomatis* die rapidly in conditions of moist heat (e.g. 60°C for 30 minutes) and are easily killed by 70% ethanol. Homogenized mycelia from fresh agar cultures survive well at 4°, -20° and -80°C for at least several weeks (unpublished data). Little is known about the in vitro and in vivo susceptibility of the fungus to different antifungal agents, especially to the new generation azoles and the echinocandins. In the past, some reports described the effectiveness of ketoconazole in treating mycetoma patients. At least, ketoconazole therapy usually leads to some degree of improvement (14, 47). Few investigators described in vitro susceptibility testing results. Preliminary data have shown that the azoles were capable of inhibiting the growth of at least 50% of all *M. mycetomatis* strains included in the studies. Unfortunately, the in vivo activity spectrum of the azoles is often poor (6, 52, 69). Still, long term treatment with itraconazole seems to be the best therapeutic regimen at the present time. However, variable responses to itraconazole have also been described (6, 25, 52). Eumycetoma due to *M. mycetomatis* responds poorly to medical treatment with ketoconazole, especially in late, advanced cases, but lesions of patients under ketoconazole treatment remain localized and well encapsulated (25).

No proper study using a standard protocol was carried out to evaluate the susceptibility of large numbers of *M. mycetomatis* clinical isolates. In general most of the investigators agree that early diagnosis followed by both surgical and chemotherapeutic treatment with appropriate antifungal agents results in the most successful outcome (4, 9, 27, 52). Mendez-Tovar *et al.* have shown that progesteron can inhibit the growth of *M. mycetomatis* and *Pyrenochaeta romeroi*, which may contribute to the genuine sex difference in the incidence of mycetoma (9, 25, 52, 53). Addition of hormonal therapy to the standard chemotherapeutic regimen has not yet been evaluated in clinical

trials.

M. MYCETOMATIS IN ANIMALS

In addition to man, natural mycetoma has also been reported in dogs, cats, horses, cows, goats and even in dolphins (10, 23, 33, 34, 38, 39, 42, 51, 54, 57, 60, 62, 63, 68). However, in contrast to actinomycetoma, the induction of eumycetoma in laboratory animals is very difficult. Many investigators reported reproducible animal models for bacterial mycetoma, but few investigators were successful in developing *M. mycetomatis* infection in small laboratory animals. Only sporadically, the characteristic black grains due to *M. mycetomatis* were reproduced in an animal model. This required inoculation of *M. mycetomatis* mixed with killed tubercle bacilli or the use of congenitally athymic nude mice. In immunocompetent mice such lesions were sometimes observed after repeated intraperitoneal inoculation (13, 45, 56).

CONCLUSIONS

In the endemic areas, mycetoma is a chronic infection affecting large numbers of people in the prime of their lives. The disease has, however, largely been ignored by public health authorities and neglected by the scientific community. Consequently, today, the infection remains difficult to diagnose, difficult to treat and still is a significant socio-economical factor to the susceptible population. Although *M. mycetomatis* is the major cause of mycetoma and has a world-wide distribution, little is known about the fungal ecology, the most susceptible hosts, and the host-pathogen interactions. Many questions still need to be answered. Are all isolates described by conventional morphological and physiological characteristics part of a single geno-species? If these are a single species, what is the correct taxonomic position in the fungal kingdom? What are the prime ecological niches of the fungus and which are the dominant routes of transmission leading to infections in humans? If the fungus resides in the soil, why was it essential never successfully recovered from this substrate? What are the in vitro and in vivo susceptibilities of the fungus to the common antifungal agents used for the treatment of patients? How does the immunopathology of infection develop? Can a reproducible animal model be designed? Can accurate, sensitive and specific serological or molecular techniques for species identification be developed? The present thesis describes investigations aimed at answering at least some of the questions listed above.

SCOPE OF THE THESIS

This first chapter provides a literature review on the tropical disease mycetoma. Literature resources were mainly the review articles, books and internet-accessible text published over the last 10 years. Special emphasis was placed on infections caused by *M. mycetomatis*.

Chapter two describes the design of a molecular-diagnostic test for *M. mycetomatis* infections. Molecular analysis of the ribosomal gene operon of the fungus was performed and a species-specific PCR-mediated test was successfully developed. The diagnostic value of the PCR test has been validated with the help of a variety of clinical specimens. A report of two complicated mycetoma cases including successful molecular diagnostics is presented in Chapter three. The species identification of the causative organisms was performed with the newly developed molecular diagnostic test.

Chapter four describes the utilization of the same molecular techniques in the study of the ecology of mycetoma causing agents. Using PCR, the environmental occurrence of *M. mycetomatis* in Sudan was studied. Molecular detection revealed the presence of fungal DNA in approximately one third of the soil samples from endemic areas, whereas culture-based searches were uniformly negative.

Chapter five describes the phylogeny and typification of *M. mycetomatis*, with comparison to other agents of eumycetoma. This study resulted in molecular neotypification of *M. mycetomatis* and the identification of its most probable taxonomic position.

Chapter six identifies the clonal behavior of clinical *M. mycetomatis* isolates. Large scale RAPD and PCR-RFLP typing of clinical isolates from Sudanese patients revealed that it is apparently impossible to distinguish DNA from a variety of clinical isolates of *M. mycetomatis* suggesting a recent evolutionary history or overall genome stability.

Chapter seven describes a novel, reproducible mouse model for *M. mycetomatis* infection. Various routes of inoculation, various amounts of *M. mycetomatis* mycelium and different adjuvants were evaluated in mice, differing with respect to age, gender and immune status.

Chapter eight describes a new protocol for determination of the Minimum Inhibitory Concentration (MIC) of different antifungal agents that may have therapeutic value against *M. mycetomatis*. The protocol based on the National Committee of Clinical Laboratory Standards guidelines M38-A was adapted for use with *M. mycetomatis*. The colorimetric assay (XTT test) was adapted and used to quantify the antifungal activity of the agents. Both assays were used to determine the in vitro activities of amphotericin B and itraconazole against a large number of *M. mycetomatis* clinical isolates.

REFERENCES

1. **Abbott, P.** 1956. Mycetoma in the Sudan. *Trans R Soc Trop Med Hyg.* **50**:11-30.
2. **Agarwal, S. C., and D. R. Mathur** 1985. Mycetoma in Northern Nigeria. *Trop Geogr Med.* **37**:133-5.
3. **Ahmed, A. O., E. S. Abugroun, A. Fahal, E. Zijlstra, A. van Belkum and H. Verbrugh.** 1998. Unexpected high prevalence of secondary bacterial infection in patients with mycetoma. *J Clin Microbiol.* **36**:850-1.
4. **Andreu, J. M.** 1986. Actual treatment of fungus mycetoma: interest in associating ketoconazole and conservative surgery. *Med Trop (Mars).* **46**:293-7.
5. **Basset, A., R. Camain, R. Baylet, and D. Lambert** 1965. Role of Mimosaceae thorns in inoculation of mycetoma (Apropos of 2 cases). *Bull Soc Pathol Exot Filiales.* **58**:22-4.
6. **Bayles, M. A.** 1992. Tropical mycoses. *Chemotherapy.* **38**:27-34.
7. **Bendl, B. J., D. Mackey, F. Al-Saati, K. V. Sheth, S. N. Ofole, and T. M. Bailey** 1987. Mycetoma in Saudi Arabia. *J Trop Med Hyg.* **90**:51-9.
8. **Bocarro, J. E.** 1909. On mycetoma. *Trans Bombay Med Congress*:324-32.
9. **Boiron, P., R. Locci, M. Goodfellow, S. A. Gumaa, K. Isik, B. Kim, M. M. McNeil, M. C. Salinas-Carmona, and H. Shojaei** 1998. *Nocardia*, nocardiosis and mycetoma. *Med Mycol.* **36**:26-37.
10. **Boomker, J., J. A. Coetzer, and D. B. Scott** 1977. Black grain mycetoma (maduromycosis) in horses. *J Vet Res.* **44**:249-51.
11. **Cameron, H. M., D. Gatei, and A. D. Bremner** 1973. The deep mycoses in Kenya: A histopathological study. 1. Mycetoma *East Afr Med J.* **50**:382-95.
12. **Corray, G. H.** 1962. Fungal infections in Ceylon. *Ceylon Med J.* **7**:185-96.
13. **Cremer, G., M. I. B. Mezence, P. Bioron, M. Huerre, and R. Houin** 1995. Experimental mycetoma due to *Madurella mycetomatis* in non-immunodeficient mice. *Med Microbiol Lett.* **4**:76-82.
14. **Cuce, L. C., E. L. Wroclawski, and S. A. Sampaio** 1980. Treatment of paracoccidioidomycosis, candidiasis, chromomycosis, lobomycosis, and mycetoma with ketoconazole. *Int J Dermatol.* **19**:405-8.
15. **de Hoog, G. S., A. Buiting, C. S. Tan, A. B. Stroebel, C. Ketterings, E. J. de Boer, B. Naafs, R. Brimicombe, M. K. Nohlmans-Paulssen, G. T. Fabius, A.H. Klokke and L.G. Visser.** 1993. Diagnostic problems with imported cases of mycetoma in The Netherlands. *Mycoses.* **36**:81-7.
16. **de Hoog, G. S., J. Guarro, J. Gene, and M. J. Figueras** 2000. *Atlas of Clinical Fungi*, 2nd ed, Ed. Centraalbureau voor Schimmelcultures / Universitat Rovira i Virgili, Utrecht / Reus.
17. **Develoux, M., J. Audoin, J. Treguer, J. M. Vetter, A. Warter, and A. Cenac** 1988. Mycetoma in the Republic of Niger: clinical features and epidemiology. *Am J Trop Med Hyg.* **38**:386-90.
18. **Develoux, M., B. Ndiaye, and M. T. Dieng** 1995. Mycetomas in Africa. *Sante.* **5**:211-7.
19. **El Hag, I. A., A. H. Fahal, and E. A. G. Khalil** 1996. Fine needle aspiration cytology of

- mycetoma. *Acta Cytol.* **40**:461-4.
20. **El Hassan, A. M., A. Fahal, I. A. El Hag, and E. A. G. Khalil** 1994. The pathology of mycetoma. *Sudan Med J.* **32**:23-45.
 21. **El Hassan, A. M., A. H. Fahal, A. O. Ahmed, A. Ismail, and B. Veress** 2001. The immunopathology of actinomycetoma lesions caused by *Streptomyces somaliensis* *Trans R Soc Trop Med Hyg.* **95**:89-92.
 22. **El Mofiti, A., I. O. Iskander, N. Nada, and S. M. Zaki** 1965. Madura foot in Egypt. *Br J Dermatol.* **77**:365-72.
 23. **Elad, D., U. Orgad, B. Yakobson, S. Perl, P. Golomb, R. Trainin, I. Tsur, S. Shenkler, and A. Bor** 1991. Eumycetoma caused by *Curvularia lunata* in a dog. *Mycopathologia.* **116**:113-8.
 24. **Erbakan, N., A. N. Or, M. Unal, and Z. Palali** 1973. A review of mycetomas in Turkey. *Mycopathol Mycol Appl.* **51**:105-13.
 25. **Fahal, A. H.** 2002, posting date. Mycetoma Review Article (Mycetoma updates). Mycetoma Research Center, University of Khartoum.
 26. **Fahal, A. H., E. A. El Toum, A. M. El Hassan, E. S. Mahgoub, and S. A. Gumaa** 1995. The host tissue reaction to *Madurella mycetomatis*: new classification. *J Med Vet Mycol.* **33**:15-7.
 27. **Fahal, A. H., M. A. Hassan, and M. Sanhoury** 1994. Surgical treatment of mycetoma. *Sudan Med J.* **32**:98-104.
 28. **Fahal, A. H., and S. H. Suliman** 1994. Clinical presentation of mycetoma. *Sudan Med. J.* **32**:46-66.
 29. **Findlay, G. H., H. F. Vismer, and N. W. Kieberger** 1979. Black grain mycetoma: the ultrastructure of *Madurella mycetomi*. *Mycopathologia.* **67**:51-4.
 30. **Gammel, J. A.** 1927. The etiology of maduromycosis with mycologic report on two new species observed in the United States. *Arch Dermatol Syph.* **15**:241-84.
 31. **Gomez, B. L., J. D. Nosanchuk, S. Diez, S. Youngchim, P. Aisen, L. E. Cano, A. Restrepo, A. Casadevall, and A. J. Hamilton** 2001. Detection of melanin-like pigments in the dimorphic fungal pathogen *Paracoccidioides brasiliensis* in vitro and during infection. *Infect Immun.* **69**:5760-7.
 32. **Gumaa, S. A.** 1994. The etiology and epidemiology of mycetoma. *Sudan Med J.* **32**:14-22.
 33. **Gumaa, S. A., and M. T. Abu-Samra** 1981. Experimental mycetoma infection in the goat. *J Comp Pathol.* **91**:341-6.
 34. **Gumaa, S. A., F. H. Mohamed, E. S. Mahgoub, S. E. Adam, A. M. El Hassan, and S. E. Imbabi** 1978. Mycetomas in goats. *Sabouraudia.* **16**:217-23.
 35. **Hay, R. J.** 1989. A thorn in the flesh—a study of the pathogenesis of subcutaneous infections. *Clin Exp Dermatol.* **14**:407-15.
 36. **Hay, R. J., and M. J. Collins** 1983. An ultrastructural study of pale eumycetoma grains. *Sabouraudia.* **21**:261-9.
 37. **HersHKovitz, I., M. Speirs, A. Katznelson, and B. Arensburg** 1992. Unusual pathological condition in the lower extremities of a skeleton from ancient Israel. *Am J Phys Anthropol.* **88**:23-6.

38. **Jasmin, A. M., C. P. Powell, and J. N. Baucom** 1972. Actinomycotic mycetoma in the bottlenose dolphin (*Tursiops truncatus*) due to *Nocardia paraguayensis*. *Vet Med Small Anim Clin.* **67**:542-3.
39. **Johnson, G. R., B. Schiefer, and J. F. Pantekoek** 1975. Maduromycosis in a horse in western Canada. *Can Vet J.* **16**:341-4.
40. **Kubba, A., and A. A. Satir** 1984. Mycetoma in Eastern province of Saudi Arabia. *Saudi Med J.* **5**:147-51.
41. **Kwon-Chung, K. J., and J. E. Bennet** 1992. *Medical Mycology.* Lea & Febiger, Philadelphia.
42. **Lewis, G. E., Jr., W. J. Fidler, and M. H. Crumrine** 1972. Mycetoma in a cat. *J Am Vet Med Assoc.* **161**:500-3.
43. **Lynch, J. B.** 1964. Mycetoma in the Sudan. *Ann R Coll Surg Engl.* **35**:319-40.
44. **Magana, M.** 1984. Mycetoma. *Int J Dermatol.* **23**:221-36.
45. **Mahgoub, E. S.** 1978. Experimental infection of athymic nude New Zealand mice, nu nu strain with mycetoma agents. *Sabouraudia.* **16**:211-6.
46. **Mahgoub, E. S.** 1973. Mycetomas caused by *Curvularia lunata*, *Madurella grisea*, *Aspergillus nidulans*, and *Nocardia brasiliensis* in Sudan. *Sabouraudia.* **11**:179-82.
47. **Mahgoub, E. S., and S. A. Gumaa** 1984. Ketoconazole in the treatment of eumycetoma due to *Madurella mycetomi*. *Trans R Soc Trop Med Hyg.* **78**:376-9.
48. **Mahgoub, E. S., S. A. Gumaa, and A. M. El Hassan** 1977. Immunological status of mycetoma patients. *Bull Soc Pathol Exot Filiales.* **70**:48-54.
49. **Mahgoub, E. S., and I. G. Murray** 1973. Mycetoma. William Heinemann, London.
50. **Mariat, F.** 1963. Sur La distribution géographique et La repartition des agents de mycetomes. *Bull Soc Pathol Exot.* **56**:35-45.
51. **McEntee, M.** 1987. Eumycotic mycetoma: review and report of a cutaneous lesion caused by *Pseudallescheria boydii* in a horse. *J Am Vet Med Assoc.* **191**:1459-61.
52. **McGinnis, M. R.** 1996. Mycetoma. *Dermatol Clin.* **14**:97-104.
53. **Mendez Tovar, L. J., C. de Bievre, and R. Lopez-Martinez** 1991. Effects des hormones sexuelles humaines sur le devel-opment in vitro des agents d'eumycetomes. *J Mycol Med.* **1**:141.
54. **Miller, R. I., J. H. Norton, and P. M. Summers** 1980. Black-grained mycetoma in two horses. *Aust Vet J.* **56**:347-8.
55. **Murray, I. G., and E. S. Mahgoub** 1968. Further studies on the diagnosis of mycetoma by double diffusion in agar *Sabouraudia.* **6**:106-10.
56. **Murray, I. G., E. T. C. Spooner, and J. Walker** 1960. Experimental infection of mice with *Madurella mycetomi*. *Trans R Soc Trop Med Hyg.* **54**:335-41.
57. **Otcenasek, M., J. Matl, J. Vitovec, P. Vladik, and J. Wohlman** 1982. Maduromycotic mycetoma in a horse. *Vet Med (Praha).* **27**:37-43.
58. **Padhye, A. A., and M. R. McGinnis** 1999. Fungi causing eumycotic mycetoma, p. 1318-1326. *In* P. R. Murray, E. J. Baron, M. A. Pfaller, F. C. Tenover, and R. H. Tenover (eds), *Manual of Clinical Microbiology*, 7th ed. American Society for Microbiology, Washington.

59. **Rajendran, C., A. Baby, S. Kumari, and T. Verghese** 1991. An evaluation of straw-extract agar media for the growth and sporulation of *Madurella mycetomatis*. *Mycopathologia*. **115**:9-12.
60. **Reinke, S. I., P. J. Ihrke, J. D. Reinke, A. A. Stannard, S. S. Jang, D. M. Gillette, and K. W. Hallock** 1986. Actinomycotic mycetoma in a cat. *J Am Vet Med Assoc*. **189**:446-8.
61. **Rippon, J. W.** 1988. *Medical Mycology, The Pathogenic Fungi and the Pathogenic Actinomycetes*, 3rd ed. W.B. Saunders Company, Philadelphia.
62. **Russo, A. M., S. E. Ebermayer, O. A. Mancebo, and C. M. Monzon** 1994. Eumycotic mycetomas in horses caused by *Curvularia verruculosa*. *Rev Argent Microbiol*. **26**:179-82.
63. **Schiefer, B., and B. Mehnert** 1965. Maduromycosis in horses in Germany. *Berl Munch Tierarztl Wochenschr*. **78**:230-4.
64. **Singh, H.** 1978. Mycetoma in India. *Indian J Surg*. **41**:577-97.
65. **Spigelman, M., and H. D. Donoghue** 2001. Brief communication: unusual pathological condition in the lower extremities of a skeleton from ancient Israel. *Am J Phys Anthropol*. **114**:92-3.
66. **Taha, A.** 1983. A serological survey of antibodies to *Streptomyces somaliensis* and *Actinomyces madurae* in the Sudan enzyme linked immunosorbent assay (ELISA). *Trans R Soc Trop Med Hyg*. **77**:49-50.
67. **Tight, R. R., and M. S. Bartlett** 1981. Actinomycetoma in the United States. *Rev Infect Dis*. **3**:1139-50.
68. **Van Amstel, S. R., M. Ross, and S. S. van den Bergh** 1984. Maduromycosis (*Madurella mycetomatis*) in a horse. *J S Afr Vet Assoc*. **55**:81-3.
69. **Venugopal, P. V., and T. V. Venugopal** 1993. Treatment of eumycetoma with ketoconazole. *Australian J Dermatol*. **34**:27-9.
70. **Wethered, D. B., M. A. Markey, R. J. Hay, E. S. Mahgoub, and S. A. Gumaa** 1987. Ultrastructural and immunogenic changes in the formation of mycetoma grains. *J Med Vet Mycol*. **25**:39-46.
71. **Wethered, D. B., M. A. Markey, R. J. Hay, E. S. Mahgoub, and S. A. Gumaa** 1988. Humoral immune responses to mycetoma organisms: characterization of specific antibodies by the use of enzyme-linked immunosorbent assay and immunoblotting. *Trans R Soc Trop Med Hyg*. **82**(6):918-23.



Chapter 2

Development of a Species-Specific PCR-Restriction Fragment Length Polymorphism Analysis Procedure for the Identification of *Madurella mycetomatis*

Abdalla O. A. Ahmed, Moawia M. Mukhtar, Marly Kools-Sijmons, Ahmed H. Fahal, Sybren de Hoog, Bert Gerrits van den Ende, Eduard E. Zijlstra, Henri Verbrugh, El Sir A. M. Abugroun, Ahmed M. Elhassan, and Alex van Belkum

Journal of Clinical Microbiology, (1999)37(10): 3175-3178

ABSTRACT

Madurella mycetomatis is the commonest cause of eumycetoma in Sudan and other countries in tropical Africa. Currently, early diagnosis of mycetoma is difficult. In attempting to improve the identification of *M. mycetomatis* and, consequently, the diagnosis of mycetoma, we have developed specific oligonucleotide PCR primers, based on the sequence of the internal transcribed spacer (ITS) regions spacing the genes encoding the fungal ribosomal RNAs. The ITS regions were amplified with universal primers and sequenced, and then two sets of species-specific primers were designed which specifically amplify parts of the ITS and the 5.8S ribosomal DNA gene. The new primers were tested for specificity with DNA isolated from human mycetoma lesions and DNA extracted from cultures of *M. mycetomatis* reference strains and related fungi as well as human DNA. To study the genetic variability of the ITS regions of *M. mycetomatis*, ITS amplicons were obtained from 25 different clinical isolates and subjected to restriction fragment length polymorphism (RFLP) analysis with *CfoI*, *HaeIII*, *MspI*, *Sau3AI*, *RsaI*, and *SpeI* restriction enzymes. RFLP analysis of the ITS region did not reveal even a single difference, indicating the homogeneity of the isolates analyzed during the current study.

INTRODUCTION

Mycetoma is a chronic granulomatous subcutaneous infection caused by true fungi (eumycetoma) or higher bacteria (actinomycetoma)(6, 14). The disease is endemic in tropical and subtropical areas and is the major mycological health problem in Sudan (6, 14). The majority of cases of mycetoma in Sudan are caused by *Madurella mycetomatis*. The pathogens involved are found in the environment in certain types of soil and are directly inoculated into the subcutaneous tissues, commonly in the foot, through minor trauma or a thorn prick (9, 14). Mycetoma has a prolonged, progressive, and indolent course and, if untreated, ultimately leads to destruction of deeper tissues and bone, resulting in deformity and disability which may necessitate amputation. The triad of a subcutaneous painless mass, sinuses, and grains discharged through the sinuses is the hallmark of mycetoma (6, 14). Diagnosis may be more difficult in early stages, especially prior to the appearance of the sinuses and grains. At this stage the disease may be difficult to distinguish from a variety of soft tissue tumors and granulomata (11, 22).

Currently, the available diagnostic tools for mycetoma are few and have many limitations. Diagnosis is based on the identification of the grains in the discharge of the sinuses or biopsies from the lesions. Staining grains allows the identification of the causative organism, but this is of limited value in the differentiation of true fungi (18). Culture is always necessary for definitive diagnosis. However, culturing clinical specimens is cumbersome, time-consuming, prone to secondary bacterial contamination (1), always needs deep surgical biopsy under general anesthesia, and is not always practical or cost-effective in areas of endemicity (18). Serodiagnosis is hampered by cross-reactivity among the multiple species of actinomycetes as well as by the lack of standardized antigen preparations(8, 19).

Comparative studies of the nucleotide sequences of the rRNA genes provide a means for analyzing phylogenetic relationships over a wide range of taxonomic levels and to assist in the development of identification assays for fungal species (23). The small-subunit ribosomal rDNA sequences evolve relatively slowly and are useful for studying distantly related organisms (23). The internal transcribed spacer (ITS) regions 1 and 2 can be amplified with the primers ITS5 and ITS4, which are located in the

conserved regions of the 18S and 28S genes, respectively. Together with the intergenic spacer of the nuclear rRNA repeat units, this region evolves faster and may vary among the different species within a genus or even among cells found in a single population (23). rDNA sequences have been utilized by many investigators for the determination of species identity for a multitude of yeasts and fungi (2, 7, 10, 12, 24). It has also been reported that ITS ribotyping is a simple method that can distinguish among most of the *Saccharomyces* species (16), and ITS sequences can differentiate between the closely related strains in the *Trichophyton mentagrophytes* complex (15).

The aim of the present study was to supplement current diagnostic tools for mycetoma with the development of a species-specific PCR assay for identification of *M. mycetomatis*, based on the nucleotide sequence of the ITS regions in the rDNA operon. The study also addressed the taxonomic position of the causative organisms and tested for the genetic variability of different *M. mycetomatis* isolates.

MATERIALS AND METHODS

Clinical specimens. Clinical specimens were collected from 48 consecutive patients presenting with black grain mycetoma at the Mycetoma Research Center, University of Khartoum, Sudan, during the period between November 1997 and August 1998. The patients were from different regions of the country. Following written consent from the patients, deep-excision biopsy specimens with visible grains were collected.

Fungal isolates. For isolation of the fungus, some grains were collected from the biopsy specimens, washed twice in physiological saline containing 1% chloramphenicol, inoculated into Sabouraud's agar (Difco, Amsterdam, The Netherlands), and incubated at 37°C for 3 to 4 weeks. Potential *M. mycetomatis* cultures were identified morphologically, and the fungal mycelia were scraped and stored in 9% glycerol broth at 80°C and shipped to the Department of Medical Microbiology and Infectious Diseases, Erasmus University Medical Center Rotterdam, Rotterdam, The Netherlands. Control strains from related fungal species were obtained from the Centraalbureau voor Schimmelcultures, The Netherlands. The following eight reference strains were included: *Madurella grisea* CBS 331-50 and CBS 332-50, *M. mycetomatis* CBS 247.48 and CBS 868.95, *Pyrenochaeta mackinnonii* CBS 674.75, *Pyrenochaeta romeri* CBS 252.60, *Pyrenochaeta unguis-homini* CBS 378.92, and *Chaetosphaeronema larense* CBS 640.73.

DNA extraction and purification. Prior to DNA extraction the fungi were subcultured on Sabouraud's agar and incubated at 37°C for 3 weeks. The mycelia were scraped from the culture medium and homogenized with sterile pestles and a mortar. The homogenized mycelia were then snap frozen in liquid nitrogen, thawed and refrozen twice, and rehomogenized in 2 ml of lysis buffer containing 4 M guanidinium isothiocyanate, 0.1 M Tris-HCl (pH 6.4), 0.2 M EDTA, and 0.1% Triton X-100. The DNA was purified by Celite affinity chromatography (Janssen Pharmaceuticals, Beerse, Belgium) as described before (3). Two other DNA purification protocols were tested for the destruction of the cell wall of the fungus, using either lysis buffer with lyticase enzymes followed by proteinase K treatment (20) or cetyltrimethylammonium bromide (Janssen Pharmaceuticals) buffer at 56°C (21).

PCR amplification. DNA extracts of 25 different *M. mycetomatis* isolates were amplified with primers ITS4 and ITS5 (23). The sequences of the two primers were 5'-TCCTCCGCTTATTGATATGC-3' and 5'-

GGAAGTAAAAGTCGTAACAAGG-3', respectively. The PCRs were performed in 50- μ l reaction volumes containing 0.2 U of *Taq* polymerase (Super *Taq*; HT Biotechnology, Cambridge, United Kingdom) and 5 ng of template DNA. Cycling was performed in a model 60 thermocycler (Biomed, Theres, Germany) with the following temperature trajectory: 40 cycles of alternating denaturation (94°C for 1 min), annealing of primers (58°C for 1 min), and enzymatic extension by the thermostable polymerase (72°C for 2 min). The PCR products were examined by electrophoresis in 1% agarose gels stained with ethidium bromide.

Cloning, sequencing, and primer design. Amplimers obtained with primers ITS4 and ITS5 were cloned into the plasmid pCRII with the Topo-TA cloning kit (Invitrogen, Leek, The Netherlands) and sequenced commercially (Eurogentec, Seraing, Belgium). The sequences obtained were aligned, adjusted, and compared for homology with the sequences derived from other species and deposited in the various databases. Two potentially *M. mycetomatis*-specific sets of primers were designed (primers 26.1A [5'-AATGAGTTGGGCTTTAACGG-3'] and 28.3A [5'-TCCCGGTAGTGTAGTGTCCCT-3'] and primers 26.1B [5'-GCAACACGCCCTGGGCGA-3'] and 28.3B [5'-TCCGCGGGGCGTCCGCCGGA-3']). The newly designed primers were tested for sensitivity and specificity with a PCR protocol that was identical to the one described above except that the extension step was shortened to 1 min.

Detection of ITS polymorphisms. Restriction fragment length polymorphism (RFLP) in the *M. mycetomatis* ITS regions was assessed by analysis of the PCR products generated by primers ITS4 and ITS5 with *CfoI*, *MspI*, *HaeIII*, *RsaI*, *Sau3A*, and *SpeI* restriction enzymes (Boehringer-Mannheim, Mannheim, Germany). The enzymes were used as recommended by the manufacturer. RFLP was determined by electrophoresis in 3% Nusieve GTG agarose gels (Biozym, Landgraaf, The Netherlands).

Nucleotide sequence accession number. The sequence of the *M. mycetomatis* ITS region has been deposited in GenBank under accession no AF162133.

RESULTS

From the 48 patients, 45 isolates were successfully cultured. Of these 45 isolates, only 25 survived storage at -80°C and transportation from the Sudan to The Netherlands. DNA isolation from fungal mycelia was initially performed in a comparative fashion. The three different protocols used for DNA purification gave virtually the same yield of DNA.

The amplified DNA fragments of the ITS regions (with ITS4 and ITS5 primers) of *M. mycetomatis* and the control strains were found to be between 600 and 1,200 bp in length (Figure 1). Note that there appears to be a small difference in length when the amplicons obtained for the two *M. mycetomatis* reference strains are compared. PCR products of identical size (approximately 630 bp) were obtained when DNA extracted from the clinical isolates of *M. mycetomatis* was amplified (result not shown). The size of this fragment equaled that obtained for *M. mycetomatis* CBS 247.48. Cloning and sequencing of this type of ITS fragment for *M. mycetomatis* revealed that the fragment was 624 bp in length, which includes the ITS4 and ITS5 primers. The potentially species-specific primer sets 26.1A and 28.3A and 26.1B and 28.3B were found to be specific for *M. mycetomatis* DNA (Figure 1). When the 26.1A-28.3A combination was used, a fragment of about 420 bp was synthesized, which is in agreement with expectations on the basis of the ITS nucleotide sequence. Similar-sized fragments were obtained as

well when DNA isolated from the clinical strains was used as a template ($n = 25$). The primers did not amplify human DNA.

When the sequences determined for the ITS regions of two different *M. mycetomatis* isolates were compared, they were found to be identical with only minor ambiguities in two nucleotide positions. Running the *M. mycetomatis* spacer sequence through the GenBank data depository did not highlight any closely related sequence homologues from other fungal species. Ranking of homologous sequences indicated that the ITS sequence as determined for a nonspeciated isolate from the genus *Phialophora* came closest to the *Madurella* sequence. However, the homology appeared to be mainly restricted to the ribosomal gene sequences. In ITS1 several mutations were documented, whereas in ITS2 a 110-nucleotide stretch showing no significant homology was encountered. Consequently, the generation of informative parsimony trees will have to await the determination of ITS sequences for more closely related fungal species, such as the ones used in the control panel described above.

The RFLP pattern generated by six different restriction enzymes produced banding profiles that were in full agreement with the nucleotide sequence. The RFLP patterns generated for the control species were clearly different (Figure 2). The two *M. grisea* isolates could not be discriminated but clearly differed from the *M. mycetomatis* isolates. Furthermore, the three species of *Pyrenochaeta* could be distinguished, since *P. romeri* and *P. unguis-homini* differed only in a single *HaeIII* site (Figure 2, bottom panel). The RFLP pattern obtained for *M. mycetomatis* (CBS 247.48) matched the RFLP pattern of the clinical isolates. In all assays, *M. mycetomatis* (CBS 868.95) showed profiles completely different from those of all other *M. mycetomatis* strains, raising doubts about the species status of this isolate (see Discussion).

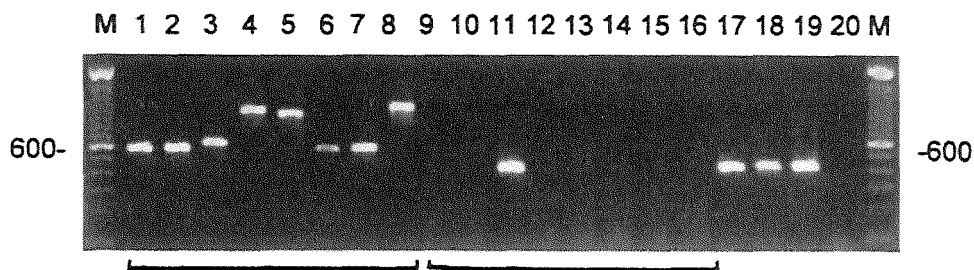


Figure 1. PCR amplification of the ITS for *M. mycetomatis* and related species. Lanes 1 to 8 show the amplicons obtained by using the universal primers ITS4 and ITS5. DNAs from the following species were amplified: *M. grisea* CBS331-50 (lane 1) and CBS 332-50 (lane 2), *M. mycetomatis* CBS 247.48 (lane 3) and CBS 868.95 (lane 4), *P. mackinnonii* CBS 674.75 (lane 5), *P. romeri* CBS 252.60 (lane 6), *P. unguis-homini* CBS 378.92 (lane 7), and *C. larense* CBS 640.73 (lane 8). In lanes 9 to 16 PCR results obtained with the primer combination 26.1A and 28.3A are displayed; the strains are ordered similarly from left to right. Note that only *M. mycetomatis* CBS 247.48 yielded a positive signal. Lanes 17 to 19 show the representative PCR products obtained for all of the clinical *M. mycetomatis* isolates. Lane 20 contains the negative PCR control. On the left and right the molecular size of the intensely fluorescing 600-bp-long fragment in the 100-bp ladder is indicated.

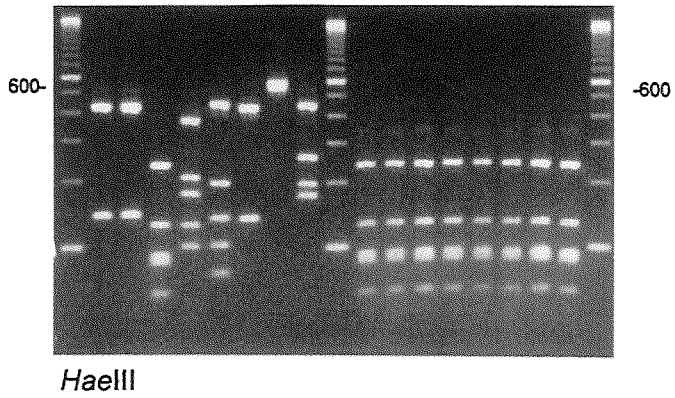
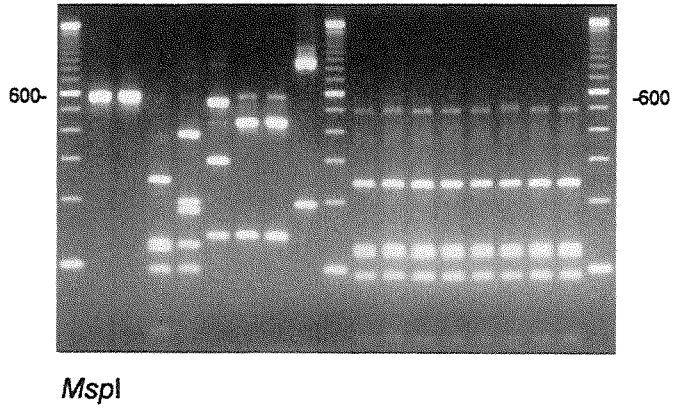
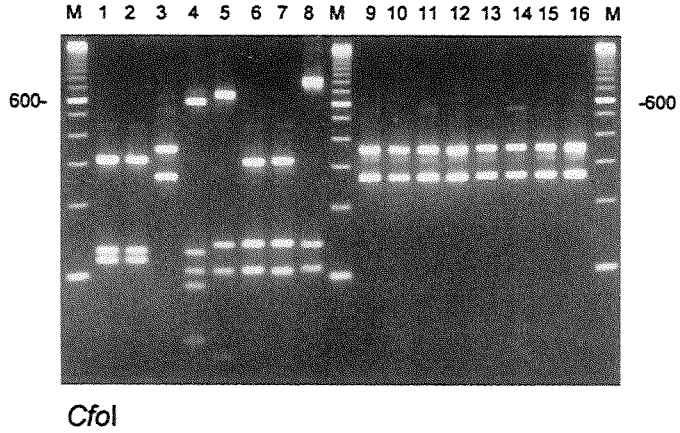
DISCUSSION

Successful medical treatment or surgical excision of mycetoma lesions depends on the accurate diagnosis of the type of mycetoma and determination of the extent of the lesion. The latter is often difficult preoperatively, since the available diagnostic tools are not sensitive or specific (6, 14). In addition to the laboratory procedures for staining, cultivation, and serology already in use for detection of *M. mycetomatis*, aspiration cytology of mycetoma was recently described, but in the absence of grains the test is of little value (5). Histopathological examination is useful, but it carries a substantial risk of spreading mycetoma, since a deep surgical biopsy is always required (2). Furthermore, it is less reliable than a positive culture (18). Also, with histopathology it is not possible to differentiate among the different clinically important species, such as *M. mycetomatis* and *M. grisea* (13). In conclusion, no simple test is currently available for the diagnosis of mycetoma, other than clinical assessment and the invasive procedure of surgical biopsy. Furthermore, assessment of response to treatment is difficult, as is the prediction of cure or relapse in the absence of a reliable diagnostic test.

Our results showed that *M. mycetomatis* can be easily isolated from clinical specimens, but its survival in the glycerol stock cultures is quite poor. This explains the lack of available archival stocks of *M. mycetomatis*, which has been described previously (17). It appeared that the protocol employing freeze-thaw cycles in combination with the guanidinium lysis procedure was most convenient for DNA isolation in our laboratory setting. It should be mentioned that the yield equaled that of the other procedures, implying that the alternative procedures can be used as effectively.

Here we present the first nucleotide sequence information for the fungal species *M. mycetomatis*. RFLP analyses of the ITS region for which the primary structure was elucidated demonstrate a high degree of homogeneity among clinical isolates of *M. mycetomatis*. The sizes of the different restriction fragments generated precisely match expectations based on simple analysis of the primary structure of the ITS region (analysis not shown). These results seem to be in conflict with an earlier supposition by De Hoog *et al.* (4) that agents of mycetoma would be highly diverse. The present data indicate that mycetomata are caused by endemic species, possibly with a limited geographical distribution or given the identity of the Caribbean strain with the Sudanese isolates at least a local preponderance. Imported cases of mycetoma, such as those in The Netherlands (4), comprise cases from diverse localities and hence are likely to show a higher species diversity.

Figure 2. RFLP analysis of the ITS amplicons obtained for *M. mycetomatis* and related species. Lanes 1 to 8 show the results obtained for *M. grisea* CBS331-50 (lane 1) and CBS 332-50 (lane 2), *M. mycetomatis* CBS 247.48 (lane 3) and CBS 868.95 (lane 4), *P. mackinnonii* CBS 674.75 (lane 5), *P. romeri* CBS 252.60 (lane 6), *P. unguis-homini* CBS 378.92 (lane 7), and *C. larense* CBS 640.73 (lane 8). The three panels were generated with the restriction enzymes indicated (*CfoI*, *MspI*, *HaeIII*). Lanes 9 to 16 show the results obtained for eight of the clinical *M. mycetomatis* isolates, indicating the high degree of ITS homogeneity. Lanes M contain the 100-bp size marker ladder; the position of the 600-bp-long fragment is indicated.



Indeed, the *M. mycetomatis*-like strains from The Netherlands proved to represent a very different taxon. The geographical origin of the patients is thus an important factor in the anamnesis of cases of mycetoma. Several potential explanations for the genetic homogeneity among the clinical isolates of *M. mycetomatis* can be considered: the entire species may be clonal, there may be a type of *M. mycetomatis* that has spread through Sudan, or there may be an intimate link between infection and fungal type. The fact that preliminary randomly amplified polymorphic DNA studies have demonstrated at least a certain degree of genetic heterogeneity in regions other than the ribosomal operons indicates that at present this question cannot be answered and that future studies, involving additional, geographically diverse strains of *M. mycetomatis*, are mandatory.

On the basis of the noncoding ITS regions, we designed PCR primers for the identification of *M. mycetomatis*, the major cause of eumycetoma in the Sudan. The differentiation of the two clinically relevant *Madurella* species is feasible with our newly described assay in a manner that could not be achieved by currently used immunological techniques, such as Western blotting (25). By using the newly designed primers, future diagnosis of eumycetoma caused by *M. mycetomatis* may be quicker and simpler, even in the early stages of the infection. We have already been able to detect fungal DNA in biopsy specimens of mycetoma lesions, but serum samples or regional lymph node biopsy specimens still require additional testing (preliminary observations). To conclude, all *M. mycetomatis* organisms isolated during the course of this study belong to a single species. In addition, the clinical value of the newly designed PCR RFLP test for the identification of *M. mycetomatis* can now be assessed for early case detection, assessment of subclinical infections, and follow-up of patients and for determination of cure or relapse.

REFERENCES:

1. **Ahmed, A. O., and E. S. Abugroun.** 1998. Unexpected high prevalence of secondary bacterial infection in patients with mycetoma. *J Clin Microbiol* **36**(3):850-1.
2. **Baleiras Couto, M. M., J. T. Vogels, H. Hofstra, J. H. Huis in't Veld, and J. M. van der Vossen.** 1995. Random amplified polymorphic DNA and restriction enzyme analysis of PCR amplified rDNA in taxonomy: two identification techniques for food- borne yeasts. *J Appl Bacteriol* **79**(5):525-35.
3. **Boom, R., C. J. Sol, M. M. Salimans, C. L. Jansen, P. M. Wertheim-van Dillen, and J. van der Noordaa.** 1990. Rapid and simple method for purification of nucleic acids. *J Clin Microbiol* **28**(3):495-503.
4. **de Hoog, G. S., A. Buiting, C. S. Tan, A. B. Stroebel, C. Ketterings, E. J. de Boer, B. Naafs, R. Brimicombe, M. K. Nohlmans-Paulssen, G. T. Fabius, A.H. Klokke and C.G. Visser.** 1993. Diagnostic problems with imported cases of mycetoma in The Netherlands. *Mycoses* **36**(3-4):81-7.
5. **El Hag, I. A., A. H. Fahal, and E. A. G. Khalil.** 1996. Fine needle aspiration cytology of mycetoma. *Acta Cytol* **40**(3):461-4.
6. **Fahal, A. H., and M. A. Hassan.** 1992. Mycetoma. *Br J Surg* **79**(11):1138-41.
7. **Fujita, S., B. A. Lasker, T. J. Lott, E. Reiss, and C. J. Morrison.** 1995. Microtitration plate enzyme immunoassay to detect PCR-amplified DNA from *Candida* species in blood. *J Clin Microbiol* **33**(4):962-7.
8. **Gumaa, S. A., and E. S. Mahgoub.** 1975. Counterimmunoelectrophoresis in the diagnosis of mycetoma and its sensitivity as compared to immunodiffusion. *Sabouraudia* **13**(3):309-15.
9. **Hay, R. J., E. S. Mahgoub, G. Leon, S. al-Sogair, and O. Welsh.** 1992. Mycetoma. *J Med Vet Mycol* **30**(Suppl 1):41-9.
10. **Johnston, C. G., and S. D. Aust.** 1994. Detection of *Phanerochaete chrysosporium* in soil by PCR and restriction enzyme analysis. *Appl Environ Microbiol* **60**(7):2350-4.
11. **Kobayashi, G. S.** 1980. Actinomycetoma: the fungus-like bacteria, p. 298-321. *In* B. D. Davis (ed.), *Microbiology*. Harper and Row, Philadelphia.
12. **Kumeda, Y., and T. Asao.** 1996. Single-strand conformation polymorphism analysis of PCR-amplified ribosomal DNA internal transcribed spacers to differentiate species of *Aspergillus* section Flavi. *Appl Environ Microbiol* **62**(8):2947-52.
13. **Machado, L. A., M. C. Rivitti, L. C. Cuce, A. Salebian, S. Lacaz Cda, E. M. Heins-Vaccari, W. Belda Junior, and N. T. de Melo.** 1992. Black-grain eumycetoma due to *Madurella grisea*. A report of 2 cases. *Rev Inst Med Trop Sao Paulo* **34**(6):569-80.
14. **Magana, M.** 1984. Mycetoma. *Int J Dermatol* **23**(4):221-36.
15. **Makimura, K., T. Mochizuki, A. Hasegawa, K. Uchida, H. Saito, and H. Yamaguchi.** 1998. Phylogenetic classification of *Trichophyton mentagrophytes* complex strains based on DNA sequences of nuclear ribosomal internal transcribed spacer 1 regions. *J Clin Microbiol* **36**(9):2629-33.

16. **McCullough, M. J., K. V. Clemons, J. H. McCusker, and D. A. Stevens.** 1998. Intergenic transcribed spacer PCR ribotyping for differentiation of *Saccharomyces* species and interspecific hybrids. *J Clin Microbiol* **36**(4):1035-8.
17. **Pasarell, L., and M. R. McGinnis.** 1992. Viability of fungal cultures maintained at -70 degrees C. *J Clin Microbiol* **30**(4):1000-4.
18. **Rippon, J. W.** 1988. The pathogenic fungi and the pathogenic *Actinomyces*, p. 80-118. *In* J. W. Rippon (ed.), *Medical mycology*, 3rd ed. Saunders, W. B., Philadelphia.
19. **Taha, A.** 1983. A serological survey of antibodies to *Streptomyces somaliensis* and *Actinomadura madurae* in the Sudan enzyme linked immunosorbent assay (ELISA). *Trans R Soc Trop Med Hyg* **77**(1):49-50.
20. **van Deventer, A. J., W. H. Goessens, A. van Belkum, H. J. van Vliet, E. W. van Etten, and H. A. Verbrugh.** 1995. Improved detection of *Candida albicans* by PCR in blood of neutropenic mice with systemic candidiasis. *J Clin Microbiol* **33**(3):625-8.
21. **van Soolingen, D., P. W. Hermans, P. E. de Haas, D. R. Soll, and J. D. van Embden.** 1991. Occurrence and stability of insertion sequences in *Mycobacterium tuberculosis* complex strains: evaluation of an insertion sequence- dependent DNA polymorphism as a tool in the epidemiology of tuberculosis. *J Clin Microbiol* **29**(11):2578-86.
22. **Welsh, O.** 1993. Mycetoma. *Semin Dermatol* **12**(4):290-5.
23. **White, T. J., T. Bruns, S. Lee, and J. Taylor.** 1996. Amplification and direct sequencing of fungal ribosomal RNA genes for phylogenetics, p. 315-322. *In* I. M. A., D. H. Gelfand, J. J. Sninsky, and T. J. White (ed.), *PCR protocols: a guide to method and applications*. Academic Press, San Diego, Calif.
24. **Williams, D. W., M. J. Wilson, M. A. Lewis, and A. J. Potts.** 1995. Identification of *Candida* species by PCR and restriction fragment length polymorphism analysis of intergenic spacer regions of ribosomal DNA. *J Clin Microbiol* **33**(9):2476-9.
25. **Zaini, F., M. K. Moore, D. Hathi, R. J. Hay, and W. C. Noble.** 1991. The antigenic composition and protein profiles of eumycetoma agents. *Mycoses* **34**(1-2):19-28.

Chapter 3

Molecular Detection and Identification of Agents of Eumycetoma: a Detailed Report of Two Cases

Abdalla O. A. Ahmed, Nicole Desplaces, Sybren De Hoog, Henri Verbrugh and Alex van Belkum

Journal of Clinical Microbiology, (2003). In press

ABSTRACT

We describe two cases of eumycetoma in the legs. The infections could not be adequately diagnosed by classical mycology, but the causative agents were successfully identified as *Madurella mycetomatis* by species-specific PCR and DNA sequencing.

INTRODUCTION

Tropical mycoses are often imported into Western countries due to the increasing number of immigrants. This challenges the medical microbiology laboratory since correct diagnosis is usually difficult. Mycetoma is a good example of an infection which is complicated to diagnose, especially because of its large number of possible causative agents (6). De Hoog *et al.* (4), for instance, reviewed eight cases imported in The Netherlands, in which only one out of seven isolates, *Actinomyces madurae*, belonged to a commonly known agent of mycetoma. The other isolates either belonged to very rare species, such as *Phialophora cyanescens*, or were not identifiable at all.

In this report, we show how molecular techniques in combination with an updated taxonomy can be utilized to solve these diagnostic problems. We discuss two mycetoma cases which with the help of PCR and DNA sequencing, were ultimately shown to be caused by *Madurella mycetomatis*.

THE FIRST CASE

A 39-year-old man, born and living in Mali. This patient was first seen on the 2nd of December 2000 at Saint Joseph Hospital in Paris, France. The patient was admitted with a fistulated infection of the left ankle, showing multiple draining sinuses. Radiographs identified a lytic lesion in the distal part associated with the fibula. The patient had a history of excision of an abscess containing black grains near the knee joint 3 or 4 years ago in Mali. At that time, he received co-trimoxazole for several months, without apparent improvement. The abscess, which appeared to be a mycetoma lesion, did not heal. Apparently, either the excision was incomplete or the patient developed a re-infection. One week after admission to the hospital, the patients underwent massive excision of soft tissues and infected bone. Numerous black grains were seen in the surgical specimens, which were hard in consistency and irregular in size and in shape. Clinical material was sent to St Joseph Hospital's microbiology laboratory. Direct microscopical examination of the grains revealed fungal hyphae with some swollen cells. Prior to culture, the grains were washed in sterile water and then seeded directly onto Sabouraud dextrose agar and Chocolate blood agar and incubated at 30° and 37°C. The growth was better at 37°C. After a few days of incubation, *Streptococcus pyogenes* (group A) was isolated and 4 to 5 days later, a slow-growing fungus producing brown diffusible pigments was recovered. The fungus showed better and more rapid growth on chocolate agar. To enhance sporulation, the fungus was subcultured on Soil extract agar and incubated at 25°C for eight weeks. The culture remained sterile, and no spores or conidia were seen (Figure 1-A). After eight weeks of incubation, still only vegetative hyphae with some swollen chlamyospore-like cells were seen. The isolated fungus could not be accurately identified to the species level. No additional pathological investigation was performed for this patient. The case was diagnosed as eumycetoma and managed with several surgical debridements combined with chemotherapy. Three weeks after the initial excision muscle flap coverage and skin grafting was performed. The patient received oral itraconazole and amoxicillin for 6

weeks followed by oral amoxicillin and itraconazole for 14 weeks, after which the medical treatment was stopped. The patient was followed for two more months. No evidence of recurrence of infection was observed at the last follow up, and since then, the patient did not return for follow up.

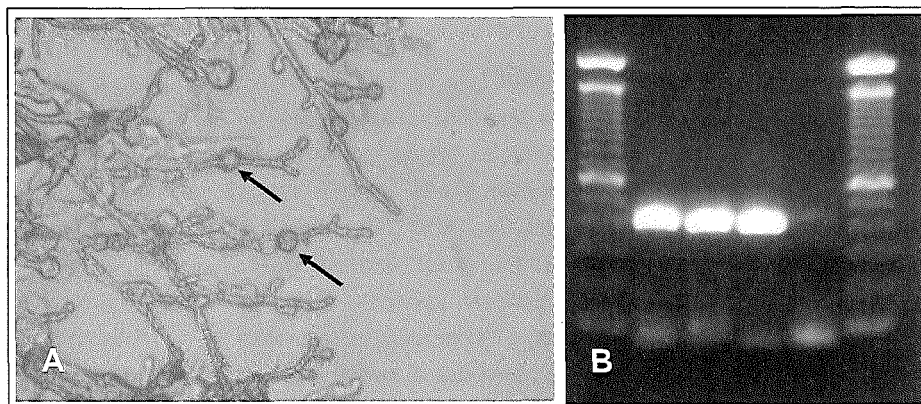


Figure 1: **A-** Direct microscopy of 8 weeks cultures of *M. mycetomatis* (P-1) on Soil extract agar. Only vegetative hyphae with some chlamydospores-like cells (arrows) were seen. Due to the absence of spores, conidia, or specialized conidiogenesis cells or conidiophores, such preparation has a little diagnostic value. **B-** *M. mycetomatis* specific PCR for species identification using primers 26.1A and 28.3A. Lanes 1 and 6 containing 100 b.p. molecular weight marker. Lanes 2-5 show the PCR amplicons of P-1, P2, positive control and negative control respectively. Both P-1 and P-2 were positive.

THE SECOND CASE

A 45-year-old man born in Mali, living in Paris (France) for more than 20 years, but traveling to Mali regularly, presented at the Croix Saint Simon Hospital, on January 3, 2001 at the Orthopedic Department. The patient was complaining of rheumatic arthritis in the left knee joint. During examination the orthopedic surgeon discovered a large subcutaneous indolent mass in the inner part of the right knee (Figure 2-A). There were no sinuses and consequently no discharge. Magnetic resonance images showed a soft tissue mass without any bone or joint involvements (Figure 2-B). The subcutaneous mass initiated gradually and grew slowly over the past 3 years. The patient did not recall any trauma, puncture or wound at the site of the infection. Complete surgical excision was performed and the entire biopsy was sent for microbiological and pathological examination (Figure 2-C). Direct examination and cultures were done in St Joseph Hospital's microbiology laboratory, while pathological examinations were done by Dr. Michel Forest, Cochin Hospital, Paris, France. The lesion was well encapsulated, and it appeared to have been excised completely. The bone and the knee joint were healthy and intact. The lesion measured more than 15 centimeters in length and consisted of dense fibrous tissue containing multiple cavities full of black grains and bloody puss (Figure 2- E and F). Black grains were hard in consistency, and had different shapes and sizes. Microscopically, the grains showed hyphae and swollen cells. Pure filamentous fungus was isolated from the grains. The cultures were done exactly the same as described for the first case. The fungus also showed better growth at 37°C than at 30°C. Better and rapid growth was obtained on chocolate agar after 3 to 4 days (Figure 2-D). The fungus was subcultured on soil extract agar for identification. Good growth was obtained after 2-3 weeks, but again fungal cultures remained sterile, and accurate identification was impossible. To avoid recurrence, the patient was started on oral itraconazole (400 mg two times per day)

immediately after surgery. Due to digestive problems, the dose was reduced to 300 mg (two times per day). The patient continued on treatment and was seen after three months, when the medical treatment was discontinued. The patient was seen once again one month later and again after one year. He cured completely.

MOLECULAR MYCOLOGY

Although the infections were correctly diagnosed from the clinical prospective as being a case of eumycetoma, the identification of the causative organisms remained a problem. For this reason the two fungal isolates were sent to the Department of Medical Microbiology and Infectious Diseases, Erasmus MC, Rotterdam, The Netherlands for identification. The two isolates were coded P-1 and P-2 and subcultured into Sabouraud dextrose agar and incubated at 37°C for 3 weeks. Identification was attempted based on the keys proposed by de Hoog *et al* (5). The cultures consisted of thallus built of regularly septate hyphae without clamp connections and fruit bodies. Both cultures were sterile, dark-brownish in color and producing black diffusible pigments. Morphologically, the cultures were similar to the known agent of eumycetoma *M. mycetomatis*. To confirm this presumptive identification, molecular verification was pursued.

Three-weeks cultures, incubated at 37°C, were subjected to DNA isolation. A previously identified *M. mycetomatis* clinical isolate was included as a positive control. The fungal material was excised from the agar and transferred into 6 ml of a 0,9% NaCl solution. The material was homogenized by sonication for 2 minutes at 30 micron (Soniprep 150, Beun de Ronde, Abcoude, The Netherlands) to fully disrupt the mycelium. Five hundred µl of this suspension was taken and DNA was isolated according to the DNA extraction method described by Boom *et al* (3). The extracted DNA was tested directly by *M. mycetomatis* species-specific PCR as has been described before (1). The PCR reaction mixture without template DNA was used as a negative control. The PCR reaction was performed in a model 60 Thermocycler (Biomed, Theres, Germany). The PCR products were analyzed by electrophoresis on 1% agarose gels and the specific, 424 base pair fragments were seen for both fungal isolates, which exactly matched the positive control. No amplicons were seen in the negative control lane (Figure 1-B).

PCR primer sequences were based on the Internal Transcribed Spacer of *M. mycetomatis* ribosomal genes, and were previously shown to react only with *M. mycetomatis* DNA. The resulting PCR is able to distinguish *M. mycetomatis* from the other black grain mycetoma agents including its close relative *M. grisea* (1). Based on this PCR result, the two isolates were presumptively identified as *M. mycetomatis*. In order to have further confirmation and to study the phylogenetic relationship with other *M. mycetomatis* isolates from different geographical origins, the two isolates were subjected to ITS sequencing using primers ITS1 and ITS4 (9). Sequencing reactions were carried out in 10 µl volumes containing 15-50 ng of the fungal DNA, 4 pmol sequencing primer and 4 µl BigDye Mix (Applied Biosystems, Nieuwerkerk a. d. IJssel, The Netherlands). The DNA products were analysed on an ABI Prism® 310 Genetic analyzer (Applied Biosystems). The sequences were adjusted using SeqMan software (DNASar, Madison, Wisconsin, USA) and aligned using BioNumerics (Applied Maths, Kortrijk, Belgium). The sequences were directly compared with all entries of the CBS database.

The P-1 and P-2 sequences showed over 99% similarity with those of the *M. mycetomatis* reference strain CBS 247.48, the *M. mycetomatis* reference strain CBS 110087, the new-type strain of *M. mycetomatis* (CBS 109801, isolated from Sudan) and with three other clinical isolates from Sudan (6). Thus, PCR and

sequencing confirmed that the causative agent in both patients was *M. mycetomatis*, belonging to the order of the Sordariales in the class Ascomycetes. *M. mycetomatis* is the most prevalent etiological agent of black grain eumycetoma (8), which is a chronic granulomatous infection of subcutaneous and deep tissues (2). In some endemic areas, this fungus is responsible of more than 70% of all mycetoma infections, although microbiological identification is often difficult or impossible (2).

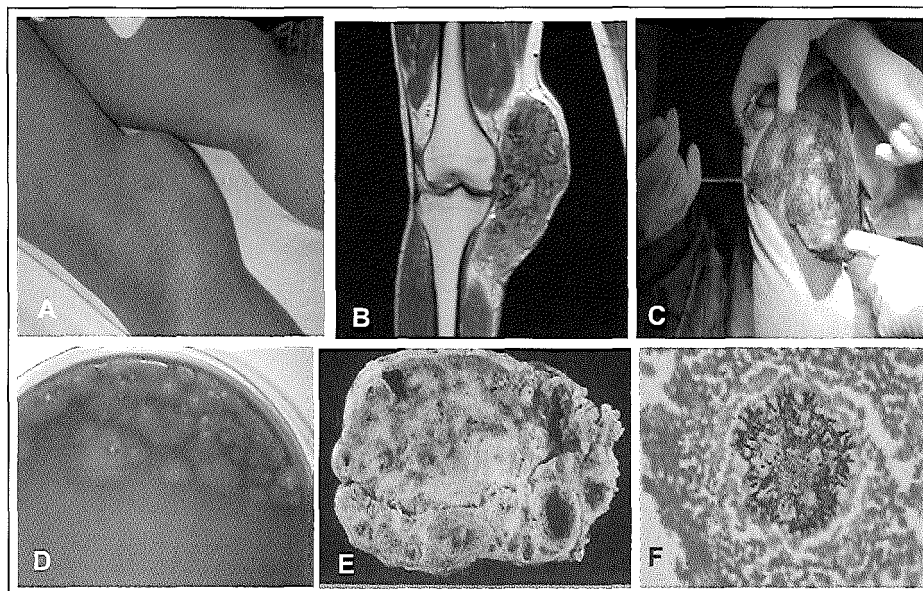


Figure 2: **A-** Massive subcutaneous mass involving the inner part of the right knee. **B-** T1- weighted magnetic resonance image after gadolinium injection showing massive soft tissue mass. Bone and knee joint are healthy and not involved. **C-** During surgical excision, the lesion was well-encapsulated, and it was excised completely. Note the massive lesion, which measure about 16 centimeters. **D-** Four days culture of the black grains on Chocolate blood agar. The fungus starts as white mycelium and later become olivaceous or brown. **E-** The lesion was consisting of dense fibrous tissues containing multiples cavities full thick exudates containing pus, blood and grains. **F-** Gomeri Grocot staining showing fungal grain surrounded by inflammatory cells. You can see clearly the fungal hyphae growing toward the periphery of the grain.

CONCLUDING REMARKS

The two patients were clinically diagnosed as suffering from eumycetoma, and both were treated with a combination of anti-mycotics and surgery. Unfortunately, the follow-up of the first case was rather short and it was impossible to assess the patient=s ultimate response to the medical treatment. Since fungal mycetoma is always difficult to treat and the chance of recurrence of the infection is quite high, especially when only surgery is involved, follow-up is deemed important (2, 8). For the second patient the situation was better. The treatment was stopped rather early, but since his lesion was nicely capsulated, the patient was seen after one and a half year and the knee was still healthy. Both patients were originally from Mali, which is located in the mycetoma endemic zone in the African continent. However, few reports have appeared in the literature describing the disease in Mali. The most recent report of 1996, written by Mahe

et al, showed that eumycetoma was apparently caused mainly by *M. mycetomatis*, but this author did not use molecular technology to really confirm this hypothesis (7). Our patients from Mali were living in France, but their clinical history showed that they most likely acquired the infection during their stay in Mali.

In fact most cases of mycetoma that are imported into the West are not easily diagnosed. The clinical picture of a subcutaneous mass, sinuses and discharge containing grains is diagnostic for mycetoma. However, a large number of etiological agents are able to cause this infection, and they all produce almost similar clinical condition. In addition, these microorganisms show poor morphological differentiation and usually present as sterile hyphae, this makes their identification rather difficult if not, impossible (4,6).

Molecular taxonomy and PCR now, for the first time, facilitate detailed studies on the incidence of mycetoma infection caused by *M. mycetomatis* and its physiologically similar agents.

REFERENCES

1. **Ahmed, A. O., M. M. Mukhtar, M. Kools-Sijmons, A. H. Fahal, S. de Hoog, B. G. van den Ende, E. E. Zijlstra, H. Verbrugh, E. S. Abugroun, A. M. Elhassan, and A. van Belkum** 1999. Development of a species-specific PCR-restriction fragment length polymorphism analysis procedure for identification of *Madurella mycetomatis*. *J Clin Microbiol.* **37**:3175-8.
2. **Boiron, P., R. Locci, M. Goodfellow, S. A. Gumaa, K. Isik, B. Kim, M. M. McNeil, M. C. Salinas-Carmona, and H. Shojaei** 1998. *Nocardia*, nocardiosis and mycetoma. *Med Mycol.* **36**:26-37.
3. **Boom, R., C. J. Sol, M. M. Salimans, C. L. Jansen, P. M. Wertheim-van Dillen, and J. van der Noordaa** 1990. Rapid and simple method for purification of nucleic acids. *J Clin Microbiol.* **28**:495-503.
4. **de Hoog, G. S., A. Buiting, C. S. Tan, A. B. Stroebel, C. Ketterings, E. J. de Boer, B. Naafs, R. Brimicombe, M. K. Nohlmans-Paulssen, G. T. Fabius, A.H. Klokke and C.G. Visser.** 1993. Diagnostic problems with imported cases of mycetoma in The Netherlands. *Mycoses.* **36**:81-7.
5. **de Hoog, G. S., J. Guarro, J. Gene, and M. J. Figueras** 2000. Atlas of clinical fungi, Second ed. Centraalbureau voor Schimmelcultures / Universitat Rovira i Virgili.
6. **de Hoog, S., D. Adelmann, A. Ahmed, and A. van Belkum** 2003. Phylogeny and typification of *Madurella mycetomatis*, with comparison of other agents of eumycetoma.. *Mycoses.* In press.
7. **Mahe, A., M. Develoux, C. Lienhardt, S. Keita, and P. Bobin** 1996. Mycetomas in Mali: causative agents and geographic distribution. *Am J Trop Med Hyg.* **54**:77-9.
8. **McGinnis, M. R.** 1996. Mycetoma. *Dermatol Clin.* **14**:97-104.
9. **White, T. J., T. Burns, S. Lee, and J. Taylor** 1996. Amplification and direct sequencing of fungal ribosomal RNA genes for phylogenetics, p. 315-322. *In* I. M. A., D. H. Gelfand, J. J. Sninsky, and T. J. White (eds), PCR protocols: a guide to method and applications. Academic Press, San Diego, Calif.

Chapter 4

Environmental Occurrence of *Madurella mycetomatis*, the Major Agent of Human Eumycetoma in Sudan

Abdalla O. A. Ahmed, Daniel Adelman, Ahmed Fahal, Henri Verbrugh, Alex van Belkum, and Sybren de Hoog

Journal of Clinical Microbiology, (2002) 40(3):1031-1036

ABSTRACT

Madurella mycetomatis is the main causative agent of human eumycetoma, a severe debilitating disease endemic in Sudan. It has been suggested that eumycetoma has a soil-borne or thorn prick-mediated origin. For this reason, efforts were undertaken to culture *M. mycetomatis* from soil samples ($n = 43$) and thorn collections ($n = 35$) derived from areas in which it is endemic. However, ribosomal sequencing data revealed that the black fungi obtained all belonged to other fungal species. In addition, we performed PCR-mediated detection followed by restriction fragment length polymorphism (RFLP) analysis for the identification of *M. mycetomatis* DNA from the environmental samples as well as biopsies from patients with mycetoma. In the case of the Sudanese soil samples, 17 out of 74 (23%) samples were positive for *M. mycetomatis* DNA. Among the thorn collections, 1 out of 22 (5%) was positive in the PCR. All PCR RFLP patterns clearly indicated the presence of *M. mycetomatis*. In contrast, 15 Dutch and English control soil samples were all negative. Clinically and environmentally obtained fungal PCR products share the same PCR RFLP patterns, suggesting identity, at least at the species level. These observations support the hypothesis that eumycetoma is primarily environmentally acquired and suggest that *M. mycetomatis* needs special conditions for growth, as direct isolation from the environment seems to be impossible.

INTRODUCTION

Eumycetoma is a subcutaneous fungal infection in which the etiological agent occurs in the form of more or less compact mycelial grains. The immune response is a granulomatous foreign body reaction characterized by impressive local necrosis and the formation of extensive fistula (8, 9, 18). Areas where eumycetoma is endemic are arid and hot climate zones with limited rainfall. A genuine "mycetoma belt" is found in tropical and subtropical regions, with foci in southern India, Somalia, Senegal, Argentina, and Sudan (12, 17). Cases are particularly common in Sudan, where, for example, Abbott (1) reported 1,231 cases in a 2.5-year period. The main causative agent of eumycetoma in Sudan is *Madurella mycetomatis* (4, 15). The disorder is supposed to originate from traumatic inoculation of plant material or soil contaminated by these fungi. Abbott (1) noted a history of thorn pricks in 10 out of 62 cases of mycetoma, and in two of these, there were actually thorns found embedded in tissue. Basset et al. (3) reported two cases with thorns inside lesions from which only non-*Madurella* fungi could be isolated. It is unlikely that *M. mycetomatis* represents a primary pathogen for humans. Rather, the fungi involved probably are saprophytes, which are able to tolerate uncharacteristic conditions when inoculated by coincidence. However, direct evidence for this hypothesis is still lacking. Thirumalachar and Padhye (22) were barely able to recover *M. mycetomatis* from soil. This is rather unexpected for a saprophytic fungus.

The present paper reports efforts to find *M. mycetomatis* in the environment in Sudan. Isolating fungi by culturing soils and thorns, which are preconditioned for traumatic inoculation, was attempted. Isolated strains were compared to patient strains from Sudan that were identified as *M. mycetomatis* (2). Environmental fungal isolates with a colony appearance resembling that of *Madurella* were identified and compared by molecular methods. In addition, direct PCR-mediated testing of environmental material was performed.

MATERIALS AND METHODS

Strains and culture conditions. Strains presented in the current study are listed in Table 1. Sudanese *Madurella* strains used for comparison were those of Ahmed et al. (2), isolated by direct culture of black grains obtained from deep biopsies of patient lesions at the Mycetoma Research Center, Khartoum, Sudan. They were maintained on malt extract agar (MEA) slants at 24°C and transferred to fresh tubes regularly to preserve viability. Reference strains, selected from genera being reported as agents of eumycetoma, were retrieved from the collection of the Centraalbureau voor Schimmelcultures (Utrecht, The Netherlands).

Cultivation of environmental pigmented fungi. Strains were cultured from soil and thorn samples collected in the Gezira area along the Blue Nile southeast of Khartoum, Sudan (Figure 1). From 43 samples (up to 20 cm in depth), 4 g of soil was suspended in 30 ml of sterile 0.9% saline by high-speed vortexing for 5 min. After settling, the supernatant was diluted 1:5 and 1:50 for inoculation of two or three MEA culture plates with 0.5 ml of the suspension.

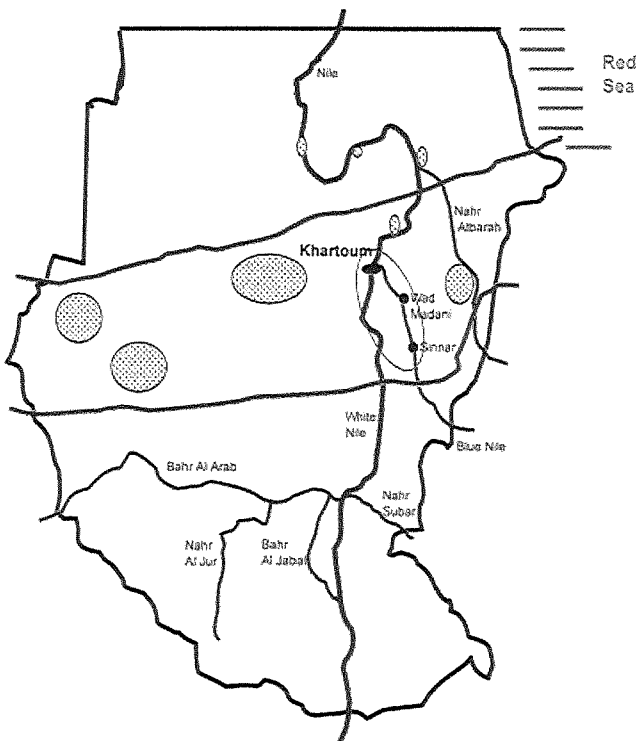


Figure 1: Detailed map of the region in Sudan where the thorns were collected and the soil was sampled. Main sampling sites were in the encircled region comprising the region southeastern to Khartoum (Wad Madani and Sinnar). Other regions where mycetoma is highly endemic are highlighted by the elliptic red-dot regions. The red bars indicate the boundaries of the Sudanese mycetoma belt.

Thirty-five thorn samples were collected and divided into two groups: fresh ones from green bushes (15 samples) and old ones lying on the ground or from old dry bushes (20 samples). Thorns primarily derived from the abundant species *Acacia mellifera*. Two or more thorns, depending on their size, were crushed in 2 ml of 0.9% sodium chloride solution. Two dilutions were made to inoculate two plates each (fresh thorns, 1:1 and 1:10; old thorns, 1:10 and 1:100). To decrease the number of contaminants in the case of several

samples, two thorns were briefly rubbed with a cotton swab with 70% ethanol before dilution (fresh thorns, 1:1; old thorns, 1:10) and used to inoculate two plates. Aliquots of 0.5 ml were used per culture plate with Sabouraud's dextrose agar (SDA) containing 100 mg of chloramphenicol/liter. Plates were incubated at 37°C and checked for appropriate colonies at 3-day intervals. Strains with a colony appearance similar to that of *M. mycetomatis* and exuding a rusty brown, diffusible pigment into the agar were selected (16, 22).

DNA isolation of fungi isolated from soil. For DNA extraction, about 1 cm² of mycelium was transferred to a 2:1 mixture of silica gel and Celite 545 with 300 µl of cetyltrimethylammonium bromide (CTAB) buffer (200 mM Tris-HCl, [pH 7.5], 200 mM Na-EDTA, 8.2% NaCl, 2% CTAB). The material was ground with a micro-pestle (Eppendorf). After adding an additional 200 µl of CTAB buffer and vigorous shaking, the sample was incubated for 10 min at 65°C in a water bath. An equal volume of chloroform was added, vortexed briefly, and centrifuged for 5 min at 14,000 rpm (model 5915C centrifuge; Eppendorf, Hamburg, Germany). After transferring the aqueous supernatant to a new Eppendorf tube, 2 volumes (≈800 µl) of 96% ethanol were added and mixed gently. DNA was precipitated at -20°C for at least 30 min. The pellet, obtained by centrifugation, was washed twice with 500 µl of 70% ethanol. DNA was dried overnight at room temperature and suspended in 97.5 µl of TE buffer (10 mM Tris, 10 mM Na-EDTA, pH 8.0) with 2.5 µl of RNase solution (200 U of pancreatic RNase A/ml in 0.01 M sodium acetate). Samples were incubated for 5 to 30 min at 37°C and stored at -20°C.

Ribosomal PCR and sequencing for identification of soil organisms. DNA samples isolated from unknown strains isolated from soil or thorns was analyzed by a general primer-mediated ribosomal PCR test. The rDNA internal transcribed spacer (ITS) domain was amplified with primers V9G and LS266 (11). Other primer combinations (V9G/ITS4, LS266/ITS5) were used in case of negative results. The near-complete SSU rDNA gene was amplified with primers NS1 and NS24. Of several programs used, optimal results were obtained with the following: 94°C for 5 min followed by 30 cycles of 94°C for 1 min, 48°C for 1 min, and 72°C for 2 min, followed by 72°C for 3 min. One unit of Super-Taq polymerase (Sphaero Q, Leiden, The Netherlands) was used for a 50-µl reaction mixture with 2 µl of DNA. In some cases, 6% dimethylsulfoxide (Merck, Darmstadt, Germany) was added. Amplicons were purified using the GFX PCR DNA and Gel Band Purification Kit according to the manufacturer's instructions (Amersham Pharmacia, Roosendaal, The Netherlands). Concentrations of amplicons were estimated by comparison with a marker (SmartLadder; Eurogentec, Seraing, Belgium) on a 1% agarose gel.

The sequencing reactions were carried out with 15 to 50 ng of DNA for a 10-µl reaction mixture, including 4 pmol of primer and 4 µl of BigDye RR Mix (Applied Biosystems) using primers ITS4 and ITS1 (ITS domain) or Oli1, Oli5, Oli9-11, Oli13, and Oli14 (reference 21 and Table 2) and NS24 (SSU gene) with 25 cycles, as follows: 96°C for 10 s, 50°C for 5 s, and 60°C for 4 min. Sequence reaction products were analyzed on an automated capillary sequencer (ABI, Gouda, The Netherlands). The sequences were adjusted using SeqMan of Lasergene software (DNASTAR Inc., Madison, Wis.) and analyzed using BioNumerics (Applied Maths, Kortrijk, Belgium). Sequences were compared to a set of dedicated sequences available at CBS (ITS fragment ITS 1+2, including 5.8S and the nearly complete SSU). Sequences of putative agents of eumycetoma were included (e.g., *Acremonium* spp., *Chaetomium*, *Neotestudina* spp., *Pseudallescheria*

spp., *Bipolaris*, *Leptosphaeria*, and *Madurella* spp.). The sequences alignment was considered confident when less than a 10% difference was observed. In case no match was found, sequences were run against the EMBL databank using BLAST.

Processing of soil and thorn samples for direct DNA testing. Two grams of soil (74 Sudanese samples, 14 Dutch controls, and 1 United Kingdom control) or four or five thorns ($n = 22$) were suspended in 5 or 2 ml of samples, sterile physiological saline containing 2% sodium dodecyl sulfate (SDS) (Merck, Darmstadt, Germany) and 5 mg of proteinase K (Merck). The samples were incubated at room temperature on a horizontal shaker for 10 min and then incubated at 37°C (1 h). One milliliter of the clear upper layer of the suspensions was extracted with an equal volume of phenol/chloroform/isoamyl alcohol (25:24:1). The DNA was precipitated from the aqueous layer with cold absolute ethanol (Merck). The pellet was washed once with 70% ethanol, air dried, and dissolved in 100 µl of sterile distilled water. This crude extract was further purified with the QIAmp Tissue kit (Qiagen, Hilden, Germany) according to the manufacturer's recommendations. The extracted DNA was then immediately tested by PCR.

PCR RFLP analysis of DNA extracted from thorns and soil samples. This analysis aimed at the broad-spectrum amplification of fungal DNA, followed by an *M. mycetomatis*-specific nested PCR. In the first PCR, ITS4 and ITS5 primers were used: 5'-TCCTCCGCTTATTGATATGC-3' and 5'-GGAAGTAAAAGTCGTAACAAGG-3', respectively (23). For the nested PCR, *M. mycetomatis* specific primers 26.1A (5'-AATGAGTTGGGCTTTAACGG-3') and (AATGAGTTGGGCTTTAACGG-3') and 28.3A (5'-TCCCGGTAGTGTAGTGT-CCCT-3') were employed (2). The PCRs were performed in 50-µl reaction volumes containing 0.2 U of SuperTaq polymerase (HT Biotech, Cambridge, United Kingdom), PCR buffer, deoxynucleotide triphosphate mix, 50 pmol of each primer, and 10 µl of extracted DNA (approximately 100 ng of DNA) in the first PCR round and 5 µl of the amplified material in the nested PCR. Cycling was performed in a model 60 thermocycler (Biomed, Theres, Germany) for 40 cycles (94°C for 1 min, 58°C for 1 min, 72°C for 3 min). PCR products were examined by electrophoresis in 1% agarose gels containing ethidium bromide (0.3 µg/ml). The electrophoresis was carried out in 0.5x Tris-borate-EDTA (TBE) buffer at a constant current of 100 mA for 1 h. Restriction fragment length polymorphism (RFLP) in the *M. mycetomatis* ITS regions was studied by analysis of the PCR products generated by primers 26.1A and 28.3A by cleavage with *CfoI*, *MspI* (Boehringer Mannheim GmbH, Mannheim, Germany), and *HaeIII* (New England Biolabs, Boston, Mass.) restriction enzymes. The restriction enzymes were used as recommended by the manufacturers. Fifteen microliters of PCR product was incubated overnight at 37°C with the restriction enzyme mixtures, which contained enzyme's buffer and 5 U of each enzyme per reaction. RFLP was determined by electrophoresis in 3% Nusieve GTG agarose gels (FMC Bioproducts, Rockville, Md.). The electrophoresis was performed in 0.5x TBE buffer at a constant current of 100 mA for 3 h.

Table 1: Survey of strains

Strain	Species	Source	Similarity with reference <i>M. mycetomatis</i> rRNA seq. ^a
Reference strains			
CBS 247.48	<i>M. mycetomatis</i>	United States (Gammel)	100%
CBS 201.38	<i>Madurella</i> sp. 1	Indonesia	Confident alignment ^b
CBS 248.48	<i>Madurella</i> sp. 1	New Mexico	Confident alignment
CBS 217.55	<i>Madurella</i> sp. 1	Argentina	Confident alignment
CBS 216.29	<i>Madurella</i> sp. 2	Italy	Distantly related
Clinical isolates			
DH11849	<i>M. mycetomatis</i>	Sudan, patient	0-bp difference
DH11850	<i>M. mycetomatis</i>	Sudan, patient	0-bp difference
DH11854	<i>M. mycetomatis</i>	Sudan, patient	0-bp difference
P2	<i>M. mycetomatis</i>	Sudan, patient	1-bp difference
DH11853	<i>M. mycetomatis</i>	Sudan, patient	2-bp difference
DH11862	<i>M. mycetomatis</i>	Sudan, patient	3-bp difference
Environmental isolates			
DH11963	<i>Exserohilum mcginnisii</i>	Sudan, soil	Nonrelevant
dH11959	<i>Bipolaris papendorfi</i>	Sudan, soil	Nonrelevant
dH11984	<i>Bipolaris spicifera</i>	Sudan, soil	Nonrelevant
4	<i>Ulospora bilgrami</i>	Sudan, thorn	Nonrelevant
5	<i>Ulospora bilgrami</i>	Sudan, thorn	Nonrelevant
6	<i>Ulospora bilgrami</i>	Sudan, thorn	Nonrelevant
7	<i>Ulospora bilgrami</i>	Sudan, thorn	Nonrelevant
8	<i>Ulospora bilgrami</i>	Sudan, thorn	Nonrelevant
9	<i>Chaetomium brasiliense</i>	Sudan, thorn	Nonrelevant
10	<i>Chaetomium murorum</i>	Sudan, soil	Nonrelevant
dH11971	<i>Phoma</i>	Sudan, thorn	Nonrelevant
dH11983	— ^c	Sudan, soil	Nonrelevant
dH11975	—	Sudan, soil	Nonrelevant

^a CBS 247.48 is considered to be the *M. mycetomatis* reference strain to which the ribosomal sequences for the other strains were matched for reasons of comparison.

^b“Confident alignment” indicates that difference was less than 10%.

^c—, isolates belong to currently undefined fungal species.

Table 2: Universal and *Madurella*-specific primers used for PCR and sequencing^a

Primer	Position (gene/nucleotides)	Reference	Primer sequence (5' → 3') ^b
ITS4	LSU/41–60	23	←TCCTCCGCTTATTGATATGC
ITS5	SSU/1745–1767	23	GGAAGTAAAAGTCGTAACAAGG→
V9D	SSU/1609–1627	6	TTAAGTCCCTGCCCTTTGTA→
LS266	LSU/287–266	19	←GCATTCCCAAACAACCTCGACTC
NS1	SSU/20–38	23	GTAGTCATATGCTTGTCT→
NS24	SSU/1769–1750	10	←AAACCTTGTTACGACTTTTA
Oli5	SSU/83–102	14	GAAACTGCGAATGGCTCATT→
Oli9	SSU/573–591	14	CGCGGTAATTCCAGCTCCA→
Oli10	SSU/951–935	14	←TGGYRAATGCTTTCGC
Oli11	SSU/962–980	14	TTRATCAAGAACGAAAGT→
Oli13	SSU/1418–1438	14	←ATAACAGGTCTGTGATGCC
Oli14	SSU/1418–1438	14	ATAACAGGTCTGTGATGCC→
26.1A ^c	ITS2/111–130	2	←AATGAGTTGGGCTTTAACGG
28.3A ^c	ITS1/474–494	2	TCCCGGTAGTGTAGTGTCCCT→

a Positions correspond to the *Saccharomyces cerevisiae* consensus sequence.

b R = purine A or G; Y = pyrimidine C or T.

c Primer sequences and positions are based on the *M. mycetomatis* ITS sequence (GenBank accession no. AF162133).

RESULTS

Cultivation and identification of soil- and thorn-borne fungi. Overall, 43 soil samples and 35 batches of thorns were analyzed for the presence of black-pigmented fungi resembling *M. mycetomatis*. Ultimately, 52 colonies from 24 samples were subcultured in a pure form on SDA. Strains were studied microscopically and by molecular analysis. None of the strains turned out to represent *M. mycetomatis* based on either morphological criteria or ribosomal sequencing. Some of the strains were excluded prior to sequencing based on ribosomal gene RFLP analyses (result not shown). Sequence results are listed in Table 1, presenting data for 13 environmental, 6 clinical, and 5 reference isolates. *M. mycetomatis* CBS 247.48 was found to be practically identical (0- to 3-bp difference) to six strains of cases of mycetoma from Sudan. CBS 247.48 might be Gammel's strain from Cleveland, Ohio, dating from 1927, which is the type strain of *Madurella americana*. Three further clinical strains putatively representing *M. mycetomatis* (CBS 201.38 from Indonesia, CBS 248.48 from New Mexico, and CBS 217.55 from Argentina) were found at some distance but could be aligned with confidence. *M. mycetomatis* CBS 216.29 from Italy was found to be different from both clusters. About 105 out of 190 positions of ITS1 and about 140 out of 160 positions of ITS2 of *M. mycetomatis* could be aligned with environmental *Chaetomium* species from Sudan, which were identified down to the species level by morphology and by comparison with sequences from the public domain. Three strains from Sudanese soil were found to be members of Pleosporales with distoseptate conidia, viz. *Exserohilummcginnisii*, *Bipolaris papendorfii*, and *Bipolaris spicifera*. Their ITS sequences showed no homology with *Leptosphaeria*. Five strains from Sudanese thorns and showing superficial resemblance to one of the known agents of mycetoma, *Neotestudina rosatii*, were morphologically identified as *Ulospora bilgramii* (13). Five reference strains of *N. rosatii* were clearly different but could be aligned with confidence. The type strain of *N. rosatii* CBS 427.62 originated from a case of mycetoma, whereas the remaining four strains were environmental (not shown in Table 1).

Although it is unlikely that *M. mycetomatis* in nature is present in the same form it is in patients, it is suggested that the isolation of this species directly from the environment is very difficult using the current protocols. Despite failed attempts to culture the organism, we now present data showing that it is possible to detect *M. mycetomatis* in the environment of areas in Sudan where it is endemic by molecular methods. In addition, thorny *A. mallifera* bushes, which are very common in the region sampled and are responsible for a high number of thorn pricks, were shown to occasionally harbor the same species of fungus. This supports the observation of Abbott (1) that the frequency of mycetoma is associated, albeit weakly, with the presence of thorny trees. The low recovery rate suggests, however, that *M. mycetomatis* is not an ordinary saprobe on the thorns.

Human subcutaneous inoculation apparently is an efficient selective means for recovery of the fungus. A comparable situation is known in black yeast-like fungi, where *Cladophialophora bantiana* (11) and *Fonsecaea pedrosoi* (De Hoog et al., unpublished data) are homologous examples. These fungi are thus far known only from mammals and can be obtained from the environment after mouse passage only. Interestingly, *F. pedrosoi* is one of the agents of chromoblastomycosis, which is also a mycosis associated with (minor) trauma.

Other fungal species (anamorph genera *Bipolaris*, *Drechslera*, and *Exserohilum*) were frequently isolated from soil in Sudan. Among these was *E. mcginnisii*, which thus far is only known from a single strain from a human patient and hence has been regarded as a true pathogen. However, its occurrence in the environment suggests that this is also one of the saprobes which only occasionally is able to infect a human host.

In conclusion, we have demonstrated the presence of *M. mycetomatis* DNA on or in *Acacia* thorns and in soil samples. The fungal prevalence in the soil especially suggests that this may be the prime reservoir from which infections originate. This is further corroborated by the fact that clinical isolates and environmental strains seem to share the same ribosomal genotype, confirming that at least the same fungal species is concerned. The challenge for current research is to elucidate the processes that underlie the culture-refractory nature of environmental *M. mycetomatis* isolates. Whether or not the fungus readily adapts to humans provides another interesting and important research topic.

ACKNOWLEDGMENTS

Part of this research was financed through a Young Investigators award provided to A.V. by the European Society of Clinical Microbiology and Infectious Diseases. D.A. thanks Boehringer-Ingelheim for financial support. A. Aptroot and G. Verkleij are acknowledged for their help with identification of fungi. R. C. Summerbell and A. A. Padhye are thanked for strains and for comments on the manuscript. K. Luijsterburg and A. H. G. Gerrits van den Ende are thanked for technical assistance.

REFERENCES

1. **Abbott, P.** 1956. Mycetoma in the Sudan. *Trans. R. Soc. Trop. Med. Hyg.* **50**:11-30.
2. **Ahmed, A. O. A., M. M. Mukhtar, M. Kool-Sijmons, A. H. Fahal, G. S. De Hoog, A. H. G. Gerrits van den Ende, E. E. Zijlstra, H. Verbrugh, A. M. El Sir Abugroun, A. M. Elhassan, and A. Van Belkum.** 1999. Development of a species-specific PCR-restriction fragment length polymorphism analysis procedure for identification of *Madurella mycetomatis*. *J. Clin. Microbiol.* **37**:3175-3178.
3. **Basset, A., R. Camain, R. Baylet, and D. Lambert.** 1965. Role des épines de mimosacées dans l'inoculation des mycétomes (à propos de deux observations). *Bull. Soc. Pathol. Exot.* **58**:22-24.
4. **Brumpt, E.** 1906. Les mycétomes. Asselin & Houzeau, Paris, France.
5. **De Hoog, G. S., A. Buiting, C. S. Tan, A. B. Stroebel, C. Ketterings, E. J. De Boer, B. Naafs, R. Brimicombe, M. K. E. Nohlmans-Paulssen, G. T. J. Fabius, A. H. Klokke, and L. G. Visser.** 1993. Diagnostic problems with imported cases of mycetoma in The Netherlands. *Mycoses* **36**:81-87.
6. **De Hoog, G. S., and G. van den Ende.** 1998. Molecular diagnostic of clinical strain of filamentous Basidiomycetes. *Mycoses* **41**:183-189.
7. **De Hoog, G. S., F. D. Marvin-Sikkema, G. A. Lahpor, J. C. Gottschall, R. A. Prins, and E. Gueho.** 1994. Ecology and physiology of the emerging opportunistic fungi *Pseudallescheria boydii* and *Scedosporium prolificans*. *Mycoses* **37**:71-78.
8. **El Hassan, A. M., A. H. Fahal, I. A. El Hag, and E. A. G. Khalil.** 1994. The pathology of mycetoma. *Sudan Med. J.* **32**(Suppl. 1):23-45.
9. **Fahal, A. H., and S. H. Suliman.** 1994. Clinical presentation of mycetoma. *Sudan Med. J.* **32**:46-66.
10. **Gargas, A., and J. W. Taylor.** 1995. Phylogeny of Discomycetes and early radiation of apothecial Ascomycotina inferred from SSU rDNA sequence data. *Exp. Mycol.* **19**:7-15.
11. **Gerrits van den Ende, A. H. G., and G. S. De Hoog.** 1999. Variability and molecular diagnostics of the neurotropic species *Cladophialophora bantiana*. *Stud. Mycol.* **43**:152-162.
12. **Gumaa, S. A.** 1994. The aetiology and epidemiology of mycetoma. *Sudan Med. J.* **32**(Suppl. 1):14-22.
13. **Hawksworth, D. L.** 1979. Ascospore sculpturing and generic concepts in the *Testudinaceae* (syn. Zopfiaceae). *Can. J. Bot.* **57**:91-99.

14. **Hendriks, L., Y. van de Peer, M. van Herck, J. M. Neefs, and R. De Wachter.** 1990. The 18S ribosomal RNA sequence of the sea anemone *Anemonia sulcata* and its evolutionary position among other eukaryotes. *FEBS Lett.* **269**:445-449.
15. **Laveran, M. A.** 1902. Au sujet d'un cas de mycetoma à grains noirs. *Bull. Acad. Med. Paris* **47**:773-776.
16. **Mackinnon, J. E.** 1954. A contribution to the causal organisms of maduromycosis. *Trans. R. Soc. Trop. Med. Hyg.* **48**:470-480.
17. **Mahgoub, E. S., and I. G. Murray.** 1973. *Mycetoma*. William Heinemann, London, United Kingdom.
18. **Mariat, F., P. Destombes, and G. Segretain.** 1977. The mycetomas: clinical features, pathology, etiology, and epidemiology. *Contrib. Microbiol. Immunol.* **4**:1-39.
19. **Masclaux, F., E. Gueho, G. S. de Hood, and R. Christen.** 1995. Phylogenetic relationship of human-pathogenic *Cladosporium* (Xylohypha) species inferred from partial LS rRNA sequences. *J. Med. Vet. Mycol.* **33**:327-338.
20. **Rippon, J. W.** 1988. *Medical mycology. The pathogenic fungi and the pathogenic actinomycetes*, 3rd ed. Saunders, Philadelphia, Pa.
21. **Sterflinger, K., R. De Baere, G. S. De Hoog, R. De Wachter, W. E. Krumbein, and G. Haase.** 1997. *Coniosporium perforans* and *C. apollinis*, two new rock-inhabiting fungi isolated from marble in the Sanctuary of Delos (Cyclades, Greece). *Antonie Leeuwenhoek* **72**:349-363.
22. **Thirumalachar, M. J., and A. A. Padhye.** 1968. Isolation of *M. mycetomi* from soil in India. *Hindustan Antibiot. Bull.* **10**:314-318.
23. **White, T. J., T. Burns, S. Lee, and J. Taylor.** 1990. Amplification and direct sequencing of fungal ribosomal RNA genes for phylogenetics, p. 315-322. *In* M. A. Innis, D. H. Gelfand, J. J. Sninsky, and T. J. White (ed.), *PCR protocols: a guide to methods and applications*. Academic Press, San Diego, Calif.

Chapter 5

Phylogeny and Typification of *Madurella mycetomatis*, with a Comparison of Other Agents of Eumycetoma

G.S. de Hoog, D. Adelman, A.O.A. Ahmed and A. van Belkum

Mycoses, (2003). In press

ABSTRACT

The genus *Madurella*, described for non-sporulating agents of human mycetoma, is proven to be heterogeneous on the basis of rDNA SSU and ITS sequencing data. *Madurella mycetomatis*, the main agent of mycetoma in arid zones of Central and East Africa, probably belongs to the ascomycete order Sordariales. *Madurella mycetomatis*, the generic type species, is neotypified. *M. grisea*, with world wide occurrence, is likely to be a member of the order Pleosporales, just as the mycetoma agents of *Leptosphaeria*, *Pseudochaetosphaeronema* and *Pyrenochaeta*. *Neotestudina rosatii* belongs to the order Dothideales. Judging from ITS data, *M. mycetomatis* and *N. rosatii* are species complexes. The ex-type strain of *N. rosatii*, from a human mycetome, has an ITS sequence that deviates from that of environmental strains of the species.

INTRODUCTION

Eumycetoma is a massive subcutaneous fungal infection from which the etiological agent emerges in the form of more or less compact mycelial grains. The immune response is a granulomatous foreign body reaction (26) characterized by local necrosis and the formation of fistels (28, 42). The disorder is supposed to originate from accidental traumatic inoculation of plant material such as thorns or splinters contaminated with fungi. For example, Abbott (1) noted a history of thorn pricks in 10 out of 62 cases of mycetoma and in two of these found thorns still embedded in infected tissue. Basset *et al.* reported on two cases with thorns inside lesions from which *Leptosphaeria senegalensis* Segretain *et al.* and *Pyrenochaeta romeroi* Borelli could be isolated (7). Judging from these case histories it is likely that the agents of mycetoma reside in the environment in regions endemic for the disease. They are supposed to be saprotrophic fungi able to survive hostile conditions in their natural niche and able to cause mycoses in humans when inoculated by coincidence.

However, recent findings on *Madurella mycetomatis* (Laveran) Brumpt are not in line with this view. This species is preponderant in cases of eumycetoma in Sudan. Abbott reported 1231 cases in a 2.5 year period (1). Ahmed *et al.* noted that clinical isolates are genetically identical (2). This suggests that living human tissue provides a suitable source for growth of the species. The fungus thus must possess a specialized pathogenic potential, which is unlikely for a saprotroph on plant material.

The genus *Madurella* was defined primarily for sterile mycelia (22). Hence, degenerate cultures may easily have been mistaken for that species. De Hoog *et al.* found that strains from imported cases of mycetoma in The Netherlands and originally identified as *M. mycetomatis* actually concerned a wide diversity of degenerate fungal strains (21). In the present study *M. mycetomatis* is taxonomically redefined by comparing superficially similar clinical and environmental strains with reference strains from an established culture collection (2). Fresh isolates originated from Sudan, which is a part of a 'mycetoma-belt' with further foci in southern India, Somalia and Senegal (41). This endemic area is characterized by an arid and hot climate with 50-500 mm rainfall concentrated in short periods between June and October.

MATERIALS AND METHODS

Culture conditions. Environmental isolates from Sudan are those listed by Ahmed *et al.* (2). Clinical

isolates were obtained by deep biopsy at the Mycetoma Research Center, Khartoum, Sudan. They were maintained on malt extract agar (MEA) slants at 24°C and transferred to fresh tubes every six months. Reference strains, selected from genera which in the literature were reported to comprise agents of eumycetoma (Table 1), were retrieved from the collection of the Centraalbureau voor Schimmelcultures (Utrecht, The Netherlands).

DNA extraction. Two protocols were used:

1. About 1 cm² of mycelium was transferred to a 2 : 1 mixture of silicagel and Celite 545 with 300 µl CTAB-buffer (Tris.HCl, 200 mM, pH 7.5; Na-EDTA, 200 mM; NaCl 8.2%; cetyltrimethylammonium bromide [CTAB] 2%). The material was ground with a micropestle (Eppendorf). After adding 200 µl CTAB-buffer and vigorous shaking the sample was incubated for 10 min in a 65°C waterbath. 500 µl Chloroform was added, vortexed briefly and centrifuged for 5 min at 14,000 rpm. After transferring the aqueous supernatant to a new Eppendorf tube, 2 volumes (~800 µl) ethanol 96%, -20°C were added and mixed gently. The DNA was precipitated at -20°C for at least 30 min. The pellet obtained by centrifuging 5 min at 14,000 rpm was washed twice with 500 µl ethanol 70%, -20°C. The DNA was dried overnight at room temperature and suspended in 97.5 µl TE-buffer (10 mM Tris, 10 mM Na-EDTA, pH 8.0) with 2.5 µl RNase-solution (10 mg pancreatic RNase 20 U/mg in 1 ml 0.01 M Na-acetate). Samples were incubated for 5-30 min at 37°C and stored in a refrigerator.
2. The FastDNA® Kit (Bio101, Carlsbad, Ca., U.S.A.) was used with 1 cm² of mycelium homogenized with a Lysing Matrix and Cell Lysing Solution (CLS-Y) in the FastPrep® Instrument. After centrifugation a Binding Matrix containing guanidine thiocyanate was added to the supernatant. The bound DNA was washed with Salt/Ethanol Wash Solution (SEWS-M) and collected with a DNA Elution Solution (DES). When checked on 1% agarose gel, the FastDNA® Kit resulted in a better quality of DNA, but less quantity.

PCR. The rDNA Internal Transcribed Spacer (ITS) region was amplified with primers V9G and LS266(32). Other primer combinations (V9G / ITS4, LS266 / ITS5) were used in case of negative result. The near-complete SSU rDNA gene was amplified with primers NS1 and NS24-UCB (31) and sequenced with primers listed by De Hoog *et al.* (22). Of several programs used, optimal results were obtained with the following: predwell (94°C, 5'), then 30 cycles of denaturation (94°C, 1'), annealing (48°C, 1') and elongation (72°C, 2'), followed by postdwell (72°C, 3'). One unit Super-Taq polymerase (ITK Diagnostics, Leiden, The Netherlands) was used for a 50 µl reaction mixture with 2 µl raw DNA. In some cases 6% dimethylsulfoxide (Merck) was added. Amplicons were purified using GFX™ and Gel Band Purification Kit (Amersham Pharmacia, Roosendaal, The Netherlands). DNA was bound to the GFX-column with a Capture-buffer (containing acetate and chaotrope), washed with a wash-buffer (containing Tris-EDTA and ethanol) and collected with TE-buffer. Concentrations of amplicons were estimated by comparison with known concentrations of SmartLadder (Eurogentec, Seraing, Belgium) on a 1% agarose gel.

RFLP. Twenty two environmental and 14 reference strains were used for a Restriction Fragment Length Polymorphism (RFLP) analysis of the ITS spacer domain amplified with primers ITS1 and ITS4 (58). Eight µl of the amplicon solution was incubated with two units of the endonucleases *HhaI* and *HaeIII* (Amersham Pharmacia) at 36°C overnight.

Sequencing and identification. The sequencing reaction was carried out with 15-50 ng of DNA for a 10 µl reaction including 4 pmol primer and 4 µl BigDye RR Mix (Applied Biosystems, Nieuwerkerk a.d. IJssel, The Netherlands) using primers ITS1 and ITS4 (58) for the ITS region or Oli1, Oli5, Oli9, Oli10, Oli11, Oli13 and Oli14(53) for the SSU gene with 25 cycles, as follows: 96°C, 10"; 50°C, 5"; 60°C, 4'. DNA was precipitated with ethanol and sequenced on an ABI Prism™ 310 Genetic Analyzer (Applied Biosystems) automated capillary sequencer. The sequences were adjusted using SeqMan of Lasergene software (DNASar, Madison, Wisconsin, U.S.A.) and aligned using BioNumerics (Applied Maths, Kortrijk, Belgium). Sequences were compared to a set of dedicated sequences available for research purposes at CBS. This database was made on the basis of the known spectrum of agents of mycetoma (Table 1; taxonomic relationships according to De Hoog *et al.*(22)). Groups of agents with strictly uncoloured hyphae were not taken into account. In case no match was found they were run against the GenBank sequences using BLASTn (5).

Tree reconstruction. A distance tree of near-complete SSU rDNA sequences was generated using Neighbor joining algorithm with Kimura correction in the TREECON package (version 1.3b) (57); bootstrap values were calculated from 100 re-sampled data sets.

RESULTS.

Selected strains analyzed are listed in Table 2. Since many of them failed to produce reproductive structures *in vitro*, strains potentially matching *M. mycetomatis* were screened by using RFLP of the rDNA ITS region. The Sudanese strains from cases of mycetoma had profiles identical to those of five *M. mycetomatis* reference strains from the CBS collection (CBS 247.48, 216.29, 201.38, 217.55) and of *Madurella* sp. CBS 248.48. The set of remaining mycetoma strains compared, comprising *Pseudochaetosphaerionema*, *Pyrenochaeta*, *Leptosphaeria*, *Neotestudina*, as well as *Madurella grisea* MacKinnon *et al.* and CBS 868.95 of *M. mycetomatis*, were consistently different. One strain of *M. mycetomatis*, CBS 246.66, appeared to be misidentified, as it was found to be identical to *M. grisea* (Table 2).

ITS sequence data (not shown) of *M. mycetomatis*, CBS 247.48 was found to be nearly identical (1-7 bp difference) to five strains from cases of mycetoma in Sudan and two in Mali. CBS 247.48 is possibly Gammel's (29) strain from the U.S.A., which may be the ex-type strain of *Madurella ikedae* Gammel; we were unable to ascertain the history of this strain in the CBS archives. Four further clinical strains, CBS 201.38, from Indonesia, CBS 248.48, from New Mexico, U.S.A., CBS 216.29, from Italy, and CBS 217.55, from Argentina, clustered at significant distance (average 5.3%) but could be aligned with confidence. The differences were not detected by *HaeIII* and *HhaI* digestion. None of these isolates was a type strain of any described species. The distance from *M. mycetomatis* involved 38 bp. Variability within the group was noted at 8 positions, none of which was phylogenetically informative. Distances to remaining species compared were too large to allow meaningful tree reconstruction. Nearest neighbours found in GenBank were members of the genera *Thielavia*, *Corynascus* and *Chaetomium*; all are classified in the ascomycete order Sordariales. Only partial ITS alignment was possible with corresponding sequences of *M. mycetomatis*, as they deviated at least 9%. *M. mycetomatis* CBS 868.95, isolated in The Netherlands from a patient originating from the

Caribbean, was very different and could not be aligned to any of the fungi mentioned above.

Sequencing of the total SSU rDNA gene of *M. mycetomatis*, CBS 247.48 revealed that *Chaetomium elatum* Kunze:Fr. (GenBank M83257) was its nearest neighbour (Ascomycetes: Sordariales), at 6 bp difference (Fig. 1). Further genera found close to CBS 247.48 were *Neurospora*, *Sordaria* and *Podospora*, which all belong to the order Sordariales.

Sequencing of the total SSU rDNA gene of an authentic strain of *Madurella grisea*, CBS 331.55, revealed that it clustered in the middle of a clade with species of the genera *Leptosphaeria*, *Cucurbitodithis*, *Westerdykella*, *Sporormia* and related genera (Fig. 1), with *Leptosphaeria bicolor* D. Hawksworth *et al.* as its nearest neighbour at 89 bp difference. All these genera are members of ascomycetes known to belong to the order Pleosporales.

ITS sequences of species of *M. mycetomatis*, *Chaetomium*, and other members of Sordariales could not be aligned to any of the above species with purported affinity to the order Pleosporales including *M. grisea*; even partial alignment did not produce acceptable levels of confidence. A separate comparison was therefore made for *M. grisea* with the coelomycetous agents of eumycetoma *Pyrenochaeta romeroi*, *P. mackinnonii* Borelli and *Pseudochaetosphaeronema larense* (Borelli & Zamora) Punithalingam, plus the ascoma-forming agents classified in *Leptosphaeria*. The mutual distances were large (Table 2), with percentages difference between 27.5 and 31.2. Only very small parts of the ITS regions of the extremes of the cluster, i.e. *Leptosphaeria senegalensis* and *L. thompkinsii* El-Ani on the one hand and *Madurella grisea* on the other, could be aligned with confidence. Two strains of *M. grisea*, CBS 331.50, CBS 332.50 (both authentic strains from J.E. MacKinnon), and one of *M. mycetomatis*, CBS 246.66, were found to be identical to each other. This species took a rather isolated position. ITS regions of other members of the Pleosporales, such as *Alternaria*, *Bipolaris* and *Curvularia*, could not be aligned to the remaining pleosporalen fungi (data not shown).

Table 1: Genera containing agents of mycetoma with their proposed phylogentic position, the later taken from de Hoog *et al.* (22) and from the present paper. Genera containing established agents (22) are printed in bold type; occasional agents are cited with reference to case reports.

Name	Order	Grain	Reference
<i>Fusarium falciforme</i> *	Hypocreales	White	
Acremonium kiliense	Hypocreales	White	
<i>Acremonium cf. potronii</i>	Hypocreales	White	(17)
Acremonium recifei	Hypocreales	White	(18)
<i>Cylindrocarpon cyanescens</i>	Hypocreales	White	(19)
<i>Cylindrocarpon destructans</i>	Hypocreales	White	(60)
<i>Fusarium verticillioides</i>	Hypocreales	White	(4)
<i>Fusarium solani</i>	Hypocreales	White	(33)
<i>Phialemonium obovatum</i> (originally published as <i>Acremonium hyalinulum</i>)(dog)	Hypocreales	White	(36)
<i>Aspergillus flavus</i>	Eurotiales	White	(59)
<i>Aspergillus hollandicus</i> (=A. <i>vitis</i>)	Eurotiales	White	(17, 44)
<i>Aspergillus nidulans</i>	Eurotiales	White	(8, 41)
<i>Bipolaris spicifera</i>	Pleosporales	Black	(34, 49)
<i>Corynespora cassiicola</i>	Pleosporales	Black	(40)
<i>Curvularia geniculata</i> (dog, horse)	Pleosporales	Black	(9, 12, 13)
<i>Curvularia lunata</i>	Pleosporales	Black	(12, 38, 41)
Leptosphaeria senegalensis	Pleosporales	Black	(50)
Leptosphaeria thompkinsii	Pleosporales	Black	(27)
Madurella grisea	Pleosporales	Black	(52)
Pseudochaetosphaeronema larense	Pleosporales	Black	(11)
Pyrenochaeta mackinnonii	Pleosporales	Black	(10)
Pyrenochaeta romeroi	Pleosporales	Black	
Madurella mycetomatis	Sordariales	Black	
<i>Phaeoacremonium parasiticum</i>	Sordariales	Black	(37)
<i>Neotestudina rosatii</i>	Dothideales	White	(35)
<i>Exophiala jeanselmei</i>	Chaetothyriales	Black	(43)
<i>Phialophora verrucosa</i>	Chaetothyriales	Black	(45, 56)
<i>Rhinocladiella atrovirens</i>	Chaetothyriales	Black	(25)
Pseudallescheria boydii	Microascales	White	
<i>Polycytella hominis</i>	Microascales	White	(15)
<i>Trichophyton</i>	Onygenales	White	
<i>Dermatophyte</i>	Onygenales	White	(16)

* Until recently known as *Acremonium falciforme* (54)

Table 2: *Madurella* strains identity

Original name	Number	Source	Locality	ITS differences			Final identification
				%	IP	b.p	
Sordariales:							
<i>M. mycetomatis</i>	CBS 109801NT	Foot	Sudan	-	0	8	<i>M. mycetomatis</i>
<i>M. mycetomatis</i>	CBS 247.48	Foot	USA	-	0	8	<i>M. mycetomatis</i>
<i>M. mycetomatis</i>	CBS 110359	Foot	Mali	-	0	8	<i>M. mycetomatis</i>
<i>M. mycetomatis</i>	P2	Foot	Mali	-	0	8	<i>M. mycetomatis</i>
<i>M. mycetomatis</i>	DH11854	Foot	Sudan	-	0	8	<i>M. mycetomatis</i>
<i>M. mycetomatis</i>	DH11849	Foot	Sudan	-	0	8	<i>M. mycetomatis</i>
<i>M. mycetomatis</i>	DH11850	Foot	Sudan	-	0	8	<i>M. mycetomatis</i>
<i>M. mycetomatis</i>	CBS 110087	Foot	Sudan	-	0	8	<i>M. mycetomatis</i>
<i>M. mycetomatis</i>	CBS 216.29	?	Italy	5.3	38	8	<i>M. species 1</i>
<i>M. mycetomatis</i>	CBS 201.38	Foot	Indonesia	5.3	38	8	<i>M. species 1</i>
<i>M. mycetomatis</i>	CBS 217.55	Hand	Argentina*	5.3	38	8	<i>M. species 1</i>
<i>M. species</i>	CBS 248.48	?	New Mexico	5.3	38	8	<i>M. species 1</i>
Dothideales:							
<i>N. rosatii</i>	CBS 331.78	Seed	India	39.5	23	1	<i>N. species 1</i>
<i>N. rosatii</i>	CBS 628.74	Soil	Egypt	39.5	23	1	<i>N. species 1</i>
<i>N. rosatii</i>	CBS 271.75	Soil	India	39.5	23	1	<i>N. species 1</i>
<i>N. rosatii</i>	CBS 690.82	Seed	Japan	39.5	23	1	<i>N. species 1</i>
<i>N. rosatii</i>	CBS 247.62T	Foot	Somalia	38.5	0	0	<i>N. rosatii</i>
<i>U. bilgramii</i>	DH11974	Thorn	Sudan	38.6	37	0	<i>U. bilgramii</i>
<i>U. bilgramii</i>	CBS 110020	Thorn	Sudan	38.6	37	0	<i>U. bilgramii</i>
<i>U. bilgramii</i>	DH11978	Thorn	Sudan	38.6	37	0	<i>U. bilgramii</i>
<i>U. bilgramii</i>	DH11979	Thorn	Sudan	38.6	37	0	<i>U. bilgramii</i>
<i>U. bilgramii</i>	DH11980	Thorn	Sudan	38.6	37	0	<i>U. bilgramii</i>
Pleosporales:							
<i>M. grisea</i>	CBS 331.50AUT	Foot	Argentina	-	0	0	<i>M. grisea</i>
<i>M. grisea</i>	CBS 332.50AUT	Foot	Chile	-	0	0	<i>M. grisea</i>
<i>M. mycetomatis</i>	CBS 246.66	Jaw	India	-	0	0	<i>M. grisea</i>
<i>Pseud. larense</i>	CBS 640.73T	Man	Venezuela	27.5	-	-	<i>Pseud. larense</i>
<i>Pyr. mackinnonii</i>	CBS 674.75T	Man	Venezuela	30.3	-	-	<i>Pyr. mackinnonii</i>
<i>Pyr. mackinnonii</i>	CBS 110022	Foot	Mexico	30.4	-	-	<i>Pyr. mackinnonii</i>
<i>Pyr. romeroi</i>	CBS 252.60T	Man	Venezuela	29.0	-	-	<i>Pyr. romeroi</i>
<i>L. thompkinsii</i>	CBS 200.79	Man	Senegal	29.6	-	-	<i>L. thompkinsii</i>
<i>L. thompkinsii</i>	CBS 201.79	Man	Senegal	29.6	-	-	<i>L. thompkinsii</i>
<i>L. senegalensis</i>	CBS 196.79T	Man	Senegal	31.2	-	-	<i>L. senegalensis</i>
Phylogenetic position doubtful:							
<i>M. mycetomatis</i>	CBS 868.95	Foot	Aruba**	-	-	-	<i>M. species 2</i>

Note: ITS differences: IP = Informative positions (mutations and indels) compared to flanking species (direction of comparison indicated by arrows); b.p = single nucleotide polymorphisms (mutation and indels) listed as variance within the species; if not alignable with confidence, a percentage difference over ITS domain is listed only. *L*=*Leptosphaeria*; *M*=*Madurella*; *N*=*Neotestudina*; *Pseud* = *Pseudochaetosphaeronema*; *Pyr* = *Pyrenochaeta*; *U* = *Ulospora*;

* Reference number (47); ** Reference number (24).

Five strains from Sudanese thorns, isolated during a search for environmental strains of *M. mycetomatis* (2), were morphologically identified as *Ulospora bilgramii* (D. Hawksworth *et al.*) D. Hawksworth *et al.*, a species with close morphological similarity to the known agent of mycetoma, *Neotestudina rosatii* Segretain & Destombes (Dothideales) (35). The ITS sequences differed in 37 bp from the ex-type strain of *N. rosatii* (Table 2), CBS 427.62, but could be aligned with confidence. CBS 427.62 originated from a case of human mycetoma in Somalia, a country located in the dry climate zone of eastern Africa. Four environmental strains in the CBS collection, morphologically identified as *N. rosatii*, proved to differ from CBS 427.62 in 23 positions (Table 2). The deviating strains all originated from (sub)tropical countries outside Africa. ITS sequences of neither *Ulospora* nor *Neotestudina* were alignable to *M. mycetomatis* or *M. grisea*.

DISCUSSION

Two diametrically opposing theories on the etiology of human eumycetoma have appeared in the literature. The classical view (*hypothesis-1*) is that a relatively limited list of causative agents exists, which contains established pathogens typically causing mycetoma. A widely used list is that of Rippon (48). The view is supported by the overrepresentation of a small number of species involved in the numerous reported cases of eumycetoma, such as *Acremonium* spp., *Pseudallescheria boydii* (Shear McGinnis *et al.* and *Madurella* spp.

Alternatively (*hypothesis-2*) it has been suggested that mycetoma is an unspecific response to the subcutaneous inoculation of a wider range of principally saprotrophic agents. There are three arguments supporting this view. The first of these is theoretical: it is difficult to imagine how a fungus can be successful in its evolution when it is dependent on the unnatural situation of being traumatically introduced into its host. Accidental infections ecologically must be a 'spill-over', because no transmission to another host is possible (22, 46). Secondly, when more ecological data become available on agents of mycetoma such as *P. boydii* or *A. killiense* Grütz, it is realized that even the most common species on Rippon's list of agents of mycetoma actually have another ecological behaviour as mainstay, in which subcutaneous growth in humans is insignificant (6, 23, 30). Thirdly and perhaps most importantly, there are large problems with the correct identification of agents of mycetoma. Most agents show poor morphological differentiation or are sterile, and hence, given Rippon's restricted list of well-known etiologic agents, a clinician can easily pick one of these names for the isolate at hand (48). This was underpinned by De Hoog *et al.*, who showed that only a small portion of the agents from imported cases in The Netherlands actually concerned recognized members from Rippon's list (21, 48). It was therefore surmised that anything cultivated from a subcutaneous grain and showing reduced growth without reproduction *in vitro* might incorrectly be identified as '*Madurella*'.

Recent molecular data suggest that both suppositions are partly correct (2, 3). The spectrum of potential agents is larger than anticipated and includes a number of undescribed taxa, favouring *hypothesis-2*. On the other hand, in geographically limited areas a marked preponderance is noted of one or a few fungal species only, suggesting correctness of *hypothesis-1*. Strains identified as *Madurella* indeed represent a delimited taxonomic entity, rather than an amalgam of poorly

differentiated strains. Below the currently known species of *Madurella* and their relatives, and *Neotestudina*-like fungi isolated from the *M. mycetomatis* endemic zone, are discussed.

Madurella mycetomatis

Thirumalachar & Padhye obtained *M. mycetomatis* from soil, although at an extremely low recovery rate (55). Ahmed *et al.* found that *M. mycetomatis* was detectable from culture-negative environmental samples by nested PCR (2). When the species is extremely refractory to direct isolation, subcutaneous inoculation of *M. mycetomatis* into living mammal tissue apparently enhances growth of the fungus. A comparable situation is known in black yeast-like fungi, where *Cladophialophora bantiana* (Sacc.) Gerrits van den Ende and de Hoog *et al.* (32) and *Fonsecaea pedrosoi* (Brumpt) Negróni (20) were shown to contain only clinical strains, environmental isolation being possible only by enrichment in living mammal tissue. Interestingly, *F. pedrosoi* is one of the agents of chromoblastomycosis, which is also a post-traumatic (sub)cutaneous mycosis. The supposition that traumatically inoculated species are likely to be strict saprotrophs is falsified for at least some fungi.

M. mycetomatis is likely to be restricted to Sudan and adjacent countries for climatic reasons. Ahmed *et al.*, using ITS RFLP, found all clinical strains from Sudan to be identical to CBS 247.48. This was confirmed by sequence data of the same domain (2, 3). Proven cases caused by this species originated from Sudan and Mali (Table 2), both countries having a desert-like climate. CBS 247.48 is probably (judging from correspondence of J.A. Gammel in the CBS archives) the ex-type strain of *Madurella ikedae* Gammel, currently a synonym of *M. mycetomatis* (22). In that case the strain would originate from a case of eumycetoma in Texas, U.S.A., a region also having a dry climate (29). The CBS collection holds a number of strains from other climatic zones which showed more than 5% ITS difference and thus are likely to be a separate species (Table 2). A precise taxonomic definition of *M. mycetomatis* (*s. str.*) is overdue.

No holotype material of *M. mycetomatis* is known to be preserved. Laveran (39) described the first fungal isolate from a case of mycetoma from Djibouti, at about 1000 km east of Khartoum (Sudan), as *Streptothrix mycetomi* Laveran. *Streptothrix* is a genus of Actinomycetes. Therefore Brumpt erected the genus *Madurella* for fungal agents of mycetoma producing grains in tissue, *in vitro* exuding a brownish pigment into the medium and remaining sterile (14). He renamed Laveran's species as '*Madurella mycetom?*' (correct Latin is *M. mycetomatis*). Clinical strains tend to produce sclerotium-like bodies *in vitro* on casein-agar. Brumpt's description exactly matches the prevalent genotype isolated from clinical cases around Khartoum, and therefore we have no doubt that this is indeed the taxon that was described by Laveran (3, 14, 39). We indicate one of the Sudanese strains, CBS 109801, from a mycetoma of the foot of a human patient, as **neotype** of *M. mycetomatis*. Using SSU and ITS rDNA sequence data, the ascomycete genus *Chaetomium* (Sordariales) was found among the closest relatives of *M. mycetomatis*. This suggests that *M. mycetomatis* is a sterile member of the order Sordariales (14).

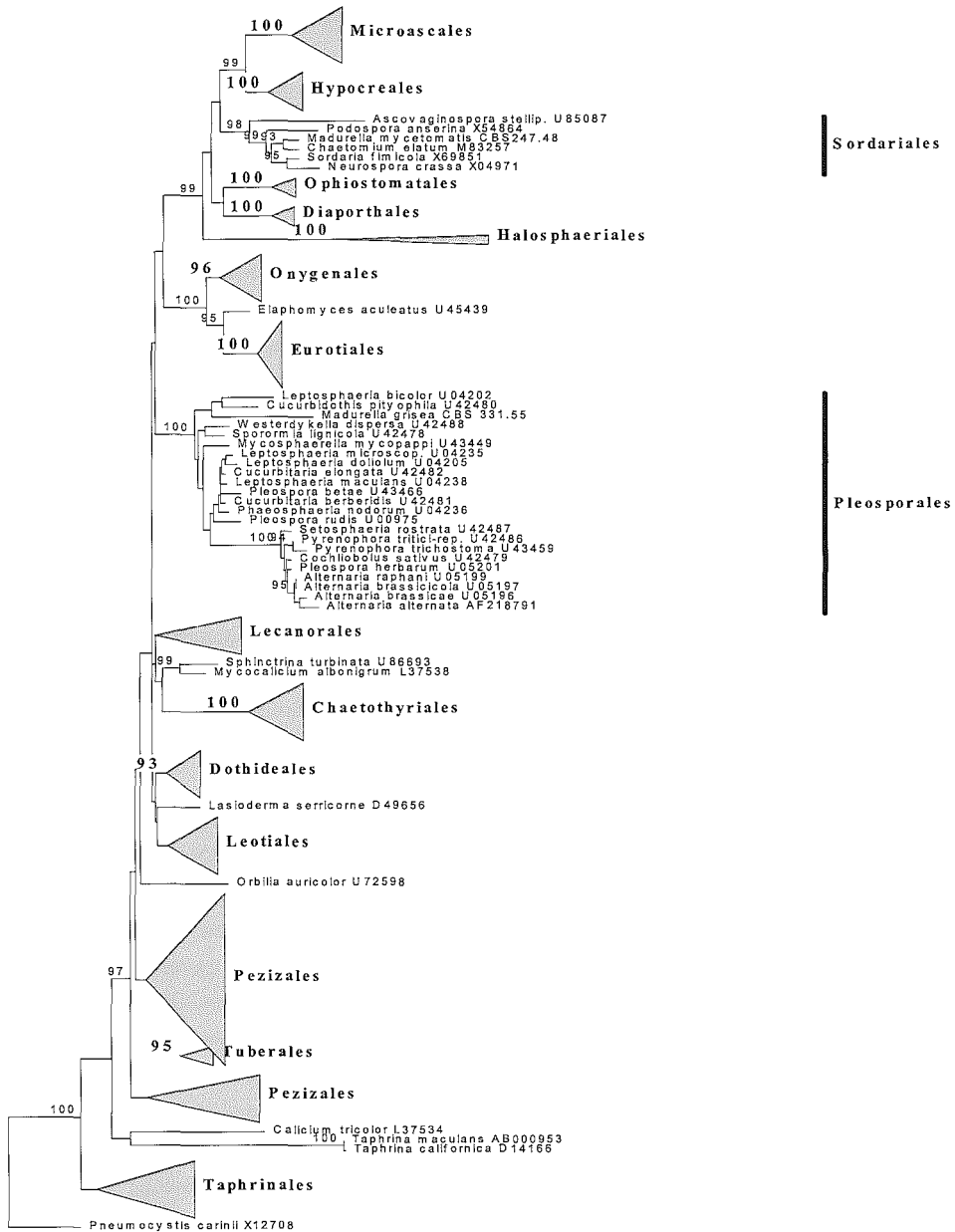


Figure 1: Distance tree of the Ascomycota based on 157 near-complete SSU rDNA sequences, constructed with the Neighbor joining algorithm with Kimura correction in the Treecon package. Bootstrap values >90 from 100 resampled datasets are shown. *Pneumocystis carinii* was selected as out-group.

Four CBS strains, originally identified as *M. mycetomatis*, showed significant ITS deviations from *M. mycetomatis*, and are hence likely to represent a separate species. None of these strains was of African origin. Strain CBS 868.95 (from Netherlands Antilles, as *M. mycetomatis*) could not be aligned with confidence and must represent a very different fungus. It had white-greyish rather than yellow-brown colonies, grew faster on SGA and did not produce any extracellular pigment. The SSU rDNA gene had an intron between the ITS1- and ITS5-primer regions. A sterile isolate of *Pseudallescheria boydii* was surmised, but no match could be found in Genbank. These data prove that “*Madurella*” is currently applied as an umbrella term covering partly unrelated species. The large number of obsolete names in the literature necessitate a taxonomic study into the genus *Madurella* (22).

Madurella grisea

M. grisea has been encountered in South America and India, but not in the dry climate zones of Africa (Table 2). ITS sequences of two authentic strains were found adjacent to *Leptosphaeria thompkinsii* and could largely be aligned with this species. *M. grisea* may thus be a member of Pleosporales and hence unrelated to *M. mycetomatis*. This supposition was confirmed by SSU rDNA sequencing data, where the species was found close to *Leptosphaeria bicolor* and *Cucurbitodithis pityophila* Petrak, though at 54 bp distance from the latter. Among the species currently most similar to *M. grisea* based on ITS data are *Pseudochaetosphaeronea larense*, known from a single case of human mycetoma (11) and several *Leptosphaeria* species from mycetomata (Table 2). Reported clinical cases in Senegal, occasionally showing thorns embedded in granulomata, concerned *Leptosphaeria senegalensis* and *Pyrenochaeta romeroi*, rather than *M. mycetomatis* (7). The climate in Senegal is more humid than in Central and East Africa, where plant remains are strongly desiccated.

Neotestudina rosatii

The ex-type strain of *N. rosatii*, CBS 427.62, a member of the order Dothideales, originated from a case of human mycetoma (51). The remaining strains morphologically identified as *N. rosatii* deviated significantly in ITS sequence profiles by 14 substitutions in ITS 1 and 9 in ITS2, and 7 Indels in ITS1 and 2 in ITS2, and thus are likely to represent a cryptic species. These strains came from soil and from seeds of *Coriandrum* and *Cuminum*. *N. rosatii* is an extremely rare species on which very few reports are available, neither clinical nor environmental. In contrast, *Ulospora bilgramii*, a close relative of *N. rosatii*, was isolated repeatedly from thorns of a *Balanitis egyptica* tree in Sudan (Table 2)(35). This species differs from *N. rosatii* including the cryptic species by having furrows on the surface of the ascospores while *N. rosatii* ascospores are smooth-walled (35). The ITS rDNA *Ulospora* / *Neotestudina* cluster could not be aligned with any of the remaining species analyzed in this study. In GenBank no sequences with a close match were found.

ACKNOWLEDGEMENTS

We are indebted to A.H. Fahal for hospitality of D. Adelman during environmental studies in Sudan, and to Boehringer Ingelheim AG for financial support. R.C. Summerbell is thanked for suggestions and comments on the manuscript. A. Aptroot and G. Verkley are acknowledged for identifications. Technical assistance was provided by K. Luijsterburg, A.H.G. Gerrits van den Ende and E. Akker.

REFERENCES

1. **Abbott, P.** 1956. Mycetoma in the Sudan. *Trans R Soc Trop Med Hyg.* **50**:11-30.
2. **Ahmed, A., D. Adelmann, A. Fahal, H. Verbrugh, A. van Belkum, and S. de Hoog.** 2002. Environmental occurrence of *Madurella mycetomatis*, the major agent of human eumycetoma in Sudan. *J Clin Microbiol.* **40**:1031-6.
3. **Ahmed, A. O., M. M. Mukhtar, M. Kools-Sijmons, A. H. Fahal, S. de Hoog, B. G. van den Ende, E. E. Zijlstra, H. Verbrugh, E. S. Abugroun, A. M. Elhassan, and A. van Belkum.** 1999. Development of a species-specific PCR-restriction fragment length polymorphism analysis procedure for identification of *Madurella mycetomatis*. *J Clin Microbiol.* **37**:3175-8.
4. **Ajello, L., A. A. Padhye, F. W. Chandler, M. R. McGinnis, L. Morganti, and F. Alberici.** 1985. *Fusarium moniliforme*, a new mycetoma agent. Restudy of a European case. *Eur J Epidemiol.* **1**:5-10.
5. **Altschul, S. F., T. L. Madden, A. A. Schaffer, J. Zhang, Z. Zhang, W. Miller, and D. J. Lipman.** 1997. Gapped BLAST and PSI-BLAST: a new generation of protein database search programs. *Nucleic Acids Res.* **25**:3389-402.
6. **April, T. M., S. P. Abbott, J. M. Foght, and R. S. Currah.** 1998. Degradation of hydrocarbons in crude oil by the ascomycete *Pseudallescheria boydii* (Microascaceae). *Can J Microbiol.* **44**:270-8.
7. **Basset, A., R. Camain, R. Baylet, and D. Lambert.** 1965. Role of Mimosaceae thorns in inoculation of mycetoma. (Apropos of 2 cases). *Bull Soc Pathol Exot Filiales.* **58**:22-4.
8. **Boiron, P., R. Locci, M. Goodfellow, S. A. Gumaa, K. Isik, B. Kim, M. M. McNeil, M. C. Salinas-Carmona, and H. Shojaei.** 1998. Nocardia, nocardiosis and mycetoma. *Med Mycol.* **36**:26-37.
9. **Boomker, J., J. A. Coetzer, and D. B. Scott.** 1977. Black grain mycetoma (maduromycosis) in horses. *J Vet Res.* **44**:249-51.
10. **Borelli, D.** 1976. *Pyrenochaeta mackinnonii* nova species agente de mycetoma. *Castellania.* **4**:227-34.
11. **Borelli, D., R. Zamora, and G. Senabre.** 1976. *Chaetosphaeronema larense* nova species agente de mycetoma. *Gaceta Med Caracas.* **84**:307-18.
12. **Bridges, C. H.** 1957. Maduromycotic mycetomas in animals. *Curvularia geniculata* as an etiologic agent *Am J Path.* **33**:411-27.
13. **Brodey, R. S., H. F. Schryver, M. J. Deubler, W. Kaplan, and L. Ajello.** 1967. Mycetoma in a dog. *J Am Vet Med Assoc.* **151**:442-51.
14. **Brumpt, E.** 1906. *In Les mycetoma.* Ed. Asselin & Houzeau.
15. **Campbell, C. K.** 1987. *Polycytella hominis* gen. et sp. nov., a cause of human pale grain mycetoma. *J Med Vet Mycol.* **25**:301-5.
16. **Chen, A. W., J. W. Kuo, J. S. Chen, C. C. Sun, and S. F. Huang.** 1993. Dermatophyte pseudomycetoma: a case report. *Br J Dermatol.* **129**:729-32.
17. **Da Sliva Lacaz, C., and C. F. Netto.** 1954. Contribucao para o estudo dos agentes etiologicos da maduromicose. *Folia clin Biol S Paulo.* **21**:331-52.
18. **De Area Leao, A. E., and J. Lobo.** 1934. Mycetoma du pied a *Cephalosporium recifei* var. sp.

- Mycetoma a grains blanc. C. R. Soc. Biol. Paris **107**:303-5.
19. **de Bruyn, H. P., J. M. Broekman, G. A. de Vries, A. H. Klokke, and J. M. Greep.** 1985. A patient with eumycetoma. Ned Tijdschr Geneesk. **129**:1099-101.
 20. **De Hoog, G. S., D. S. Attili-Angelis, V. A. Vicente, A. H. G. Gerrits van den Ende, and F. Queiroz-Telles.** 2003. Molecular ecology and pathogenic potential of *Fonsecaea species*. Med Mycol. In press.
 21. **de Hoog, G. S., A. Buiting, C. S. Tan, A. B. Stroebel, C. Ketterings, E. J. de Boer, B. Naafs, R. Brimicombe, M. K. Nohlmans-Paulssen, G. T. Fabius, A.H. Klokke and C.G. Visser.** 1993. Diagnostic problems with imported cases of mycetoma in The Netherlands. Mycoses. **36**:81-7.
 22. **de Hoog, G. S., J. Guarro, J. Gene, and M. J. Figueras.** 2000. Atlas of Clinical Fungi, 2nd ed. Centraalbureau voor Schimmelcultures / Universitat Rovira i Virgili, Utrecht / Reus.
 23. **de Hoog, G. S., F. D. Marvin-Sikkema, G. A. Lahpoor, J. C. Gottschall, R. A. Prins, and E. Gueho.** 1994. Ecology and physiology of the emerging opportunistic fungi *Pseudallescheria boydii* and *Scedosporium prolificans*. Mycoses. **37**:71-8.
 24. **de Vries, G. A., and L. H. van der Hoeven.** 1957. Report of the a case of black grain maduromycosis of the foot caused by an aberrant strain of *Madurella mycetomi* (Laveran). Mycopath. Mycol. Appl. **8**:253-59.
 25. **Develoux, M., B. Ndiaye, A. Kane, O. Ndir, M. Huerre, and C. De Bievre.** 1994. Madura foot caused by *Rhinocladiella atrovirens*. Abstract 12th ISHAM Congress. Adelaide.
 26. **el Hassan, A. M., A. Fahal, I. A. el Hag, and E. A. G. Khalil.** 1994. The pathology of mycetoma. Sudan Med J. **32**:23-45.
 27. **el-Ani, A. S.** 1966. A new species of *Leptosphaeria*, an etiologic agent of mycetoma. Mycologia. **58**:406-11.
 28. **Fahal, A. H., and S. H. Suliman.** 1994. Clinical presentation of mycetoma. Sudan Med. J. **32**:46-66.
 29. **Gammel, J. A.** 1927. The etiology of maduromycosis with a mycologic report on two species observed in the United States. Archs Derm Syph. **15**:241-84.
 30. **Gams, W.** 1971. Cephalosporium-artige Schimmelpilze (hyphomycetes). Gustav Fisher, Stuttgart.
 31. **Gargas, A., and J. W. Taylor.** 1992. Polymerase chain reaction (PCR) primers for amplifying and sequencing nuclear 18 S rDNA from lichenized fungi. *Mycologia*. **84**:589-92.
 32. **Gerrits van den Ende, A. H. G., and G. S. de Hoog.** 1999. Variability of molecular diagnostics of the neurotropic species *Cladophialophora bantiana*. Stud Mycol. **43**:152-62.
 33. **Guarro, J., and J. Gene.** 1992. Fusarium infections. Criteria for the identification of the responsible species. Mycoses. **35**:109-14.
 34. **Hall, J. E.** 1965. Multiple maduromycotic mycetoma in a dog caused by *Helminthosporium*. Southwest Vet. **18**:233-34.
 35. **Hawksworth, D. L.** 1979. Ascospore sculpturing and generic concepts in the *Testudinaceae* (syn. Zopfiaceae). Can J Bot. **57**:91-9.
 36. **Hay, C. E. M., R. K. Loveday, B. M. T. Spencer, and D. B. Scott.** 1978. Bilateral mycotic mycositis, osteomyelitis and nephritis in a dog caused by *Cephalosporium-like hyphomycete*. J S

- Afr Vet Ass. **49**:359-61.
37. **Hood, S. V., C. B. Moore, J. S. Cheesbrough, A. Mene, and D. W. Denning.** 1997. Atypical eumycetoma caused by *Phialophora parasitica* successfully treated with itraconazole and flucytosine. *Br J Dermatol.* **136**:953-6.
 38. **Janaki, C., G. Sentamilselvi, V. R. Janaki, S. Devesh, and K. Ajithados.** 1999. Case report. Eumycetoma due to *Curvularia lunata*. *Mycoses.* **42**:345-6.
 39. **Laveran, M. A.** 1902. Au sujet d'un cas de mycetoma a grains noirs. *Bull Acad Med , Paris III.* **47**.
 40. **Mahgoub, E.** 1969. *Corynespora cassicola*, a new agent of maduromycetoma. *J Trop Med Hyg.* **72**:218-21.
 41. **Mahgoub, E. S., and I. G. Murray.** 1973. Mycetoma. William Heinemann, London.
 42. **Mariat, F., P. Destombes, and G. Segretain.** 1977. The mycetomas: clinical features, pathology, etiology and epidemiology. *Contrib Microbiol Immunol.* **4**:1-39.
 43. **Murray, I. G., G. E. Dunkerley, and K. E. A. Hughes.** 1963. A case of Madurea foot caused by *Phialophra jeanselmi*. *Sabouraudia.* **3**:175-7.
 44. **Negróni, P., and J. A. Tey.** 1939. Estudio mycologico del primer caso Argentino de micetoma maduromicosico de granos negros. *Revta Ist. Bact.* **9**:176-89.
 45. **Pasaerli, L., M. E. Kemna, and M. R. McGinnis.** 1993. Mycetoma caused by *Phialophora verrucosa*. Abstract 532, ASM General Meeting.
 46. **Perfect, J. R.** 1996. Fungal virulence genes as targets for antifungal chemotherapy *Antimicrob Agents Chemother.* **40**:1577-83.
 47. **Pochat, A. L., and R. C. Zapter.** 1956. Observaciones de dos casos de muduromycosis (podaly de mano respectivamente) ocasionados por *Madurella mycetomi*. *Prensa Med Argent.* **43**:1542.
 48. **Rippon, J. W.** 1988. *Medical Mycology, The Pathogenic Fungi and the Pathogenic Actinomycetes*, 3rd ed. W.B. Saunders Company, Philadelphia.
 49. **Schauffler, A. F.** 1972. *Maduromycotic mycetoma* in an aged mare. *J Am Vet Med Assoc.* **160**:998-1000.
 50. **Segretain, G., R. Baylet, H. Darasse, and R. Camain.** 1959. *Leptosphaeria senegalensis* n. sp., agent de mycetoma a grains noirs. *C R Hebd Seanc Acad Sci., Paris,* **284**:3730-2.
 51. **Segretain, G., and P. Destombes.** 1961. Description d'un nouvel agent de maduromycose, *Neotestudina rosatii*, n. gen., n. sp., isole en Afrique. *C R Hebd Seanc Acad Sci., Paris* **53**:2577-9.
 52. **Severo, L. C., G. Vettoratto, M. Oliveira Fde, and A. T. Londero.** 1999. Eumycetoma by *Madurella grisea*. Report of the first case observed in the southern Brazilian region. *Rev Inst Med Trop Sao Paulo.* **41**:139-42.
 53. **Sterflinger, K., R. De Baere, S. De Hoog, R. De Wachter, W. E. Krumbein, and G. Haase.** 1997. *Conisporium perforans* and *C. apollinis*, two new rock inhabiting fungi isolated from marble in Sanctuary of Delos (Cyclades, Greece). *Antonie van Leeuwenhoek.* **72**:349-63.
 54. **Summerbell, R. C., and H. J. Schroers.** 2002. Analysis of phylogenetic relationship of *Cylindrocarpon lichenicola* and *Acremonium falciforme* to the *Fusarium solani* species complex and a review of similarities in the spectrum of opportunistic infections caused by these fungi. *J Clin Microbiol.* **40**:2866-75.

55. **Thirumalachar, M. J., and A. A. Padhye.** 1968. Isolation of *Madurella mycetomi* from soil in India. *Hindustan Antibiot Bull.* **10**:314-8.
56. **Turiansky, G. W., P. M. Benson, L. C. Sperling, P. Sau, I. F. Salkin, M. R. McGinnis, and W. D. James.** 1995. *Phialophora verrucosa*: a new cause of mycetoma. *J Am Acad Dermatol.* **32**:311-5.
57. **Van de Peer, Y., and R. De Wachter.** 1994. TREECON for Windows: a software package for the construction and drawing of evolutionary trees for the Microsoft Windows environment. *Comput Appl Biosci.* **10**:569-70.
58. **White, T. J., T. Bruns, S. Lee, and J. Taylor.** 1996. Amplification and direct sequencing of fungal ribosomal RNA genes for phylogenetics, p. 315-322. *In*: I. M. A., D. H. Gelfand, J. J. Sninsky, and T. J. White (eds), *PCR protocols: a guide to method and applications*. Academic Press, San Diego, Calif.
59. **Witzig, R. S., D. L. Greer, and N. E. Hyslop, Jr.** 1996. *Aspergillus flavus* mycetoma and epidural abscess successfully treated with itraconazole. *J Med Vet Mycol.* **34**:133-7.
60. **Zoutman, D. E., and L. Sigler.** 1991. Mycetoma of the foot caused by *Cylindrocarpon destructans*. *J Clin Microbiol.* **29**:1855-9.

Chapter 6

***Madurella mycetomatis* Strains from Mycetoma Lesions in Sudanese Patients are Clonal**

Abdalla O. A. Ahmed, Wendy van de Sande, Henri A. Verbrugh, Ahmed H. Fahal and Alex van Belkum

ABSTRACT

Molecular diversity among clinical *Madurella mycetomatis* isolates, the prime fungal agent of human mycetoma in Sudan, could possibly explain the diverse clinical presentations of this severely debilitating infectious disease. In addition, culture-independent DNA mediated typing tests need to be developed for this organism since *M. mycetomatis* DNA but not the organism itself can be identified in soil, the material from which infections are thought to originate. A collection of 38 different clinical *M. mycetomatis* isolates was characterised by large scale random amplification of polymorphic DNA (RAPD) using 20 different primer species. These analyses, involving at least 2600 annealing sites, showed a complete lack of DNA fingerprint variation between the various isolates. From the resulting homogeneous DNA fingerprints seven fragments were cloned, sequenced and novel, species-specific PCR restriction fragment length polymorphism (RFLP) tests were designed. The seven PCR RFLP tests were successfully performed on the 38 different *M. mycetomatis* strains. However, again all *M. mycetomatis* DNA patterns obtained appeared to be identical, whereas patterns produced using DNA from related species were clearly discriminatory. These results suggest that there is little genetic variation among clinically relevant *M. mycetomatis* strains from Sudan. These data cautiously imply that different manifestations of mycetoma are due to differences in host susceptibility rather than differential virulence of the causative agent.

INTRODUCTION

Mycetoma presents as a chronic, relatively painless, subcutaneous, granulomatous lesion which is characterised by the formation of multiple sinuses. In approximately 40% of all infections a fungus is the causative agent, the sclerotia of which are shed through these sinuses in the form of fungal grains (11, 8). The colour of these grains has diagnostic value. Green grains identify *Aspergillus flavus* as the most likely causative agent, whereas white grains are usually produced by *Pseudoallescheria boydii*, *Aspergillus nidulans* or *Acremonium kiliense*. Brownish grains are produced by *Neotestudina rosatii*, whereas deep-black grains are produced by species such as *Curvularia lunata*, *Phialophora jenselmi*, *Pyrenochaeta romeroi*, *Leptosphaeria senegaliensis*, *Madurella grisea* or *Madurella mycetomatis*. This latter fungus is the most prevalent mycetoma agent in Sudan (8). Although this agent has been shown to occur in various geographic regions, most cases of *M. mycetomatis* mycetoma occur in a relatively comprehensive "mycetoma belt" (e.g. (1)). Although the precise mechanism of infection remains enigmatic, it is frequently suggested that traumatic inoculation of fungus-containing soil, assisted by the presence of plant materials such as thorns, provides a likely route of dissemination (8, 9, 11, 15). However, growing the organism from soil has been documented only sparsely, although recent molecular detection has revealed that fungal DNA can be detected quite easily in soil from different regions in the mycetoma belt (1). Because of the apparent impossibility of culturing the fungus directly from soil it is very hard to study the precise transmission routes of the fungus. Since *M. mycetomatis* DNA can be easily amplified from soil, development of methods for further analysis of the genetic variation in this soil-embedded material has a high priority. Tools for the assessment of strain-specific characteristics may also be helpful for distinguishing relapsing disease from re-infection events. For the reasons outlined above we have tried to develop direct DNA identification assays suited for the

discrimination between Sudanese *M. mycetomatis* strains. Using a large collection of clinical isolates of *M. mycetomatis* we tried to identify polymorphic genome fragments suited for direct DNA characterisation. Strains were initially typed by high-throughput random amplification of polymorphic DNA (RAPD). Possible sequence variability within individual RAPD fragments was investigated by the application of PCR restriction fragment length polymorphism (RFLP) tests.

MATERIALS AND METHODS

Strains and culture conditions. The Sudanese *M. mycetomatis* strains (n = 38) were identified by PCR as previously described by Ahmed *et al.* (2). Strains were isolated by direct culture of black grains obtained from deep biopsies of patient lesions at the Mycetoma Research Center, Khartoum, Sudan. Patients originated from a large geographic region, essentially covering the entire Sudanese mycetoma belt. Strains were maintained on Sabouraud agar (Difco Laboratories, Becton Dickinson, USA) with gentamicin at an incubation temperature of 37°C. Examples of *M. mycetomatis*-related organisms were obtained from the CBS (Centraalbureau voor Schimmelcultures, Utrecht, The Netherlands). These fungi were: *Alternaria infectoria* (CBS 160.79), *Alternaria tenuissima* (CBS 160.52), *Alternaria alternata* (CBS 137.90), *Curvularia geniculata* (CBS 731.96), *Curvularia verruculosa* (CBS 444.70), *Pseudallescheria boydii* (2 different strains) (CBS 883.71 en CBS 1003.92), *Leptosphaeria tompkinsii* (CBS 201.79), *Bipolaris hawaiiensis* (CBS 727.96), *Exophiala jaenselmei* (CBS 635.69), *Phialophora verrucosa* (CBS 839.69), *Aspergillus fumigatus* (dH 12472), *Penicillium crustaceum* (CBS 581.67), *Fusarium oxysporum* (CBS 1098.98), *Fusarium solani* (CBS 1022.56), *Cylindrocapsa lichenicol* (CBS 623.92) and *M. grisea* (CBS 172.22).

DNA isolation. After 4 weeks of incubation at 37°C the fungal material was excised from the agar and transferred into 6 ml of a 0,9% NaCl solution. The material was sonified for 2 minutes at 30 micron (Soniprep 150, Beun de Ronde, Abcoude, The Netherlands) to fully disrupt the mycelium. Five hundred microlitres of this suspension was taken and DNA was isolated according to the DNA extraction method described by Boom *et al.* (6). Because of the low amount of DNA isolated with this method an alternative method was used too. After sonification, the suspension was frozen in liquid nitrogen, thawed and ground in a mortar using a porcelain pestle. DNA was extracted from this emulsified sample using the Wizard® Genomic DNA Purification Kit (Promega Corporation, Leiden, The Netherlands) employing the Yeast protocol which starts by the addition of the Nuclei Lysis Solution.

Randomly amplified polymorphic DNA analysis. The RAPD reactions were performed in 50 µl reaction volumes containing 5 µl 10x Supertaq PCR buffer 1 (HT Biotechnology Ltd., United Kingdom), 10 µl 1 mM PCR nucleotidemix (Amersham Life Sciences, Roosendaal, The Netherlands), 0,5 µl primer at 50 pmol per µl; 1.2 U Supertaq (HT Biotechnology Ltd.) and distilled water to complete the volume. The twenty primers used are listed in Table 1. The PCR reaction was performed in a model 60 Thermocycler (Biomed, Theres, Germany). PCR was composed of a pre-denaturation step of 4 minutes at a temperature of 94°C and 40 cycles of each a denaturation step of 1 minute at 94°C, an annealing step of 1 minute at 25°C and an extension step of 2 minutes at 74°C. The RAPD patterns

PCR-products with a similar size as those of *M. mycetomatis* were analysed by RFLP involving two enzyme-combinations. Only in case of the 814/813 PCR product of *M. grisea* some restriction fragments had an identical size as the restriction fragments obtained from *M. mycetomatis*. Essentially, all species could be differentiated from the *M. mycetomatis* strains. The data for the other primers showed similar species specificity, albeit that DNA from other species than described above resulted in amplification of multiple DNA fragments or non-amplification at all (data not shown).

Table 1: Primers used for the high throughput RAPD analysis of 38 clinical *Madurella mycetomatis* isolates

Primer number	Primer name	Primer sequence	Nucleotide size of the amplimers synthesised
13	ERIC-2	AAGTAAGTGACTGGGGTGAGCG	550, 900, 1100
26	REP-2I	ICGICTTATCCIGGCCTAC	950, 1300, 1500
46	RAPD1	GGTTGGGTGAGAATTGCACG	200, 300, 500, 550, 700
47	random	GGCCATAGAGTGTTCGACACAACTGC	nothing amplified
51	random	GCGATCCCA	500, 550, 720
52	RAPD7	GTGGATGCGA	500, 550, 600, 800, 820, 1500, 1550
174	VanC2	CTTCCGCCATCATAGCT	nothing amplified
214	CEP PA480	GTTACCAACAGAATAAGC	nothing amplified
312	PC2	GCCTTCTCCAATGCAGCGAC	450, 900
449	28.3b	TCCGCGGGGCGTCCGCCGGA	650, 710, 950, 1100
548	wlaclus1	ATCAGATCGTTCCTATACAG	nothing amplified
683	uspA2repeat1	TGGATATGATAGAGATTTTTCCAT	600, 620, 630, 750, 800, 900, 1100, 1400, 1500, 1550
689	campcoli1	AGGCAAGGGAGCCTTTAATC	600, 620, 800
695	CalE1	TATGACAAACACAGGGACAAC	600, 1100, 1150, 1400, 1500, 1550
699	McCAACrep	GTCGGTATTATGGGCAG	700, 900, 950, 1000, 1100, 1300, 1500
701	repeatF1	AGGATTTGGCGAAGTTTGG	700, 800, 950, 960, 1000, 1100, 1250, 1260, 1350, 1550, 1560, 1600, 1650
714	PstBseq1	TAGTCTGGTGGCTGGTGTGGGC	nothing amplified
718	PstSprer	AACCTTCATAATGTCTCCTG	500
729	13,1VNTR	TGAACCATGGGTAATTTGA	nothing amplified
786	AW-14.2	GCTTATCGTAAAGTAAACGA	nothing amplified

Table 2: RAPD fragments cloned and used for the PCR RFLP procedure.

Frag. nr	RAPD primer	Frag. size	Seq length	Seq homol	Forward primer Number	Forward primer sequence	Reverse primer Number	Reverse primer sequence	Ann. Temp.
1	695	600	585	none	989	AGAAAACGGACACGGAGCAAAATG	990	TATGACAAACACAGGACAACGAG	54
5	701	1550	1467	None	1144	AGGGTGAATTTGAGCCAGTTGAGT	1145	AGTGGGGCGAGTACAGGATAATA	55
7	701	1000	811	None	995	TGCTGCTGCTCCTCCTGCTTTAC	996	CGACTACCACCACCGCCACTACT	59
8	701	800	682	None	998	AGTTTGGCACGAGGAAGTCAITG	999	TTTGGCGAAGTTGGGTAGGATGG	54
15	52	1050	1061	cumA	813	TTTCAGGCTCAGGGTGGTTCGTG	814	GTTTAGGTGATGCCGGTGTATGGT	56
16	52	800	793	None	810	CGGTGGCGGTTAGAGAAAT	411	TCGGGGGCCACTGCTGCTA	50
17	46	450	439	None	1192	TGCACGTGGAATCGCATAATAATA	1193	TCGGGGGCCACTGCTGCTA	55

DISCUSSION

Classical high-throughput RAPD and newly developed PCR-RFLP tests were applied to detect possible genetic variation among different clinical *M. mycetomatis* strains from Sudan. The RAPD results were frustrating: out of twenty primer species employed 25% did not result in any DNA amplification, whereas the remaining 75% generated completely identical patterns for all of the strains analysed. Several thousands of annealing sites were scanned and the complete lack of variability is at least remarkable. For most micro-organisms, including eukaryotes, RAPD is a technique well suited for the detection of genetic diversity in and between different species. RAPD studies performed with other clinically relevant fungi, such as *A. fumigatus*, resulted in many different genotypes, even when only limited numbers of primers and fungal strains were employed. Bertout *et al.* defined 8 different genotypes among 52 *A. fumigatus* isolates (4), while Bart-Delabesse *et al.* detected 31 different genotypes in 67 isolates (3). These are only two examples of the many which can be found. Examples for fungal species as diverse as *Malassezia* spp., *Histoplasma capsulatum*, *Exophiala dermatitidis* and *Blastomyces dermatitidis* have been published in the past and all of these studies successfully demonstrated genetic diversity among strains (16, 17, 19, 20). On the other hand, past studies on *Naegleria* spp revealed that for this species RAPD analysis was similarly homogeneous in its outcome (18), although a far smaller number of primers were used. The conclusion based on the RAPD analysis can only be that the *M. mycetomatis* isolates collected from infections in the Sudanese mycetoma belt are strongly clonal.

The observations outlined above were further corroborated by PCR-RFLP, which again did not reveal any genetic variation between the isolates (1, 2). Firstly, all the PCR primers selected from the sequences of the RAPD fragments that were cloned reacted positively with the DNA from all 38 strains. Apparently these randomly selected priming sites were well conserved. Secondly, all PCR products derived from the various *M. mycetomatis* isolates presented the same restriction pattern after digestion by 6 different enzymes, which is in line with at least species homogeneity. That PCR-RFLP can be useful to detect fungal genetic variability has been shown repeatedly before as well (5, 12, 14, 20). To test if the different primer combinations were species-specific, these were tested on different fungal species. It appeared that when amplicons were obtained, the other fungi could be identified on the basis of a deviating RFLP pattern. Only for *M. grisea* and *M. mycetomatis* similar restriction fragments were found. These data demonstrate that significant inter-species variability exists and that this variation can be easily documented by PCR RFLP.

The lack of molecular diversity among *M. mycetomatis* strains that we document here seemingly contrasts with data by Lopes *et al.* (13). These authors were able to identify 9 different genotypes in 17 *M. mycetomatis* isolates by RAPD and restriction endonuclease assays (REA). These strains were obtained from geographically diverse locations. However, two isolates from Sudan could not be separated, which is in agreement with our findings. The Sudanese strains clustered with strains from Cameroon, Marocco and Chad. We here included two strains from Mali (p1 and p2). Mali is in West-Africa, while Sudan is in East-Africa; climate and vegetation are completely different in these two countries. Still, the strains from Mali had the same genotype in the RAPD as the clinical isolates from

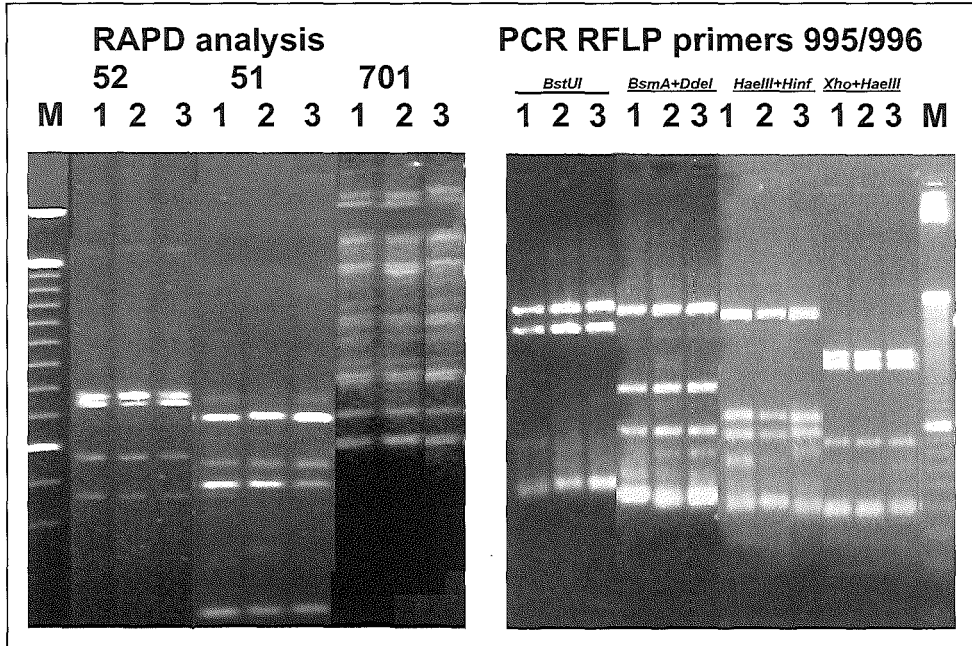


Figure 1: RAPD and PCR-RFLP analysis of DNA sequence variability in specific regions of the *M. mycetomatis* genome amplified by RAPD primers.

Sudan. A problem with the Lopes study (13) was that it was not clearly indicated how the strains were identified to the species level.

In our experience, not all *Madurella* strains are easily identified and misclassification may be an explanation for the enhanced levels of genetic heterogeneity encountered by these authors. For instance, *M. grisea* is another member of the same genus, also presents with dark, slowly growing colonies of a sterile mycelium and cannot be discriminated easily from *M. mycetomatis* (15). All strains, including the 2 from Mali, that are presented here have been species defined by PCR diagnostics (2).

In conclusion, no sequence heterogeneity was encountered among a large number of clinical isolates of *M. mycetomatis* from Sudanese patients. This indicates that the organism is clonal and makes one wonder whether physical boundaries to the mycetoma belt have resulted in the spatial confinement of a certain *M. mycetomatis* clone. This clone is apparently well adapted to its human host, but it is also able to persist concealed in the environment.

REFERENCES

1. **Ahmed AOA, Adelman D, Fahal A, Verbrugh HA, Van Belkum A, De Hoog GS.** (2002) Environmental occurrence of *Madurella mycetomatis*, the major agent of human eumycetoma in Sudan. *J Clin Microbiol* **40**:1031-1036.
2. **Ahmed AOA, Mukhtar MM, Kools-Sijmons M, Fahal AH, De Hoog GS, Gerrits van den Ende AHG, Zijlstra EE, Verbrugh HA, El Sir Abugroun AM, Elhassan AM, Van Belkum A.** (1999) Development of a species-specific PCR-Restriction Fragment Length Polymorphism analysis procedure for identification of *Madurella mycetomati*. *J Clin Microbiol* **37**:3175-3178.
3. **Bart-Delabesse E, Sarfati J, Debeauvais J-P, Van Leeuwen W, Van Belkum A, Bretagne S, Latge JP.** (2001) Comparison of Restriction Fragment Length Polymorphism, microsatellite length polymorphism, and Random Amplification of Polymorphic DNA analyses for fingerprinting *Aspergillus fumigatus* isolates. *J Clin Microbiol* **39**:2683-2686.
4. **Bertout S, Renaud R, Barton R** (2001) Genetic polymorphism of *Aspergillus fumigatus* in clinical samples from patients with invasive aspergillosis: investigation using multiple typing methods. *J Clin Microbiol* **39**:1731-1737.
5. **Birch M, Anderson MJ, Denning DW.** (1995) Molecular typing of *Aspergillus* species. *J Hosp Infect* **30**:339-351.
6. **Boom R, Sol DJA, Salimans MMM, Jansen CL, Wertheim van Dillen PM, Van der Noordaa J.** (1990) Rapid and simple method for purification of nucleic acids. *J Clin Microbiol* **33**:24-27.
7. **Brouwers GJ, de Vrind JPM, Corstjens PL, Cornelis P, Baysse C, De Vrind de Jong EW.** (1999) CumA, a gene encoding a multicopper oxidase, is involved in Mn²⁺ oxidation in *Pseudomonas putida* GB1. *Appl Environ Microbiol* **65**:1762-1768.
8. **Fahal AH, Hassan MA** (1992) Mycetoma. *Br J Surg* **79**:1138-1141.
9. **Fahal AH, Hassan MA, Sanhoury M** (1994) Surgical treatment of mycetoma. *Sudan Med J* **32**:98-104.
10. **Francis CA, Tebo BM.** (2001) CumA multicopper oxidase genes from diverse Mn(II)-oxidizing and non-Mn(II)-oxidizing *Pseudomonas* strains. *Appl Environ Microbiol* **67**:4272-4278.
11. **Gumaa SA** (1994) The aetiology and epidemiology of mycetoma. *Sudan Med J* **32**:14-22.
12. **Kemker BJ, Lehmann PF, Lee JW, Walsh TJ** (1991) Distinction of deep versus superficial clinical and non-clinical isolates of *Trichosporon beigellii* by isoenzymes and restriction fragment length polymorphisms of rDNA generated by polymerase chain reaction. *J Clin Microbiol* **29**:1677-1683.
13. **Lopes MM, Freitas G, Boiron P** (2000) Potential utility of random amplified polymorphic DNA (RAPD) and restriction endonuclease assay (REA) as typing systems for *Madurella mycetomatis*. *Curr Microbiol* **40**:1-5.
14. **Semighini CP, Delmas G, Park S, Armstrong D, Perlin D, Goldman GH** (2001) New restriction fragment length polymorphism (RFLP) markers for *Aspergillus fumigatus*. *FEMS Immunol Med Microbiol* **31**:15-19.
15. **Suliman EN** (1994) Laboratory diagnosis of mycetoma. *Sudan Med J* **32**:67-73.

16. **Uijthof JMJ, De Hoog GS, De Cock AWAM, Takeo K, Nishimura K** (1994) Pathogenicity of strains of the black yeast *Exophiala (Wangiella) dermatitidis*: an evaluation based on polymerase chain reaction. *Mycoses* **37**:235-242.
17. **Van Belkum A, Boekhout T, Bosboom R** (1994) Monitoring spread of *Malassezia* infections in a neonatal intensive care unit by PCR-mediated genetic typing. *J Clin Microbiol* **32**:2528-2532.
18. **Van Belkum A, De Jonckheere J, Quint W** (1992) Genotyping *Naegleria* spp and *Naegleria fowleri* isolates by interrepeat polymerase chain reaction. *J Clin Microbiol* **30**:2595-2598.
19. **Woods JP, Kersulyte D, Goldman WE, Berg DE** (1993) Fast DNA isolation from *Histoplasma capsulatum*: methodology for arbitrary primer polymerase chain reaction-based epidemiological and clinical studies. *J Clin Microbiol* **31**:463-464.
20. **Yates-Siilata KE, Sander DM, Keath EJ** (1995) Genetic diversity in clinical isolates of the dimorphic fungus *Blastomyces dermatitidis* detected by a PCR-based random amplified polymorphic DNA assay. *J Clin Microbiol* **33**:2171-2175.

Chapter 7

A Murine Model of *Madurella mycetomatis* Eumycetoma

Abdalla O. A. Ahmed, Wim van Vianen, Marian T. ten Kate, Wendy W. J. van de Sande, Alex van Belkum, Ahmed H. Fahal, Henri A. Verbrugh and Irma A. J. M. Bakker-Woudenberg

ABSTRACT

Eumycetoma due to *Madurella mycetomatis* is a major mycological health problem in endemic areas. We infected BALB/c mice (male or female) with various amounts of *M. mycetomatis* mycelium, containing sterilized soil as a natural adjuvant or Freund's incomplete adjuvant. Mice differed with respect to age and immune status. Intraperitoneal, subcutaneous and intravenous inoculation was explored and survival was monitored. Mice were killed at various intervals after inoculation, checked for the presence of the characteristic black grains, and organs were cultured for *M. mycetomatis*. Infected organs were subjected to histopathological examination. Immunocompetent male mice were as susceptible as immunocompromised female mice, but showed higher mortality rates. In conclusion, a reproducible mouse model of intraperitoneal *M. mycetomatis* infection with characteristic black grains in immunocompetent adult or young female mice was developed. Although this experimental model does not simulate macroscopic features of the subcutaneous *M. mycetomatis* infection in humans, the histopathological characteristics of the lesions and the development of black grains are clearly representative for the human infection. This model will enable further studies on the pathogenesis as well as prevention and treatment of the fungal infection.

INTRODUCTION

Mycetoma is a chronic, slowly progressive, relatively painless subcutaneous granulomatous disease, which can be caused by fungi (eumycetoma) or aerobic actinomycetes (actinomycetoma). It is characterized by swollen lesions and sinuses, through which grains of different color, size and consistency are discharged. The organisms that cause mycetoma are presumably soil saprophytes [1 and 2]. The infection is supposed to originate from accidental traumatic inoculation of plant material such as thorns or any other minor trauma that leads to the penetration of the causative organisms into the subcutaneous tissues [3, 4 and 5]. The geographical distribution of mycetoma cases and mycetoma-causing organisms depends on many factors including temperature, rainfall, type of soil and vegetation as well as the demographic variables of the susceptible population. Most mycetoma cases are seen in tropical and sub-tropical regions. Males are more frequently affected than females, with a sex ratio of 5:1. The disease is frequently seen in young people (20–40 years old), affecting feet (70% of cases) or hands (12% of the cases). Infection of other sites such as leg, knee, thigh, perineum, back, arms, thorax, shoulders, head, and neck are reported less frequently [4 and 5]. Secondary bacterial infections of the mycetoma lesions are often observed, thereby complicating and aggravating disease development [6].

The fungus *Madurella mycetomatis* is the most prevalent etiological agent of eumycetoma [5]. In tissue biopsies it is observed that the fungus produces numerous black grains, composed of aggregates of fungal hyphae embedded in a hard extracellular cement material. Early diagnosis followed by proper surgical and chemotherapeutic intervention, before bone involvement occurs, results in the most successful outcome [5]. However, reports describing successful and lasting treatment of advanced eumycetoma due to *M. mycetomatis* are few and conflicting [4 and 5].

Some investigators were successful in inducing *M. mycetomatis* infection producing characteristic black grains in laboratory animals [9], but reproducibility was poor. Successful infection required inoculation of *M. mycetomatis*, mixed with killed tubercle bacilli or the use of congenitally athymic nude mice or immunocompetent mice after repeated intraperitoneal inoculation [7, 8 and 9]. Although some of the models appeared to be clinically useful, efforts to reproduce the experimental infection were again not successful (e.g. [10]). The determinants important for the establishment of mycetoma in experimental animals are thus not yet elucidated. In the present study we describe a reproducible infection model for *M. mycetomatis* in mice. A number of variables were examined, including age, gender and immune status of the host, the inoculum of *M. mycetomatis*, the use of an adjuvant, and the route of inoculation.

MATERIALS AND METHODS

Animals. Specified pathogen-free male or female BALB/c mice at the age of 5–6 weeks (young) or 12–13 weeks (adult) were obtained from Iffa Credo (L'Arbresle, France). Mice were housed in filtered-top cages, and supplied with commercial food pellets and sterile drinking water. To prevent bacterial super-infection, mice received ciprofloxacin (660 mg l⁻¹) and colistin sulfate (100 mg l⁻¹) in their drinking water during the experiment. The animal experiments ethical committee of the Erasmus Medical Center approved the studies described in the current paper. Leukocyte depletion was induced by cyclophosphamide (100 mg kg⁻¹ intraperitoneally, Sigma-Aldrich Chemie, Steinheim, Germany) 4 days before fungal inoculation, followed by repeated doses of 75 mg kg⁻¹ starting on the day before inoculation with a 3-day interval. This treatment results in persistent granulocytopenia of <0.1×10⁹ cells per liter of blood. Corticosteroid treatment was applied by administration of methylprednisolon acetate (80 mg kg⁻¹ subcutaneously; Pharmacia and Upjohn, Woerden, The Netherlands) 5 h before inoculation followed by repeated doses of 10 mg kg⁻¹ subcutaneously at a 3-day interval. Granulocytopenia was not checked for each individual mouse, but was assessed in parallel experiments. The number of mice per group varied from 4 to 12.

Fungal strain. A strain of *M. mycetomatis*, originally isolated from a mycetoma patient seen in the Mycetoma Research Center, University of Khartoum, Sudan, was used in this study. This strain was isolated by direct culture of the black grains obtained by deep surgical biopsy and identified by morphology and polymerase chain reaction as *M. mycetomatis* [11]. This isolate was maintained in the laboratory for 2 years in Sabouraud agar (Difco Laboratories, Becton Dickinson, Sparks, MD, USA) by repeated subculturing every 4–6 weeks.

Fungal inocula. Fresh inocula were prepared for each experiment. *M. mycetomatis* was cultured in 1–2 liters of Sabouraud broth (Difco Laboratories, Becton Dickinson) and incubated at 37°C for 2 weeks. Mycelia were separated and washed by vacuum filtration (Nalgene, Abcoude, The Netherlands). Wet weights of the mycelia were determined. A suspension containing 300 mg wet weight of *M. mycetomatis* per ml in phosphate-buffered saline (PBS) was sonicated for 2 min at 28 (MSE Soniprep 150, Integrated Service TCB, USA). This procedure does not kill the fungus, although the remaining

hyphal segments appear to be significantly shortened. The main advantage of sonication was the fact that inocula were prepared in a more standardized fashion and were prepared more reproducibly. Various inocula were prepared by dilution with sterile PBS. The fungal viability in terms of colony-forming units (CFU) was determined for each inoculum by sub-culturing a diluted sample on Sabouraud agar and direct colony counting after 2 weeks incubation at 37°C. The inocula of heat-killed *M. mycetomatis* were prepared by autoclaving the viable fungal suspension at 121°C for 15 min. The sterility of these materials was checked for each batch separately by culture assays. As a natural adjuvant sterile fine soil in a final concentration of 10 mg ml⁻¹ was used. Soil was obtained from mycetoma endemic areas in Al Jazirah state along the Blue Nile, Sudan. Also Freund's incomplete adjuvant (FIA) (Difco Laboratories, Detroit, MI, USA) was used in a final concentration of 50% (v/v).

Animal inoculation. Animals were inoculated with various amounts of viable or heat-killed *M. mycetomatis*, ranging from 0.8 to 140 mg wet weight per mouse. Inoculation was performed either subcutaneously in the neck (0.4 ml) or intraperitoneally (0.4 ml). In pilot experiments intravenous inoculation (0.2 ml) and subcutaneous inoculation in the foot pad (0.02 ml) or in the abdomen at two sites (0.2 ml per site) were performed.

Assessment. Mycetoma infection was diagnosed when black grains could be observed macroscopically after the inoculation of the *M. mycetomatis* mycelia suspension. To monitor the course of the infection, mice were checked daily for survival. Dead mice were dissected and internal organs were examined macroscopically for the presence of black grains. Organs were stamped onto blood agar and Sabouraud agar (Difco Laboratories, Becton Dickinson), to exclude bacterial superinfection and to test for the presence of *M. mycetomatis* by aerobic cultivation. In case of the presence of the black grains, culture in Sabouraud agar was performed to test their viability. Also, mice were killed at various intervals after inoculation (days 17–51), depending on the immune status of the animal and the inoculum used. Blood samples (0.4–0.5 ml) were taken via retro-orbital bleeding under CO₂ anesthesia. The serum was collected and stored at -20°C. During dissection a careful search for the presence of black grains was performed. From each mouse, liver, spleen, kidneys, heart and lungs were aseptically excised and bacterial and fungal cultures were performed. Representative biopsies from different organs, subcutaneous lesions and abdominal lesions were fixed in 10% buffered formalin and processed. Sections were stained with hematoxylin and eosin, periodic acid Schiff and Grocott methenamine silver stain for fungi [24]. Fisher's exact test was used to determine the possible significance of differences in the infection and mortality rates between the different groups of mice.

RESULTS

For the low inocula of 0.8, 8 and 40 mg wet weight of viable *M. mycetomatis* a good correlation was found in vitro with viable counts being 3×10³, 3×10⁴ and 1.5×10⁵ CFU, respectively. At higher inoculum sizes, counting of CFU was less reliable. This is the main reason for using wet weight of the fungal material to standardize the inoculum size. Intraperitoneal inoculation with the high inoculum of 140 mg heat-killed *M. mycetomatis* in young immunocompetent female mice caused quick death in

two out of five mice (data not shown). In all groups, inoculated with viable *M. mycetomatis*, after dissection, the internal organs showed negative cultures for *M. mycetomatis*. In mice that died during the first few days after intraperitoneal inoculation, *M. mycetomatis* was incidentally isolated from either spleen and/or liver. These positive cultures indicate that *M. mycetomatis* could survive for at least a few days in immunocompetent mice. In only one leukocyte-depleted mouse, *M. mycetomatis* was isolated from all internal organs after spontaneous death at day 33 after intraperitoneal inoculation. However, this mouse did not show black grains. An apparent difference in the susceptibility to infection was found between immunocompetent male and female mice, not in terms of infection rate, but in terms of mortality, which was elevated in male mice. Overall 2/8 young females and 4/8 adult females in the immune competent group of mice inoculated intraperitoneally with 120 mg of the fungus succumbed to the infection. For the young and adult males the figures were 5/8 and 7/8, respectively. The cumulative mortality was 6/16 for the females and 12/16 for the males with a two-sided Fisher exact *P* value equaling 0.07. This suggests a certain association, which, however, needs corroboration by additional experiments involving larger numbers of experimental animals (work in progress).

When mycetoma lesions were observed in mice, pathology was similar to that defined for mycetoma in man. Black grains surrounded by several zones of inflammatory cells were observed (see Figure 1C). Silver stain of the fungus showed thick wall hyphae embedded in the cement material protecting the fungus from the immune system [5, 20 and 21]. The fungal black grains were usually attached to internal organs, surrounded by fibrous tissue. Sinuses did not develop in case of superficial mycetomas after intraperitoneal inoculation, but sinus-like structures were observed occasionally after subcutaneous inoculation in all groups (see Figure 1A). The grains were black, irregularly shaped and hard in consistency (see Figure 1B).

Only a few abdominal or subcutaneous sterile abscesses (incidence less than 1%) were seen in all mouse groups injected with the heat-killed inocula, but infection did not develop within 51 days with interim assessment at days 17 and 38. Material derived from the abscesses always scored negative in the culture-based detection assays.

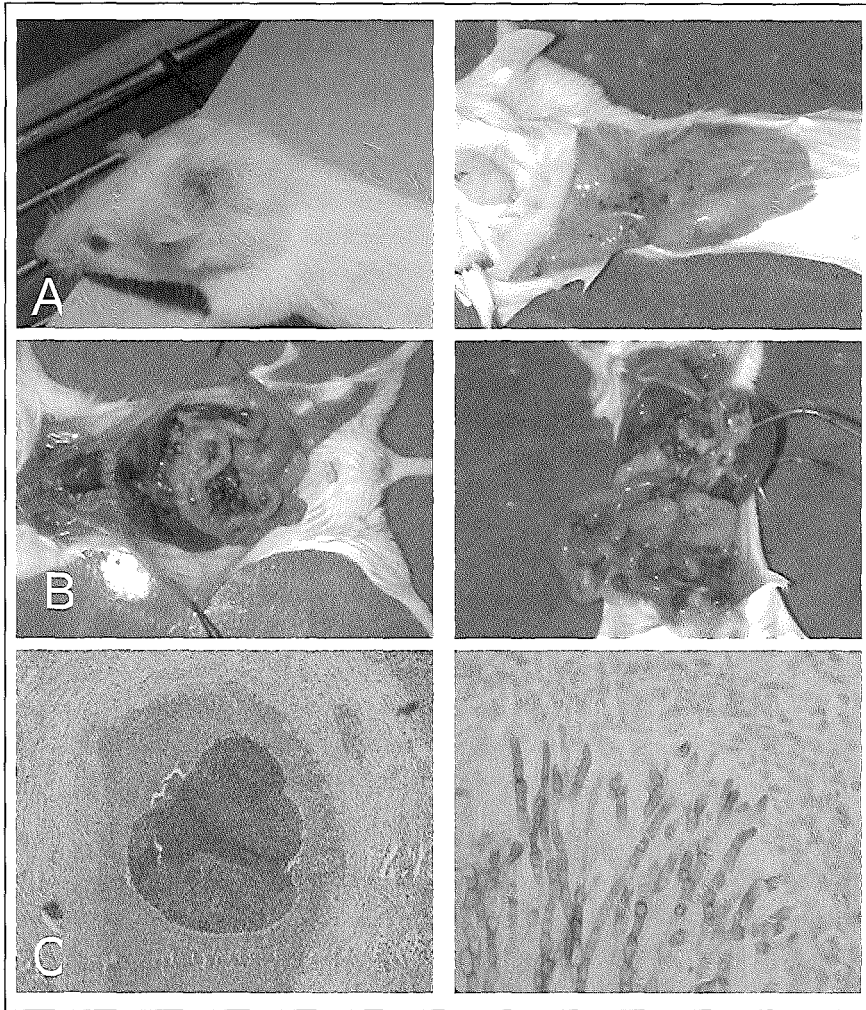


Figure 1: A: Adult corticosteroid-treated female BALB/c mouse at day 17 after subcutaneous inoculation of 40 mg of *M. mycetomatis* mycelia and 4 mg sterile soil. Before dissection, a big subcutaneous nodule with a healed sinus was seen (left). After killing the mouse numerous small black grains characteristic for *M. mycetomatis* lesions were seen (right). **B:** Adult immunocompetent male (left) and female (right) BALB/c mouse intraperitoneally inoculated with 120 mg fungal mycelia and soil adjuvant. The mice showed massive mycetoma lesions in the abdomen. Black grains, which are surrounded by fibrous capsules and attached to the peritoneal wall, liver, spleen and other internal organs are clearly visible. Mice were dissected 38 days after inoculation. **C:** Stained histology sections of the mycetoma lesion of a mouse intraperitoneally inoculated with 40 mg fungal mycelia and soil adjuvant. The left section, hematoxylin and eosin (100 \times), shows one black grain (arrow) surrounded by inflammatory cells similar to that described in human mycetoma. In the inner zone, neutrophils are the predominant cells, followed by a middle zone containing histocytes. The right section, Grocott methenamine silver stain (400 \times), shows intact growing fungal hyphae embedded in hard cement material protecting the fungus from surrounding inflammatory cells. Mice were dissected at 17 days after inoculation.

M. MYCETOMATIS INFECTION

Adult immunocompetent female BALB/c mice infected intravenously, subcutaneously or intraperitoneally. Intravenous inoculation or subcutaneous inoculation in the foot pad or abdomen at two sites did not result in the development of *M. mycetomatis* infection (data not shown). As shown in Table 1 most of the mice tolerated subcutaneous inoculation in the neck and showed a good survival rate. Only two mice died during the first week after inoculation of 80 mg. Infection did not develop after subcutaneous inoculation in the neck even with the highest inoculum of 120 mg. All mice developed subcutaneous abscesses or nodules, never containing black grains, which reached their maximum size in the first 2 weeks, then started to resolve and disappeared completely within 4–5 weeks. Only mice infected intraperitoneally showed typical mycetoma lesions with characteristic black grains. These mice showed mortality when relatively high inocula were injected. Infection rates after intraperitoneal inoculation increased with increasing inocula. The infection was characterized by typical mycetoma lesions and numerous black grains.

Young immunocompetent and adult corticosteroid-treated or leukocyte-depleted female BALB/c mice infected intraperitoneally. In comparison to adult immunocompetent mice (Table 1), adult corticosteroid-treated mice (Table 2) showed similar survival rates, whereas higher infection susceptibility was noticed in young immunocompetent and adult leukocyte-depleted mice. The difference, however, was not statistically significant ($P=0.07$ and $P=0.12$, respectively) (Table 2). Abdominal mycetomas with many black grains were seen in young immunocompetent mice starting from the inoculum of 8 mg in which two out of eight mice developed infection. The infection rates were inoculum-dependent, and at high inocula were comparable to the infection rates seen in the adult immunocompetent mice.

Young and adult immunocompetent male BALB/c mice infected intraperitoneally. There were no differences in infection rate between the young and the adult immunocompetent male BALB/c mice (Table 3). Compared to young and adult immunocompetent female mice (Table 1 and Table 2) male mice showed similar infection rates. However, infected male mice died more quickly before the dissection days with numerous black grains.

Young immunocompetent female BALB/c mice infected intraperitoneally, role of adjuvant. The data in Table 4 show that the addition of an adjuvant to *M. mycetomatis* is important for the development of the infection. After inoculation of 100 mg *M. mycetomatis* without adjuvant, only one mouse had a single black grain attached to the spleen. Addition of soil or FIA to the same inoculum significantly increased the infection rates (8/12 and 7/11, respectively). The difference in the infection rates when using the soil adjuvant or FIA was statistically significant ($P=0.009$ and $P=0.009$, respectively), but no significant difference was observed between the use of soil or FIA. Soil was used as the standard adjuvant (Table 1, Table 2 and Table 3), except in those experiments designed to study adjuvant activity (Table 4).

Table 1: Course of *M. mycetomatis* infection in adult immunocompetent female BALB/c mice infected via subcutaneous or intraperitoneal routes of inoculation.

Inocula ^a per mouse	0.8 mg	8 mg	40 mg	80 mg	120 mg
Subcutaneous					
Survival rate ^b	4/4	4/4	4/4	6/8 ^c	8/8
Infection rate in surviving mice					
at day 17	0/4	0/4	0/4	0/4	0/4
at day 38	N.D	N.D	N.D	0/2	0/4
at day 51	N.D	N.D	N.D	N.D	N.D
Total infection rate in mice	0/4	0/4	0/4	0/6	0/8
Intraperitoneal					
Survival rate ^b	8/8	8/8	7/8 ^c	1/7 ^c	4/8 ^c
Infection rate in surviving mice					
at day 17	0/4	0/4	1/3	1/1	2/2
at day 38	N.D	N.D	N.D	-	2/2
at day 51	0/4	0/4	2/4	N.D	N.D
Total infection rate in mice	0/8	0/8	3/7	1/1	4/4

^a Inocula of *M. mycetomatis* contained 4 mg sterile soil (regardless of the inoculum size). All mice were infected with inocula ranging from 0.8 to 120 mg.

^b Number of surviving mice/total number of mice.

^c Mice died during the first week, due to toxic side effects, and were excluded from the calculation of the total infection rates.

ND: not done.

Table 2: Course of *M. mycetomatis* infection in young immunocompetent and adult corticosteroid-treated or leukocyte-depleted female BALB/c mice infected via the intraperitoneal route of inoculation.

Inocula ^a per mouse	0.8 mg	8 mg	40 mg	80 mg	100 mg	120 mg	140 mg
Young immunocompetent							
Survival rate ^b	10/10	8/8	6/8 ^c	6/8 ^c	6/8 ^c	6/8 ^c	1/10 ^c
Infection rate in surviving mice							
at day 17	0/4	2/4	1/4	1/3	N.D	3/3	N.D
at day 38	N.D	N.D	N.D	2/3	3/6	3/3	1/1
at day 51	0/6	0/4	1/2	N.D	N.D	N.D	N.D
Total infection rate in mice	0/10	2/8	2/6	3/6	3/6	6/6	1/1
Adult corticosteroid-treated							
Survival rate ^b	8/8	8/8	5/8 ^c				
Infection rate in surviving mice							
at day 17	0/4	0/4	2/3				
at day 38	N.D	N.D	N.D				
at day 51	0/4	0/4	1/2				
Total infection rate in mice	0/8	0/8	3/5				
Adult leukocyte-depleted							
Survival rate ^b	8/8	5/8 ^c	2/8 ^{c,d}				
Infection rate in surviving mice							
at day 17	1/4	1/3	1/2				
at day 38	N.D	N.D	N.D				
at day 51	0/4	2/2	-				
Total infection rate in mice	1/8	3/5	2/3				

^a Inocula of *M. mycetomatis* contained 4 mg sterile soil (regardless of the inoculum size). Young mice were infected with inocula ranging from 0.8 to 140 mg. Immunocompromised mice (corticosteroid-treated or leukocyte-depleted) were infected with inocula ranging from 0.8 to 40 mg.

^b Number of surviving mice/total number of mice.

^c Mice died during the first week, due to toxic side effects, and were excluded from the calculation of the total infection rates.

^d One mouse died with many black grains at day 32 after inoculation, this mouse was considered infected.

ND: not done.

Table 3: Course of *M. mycetomatis* infection in young and adult immunocompetent male BALB/c mice infected via the intraperitoneal route of inoculation

Inocula ^a per mouse	40 mg	80 mg	120 mg
Adult			
Survival rate ^b	8/8	8/8	1/8 ^{c,d}
Infection rate in surviving mice			
at day 17	1/4	4/4	1/1
at day 38	2/4	4/4	-
Total infection rate in mice	3/8	8/8	6/6
Young			
Survival rate ^b	7/8 ^c	8/8	3/8 ^c
Infection rate in surviving mice			
at day 17	0/3	3/4	1/1
at day 38	0/4	2/4	2/2
Total infection rate in mice	1/8	5/8	8/8

^a Inocula of *M. mycetomatis* contained 4 mg sterile soil (regardless of the inoculum size). All mice were infected with inocula ranging from 40 to 120 mg.

^b Number of surviving mice/total number of mice.

^c Mice died with many black grains between days 2 and 5, these mice were considered infected.

^d Two mice died during the first week, due to toxic side effects, and were excluded from the calculation of the total infection rates.

Table 4: Course of *M. mycetomatis* infection in young immunocompetent female BALB/c mice infected via the intraperitoneal route of inoculation with 100 mg of *M. mycetomatis* without or with adjuvant: 4 mg sterile soil or 50% (v/v) FIA.

	Without adjuvant	Soil adjuvant	FIA
Survival rate ^a	12/12	12/12	11/12 ^b
Total infection rate in mice ^c	1/12	8/12	7/11

^a Number of surviving mice/total number of mice.

^b One mouse died during the first week, due to toxic side effects, and was excluded from the calculation of the total infection rates.

^c Infection rate in surviving animals at day 51.

Macroscopic and microscopic development of black grains. In 25% of the adult corticosteroid-treated female mice subcutaneously inoculated with 40 mg mycelium, a big subcutaneous nodule containing numerous small black grains was observed (Figure 1A). In intraperitoneally infected immunocompetent mice, black grains were seen as early as 5 days after the inoculation in mice that died before the scheduled dissection. The grains were black, irregular and hard in consistency (Figure 1B). There was no clear correlation between the size of the grains and time of dissection, although incidentally higher numbers of larger grains were observed with increasing incubation period. Due to the irregularity of the massive abdominal lesions it was considered impossible to count the actual number of grains. Intraperitoneal inoculation of the mice with the inoculum of 100 mg induced the development of a few to a moderate number of grains, while a slight increase of the inoculum up to 120 mg resulted in severely infected mice with many black grains. The black grains were surrounded by a fibrous capsule attached to the peritoneal wall or internal organs, in particular spleen and liver. In some mice it was observed that grains were attached to the diaphragm, but grains were never seen in other body compartments. Black grains were never expelled through genuine sinuses. Histological examination (Figure 1C) of infected tissues showed typical vesicular type of grains surrounded by three zones of inflammatory cells. The first ring of cells around the grains was composed mainly of neutrophils, followed by histiocytes and an outer vascular zone.

DISCUSSION

Mycetoma is a fungal disease affecting the earning sector in the mostly rural communities of endemic areas. Without adequate medical treatment and aggressive surgical intervention, mycetoma remains a major mycological health problem in these areas affecting young productive people and leading to increased morbidity and detrimental social and economic consequences. Models of mycetoma in experimental animals remain extremely important for the study of various aspects of the disease. Very little is known on the pathogenesis and pathology of mycetoma, and one very attractive area of research is the study of therapeutic responses to the broad range of antimicrobial agents presently used in clinical practice. In case of bacterial mycetoma (actinomycetoma), considerable success has been achieved, in which the major infectious agents have been successfully used for infection in laboratory animals [12, 13, 14, 15, 16 and 17]. However, in case of fungal mycetoma (eumycetoma), only few investigators have been successful in developing an animal model [8, 9, 10 and 18].

The aim of our study was to develop a reproducible infection model for the fungus *M. mycetomatis* [5]. In humans, the fungus produces numerous black grains, which are composed of aggregates of the fungal hyphae embedded in a hard extracellular cement material. In the present paper, an infection model for *M. mycetomatis* in young or adult immunocompetent female BALB/c mice is described. Many variables were included in the study. Different routes of inoculation were compared, including subcutaneous inoculation in the neck, in the abdomen or in the foot pad. Also intraperitoneal and intravenous routes of inoculation were applied. In addition, the infection rate was investigated in mice

in relation to age, gender, immune status and addition of adjuvant. Abdominal mycetoma with numerous black grains developed a few weeks after intraperitoneal inoculation of the fungal mycelia suspension in the presence of sterile soil or FIA. After subcutaneous inoculation black grains developed only in immunosuppressed mice, while abdominal mycetoma was seen after intraperitoneal inoculation in all mouse groups regardless of their immune status, age or gender.

Establishment of subcutaneous infection in immunocompetent mice was not successful, which is in agreement with the studies of other investigators [7, 8 and 10]. Subcutaneously inoculated mice developed subcutaneous nodules within 2 weeks. From that time onwards discharge of the inoculum itself to the skin surface of the nodules through draining sinuses was observed. This may explain why subcutaneous mycetoma with black grains did not develop.

Young immunocompetent mice and adult leukocyte-depleted mice showed increased susceptibility to infection compared to adult immunocompetent mice. As most patients with *M. mycetomatis* infection in endemic areas appear to be immunocompetent, we prefer to elaborate on the infection model in young or adult immunocompetent mice. Recent reports, however, stated that one of the predisposing factors for acquiring mycetoma might be a partial suppression of cell-mediated immunity [4], substantiating previous suggestions by some investigators [8, 12 and 19]. In the present study we demonstrate that the *M. mycetomatis* infection can be produced in immunocompetent as well as immunosuppressed mice, thereby suggesting that immune depletion is indeed not needed for the development of mycetoma. Our data do not permit speculation on persistence versus clearance of the fungus. Although our data suggest that the fungus is present persistently, especially when mice are inoculated intraperitoneally, it is unclear whether or not the mice are capable of suppressing the infection as time proceeds. Additional studies should be performed, especially in case the model is going to be used for testing the efficacy of antifungal agents.

Most of the previous work in experimental animals such as rabbits, mice, rats, and guinea pigs failed to result in reproducible models with high infection rates. Already in 1957 Borelli was able to develop *M. mycetomatis* infection in immunocompetent rats using cultures of *M. mycetomatis* mixed with either *Blastomyces dermatitidis* or *Histoplasma capsulatum* [18]. Murray *et al.* [9] were also able to develop mycetoma in immunocompetent mice with characteristic black grains when the inocula were mixed with killed *Mycobacterium tuberculosis*. None of these investigations have been easily reproduced by other researchers [9 and 10]. Mahgoub and his co-workers were able to induce mycetoma due to *M. mycetomatis* only in congenitally athymic nude mice, three out of eight inoculated mice were infected [8]. In recent work, Cremer *et al.* [7] did not use immunosuppression or adjuvant in their mouse model of *M. mycetomatis* infection. Black grains were seen microscopically only after repeated intraperitoneal inoculation, while black grains did not develop after subcutaneous inoculation. From the present study and the work of others, it seems that using adjuvant is necessary to induce mycetoma due to *M. mycetomatis*. Another factor and perhaps more important is the use of relatively high inocula containing at least 40 mg wet weight of the fungal mycelia. This study shows that the infection rate is inoculum-dependent and that the mice were able to clear relatively low inocula.

Factors determining the susceptibility of man and animals to mycetoma remain unclear. Only few people in the endemic areas develop mycetoma, although all share a similar risk through, for instance, walking barefoot and frequent occurrence of minor trauma due to thorn pricks. Most of the patients in the endemic areas are immunocompetent and have no apparent underlying diseases or increased susceptibility to the other endemic infectious diseases.

M. mycetomatis is known to be a sterile fungus. However, the exact nature of the infectious fungus particles in the environment is not exactly known, but it is very unlikely that the fungus exists in the environment in the same form as in man or animals [22]. Possibly the fungus exists in soil in a specialized infectious form or repeated inoculation of small amounts of fungus leads to sensitization and higher susceptibility to the infection in man [10 and 23]. Alternatively, mycetoma endemic areas are also endemic for many infectious parasitic diseases like malaria and worm infections, which could prime the immune system, leading to differing susceptibility to the *M. mycetomatis* infection.

In conclusion, a reproducible model of intraperitoneal *M. mycetomatis* infection has been developed in young and adult immunocompetent female BALB/c mice. The infection rate was found to be inoculum-dependent, and inoculation of 120 mg of fungal mycelia results in the development of many black grains in around 75% of mice when sterile soil is used as adjuvant. Although this mouse model does not exactly simulate the subcutaneous *M. mycetomatis* infection in man, the histopathological features of the lesions and the development of black grains are representative for the human infection. Further studies will be performed to investigate the pathogenesis of the disease and the immune response of the host although it has to be emphasized that atypical intraperitoneal localization of the black grains may be a confounding factor in this respect. The model, however, should prove its value primarily during studies on the prophylactic and therapeutic efficacy of antifungal agents.

Chapter 8

Assessment of In Vitro Susceptibility of *Madurella mycetomatis* to Itraconazole and Amphotericin B by a Modified NCCLS Method and a Viability-based XTT Assay

Abdalla O. A. Ahmed, Wendy W. J. van de Sande, Wim van Vianen, Alex van Belkum, Ahmed H. Fahal, Henri A. Verbrugh and Irma A. J. M. Bakker-Woudenberg

Submitted to Antimicrobial Agents & Chemotherapy

ABSTRACT

The antifungal susceptibility of 36 *Madurella mycetomatis* clinical isolates against amphotericin B and itraconazole was determined using an adapted protocol based on the National Committee of Clinical Laboratory Standards (NCCLS) guidelines M38-A. Furthermore, the 2,3-bis {2-methoxy-4-nitro-5-[(sulfenylamino) carbonyl]-2H-tetrazolium-hydroxide} colorimetric assay (XTT test) was used to quantify the antifungal activity in terms of reduction of viable fungal mass. Since *M. mycetomatis* presents as a putatively sterile hyphal suspension, visual reading of the MIC is difficult, particularly when azoles are used. Quantitative determination of the viable fungal mass using the XTT assay was successfully performed for both amphotericin B as well as itraconazole. The test appeared to be reproducible and sensitive. Investigation of 36 independent clinical *M. mycetomatis* isolates showed that the antifungal effect of itraconazole is superior to that of amphotericin B. For amphotericin B, minimal inhibitory concentrations (MICs) ranged from 0.13 to 4 mg/L, the MIC for 50% of the 36 strains (MIC₅₀) was between 0.5 and 1 mg/L. For itraconazole MICs ranged from 0.016 to 1 mg/L, the MIC₅₀ varied between 0.06 and 0.13 mg/L. The wide range of MICs for both antifungal agents obtained for the clinical *M. mycetomatis* isolates suggests that the introduction of routine antifungal susceptibility testing for this particular species is important for adequate therapeutic management, especially for patients not responding to medical treatment.

INTRODUCTION

Little is known on the in vitro and in vivo susceptibility towards antifungal agents of the fungus *Madurella mycetomatis*, the major cause of eumycetoma. Eumycetoma is a chronic disease, endemic in many tropical and subtropical countries (6). Adequate clinical management of the infection requires prolonged antifungal treatment combined in many cases with extensive surgical treatment (6, 19). A number of antifungal agents is being used for the treatment of eumycetoma, with various degrees of success (10). Very little data is as yet available regarding the susceptibility of *M. mycetomatis* to amphotericin B, the azoles and the echinocandins. In the past, some reports have promoted ketoconazole as the drug of choice in treating eumycetoma patients, sometimes leading to complete cure or, more often, a more limited degree of improvement (8, 16, 17). On the whole, the clinical response to ketoconazole is often poor (5, 19, 20, 26). Other studies show that long term treatment of eumycetoma due to *M. mycetomatis* with itraconazole seems to be the best regimen, although variable responses in patients have also been described (5, 10, 19). Particularly in advanced cases of *M. mycetomatis* eumycetoma the response to medical treatment is poor. As the lesions of patients under medical treatment remain localized and well encapsulated, it is generally agreed that early diagnosis followed by both surgical and medical treatment with appropriate antifungal agents is needed for complete cure (4, 6, 10, 19). Few investigators have published in vitro susceptibility data showing that azoles are capable of inhibiting the growth of at least 50% of the clinical *M. mycetomatis* isolates tested. For determination of the in vitro antifungal susceptibility pattern of *M. mycetomatis* strains no proper study using a standardized protocol has been carried out as yet.

In the present study we evaluated the in vitro activities of two antifungal agents, itraconazole and amphotericin B, against 36 clinical isolates of *M. mycetomatis*. Minimum inhibitory concentrations (MICs) were determined visually using a modified method based on the National Committee of Clinical Laboratory

Standards (NCCLS) guidelines (M38-A) (23). In addition, a quantitative colorimetric method using the dye 2,3-Bis {2-methoxy-4-nitro-5-[(sulfenylamino) carbonyl]-2H-tetrazolium-hydroxide} (XTT) was used for quantification of the antifungal activity (13, 14, 25).

MATERIALS AND METHODS

***M. mycetomatis* strains.** A total of 38 independent clinical isolates obtained from mycetoma patients seen in the Mycetoma Research Clinic (University of Khartoum, Sudan) during the year 1999 were included in the study. All patients originated from diverse and distant regions in Sudan (data not shown). Two additional *M. mycetomatis* clinical strains, isolated from two mycetoma patients from Mali were obtained from Dr. Nicole Desplaces, Croix Saint Simon Hospital, Paris, France (2). All *M. mycetomatis* strains were isolated by direct cultivation of black grains obtained from surgical biopsies. Sabouraud dextrose agar (Difco Laboratories, Becton Dickinson and Company, Paris, France) was used for primary fungal isolation from clinical specimens. Cultures were maintained by repeated subculture in either Malt extract agar (Difco Laboratories, Becton Dickinson and Company, Paris, France) or Sabouraud dextrose agar plates supplemented with 80 mg/l gentamicin (Centrafarm, Etten-Leur, The Netherlands). Species identification was determined by morphology and PCR-RFLP as described before (1, 9).

Antifungal agents. Itraconazole was obtained from Janssen Pharmaceutica Products, Belgium and Amphotericin B was obtained from Bristol-Myers Squibb, Woerden, The Netherlands. Stock solutions of 1600 mg/L were prepared as described by the NCCLS protocol M38-A (23). All stock solutions were stored at -80°C .

In vitro antifungal susceptibility test. The protocol for the susceptibility testing was based on the procedure described for filamentous fungi according to the NCCLS guidelines (M38-A) (23) with some modifications in inoculum preparation and incubation period. The inocula were prepared from a hyphal suspension instead of a conidial suspension. Cultures of *M. mycetomatis* in tubes containing RPMI-1640 with L-glutamine (0.3 g/L), 20 mM 3/4-morpholinopropanesulfonic acid (MOPS) and phenol red were incubated at 37°C for 5 days. The cultures were sonicated for 20 sec at 28 micron maximum power (Soniprep 150, Beun de Ronde, Abcoude, the Netherlands). The sonicated hyphal suspensions were used to inoculate 40 mL of RPMI-1640 medium followed by incubation at 37°C for 10 days. Mycelia were harvested by 5 min centrifugation at 2158 g and washed once with sterile saline. The pellet was resuspended into 15 ml of RPMI-1640 with L-glutamine and MOPS, but without phenol red. To obtain a homogenous hyphal suspension, the mycelia were sonicated again. To reduce the effect of surface hydrophobicity of the hyphae, Tween-60 (Merck, Amsterdam, The Netherlands) was added in a final concentration of 0.05%. The inocula were diluted in RPMI-1640 medium and the transmissions were adjusted to 70% at 660 nm using a spectrophotometer (Novaspec II, Pharmacia Biotech). For visual determination of the antifungal susceptibility the broth macrodilution method in tubes was applied using two-fold dilutions of the antifungal agents according to the NCCLS guidelines. The inoculated tubes were incubated for 7 days at 37°C . To avoid confusion due to the nature of the hyphal inocula, additional inoculum "reading" controls (hyphal suspension in saline without antifungals) were always included. In addition, growth controls (hyphal suspension in RPMI without antifungals) were included. Visually the degree of fungal growth was assessed and graded to four scales ranging from score 4 (no reduction in

fungal growth) up to score 0 (complete absence of fungal growth). For both amphotericin B and itraconazole, MICs were determined as the lowest concentration that prevented any discernible fungal growth.

XTT assay. After visual reading of the antifungal effect the viable fungal mass was determined colorimetrically as described by Meletiadis *et al.* (21) with some modifications. In short, XTT powder (Sigma-Aldrich Chemie, Zwijndrecht, The Netherlands) was dissolved in saline to prepare 500 mg/L stock solution. A working solution of XTT was prepared by mixing 5 ml of the XTT stock solution with 0.6 ml 1 mM menadione (Sigma-Aldrich Chemie, Zwijndrecht, The Netherlands) and 4.4 ml saline. All tubes were incubated with 660 μ l XTT working solution (250 μ g/ml), and incubated for 2 h at 37°C and for another 3 h at room temperature. The tubes were then centrifuged for 1 min at 187 g and 300 μ l of the supernatant was transferred to flat-bottom microtiter plates. The extinction of the supernatant was measured spectrophotometrically at 450 nm in the BioRad model 550 microplate reader (Bio-Rad Laboratories Inc., Veenendaal, The Netherlands).

RESULTS:

The antifungal activity of amphotericin B and itraconazole against a number of *M. mycetomatis* isolates was determined visually according to the modified NCCLS guidelines and the XTT assay for quantification of the viable fungal mass.

Figure 1 shows the susceptibility of *M. mycetomatis* strain (mm-55) to amphotericin B and itraconazole, respectively, according to the XTT assay. Exposure of mm-55 to increasing concentrations of amphotericin B resulted in a concentration-dependent reduction in viable fungal mass, with a sudden switch from no reduction to full reduction. Repeating the assay eight times showed highly reproducible results. A concentration-dependent gradual decrease in viable fungal mass was observed when mm-55 was exposed to itraconazole. Again the results were highly reproducible.

In Figure 2, the *in vitro* antifungal activity of amphotericin B and itraconazole against the *M. mycetomatis* strain mm-55 according to the XTT assay versus the modified NCCLS method are compared. A rapid switch from no reduction in fungal growth to absence of fungal growth at increasing concentrations of amphotericin B was observed which is in full agreement with the sharp switch in viable fungal mass as determined by the XTT assay. The MIC of *M. mycetomatis* mm-55 for amphotericin B was 2 mg/L. Fungal exposure to itraconazole resulted in a concentration dependent gradual reduction in fungal growth determined by the modified NCCLS method. Again these results agreed with the gradual decrease in viable fungal mass following the XTT assay. The MIC of *M. mycetomatis* mm-55 for itraconazole was 0.5 mg/L.

Figures 3-5 show the susceptibility of 36 *M. mycetomatis* clinical isolates determined by the modified NCCLS method (Figure 3) or the XTT assay (Figures 4 and 5). Four out of forty Sudanese isolates available could not be evaluated as the inocula of 3 isolates could not be homogenized efficiently and one isolate did not grow in RPMI medium. The 36 *M. mycetomatis* strains were tested three times, and the median value is presented in the Figures. For amphotericin B, the MIC values (modified NCCLS method) ranged from 0.13 to 4 mg/L, the MIC for 50% of the 36 strains (MIC₅₀) was between 0.5 and 1 mg/L (Figure 3). For itraconazole, the MIC values ranged from 0.016 to 1 mg/L, whereas the MIC₅₀ ranged between 0.06

and 0.13 mg/L (Figure 3).

Figure 4 and 5 show the result of the antifungal effect in term of reduction of viable fungal mass. With the XTT assay 100% reduction in viable fungal mass could not be established for all *M. mycetomatis* strains as a number of strains produced pigments influencing the color intensity. For all 36 *M. mycetomatis* isolates less than 20% of the viable fungal mass remained with amphotericin B in a concentration range of 0.13 to 16 mg/L. For itraconazole this concentration range turned out to range between 0.016 to 1 mg/L. Amphotericin B concentrations and itraconazole concentrations resulting in more than 50% reduction of the viable fungal mass ranged from 0.06 to 4 mg/L, and 0.016 to 0.5 mg/L, respectively.

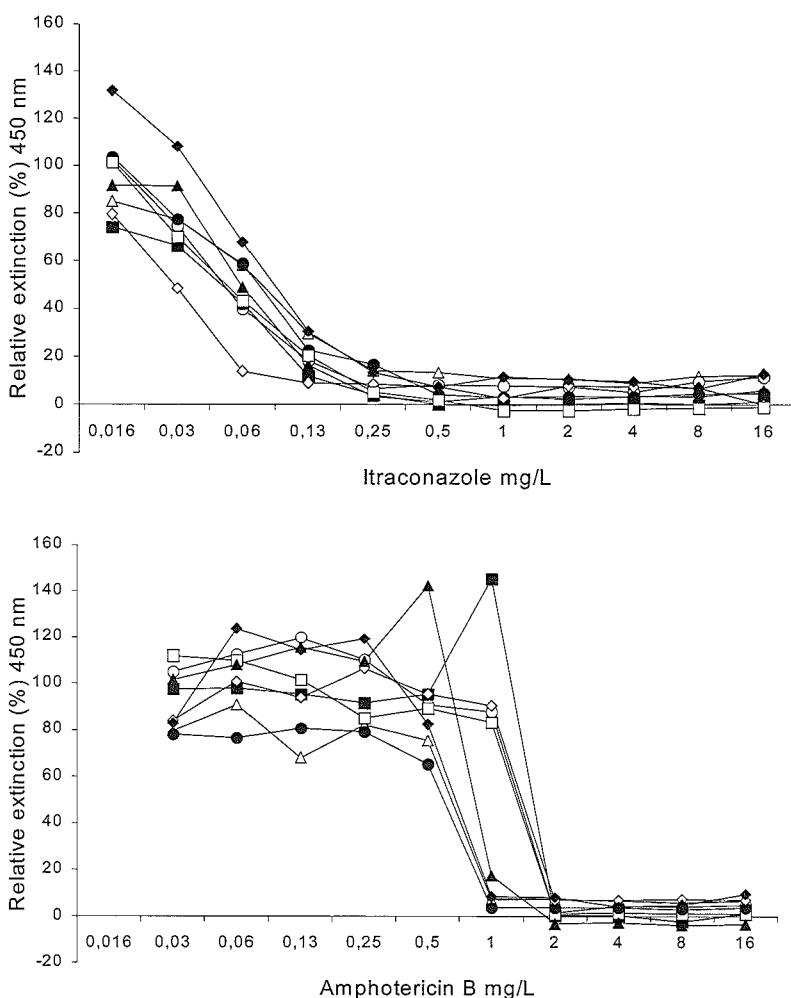


Figure 1: Reproducibility of susceptibility testing of *M. mycetomatis* strain mm-55 against amphotericin B and itraconazole using the XTT method. Curves represent the relative extinction at 450 nm for each drug concentration compared to the growth control (100%). Assays were repeated eight times.

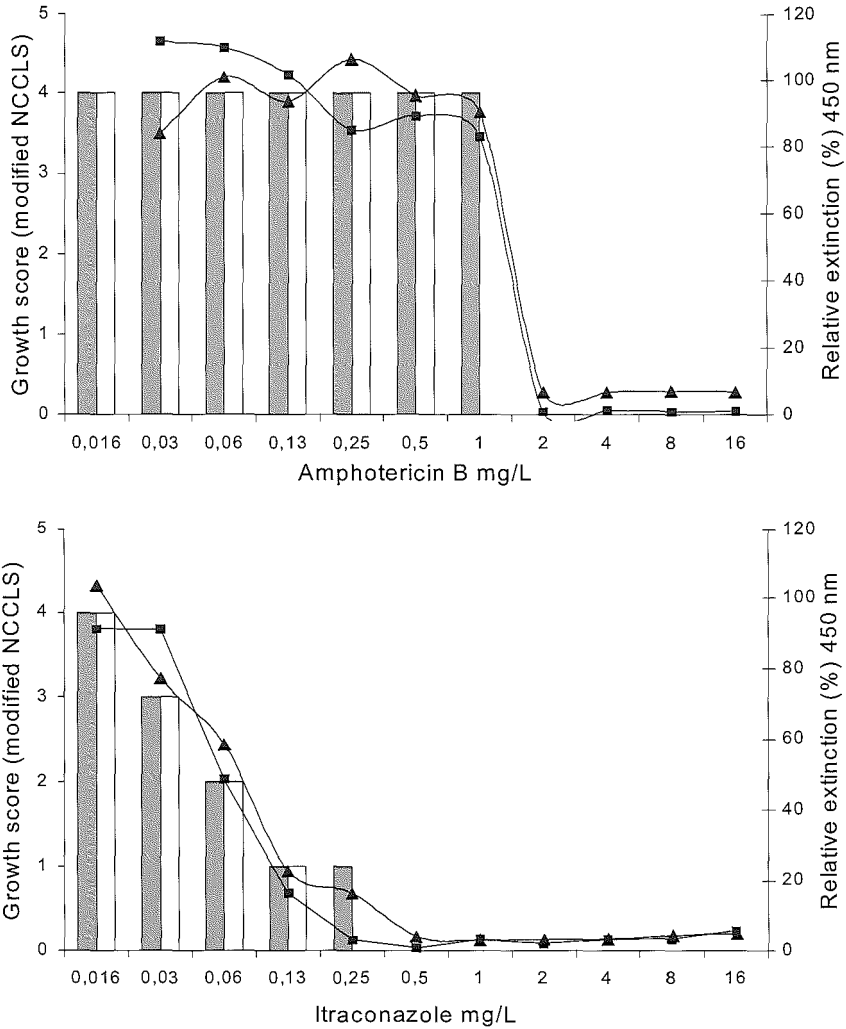


Figure 2: Antifungal susceptibility testing of *M. mycetomatis* strain mm-55 against amphotericin B and itraconazole in duplicate. Curves represent the relative extinction at 450 nm for each drug concentration compared to the growth control (100%) obtained by the XTT assay. Bars represent the growth levels obtained by the modified NCCLS method

Assessment of In Vitro Susceptibility to Itraconazole and Amphotericin B

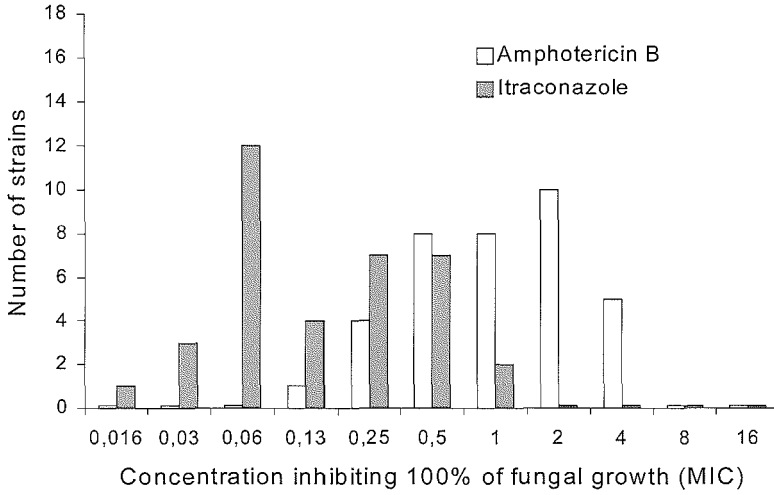


Figure 3: Antifungal susceptibility of 36 *M. mycetomatis* clinical isolates against amphotericin B and itraconazole according the modified NCCLS method.

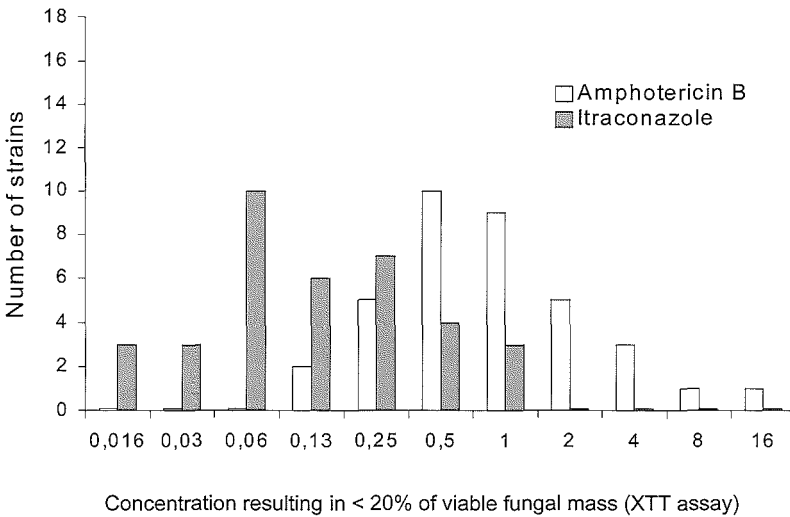


Figure 4: Antifungal susceptibility of 36 *M. mycetomatis* clinical isolates for amphotericin B and itraconazole resulting in less than 20% of viable fungal mass obtained with the XTT assay.

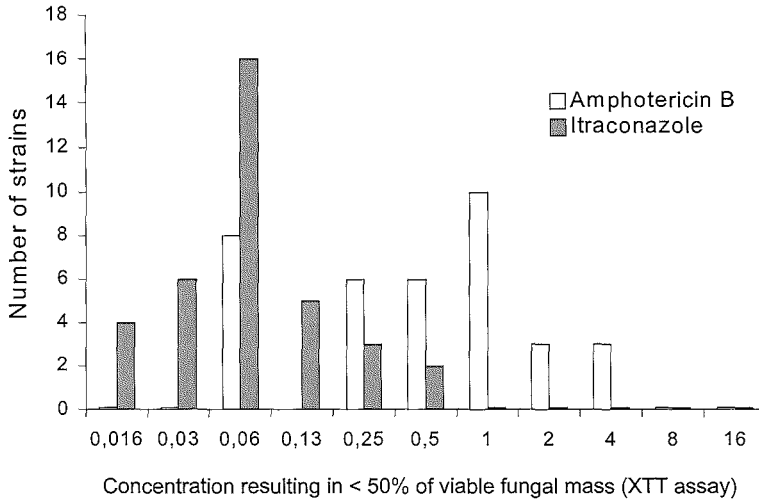


Figure 5: Antifungal susceptibility of 36 *M. mycetomatis* clinical isolates for amphotericin B and itraconazole resulting in less than 50% of viable fungal mass obtained with the XTT assay.

DISCUSSION:

Conflicting reports of the clinical response of eumycetoma to antifungal treatment, together with evidence of varying response of eumycetoma cases to treatment with azoles motivated us to develop a standardized method for the antifungal susceptibility testing of *M. mycetomatis* (19). A standard method for determination of the antifungal susceptibility for *M. mycetomatis* is not available. As a result, limited data are available regarding the antifungal susceptibility of this major cause of mycetoma (5, 19, 20, 27). In general and unlike bacteria, the different behavior of filamentous fungi makes it impossible to use one standard method for antifungal susceptibility testing. Even with the standardized NCCLS documents for different groups of fungi, further adaptation is needed for *Madurella* spp (7, 11). The protocol described in the present study for susceptibility testing of *M. mycetomatis* was based on the NCCLS guidelines (M38-A) which is the recommended method for spore-forming filamentous fungi such as *Aspergillus* spp. For these fungi, a conidial suspension is used as an inoculum (23). Preparing a standardized inoculum for poorly differentiating and hardly- to non-sporulating (sterile) fungal species, like *M. mycetomatis*, is problematic (9). In the present study inocula were prepared from hyphae instead of conidia. To standardize the inoculum the harvested hyphae were first homogenized and the inoculum density was set at 70% optical transmission as recommended for spores in the NCCLS guideline. The inocula of *M. mycetomatis* were found to be within the recommended range of 0.4×10^4 to 0.5×10^4 CFU per ml (data not shown) (23). For amphotericin B, reproducible results with the modified NCCLS method were obtained for 90% of the *M. mycetomatis* isolates included in the study. However, for itraconazole visual reading of the gradually decreasing antifungal activity was not always accurate. A wide range of MICs of amphotericin B as well as itraconazole for our clinical isolates originating from the same region was obtained. This is irrespective of the fact that based upon genetic parameters all strains seem to be clonally related (3). This implies that gene expression differences rather than differential gene presence or absence is a driving factor in the development of antifungal resistance. These observations underscore the necessity of antifungal

susceptibility testing before or during the treatment of eumycetoma in endemic areas. Assessment of antifungal susceptibility may be particularly useful in patients not responding to medical treatment.

In the present study a second method for antifungal susceptibility testing of *M. mycetomatis*, the XTT assay, was used as well. In this assay the antifungal activity can be quantified by relating the viable fungal mass to levels of fungal mitochondrial dehydrogenase activity, converting XTT into formazan, a colored end product. The XTT assay was considered to be more appropriate and accurate for determination of antifungal susceptibility of *M. mycetomatis* as the nature of the fungal inoculum is a suspension of hyphae. The initial hyphal suspension already shows a significant turbidity which complicates visual reading of the inhibition of fungal growth. Determination of the antifungal susceptibility of the 36 *M. mycetomatis* isolates following the XTT assay generated reproducible data. For amphotericin B the XTT assay showed good agreement with the MIC determined by the modified NCCLS method. This overall agreement was also documented by Meletiadis *et al.* who investigated various other fungal species (21). However, for itraconazole visual reading of the MICs according to the modified NCCLS method was difficult and was not always in agreement with the XTT values.

Exposure of *M. mycetomatis* to amphotericin B resulted in a rapid concentration-dependent decline in viability, as observed with both methods of susceptibility testing. In contrast, after exposure to itraconazole a gradual concentration-dependent effect was seen with both methods. Investigation of 36 clinical *M. mycetomatis* isolates shows that the antifungal effect of itraconazole is superior to that of amphotericin B, as confirmed by both methods of susceptibility testing. Approximately 45% of the 36 *M. mycetomatis* isolates were susceptible to itraconazole concentrations less than 0.13 mg/L, whereas amphotericin B was not effective at those concentrations. Less than 1 mg/L itraconazole already inhibited the growth of all 36 *M. mycetomatis* isolates, whereas at that concentration amphotericin B inhibited the growth of only 21 out of 36 isolates. A fourfold increase in concentration up to approximately 4 mg/L amphotericin B was needed for prevention of growth of all 36 isolates. Significant variation in susceptibility to both amphotericin B and itraconazole between the 36 *M. mycetomatis* isolates was seen (see Figures 3-5).

The data from the present study demonstrate that low concentrations of itraconazole are effective in inhibiting the growth of *M. mycetomatis*. This is in agreement with the findings of McGinnis *et al.* for itraconazole and other filamentous ascomycetes (20). Other investigators also found that itraconazole was effective in inhibiting the growth of many other clinically relevant fungi. Li and his colleagues showed that 90% of dimorphic fungi included in their study were inhibited by 1 mg/L of itraconazole (15). Activity of itraconazole against dermatophytes (11) and agents of hyalohyphomycosis, phaeohyphomycosis, chromoblastomycosis and mycetoma was also demonstrated (20). With respect to clinical efficacy Yera *et al.* recently described that itraconazole has been effectively used for the treatment of a case of fungal mycetoma due to *Fusarium solani* (28).

The in vitro susceptibility of the *M. mycetomatis* isolates may nominate itraconazole to be the drug of choice for the treatment of eumycetoma due to *M. mycetomatis*. Experience in our clinic also showed that itraconazole is effective in treating patients with eumycetoma due to *M. mycetomatis*. Most of our patients showed good a response to long term treatment with itraconazole, although variable responses are also seen (unpublished data). Whether these observations correlate with variation in susceptibility to itraconazole for the *M. mycetomatis* isolates is currently not known. Clinical experience underscores that

treatment of chronic, advanced eumycetoma requires continuation for a prolonged period of time, even when apparent clinical improvement occurs at early stages. In some advanced cases medical treatment alone is not enough (22).

Although amphotericin B is widely used in the treatment of many invasive fungal infections, the future use of this drug in mycetoma patients cannot be recommended. About 40% of the *M. mycetomatis* isolates included in this study had an amphotericin B MIC which is higher than the average peak plasma level of 1.5 mg/L (24). In addition to the relatively low antifungal activity, the requirement for long term treatment of mycetoma patients together with the toxicity of amphotericin B further limits its use as a first line therapeutic agent.

In the present study an inoculum prepared from hyphae was used instead of conidia. Manavathu (1999) showed that in case of *Aspergillus fumigatus* similar MIC values can be obtained when using inocula prepared from conidia or hyphae. These authors concluded that the physical and biological nature of the inoculum hardly affected the measurements (18). In contrast, Guarro and co-workers showed high in vitro discrepancies in antifungal susceptibility of filamentous fungi observed when inocula were prepared from either hyphae or conidia (12). Here we show that there is essentially no discrepancy between the outcome of two methods for assessing the antifungal susceptibility of *M. mycetomatis* strains. Apparently, the nature of the inoculum is not much of a compromising factor.

In conclusion, a modified protocol based on the NCCLS guidelines (M38-A) was developed and adapted for antifungal susceptibility testing of *M. mycetomatis*. As the inocula are prepared from a hyphal suspension, visual reading of the MIC is not always accurate. The XTT assay, allowing colorimetric measurement, seems to be preferable for antifungal susceptibility testing of *M. mycetomatis* since it avoids having to read results visually. The XTT assay appeared to be very reproducible and the percentual decrease in viable fungal mass can be assessed at different levels, providing additional insight in the dynamics of fungal killing. We here show that determination of 50% reduction in viable fungal mass probably is appropriate to establish the relative antifungal activity of a number of antifungal agents. The present study shows that for the *M. mycetomatis* isolates tested the antifungal effect of itraconazole is superior to that of amphotericin B. Further work is needed to study the in vivo activity of both agents and to evaluate the possible correlation between the in vitro results and the clinical response. The recent availability of an animal model of *M. mycetomatis* infection may in the near future assist in the definition of the clinical relevance of the susceptibility towards antifungals in establishing adequate therapeutic protocols.

REFERENCES:

1. **Ahmed, A. O., M. M. Mukhtar, M. Kools-Sijmons, A. H. Fahal, S. de Hoog, B. Gerrits Van den Ende, E. E. Zijlstra, H. Verbrugh, E. S. Abugroun, A. M. Elhassan, and A. van Belkum.** 1999. Development of a species-specific PCR-restriction fragment length polymorphism analysis procedure for identification of *Madurella mycetomatis*. *J. Clin. Microbiol.* **37**:3175-8.
2. **Ahmed, A.O., N. Desplaces, P. Leonard, F. Goldstein, S. De Hoog, H. Verbrugh, and A. van Belkum.** 2003. Molecular detection and identification of agents of eumycetoma: detailed report of two cases. *J. Clin. Microbiol.*, in press.
3. **Ahmed, A.O., W. van de Sande, H. Verbrugh and A. van Belkum.** *Madurella mycetomatis* strains from mycetoma lesions in Sudanese patients are clonal. *J. Clin. Microbiol.* **41**:4537-41.
4. **Andreu, J. M.** 1986. Actual treatment of fungus mycetoma: interest in associating ketoconazole and conservative surgery. *Med. Trop. (Mars).* **46**:293-7.
5. **Bayles, M. A.** 1992. Tropical mycoses. *Chemother.* **38**:27-34.
6. **Boiron, P., R. Locci, M. Goodfellow, S. A. Gumaa, K. Isik, B. Kim, M. M. McNeil, M. C. Salinas-Carmona, and H. Shojaei.** 1998. *Nocardia*, nocardiosis and mycetoma. *Med. Mycol.* **36**:26-37.
7. **Capilla, J., M. Ortoneda, F. J. Pastor, and J. Guarro.** 2001. In vitro antifungal activities of the new triazole UR-9825 against clinically important filamentous fungi. *Antimicrob. Agents Chemother.* **45**:2635-7.
8. **Cuce, L. C., E. L. Wroclawski, and S. A. Sampaio.** 1980. Treatment of paracoccidioidomycosis, candidiasis, chromomycosis, lobomycosis, and mycetoma with ketoconazole. *Int. J. Dermatol.* **19**:405-8.
9. **de Hoog, G. S., J. Guarro, J. Gene, and M. J. Figueras.** 2000. Atlas of clinical fungi, Second ed. Centraalbureau voor Schimmelcultures / Universitat Rovira i Virgili.
10. **Fahal, A. H.** 2002, posting date. Mycetoma Review Article (Mycetoma updates). Mycetoma Research Center, University of Khartoum. [Online.]
11. **Fernandez-Torres, B., A. J. Carrillo, E. Martin, A. Del Palacio, M. K. Moore, A. Valverde, M. Serrano, and J. Guarro.** 2001. In vitro activities of 10 antifungal drugs against 508 dermatophyte strains. *Antimicrob. Agents Chemother.* **45**:2524-8.
12. **Guarro, J., C. Llop, C. Aguilar, and I. Pujol.** 1997. Comparison of in vitro antifungal susceptibilities of conidia and hyphae of filamentous fungi *Antimicrob. Agents Chemother.* **41**:2760-2.
13. **Hawser, S. P., C. Jessup, J. Vitullo, and M. A. Ghannoum.** 2001. Utility of 2,3-bis(2-methoxy-4-nitro-5-sulfophenyl)-5-[(phenyl-amino)carbonyl]-2-H-tetrazolium hydroxide (XTT) and minimum effective concentration assays in the determination of antifungal susceptibility of *Aspergillus fumigatus* to the lipopeptide class compounds. *J. Clin. Microbiol.* **39**:2738-41.
14. **Hawser, S. P., H. Norris, C. J. Jessup, and M. A. Ghannoum.** 1998. Comparison of a 2,3-bis(2-methoxy-4-nitro-5-sulfophenyl)-5- [(phenylamino)carbonyl]-2H-t etrazolium hydroxide (XTT) colorimetric method with the standardized National Committee for Clinical Laboratory Standards method of testing clinical yeast isolates for susceptibility to antifungal agents. *J. Clin. Microbiol.*

- 36:1450-2.
15. **Li, R. K., M. A. Ciblak, N. Nordoff, L. Pasarell, D. W. Warnock, and M. R. McGinnis.** 2000. In vitro activities of voriconazole, itraconazole, and amphotericin B against *Blastomyces dermatitidis*, *Coccidioides immitis*, and *Histoplasma capsulatum*. *Antimicrob. Agents Chemother.* **44**:1734-6.
 16. **Mahgoub el, S.** 1994. Medical treatment of mycetoma. *Sudan Medical Journal.* **32**:88-97.
 17. **Mahgoub, E. S., and S. A. Gumaa.** 1984. Ketoconazole in the treatment of eumycetoma due to *Madurella mycetomi*. *Trans. R. Soc. Trop. Med. Hyg.* **78**:376-9.
 18. **Manavathu, E. K., J. Cutright, and P. H. Chandrasekar.** 1999. Comparative study of susceptibilities of germinated and ungerminated conidia of *Aspergillus fumigatus* to various antifungal agents *J. Clin. Microbiol.* **37**:858-61.
 19. **McGinnis, M. R.** 1996. Mycetoma. *Dermatol. Clin.* **14**:97-104.
 20. **McGinnis, M. R., and L. Pasarell.** 1998. In vitro testing of susceptibilities of filamentous ascomycetes to voriconazole, itraconazole, and amphotericin B, with consideration of phylogenetic implications. *J. Clin. Microbiol.* **36**:2353-5.
 21. **Meletiadis, J., J. W. Mouton, J. F. Meis, B. A. Bouman, P. J. Donnelly, and P. E. Verweij.** 2001. Comparison of spectrophotometric and visual readings of NCCLS method and evaluation of a colorimetric method based on reduction of a soluble tetrazolium salt, 2,3-bis [2-methoxy-4-nitro-5-[(sulfenylamino) carbonyl]-2H-tetrazolium-hydroxide], for antifungal susceptibility testing of *Aspergillus* species. *J. Clin. Microbiol.* **39**:4256-63.
 22. **Smith, E. L., and S. Kutbi.** 1997. Improvement of eumycetoma with itraconazole. *J. Am. Acad. Dermatol.* **36**:279-80.
 23. **National committee for Clinical Laboratory Standards.** 2002. Reference method for broth dilution antifungal susceptibility testing of filamentous fungi, Approved standard M38-A. National committee for Clinical Laboratory Standards, Wayne, Pennsylvania.
 24. **Rippon, J. W.** 1988. *Medical Mycology, the pathogenic fungi and the pathogenic actinomycetes*, Third edition. W.B. Saunders Company, Philadelphia.
 25. **Tellier, R., M. Krajdén, G. Grigoriev, and I. Campbell.** 1992. Innovative endpoint determination system for antifungal susceptibility testing of yeasts. *Antimicrob. Agents Chemother.* **36**:1619-25.
 26. **Venugopal, P. V., and T. V. Venugopal.** 1993. Treatment of eumycetoma with ketoconazole. *Australas. J. Dermatol.* **34**:27-9.
 27. **Venugopal, P. V., T. V. Venugopal, E. S. Ramakrishna, and S. Ilavarasi.** 1993. Antimycotic susceptibility testing of agents of black grain eumycetoma. *J. Med. Vet. Mycol.* **31**:161-4.
 28. **Yera, H., M. E. Bougnoux, C. Jeanrot, M. T. Baixench, G. De Pinieux, and J. Dupouy-Camet.** 2003. Mycetoma of the Foot Caused by *Fusarium solani*: Identification of the Etiologic Agent by DNA Sequencing. *J. Clin. Microbiol.* **41**:1805-8.

Chapter 9

General discussion

Chapter 9

Mycetoma is a chronic granulomatous subcutaneous infection caused either by bacteria (actinomycetoma) or fungi (eumycetoma) (5). Actinomycetoma responds better to antibiotics and other antimicrobial agents, whereas eumycetoma is always difficult to treat (11). The mycetoma infection is supposed to originate after traumatic inoculation of plant materials like thorns or splinters contaminated with the causative agents (5, 11).

Many studies have been published about mycetoma describing all aspects of the infection. A large number of citations can be retrieved from the PubMed-Medline when the search term "mycetoma" is used, but not all are actually describing mycetoma. The term mycetoma is often inappropriately used to describe other fungal conditions like fungal balls or fungomata (11). However, review articles, original papers, case reports, letters and other formats describing the history, epidemiology, etiology, pathology, clinical presentation and management have appeared in the literature. However, the literature is dominated by clinical case reports and case management. Little attention has been paid to basic research on host-parasite relationships, ecology of mycetoma agents, immunological and molecular characterization of mycetoma causative agents, advanced high-tech diagnosis and possible vaccine development. The clinical disease and its history, epidemiology, etiology and pathology have been reviewed in chapter 1 of this thesis with special emphasis on *Madurella mycetomatis* infection.

Successful medical and surgical treatment depends on the correct identification of the causative agent (5, 11). Currently available diagnostic tests of mycetoma are few and with many limitations. Direct examination of the produced grains is useful in differentiation of mycetoma into actinomycetoma and eumycetoma, but especially fungal species identification can not be easily determined. The color of grains may give a clue about the possible causative agents (5), but may be also confusing. For instance, both *Pseudallescheria boydii* and *Nocardia brasiliensis* cause white grains mycetoma. However, the former is a fungus whereas the latter is a bacterial species (12). Even if the causative organism is isolated in pure culture, identification remains a problem. Many fungi that cause mycetoma remain sterile or show poor morphological differentiation (reference 6 and chapter 3). In order to improve the identification of the causative organisms of mycetoma we developed a DNA-based technique for the identification of *M. mycetomatis*, the major cause of mycetoma in Sudan and other tropical countries (5, 11). We presented for the first time nucleotide sequences of the rDNA operon of *M. mycetomatis*. Study of the ITS spacer region in the ribosomal genes, showed that clinical isolates of *M. mycetomatis* from large endemic area belong to the same single species. By using this molecular diagnostic technique, *M. mycetomatis* can be easily differentiated from other fungal agents of mycetoma including members of the genus *Madurella*, such as *Madurella grisea*. Despite the development of conventional mycological techniques for the identification of clinically relevant fungi, PCR and sequencing of the ribosomal gene are some times needed for the identification of uncommon and poorly differentiated fungi (7). The etiological agents of two unexpected cases of eumycetoma were identified by the help of PCR and sequencing as described in chapter 3. Implementation of our new test may question the species identification of the causative agents of many previously reported cases of eumycetoma. In most reports agents were identified either by culture morphology or histopathology alone. The molecular test presented in this thesis may help to identify the real prevalence of *M. mycetomatis* as a causative agent of mycetoma.

The exact prevalence of mycetoma in endemic areas is not known, but its incidence has been previously

described. Abbott in 1956 described the admission of thousands of new cases within a few years in an endemic area like Sudan (1), with an estimated number of 300-400 new cases each year (9). Climate factors, especially the rain fall, were found to be the most important factors affecting the distribution of mycetoma causative agents (5). In chapter 4 ecological data of the fungus *M. mycetomatis* are presented. Direct isolation of the fungus from soil and plant materials always failed, although Thirumalachar and Padhye were able to isolate *M. mycetomatis* in a very low recovery rate (13). However, using nested PCR *M. mycetomatis* DNA was detected in 25% of the specimens collected from endemic areas. Our observations support the hypothesis that mycetoma agents found in the soil or plants materials in the endemic areas are clinically relevant. No teleomorph structures have been described for this fungus. The exact nature of the infectious stage in the lifecycle is not known. Natural mycetoma in animals has been described, but no other animal or plant reservoir host has thus far been reported. Therefore, further work is still needed to provide precise ecological data and to help explaining the pathogenesis of the infection. From the current study and the previous work of many investigators, it seemed that the induction of the infection in laboratory animal is not easy. Infection of animal needs high inocula in combination with an adjuvant. In nature, it is unlikely that the fungus exists in the same form as in cultures and clinical samples. In order to resist the harsh environmental conditions during the dry seasons, this fungus should be able to develop specialized spores. These spores may have the capacity to induce the infection when accidentally inoculated in the subcutaneous tissues.

In chapter 5 the phylogeny and typification of *M. mycetomatis* were addressed. SSU and ITS regions in the rDNA of *M. mycetomatis* clinical isolates and other morphologically similar environmental fungal isolates were studied. Sequences were compared to reference strains of *M. mycetomatis* from established culture collections and with other known agents of eumycetoma. *M. mycetomatis* and *M. grisea* are considered to be members of a single genus (12). Based on rDNA SSU and ITS sequencing data, the two species were proven to be heterogeneous. *M. mycetomatis* is probably belonging to the ascomycete order Sordariales, while *M. grisea* is likely to be a member of the order Pleosporales in the class ascomycete. In addition to *M. grisea*, the order Pleosporales contains other known agents of eumycetoma *Leptosphaeria*, *Pseudochaetosphaeronema* and *Pyrenochaeta*. Due to the fact that many microbiologists do not attempt to induce sporulation in cultures identified as *M. grisea*, it is impossible to know how many of these cultures are actually *Pyrenochaeta mackinnonii* (reference 11 and figure 1 in chapter 5). These data are also supported by the fact that *M. mycetomatis* and *M. grisea* have a different geographical distribution (12). *Neotestudina rosatii*, which belongs to the order Dothideales, seems to make species complexes with *M. mycetomatis*. However, sequences data of the SSU and ITS rDNA showed that the ascomycete genus *Chaetomium*, in the order Sordariales, is among the closest relatives of *M. mycetomatis*. This suggests that *M. mycetomatis* is a sterile member of the order Sordariales.

Two opposing theories about the etiological agents of eumycetoma were also discussed in chapter 5. The theory suggesting that wide range of saprotrophic agents can actually cause eumycetoma was strongly supported. The problem with the incorrect identification of agents of eumycetoma, leads to the over presentation of a limited number of agents. However, it was also found that in some endemic areas a limited number of agents are responsible of all eumycetoma cases (2, 3).

Mycetoma patients have diverse clinical presentations. In order to investigate the possible correlation

General discussion

described. Abbott in 1956 described the admission of thousands of new cases within a few years in an endemic area like Sudan (1), with an estimated number of 300-400 new cases each year (9). Climate factors, especially the rain fall, were found to be the most important factors affecting the distribution of mycetoma causative agents (5). In chapter 4 ecological data of the fungus *M. mycetomatis* are presented. Direct isolation of the fungus from soil and plant materials always failed, although Thirumalachar and Padhye were able to isolate *M. mycetomatis* in a very low recovery rate (13). However, using nested PCR *M. mycetomatis* DNA was detected in 25% of the specimens collected from endemic areas. Our observations support the hypothesis that mycetoma agents found in the soil or plants materials in the endemic areas are clinically relevant. No teleomorph structures have been described for this fungus. The exact nature of the infectious stage in the lifecycle is not known. Natural mycetoma in animals has been described, but no other animal or plant reservoir host has thus far been reported. Therefore, further work is still needed to provide precise ecological data and to help explaining the pathogenesis of the infection. From the current study and the previous work of many investigators, it seemed that the induction of the infection in laboratory animal is not easy. Infection of animal needs high inocula in combination with an adjuvant. In nature, it is unlikely that the fungus exists in the same form as in cultures and clinical samples. In order to resist the harsh environmental conditions during the dry seasons, this fungus should be able to develop specialized spores. These spores may have the capacity to induce the infection when accidentally inoculated in the subcutaneous tissues.

In chapter 5 the phylogeny and typification of *M. mycetomatis* were addressed. SSU and ITS regions in the rDNA of *M. mycetomatis* clinical isolates and other morphologically similar environmental fungal isolates were studied. Sequences were compared to reference strains of *M. mycetomatis* from established culture collections and with other known agents of eumycetoma. *M. mycetomatis* and *M. grisea* are considered to be members of a single genus (12). Based on rDNA SSU and ITS sequencing data, the two species were proven to be heterogeneous. *M. mycetomatis* is probably belonging to the ascomycete order Sordariales, while *M. grisea* is likely to be a member of the order Pleosporales in the class ascomycete. In addition to *M. grisea*, the order Pleosporales contains other known agents of eumycetoma *Leptosphaeria*, *Pseudochaetosphaeronema* and *Pyrenochaeta*. Due to the fact that many microbiologists do not attempt to induce sporulation in cultures identified as *M. grisea*, it is impossible to know how many of these cultures are actually *Pyrenochaeta mackinnonii* (reference 11 and figure 1 in chapter 5). These data are also supported by the fact that *M. mycetomatis* and *M. grisea* have a different geographical distribution (12). *Neotestudina rosatii*, which belongs to the order Dothideales, seems to make species complexes with *M. mycetomatis*. However, sequences data of the SSU and ITS rDNA showed that the ascomycete genus *Chaetomium*, in the order Sordariales, is among the closest relatives of *M. mycetomatis*. This suggests that *M. mycetomatis* is a sterile member of the order Sordariales.

Two opposing theories about the etiological agents of eumycetoma were also discussed in chapter 5. The theory suggesting that wide range of saprotrophic agents can actually cause eumycetoma was strongly supported. The problem with the incorrect identification of agents of eumycetoma, leads to the over presentation of a limited number of agents. However, it was also found that in some endemic areas a limited number of agents are responsible of all eumycetoma cases (2, 3).

Mycetoma patients have diverse clinical presentations. In order to investigate the possible correlation

markers and therapeutic targets.

General discussion

REFERENCES:

1. **Abbott, P.** 1956. Mycetoma in the Sudan. *Trans R Soc Trop Med Hyg.* **50**:11-30.
2. **Ahmed, A. O., E. S. Abugroun, A. Fahal, E. Zijlstra, A. van Belkum and H. Verbrugh.** 1998. Unexpected high prevalence of secondary bacterial infection in patients with mycetoma. *J Clin Microbiol.* **36**:850-1.
3. **Ahmed, A. O., M. M. Mukhtar, M. Kools-Sijmons, A. H. Fahal, S. de Hoog, B. G. van den Ende, E. E. Zijlstra, H. Verbrugh, E. S. Abugroun, A. M. Elhassan, and A. van Belkum** 1999. Development of a species-specific PCR-restriction fragment length polymorphism analysis procedure for identification of *Madurella mycetomatis* *J Clin Microbiol.* **37**:3175-8.
4. **Bendl, B. J., D. Mackey, F. Al-Saati, K. V. Sheth, S. N. Ofole, and T. M. Bailey** 1987. Mycetoma in Saudi Arabia. *J Trop Med Hyg.* **90**:51-9.
5. **Boiron, P., R. Locci, M. Goodfellow, S. A. Gumaa, K. Isik, B. Kim, M. M. McNeil, M. C. Salinas-Carmona, and H. Shojaei** 1998. *Nocardia*, nocardiosis and mycetoma. *Med Mycol.* **36**:26-37.
6. **de Hoog, G. S., A. Buiting, C. S. Tan, A. B. Stroebel, C. Ketterings, E. J. de Boer, B. Naafs, R. Brimicombe, M. K. Nohlmans-Paulssen, G. T. Fabius, A.H. Klokke and C.G. Visser.** 1993. Diagnostic problems with imported cases of mycetoma in The Netherlands. *Mycoses.* **36**:81-7.
7. **de Hoog, G. S., J. Guarro, J. Gene, and M. J. Figueras** 2000. Atlas of clinical fungi, Second ed. Centraalbureau voor Schimmelcultures / Universitat Rovira i Virgili.
8. **Fahal, A. H., and S. H. Suliman** 1994. Clinical presentation of mycetoma. *Sudan Med. J.* **32**:46-66.
9. **Lynch, J. B.** 1964. Mycetoma in the Sudan. *Ann R Coll Surg Engl.* **35**:319-40.
10. **Mahgoub, E. S., S. A. Gumaa, and A. M. El Hassan** 1977. Immunological status of mycetoma patients. *Bull Soc Pathol Exot Filiales.* **70**:48-54.
11. **McGinnis, M. R.** 1996. Mycetoma. *Dermatol Clin.* **14**:97-104.
12. **Rippon, J. W.** 1988. Medical Mycology, the pathogenic fungi and the pathogenic actinomycetes, Third edition ed. W.B. Saunders Company, Philadelphia.
13. **Thirumalachar, M. J., and A. A. Padhye** 1968. Isolation of *Madurella mycetomi* from soil in India. *Hindustan Antibiot Bull.* **10**:314-8.
14. **Yera, H., M. E. Bognoux, C. Jeanrot, M. T. Baixench, G. De Pinieux, and J. Dupouy-Camet** 2003. Mycetoma of the Foot Caused by *Fusarium solani*: Identification of the Etiologic Agent by DNA Sequencing. *J Clin Microbiol.* **41**:1805-8.

Summary

Samenvatting

Acknowledgement

Curriculum vitae

List of publications

SUMMARY

Madurella mycetomatis is the most common cause of eumycetoma in tropical and sub tropical countries. The mycetoma infection is a serious mycological problem affecting a large number of active members of the society in endemic areas. The infection is difficult to treat and has an important social and economical impact on affected patients. *M. mycetomatis* is a fungus showing poor morphological differentiation, and identification of the species is always difficult.

The early diagnosis is one of the key elements mandatory to successful treatment of mycetoma. This, however, is not easy due to the many limitations of the currently used diagnostic techniques such as direct examination of grains, culture and histopathology. In an attempt to improve the diagnosis, we developed a PCR-RFLP procedure for the detection and identification of the fungus in cultures and clinical specimens. The *M. mycetomatis* ribosomal gene complex was amplified and sequenced using fungal universal primers. Two sets of species-specific PCR primers were designed. Based on ITS sequences and RFLP patterns, clinical isolates from Sudan were found to belong to a single species. In chapter 3, complicated eumycetoma cases were reported, in which the etiological agents were identified using diagnostic PCR and DNA sequencing. The novel PCR primers were also used for the study of the environmental occurrence of *M. mycetomatis* in endemic regions. Direct culture-based isolation of *M. mycetomatis* from the patient's surrounding environment failed, but DNA was detected in 25% of the environmental specimens (chapter 4). The phylogenetic relationship of *M. mycetomatis* to morphologically similar fungal species was also studied, and its taxonomic position in the fungal kingdom was redefined. Our results suggested that *M. mycetomatis* belongs to the ascomycete order Sordariales, while the other proposed member of the same genus "*Madurella grisea*" likely to be a member of the order Pleosporales (chapter 5).

In order to establish the genetic relatedness of *M. mycetomatis* clinical isolates, a collection of isolates from two endemic foci in Africa were analyzed using large-scale RAPD typing. These analyses showed a complete lack of DNA fingerprint variation between the various isolates. These results suggest that there is little genetic variation among clinically relevant *M. mycetomatis* strains from the regions involved (chapter 6).

A reproducible infection model for *M. mycetomatis* in BALB/c mice was developed. Different routes of inoculation, adjuvant types, host immune status, and gender of mice were evaluated. The infection was found to be inoculum-dependent with increased infection rates for larger inocula. Adjuvants were needed for the induction of the infection (chapter 7).

The antifungal susceptibility of *M. mycetomatis* to amphotericin B and itraconazole was studied using two new protocols, one adapted from the NCCLS approved guidelines M38-A, the other assay was developed to quantify the antifungal activity. Most of the *M. mycetomatis* clinical isolates were highly susceptible to itraconazole, but not to amphotericin B (chapter 8).

In conclusion, sequence data from the *M. mycetomatis* rDNA were used to develop a novel diagnostic PCR-RFLP procedure for the identification of *M. mycetomatis* in cultures, clinical specimens, the environment and for solving diagnostic problems with unexpected, complex patient cases. In addition, molecular biological techniques enabled us to study the ecology, taxonomy and phylogeny of *M. mycetomatis*. An infection model in mice was developed and is now ready to be used for the study of

the pathology, immunology and the in vivo susceptibility to common antifungal agents of *M. mycetomatis*.

A sound basis for future research into (early) serodiagnosis, host susceptibility towards *M. mycetomatis* infection and in vivo therapeutic studies has been laid.

SAMENVATTING

De schimmel *Madurella mycetomatis* is de belangrijkste verwekker van eumycetoma in tropische- en subtropische gebieden. Mycetoma-infectie is een ernstig mycologisch probleem, waarmee in endemische gebieden een belangrijk deel van de economisch-actieve bevolking wordt geconfronteerd. De infectie is moeilijk te behandelen en heeft een grote sociaal-economische invloed op de besmette patiënt. *M. mycetomatis* is een schimmel welke morfologisch lastig te identificeren is en om die reden is identificatie een moeizame opgave.

Het sleutelwoord voor een succesvolle behandeling van mycetoma is sneldiagnostiek. Dit is momenteel lastig te realiseren, vanwege het gebrek aan adequate diagnostische testen. Een direct onderzoek van de schimmelkorrels bijvoorbeeld, is niet erg specifiek. In een poging om deze diagnostiek te verbeteren, ontwikkelden wij een PCR-RFLP procedure om potentiële isolaten van de schimmel *M. mycetomatis* uit culturen en klinisch materiaal te identificeren. Een deel van het ribosomale genencomplex van *M. mycetomatis* werd geamplificeerd m.b.v. universele "schimmelprimers" en bovendien werden twee paar soortspecifieke primers op basis van sequentieanalyse ontwikkeld (hoofdstuk 2). Op basis van ITS sequenties en RFLP patronen is gebleken dat klinische isolaten afkomstig uit Soedan tot één enkele soort behoren. In hoofdstuk 3 zijn gecompliceerde cases van eumycetoma beschreven, waarbij de ziekteveroorzakende agentia werden aangetoond m.b.v. PCR en DNA sequentie analyse. De nieuwe PCR primers werden ook toegepast in een PCR analyse, waarbij de aanwezigheid van *M. mycetomatis* in omgevingsmonsters van endemische gebieden werd onderzocht. Op groei gebaseerde isolatie van *M. mycetomatis* in de directe omgeving van de patiënt mislukte, maar in 25% van de omgevingsmonsters werd specifiek DNA aangetoond (hoofdstuk 4). Eveneens werd de fylogenetische verwantschap van *M. mycetomatis* met morfologisch gelijke schimmelsoorten bestudeerd en de taxonomische positie van dit soort in het schimmelrijk werd opnieuw gedefinieerd. Onze resultaten suggereren dat *M. mycetomatis* waarschijnlijk behoort tot de ascomycetenorde van de Sordariales, terwijl een ander lid van dezelfde familie, *Madurella grisea*, waarschijnlijk tot de orde van Pleosporales behoort (hoofdstuk 5).

Om de genetische verwantschap van klinisch relevante *M. mycetomatis* isolaten vast te stellen, werd een stammencollectie afkomstig van twee Afrikaanse endemische haarden geanalyseerd d.m.v. een grootschalige RAPD typeringsonderzoek. Deze analyse toonde het volledig ontbreken van DNA "fingerprint" variabiliteit tussen de verschillende stammen aan en suggereerde een compleet gebrek aan genetische variatie tussen klinisch-relevante *M. mycetomatis* stammen in dit gebied (hoofdstuk 6). Een reproduceerbaar *M. mycetomatis* mycetoma infectiemodel in BALB/c muizen werd ontwikkeld. De invloed van diverse parameters, zoals de route van inoculatie, het gebruik van adjuvantia, de immuun status, de leeftijd en het geslacht van de muizen werden geëvalueerd. De infectie bleek afhankelijk van de aard van het inoculum te zijn, waarbij de mate van infectie recht evenredig aan de inoculumgrootte was. Het toedienen van adjuvantia bleek noodzakelijk voor het succesvol induceren van de infectie, de immuunstatus van de gastheer bleek van minder belang (hoofdstuk 7).

De antifungale gevoeligheid van *M. mycetomatis* voor amfotericine B en itraconazol werd onderzocht. Hierbij werden twee experimentele protocollen voor filamenteuze fungi ontwikkeld en toegepast. Eén

assay was afgeleid van de door het NCCLS goedgekeurde standaard richtlijn M38-A, met de andere assay kan de antifungale activiteit van de middelen kwantitatief gemeten worden. De overgrote meerderheid van de klinische *M. mycetomatis* isolaten vertoonden een hoge gevoeligheid voor itraconazol, maar waren in mindere mate gevoelig voor amfotericine B (hoofdstuk 8).

Concluderend, de rDNA sequentie gegevens van *M. mycetomatis* werden gebruikt om een diagnostische PCR-RFLP techniek te ontwikkelen. De test is bruikbaar om *M. mycetomatis* uit culturen en klinisch materiaal kon worden te identificeren. Bovendien werden moleculair biologische technieken toegepast om de ecologie, taxonomie en fylogenie van *M. mycetomatis* te bestuderen. Een infectiemodel in muizen werd ontwikkeld en is nu geschikt om de pathologie, immunologie en de in-vivo gevoeligheid van *M. mycetomatis* ten opzichte van de algemeen gebruikte antifungale middelen te bestuderen. Voor deze categorie geneesmiddelen werd een in vitro gevoeligheidstest ontwikkeld. Een stevige basis voor toekomstig onderzoek in serumdiagnostiek, de gastheergevoeligheid voor *M. mycetomatis* infecties en in vivo therapie studies, is hiermee gelegd.

ACKNOWLEDGEMENTS

I would like to take this opportunity to express my sincerest gratitude to all the colleagues who provided me with help and assistance during the course of my study, and who significantly contributed to make the work presented in this thesis possible. A list of colleagues that I would specifically like to mention is presented below, and if your name does not appear, then please accept my apologies and consider this statement as acknowledgement for the valuable contribution that you have made to my thesis.

Firstly, I would like to express my thanks and gratitude to my Ph.D. supervisor **Professor Henri A. Verbrugh**, Head Department of Medical Microbiology and Infectious Diseases, Erasmus MC, Rotterdam, The Netherlands. I thank him for his kind and unlimited academic and financial support. I would also like to thank him and his department for the kind hospitality that I enjoyed over the past two years. I am also very grateful for his valuable suggestions and comments during the course of this study.

Secondly, I would like to express my deep thanks and gratitude to my second supervisor **Professor Ahmed H. Fahal**, Department of Surgery, Faculty of Medicine, University of Khartoum, Sudan. Special thanks to him for giving me the opportunity to work in the Mycetoma Research Group. I thank him for giving me confidence in myself, continuous advice, encouragement and kindness, and last but not least unlimited support.

Professor Alex Van Belkum was my co-supervisor, and as such is the main person working behind the scene to realize my thesis. I can't thank him enough or really express my feelings of gratitude for what he has done for me during my period of study in Rotterdam. I am especially grateful for his unlimited personal help, support, encouragement and scientific supervision.

Many thanks are also due to **Dr. Irma A. J. M. Bakker-Woudenberg**, who also gave me the opportunity to work under her supervision. I am very grateful for her support and advice regarding the development of mouse infection model and the in vitro susceptibility testing studies. This work would have never been done without her personal help and support.

Special thanks go to **Professor Sybren De Hoog**, Centraalbureau voor Schimmelcultures (CBS), Utrecht, The Netherlands for his wonderful collaboration. He was always kind and helpful, always willing to provide valuable suggestions. Of course, my appreciation and thanks also go out to all members of staff and colleagues at the CBS, since a considerable part of the work described in this thesis was performed there. I especially appreciated the help of **Bert** and **Kasper**.

I am very grateful for my colleagues in the Research and Development Unit, Department of Medical Microbiology and Infectious Diseases, Erasmus MC. Special thanks to **Dr. Willem van Leeuwen** for helping me with almost everything and providing me with valuable advice and for his help in preparing and printing this thesis.

Many thanks to my colleague **Wendy van de Sande**, who performed a large proportion of the laboratory work presented in this thesis. I thank her for doing the practical work with the RAPD and the antifungal susceptibility testing studies. In addition, she was a great help in supervising the animal model studies and in maintaining the *M. mycetomatis* culture collections.

I would also like to express my appreciation, hospitality and assistance of by the Rotterdam colleagues, namely: **John Hays, Nicole Lemmens, Dr. Nicole van den Braak, Deborah Horst-Kreft, Cindy van der Schee, H el ene Boelens, Susan Snijders, Kimberly Eadie, Dr. Wim Ang and Marly Kools-Sijmons.**

I thank **Wim van Vianen** and **Marian T. ten Kate** for their continuous support and help during the mouse experiments and antifungal susceptibility testing.

Our departmental secretaries (especially **Marian Humphrey**), and all other members of the department should all be mentioned as well. They were, without exception, nice, friendly and helpful.

Many thanks to **Dr. Peter Hermans, Theo Hoogenboezem** and **Marcel Sluijter** from the Department of Pediatrics, Erasmus MC and **Dr. Hans Kusters** and **Dr. Arnoud van Vliet** from the Hepatology and Gastroenterology Department, Erasmus MC, for their help and support.

I am very grateful to **Dr. Eduard E. Zijlstra**, Head of the Department of Medicine, Faculty of Medicine, Malawi, who initiated this collaboration with the Dutch centers. I would like to give him my thanks and gratitude for his kind help and follow-up during the course of my study.

Special thanks to **Professor Ahmed M. Elhassan, Professor Moawia M. Mukhtar, Professor Eltahir A. G. Khalil** and **Dr. Muntasir E. Ibrahim**, Institute of Endemic Diseases, University of Khartoum, Sudan, for their kind hospitality and useful comments and suggestions.

This work would have never been done without the continuous help and support of my colleagues from the **Faculty of Medical Laboratory Sciences**, University of Khartoum, Sudan.

Of course, at this point, I would like to mention my mother, late father, wife and family: **Karima, Osman, Nowar, Muaz** and **Zeinab**, who have been a source of encouragement and strength to me during my stay in The Netherlands and the whole of my life.

Finally, most thanks go my **God "Allah"** who has been my support not only during the course of this study, but during my whole life.

CURRICULUM VITAE

The author of this thesis was born in Delft, The Netherlands on the 5th of April 1972, while his father was studying geology in The Netherlands. The author received his higher secondary education in Sudan, and then he studied medical laboratory sciences at the University of Khartoum. After his graduation in 1995 he became a member of the academic staff of the Faculty of Medical Laboratory Sciences, University of Khartoum. In May 2000 he got a master's degree in Molecular Biology from the Institute of Endemic diseases, University of Khartoum. The research submitted for the master degree was done in the Department of Medical Microbiology and Infectious Diseases, Erasmus MC, The Netherlands within the mycetoma research collaboration. After that the author stayed and worked in The Netherlands for more than two years as a trainee research assistant, and this Ph.D. thesis was prepared at the Erasmus University. The author is currently working as lecturer in the Department of Microbiology, Faculty of Medical Laboratory Sciences, University of Khartoum, Sudan.

List of publications:

1. Fahal, A. H., A. M. el Hassan, **A. O. Ahmed**, and H. E. Sheik. 1998. Cystic mycetoma: an unusual clinical presentation of *Madurella mycetomatis* infection. *Trans R Soc Trop Med Hyg* 92(1):66-7.
2. **Ahmed, A. O.**, E. S. Abugroun, A. Fahal, E. Zijlstra, A. van Belkum and H. Verbrugh. 1998. Unexpected high prevalence of secondary bacterial infection in patients with mycetoma. *J Clin Microbiol* 36(3):850-1.
3. **Ahmed, A. O.**, A. van Belkum, A. H. Fahal, A. E. Elnor, E. S. Abougroun, M. F. Vanden Bergh, E. E. Zijlstra, and H. A. Verbrugh. 1998. Nasal carriage of *Staphylococcus aureus* and epidemiology of surgical-site infections in a Sudanese university hospital. *J Clin Microbiol* 36(12):3614-8.
4. **Ahmed, A. O.**, M. M. Mukhtar, M. Kools-Sijmons, A. H. Fahal, S. de Hoog, B. G. van den Ende, E. E. Zijlstra, H. Verbrugh, E. S. Abugroun, A. M. Elhassan, and A. van Belkum. 1999. Development of a species-specific PCR-restriction fragment length polymorphism analysis procedure for identification of *Madurella mycetomatis*. *J Clin Microbiol* 37(10):3175-8.
5. Mahdi, S. E., **A. O. Ahmed**, H. Boelens, A. Ott, E. S. Abugroun, A. van Belkum, E. Zijlstra, H. Verbrugh, and A. Fahal. 2000. An epidemiological study on the occurrence of *Staphylococcus aureus* in superficial abscesses of patients presenting for surgery in a teaching hospital in Khartoum, Sudan. *FEMS Immunol Med Microbiol* 29(2):155-62.
6. El Hassan, A. M., A. H. Fahal, **A. O. Ahmed**, A. Ismail, and B. Veress. 2001. The immunopathology of actinomycetoma lesions caused by *Streptomyces somaliensis*. *Trans R Soc Trop Med Hyg* 95(1):89-92.
7. **Ahmed, A. O.**, D. Adelman, A. Fahal, H. Verbrugh, A. van Belkum, and S. de Hoog. 2002. Environmental occurrence of *Madurella mycetomatis*, the major agent of human eumycetoma in Sudan. *J Clin Microbiol* 42(3):1031-6.
8. **Ahmed A. O.**, Wim van Vianen, Marian T. ten Kate, Wendy W.J. van de Sande, Alex van Belkum, Ahmed H. Fahal, Henri A. Verbrugh and Irma A.J.M. Bakker-Woudenberg. 2003. A murine model of *Madurella mycetomatis* eumycetoma *FEMS Immunol and Med Microbiol* 37(1):29-36.

9. **Ahmed A. O.**, Wendy van de Sande, Henri Verbrugh, Ahmed Fahal and Alex van Belkum. 2003. *Madurella mycetomatis* strains from mycetoma lesions in Sudanese patients are clonal. J Clin Microbiol. **41**:4537-4541.
10. De Hoog GS, D. Adelmann, **A. O. Ahmed** and A. van Belkum. 2003. Phylogeny and typification of *Madurella mycetomatis* and phenetically similar agents of eumycetoma. Mycoses. In press
11. **Ahmed A. O.**, Nicole Desplaces, Sybren De Hoog, Henri Verbrugh and Alex van Belkum. 2003. Eumycetoma caused by *Madurella mycetomatis* identified by PCR and sequencing: a report of two cases. J Clin Microbiol. In press.
12. **O. A. Ahmed**, Wendy W. J. van de Sande, Wim van Vianen, Alex van Belkum, Ahmed H. Fahal, Henri A. Verbrugh and Irma A. J. M. Bakker-Woudenberg. Assessment of In Vitro Susceptibility of *Madurella mycetomatis* to Itraconazole and Amphotericin B by a Modified NCCLS Method and a Viability-based XTT Assay. Submitted to Antimicrob Agents Chemother.