

EUR Research Information Portal

Oral lichen planus

Publication status and date:

Published: 17/11/2005

Document Version

Publisher's PDF, also known as Version of record

Citation for the published version (APA):

Laeijendecker, R. (2005). *Oral lichen planus*. [Doctoral Thesis, Erasmus University Rotterdam]. Erasmus Universiteit Rotterdam (EUR).

[Link to publication on the EUR Research Information Portal](#)

Terms and Conditions of Use

Except as permitted by the applicable copyright law, you may not reproduce or make this material available to any third party without the prior written permission from the copyright holder(s). Copyright law allows the following uses of this material without prior permission:

- you may download, save and print a copy of this material for your personal use only;
- you may share the EUR portal link to this material.

In case the material is published with an open access license (e.g. a Creative Commons (CC) license), other uses may be allowed. Please check the terms and conditions of the specific license.

Take-down policy

If you believe that this material infringes your copyright and/or any other intellectual property rights, you may request its removal by contacting us at the following email address: openaccess.library@eur.nl. Please provide us with all the relevant information, including the reasons why you believe any of your rights have been infringed. In case of a legitimate complaint, we will make the material inaccessible and/or remove it from the website.

ORAL LICHEN PLANUS

R. Laeijendecker

Dit proefschrift is tot stand gekomen zonder enige vorm van externe financiering of sponsoring.

Academic thesis to obtain Ph.D. degree in Medical Sciences at the Erasmus University Rotterdam.

Photograph on the cover:

‘La Bocca della Verità’. ‘The Mouth of Truth’. In the portico of the church of Santa Maria in Cosmedin, Rome, ITALY.

ISBN 90-5335-068-3

© 2005, R. Laeijendecker

Lay-out: Grafische Vormgeving Kanters, Sliedrecht
Printed by Drukkerij Ridderprint B.V., Ridderkerk

No part of this thesis may be reproduced or transmitted in any forms by means, electronic or mechanical, including photocopying, recording or any information storage and retrieval system, without permission in writing from the publisher (R. Laeijendecker, dermatologist, Albert Schweitzer Hospital, Albert Schweitzerplaats 25, 3318 AT Dordrecht, The Netherlands).

ORAL LICHEN PLANUS

Orale lichen planus

Proefschrift

ter verkrijging van de graad van doctor aan de
Erasmus Universiteit Rotterdam
op gezag van de
rector magnificus
Prof.dr. S.W.J. Lamberts
en volgens besluit van het College voor Promoties.

De openbare verdediging zal plaatsvinden op
donderdag 17 november 2005 om 13.30 uur

door

Ronald Laeijendecker

geboren te Dordrecht

Promotiecommissie

Promotor: Prof.dr. H.A.M. Neumann

Overige leden: Prof.dr. J.W. Oosterhuis
Prof.dr. E.P. Prens
Prof.dr. I. van der Waal

Copromotor: Dr. B. Tank

*“Si tibi videtur quod multa scis, et satis bene intellegis,
scito tamen quia sunt multo plura quae nescis”.*

*“Als het u schijnt, dat gij veel weet, en vrij goed begrijpt,
weet dan, dat er nog veel meer is, dat gij niet weet”.*

Thomas A Kempis (1380-1471), *De imitatione Christi* 1. 2. 3.

“Artes serviunt vitae, sapientia imperat”.
“Wetenschappen dienen het leven, wijsheid beheerst het”.

Lucius Annaeus Seneca (3 B.C.-65), *Epistulae* 85. 32.

Voor de zorg van de patiënten met OLP

Voor Marjon, Annelien, Michiel en Esther

Voor mijn ouders

In herinnering: mijn broer Erik

CONTENTS

List of abbreviations	9
Chapter 1 General introduction and aim of the thesis	13
Chapter 2 Oral lichen planus: A review of the literature	25
Chapter 3 A: Oral lichen planus and allergy to dental amalgam restorations	109
B: Lichenoid contact stomatitis (Editorial)	123
Chapter 4 A: Oral manifestations of gold allergy	129
B: An update on gold allergy	141
Chapter 5 Premalignant nature of oral lichen planus	147
Chapter 6 Oral lichen planus and hepatitis C virus infection	159
Chapter 7 Oral lichen planus in childhood	167
Chapter 8 A comparison of treatment of oral lichen planus with topical tacrolimus and triamcinolone acetonide ointment	179
Chapter 9 Clinical guidelines on the management of oral lichen planus	187
Chapter 10 Summary, general discussion and recommendations for further research	195
Chapter 11 Samenvatting, algemene discussie en aanbevelingen voor verder onderzoek	207
Figures and legends to the figures	219
Dankwoord	229
Curriculum vitae	233
Bibliography	237

LIST OF ABBREVIATIONS

ALAT	Alanine aminotransferase
Alc	in alcohol 70% (ethanol)
ALP	Alkaline phosphatase
ANA	Anti-nuclear antigen
ANOVA	(Statistical) Analysis of Variance
Aq	Aqueous solution
ASAT	Aspartate aminotransferase
Au	Gold
B-cells	“Bursa of Fabricius” (Bone marrow-dependant) cells
BCG	Bacille Calmette-Guérin
Bis-GMA	2,2-bis[4-(2-hydroxy-3-methacryloxypropyloxy)phenyl]-propane
BMS	Burning mouth syndrome
BMZ	Basal membrane zone
C	Complement
CD	Cluster determinant or cluster of differentiation antigen
cm	centimeter(s)
Cl	Chloride
CLP	Cutaneous lichen planus
CO ₂	Carbon dioxide
COX	Cyclooxygenase
DNA	Deoxyribonucleic acid
ELISA	Enzyme-linked immunosorbent assay
F	Female
FSH	Follicle-stimulating hormone
G0	no growth in the cell cycle
G1	post-mitotic growth phase
GGT	Gamma-glutamyl transpeptidase
GVHD	Graft-versus-host disease
HAV	Hepatitis A virus
HBV	Hepatitis B virus
HCV	Hepatitis C virus
HDL	High density lipoprotein
HE	Hematoxylin and Eosin
HEMA	Hydroxyethyl methacrylate
HIV	Human immunodeficiency virus
HLA	Human leukocyte antigen (or Human leukocyte system A)

HSP	Heat shock protein
GM-CSF	Granulocyte-macrophage colony-stimulating factor
I	International
ICAM	Intercellular adhesion molecule
IF	Immunofluorescence
IFN	Interferon
Ig	Immunoglobulin
IL	Interleukin
KDa	kilodalton
Kg	kilogram
LDE(s)	Lichenoid drug eruption(s)
LDH	Lactate dehydrogenase
LDL	Low density lipoprotein
LE	Lupus erythematosus
LFA	Lymphocyte function-associated antigen
LH	Luteinizing hormone
LP	Lichen planus (OLP + CLP)
LPSA	Lichen planus-specific antigen
M (or M in TNM-system)	Male (or distant metastases)
M.	Morbus
MHC	Major Histocompatibility Complex
mg	milligram(s)
ml	milliliter(s)
MTX	Methotrexate
N	Lymph nodes
ND:YAG	Neodymium: yttrium-aluminium-garnet
nm	nanometer
OLP	Oral lichen planus
OLPa	Oral lichen planus in adulthood (age older than 17 years)
OLPc	Oral lichen planus in childhood (age younger than 18 years)
OSCC	Oral squamous cell carcinoma
p	the short arm of a chromosome
P	Probability
PAS	Periodic acid-Schiff
Pet	in Petrolatum
PLEVA	Pityriasis lichenoides et varioliformis acuta
PPDA	Paraphenylenediamine
(P)UVA	(Psoralens and) ultraviolet-A
RNA	Ribonucleic acid
T	Primary tumor
TB	Total bilirubin

T3	Triiodothyronine
T4	Thyroxin
T-cells	Thymus-dependant cells
TCR	T-cell receptor
TEGDMA	Triethyleneglycol dimethacrylate
TEN	Toxic epidermal necrolysis
TNF	Tumor necrosis factor
TSH	Thyroid-stimulating hormone
U	Units
UVB	Ultraviolet-B
VCAM	Vascular cell adhesion molecule
VLDL	Very low density lipoprotein
VVGS	Vulvovaginal-gingival syndrome
WHO	World Health Organization

CHAPTER 1

GENERAL INTRODUCTION AND AIM OF THE THESIS

General introduction

Oral diseases are usually local, but may also be the signs of systemic diseases, including dermatological disorders.^{1,2} Generally, the disorders of the oral cavity are studied by the dentist, the general practitioner, several dental and medical specialisms such as the Oral and Maxillofacial Surgery, the Periodontology, the Otorhinolaryngology, the Internal Medicine and the Dermatology.

Dermatology may be defined literally as the study of the skin and its diseases.³ However, today dermatology is a separate medical specialism, which is not only confined to the skin, but also includes the study of the disorders of the adjacent mucous membranes (for example, the oral cavity), many internal diseases, environmental (chemicals, plants and radiation) and psychological factors which may influence the skin, phlebology, oncology, dermatological surgery, venereology, allergology, microbiology, immunology, histopathology, genetics and pharmacotherapy.³ In the second half of the 20th century, there was a considerable increase in the dermatological knowledge especially on sophisticated research techniques in dermatology. Research techniques involving biochemistry, electron microscopy, immunology, immuno-cytochemistry and molecular biology have provided a better understanding of the pathogenesis and the treatment of many skin diseases.³

A short treatise on the history of medicine (historia medicinae) and dermatology

“L’histoire de la science, c’est la science même”.

Auguste Comte (1798-1857).

The medical science is as old as the mankind itself. The same applies to the study of skin diseases.⁴ However, the expression “dermatology” is from more recent times.⁵ The important ancient nations such as Egypt, Greece, the Roman Empire, India and China have largely influenced the medical science. A clay tablet with a text in cuneiform writing on the preparation of medication from the Babylonian period (more than 4000 years ago) is perhaps one of the oldest remnants of medicine (nowadays in the Museum of the University of Pennsylvania, U.S.A.). More than 2000 years ago specialists on skin diseases from Egypt were invited to Rome for their expertise and knowledge. In the Bible, there are many reports on skin diseases.⁴ “Leprosy” in the Old Testament probably also includes disorders such as scabies, psoriasis, pellagra, tuberculosis, syphilis and vitiligo.⁶ Hippocrates (460-377 B.C.) from Greece has been considered to be “the father of the medical science” (Figure A). The intrinsic power of healing of an individual overcomes most diseases. The doctor is only the servant, not the master of nature (“minister non magister naturae”). Hippocrates had high ethical regard for the medical pro-

fession (“Officium nobile”). This is seen by the famous “Oath of Hippocrates”, which is still taken after qualifying medical examination. The hospital “Asklepion” of Hippocrates is on the Greek island of Kos with a view of Turkey. The remnants may still be visited today.⁴

Several famous names in the history of medicine are Celsus, da Vinci, Paracelsus, Vesalius, Sydenham, Harvey, Virchow, Pasteur, Van Foreest, Semmelweis, Lister, Boerhaave, Dunant, Fleming, Einthoven, Röntgen, Curie, Osler, Freud, Schweitzer and Kolff. Each of them has influenced the medical science significantly, but the exact contribution made by each is beyond the scope of this thesis.⁴ One exception is Albert Schweitzer (1875-1965) from the Elzas, who was a physician, theologian, philosopher, historian and a musician. He gave up a brilliant medical career to heal the poor and needy in Lambarene (Gabon in Africa). His basic principle was “the respect for all living things”. In his opinion the vocation for a doctor should be “being beneficial to the health of all patients”, which is still true today.⁷

G. Mercuriale (1530-1606) of Venice in Italy is credited with writing the first treatise on dermatology in 1572, also considered to be the first systematic textbook on diseases of the skin.^{5,8} It was written in Latin and was essentially a compilation of ancient writers.⁹ In 1714, D. Turner (1667-1741) of London in England authored “De morbis cutaneis. A treatise of diseases incident to the skin”, the first textbook on dermatology in the English language or in any vernacular other than Latin.¹⁰ In 1777, A. Lorry (1726-1783) of Paris in France described for the first time the skin as a living organ and noted its interaction with other organs. This contrasted with the previously held view that the skin was merely an enclosure for the body.⁹ J.J.R. (von) Plenck (1738-1807) of Vienna in Austria proposed a new classification of skin diseases in “Doctrina de morbis cutaneis” mostly based on the morphology of the characteristic skin lesions.¹¹ More than 20 years later R. Willan (1757-1812) from England improved this work and Th. Bateman (1778-1821) completed it. Dermatology was begun as a specialty in France in 1801 by J.L. Alibert (1768-1837).¹² V. Chiarugi (1759-1820) was the first professor of dermatology (1802) in Europe at the University of Pisa, Italy.⁹ F. Hebra was the founder of the Vienna School, the first and the most important school of dermatology within the German-speaking area in Europe. By categorizing skin diseases on the basis of the pathological anatomy of the skin, he can be regarded as the founder of modern dermatology. In 1849, Hebra was one of the first professors of exclusively skin diseases and the only professor in Vienna (Vienna Allgemeines Krankenhaus) to be appointed for life.⁹ He published the famous “Atlas der Hautkrankheiten” [German] (“Atlas of skin diseases”), a huge undertaking and a masterpiece of Viennese medical illustration.¹³ M. Kaposi was Hebra’s son-in-law and also his pupil and successor. In 1836, H.D. Bulkley (1804-1872) established the first institution in New York in the United States of America for the treatment of cutaneous diseases. L.A.

Duhring (1845-1913) was a famous professor of dermatology at the University of Pennsylvania for 40 years.⁹ Towards the end of the 19th century, skin diseases, especially syphilis and tuberculosis formed a substantial part of the general physician's practice.⁵ Important names in dermatology in the later 19th and early 20th century are Besnier, Sabourad and Darier.⁹ P.G. Unna (1850-1929) gave the histopathology of the skin diseases a central position, which also resulted in adequate treatment options in several dermatoses.¹⁴ In 1895, J. Jadassohn described contact allergy to mercury and he can be considered as the "father" of the concept of contact dermatitis.¹⁵

In The Netherlands, the skin and the venereal diseases were treated by surgeons and quacks until the 19th century.⁵ In about 1800, there was a rearrangement in the science of the skin which resulted in dermatology as a separate specialty in medicine.³ In 1790, R. Arends, a surgeon in Dordrecht, The Netherlands, translated the "Doctrina de morbis cutaneis" ("Treatise on diseases of the skin") by Plenck in Dutch "Leerstuk wegens de Huidziekten".¹⁶ Dermatology was historically a part of surgery and many skin diseases were previously described in surgical textbooks.³ However, because of the overlap between internal diseases and dermatoses, dermatology was attached to the internal medicine.³ In about 1900, dermatology consisted partly of urology probably because of the venereal diseases especially syphilis.⁵ In 1896, the Dutch Society of Dermatology was founded.⁵ The first Dutch textbook of dermatology was written in 1897 by S. Mendes da Costa and A.N. van Praag.¹⁷ Treatment of several skin diseases such as lichen planus, psoriasis, chronic dermatitis, lupus vulgaris at that time consisted of arsenic in pills or in liquor Fowleri because it would positively influence the metabolism.⁵ The first professor in dermatology was J.L.C. (Chanfleury) van IJsselsteijn (1819-1905) in Amsterdam in 1867. Other important names in the history of dermatology in The Netherlands were D. van Haren Noman, S. Mendes da Costa and S.B. Selhorst.⁵

Several aspects of the oral cavity

The oral cavity

The first part of the digestive process commences in the oral cavity with the ingestion, fragmentation and moistening of food. Moreover, the oral cavity is involved in speech, facial expression, sensory perception and breathing. The major structures of the oral cavity are the lips, the teeth, the tongue and the oral mucosa with the associated salivary glands. The entire oral cavity is lined by a protective mucous membrane, the oral mucosa, which has numerous sensory receptors. Saliva plays a considerable role in the digestion through the action of enzymes, such as amylase and maltase.¹⁸

The structure of the oral mucosa

The mucosa consists of an epithelium and a lamina propria. The epithelium is of the stratified squamous type, which tends to keratinize in the areas of great friction. The oral epithelium is supported by dense connective tissue, the lamina propria. The epithelium consists of a functional compartment which is the site of cell division with the basal and the parabasal cells (progenitor cells), a maturation compartment with spinous or granular cells where the cells become more differentiated and superficial cornified compartment with areas of either orthokeratotic or parakeratotic keratinization and non-keratinized regions in which granular cells are absent and the surface cells are flattened, such as the buccal and the floor of the mouth mucosae. The lamina propria is connected with the underlying muscle by loose submucosal connective tissue in highly mobile areas in the oral cavity. In contrast, in areas where the oral mucosa overlies bone, such as the hard palate and tooth-bearing ridges, the lamina propria is tightly bound to the periosteum by a relatively thin, dense fibrous submucosa. Throughout the oral mucosa, numerous small accessory salivary glands of both serous and mucous types are distributed in the submucosa.^{1,18-21}

The mucosa is divided into masticatory, lining and specialized types. The masticatory mucosa (hard palate, gingiva) is adapted to the forces of pressure and friction and is keratinized with numerous tall rete ridges and connective tissue papillae and little submucosa. The lining mucosa (buccal, labial and alveolar mucosa, floor of the mouth mucosa, ventral surface of the tongue, soft palate and the lips) is non-keratinized with broad rete ridges, connective tissue papillae and abundant elastic fibres in the lamina propria. Specialized mucosa on the dorsum of the tongue, adapted for taste and mastication is keratinized with numerous rete ridges and connective tissue papillae, abundant elastic and collagen fibres in the lamina propria and no submucosa.

The various papillae on the dorsum of the tongue are the filiform, the fungiform, the circumvallate and the foliate papillae. The dentogingival junction represents a unique anatomical feature concerned with the attachment of the gingival mucosa (gum) to the tooth. Non-keratinized gingival epithelium forms a cuff surrounding the tooth, and its lowest point on the tooth adheres to the enamel or the cement. This “junctional” epithelium is unique because it is bonded to both its tooth and lamina propria aspects by basement membranes. The lingual tonsils are round or oval prominences with intervening crypts lined by non-keratinized epithelium. The external surface of the lip is covered by hairy skin which passes through a transition zone to merge with the oral mucosa of the inner surface. The transition zone constitutes the free vermilion border of the lip and derives its color from the rich vascular dermis, which here only has a thin, slightly keratinized epidermal covering. The vermilion zone contains no hair or sweat glands. Moreover, the free border has a rich sensory innervation.^{1,18-21}

Immunity of the oral cavity

Movement of the soft tissues during speech and swallowing, and salivation ensures that much of the foreign material is swallowed. This prevents an accumulation of oral debris and subsequent infection, irritants and possible sensitizers. Saliva also aggregates bacteria and deters their attachment to surfaces. Salivary lysozyme, thiocyanate, peroxides and various mucins and other components are inhibitory to various microbial agents. Salivary tissue derives its B-cells from the gastrointestinal-associated lymphoid tissue (GALT) system. Salivary acinar cells produce a secretory component (transport piece) needed for transport of IgA into the saliva and its stability in the presence of salivary or gastric proteolytic enzymes. The exact contribution made by salivary IgA antibodies in the oral defence is difficult to assess. However, patients with IgA deficiency suffer from various oral infections. Neutrophils and other leucocytes are also essential in oral health. Neutropenia and/or leucopenia predisposes to severe gingivitis, oral ulceration and infections. The lingual tonsils are a part of “Waldeyer’s oropharyngeal ring” of lymphoid tissue.^{1,20}

The dentition

The subject of the dentition is very well known by the dentist and the oral and maxillofacial surgeon. Unfortunately, it may often be less known by other medical specialists. Each tooth may roughly be divided into two segments, the crown and the root. The crown is that portion, which projects into the oral cavity and is protected by a layer of highly mineralized enamel. The bulk of the tooth consists of dentine, a mineralized tissue with a similar chemical composition to the bone. The dentine has a central pulp cavity containing the dental pulp which consists of specialized connective tissue containing many sensory nerve fibres. The root is embedded in a bony ridge in the jaw called the alveolar ridge. The tooth socket is known as the alveolus. The root of the tooth is invested by a thin layer of cementum which is connected to the bone of the socket by a thin, fibrous layer called the periodontal ligament or periodontal membrane. The potential space between the gingival cuff and the enamel is called the gingival crevice. All of the tissues which surround the tooth are collectively known as the peridontium.^{18,19}

There are 10 deciduous (primary or milk) teeth (4 incisors, 2 canines and 4 molars) in each jaw. All elements are fully emerged by the age of about 3 years. The secondary or permanent teeth begin to emerge about the age of 6-7 years. However, some milk teeth may still be present at the age of 12-13 years. The full permanent dentition has generally emerged by the age of 12-14 years and finally consists of 16 teeth in each jaw (4 incisors, 2 canines, 4 premolars and 6 molars). However, the last molars (third or wisdom teeth), if present, often emerge later or may be impacted and never appear in the oral cavity.¹

The nomenclature of the permanent teeth given to the right upper quadrant is number 1 (in primary teeth number 5), the left upper quadrant is number 2 (in primary teeth number 6), the left lower quadrant is number 3 (in primary teeth number 7) and the right lower quadrant is number 4 (in primary teeth number 8). In addition to these numbers, a second number follows depending on the specific place of the tooth starting from the median line. Thus, the permanent canine in the right upper quadrant is designated as 13 (pronounced as one-three) and the primary last molar in left lower quadrant is designated as 75 (pronounced as seven-five).

The outline for the primary teeth is as follows:

Right	55 54 53 52 51	61 62 63 64 65	Left
	85 84 83 82 81	71 72 73 74 75	

The outline for the secondary teeth is as follows:

Right	18 17 16 15 14 13 12 11	21 22 23 24 25 26 27 28	Left
	48 47 46 45 44 43 42 41	31 32 33 34 35 36 37 38	

The terminology of the anatomical positions of the teeth differ from the medical terminology elsewhere in the human body. The sides of the teeth located respectively towards the cheeks are the “buccal” sides and towards the lips are the “labial” sides. The sides of the teeth in the maxilla located towards the palate are the “palatal” sides and the sides of the teeth in the mandibula located towards the tongue are the “lingual” sides. The sides of mastication of the (pre)molars are the “occlusal” sides and of the incisors the “incisal” edges. The sides between the teeth are the “approximal” sides. These are designated as “mesial” if the side is located towards the median line and as “distal” if the side is located towards the lateral part of the oral cavity.^{1,22}

History of oral lichen planus

Erasmus Wilson (1809-1884) was a leading figure in the British dermatology and his most important text “A practical and theoretical treatise on the diagnosis, pathology and treatment of the skin arranged according to a natural system of classification, and preceded by an outline of the anatomy and the physiology of the skin” in 1842 was regarded as the standard work in England and a landmark of the English School of Dermatology.^{9,23}

Nonetheless, it did not include any illustration of “lichen planus” (LP) (or Wilson’s disease), which he was the first to name and describe in 1869.²⁴ In a study of 50 cases of LP, he reported that 3 patients also had involvement of the oral

mucosa. The clinical descriptions of the three cases of oral lichen planus (OLP) were brief and he attributed the disease to summer heat.²⁴ Wilson considered it to be the same disease “lichen ruber” described by F. (von) Hebra in 1860. However, Hebra introduced the disease “lichen ruber acuminatus” which later appeared to be “pityriasis rubra pilaris”.¹³ Because Wilson thought that there was an association between “his” LP and Hebra’s “lichen ruber acuminatus” the synonyms “lichen planus”, “lichen ruber” and “lichen ruber planus” were introduced and still exist today.²⁵ In 1953, R. Degos reported that there was a confusion in the nomenclature of LP because of the historical terminology.²⁶ In 1892, the first variant of LP “lichen ruber pemphigoides” was reported by M. Kaposi.²⁷ In 1895, L.F. Wickham noted the punctations and striae atop the lesions of LP that currently bear his name.²⁸ In 1909, J. Darier defined the histopathological characteristics of the skin lesions of LP and W. Dubreuilh did the same for the oral lesions of LP in 1906.^{29,30} In 1910, H. Hallopeau reported a case of OLP with malignant degeneration.³¹ In 1953, H. Gougerot and A. Civatte described the presence of colloid bodies (Civatte’s bodies) in microscopical examination of LP.³² Civatte’s bodies are degenerated epidermal basal cells.^{33,34}

Nomenclature in oral lichen planus

The term “lichen” is probably derived from the Greek word “leichen (λεϊχην)”, which means “treemoss”. The word “planus” comes from “planum” [Latin] which means “smooth, level and even”. The word “oral” originates from “os, oris” [Latin] which means “mouth”. The word “ruber” comes from “ruber,-bra,-brum” [Latin] which means “red”. The term “cutaneous” comes from “cutis,-is” [Latin] which means “skin”. The word “mucosa” comes from “mucus” [Latin] which means “slime or mucus”.

Dermatology comes from the Greek words “derma (δερμα)” which means “skin” and “logos (λογος)” which is translated as “study”.^{35,36}

General introduction on oral lichen planus

The clinical spectrum of lichen planus (LP) is broad and may involve the skin surface, the mucous membranes, the hair and the nails.^{33,34} Oral lichen planus (OLP) may affect up to 0.5-2% of the population and is more common than cutaneous lichen planus (CLP).^{22,37} Oral lichen planus appears to affect women preferentially.^{34,38} The oral mucosa may be involved alone or in combination with lesions on the skin or other mucosa.^{39,41} The diagnosis of OLP is based on a combination of characteristic clinical findings, history and histopathological examination.^{33,34} Oral lichen planus is generally a very persistent disorder

despite several kinds of treatment.^{34,40} The exact cause of OLP is unknown, but an immune-mediated (T-cell dependant) pathogenesis is proposed. Current concepts on the pathogenesis of OLP include immunological, environmental and genetic factors.^{33,34,37}

Cutaneous lichen planus is a benign, self-limiting inflammatory dermatosis, which in its classical presentation is characterized by pruritic violaceous papules most commonly on the extremities of middle-aged adults. However, there are numerous clinical variants of CLP with other clinical features than the classical form.^{33,41}

The aim of the thesis

The aim of the studies described in this thesis was to review the literature on oral lichen planus (Chapter 2), to give an update on gold allergy (Chapter 4), to give clinical guidelines on the management of oral lichen planus (Chapter 9) and to attempt to clarify several persistent controversies in oral lichen planus. Answers to the following questions were sought whereby various approaches were persued.

- 1 Is it possible to identify specific subgroups of patients with oral lichen planus depending on the differences in the relationship between the oral lesions and dental amalgam fillings? Are there contact allergies in patients with oral lichen planus and amalgam fillings? What are the results of partial or complete replacements of amalgam following a positive patch test reaction to ammoniated mercury, metallic mercury or amalgam? (Chapter 3)
- 2 What is the frequency of sensitization to gold in patients with symptoms of persistent oral mucosal or cutaneous lesions that were possibly related to allergy to constituents of dental gold alloys or gold jewelry? (Chapter 4)
- 3 Is oral lichen planus a premalignant disorder? Is there an intrinsic malignant potential of oral lichen planus or are there contributing external risk factors, which may also be responsible for the transformation of oral lichen planus into an oral squamous cell carcinoma? (Chapter 5)
- 4 Is there a relationship between oral lichen planus and hepatitis C virus infection in The Netherlands? Is screening for anti-hepatitis C virus antibodies and liver enzymes necessary in our patients in The Netherlands? Are there any reports in the literature on the association of oral lichen planus and hepatitis C virus infection? (Chapter 6)
- 5 What is the incidence of oral lichen planus in childhood encountered in dermatological practice? What are the clinical characteristics of these patients? Are there any differences between oral lichen planus in childhood and oral lichen planus in adulthood? Are there any reports on oral lichen planus in childhood in the literature? (Chapter 7)

- 6 Is treatment with topical tacrolimus ointment more effective than treatment with topical triamcinolone acetonide ointment in patients with symptomatic oral lichen planus? Are there differences in the remission periods between the two treatments? (Chapter 8)

References

1. Scully C. The oral cavity. In: Rook/Wilkinson/Ebling. Textbook of Dermatology. Champion RH, Burton JL, Burns DA, Breathnach SM. 6th edn. Vol 4. Oxford: Blackwell Science Ltd 1998; 3074-147.
2. van der Waal RIF. Thesis. Oral manifestations of systemic diseases and malignancies located elsewhere in the body. University of Amsterdam. Ponsen & Looijen BV, Wageningen 2003.
3. Burton JL, Champion RH. Introduction and historical bibliography. In: Rook/Wilkinson/Ebling. Textbook of Dermatology. Champion RH, Burton JL, Burns DA, Breathnach SM. 6th edn. Vol 1. Oxford: Blackwell Science Ltd 1998; 1-15.
4. Lindeboom GA. Inleiding tot de geschiedenis der geneeskunde. [Dutch]. Introduction on the history of medicine. 6th edn. Rodopi BV, Amsterdam 1985.
5. Mesander B. Van Praedermatoloog tot Dermatoloog. De historie van het ontstaan van het specialisme dermatologie in Nederland. [Dutch]. From praedermatologist to dermatologist. The history of the specialty of dermatology in The Netherlands. Belvédère/Medidact. Overveen/Alphen aan de Rijn 2001.
6. Crijns M, van Leeuwen R. Huidziekten in de beeldende kunst. [Dutch]. Skin diseases in the visual arts. Edn 1. Glaxo BV, Nieuwegein 1992.
7. Daeter B. Albert Schweitzer. Een pionier in het oerwoud. [Dutch]. Albert Schweitzer. A pioneer in the jungle. Tirion Uitgevers BV, Baarn 2002.
8. Mercuriale G. De morbis cutaneis et omnibus corporis humani excrementis tractatus locupletissimi... Ex ore Hieronymi Mercurialis...excepti, atque in libros quinque digesti, opera Pauli Aicardii, Venetiis [Latin]; Apud Paulum & Antonium Meietos; 1572.
9. Potter BS. Bibliographic landmarks in the history of dermatology. J Am Acad Dermatol 2003; 48(6): 919-32.
10. Turner D. De morbis cutaneis. A treatise of diseases incident to the skin. London: Bonwicke R, Freeman W, Goodwin T, Walthoe J, Wotton M, Manship S, Nicholson J, Parker R, Tooke B, and Smith R; 1714.
11. Plenck JJ. Doctrina de morbis cutaneis: qua hi morbi in suas classes, genera & species rediguntur. [Latin]. Viennae: Apud Rudolphum Graeffer; 1776.
12. Alibert JL. Description des maladies de la peau observées a l'Hôpital Saint-Louis, et exposition des meilleures méthodes suivies pour leur traitement. [French]. Paris: Barrois l'ainé et fils; 1806.
13. Hebra F, Elfinger A, [Heitzmann C]. Atlas der Hautkrankheiten. [German]. Atlas of skin diseases. Wien: Kaiserliche Akademie der Wissenschaften; 1856-76.
14. Unna PG. Die Histopathologie der Hautkrankheiten. [German]. Histopathology of skin diseases. In: Orth J, editor. Lehrbuch der speciellen pathologischen Anatomie. [German]. Textbook of Histopathology. Vol 8. Berlin: August Hirschwald; 1894.
15. Jadassohn J. Zur Kenntnis der Medikamentösen Dermatosen. [German]. Review of drug-induced skin disorders. Verh Dtsch Derm Gesellschaft v Kongress 1895; 103.
16. Arends R. Leerstuk wegens de huidziekten, waar in deze Gebreken onder hunne Orden, Geslagten en Soorten gebracht worden van Josef Jacob Plenck. [Dutch]. Textbook of skin diseases. Nicolaas de Rot, Johannes Crevel; 1790.

17. Mendes da Costa S, van Praag AN. Leerboek Dermatologie. [Dutch]. Textbook of Dermatology. De Erven F. Bohn. Haarlem; 1897, 1899, 1901.
18. Wheater PR, Burkitt HG, Daniels VG. Functional histology. A text and colour atlas. Churchill Livingstone. Edinburgh London New York 1979; 171-81.
19. Junqueira LC, Carneiro J. Functionele histologie. [Dutch]. Basic Histology. Edn 3. Bunge, Utrecht 1984: 360-9.
20. Prime SS. Development, structure and function of oral mucosa. In: Scully C, ed. The mouth in health and disease. Heinemann Medical, Oxford 1989: 124-44.
21. Meyer J, Squier CA, Gerson SJ. The structure and function of oral mucosa. Pergamon Press, Oxford 1984.
22. van der Waal I, van der Kwast WAM, van der Wal JE. Pathologie van de mondholte. [Dutch]. Pathology of the oral cavity. Edn 3. Bohn Stafleu Van Loghum, Houten/Diegem 1996.
23. Wilson E. A practical and theoretical treatise on the diagnosis, pathology and treatment of diseases of the skin: arranged according to a natural system of classification, and preceded by an outline of the anatomy and physiology of the skin. John Churchill, London 1842.
24. Wilson E. On lichen planus. J Cutan Med Dis Skin 1869; 3: 117-32.
25. Eerdekens M, Matthieu L, Jacob W et al. Lichen ruber planus. [Dutch]. Lichen planus. Cilag. Derma Forum, Kaatsheuvel/Herentals 1989, 13 H.
26. Degos R. Dermatologie. Edn 1. Paris, Editions médicales Flammarion. [French]. 1953; 1: 270.
27. Kaposi M. Lichen ruber pemphigoides. Arch Dermatol Syph (Berl) 1892; 24: 343-6.
28. Wickham LF. Sur un signe pathognomique du lichen de Wilson (lichen plan). Stries et ponctuations grisâtres. [French]. Ann Derm Syph 1895; 6: 517-26.
29. Darier J. Précis de dermatologie. [French]. Masson, Paris 1909: 118-20.
30. Dubreuilh W. Histologie du lichen plan des muqueuses. [French]. Ann Derm Syph 1906; 7: 123-9.
31. Hallopeau H. Sur un cas de lichen de Wilson gingival avec neoplasie voisine dans la region maxillaire. [French]. Bull Soc Fr Derm Syph 1910; 17: 33.
32. Gougerot H, Civatte A. Critères cliniques et histologiques des lichen plans cutanés et muqueux: délimitations. [French]. Ann Derm Syph 1953; 80: 5-29.
33. Boyd AS, Neldner KH. Lichen planus. J Am Acad Dermatol 1991; 25: 593-619.
34. Scully C, Beyli M, Ferreira MC et al. Update on oral lichen planus: etiopathogenesis and management. Crit Rev Oral Biol Med 1998; 9: 86-122.
35. Muller F, Thiel JH. Grieks-Nederlands woordenboek. [Dutch]. Greek-Dutch dictionary. Wolters Noordhoff, Groningen, The Netherlands, 11th edn, 1969.
36. Muller F, Renkema EH. Latijn-Nederlands woordenboek. [Dutch]. Latin-Dutch dictionary. Wolters Noordhoff, Groningen, The Netherlands, 11th edn, 1967.
37. Vincent SD, Fotos PG, Baker KA et al. Oral lichen planus: the clinical, historical and therapeutic features of 100 cases. Oral Surg Oral Med Oral Pathol 1990; 70: 165-71.
38. Lozada-Nur F, Miranda C. Oral lichen planus: epidemiology, clinical characteristics, and associated diseases. Semin Cutan Med Surg 1997; 16(4): 273-7.
39. Eisen D. The evaluation of cutaneous, genital, scalp, nail, esophageal, and ocular involvement in patients with oral lichen planus. Oral Surg Oral Med Oral Pathol Oral Radiol Endod 1999; 88(4): 431-6.
40. Setterfield JF, Black MM, Challacombe SJ. The management of oral lichen planus. Clin Exp Dermatol 2000; 25: 176-82.
41. Black MM. Lichen planus and lichenoid disorders. In: Rook/Wilkinson/Ebling. Textbook of Dermatology. Champion RH, Burton JL, Burns DA, Breatnach SM. 6th edn. Vol 4. Oxford: Blackwell Science Ltd. 1998; 1899-926.

CHAPTER 2

ORAL LICHEN PLANUS: A REVIEW OF THE LITERATURE

Introduction

The various terms for oral lichen planus (OLP) in the literature are oral lichenoid lesions, oral lichenoid reactions, (lichenoid) contact lesions, lichenoid contact stomatitis, lichen planus-like lesions, and lichen planus mucosae oris. These terms are used interchangeably, which is confusing. Generally, the term “oral lichen planus” is used here because there is no reliable difference in clinical practice based on symptomatology, clinical examination and histopathology.¹⁻⁵

Epidemiology

Oral lichen planus is a rather common benign inflammatory disease. The prevalence of OLP is about 0.5 to 2% in the general population, but there is a variation of 0.1 to 4% in the literature, probably depending on the selected population.⁶⁻⁹ Generally, it is a disease of the middle-aged and the elderly and the female-to-male ratio is about 2: 1. The peak age in OLP is between 50 and 65 years.⁶⁻¹⁰ The disease is rare in childhood.^{10,11} There is an increased incidence in India and this is probably correlated with betel nut chewing.¹² In a demographic study by Axell and Rundquist in 20,333 Swedish individuals aged 15 years and older, OLP was found in 1.9% of these individuals (1.6% in men and 2.2% in women). The highest prevalences were noted in the age groups 65-74 years and 55-64 years.¹³ The prevalence of OLP may show a significant variation between different studies, because a significant proportion of the patients is asymptomatic and does not seek medical help. It has been reported that one-third of the patients with OLP have no symptoms, whereas two-thirds of the patients have one or more symptoms.^{6,10}

The clinical characteristics of the variants of oral lichen planus

In 1978, the WHO formulated a clinical definition of OLP: “Lichen planus commonly affects the oral mucosa, and lesions may occur in the mouth in the absence of skin lesions. Mucosal lesions are usually multiple and often have a symmetrical distribution. They commonly take the form of minute white papules which gradually enlarge and coalesce to form either a reticular, annular, or plaque pattern. A characteristic feature is the presence of slender white lines (Wickham’s striae) radiating from the papules. In the reticular form, there is a lacelike network of slightly raised gray-white lines, often interspersed with papules or rings. The plaque form may be difficult to distinguish from leukoplakia, but in lichen planus there is usually no change in the flexibility of the

affected mucosa. In some patients the lesions are atrophic, with or without erosions. Oral lesions of lichen planus may also include bullae, but these are rare".¹⁴

Oral lichen planus can be categorized into 6 different clinical subtypes namely **reticular**, **papular**, **plaque**, **erosive**, **ulcerative** (or **bullous** or vesicular), and **atrophic** (or **erythematous**) (Table I).^{6,15,16} A division of OLP into 3 subtypes is also possible: **reticular**, including white lines, papules and plaques (**hyperkeratotic** lesions); **erosive**, including ulcerations and bullae; and **atrophic** or **erythematous** (Table I).^{10,17}

The extremely rare pigmented variant of OLP is not categorized as a separate form in these clinical variants of OLP. The pigmented variant is characterized by pigmented papules arranged in a reticular pattern interspersed with whitish lesions. This form is due to melanin overproduction during the acute phase of the disease.²¹

The reticular form with Wickham's striae, the papular form and the plaque form are usually asymptomatic and show hyperkeratotic (white) lesions (Figure 1). The atrophic or erythematous (red) variant and the erosive or ulcerative (or bullous) (yellow) variant generally have persistent symptoms (Figures 2 and 3). The symptoms are pain (the single most frequent complaint) or stinging in the oral cavity aggravated during eating and drinking, and difficulties with the speech and overall functioning. These symptoms can be extremely distressing and even disabling, and may affect the quality of life. Sometimes, there is a burning sensation with a dry mouth or bleeding while brushing the teeth.^{6,10,17-19} A metallic taste in the mouth has also been reported.²⁰ Only a few patients with the reticular variant complain of a little oral discomfort or soreness, but reticular lesions on the tongue may produce dysgeusia (taste disturbance) (Figure 4).^{10,17}

The different variants of OLP may occur together in one patient or may transform into each other.¹⁵ The erosive and the atrophic variants often also have minor signs of the hyperkeratotic (reticular) variant in the surrounding mucosa (Figures 2 and 3). This may be an additional clue in the clinical diagnosis of OLP.^{10,17} The lesions are found (in diminishing frequency) on the buccal mucosa (typically in the posterior part), the lateral margins of the tongue, the gingiva, the labial mucosa and the vermillion of the lower lip (Figures 5 and 6). The upper lip, the palate and the floor of mouth are not commonly involved. Symmetrical or bilateral involvement of the oral mucosa is very common (more than 90% of the cases) and this may also be helpful in the clinical diagnosis of OLP.^{6,10,17,21,22} Generally, the reticular variant is by far the most common form of OLP and it may be regarded as the classical variant of OLP (Figure 1).^{18,23}

In the study by Axell and Rundquist, 77.3% of the patients had the reticular form of OLP.¹³ However, in the hyperkeratotic variant (in sharp contrast with the atrophic and erosive variant), the patients often do not consult a physician

because of the lack of symptoms and the disease is often discovered fortuitously during a regular dental visit.¹⁷ Therefore, the percentages of the specific types of OLP may show significant variations in different studies, particularly biased by symptomatology. The erosive variant of OLP was found to be the most common variant in some other studies.^{8,17,19} The atrophic form of OLP may also be the result of the erosive form.²¹ The initial presence of papular lesions in OLP was associated with an age younger than 60 years and atrophic lesions in OLP with an age older than 60 years.¹⁵ The bullous (or vesicular) variant is very rarely seen because vesicles or bullae easily rupture in the oral cavity, leaving an ulcerative (or erosive) lesion.¹⁸ The bullae usually arise on a background of hyperkeratotic lesions.²¹ In large cohort studies in patients with OLP, atrophic lesions were present in 5 to 44% of the patients, whereas ulcerative or erosive lesions were present in 9 to 46% of the patients.^{13,15,17} As already mentioned, the clinical manifestations of OLP can significantly change in one patient. However, the plaque variant seems to be very persistent. In a study by Thorn in 611 patients with a mean follow-up of 7.5 years, 44% of the patients had atrophic lesions at the initial visit, but in 23% of the patients these lesions had disappeared by the time of the last consultation, but another 12% of the patients had developed “new” atrophic lesions. Similar results were reported in patients with ulcerative OLP.¹⁵

When OLP is confined to the gingiva (approximately 10 % of the cases), the clinical appearance may show erythematous or erosive lesions and this is called a “desquamative gingivitis”. It shares many clinical features with the bullous auto-immune diseases and lupus erythematosus. Therefore, it is difficult to establish a good clinical diagnosis in these cases. Sometimes the gingiva shows keratotic lesions and in these cases it is easier to establish a clinical diagnosis of OLP.^{6,7,10,17,21}

Approximately 15 to 35% of the patients with OLP also have concomitant cutaneous involvement.^{10,24,25} Conversely, about 30 to 50% of the patients with the classical variant of CLP have oral involvement.^{6,10,26} The cutaneous

Table I. Clinical variants of oral lichen planus (OLP).

Six subtypes	Color	Symptoms	Three subtypes
Reticular	White	(mostly) none	Reticular
Papular	„	„	(Hyperkeratotic)
Plaque	„	„	
Erosive	Yellow	pain and/or burning	Erosive
Ulcerative (or Bullous)	„	„	
Atrophic (or Erythematous)	Red	„	Atrophic (or Erythematous)

and oral involvement does not necessarily occur at the same time.²⁴ In most instances, cutaneous lesions typically develop within several months after the appearance of the oral lesions. The severity of OLP usually does not correlate with the extent of CLP.^{10,24} However, in a number of Scandinavian studies, it was reported that oral involvement was eight times more common than cutaneous involvement.^{27,28} These percentages show a large variation in the literature also depending on the medical specialty. It appears to be easier for a dermatologist to look into the mouth of a patient than for a dentist to look at the skin of a patient with LP.^{6,17,24}

Etiology

The exact cause of OLP remains unknown, but an immune-mediated (T-cell dependant) pathogenesis has been proposed.^{29,30} Abnormal metabolism, impaired production of tonofilaments, and defects in the assembly of desmosomes have also been implicated as etiological factors.³¹ Numerous studies support the hypothesis that OLP is a complex immunological disease mediated by cytotoxic T-cells directed against basal keratinocytes.^{6,32,33} In the etiology, there is an interplay of host factors, environmental factors and lifestyle.⁶ Nevertheless, this is the rule in many diseases. Cell-mediated immunity appears to play a major role in OLP.³⁰ Endogenous and exogenous factors are probably necessary for developing of OLP in a person with a genetic predisposition.^{34,35} Oral lichen planus is considered to be idiopathic in most cases.^{1,10,23,25}

Genetic background

The Human Leucocyte system A (HLA) is a group of cellular proteins on the surface of the cell-membrane of all nucleated cells and thrombocytes. These histocompatibility antigens are genetically determined by genes on 4 associated loci: HLA-A, HLA-B, HLA-C and HLA-D. These 4 loci are located on chromosome 6.³⁹ Generally, the associations between HLA-antigens and OLP are inconsistent in the literature.^{6,36-38} Lowe et al evaluated 57 patients and 300 control subjects. A significantly higher prevalence of HLA-A3 was found (54% versus 29.7%) and more than twice as many affected patients (19.3% versus 9%) carried HLA-A5. Additional HLA-loci were not evaluated.³⁷ Simon et al reported elevated prevalence of HLA-B16, HLA-B8 and HLA-Bw35. HLA-Bw35 was more common in patients with only cutaneous lesions, whereas HLA-B8 was more common in patients with oral lesions.⁴⁰ Powell et al studied 72 patients with LP. Eighty percent of the patients with generalized disease, 56% of the patients with a lichenoid drug eruption, 54% of those with localized lesions, 31% of the patients with OLP, and 25% of the control group were positive for HLA-DR1 (HLA-class II-antigen). HLA-DQw1 was reported in

62% of the control sera and in 83% of the affected patients.⁴¹ Porter et al investigated the prevalence of HLA-A, HLA-B, HLA-C, HLA-DR, and HLA-DQ1 in a group of 40 British patients with OLP compared with healthy control individuals. In the group of patients with OLP, an increase in the frequency of HLA-Bw57 and a decrease in the frequency of HLA-DQ1 were found. The authors suggested that OLP may represent a heterogenous group of diseases and that HLA-Bw57 may predispose a person to OLP, whereas HLA-DQ1 may be associated with resistance to it.³⁶ Lin et al found an increase in HLA-DR9 in Chinese patients with OLP.³⁸

The familial LP also indicated that there is a substantial contribution of a specific genetic predisposition in the development of LP. A possible explanation for familial LP would be similar HLA-alleles.²² However, in familial LP conflicting results on HLA-alleles were reported.⁴²⁻⁴⁴

Emotional stress and lifestyle

Stress was implicated as an important etiological factor in the pathogenesis of OLP.^{45,46} Stress was identified as the most frequent cause of exacerbations of OLP.^{6,47} However, the chronic discomfort that can afflict patients with symptomatic OLP may be itself a stress factor and may perhaps partially explain the cases in which this association was documented. Furthermore, patients with OLP may be concerned about the possibility of malignancy, the (not justified) contagious nature of the lesions and the lack of available educational material.^{6,17} Education of patients with OLP on their disease can alleviate much of the anxiety.¹⁷ Altman and Perry reported in a study in 197 patients with LP that only 10% of the affected patients could recall a stressful situation at the onset of their disease, whereas 60% of the patients believed that chronic stress aggravated its course.⁴⁶ Most studies on LP accentuate the association between oral lesions and stress.²² Patients with OLP frequently report worsening of the disease during periods of stress and others noticed onset or exacerbation of OLP with fatigue.⁴⁵ Nervous, highly stressed individuals suffer from OLP rather frequently.⁴⁸ Lowental and Pisanti reported an association between emotional stress and erosive OLP, but not with the reticular variant of OLP.⁴⁹ However, Allen et al reported that there was no significant association between stress and OLP.⁵⁰ In a study by Rojo-Moreno et al there were 100 patients with OLP and 50 control subjects. In a psychometric evaluation, the patients with OLP (particularly with symptomatic OLP) were found to have a higher vulnerability for psychic disorders, higher anxiety and increased depression scores than those in the control group. However, it could not be concluded that both the observed psychologic alterations acted as a direct etiological factor of OLP and these alterations were a consequence of OLP.⁵¹

Ostman et al reported different lifestyle patterns in patients with OLP compared with an age- and sex-matched control group in Sweden. In the patients with

OLP, the frequency of physical activity was significantly higher than in the patients in the control group. In the group with OLP, more individuals were divorced or whose spouse had died. Furthermore, the daily intake of carbohydrates, fibers and iron was statistically significant higher in patients with OLP.⁵² Unfortunately, the exact relationship with the pathogenesis of OLP in those patients could not be established.

Tobacco

Generally, there is no increased prevalence of cigarette smoking in patients with OLP.⁵³ Murti et al examined 722 Indian patients with OLP and found a strong association between OLP and the use of tobacco.⁵⁴ Betel nut chewing is also more prevalent in Indian patients with OLP.¹² In a prospective study by Silverman et al in San Francisco in the U.S.A., there was no correlation between the onset of OLP and smoking.⁸ However, the plaque form of OLP is more often encountered in patients who used tobacco.¹⁵

Exposure to tobacco should be discouraged strongly in patients with OLP, because it is a well-known risk factor for oral cancer, and there is also a possible synergistic premalignant effect in patients with OLP.^{55,56,389}

Trauma

The Koebner's phenomenon or isomorphic response is a common feature in LP, and develops in areas subjected to some type of trauma in the absence of previous clinically visible lesions.^{26,57} In a study by Eisen in 723 patients in 2002, mechanical traumata, dental interventions, heat and irritants from tobacco products, friction from sharp cusps, rough dental restorations, poorly fitting dental prostheses and oral habits as lip chewing and cheek biting (*morsicatio buccarum*) were frequently found to be exacerbating factors that resulted in (symptomatic) OLP. When these factors were minimized or eliminated, the oral lesions either reverted to the less severe forms of the disease or sometimes resolved completely. Dental plaque and calculus are particularly associated with a significantly higher incidence of gingival OLP lesions.¹⁷

Micro-organisms and infections

Dental plaque consists of micro-organisms (more than 70%), mucines and degenerated epithelial cells, and may frequently produce a (chronic) gingivitis.^{48,58} This chronic infection of the gingiva (possibly also in combination with the Koebner's phenomenon) may aggravate OLP.^{17,59} In long-standing dental plaques, calcifications may occur and produce dental calculus.⁴⁸ Ramon-Fluixa reported in a study in 90 patients with OLP that increased

dental plaque and calculus deposits were associated with a significantly higher incidence of erythematous and erosive gingival lesions.⁵⁹ Oral hygiene in patients with OLP should be optimized by both the patient and the patient's dentist or periodontist to reduce the severity of gingival inflammation and to avoid periodontal surgical interventions that may exacerbate OLP.^{17,57}

Oral lichen planus was suggested to be related to bacteria such as a Gram-negative anaerobic bacillus (Jacob and Helmbold, 1933) and spirochetes (Lehnhoff, 1948), but this has not yet been confirmed.^{60,61} Lichenoid reactions have been seen in syphilis (Lochner and Pomeranz, 1974), chronic bladder infection (Shelley and Shelley, 1989), and intestinal amebiasis (Wahba-Yahav, 1989).⁶²⁻⁶⁴ In the latter two cases the lesions disappeared after systemic treatment with metronidazole.^{63,64}

The involvement of viral agents in OLP has been suggested.⁶⁵ Oral lichen planus was reported in HIV infection.⁶⁶ Human papillomaviruses (HPV) were found in the lesions of OLP, but any causal role remains speculative.^{67,68} Walsh et al suggested that low-grade or persistent infection of epithelial cells with herpes viruses may be a possible etiologic factor in OLP.^{29,69} The possible relationship between OLP and hepatitis C virus infection has been frequently reported.⁷⁰⁻⁷⁵ The possible association between OLP and hepatitis B virus infection has been reported less often.^{76,77} Interestingly, hepatitis B vaccination has also been implicated in the development of OLP.^{78,79}

Generally, there is an increased prevalence of candidal carriage and infection in patients with OLP and candida albicans has been considered as a provocative factor in OLP.⁸⁰⁻⁸² Oral candidosis may also be provoked by endocrinopathies, immune-dysfunction and specific drugs.⁸⁰ Candida was demonstrated in cultures in 37 to 50% of the patients with OLP.^{80,82} Candidal infection has been demonstrated in 0 to 17% of the biopsies of OLP without predilection for a specific variant of OLP.^{83,84} However, candida albicans can be detected in the oral cavity without any symptoms in about 40% of the normal population.^{80,82} The natural barrier of the oral mucosa in OLP is decreased and the treatment of OLP with corticosteroids and other immunomodulators frequently predisposes to candidosis.⁸⁰ Symptoms of OLP may be worsened by candidal overgrowth or by infection.⁸⁰⁻⁸⁴ Furthermore, candida albicans can enzymatically catalyze the formation of N-nitrosobenzylmethylamine, a potential carcinogen.⁸⁴ However, the presence of this yeast and the development of OLP and a higher rate of candida albicans colonization in OLP was not correlated in several other studies.^{8,83} It seems reasonable to start with antifungal treatment to avoid the role of candidosis in (symptomatic) OLP.⁸⁵ It has been reported that antifungal treatment of erosive lesions of OLP from which candida had been isolated by culture often transformed the lesions to reticular form.^{6,80} Unfortunately, we are unable to corroborate this statement from our experience.

Contact allergy

Contact allergens are mostly low molecular weight (less than 500 daltons) substances, which are able to penetrate the oral mucosa. These substances must be presented by antigen-presenting cells, principally Langerhans cells, to T-lymphocytes to induce contact allergy. Antigenicity is also accomplished by the conjugation of these allergens with autologous proteins present in the mucosa. An antigen with a molecular weight of at least 5,000 daltons is required to induce and elicit a contact allergy. The effector cells, which mediate delayed-type allergic reactions are the progeny of these T-lymphocytes.⁸⁶ The pathogenesis of an allergic contact stomatitis shows significant similarities with the pathogenesis of OLP.^{30,87,89} Generally, allergic contact sensitivity affects both the skin and the oral mucosa. In general, allergic contact stomatitis occurs less frequently than allergic contact dermatitis probably because of the following reasons. The epidermis of the skin consists of proteins that combine more readily with low molecular weight substances to form allergens. The period of contact of sensitizers with the oral mucosa is brief (with the exception of dental appliances) because the saliva dilutes and removes the potential allergens or neutralizes chemicals. The extensive vascularization of the mucosa aids in rapid dispersion and absorption of the allergens.⁸⁷ The patch test is a scientific *in vivo* method of investigating contact allergies. A possible role of contact allergy in OLP should be investigated by patch tests, which are generally performed on the upper part of the back conform patch tests in allergic contact dermatitis.⁸⁶⁻⁸⁸ Generally, patch testing is a routine procedure in dermatology.⁹¹ However, properly applied allergens and correctly interpreted patch test reactions with clinical consequences may be more complicated (Figure 16).⁸⁶ Several *in vitro* tests such as the lymphocyte transformation test and the macrophage inhibition test, often parallel clinical contact sensitivity.^{92,93} However, these tests may show a significant variation in results and have been optimized for only a few contact allergens.⁹⁴

Allergy to dental metal restorations and electrogalvanism

Generally, there is no evidence of any association between allergy and dental restorative materials in the majority of the patients with OLP.^{17,95,96} However, contact with or proximity to dental restorations may cause OLP.⁹⁷⁻¹⁰⁰ These reactions are typically induced by a contact allergy, but friction by dental fillings (via the Koebner's phenomenon), toxic reactions to compounds released or generated, and dental plaque should be excluded.^{17,100-103}

The hypothesis is that dental metal restorations in the oral cavity are prone to corrosion and by releasing ions may be responsible for sensitization and allergic reactions (type IV, T-cell dependant). This process may lead to chronic antigenic stimulation with mucosal changes and ultimately to OLP.^{100,104} An

unequal distribution of the metals in dental alloys by a less meticulous manufacture also increases corrosion.¹¹⁶ Another, less favorable, hypothesis is that close contact between dissimilar metals (for example, amalgam and gold) may produce different electrical potentials and lead to electrochemical reactions (= electrogallvanism), corrosion and increased release of metal ions inducing mucosal changes.^{2,105} However, the currents produced by amalgam fillings were considered to be too small (less than a few microamperes) to have any significant corrosive effect.¹¹² A combination of both hypotheses has also been suggested in OLP.^{9,106} Oral lichen planus may be due to an allergy to dental restorations especially amalgam and less frequently to dental gold alloys (Table II).^{97-100,107,108,118} All dental amalgams consist of mercury and added copper, silver, tin and other metals such as zinc.¹⁰⁸ According to the number of metals they contain, amalgams are classified as binary (2), tertiary (3), quaternary (4), quinary (5), and so forth.⁸⁷

Kubicka-Muranyi et al reported the presence of mercury-specific T-cells in sensitized mice.¹⁰⁹ Stejskal et al studied the immune response to mercury by an "optimized" lymphocyte proliferation test (MELISA = memory lymphocyte immunostimulation assay) in vitro and by patch tests in 18 patients with OLP, 20 individuals with amalgam fillings without oral lesions, and 12 individuals without amalgam fillings. The patients with OLP showed a significantly higher lymphocyte reactivity to inorganic mercury compared with the control group(s). Moreover, removal of amalgam fillings in these patients resulted in healing of OLP, thus indicating a causal relationship. They also reported that the immune system of susceptible individuals may be triggered by different mercury compounds and that low-grade chronic exposure to mercury may induce a state of systemic sensitization as verified by mercury-specific lymphocyte reactivity in vitro. They concluded that lymphocyte reactivity to mercury salts in vitro may be used for an objective diagnosis of mercury allergy in man.¹¹⁰

Mercury may be encountered as organic mercury in thimerosal used as an anti-septic and a preservative in topical medications and vaccines. Inorganic mercury is present in dental amalgam restorations and thermometers.¹¹⁹

In dentistry, metal alloys with the exception of pure gold and pure titanium are mostly used in restorations.¹¹⁶

It is important to be aware of other metals such as nickel, cobalt, chromium, cadmium, gallium and beryllium that may be substituted because of the high cost of gold alloys.⁸⁷ There are also several reports on the association between OLP and allergy to other dental metal allergens with positive patch test reactions to cadmium chloride (cadmium)², cobalt chloride (cobalt)^{104,111}, potassium dichromate (chromium)^{1,104}, gold sodium thiosulfate or potassium dicyanoaurate (gold)^{1,2}, palladium chloride (palladium)^{1,2,114}, ammonium tetrachloroplatinate (platinum)¹¹⁴, silver nitrate (silver)^{1,2} and copper sulfate (copper)^{1,2,113}. Scalf et al reported a patient with OLP who had a positive patch test

to iridium (III) chloride hydrate (1% aq) (iridium) and indium (III) sulfate (10% aq) (indium) (Table II).¹ Yiannis et al reported a positive patch test to beryllium sulfate tetrahydrate (1% aq) (beryllium) in 2 patients with OLP (Table II).² However, in both the studies the clinical relevance of the findings was debatable because other allergens could also be relevant in these patients.^{1,2} Mizoguchi et al described a case of linear, facial LP with a “peculiar sensation” in the mouth that was caused by allergy to palladium. Patch tests were positive to both palladium and platinum. Removal of the palladium-containing dental work resulted in total resolution of the symptoms.¹¹⁵

Dental alloys may contain small proportions of nickel, cadmium, beryllium, indium, gallium, platinum, and palladium.^{116,117,123} These constituents may produce local pathogenic effects including stomatitis, gingivitis, parodontitis, and even alveolar bone loss.^{120,122} Local toxic reactions by dental metals occur more frequently in women than in men. Generally, such reactions occur shortly after the placement of the dental metal restorations. A metallic taste is commonly an important symptom of the local toxic reaction.^{116,120} It was also reported that local reactions may be possibly involved in the pathogenesis of the Burning Mouth Syndrome (BMS).^{96,124}

The exact composition of dental metal restorations in the oral cavity of a patient may be unknown.

Screening for dental metal restorations in the oral cavity may be performed by an Orthopantogram (X-ray).

Chemical analysis for establishing the exact composition may be performed after complete removal of the dental metal restoration. The exact composition of the dental metal restorations may also be investigated by analyzing a small sample of the alloy with scanning electronmicroscopy and a subsequent röntgen diffraction spectrum.^{116,124}

It was reported that dental metal restorations, particularly amalgam, were associated with several disorders such as chronic fatigue syndrome, aspecific symptoms in the oral cavity, abnormal psychological signs, and a feeling of decreased general well-being.⁸⁹ Moreover, neurological disorders such as multiple sclerosis and Alzheimer’s disease were reported to be caused by chronic mercury poisoning.¹²¹ The leakage of very small amounts of mercury from

Table II. Allergy to dental metal restorations and OLP.

Metals:			
Mercury (Amalgam)	Gold	Platinum	Indium
Cobalt	Chromium	Silver	Iridium
Cadmium	Palladium	Copper	Beryllium

dental amalgam was detected but intensive investigation showed that amalgam did not cause a significant health risk for the general population. However, volatile free mercury in dental clinics should be monitored to avoid occupational health risks.¹²⁵

Allergy to other allergens

In 2000, Yiannis et al reported in a study in 46 patients with a clinical and histopathological diagnosis of OLP that 6 patients had positive patch tests to flavorings such as vanillin, cinnamic aldehyde, fragrance mix and balsam of Peru. These patients noted a substantial aggravation of their symptoms when exposed to these allergens. Avoidance of these flavoring agents (in specific foods or oral hygiene products (fragrance mix)) resulted in clinical and symptomatic improvement in all 6 patients underlining the clinical relevance. One patient had a positive patch test to acrylic resin monomer (used as an adhesive material) and a moderate improvement was noted after removal of an acrylate dental retainer. Besides these cases, there were several positive reactions to dental metals in other patients. In this study, nearly 40% of the patients with OLP had an exacerbating contact hypersensitivity.² An important aspect in this study was possibly that macular erythema as a result of the patch test was already regarded as positive in contrast with regular patch tests.⁸⁶ A few other studies also reported that a small minority of the patients with OLP reacted to certain foods and to food additives such as cinnamic aldehyde.¹²⁶⁻¹²⁸ Contact allergy in association with OLP to one or more of the acrylic denture materials or composite fillings has also been described.^{2,129}

Hensten-Pettersen reported the introduction of more than 100 similar new brands of resin-based cold-curing materials.¹³⁰ Resin-based unfilled and composite materials, pit and fissure sealants, orthodontic adhesives, glazes, veneers and repair kits for porcelain-fused-to-metal restorations, root canal sealers, and temporary crowns are used in a large segment of the population and may also cause allergic reactions. After cold-curing, it is likely that small amounts of the monomers will be left unpolymerized. Depending on the composition, the polymerization is induced by chemical catalysts, visible, or ultraviolet light sources. The materials are based on different types of monomers such as methacrylate monomers, urethane-based-dimethacrylates, epoxybisphenol resins, and ethylene-amino derivatives.¹³⁰ Moreover, many chemicals such as benzoyl peroxide, hydroquinone, phthalates, tertiary aromatic and aliphatic amines, ultraviolet stabilizers and antioxidants involved in the polymerization process may still be present. Saliva, water and alcohol may leach out any unpolymerized residual material in “cured” orthodontic bonding resins, which may cause allergic reactions. Frequently occurring methacrylates in bonding resins

are 2,2-bis[4-(2-hydroxy-3-methacryloxypropoxy)phenyl]-propane (bis-GMA) and 2-hydroxyethyl methacrylate (2-HEMA). “Bis” stands for the epoxy resin bisphenol A, which reacts with glycidyl methacrylate. The plastic is generally combined with quartz, lithium aluminium silicate, glass, or silicon dioxide to modify the physical properties of the resin. Bis-GMA and triethyleneglycol dimethacrylate (TEGDMA) frequently occur in composite resins. Glass ionomers may include 2-HEMA or trimethylolpropane trimethacrylate. Most dentures are made of acrylic resins that are heat-cured. Heat-cured acrylic dentures rarely cause allergic reactions. Self-curing acrylics that harden without heat are available for repairs and relining.^{87,131,132} In our opinion, it cannot be ruled out with certainty that these allergens may also play a role in the pathogenesis of OLP.

Specific foods

Specific foods, such as citrus juices, tomatoes, spicy ingredients, strong alcoholic liquors, and crisp foods such as corn chips and toasts may aggravate the symptoms of OLP.^{17,134,294} Generally, such reactions are not based on allergy, but on local irritation or toxicity.^{17,133} An adequate nutrition is also essential for a healthy oral mucosa. Nutrients related to energy support, enzyme activity, iron, zinc and vitamin A are documented to affect the state of epithelial cells and the mucosa. Trauma and infections increase the nutritional demands, but painful oral lesions may reduce adequate dietary intake.⁵²

Histopathology

Generally, histopathological examination is necessary to establish the diagnosis of OLP and to exclude other diagnoses especially (pre)malignant disorders, bullous auto-immune diseases and lupus erythematosus.^{6,9,17,135} The clinical presentation of the (chronic) lesions in OLP may essentially change in the time in one patient and may resemble other diseases.¹⁵ An exception against the rule for taking a biopsy could be made for the reticular variant of OLP without any symptoms with localized and symmetrical lesions for example on the buccal mucosa without contributing external risk factors such as smoking and alcohol abuse. Furthermore, the clinical aspects of OLP may be sufficient to establish a correct diagnosis if there are also concomitant characteristic CLP lesions.^{6,9,10}

The punch biopsy of the skin is familiar to all dermatologists. It is also a safe and useful technique for the diagnosis of diseases of the oral cavity. However, knowledge of the anatomical structures of the oral cavity is essential and neurovascular structures in the specific regions must be avoided by taking rather superficial biopsies. After local anesthesia with lidocaine (1% or 2%) and

epinephrine (1:100,000) one or more punch biopsies of at least 3 millimeters diameter can be taken. Suturing is not necessary and healing occurs by secondary intention and almost complete re-epithelialization occurs within 2 weeks. Bleeding is one of the most dreaded complications of oral surgery, but can be adequately controlled by applying pressure during several minutes in the majority of the cases.^{136,137} Punch biopsies should be taken from the hyperkeratotic or erythematous lesions and from the edge of the lesions in case of erosions or ulcerations to avoid non-specific histopathological features.⁹ Routinely, the biopsies are fixed in buffered 4% formalin and stained with hematoxylin and eosin (HE) and also with periodic acid-Schiff (PAS) reagent. If there are obvious erosions, ulcerations or bullae, without concomitant signs of the hyperkeratotic (reticular) variant, the biopsies must be transported in physiological saline for direct immunofluorescence examination to exclude bullous auto-immune diseases or lupus erythematosus.¹³⁷ Direct immunofluorescence should also be performed in lesions confined to the gingiva for a correct diagnosis, particularly when there is the clinical presentation of a desquamative gingivitis.^{7,138} Generally, it is much easier to biopsy non-gingival lesions.⁶

Light microscopy

The histopathological features of OLP and of CLP are essentially the same, but in OLP these features may be less distinct than in CLP (Figures 7, 8, 9,10 and 11).^{9,23} A histopathological definition of OLP was formulated by the WHO in 1978 as follows:

“The histopathological features of OLP are characteristic. There is usually a keratinized layer, and this may be either ortho- or parakeratinized. If keratinization is normally found at the affected site, then the keratinized layer is thickened. If the site is normally non-keratinized (for example, the buccal mucosa), the keratinized layer in the lichen planus lesion may be very thin; if there is normally a stratum granulosum this will be thickened. If there is normally no stratum granulosum, then the granular cells may be present in small numbers. The ‘saw-tooth’ appearance of the rete processes that is a common feature of skin lesions is less frequently seen in the oral mucosa. The thickness of the epithelium varies and atrophy is often seen. Civatte’s (colloid) bodies may be present in the region of the basal-cell layer, lying either in the epithelium or within the superficial part of the connective tissue. These are rounded or lobulated acidophilic structures which sometimes contain a pyknotic nucleus or nuclear fragments. The changes in the basal cell layer often include “liquefaction degeneration”, and there may be a narrow band of eosinophilic material in the position of the basement membrane. There is a well-defined zone of cellular infiltration that is confined to the superficial part of the connective tissue (lamina propria), and the infiltrate consists mainly of lymphocytes except in the vicinity of an erosion”.¹⁴

Histologically, the principal feature is the dense band-like inflammatory infiltrate that mainly consists of T-lymphocytes and a low number of histiocytes in the superficial stroma and the basement membrane zone (BMZ) associated with liquefaction degeneration of basal epithelial cells.^{6,9,26} Another feature is the presence of Civatte's bodies, which are dyskeratotic basal keratinocytes that have undergone premature keratinization and have been extruded into the papillary mesenchyma.^{140,141} Civatte's bodies were noted in 27% of patients with OLP and are considered to be among the earliest histopathological changes.^{26,142} As the BMZ becomes vacuolated, fluid accumulates and leads to the formation of clefts known as Max Joseph spaces (or Caspary-Joseph spaces).^{143,144} Plasma cells and melanophages may also be present.¹⁴⁵ Parakeratosis may be more common in OLP than in CLP (Figures 7, 8, 9, 10 and 11).^{16,65} The Wickham's striae appear to be correlated with an increased granular cell layer.¹⁴⁷ Unfortunately, there are no defined histopathological features for the different clinical subtypes of OLP.^{22,146}

Although the above characteristics of OLP seem to result in a well-described entity, Van der Meij et al reported in a study in 1999 that there was a significant inter-observer and intra-observer variation in the histological assessment of OLP between 5 oral pathologists.¹⁴⁸ Some pathologists reported conclusions of "evident OLP" or "compatible with OLP" in a considerable number of cases, while others classified the same cases as "no histological support for OLP". They concluded that "the histopathological assessment of OLP, based on the available WHO-definition, is a rather subjective and insufficiently reproducible process. Stricter diagnostic criteria are required in order to obtain a more reproducible diagnosis of OLP".^{139,148,389} Unfortunately, the pathologists were not provided with any clinical information and patient data, and similar studies in nearly all other diseases are lacking.

Electron microscopy

The ultrastructural changes of OLP are closely related with the findings reported in conventional light microscopy and include disruption and thickening (or duplication) of the basement membrane with degenerative changes in the cells of the basal cell layer and the stratum spinosum, the presence of inflammatory cells in intercellular spaces of the epithelium, pools of fluid filling epithelial intercellular spaces (Max Joseph spaces or Caspary-Joseph spaces) with maintenance of desmosomes, distortion of cytoplasmic membranes of the epithelium adjacent to desmosomes because intercellular pools forming cytoplasmic "villi", irregularity of the nuclear membrane of epithelial cells, and increased thickening and granularity of epithelial tonofibrils.^{149,150} The cellular infiltrates in OLP and CLP essentially have similar ultrastructural characteristics.¹⁵¹ The infiltrate consists of predominantly T-lymphocytes and a low number of macrophages.¹⁵¹ In the cytoplasm of the lymphocytes, there is a decreased

number of mitochondria and the Golgi apparatus is poorly developed. Transforming lymphocytes (lymphoblasts) were not encountered. The cytoplasm of the macrophages contained primary and secondary lysosomes, some of which contained phagocytosed material.¹⁵¹ Civatte's bodies are believed to be formed by a meshwork of 70 ångström (= 7 nanometers) strands probably derived from intracellular tonofilaments. As the disease process continues, there is a steady loss of tonofilaments, desmosomes, and hemidesmosomes. The degeneration of hemidesmosomes in the basal layer may explain the blistering.^{26,140,153} In a study by Tyldesley and Appleton, it was explicitly mentioned that no viral inclusions were observed.¹⁵²

Immunopathology

Direct immunofluorescence shows fibrin and (shaggy) fibrinogen in a fibrillar or linear pattern at the basal membrane zone (BMZ) in a high number of OLP lesions, which is an important feature.^{141,154,156} IgM and complement components, principally C3, C4, and C5, have also been observed in the BMZ. IgA could not be demonstrated in the BMZ. Colloid bodies most often stain positively for IgM, C3, and C4.^{141,155} IgA, IgG, C1, and C5 may sometimes also be detected.^{155,156} IgM is particularly found in early stages of colloid body formation. Both fibrin and albumin were also noted.^{22,155} However, it is important to stress that these findings when combined with histopathology are only highly indicative, and not diagnostic for OLP.^{6,9,104} Indeed, oral lichenoid drug reactions also have the same features.^{14,95,157,160,464,467}

When there are oral lesions with erosions, ulcerations, or bullae, without concomitant signs of the hyperkeratotic (reticular) variant in the surrounding mucosa, direct immunofluorescence should be performed for distinguishing between OLP and bullous auto-immune diseases and lupus erythematosus.^{6,158-160} Direct immunofluorescence should also be performed when the oral lesions are confined to the gingiva because the histopathological features of OLP on the gingiva are often non-diagnostic, particularly in case of the clinical picture of a desquamative gingivitis.^{17,138}

Immunohistochemical examination shows a band-like infiltrate mainly consisting of T-lymphocytes in the BMZ characteristic of OLP.^{161,162} The duration of the lesions seems to influence the composition of this inflammatory infiltrate. The infiltrate in early lesions principally consists of T-helper/inducer cells (CD4 +, Leu-3a) and a low number of macrophages. The infiltrate in advanced lesions primarily consists of T-suppressor/cytotoxic cells (CD8+, Leu-2a) that also express HLA-DR antigens.^{146,159,163} A few or no B-cells were identified.^{22,163} Boissic et al reported in a histochemical study on OLP that the band-like infiltrate consisted of 94% T-lymphocytes and 6% B-lymphocytes.¹⁶⁴

There is an increased number of Langerhans cells in the epithelium of OLP and these cells are important in antigen presentation.¹⁶⁵ Furthermore,

numerous basal keratinocytes are positive for HLA-DR class II antigens, whereas in normal epithelium, keratinocytes were found not to express those antigens. HLA-DP and HLA-DQ antigens were not observed to be expressed.^{164,166,167} In 1983, Olsen et al identified lichen planus-specific antigen (LPSA) by indirect immunofluorescence in lesional tissue from patients with LP.¹⁶⁸ Subsequent investigation showed that this antigen was present in 20 patients (80%) with CLP.¹⁶⁹ However, not all lesions of CLP in the same patient have LPSA. The circulating antibodies to LPSA are more likely to be markers of the disease than to be causative.¹⁷⁰ In OLP, LPSA seems to be less prevalent than in CLP, but patients with OLP may also have antibodies directed against this antigen.¹⁷⁰ The LPSA was found in the granular or spinous layer and seems to be specific for LP because it was not found in patients with other dermatoses. Moreover, LPSA was reported in childhood bullous LP.¹⁷¹ The immunohistopathological changes that are typical in OLP may also be observed in the oral lichenoid tissue reactions.¹⁵⁹

Pathogenesis

To date, the exact cause of OLP remains unknown.^{6,22,26} A number of etiological factors and associated mechanisms have been put forward, but none of them provide a satisfactory unifying explanation on the underlying antigenic trigger which ultimately leads to the histopathological changes that are observed in this disease.³⁰ Abnormal metabolism, impaired production of tonofilaments, and defects in the assembly of desmosomes have also been implicated as pathogenetic factors.³¹ Basal cells behave more like keratinocytes because of decreased metabolic and regenerative capacity. This leads to an increased production of granular cells.¹⁷² Although immunological involvement in the pathogenesis was demonstrated in previous studies, the primary event in the disease was not identified and it is still a matter of speculation and remains to be elucidated.^{30,70,161,162}

The levels of epidermal glucose-6-phosphate dehydrogenase were observed to be inconsistent (normal, decreased or increased).^{173,174} A reduced quantity of this enzyme may predispose patients to develop LP after ingestion of anti-malarial drugs.¹⁷⁵ Reduced levels of respiratory enzymes such as cytochrome oxidase, succinic-dehydrogenase, reduced form of nicotinamide-adenine-dinucleotide (-phosphatase), and β -hydroxyacyl-coenzyme-A-dehydrogenase were also reported.^{172,176,177} Holmstrup and Dabelsteen reported that two plant agglutinins, concanavalin-A and Ricinus communis agglutinin fraction-I, did not bind to the cell membranes of basal cells in OLP. They postulated that an antigenic change had taken place in the cells involved and that this change might play a role in the pathogenesis of OLP.¹⁷⁸

The genes of the Major Histocompatibility Complex (MHC) encode for cell determinants that regulate immune responsiveness. Class I MHC molecules

are present on all nucleated cells of the body in varying amounts from scarcely detectable to very strong expression. The amount of these cell-surface molecules may markedly increase during immune reactions. They are the core of the individuality antigens of each person, and form the recognition signal for CD8+ cytotoxic T-cells. In humans, the HLA-system fulfils the role of histocompatibility.¹⁷⁹

Humoral immunity

There are contradictory reports on the levels of immunoglobins IgM, IgA, IgG, IgD and IgE in the sera of patients with LP.¹⁸⁰ The levels of complement were reported to be normal.¹⁸¹ Circulating immune complexes and complement components, such as C3, were reported in patients with OLP.¹⁸² Mahood et al evaluated 45 patients with LP and found that when the disease was active or recently resolved (< 2 years), serum IgM levels were slightly low. Patients with a history of LP (> 2 years) had normal levels of serum immunoglobulins.¹⁸³ In one study, serum cryoglobulins were found in 31% of the patients with LP.¹⁸⁴ The exact role played by humoral (auto) immunity in OLP still remains obscure and its contribution appears to be minor as compared with that of the cellular (auto)immunity.^{30,162}

Cellular immunity

The pathogenic mechanism responsible for OLP has been mainly attributed to dermal T-cells. Evidence for the central role of T-cells in the evolution of OLP has been reported in various studies.^{30,70,161,162} T-cell receptor gene and rearrangement studies indicated that clonal T-cells are present in LP tissue.⁹⁰ These T-cells significantly showed more cytotoxicity against autologous lesional keratinocytes than T-cells from non-lesional tissue.¹⁸⁹ There is a selective recruitment of T-cells in OLP.^{30,161,162} The histopathological abnormalities observed in LP disappeared when lesional skin was transplanted onto athymic mice (lacking functional T-cells).¹⁸⁵ Similar changes were reported to occur in explants of lesional skin maintained in organ cultures.¹⁸⁶ These findings indicated that the migration of T-cells and other components of the cellular immune response is a crucial factor in the pathogenesis of LP.^{151,164,185} A diagrammatic representation of the events leading to the evolution of OLP is shown in Figure 12 and was modified from Boyd and Neldner.^{26,30,98} It is also a modification of the proposed immunological lichenoid tissue reaction from Morhenn and Shiohara et al.^{187,188,198.}

It has been postulated that the primary event in OLP is a delayed-type hypersensitivity (Type IV) in which an unidentified “neoantigen” of basal keratinocytes is processed in the Langerhans cells followed by the recruitment of T-cells.^{9,26,159} This process is mediated via adhesive interactions between

specific cell surface molecules and directed by chemotactic cytokines produced by epithelial cells.^{190,191} Cytokines are soluble messenger proteins elaborated by cells, usually involved in inflammatory processes.^{26,192} Interaction of intercellular adhesion molecule-1 (ICAM-1, CD54) on Langerhans cells (CD 6+) and lymphocyte function-associated antigen-1 (LFA-1, CD11a) on T-cells results in the generation, among others, of either CD8+ (MHC class I restricted) or CD4+ (MHC class II restricted) cytotoxic T-cells.^{159,193-195} Other specific adhesive interactions include CD3/T-cell receptor: antigen, CD8: MHC class I and CD4: MHC class II.^{190,196} The cell-mediated response initiated by Langerhans cells thus includes cytotoxic T-cells that are directed against the “altered” keratinocytes and which may also be responsible for damaging cells of other organ systems such as hepatocytes.¹⁹⁷ The mucosa in OLP contains an increased number of Langerhans cells compared with normal oral mucosa.³⁰ There is an interaction of an antigen (drugs, contact allergens or viruses) with either keratinocytes or Langerhans cells, resulting in the production of interleukin-1 (IL-1) (Figure 12).^{26,98} This IL-1, in turn, stimulates the production of interleukin-2 (IL-2) by T-cells.^{30,187} In addition, HLA-DR+ keratinocytes produce pro-inflammatory cytokines.¹⁹⁸ The production of interferon gamma (IFN- γ) by activated T-cells is increased.^{26,188} This, in turn, induces the expression of HLA-DR on keratinocytes which progress into lesional cells.¹⁸⁷ The expression of LFA-1 on monocytes was observed to be induced by IFN- γ produced by T-cells, thereby facilitating the attachment of these cells to keratinocytes.¹⁹⁸ Helper T-cells (CD4+) and cytotoxic T-cells (CD8+) destroy keratinocytes via interaction with HLA-DR (MHC class II) and class I antigens, respectively.^{163,164} Lymphokines may also directly damage basal cells or down-regulate (CD8+) cytotoxic/suppressor cells.¹⁹⁹ It was also suggested that activated T-cells may recognize keratinocytes as “target cells” and interact directly with them.¹⁶¹ In early lesions of OLP, helper T-cells and macrophages were predominant, but in older lesions cytotoxic/suppressor T-cells were mainly observed within the infiltrate.^{156,159,163,164} An imbalance existed between T-helper and T-suppressor activity.^{200,201} T-lymphocytes in OLP generate increased levels of interleukin-6 (IL-6) and granulocyte-macrophage colony-stimulating factor (GM-CSF). The local cytokine production may be important in the perpetuation of OLP.²⁰² Calprotectin and cutaneous lymphocyte antigen (involved in homing T-cells) are up-regulated in OLP.^{30,472,473}

Heat shock proteins (HSPs), also called “stress proteins”, are expressed by most living cells. They play a role in case of stress, including heat, oxidative injury, infection, apoptosis, protection againsts ultraviolet damage, wound healing and other protein remodelling processes. These proteins also play an essential role in cellular survival and are encountered in many immune and inflammatory responses in the skin and the mucosal membranes. Heat shock proteins are classified according to molecular weight, homology, and func-

tion. An altered HSPs 60 and 70 expression in the oral mucosal epithelial cells was reported in OLP and was claimed to have a role in the pathogenesis of OLP.²⁰³⁻²⁰⁶ The T-cells in OLP consist of a distinctive population of gamma-delta T-cells. This subtype of T-cells may interact with certain parts of HSPs. Heat shock proteins and vascular adhesion molecule-1 (VCAM-1) may also be expressed under the influence of IFN- γ and facilitate the lymphocyte-to-keratinocyte adherence which determines the apoptotic death of keratinocytes.^{32,203-206}

Laminin and types IV and VII collagen extracellular matrix are significantly increased at the epithelio-mesenchymal junction in OLP and may bind to beta-1 integrins on the surfaces of infiltrating lymphocytes.¹⁵⁹ In addition, fibrinogen is deposited at the BMZ and adjacent areas of lymphocyte accumulation.^{6,159} Oral lichen planus differs from CLP in the expression of alpha-beta integrin, which is up-regulated in OLP but not in CLP.⁴⁷³ There are contradictory reports on the peripheral CD8 count and the CD4/CD8-ratio.^{207,208} The possible contribution of auto-reactivity in the pathogenesis of OLP was also indicated on the basis of studies demonstrating changes in T-lymphocytes in the peripheral blood, including a depressed number of CD4+ and CD45RA+ cells in patients with OLP compared with age- and sex-matched healthy individuals.^{6,217} Simon et al reported that the activity of natural killer cells in patients with LP was decreased and it seemed to be related to the severity of LP.²⁰⁹ A normal amount of β 2-microglobulin was reported to be produced by activated lymphocytes in patients with OLP.²¹⁰ As the lesions evolve, cytokines derived from lymphocytes (IFN- γ) and keratinocytes (IL-1, IL-6) influence the behavior of the lesional cells and the overlying epidermis.^{30,209} The majority of T-lymphocytes within the epithelium express the alpha-beta T-cell receptor (TCR) and are “memory” T-cells.^{69,70} The TNF α -receptor is known to play an important role in apoptosis which is a very important phenomenon in the histopathology of OLP.⁴⁷⁴

Associated diseases

Oral lichen planus has been reported to be associated with a variety of disorders and particularly with disorders involving altered or disturbed immunity. However, it may be difficult to determine whether there is a causal or a purely fortuitous association.^{22,26} A small number of patients with OLP may coincidentally suffer from systemic disease not necessarily linked causally with OLP, because OLP is a relatively common disease. Furthermore, OLP is predominantly seen in individuals older than 50 years. This also increases the chances of coincidental systemic disease.⁶ There is also the difficulty in the differential diagnosis between OLP and oral lichenoid drug eruption (LDE).^{10,157} It may be impossible to distinguish both disorders based on clinical and histopathologi-

cal examination.¹⁵⁷ Since many different drugs may be involved in oral LDE (Table VIII), some reports on apparent association of OLP with systemic disease were likely because of side effects of drugs rather than associations with a specific systemic disease.⁶

There are contradictory reports on associations between OLP and/or CLP and disorders such as alopecia areata^{211,243}, chronic active hepatitis^{212,218,219}, dermatomyositis²¹¹, dermatitis herpetiformis²¹³, diabetes mellitus^{19,214-216,222}, Hashimoto's thyroiditis^{220,221}, HIV infection⁶⁶, hypertension²²³⁻²²⁵, hyperthyroidism²⁵⁰, hypogammaglobulinemia^{211,226}, keratoconjunctivitis sicca and xerostomia (Sjögren's syndrome)^{227,274,356}, lupus erythematosus^{228,229}, malignancies^{6,230,232}, morphea²³³, myasthenia gravis^{234,235}, pemphigus foliaceus²³⁶, pemphigus vulgaris^{236,237}, pernicious anemia^{238,239}, primary biliary cirrhosis^{240,241}, rheumatoid arthritis²⁶⁹, systemic sclerosis²⁴², thymoma^{211,234}, ulcerative colitis^{243,244} and vitiligo^{211,233}. Marren et al reported an association between vulval lichen sclerosus and OLP in older women.²⁴⁵ Occasionally, associations were also reported between LP and other conditions such as coeliac disease²⁴⁶, Crohn's disease²⁴⁷, vitamin deficiencies (B1, B6, C, iron or folate acid)^{52,248}, erythema dyschromicum²⁴⁹, mesangioproliferative glomerulonephritis²⁵⁰, psoriasis vulgaris²⁵¹, Turner's syndrome with endocrinopathies²⁵², and urolithiasis²⁵³.

It was reported that OLP was most strongly related to chronic liver diseases, especially chronic active hepatitis^{212,218,219} and primary biliary cirrhosis^{240,241}. However, the treatment of primary biliary cirrhosis with penicillamine may produce an oral LDE.^{254,255} Bagan et al reported that the erosive form of OLP was more commonly associated with chronic liver disease than other forms of OLP. They suggested that the clinical presentation of OLP seems to be influenced by the concomitant disease.²⁵⁶ The reports on increased associations between OLP and chronic liver disease were particularly from Italy²⁵⁷, Spain²⁵⁸ and Japan²⁵⁹. In British²¹⁹, North American²⁶⁰ and North European²⁴⁰ studies, the association between chronic liver disease and OLP was not observed.

The bullous (or vesiculo-bullous) variant of CLP and LP pemphigoides were most commonly reported in association with underlying malignancies.⁶ Concurrent LP and neoplastic disorders were reported in breast cancer²⁶¹, Castleman's tumor²³², craniopharyngioma²³¹, lymphosarcoma²³¹, malignant fibrohistiocytoma²⁶², metastatic adenocarcinoma²³⁰, neuroblastoma²⁶³, non-Hodgkin's lymphoma^{230,264}, pituitary adenoma²³¹, retroperitoneal sarcoma²³⁰, stomach cancer²²⁰ and thymoma^{211,234}. However, some other authors reported no higher risk either of skin malignancy or of internal organs in CLP.^{26,46,265,266}

Shuttleworth et al studied 54 patients with LP and an equal number of matched control individuals and found no association between LP and auto-immune diseases.²⁶⁷ Altman and Perry did not find a consistent link with other diseases in a study of 307 patients with LP.⁴⁶ The association between ulcerative colitis

and LP was reported as “epidemiologically evident” in a multicenter, case-control survey.²⁴³

Some authors found an impaired glucose metabolism in a higher number of patients with OLP^{215,268}, whereas other authors only found low prevalences of OLP in large groups of patients with diabetes mellitus^{8,216}. Bagan et al reported that there may be a higher prevalence of lingual involvement and erosive lesions in patients with diabetes mellitus and OLP.²⁷⁰ Powell et al reported that LP could antedate diabetes, like necrobiosis lipoidica.²⁷¹

In 1966, Grinspan et al described seven cases of OLP associated with diabetes and hypertension, a triad which became known as Grinspan’s syndrome.²²³ This is still seen but is probably a coincidental combination of three common disorders or may be an oral LDE provoked by the drugs used to control diabetes and/or hypertension.²²⁵ Oral lichen planus and hypertension probably also have no significant correlation.²⁷²

In 2000, Blanco Carrion et al investigated possible associations between OLP and biochemical alterations in 52 patients with OLP and 54 control individuals.²⁷³ Basic biochemical parameters such as globulin, albumin, glucose, urea, creatinine, uric acid, total cholesterol, triglycerides, lipoprotein fractions (LDL, HDL, VLDL), liver enzymes (ASAT, ALAT, GGT, ALP), LDH, calcium, phosphorus, thyroid hormones (TSH, T3, T4) and sex hormones (FSH, LH, estradiol, progesterone) were determined. The results showed that the mean values of the different parameters were within the normal range, with the exception of glucose, which exhibited borderline values, and LDL, which exceeded the reference concentrations. Patients with OLP showed higher mean cholesterol levels than the controls. Patients with atrophic or erosive lesions presented an increase in VLDL versus patients with reticular lesions. The conclusions were that the endocrine changes associated with the menopause did not seem to influence the development of OLP (or a specific variant) and that minor alterations were observed in lipid metabolism in patients with OLP.²⁷³

Differential diagnosis

The differential diagnosis of OLP depends largely on the clinical variant of OLP, the involved anatomical location in the oral cavity, the symmetry, the persistence and the severity of the lesions, the age and the sex of the patient, the possible concomitant diseases, the potential risk factors such as exposure to tobacco, prior treatment, and the possible involvement of the skin.

Generally, the diagnosis of the reticular type of OLP can be established on the basis of clinical features such as the characteristic Wickham’s striae (Figure 1).^{13,18,22} The papular variant of OLP has also a typical, clinical appearance, although it is not very common.^{15,18} The plaque-type OLP should be par-

ticularly distinguished from leucoplakia, several forms of keratosis (frictional, smoker's, idiopathic or benign oral), and candidosis (especially the chronic hyperplastic form) (Table III).^{18,275-277}

The differential diagnosis of the hyperkeratotic form of OLP may also include chronic discoid lupus erythematosus, geographic stomatitis, morsicatio buccarum, papillomas, psoriasis, hairy leukoplakia (mainly associated with HIV infection), syphilis, oral lesions in chronic renal failure, burns, grafts, lichen sclerosus and carcinoma (Table III).^{6,65,275,278} White lesions are also seen in rare disorders including white sponge nevus, chronic mucocutaneous candidiasis, dyskeratosis congenita, dyskeratosis follicularis, pachyonychia congenita, Clouston's syndrome, oral hyperkeratosis syndrome, hereditary benign intraepithelial dyskeratosis.^{275,279,280} Histopathological examination should be undertaken in these cases. Direct immunofluorescence may also be valuable in differentiating the plaque variant of OLP from leucoplakia.⁹

In 2002, Van der Meij et al published a study on 4 experienced clinicians who conducted a clinical examination of 60 patients with white oral lesions based on clinical pictures with an interval of three months.¹³⁵ The diagnosis varied from diagnosis of OLP (based on the WHO definition), leukoplakia or other definable lesion. The results showed that there was a moderate to substantial inter-observer agreement, whereas the intra-observer agreement varied from substantial to good. Their conclusions were that although the clinical WHO definition of OLP seemed to be more reproducible than the histopathological one, there was still a significant level of subjectivity in using this definition. They suggested that there should be a set of clinical and histopathological diagnostic criteria with good inter-observer and intra-observer agreements.^{135,389} This is very important for reproducible and reliable studies on OLP.

Clinically, the atrophic, the erosive and the ulcerative variants are the most difficult forms of OLP to distinguish from other disorders (Figures 2 and 3) (Table IV).^{22,281} Consecutive histopathological examination and direct immunofluorescence should be performed in these cases.^{17,275} These variants often also have minor signs of the hyperkeratotic (reticular) variant in the surrounding mucosa, which may be an additional clue in the diagnosis of OLP.¹⁷ Furthermore, in patients who underwent multiple biopsies of different forms of OLP, reticular lesions were histologically diagnosed as OLP much more commonly than erythematous or erosive lesions, which were often interpreted as non-specific mucositis.^{17,146} Approximately 15 to 35% of the patients with OLP also have concomitant CLP and generally the diagnosis of the skin can be established more easily.⁶ Many diseases may resemble the atrophic, the erosive and the ulcerative variants of OLP including particularly lupus erythematosus (systemic, subacute cutaneous, and chronic discoid), (allergic) contact stomatitis, cicatricial pemphigoid (benign mucous membrane pemphigoid), erythema exudativum multiforme (major), erythematous (atrophic) candidiasis, erythroplakia, pem-

Table III. Main causes of white oral lesions.

Oral lichen planus (OLP)	Oral lichenoid drug eruption (LDE)	Burns
Leucoplakia	Lupus erythematosus (LE)	Papillomas (some)
Idiopathic keratosis	Geographic stomatitis	Grafts
Frictional keratosis	Morsicatio buccarum	Lichen sclerosus
Smoker's keratosis	Carcinoma	Psoriasis
Benign oral keratosis	Candidosis	Hairy leucoplakia
Syphilitic keratosis	Chronic renal failure	Several inherited lesions (e.g. white sponge nevus)

Table IV. Main causes of erythematous or ulcerative oral lesions.

Oral lichen planus (OLP)	Oral lichenoid drug eruption (LDE)	Malignant neoplasms
Lupus erythematosus (LE)	(Allergic) contact stomatitis	Cicatricial pemphigoid
Erythema multiforme (major)	Erythematous candidosis	Erythroplakia
Pemphigus vulgaris	Recurrent aphthous stomatitis	Mucocele
Several viral infections (e.g. herpes simplex)	Mucha-Habermann's disease (PLEVA)	Immunodeficiencies
Pyostomatitis vegetans	M. Behçet	Sweet's syndrome
Dermatitis herpetiformis	Linear IgA disease	Epidermolysis bullosa
Toxic epidermal necrolysis (TEN)	Acute necrotizing gingivitis	Kawasaki's disease
Several fungal infections	Leishmaniasis	Noma
M. Crohn	Ulcerative colitis	Coeliac disease
Reiter's disease	Tuberculosis	Syphilis
(Cytotoxic) drugs (e.g. MTX)	Radiation-induced mucositis	Ulcerative stomatitis
Hypereosinophilic syndrome	Angina bullosa hemorrhagica	Eosinophilic ulcer
Several blood disorders (e.g. anemia, leukemia, neutropenia)	Nutrition deficiency states	Necrotizing sialometaplasia

phigus vulgaris, recurrent aphthous stomatitis, superficial mucocoeles, malignant neoplasms and viral infections such as Herpes simplex, Chickenpox, Herpes zoster, Epstein-Barr (Infectious mononucleosis), Coxsackie (Herpangina, and Hand-foot-mouth disease), Cytomegalovirus and HIV.^{6,9,19,275,279} Erosions or ulcerations in the mouth may be encountered in many other diseases such as dermatitis herpetiformis, epidermolysis bullosa, linear IgA disease, pemphigus vegetans, toxic epidermal necrolysis (TEN), immunodeficiencies, several blood disorders (anemia, leukemia, leukopenia, neutropenia, other white cell dyscrasias), nutrition deficiency states (low iron, folate or vitamin B12), Kawasaki's disease, acute necrotizing (ulcerative) gingivitis, noma, fungal infections (histoplasmosis, aspergillosis, cryptococcosis, mucormycosis, blastomycosis), Leishmaniasis, glucagonoma, M. Behçet, Sweet's syndrome, Reiter's disease, M. Crohn, ulcerative colitis, coeliac disease, tuberculosis, secondary syphilis, drugs (cytotoxic (especially methotrexate) and other agents, acrodynia (mercury poisoning)), radiation-induced mucositis, angina bullosa hemorrhagica, hypereosinophilic syndrome, eosinophilic ulcer, necrotizing sialometaplasia, monoclonal plasmacytic ulcerative stomatitis, pyostomatitis vegetans, and Mucha-Habermann's disease (pityriasis lichenoides et varioliformis acuta (PLEVA)) (Table IV).^{275,279} Nevertheless, many of those disorders have other specific clinical features which may be easily distinguished from OLP.

When OLP is confined to the gingiva, the clinical appearance in the form of "desquamative gingivitis" shares many clinical features with bullous autoimmune diseases and lupus erythematosus and it may be very difficult to distinguish from these disorders.^{7,17,65}

The histopathological and immunological examination of oral LDE generally show features identical or very similar to those of "idiopathic" OLP. Such investigations cannot be used to reliably distinguish between oral LDE and "idiopathic" OLP.^{10,157,159}

The Burning Mouth Syndrome (BMS) may also be encountered in the differential diagnosis of symptomatic OLP, particularly when there are nearly no objective lesions of OLP. The BMS is characterized by chronic intermittent or constant burning or tingling in the oral cavity without macroscopically visible lesions of the oral mucosa.⁹⁶

Treatment

"Primum non nocere". "First, do no harm".

Hippocrates (?) (460-377 B.C.)

Many of the currently used treatments for OLP are empirical and are based on anecdotal reports or open clinical trials without adequate control groups. Randomized placebo-controlled clinical trials have rarely been reported and

usually involve small populations.²⁸² Much of the data cannot directly be compared and meta-analysis is not possible because of the heterogeneity of the publications concerning the exact definition of OLP, the design of the study, associated disorders, the therapeutic response and the follow-up.^{133,295} The most common cause of treatment failure in OLP is lack of an appropriate diagnosis, particularly in the erosive and the atrophic forms.¹³⁴

In the literature, it has been reported that only symptomatic OLP requires treatment.^{10,85,282} The chronic oral symptoms and the possible small risk for malignant transformation necessitate adequate treatment.^{10,133} Generally, we agree with this statement. However, malignant transformation was also reported in the hyperkeratotic (asymptomatic) variant of OLP.^{6,18,283,284} Moreover, the clinical variant of OLP in one patient may show a variation in the (near) future.¹⁵ Therefore, in our opinion, it may also be necessary to treat those forms, especially when there are extensive or persistent lesions or when contributing risk factors such as use of tobacco and alcohol abuse for malignant transformation are present. An exception for the treatment could be made for circumscribed forms such as the asymptomatic reticular variant of OLP with bilateral lesions on the buccal mucosa.^{10,18} However, treatment in (symptomatic) OLP is commonly not effective.^{9,10} The large number of agents used in the management of OLP reflects the inadequacy of any agent to control the symptoms in all patients (Table V).^{6,85} The clinical guidelines on the management of OLP are summarized in chapter 9.

Silverman et al reported that symptomatic OLP was fairly common, with 61% of the patients with OLP having lesion-associated pain and an additional 21% of the patients having non-painful irritation. Most patients with symptomatic OLP were women with erosive or ulcerative lesions. Complete remissions were either absent or infrequent, particularly in patients with erosive or ulcerative lesions.²⁸⁵

General measures

General therapeutic measures may include an increase in oral hygiene sometimes by referral to a dental hygienist.¹⁰² Accumulation of plaque may aggravate mucosal inflammation and causes additional pain.⁶ In these cases, an antibacterial mouthwash with chlorhexidine 0.2 % (or 0.12%) may be helpful.^{101,282} The patients are strongly urged to disengage from use of tobacco and alcohol abuse.^{6,55,56,286} Information on possible aggravating factors such as stress, lifestyle and specific foods (crisp foods, tomatoes, citrus juices and spicy ingredients) should be provided.^{17,47,52} Traumatizing factors such as morsicatio buccarum, lip chewing, sharp or roughened teeth, ill-fitting dentures or oral appliances or intensive tongue thrusting should be eliminated as much as possible.¹⁷

Possible extra-oral manifestations of LP should be distinguished, because it may influence the modality of the treatment.^{24,266} Possibly associated disorders such as diabetes mellitus, Hashimoto's thyroiditis, ulcerative colitis and LE must also be identified.⁶ Contact allergy as a cause of OLP should be considered when the oral lesions are in close contact with specific dental restorative materials such as amalgam, gold, palladium, acrylic denture materials and composite fillings, because partial or complete replacement of the dental restorative material will lead to a significant improvement in many patients (Figures 13, 14 and 16).^{3,10,108,114} Contact allergy to flavorings such as vanillin, cinnamic aldehyde, fragrance mix or balsam of Peru may also be encountered.² Many drugs (Table VIII) may be involved in oral LDE and these reactions generally show features identical or very similar to those of "idiopathic" OLP. The distinction between "idiopathic" OLP and oral LDE may be very difficult in clinical practice. The oral LDE will resolve within several weeks or months when the specific drug is withdrawn.^{10,157,159}

Specific treatment

Generally, topical agents do not easily adhere to the moist mucous membranes.⁸⁵ Sometimes, it may also be difficult to apply the topical agent to all of the affected sites in the oral cavity, particularly in the elderly, who form a considerable proportion of the patients with OLP. Furthermore, a high frequency of application is commonly necessary and may lead to a lower compliance. Optimal effects are generally achieved with 4 (to possibly 10) applications daily.⁸⁵ Generally, patients are instructed not to eat or rinse their mouths for at least 1 hour after application. Topical agents may be applied as ointments, pastes, lozenges, mouthwashes or inhalers.¹³³ The mode of application may vary with the extent and the severity of the disease.¹³⁴ The decision on which topical vehicle to use, is largely based on the practitioner's personal preference.⁸⁵ Ointments tend to be the most helpful vehiculum in oral lesions, because gels may often irritate and creams are often bitter.^{9,22} Systemic immunosuppressive agents should generally be reserved for acute exacerbations of OLP which are characterized by multiple or persistent erosions or ulcers, or widespread symptomatic disease.¹³⁴ Combinations of treatment are commonly used in practice (Table V).^{10,127}

Antifungal agents

Oral candidosis superimposed on OLP is rather common, especially when topical or systemic immunosuppressive agents are used.^{18,287} Vincent et al reported superinfection of candida albicans in 25 of 100 patients with OLP.⁷ Generally, it seems reasonable to start with an antifungal treatment to avoid a contributing

factor of candidosis in OLP.^{6,282} Nystatin oral suspension (100,000 U/ml, 3-4 times daily 5 ml during 1-2 weeks), miconazole gel (20 mg/g, 3-4 times daily during 1-2 weeks), amphotericin lozenges (10 mg, 3-4 times daily during 1-2 weeks) are effective. In chronic resistant or frequently relapsing candidosis, systemic itraconazole (capsule 100 mg, once daily during 1-2 weeks) and systemic fluconazole (capsule 50 mg, once daily one or two capsules during 1-2 weeks) are effective.^{275,288} Some authors advise regular use of topical antifungal suspensions (miconazole gel once daily) to prevent superimposed candidosis on OLP.²⁹⁸

Analgesics

Lidocaine gel can be used safely against persistent lesion-associated pain in patients with OLP alongside other therapeutic agents.²⁸² Lidocaine gel can be used in the mouth, but is limited to restricted areas of pain with a maximum of 6 doses per day. The patient should not eat or drink shortly after the use of the gel in the whole oral cavity because of an increased risk of choking.²⁸⁸

Corticosteroids

The mainstay of treatment of OLP remains corticosteroids, which can be used topically, intralesionally, or systemically.^{7,85} Corticosteroids both inhibit the membrane enzyme phospholipase A2 and stimulate the cell-membrane protein lipocortin. These factors indirectly influence prostaglandins, leukotrienes, and platelet-activating factor.²⁸⁹ Other proposed mechanisms include a cytostatic action, a “stabilizing” action on lysosomal membranes and cytokine suppression. Generally, corticosteroids are anti-inflammatory, immunosuppressive, antiproliferative and vasoconstrictive.²⁸⁹

Topical corticosteroids

In The Netherlands, hypromellose 20% ointment (hydroxypropylmethylcellulose) is an appropriate base used for mucous membranes.²⁸⁸ In other countries, the base called Orabase is commonly used. It consists of carboxymethylcellulose, pectin and gelatin.^{134,290}

Triamcinolone acetonide 0.1% in hypromellose 20% ointment administered at least 4 times per day may be useful in patients with mildly symptomatic OLP.^{134,282,291} Lidocaine 1-2 % may be supplementary to this ointment.²⁸⁸

Fluocinolone acetonide was reported to be more effective than triamcinolone acetonide.^{291,292} Unfortunately, fluocinolone acetonide is no longer available in The Netherlands.²⁸⁸ Greenspan reported that corticosteroids had no significant effect on the hyperkeratotic lesions of OLP.²⁹³

Betametasone valerate as an aerosol was compared with placebo in a double-blind study in 23 patients with symptomatic OLP. During 2 months of treatment, 8 out of 11 patients responded well compared with 2 in the placebo group.²⁹⁶ The safety profile of betametasone used regularly for several weeks in patients with erosive OLP was studied, but significant adrenal suppression could not be established.²⁹⁷ Nevertheless, if swallowed, the systemic absorption of 750 microgram betametasone is equivalent to 5 mg prednisolone.²⁹⁷ Clobetasol propionate ointment was reported to be highly effective in OLP and may also be more effective than fluocinolone.^{299,300} No significant adrenal suppression or other adverse effects were found during a 6-month follow-up.³⁰¹

In 2002, Hegarty et al reported a randomized cross-over study in 44 patients (9 males and 35 females; aged 26-86 years, mean age 54 years) with symptomatic OLP.³⁰² Fluticasone propionate was administered for 6 weeks as a spray (50 micrograms aqueous solution per dose, 2 puffs applied onto the lesion(s), 4 times daily) and betametasone sodium phosphate was also administered for 6 weeks as a mouthwash (0.5 mg tablet dissolved in 10 ml water). The resulting solution was held in the mouth against the lesion(s) for 3 minutes, 4 times daily). Subjective improvement of the symptoms occurred in 35 patients after fluticasone propionate treatment and in 32 patients after betametasone sodium phosphate treatment. The conclusions were that both fluticasone propionate spray and betametasone sodium phosphate solution were effective in the short-term management of symptomatic OLP. Fluticasone propionate spray was slightly more acceptable to the patients because of the convenience of the spray form, but there were significantly more minor side effects such as bad taste and smell, nausea and a dry mouth associated with the spray.³⁰² "Generalized" OLP may possibly be managed better by the oral mouthwash of betametasone sodium phosphate tablets 0.5 mg dissolved in 10 ml water, whereas localized erosions may possibly be controlled better by fluticasone propionate spray or a topical corticosteroid ointment.^{282,302} An alternative spray is budesonide spray, 100 microgram per dose, at least two puffs twice daily on the individual lesions.²⁸² Rodström et al advised an initial treatment with a highly potent steroid (e.g. clobetasol propionate) and for the maintenance treatment a moderately potent steroid (e.g. triamcinolone acetonide).²⁹¹

It is important to state that all of these corticosteroid preparations (classes II, III and IV) may be associated with adrenal suppression or secondary oral candidosis if used for prolonged periods.³⁰³ Atrophy of the oral mucosa is rarely observed.¹⁰ Moreover, pain and ulceration cannot be alleviated in all patients.⁸⁵ Other modalities of treatment may be necessary.^{85,133,305} Beckman reported that betametasone valerate aerosol could be harmful and even fatal when applied to mucous membranes.³⁰⁴ A poorly evaluated aspect of the use of topical corticosteroids in OLP could be the reduced efficacy on repeated use (= tachyphylaxis).³⁰⁶

Intralesional corticosteroids

Intralesional corticosteroids may be of benefit in the management of symptomatic, localized, erosive or ulcerative lesions which have been unresponsive to other topical agents.³⁰⁵ Triamcinolone acetonide 5-10 mg/ml injected at weekly or twice weekly intervals over 3 to 4 weeks, or every 4 weeks, is generally preferred (with a maximum of 0.1 ml per 1 square cm of tissue per injection).^{85,305} Moreover, hydrocortisone, dexamethesone, or methyl-prednisolone have also been used.⁶ A 50% mixture in local anesthetic has been recommended to lessen the pain of the injections.³⁰⁵ Side effects such as tissue atrophy, oral candidosis and intravascular injection are certainly possible together with systemic side effects associated with corticosteroids.^{18,307} Furthermore, it is very difficult to inject sufficient quantities into gingival lesions for an adequate effect.³⁰⁷

Systemic corticosteroids

Various regimens have been used, but doses of prednisone 30-80 mg are generally administered once daily in the morning for two or three weeks, depending on the severity of symptomatic OLP.^{10,134} Prolonged use of systemic corticosteroids may be limited by toxicity and should only be used in exceptional circumstances.^{85,310} However, adverse effects may also occur during short treatment courses.³¹⁰ Many side effects from long-term treatment can be avoided if combination therapy or alternate-day therapy is established as soon as possible.^{308,309} However, relapses often occur when the dose of corticosteroids is lowered or discontinued and the frequent need to reinstitute therapy indicates the need for a corticosteroid-sparing agent.¹⁰ Moreover, the outcome after systemic treatment may be worse than that after topical treatment.²⁸⁵ Many side effects of treatment with systemic corticosteroids have been reported and include iatrogenic Cushing's syndrome, relative adrenal insufficiency, weight gain, altered fat deposition, muscle wasting, osteoporosis, psychosis, mood alteration, insomnia, cataract, glaucoma, hypertension, edema, peptic ulcers, occult infections, (dysregulation of) diabetes mellitus, steroid acne, thinning of the skin, striae and bruising.^{133,308,309}

Topical tacrolimus

Treatment of OLP with topical tacrolimus ointment is described in Chapter 8.

Topical cyclosporin

The efficacy of topical cyclosporin in symptomatic OLP remains controversial.^{85,134,282} In 1990, Eisen et al reported a double-blind, placebo-controlled trial in 16 patients with symptomatic OLP.³¹¹ The patients received either

topical cyclosporin (containing 100 mg per milliliter) or its vehicle and they swished and expectorated 5 ml of medication after 5 minutes three times daily during 8 weeks. The 8 patients treated with cyclosporin showed a marked improvement, whereas the 8 patients with the vehicle showed no or minimal improvement. After a switch to cyclosporin for 8 weeks, the vehicle-treated patients had improvement similar to that seen in patients who initially received cyclosporin. There were no systemic side effects. In most cases, blood cyclosporin levels were low or undetectable. However, there were relapses of OLP in 4 patients (25%) within 1 month after the end of treatment. Eight patients (50%) showed a complete remission in a follow-up period of 3 to 8 months. Unfortunately, there was no follow-up possible in 4 patients.³¹¹

Because of the prohibitively high costs of this form of treatment, we advised a modification of this therapy by applying cyclosporin suspension 4 times daily with a cotton swab onto the symptomatic lesions with variable results in many patients (unpublished observations). The volume of medication used in this application is significantly lower. Several authors have reported that topical cyclosporin may be of significant benefit in the management of OLP.^{312-314,322} Nevertheless, other groups reported less encouraging results.³¹⁵⁻³¹⁸ Cyclosporin was not detected in the sera of treated patients in most of the studies.^{133,311} Surber et al suggested that the efficacy of topically applied cyclosporin in OLP could be related to a systemic effect of the drug.³¹⁹ Generally, the systemic absorption is low and the efficacy of treatment does not correlate with cyclosporin blood levels.³¹¹ In patients who respond to topical cyclosporin treatment, the effect is typically observed within 4 to 8 weeks of the treatment.¹⁰

Systemic cyclosporin

Cyclosporin is a cyclic polypeptide made up of 11 amino acids. It was isolated and purified in 1972 from a soil fungus found in Norway. Cyclosporin is an immunosuppressive agent which inhibits the production and the release of interleukin-1 (IL-1) from monocytes and interleukin-2 (IL-2) from helper/inducer T-cells.

The proliferation and function of helper/inducer T-cells are selectively inhibited and cyclosporin may reduce IFN- α leading to reduced expression of intracellular adhesion molecule-1 (ICAM-1) on keratinocytes. This specific and reversible inhibitory effect on immunocompetent lymphocytes occurs in the G0 or G1 phase of the cell cycle. Cyclosporin is also reported to inhibit transcription of IL-3, IL-4, GM-CSF, TNF- α and IFN- γ .²⁸⁹ Apart from its use in transplantation patients, cyclosporin has been used in a wide range of T-cell mediated diseases such as psoriasis, atopic dermatitis and LP.^{266,289} Cyclosporin may significantly interfere in the pathogenesis of OLP.^{26,88,266,289} Generally, treatment at low doses (3-5 mg/kg/day) are used in dermatology for several months.²⁸⁹ Cyclosporin in low doses (1-2 mg/kg/day) was reported to

be beneficial in OLP. Side effects of cyclosporin are common, even with careful monitoring of the patient. Cyclosporin may have a considerable, and largely reversible, toxicity on the kidney (renal dysfunction), especially when it is used for long periods. Other side effects include nausea and vomiting, hypertension, hypertrichosis, tremor, hyperkalemia, gingival hypertrophy. Long-term immunosuppression leads to a higher risk of infections and malignancies, particularly lymphomas. Moreover, many drugs show pharmacological interactions with cyclosporin.^{288,320}

Systemic cyclosporin at doses ranging from 3-6 mg/kg/day have been shown to control OLP and in some patients a more prolonged remission was achieved.^{294,321} Generally, systemic treatment with cyclosporin is limited to patients with severe and persistent symptomatic OLP, when most other treatments have failed.¹³⁴ The adverse effects of cyclosporin and the chronicity of the oral lesions have dissuaded many clinicians from using it for systemic treatment of OLP.²⁶

Topical retinoids

Sloberg et al reported in a placebo-controlled study in 23 patients that topical tretinoin 0.1% in Orabase, applied 4 times per day for 2 months led to an improvement or healing in 71% of the patients with atrophic or erosive lesions or with reticular or plaque lesions. The side effect of transient burning directly after application was controlled by reducing the number of applications.³²³ Buajeeb et al reported no side effects with topical tretinoin 0.05% in an oral base, but only partial improvement occurred in 50% of the patients with erosive OLP.³²⁴ Generally, topical corticosteroids (0.1% fluocinolone acetonide) have shown to be more effective than topical retinoids (0.05% retinoic acid) in the treatment of the atrophic or the erosive variants of OLP.^{305,323,324} Topical tretinoin 0.1% seems to be more effective than tretinoin 0.05%, but tretinoin 0.1% may have more side effects such as irritation and burning.^{85,295,325} We agree with some of the authors who reported that tretinoin was more effective in the hyperkeratotic variants of OLP than in the erosive or atrophic variants.^{9,325} Moreover, retinoids may be very irritating, particularly in patients with erosive lesions.⁹ Tradati et al used a new topical retinoid fenretinide (4-HPR) effectively in a few patients with OLP. Side effects were reported to be minimal.³²⁶

Systemic retinoids

Retinoids have profound effects on differentiation, cell growth, and immune response.²⁸⁹ They have anti-inflammatory properties, because of macrophage activation and antibody-dependent cell-mediated cytotoxicity.³²⁷ Moreover, retinoids may also reduce the CD4+ lymphocyte infiltrate and increase the

macrophages in OLP, thus accelerating the healing process.³²⁸ Several drugs such as isotretinoin, etretinate, acitretin and temarotene belong to the group of systemic retinoids. Isotretinoin is very effective in the treatment of severe acne.^{289,294} A wide group of keratinization disorders were treated with etretinate, which has now been superseded by acitretin. The major disadvantage of etretinate is its binding to body fat for up to 2 years after the treatment was completed. The elimination half-life of etretinate is over 100 days, whereas acitretin is 2 days.²⁸⁹ A number of side effects to the retinoids are common, appear to be dose related and are mostly reversible. The side effects include cheilitis, conjunctivitis, dryness of the mucous membranes and the skin, epistaxis, desquamation of the hands and the feet, pruritus, myalgia, arthralgia, lethargy, depression, headache, increased photosensitivity, hyperostosis, premature closure of the epiphyses, hair loss and alopecia. Intracranial hypertension may occur and this is also the reason for not combining isotretinoin with tetracyclines. Abnormal liver enzyme levels, increase in very low density lipoprotein (VLDL) cholesterol, and reduction in high density lipoprotein (HDL) cholesterol were reported after retinoid therapy. Retinoids are known to be teratogenic. Therefore, it is important that women of childbearing potential use an effective form or forms of contraception shortly before, during and a variable period (depending on which agent is used) after treatment.^{288,289,309} Informed consent must be provided by the female patient before the start of treatment. Hersle et al used etretinate (mean dose: about 1 mg/kg/day) for 2 months in a double-blind study in 28 patients with severe OLP.³³⁰ A complete or partial response was seen in 93% of the patients, but all patients developed side effects (cheilitis, conjunctivitis, dryness of skin and mouth, hair loss, pruritus, and headache), which resulted in a drop-out rate of 26%. Lower doses of etretinate produced fewer side effects, but also showed lower improvement in patients with OLP.³³⁰ Ferguson et al reported that etretinate in doses of 25-75 mg per day for 2 months was of minimal benefit in the management of erosive OLP.³²⁷ Camisa and Allen drew a similar conclusion for isotretinoin at doses of 10-60 mg per day for 2 months.³³¹ Laurberg reported in a study in patients with CLP, some of whom also had oral lesions, who were treated with acitretin 30 mg per day for 2 months that there was an improvement, but the oral lesions were not specified, which negatively influenced the importance of their study.³³² Bollag and Ott reported an open pilot study in 13 LP patients who were treated with temarotene at doses of 800 to 4800 mg per day.³²⁹ Temarotene is a newer retinoid (aretinoid) which lacks the conventional cutaneous adverse effects of the other systemic retinoids. It was beneficial in the cutaneous lesions, but less effective in the oral lesions. Moreover, the optimal dose still remains uncertain and 4 patients experienced raised transaminase levels and one patient had nausea and vomiting.³²⁹

In conclusion, complete remission in patients with OLP is difficult to achieve with systemic retinoids alone and the possible adverse effects currently dissuade

their use.¹³³ Retinoids should probably be used as adjuvant therapy or when alternative therapy failed in the treatment.¹⁰ Retinoids combined with topical corticosteroids may improve the efficacy of the treatment.¹³⁴ Larger placebo-controlled studies with temarotene should be performed in the near future to investigate its beneficial effects and possible side effects.²⁹⁴

Azathioprine

Azathioprine is converted in the body to mercaptopurine, an inhibitor of purine synthesis and it is a systemic immunosuppressive agent with potent anti-inflammatory properties. Azathioprine is particularly used in dermatological practice as a steroid-sparing drug to minimize adverse effects when systemic corticosteroids are needed for a long-term treatment. However, azathioprine may generally produce bone marrow suppression, which may be severe.^{289,309} Lozada reported that azathioprine may be a successful steroid-sparing adjunct to systemic prednisone therapy in patients with OLP.³³³ Lear and English chose azathioprine as monotherapy at a dose of 75-150 mg/day as an alternative for systemic corticosteroids in the treatment of OLP.³³⁴ The response to treatment is slow, and the maximum benefits were achieved after 3 to 6 months.¹⁰

Photochemotherapy: psoralen and oral ultraviolet A (oral puva)

Certain plastics used in dental restorations are cured in the mouth by UV light. The units designed for this purpose may be modified to provide UVA in the oral cavity.³³⁵

Lundquist et al reported that UVA was applied to one buccal mucosa 2 hours after ingestion of 8-methoxypsoralen (dose: 0.6 mg/kg).³³⁶ The results were compared with the non-exposed buccal mucosa (control side) after 12 treatments (total dose, 16.5 Joules/cm²). Thirteen of the 18 treated patients' buccal mucosae showed some degree of improvement compared with 6 from 18 control sides, with a sustained benefit observed during the 12 months follow-up. Sixteen patients complained of side effects including nausea, dizziness, eye-symptoms, paraesthesia and headache, and 2 of whom dropped-out because of severe nausea.³³⁶ The basic design of this study was debated because in the confined space of the oral cavity, it is unlikely that the successful treatment of one side would not influence the other side.³³⁷ Kuusiletho et al reported in a preliminary trial the use of topical PUVA by topical application of 0.01% trioxsalen to avoid the common side effects of "systemic" PUVA.³³⁸ One potential drawback of PUVA therapy is the risk of development of squamous cell carcinoma in a condition with a possible premalignant potential.^{339,340} Until further evaluation of safety is undertaken, photochemotherapy has to be considered as experimental.^{6,85}

Surgical techniques

Surgical excision, cryotherapy, carbon dioxide (CO₂) laser, ND:YAG laser and low-dose excimer 308 nm laser have been used for the treatment of symptomatic OLP with variable results.^{85,282,475} There are insufficient double-blind placebo-controlled studies to allow any definite conclusions.¹³³ The well-recognized Koebner's phenomenon may possibly be a contraindication for frequent use of these techniques.^{85,282}

Emslie and Hardman reported 4 patients with symptomatic OLP. They were treated with primary excision and closure. The results were satisfactory in all the 4 patients.³⁴¹ Hovick and Kalkwarf reported treatment of localized erosive OLP with free intra-oral soft tissue grafts.³⁴² Two patients initially demonstrated unresolvable discomfort of localized gingival lesions. Therapy consisted of grafting normal appearing palatal tissue onto the gingiva. Evaluation at 10 months post-operatively revealed no recurrence of symptomatic OLP in both patients.³⁴² Generally, surgery should be reserved for removal of (lichenoid) dysplastic circumscribed areas in patients at high risk of malignancy.²⁸²

Cryosurgery has also been used in a number of patients with OLP.³⁴³⁻³⁴⁵ Cryosurgery destroys local tissue and may cause erosions to enlarge, necessitating close and regular review. Healing generally occurs within several weeks, but relapses are common.⁸⁵

Carbon dioxide lasers were used to treat erosions with varying rates of recurrence.^{346,347,363} The procedure causes little discomfort and the wounds heal without contraction or fibrosis. Frame et al treated 3 patients with erosive OLP with a carbon dioxide laser. They noted re-epithelialization, minimal wound contraction, and a normalization of the oral function within 4 to 6 weeks.³⁴⁶ In our opinion, this laser treatment may be performed in patients with severe, persistent symptomatic OLP with circumscribed areas. The initial results were good but recurrences commonly occurred after about 6 to 8 weeks (unpublished observations).

Other agents

A variety of other agents have less thoroughly been evaluated for the treatment of OLP.¹³³ Generally, these agents have variable results in the treatment of small groups of patients with OLP (Table V).

In 1989, Chen used UVA alone in once weekly doses in 35 patients with OLP. In 30 patients (86%), the oral lesions improved or were cured after 8 weeks.³⁴⁸

In 1995, Nagao et al reported a single case of OLP with chronic hepatitis C virus infection which was successfully treated by glycyrrhizin which is an active component of liquorice roots.^{133,349}

The efficacy of griseofulvin in OLP is debatable.⁸⁵ The earliest studies of

griseofulvin in OLP were very encouraging³⁵⁰⁻³⁵², but subsequent studies have failed to show any benefit³⁵³⁻³⁵⁵.

Dapsone may be considered in resistant cases, particularly when bullous or severely eroded lesions are present, but it may have considerable adverse effects which may outweigh any likely moderate benefit.^{85,133,294,357}

However, Matthews et al reported good results with Dapsone particularly in patients with desquamative gingivitis.³⁵⁸

In 1990, Bogaert and Sanchez in a study of 4 patients with OLP reported a complete healing in 2 patients on phenytoin therapy.³⁵⁹

In 1984, Lundström et al reported that amphotericin B treatment resulted in a 94% clinical improvement in patients with OLP and positive *Candida albicans* cultures.⁸⁰ However, Carbone et al reported in 1999 that treatment against *Candida albicans* only played a marginal role (if any) in the management of OLP.²⁹⁸

Aureomycin and tetracycline mouthwashes have also been used with some success in patients with OLP.^{20,361,362}

Psychotherapy and psychiatric drugs have been successfully used in patients with OLP.^{45,47,360}

In 1989, Pelisse described a patient with the vulvovaginal-gingival syndrome who was successfully treated with sulpiride.³⁶⁴

In 1977, Jolly and Nobile investigated the vitamin status of patients with OLP and reported that vitamins could be beneficial in these patients.³⁴⁸

Levamisole has been used in patients with OLP.³⁶⁵ Clinical efficacy could not be established in these patients despite significant immune alterations. The side effects of levamisole preclude its routine use.³⁶⁶ Combination of levamisole (150 mg a day for three consecutive days in one week) and low-dose prednisolone may be helpful in the control of severe erosive OLP.³⁶⁷ However, this improvement may have resulted from the corticosteroids.⁸⁵

Antibiotics, such as penicillins, chloramphenicol, tetracyclines, and doxycycline were used in patients with OLP with variable results.³⁶⁸⁻³⁷⁰ Doxycycline (200 mg a day) may improve desquamative gingivitis, but not invariably.^{370,371}

In 1993, Eisen reported in an open trial, a beneficial effect of hydroxychloroquine sulfate (200 to 400 mg a day) in 9 of the 10 patients with OLP, mainly in combination with topical corticosteroids, because the effect of both agents appear to be additive.³⁷² Hydroxychloroquine can be administered long-term to patients with symptomatic OLP with few adverse effects. Treatment is not always effective and improvement often takes 4 to 6 months.^{10,372} However, antimalarial agents were also implicated as a cause of an oral lichenoid drug reaction.¹⁵⁷

In 1985, Sato et al reported a complete resolution in 10 patients with OLP after the use of topical human interferon- β .³⁷³ Systemic IFN- α (3 to 10 million IU, three times weekly) may be used in the treatment of OLP both in patients with

Table V. Agents used in the treatment of oral lichen planus (OLP)

Group of drugs	Systemic drugs	Topical drugs
Analgesics	Paracetamol	Lidocaine
Antibiotics	Doxycycline, Penicillin Chloramphenicol, Tetracycline	Tetracycline, Aureomycin
Anticonvulsants	Phenytoin	[Phenytoin]
Antifungals	Itraconazole, Fluconazole Griseofulvin, Amphotericin B	Nystatin, Miconazole, Amphotericin B
Antileprotics	Dapsone	
Antimalarials	Hydroxychloroquine sulfate	
Antivirals	Interferon-alpha	Interferon-beta
Corticosteroids	Betametasone, Prednisolone Prednisone	Betamethasone valerate, Clobetasole propionate, Fluocinonide, Hydrocortisone Triamcinolone acetonide (classes I-IV). INTRALESIONAL: Dexamethasone, Hydrocortisone, Methyl-prednisolone, Triamcinolone acetonide
Cytotoxic agent	Azathioprine	
Hormones	Adrenocorticotrophic hormone (ACTH)	
Immunostimulants	Levamisole	
Immunosuppressants	Cyclosporin, Mycophenolate mofetil	Cyclosporin, Tacrolimus
Miscellaneous	Diethyldithiocarbamate, Eiconol, Enoxaparin, Glycyrrhizin, Oxpentifylline, Thalidomide, Vitamins, [Magnetism, Reflexotherapy]	
Psychological interventions	Psychiatric drugs (e.g. Sulpiride), Psychotherapy	
Retinoids	Acitretin, Etretinate, Isotretinoin, Tamarotene	Tretinoin, Isotretinoin, Fenretinide
Surgery		Conventional, Cryosurgery, Grafting, Laser (CO ₂ , ND:YAG, Low-dose excimer)
UV-radiation	PUVA	Local PUVA, UVA

HCV infection and in patients without HCV infection.^{374,375} However, IFN- α may also trigger or worsen OLP.^{376,377} Antibodies against IFN- γ were reported to abrogate experimentally induced lichenoid reactions.³⁷⁸

In 1985, Naafs and Faber reported a successful treatment of a patient with CLP with thalidomide.³⁷⁹ In 1996, Dereure et al reported successful treatment with thalidomide (150 mg a day) in 2 patients with severe erosive OLP. The only side effect was a mild lymphopenia, which resolved after the treatment was discontinued.³⁸⁰ Thalidomide has severe teratogenic effects and patients should also be monitored for the development of peripheral nerve damage.³⁸¹

In 1998, Hodak et al reported a study in 6 CLP patients and 4 patients with CLP and active OLP that low-molecular weight, low-dose heparin, enoxaparin (3 mg subcutaneously once a week) was beneficial in 1 patient with oral lesions and in 9 patients with cutaneous lesions. This low dose of enoxaparin did not influence the coagulation activity in the patients.³⁸²

In 1991, Sun et al reported a beneficial effect of diethyldithiocarbamate in a few patients with OLP by influencing IL-2 production.³⁸³

In 1995, Barer and Polovets reported the treatment with eiconol in patients with OLP.³⁸⁴

In 2003, Eisen reported that mycophenolate mofetil, a new immunosuppressive drug, at doses of 2 to 3 g/day is both well tolerated and effective in patients with OLP who were unresponsive to other treatments. The response to treatment was achieved over a course of several months. Moreover, this treatment is very expensive and gastrointestinal adverse reactions may require discontinuation of the drug.¹⁰

In 2005, Wongwatana et al reported that it was unlikely that oxpentifylline at a dose of 400 mg 3 times daily, had any benefit in the treatment of OLP.⁴⁷⁶

Alternative therapies such as magnetism and reflexotherapy were also used in an attempt to control OLP.^{385,386}

Prognosis

Generally, OLP is a very persistent disorder and spontaneous remission is not very common in contrast with CLP.^{17,18,294} Despite several kinds of treatment, OLP may persist for many years (for up to 25 years).^{65,133} The long-term effect of treatment upon the course of OLP is uncertain.⁸⁵ Generally, OLP follows a chronic course, with periods of quiescence and periods of flares.^{85,133,134} Thorn et al reported a complete remission rate of 17% in the 611 patients with OLP with a mean follow-up period of 7.5 years.¹⁵ Silverman et al reported an estimated overall spontaneous remission in 2.8% of the 570 patients and in 6.5% of the 214 patients during a mean follow-up of 7.5 years.^{8,285} In another study, Silverman reported no spontaneous remissions in 95 OLP patients with a female-

to-male ratio of 2.3: 1 and with more than 50% of the patients with the erosive form in a follow-up period of 1 to 20 years (mean 6.1 years). Furthermore, OLP was quite stable with only 11.6% of the patients developing new lesions in the follow-up period.²⁵ The various clinical variants of OLP follow somewhat different courses.^{6,15} Andreasen observed that 41% of the reticular oral lesions, 12% of the atrophic lesions, 7% of the plaque-type lesions, and none of the erosive lesions underwent spontaneous resolution.¹⁶ Fulling reported a clearance rate of 15% with therapy in patients with OLP in an average of 3.6 years.³⁸⁷ Generally, remission rates are higher for the reticular variant than for the erosive or the ulcerative variant.¹⁸ Papular lesions are mainly seen in the initial phase and have a transitory course.¹⁵ Complete spontaneous remission is most commonly seen in patients with an initial presence of the papular variant. Ulcerative and erosive lesions are rather persistent. Atrophic lesions show remissions and exacerbations.^{6,22} The plaque type is a very chronic variant.^{15,16} Thorn et al described that after a few years many patients had persistent OLP lesions that no longer included the characteristic, initial features of the reticular and papular form OLP.¹⁵

Complications

Oral candidosis is a common complication of OLP particularly when topical or systemic immunosuppressive therapeutic agents are used.^{7,18,287} The possible malignant transformation of OLP is a very important issue and still remains controversial in the literature.^{17,18,388,389} The malignant transformation of OLP into an oral squamous cell carcinoma ranges from 0-10% in the literature.³⁹⁰ In 2003, Van der Meij et al suggested that immunomodulating agents, such as topical and systemic corticosteroids, which are commonly used in the treatment of OLP, may suppress local cell-mediated immunity and may increase transformation of OLP into an oral malignancy. Moreover, the clinical signs of an oral malignancy may be less obvious during sustained treatment with corticosteroids, which may also increase the chance of progression into an advanced state of malignancy before establishing the diagnosis and the treatment.³⁸⁹

Chronic, symptomatic OLP may negatively influence the quality of life of the patients and may lead to feelings of chronic discomfort. The uncertainty on the possible inadequate treatment of OLP, the possible involvement of extra-oral sites and the possible malignant transformation may enhance feelings of anxiety and stress.^{6,10,17} Moreover, prolonged complaints of oral pain may cause deranged alimentary canal. Specific nutritional deficiencies and even significant loss of weight may occur during prolonged symptomatic disease.⁵² Persistent treatment of chronic OLP may also cause several side effects related to the administration of the specific drug.^{133,134} Patients with

desquamative gingivitis frequently complain of pain and bleeding while brushing the teeth.¹⁰ This results in reduced oral hygiene with an increased accumulation of plaque and calculus and this, in turn, may result in worsening of the gingival lesions.^{48,57} Periodontal surgery may be necessary in such cases to prevent advanced periodontal disease and rarely tooth loss.⁵⁷ Chronic complaints of pain and burning in the oral cavity may cause difficulties with speech and overall functioning and may also interfere with work and relationships.^{10,17}

Follow-up

Generally, the schedule of follow-up of patients with OLP should include at least one or two visits per year as long as OLP persists.^{6,389,391} More frequent visits may be necessary depending on symptomatology, significant changes of symptoms, the extent and severity of OLP, possible extra-oral involvement of LP, the necessity of monitoring of a specific treatment, and the possible accompanying risk factors of oral malignancy such use of tobacco, alcohol abuse, (chronic) candidosis, and poor nutrition.^{6,55,133,388} A careful physical examination at each visit is necessary and histopathological examination should be repeated when a malignancy is suspected, because an early detection of an oral squamous cell carcinoma favors the prognosis significantly.³⁹⁰⁻³⁹² In such cases, red mucosal areas (rather than white), which may show more frequently epithelial dysplasia, should preferentially be biopsied.²⁷⁵ When risk factors of oral malignancy such as use of tobacco and/or alcohol abuse are present, the patients are strongly urged to disengage from the (bad) habit.^{6,393}

Verbal and written general information on OLP including diagnosis, symptoms, possible extra-oral LP involvement, treatment options, possible side effects, contributing risk factors, the possible risk of malignant transformation, the schedule of follow-up and the probable aggravating factors of OLP such as stress, specific foods (acidic fruits, spicy ingredients and crisp foods), mechanical trauma, irritation or allergy to dental restorations and poor oral hygiene should be provided to the patients.^{17,85,294,391}

Written information on OLP of the patient including diagnosis, symptoms, probable aggravating factors, results of further investigations, possible extra-oral LP involvement, recommendations, treatment, contributing risk factors, possible risk of malignant transformation and schedule of follow-up should also be provided to the general practitioner, the dentist and to other possibly involved dental and medical specialists.

A multi-disciplinary approach may be necessary for adequate diagnosis, treatment and follow-up when extra-oral sites are concomitantly involved in patients with OLP.^{24,26,294}

Table VI. Clinical variants of lichen planus (LP).

CUTANEOUS LICHEN PLANUS (CLP):	OVERLAP SYNDROMES:
Actinic ((sub-)tropicus)	Lupus erythematosus - lichen planus overlap syndrome (= LE-LP overlap syndrome)
Acute, eruptive and subacute	Lichen planus pemphigoides
Annular	
Atrophic	
Bullous (vesiculo-bullous)	MUCOSAL LICHEN PLANUS:
Classical	Anal
Erythematous	Conjunctival
Exfoliative	Esophageal
Eyelid	Genital
Familial	Larynx
Guttate	Lip
Hypertrophic	Nose
Inversa	Oral (OLP)
Invisible	Stomach
Linear	Urinary bladder
Nail	
Palms and soles	Vulvovaginal - gingival syndrome (VVGs)
Perforating	Peno-gingival syndrome
Pigmentosus	
Planopilaris (follicular)	LICHENOID REACTIONS:
Solitary	Graft-versus-host disease (GVHD)
Tumidus	Lichenoid contact dermatitis
Ulcerative	(Oral) lichenoid drug eruption (LDE)
Unilateral	
Zosteriform	

Oral lichen planus and extra-oral manifestations of lichen planus

Approximately 15 to 35% of the patients with OLP have concomitant CLP involvement (Table VI).^{10,24,25} However, in a few studies the reported incidence even varied from 4 to 44%.^{16,65}

In 1999, Eisen evaluated 410 women (mean age 52 years) and 174 men (mean age 43 years), all with OLP based on clinical and histopathological features.²⁴ In 93 patients (16%) of the 584 patients with OLP, there was also an involvement of the skin. The onset of cutaneous and oral lesions occurred simultaneously in about 50% of these patients. The development of cutaneous lesions preceded the onset of mucosal lesions, usually by 1 year (in about 25% of the patients), and by as much as 10 years in 1 patient. In the remaining patients, CLP followed OLP, typically within several months. The severity of OLP did not correlate with the extent of CLP.

Six female patients were diagnosed with lichen planopilaris. The development of the lesions of the scalp preceded the onset of OLP in 83% of the patients by 1 to 3 year(s). Lichen planopilaris and the oral lesions simultaneously developed in one patient. Nail changes typical of LP were noted in 11 patients and preceded the onset of OLP in all patients by approximately 2 to 5 years. The most common clinical manifestations included thinning, ridging, and distal splitting of the nail plate. Six patients had involvement of all fingernails, 3 patients showed LP limited to several fingernails, and 2 patients had involvement of both the fingernails and the toenails. Vulvar and vaginal LP was identified in 77 (19%) of the 399 women who were examined. The erosive form of the disease was the predominant type, and the asymptomatic reticular lesions were identified in 25% of the patients. The simultaneous appearance of the genital and oral lesions was noted in 50% of the patients. Genital LP preceded OLP in 20% of the cases, and OLP preceded genital LP in 30% of the cases, usually within 1 year. Eight men of the 174 examined patients had genital LP with simultaneous involvement of the oral mucosa. Four of the patients showed LP of the esophagus upon endoscopy with symptoms of dysphagia and one patient showed ocular LP. The conclusions were that a thorough evaluation, if necessary by a multi-disciplinary group of healthcare providers, in patients with OLP should be performed, because a relatively high percentage of patients with OLP may display extra-oral manifestations of LP.²⁴

Mucosal lichen planus

The vulvovaginal-gingival syndrome

In 1982, Pelisse et al described a new entity of erosive LP: the vulvovaginal-gingival syndrome (VVGs). It consists of the triad of erosive or desquamative vulvitis, vaginitis, and gingivitis.³⁹⁴ The term “plurimucosal LP” was already reported by Gougerot and Burnier in 1937 and described the occurrence of LP involving the buccal mucosa, the cervix and the stomach without skin involvement.³⁹⁵ Bermejo et al suggested that the term “plurimucosal LP” was more appropriate than “the vulvovaginal-gingival syndrome”.³⁹⁶ We suggest the term “oro-genital LP”, which describes this disease more accurately and can easily be distinguished as a clinical entity in the spectrum of LP. However, the term “vulvovaginal-gingival syndrome” will be used here because it is mostly used in the literature.^{24,364,394} In 1989, M. Pelisse reported 19 women aged 27 to 70 years (median age 44 years) with VVGs.³⁶⁴ Eighteen women had an erosive vulvitis with complaints of burning and/or pain and 12 women had serious complaints of dyspareunia. All 18 patients showed several erythematous plaques with epithelial desquamation or frank erosions. In most instances, there was an easily overlooked narrow rim of white reticulation at the periphery of the red plaques. In 6 patients, vulvar adhesions or atrophic lesions were found.

Eleven patients showed a desquamative vaginitis with dyspareunia and post-coital bleeding. Four patients developed a greenish, somewhat bloody vaginal discharge. Vaginal examination was difficult to accomplish because of pain and bleeding. When inspection was successful, it showed either a diffuse, erosive vaginitis or a slightly less erosive, red, desquamative vaginitis with indications of a fine white reticular network. Cervical involvement was noticed in 2 women. Even in the quiescent stages, the vaginal mucosa was atrophic and fragile. Twelve patients also showed a desquamative or erosive gingivitis with discomfort and easy bleeding. The gingival surfaces were diffusely red and were usually eroded. In 5 patients, there were also typical white, reticular lesions on the buccal mucosa. The labial aspect of the maxillary gingival surface was the single area most commonly involved. Biopsy specimens taken from the white, reticulated border generally showed the typical histology of LP, whereas biopsy specimens taken from the eroded surface more often showed only a non-specific inflammatory reaction. Direct immunofluorescent examination in these patients did not show significant deposition of immuno-reactants. It is important that all patients had lesions on the vulvar, vaginal, and gingival mucosal surfaces, but often, at a single point in time, only one or two of the three sites were involved. The time interval between involvement of the different sites may show a variation of several years. Seven patients had concomitant involvement at the three sites. Vulvo-vaginitis preceded oral involvement (by up to 7 years) in 7 patients. In 5 patients, oral lesions preceded symptomatic genital disease by 2 to 9 years. Three patients also developed typical CLP. Treatment in all patients consisted of topically applied corticosteroids. However, only 5 patients showed satisfactory improvement. Ten patients were treated with systemic prednisone at a dose of at least 0.5 mg/kg/day. The initial response was excellent and required at least three weeks of therapy. Unfortunately, when the dose was tapered, relapse generally occurred at a dose of 10 mg/day. Systemic retinoids, griseofulvin and dapsone were administered in a few patients but generally had disappointing results.³⁶⁴

In 1994, Eisen reported 22 patients with VVGS and reported that therapy with potent topical corticosteroids was generally beneficial.³⁷⁰

In 1999, the same author reported that from the 399 women with OLP, 77 (19%) women also had vulvar and vaginal LP.²⁴ The erosive form of the disease was the predominant type in the genital region, although asymptomatic reticular lesions were identified in 25% of the patients. The patients with severe oral lesions commonly displayed mild genital disease, whereas the patients with asymptomatic gingival disease frequently suffered from severe erosive vulvovaginal disease. It is important to state that in many patients whose genital symptoms had been evaluated by other physicians, the condition was commonly misdiagnosed or undiagnosed. Generally, in patients with OLP, 6% will manifest simultaneous involvement at three or more sites, thus highlighting the importance of thorough examination and the need for a multi-disciplinary

Table VII. A review of the clinical characteristics of the patients with the vulvovaginal-gingival syndrome (VVGS) (Ramer et al (2003)).³⁹⁷

	Investigated number of patients	Patients
Mean age	113	52 years
Age range	113	29-79 years
Dyspareunia	132	88 (67%)
Burning/ pruritus/ pain	132	105 (80%)
Vaginal discharge	132	62 (47%)
Desquamation or erosions	132	95 (72%)
Vulvar itching	113	64 (57%)
Premenopausal	27	14 (52%)
Postmenopausal	27	13 (48%)
CLP	55	7 (13%)
Initial presentation of:		
Oral lesions	132	33 (25%)
Genital lesions	132	34 (26%)
Both oral/genital lesions	132	65 (49%)

approach in these patients. Lichen planus is the most common cause of desquamative vulvitis associated with desquamative vaginitis.²⁴

In 2003, Ramer et al reviewed 127 cases of the VVGS found in the literature and added 5 new ones.³⁹⁷ The clinical characteristics of those patients are shown in Table VII. The onset of the erosive or ulcerative oral lesions may precede or follow the onset of vulvovaginal lesions by months or even years. It is possible that the initial diagnosis of OLP or genital LP has to be revised into VVGS after a while, because other mucosal membranes are consecutively affected. Generally, histopathological and immunopathological examinations in patients with VVGS show the typical features of mucosal LP. Complications of progressive disease in genital LP or VVGS are vulvar scarring, vaginal adhesions and synechiae that prohibit sexual intercourse. Gynecological surgery (adhesiolysis) may be necessary in these cases. Nevertheless, adhesions frequently recur after treatment.³⁹⁷ Insertion of intravaginal tampons may prevent new adhesions.^{398,401}

Peno-gingival syndrome

In 1993, Cribier et al reported the male equivalent of the VVGS.³⁹⁹ In 1999, Eisen reported in a study of 584 patients with OLP that 8 patients also had genital LP.²⁴ The mean age of onset of these 8 patients was 40 years. There was a simultaneous appearance of the mucosal lesions in all patients. Two patients had symptomatic, erosive genital lesions, 5 patients had asymptomatic hyper-

keratotic lesions (2 patients annular, 2 patients papular and 1 patient plaque form), and 1 patient had an asymptomatic, erythematous form. The glans penis was the most common site of involvement. Two patients also had lesions on the penile shaft and one patient also had lesions on the scrotum. Unlike female patients with VVGS, only 4 of the 8 males with oral and genital disease had gingival lesions.²⁴ In our opinion, the term “oro-genital LP” also seems to be more appropriate in such cases.

Genital lichen planus

Females

The clinical signs and symptoms of genital LP in females were described in the VVGS.^{364,394,397} Generally, genital LP may occur solitary or within the VVGS.^{24,400} The exact percentage of involvement of the female genitalia in CLP is unknown.^{26,144} It seems to be likely that (especially asymptomatic) genital lesions in women with LP are unnoticed or misdiagnosed.²⁴ Genital LP may be even more severe and recalcitrant to treatment compared with OLP. Treatment modalities with changing results consist of topical agents such as corticosteroids (class III or IV), lidocaine gels, antifungal agents, retinoids, estrogens, and cyclosporin, as well as systemic agents such as corticosteroids, retinoids, antifungal agents, hydroxychloroquine, dapsone and cyclosporin.^{397,400} In 2004, Byrd et al reported a significant improvement of clinical signs and symptoms with topical tacrolimus 0.1% ointment twice daily within 3 months (mean 4.2 weeks) in 15 (94%) of 16 patients with symptomatic vulvar LP, recalcitrant to many other treatments. Six patients (38%) reported mild adverse effects, including irritation, burning and tingling. These adverse effects resolved with continued medication. Genital LP returned in 10 (83%) of the 12 patients within 6 months after discontinuation of therapy over a period of several weeks, but in 6 patients the lesions were less severe than the lesions before treatment. They concluded that topical tacrolimus therapy effectively controlled symptoms and improved lesions in all but 1 patient. The effect may be temporary requiring continued use of tacrolimus, which appeared to be safe and effective in controlling the disease.⁴⁰⁰

There are some reports on the malignant transformation of genital LP into a squamous cell carcinoma, which particularly underlines the clinical importance of a thorough investigation with adequate histopathological examination and a multi-disciplinary approach.⁴⁰²⁻⁴⁰⁴ The differential diagnosis includes atrophic vulvovaginitis, desquamative vulvovaginitis, lichen sclerosus (et atrophicus), and localized bullous auto-immune diseases such as localized bullous pemphigoid and cicatricial pemphigoid.^{405,406} In 1994, Marren et al reported the association of vulvar lichen sclerosus and OLP in older women.²⁴⁵

Males

It has been reported that the genitalia in males (particularly the glans penis) were involved in 25% in the classical form of CLP.²⁶ Involvement of the genitalia in men in the classical form of CLP has to be considered as a site of predilection.^{22,30,266} Isolated genital LP does occur in men, especially the annular variant.²⁶⁶ Malignant transformation of LP of the penis into a squamous cell carcinoma was rarely reported.^{407,408}

Other sites of mucosal lichen planus

Lichen planus has also been described in the anal region, the conjunctivae, the larynx, the lip, the nose, the esophagus, the stomach and in the urinary bladder (Table VI).^{26,65}

Anal region

Lichen planus may affect the anal and the perianal region and may produce intense localized pruritus.⁴⁰⁹

Conjunctivae

Conjunctival LP was recognized as a rare cause of cicatrizing conjunctivitis and in most cases these patients also had concomitant OLP.²⁴ The institution of prompt treatment controlled inflammation and prevented cicatrization.^{410,411}

Lips

Formally, the vermilion border of the lip does not belong to the oral mucous membrane, but in the literature the disorders of the lips are often included in the section on oral diseases. Moreover, the vermilion border of the lips generally shows LP lesions which resemble the clinical features of the different subtypes of OLP (Figure 6).⁴¹² Generally, the lower lip is more affected than the upper lip. However, isolated LP of the lips is rarely seen. The reticular variant is most commonly seen, but the other variants also occur. The differential diagnosis includes chronic discoid lupus erythematosus, leukoplakia, actinic cheilitis, bullous auto-immune diseases, infective cheilitis, plasma-cell cheilitis and squamous cell carcinoma. Histopathological and/or immunopathological examination is often necessary to establish the diagnosis LP on the lips.^{413,414}

Squamous cell carcinoma is the most common malignancy affecting the vermilion border and occurs on the lower lip in 89%, on the upper lip in 3%, and at the commissures in 8% of the patients (Figure 18). Risk factors for this malignancy

are exposure to sunlight (actinic damage), tobacco smoking, low social class, poor nutrition, poor dentition, and immune suppression. Malignant transformation of LP of the vermilion border of the (lower) lip both into a squamous cell carcinoma, and rarely into a verrucous carcinoma was reported.^{412,415,416} It is difficult to establish whether there is a synergistic premalignant effect in case of exposure to external carcinogens and the persistence of LP on the lips, which may act as an intrinsic risk factor.

Esophagus

In 1990, Dickens et al reported in a study of 19 patients with LP that 5 patients also had esophageal LP diagnosed via endoscopy. Four of the 5 patients were asymptomatic yet they displayed subtle papular lesions typical of LP. One patient with dysphagia showed erosive LP. Four of the 5 patients also had OLP.⁴¹⁷

In 1997, Eisen reported in a study of 584 patients with OLP that 4 patients had dysphagia and esophageal LP was discovered via endoscopy.²⁴ The incidence of esophageal disease was probably higher, given the fact that only symptomatic patients were screened and only erosive esophageal LP was detected. Endoscopy is probably not performed in patients with asymptomatic hyperkeratotic (reticular) esophageal LP and therefore it is not detected. A thorough history of symptoms like dysphagia should be obtained in patients with OLP.²⁴ Although malignant transformation has not yet been reported, untreated erosive esophageal LP may result in chronic pain, dysphagia, strictures and stenosis.⁴¹⁸

Further discussion of LP of the larynx, the nose, the stomach and the urinary bladder is beyond the scope of this thesis.

Clinical aspects of cutaneous lichen planus

Cutaneous lichen planus (CLP) is a benign, self-limiting inflammatory dermatosis characterized by a combination of clinical and histopathological features that most commonly affects middle-aged adults.²⁶⁶ It has a worldwide distribution with no overt racial predisposition and the estimated prevalence is about 0.5% in the European and in the North American populations. However, there is a considerable variation in its incidence in several countries.⁴¹⁹ In Nigeria, CLP is one of the most common dermatological diseases.⁴²⁰ Outbreaks of CLP occur throughout the year, although in one study it was suggested that an unexplained seasonal influence existed, showing an increased incidence between January and July.⁴²¹

The classical form of cutaneous lichen planus

Cutaneous lichen planus is generally an idiopathic dermatosis with an insidious onset and its classical form commonly lasts 8 to 12 months (Table VI). The

lesions clear without any treatment within 18 months in 85% of the patients. However, CLP may even persist indefinitely.^{26,266} Current concepts on pathogenesis include immunological, genetic and environmental factors.^{11,30} The **classical form of CLP** comprises pruritic, faintly erythematous to violaceous, shiny, flat-topped papules, which may be polygonal in morphology and are usually symmetrically distributed (Figure 15). Fine white lines known as Wickham's striae may be present on the surface of the lesions. Application of mineral oil on the surface of the lesions to fill air spaces in the keratin makes the striae more easily visible. The lesions may occur anywhere on the body but there appears to be a predilection for the flexor aspects of the wrists and the forearms, the ankles, the lumbar area, the (male) genitals and the shins. The face and the scalp are usually spared in classical CLP. The lesions vary in size from less than a millimeter to over a centimeter in diameter and may be scattered or occur in clusters. Scaling may be present in plaques and in lesions of prolonged duration. Linear lesions often appear along scratch marks or in scars (Koebner's phenomenon).^{22,26,266,424} Cutaneous lichen planus may be intensely pruritic. However, physical evidence of scratching, such as excoriations, secondary infections and blood crusts, is infrequently seen, in contrast with many other itchy dermatological diseases such as atopic dermatitis, allergic contact dermatitis and prurigo nodularis.²⁶⁶ Twenty percent of the patients with CLP may be asymptomatic.⁴¹⁹ The nails (particularly of the fingers) are also involved in about 10% of the cases of CLP, but this is usually a minor feature of the disease.²⁶

The female-to-male ratio in CLP is probably 3:2. The ages of highest prevalence of CLP differ significantly in men and in women and is about 30 years in men and about 50 years in women. There is oral involvement in about 50% of the patients with classical CLP, with a significant variation in several studies, probably depending on symptomatology and medical specialty.^{22,266} Lichen planus in childhood is rare and only 2-3% of all patients with LP are pediatric patients.^{11,422}

The differential diagnosis may include psoriasis guttata, secondary syphilis, lichen nitidus, verrucae planae, (lichenoid) drug eruption, pityriasis lichenoides chronica, eczematous eruptions with lichenification, prurigo, (papular) lichen amyloidosis and Darier's disease.^{144,419}

Other remarks on the terms lichen, lichenoid and lichenification

Many diseases have the word "lichen" in common, but do not belong to the spectrum of LP.^{26,144} However, some of these disorders may be included in the differential diagnosis of a variant of LP (Table VI). In this thesis only an enumeration is given: lichen amyloidosis, lichen aureus (lichen purpuricus), lichen

myxoedematosus (lichen fibromucinodosis), lichen nitidus, lichen nuchae (a variant of lichen simplex), lichen sclerosus et atrophicus, lichen scrofulosum, lichen simplex (chronicus), lichen spinulosus, lichen striatus, lichen verrucosus et reticularis (Nékam's disease, keratosis lichenoides chronica, lichen ruber moniliformis).

The term "lichenoid" may be used by clinicians to describe a flat-topped, shiny, papular eruption resembling LP, or by histopathologists to describe a type of tissue reaction principally consisting of a basal cell liquefaction degeneration and a band-like inflammatory infiltrate in the papillary dermis or in the lamina propria ("interface dermatitis"), consisting predominantly of mononuclear cells. Colloid bodies may be present. This pattern may be seen in a wide variety of conditions: LP, lupus erythematosus, lichen sclerosus, poikilodermas, several cutaneous drug reactions.^{266,419}

The word "lichenoid" is also used in: pityriasis lichenoides chronica, pityriasis lichenoides et varioliformis acuta (PLEVA, M. Mucha-Habermann), pigmented purpuric lichenoid dermatosis of Gougerot and Blum and exudative discoid and lichenoid dermatitis (Sulzberger-Garbe syndrome).

Lichenification is a pattern of cutaneous response to repeated rubbing or scratching. It is characterized histologically by acanthosis and hyperkeratosis, and clinically by a thickened appearance of the skin, with accentuation of the surface markings so that the affected skin surface resembles "tree bark". It is common in patients with atopic dermatitis, but may also occur in other "irritant" dermatoses.⁴²³

Other clinical variants of cutaneous lichen planus (Table VI)

Actinic LP (LP (sub-)tropicus) mostly affects young individuals from the Middle East, East Africa or India. It begins during spring or summer and mainly involves sun-exposed skin particularly of the face and of the dorsum of the hands and the arms. The lesions are characterized by well-defined nummular patches, which have a deeply hyperpigmented center surrounded by a strikingly hypopigmented zone. Sunlight appears to be the precipitating factor and lesions have been provoked experimentally with UVB. Actinic LP may mimic melasma and lupus erythematosus.²⁶

Acute, eruptive and subacute LP shows many, small and dissiminated lesions with a rapid evolution. This form may mimic a lichenoid drug eruption and lichen nitidus.^{266,424}

Annular LP shows a few, rather large annular lesions. In males, these lesions are typically found on the penis and are more common in negroid patients. This form may resemble psoriasis, granuloma annulare and sarcoidosis.^{266,419}

Atrophic LP has only a few lesions and may be the result of faded annular or hypertrophic lesions. It may mimic lichen sclerosus et atrophicus.²⁶⁶

Bullous LP (or vesiculo-bullous LP) is uncommon and refers to the development of vesicles and bullae on pre-existing lesions of CLP. Histopathological examination shows findings compatible with those of typical CLP and a sub-epidermal bulla with a negative direct immunofluorescence. It may resemble several bullous auto-immune diseases.^{26,424}

Lichen planus erythematosus is rare. Deep red, asymptomatic papules blanching with pressure appear on the trunk and extremities. Histopathological findings are consistent with CLP.²⁶

Exfoliative LP resembles a general exfoliative dermatitis, which may be associated with erythroderma or toxic epidermal necrolysis.⁴²⁴

Eyelid LP shows isolated lesions on the skin of the eyelids which may be typical for CLP or may mimic a brown retiform-like eruption resembling erythema ab igne.⁴²⁴

Familial LP is uncommon and occurs in individuals of the same family. It has a longer duration and more common relapses than the classical form of CLP. Familial LP commonly shows disseminated skin lesions with frequent involvement of the oral mucosa. Familial LP occurs at a younger age particularly in the third decade, but may occur rather frequently under the age of 20 years.^{11,266} There may be an increased incidence of transformation into squamous cell carcinoma in children with familial LP.⁴²²

Guttate LP shows widely scattered, 1-2 mm lesions without the tendency of forming plaques. Guttate LP has a relatively good prognosis.²⁶⁶

Hypertrophic LP is characterized by thickened, hyperkeratotic, intensely pruritic lesions on the ventral parts of the lower limbs and the ankles and the lesions may persist for many years. It may resemble lichen simplex chronicus, lichen amyloidosis and lichen myxoedematosus.^{26,419} The occurrence of squamous cell carcinomas in hypertrophic LP has been reported.⁴²⁵

Lichen planus inversa was described, with violaceous papules in the axillae, groin and inframammary areas.²⁶

The disease “**lichen invisible**” introduced by H. Gougerot in 1926 would only show subjective symptoms of LP without any clinical sign.⁴²⁶ In the oral cavity, it is probably similar to the Burning Mouth Syndrome (BMS).⁹⁶ In such cases, the term “lichen invisible” should be avoided in our opinion. In 1966, Cram et al described another type of “LP invisible”. Premonitory pruritus is found, but the lesions are not apparent to the naked eye, and may be visualized by illumination with a Wood’s lamp. Histopathological examination shows features compatible with those of CLP.²⁰

Linear lesions seen as a Koebner’s phenomenon are frequently found in many variants of LP.²⁶ However, **linear LP** is rare, although rather more common in childhood. This variant shows isolated, long, narrow linear lesions which may extend the whole length of the limb and may occur in Blaschko’s lines (Figure 17). Linear LP has more often been described on one side of the body and may resemble lichen striatus, linear epidermal nevi, inflammatory linear verrucous

epidermal nevus (ILVEN) and linear forms of psoriasis.⁴²² In 2004, Agaki et al reported three patients with a **linear LP pigmentosus**.⁴²⁷

In **nail LP**, the fingernails are more frequently affected than the toenails and initially only two or three fingernails are involved before spreading to the remaining digits. The most common change is a slight thinning of the nail plate, which may be observed to emerge from beneath the cuticle and extend forward with the growing nail. The nails may show longitudinal ridging, linear depressions and grooving, splitting (onychoschizia), shedding (onychomadesis), longitudinal striation (onychorrhexis), absence (anonychia), subungual hyperkeratosis and a pterygium. Pterygium is formed by an adhesion between the dorsal nail fold and the nail bed with a partial destruction of the matrix resulting in the destruction of the nail. Lichen planus of the nail bed may produce longitudinal melanonychia, hyperpigmentation, subungual hyperkeratosis or onycholysis and may mimic psoriasis unguium. However, nail abnormalities in LP are neither specific nor pathognomic.^{24,26,266}

Lichen planus on the palms and the soles lacks the characteristic shape and color of most lesions of CLP elsewhere. The firm, yellow lesions are papular or nodular and may mimic hyperkeratotic eczema, atypical psoriasis, warts, callosity and keratosis palmoplantaris areata.^{266,419}

Perforating LP has been reported and show papules with crustae. Histopathological examination shows the classical features of CLP in addition to areas of perforation in the epidermis with numerous hyaline bodies present at the base of the perforation.²⁶

Lichen planus pigmentosus is a pigmentary disorder, which may be associated with the typical papular CLP lesions seen in India and in the Middle East. The macular hyperpigmentation mainly involves the face and the upper limbs. It may mimic erythema dyschromicum perstans.⁴²²

Lichen planopilaris or **follicular LP** presents with follicular involvement of hair-bearing areas. It is more common in women and there are follicular spinous lesions and often classical LP lesions elsewhere on the body. It may occur on the scalp and is likely to produce a cicatricial alopecia because of the deep inflammatory infiltrate around the hair follicles. It should be distinguished from chronic discoid lupus erythematosus, folliculitis decalvans, tufted hair folliculitis, perifolliculitis capitis abscedens et suffodiens and the final stage of pseudopelade of Brocq.^{24,266} There are obviously overlapping clinical and histopathological aspects between lichen planopilaris and the so called Graham-Little-Piccardi-Lassueur syndrome.^{144,428}

In **solitary LP**, there is only one lichenoid lesion which looks like a (pre)malignant epidermal tumor and will frequently be treated by excision. However, histopathological examination shows typical features of CLP.⁴²⁹

Lichen planus tumidus is a variant of follicular LP with a deep inflammatory infiltrate with clusters of milium cysts and comedones.⁴³⁰

Ulcerative LP is very rare. Large and painful ulcerations mostly occur on the sole of one or both feet. The lesions heal with great difficulty.²⁶

In **unilateral LP** only a part of one side of the body is involved.⁴³¹

In **zosteriform LP**, the lesions follow a segmental distribution like those in herpes zoster.²⁶⁶

Histopathology of cutaneous lichen planus

Histopathological features of the classical form of CLP are characteristic and show an irregularly thickened granular layer with orthokeratotic hyperkeratosis. Parakeratosis is rarely found. Irregular acanthosis is usually present, with rete ridges that form a “sawtooth” pattern. The focal increase in thickness of the granular layer and infiltrate corresponds to the presence of the Wickham’s striae.²⁶ A dense, band-like inflammatory infiltrate in the papillary dermis is an important feature and may obliterate the dermo-epidermal interface. The infiltrate consists almost entirely of lymphocytes intermingled with a few histiocytes and melanophages.^{266,422} There may be a vacuolar (“hydropic”) degeneration of the basal layer. Eosinophilic-staining Civatte’s bodies (hyaline bodies, cytooid bodies or colloid bodies) represent degenerated basal epidermal cells, which have probably undergone premature keratinization and have extruded into the papillary dermis.⁴¹⁹ Civatte’s bodies are found in 37-100% of the biopsy specimens of CLP and are considered to be among the earliest histopathological changes, but are not specific for LP.^{22,30} If the basal membrane zone becomes vacuolated, fluid accumulates and leads to the formation of clefts, known as Max Joseph spaces (or Caspary-Joseph spaces), which may be seen in up to about 17% of the specimens.^{144,432} Melanocytes are considerably decreased in number or even absent. The liberated melanin granules are ingested by dermal macrophages (“melanophages”) in the papillary dermis (Figures 7, 8, 9, 10 and 11).^{26,266} The histological features of the several clinical variants of LP may be less obvious or may show some other characteristics. For example in lichen planopilaris, a perifollicular inflammatory cell infiltrate is seen in early stages, with subsequent destruction of the follicles.²⁶ In LP pigmentosus, there is an increase of deposition of melanin in the basal and malpighian layers.⁴²² Hypertrophic LP usually shows extensive acanthosis.^{26,266}

Treatment

Treatment of CLP is mostly necessary, because it relieves pruritus and induces a remission.²⁶⁶ Treatment depends on the symptoms of LP, the involved variant (Table VI), the extent and the anatomical location of the lesions,

the age of the patient, concomitant disorders and co-medication.^{22,26,294,419} It is important to state that there are no large randomized trials with definite results in the literature examining the efficacy of the various drugs or physical treatments in LP. Many published trials are observational and are not always prospective and the recommendations of the experts are based on their personal experience and not on “evidence-based medicine”.^{294,295} Generally, potent topical (class III or IV) or systemic corticosteroids (prednisolone 20-40 mg once a day) are used in the treatment of CLP during 6 to 8 weeks. Intralesional corticosteroids or very potent topical corticosteroids under occlusion are particularly used in hypertrophic LP lesions. Furthermore, systemic retinoids (acitretin 0.5-1.0 mg/kg/day), antihistamines, cyclosporin (3-5 mg/kg/day) and ultraviolet radiation ((bath)PUVA, UVA and UVB) are taken into account. Griseofulvin, antibiotics (penicillins, trimethoprim and metronidazole), dapsone, azathioprine, methotrexate, antimalarial drugs, isoniazid, cyclophosphamide, mycophenolate mofetil, enoxaparin, interferon- α 2b and thalidomide are far less common variants of treatment.^{26,266,294,295,379,382,422} Even skin grafting may be required in persistent ulcerative lesions on the palms or the soles.^{20,294}

Prognosis

When the lesions in CLP have disappeared (with or without treatment), post-inflammatory hyperpigmentation occurs rather frequently and intensely and may persist for several months. Generally, there is a recurrence in about 12 to 20 % of the patients with the classical CLP after initial clearing.^{22,26} The period of healing of the classical variant of CLP with intensive treatment is mostly 1 to 3 months.²⁶⁶ In general, CLP has no increased risk of malignancies of the skin or internal organs. Lichen planus pemphigoides and possibly also vesiculo-bullous LP have been described in association with several forms of internal malignancies.²⁶⁵ Malignant transformation of the involved skin was rarely reported in hypertrophic LP and familial LP.^{266,422}

Overlap syndromes

Lichen planus-lupus erythematosus overlap syndrome

The lichen planus-lupus erythematosus overlap syndrome (LP-LE overlap syndrome) was described by Copeman et al in 1970. In that study, 4 patients showed overlapping clinical and histopathological features of LP and LE.⁴³³ Later, further combinations of CLP and OLP with either chronic discoid LE, subacute cutaneous LE or systemic LE were described.²²⁹ However, some

authors prefer to diagnose LP and LE separately. The lesions are often seen on the hands and the feet. The presence of systemic immunological markers such as ANA titers is also controversial.^{26,266,424} Distinctions between LP and LE include colloid bodies, basement membrane changes and direct immunofluorescence. However, colloid bodies may also be seen in LE, but in LP they tend to be more numerous and are situated deeper, even into the upper area of the reticular dermis. In LP, basement membrane clefts may be due to lysis of keratinocytes, whereas in LE vacuolization forms on either side of this membrane. Direct immunofluorescence shows immunoglobulin and complement deposition in a granular, linear band along the dermo-epidermal junction in LE, whereas in LP these immunoreactants tend to be limited to colloid bodies. The demonstration of the LP-specific antigen in the granular layer by indirect immunofluorescence in LP can also be helpful in distinguishing from LE. Some studies on the basement membrane zones showed that there are possibly several similar steps in the pathogenesis of LP and LE.^{22,26,434}

Lichen planus pemphigoides

Lichen planus pemphigoides shows a combination of clinical features of LP and bullous pemphigoid with subepidermal bullae.^{26,266,435} The bullae may also present on a previously healthy skin in contrast with bullous LP. In contrast with bullous LP, LP pemphigoides also shows linear C3 and IgG deposits at the BMZ, like bullous pemphigoid in direct immunofluorescence. Indirect immunofluorescence may also be positive in LP pemphigoides.⁴²² Recent immunoblotting data revealed a 180-KDa antigen and a 200-KDa antigen similar to that found in bullous pemphigoid. These data indicated the coexistence of two separate diseases (LP and bullous pemphigoid) in the same patient.^{22,419} However, some authors take the view that the antigen in LP pemphigoides is different from the antigen in bullous pemphigoid. The mean age of patients with LP pemphigoides is lower and the course tends to be less severe than in classical bullous pemphigoid.^{26,144} Lichen planus pemphigoides was reported in association with several forms of internal malignancies including stomach cancer, lymphosarcoma, reticulum cell carcinoma, craniopharyngioma, and neuroblastoma.²⁶

Lichenoid reactions

Lichenoid reactions may resemble LP in many respects and may be induced by contact, inhalation or ingestion of a large number of different drugs and chemicals. Lichenoid reactions may clinically resemble the classical form of CLP.²⁶

Graft-versus-host disease

Graft-versus-host disease (GVHD) is important because skin manifestations are prominent and LP can be closely simulated both clinically and histologically. Furthermore, cutaneous GVHD provides an excellent biological model for the study of interactions between lymphocytes and the skin and can also provide a clue in the pathogenesis of LP and lichenoid eruptions.^{266,422,438} Bone-marrow transplantation is a well-accepted treatment for a variety of severe hematological disorders, including acute leukemias, aplastic anemia, certain immunodeficiency disorders and some inborn errors of metabolism. A major obstacle to successful transplantation is the threat of GVHD.^{26,419} Graft-versus-host disease occurs when lymphoid cells from an immunocompetent donor are introduced into a histo-incompatible recipient who is incapable of rejecting them. Although GVHD usually occurs in patients undergoing allogeneic bone-marrow transplantation, it may also occur in immunodeficient children after maternal-fetal cell transfer and surprisingly also in otherwise healthy patients receiving blood transfusions after heart surgery. Rarely, GVHD can develop “spontaneously” during a disseminated carcinoma.^{22,30,439}

The main targets of GVHD in man are the skin, the gastrointestinal tract and the liver. The severity of the reaction, clinically and histologically, varies from mild to severe (grades 1 to 4). There are two main forms of GVHD namely the acute form, which develops between 1 week and 3 months after transplantation and the chronic form, which develops after 3 months. The chronic form is not preceded by the acute phase in about 15% of the cases.^{266,436}

The oral manifestations of acute GVHD consist of painful mucosal ulceration, cheilitis, and the presence of lichenoid striae or plaques. Small, white lesions affect the buccal and lingual mucosa early on, but disappear after 2 weeks. Erythema and ulceration are most pronounced at 7 to 11 days and may be associated with obvious infection.^{275,437} Candidosis or herpes simplex stomatitis (occasionally herpes zoster) is common and there may also be oral purpura, especially in adults.^{438,439} The oral lesions in chronic GVHD occur together with skin lesions, and include generalized mucosal erythema, lichenoid lesions, mainly in the buccal mucosa, and xerostomia. Xerostomia is most significant in the first 2 weeks after transplantation and is a consequence of drug treatment, irradiation and/or GVHD.^{275,440} Lip biopsy is useful in the diagnosis of chronic GVHD and should include both the mucosa and the underlying minor salivary glands. Histology shows changes similar to those seen in Sjögren's syndrome.⁴⁴¹

The severity of the cutaneous eruption often parallels that of GVHD. In acute GVHD, the earliest cutaneous features include a malar flush, erythema of the palms or soles and a generalized morbilliform rash. Occasionally, erythematous to violaceous follicular papules occur and rarely a toxic epidermal necrolysis

or a severe exfoliative erythroderma occur.²⁶⁶ Characteristic histopathological features are present in the patients with acute GVHD. The epidermis shows focal vacuolar alteration of the basal layer with a few lymphoid cells at the dermo-epidermal interface. The numbers of the mononuclear inflammatory cells correlate positively with the severity of the disease. IgM deposits may occur at the dermo-epidermal junction.⁴⁴²

Chronic GVHD develops in 10% of all patients undergoing allogeneic bone-marrow transplantation and even in 30% of all long-term survivors (over 150 days). The cutaneous changes may be localized or generalized. The localized forms may be linear or whorled along Blaschko's lines. The initial eruption is usually lichenoid and may involve the oral cavity, the skin, the nails and the hair. Clinically and histologically, it closely resembles "idiopathic" LP. However, hyper- and hypopigmentation are often more prominent features. Chronic GVHD may also resemble Sjögren's syndrome, LE and dermatomyositis. A very serious disorder is a severe poikiloderma with widespread cutaneous sclerosis, contractions, malabsorption, wasting, alopecia and areas of ulceration.^{26,30,438} There is an increased frequency of HLA-A1, HLA-B1 and HLA-B2 in chronic GVHD with scleroderma-like complications which indicates that a specific genetic predisposition is important.²⁶⁶ A malignant transformation into a squamous cell carcinoma has been reported in an indolent ulcer in chronic GVHD.⁴⁴³ In the early phase of chronic GVHD, histopathological examination may resemble LP. However, the infiltrate at the dermo-epidermal interface is often less dense than that in LP and may contain eosinophils. It was observed that the number of CD3+ infiltrating T-cells was lower than that in OLP. The final stages of chronic GVHD show an atrophy of the epidermis with gross fibrosis of the dermis, skin appendages or even subcutis.^{30,439,442} The mortality in chronic GVHD is about 10%.²⁶⁶ Epithelial damage in GVHD appears to be mediated particularly by cytotoxic T-cells in which Langerhans cells are selectively lost. Various lymphokines such as interferons and IL-2 may be released by T-cells which were sensitized via interaction with host cells and this process will activate both donor and host mononuclear cells.⁴⁴⁴ The future success of bone-marrow transplantation largely depends on the extent to which GVHD can be prevented. The mortality of GVHD grades 2 to 4 exceeds 75%. The threat of GVHD increases when the donor and recipient genotypes are not identical. Prospective CD31 typing may reduce the risk of acute GVHD. Transplantation of bone-marrow that has been depleted of T-cells by the use of a cocktail of anti-T-cell monoclonal antibodies has made a major contribution in the prevention of GVHD. The most effective combinations of systemic steroids and immunosuppressive agents have yet to be established. Cyclosporin has also failed to reduce the incidence and the severity of GVHD. Phototherapy (UVB) and photochemotherapy (PUVA) are also used in the treatment of GVHD.^{26,30,266,438}

Lichenoid contact dermatitis

A lichenoid contact dermatitis has been described after exposure to nickel⁴⁴⁵, mercury⁴⁴⁶, gold¹¹⁴, aminoglycoside antibiotics⁴⁴⁷, methacrylic acid esters⁴⁴⁸, epoxy resin⁴⁴⁹ and color film developing chemicals based on paraphenylenediamine⁴⁵⁰. The “closed” patch test is the most convenient method for testing lichenoid contact dermatitis in conformation with allergic contact dermatitis. However, the typical lichenoid features often occur after the regular (last) reading of the patch tests after 72 hours.^{114,451}

The active ingredients in the color film developer responsible for the reaction are certain substituted paraphenylenediamine (PPDA) compounds. The following types of reaction are observed: an acute or subacute eczematous or papular dermatitis and an (subacute) lichenoid dermatitis both clinically and histologically identical to CLP. These reactions may occur individually or may evolve into each other. However, it is not quite clear why exposure to color film developers induces an eczematous reaction in some patients and a lichenoid dermatitis in others. There are gradations both in clinical and histological aspects between the spectrum of typical eczematous dermatitis and typical CLP. The fact that the condition begins on areas exposed to the chemical strongly indicates that direct contact with the developer is the cause of the eruption, but ingestion or inhalation cannot be ruled out entirely. Moreover, oral lichenoid lesions affecting the buccal mucosa or the tongue occasionally appear in patients with a lichenoid contact dermatitis to color film developers. Sensitization in exposed workers is fairly high and may take 1 month to 3 years to develop. The skin reaction subsides after several weeks, leaving marked hyperpigmentation. Patch test reactions are usually positive to PPDA and are eczematous in nature but may become lichenoid.^{26,266,451,452} A lichenoid contact dermatitis associated with PPDA itself (in hair dyes) has been reported, but is not common.⁴⁵³ Moreover, a lichenoid pigmented contact dermatitis from isopropyl-PPDA (IPPD) has been reported.⁴⁵⁴ Other allergens are diethylparaphenylenediamine (CD2) and amino-4-N-ethyl-N-methane-sulfon-aminoethyl-m-toluidine (CD3).^{451,455} A lichenoid dermatitis has been described in the parts of tattoos in case of a coexisting mercury hypersensitivity to the injected red dye, indicating a lichenoid reaction induced by delayed-type cellular hypersensitivity. The reaction may eventually subside spontaneously, but the risk of a generalized eruption is high. It is possible that there is an accompanying OLP in these patients in case of contact with dental amalgam fillings.^{446,456} A photo-contact lichenoid eruption has been occurred after application of musk ambrette.⁴⁵⁷

Cutaneous lichenoid drug eruptions

A cutaneous lichenoid drug eruption (cutaneous LDE) generally shows a less typical distribution and more frequently a photodistribution of the clini-

cal lesions with more polymorphism than the classical form of CLP.^{266,419} Eczematization, hypertrophy, unusual pigmentation, scaling (sometimes more psoriasiform), and intense post-inflammatory hyperpigmentation are common.⁴⁵⁸ This hyperpigmentation regresses very slowly and may even be permanent.⁴⁵⁹ Alopecia may be profound and unrelenting. Rarely, atrophy of the skin may occur with anhidrosis of the affected areas.^{458,459} Concomitant oral involvement is less common in cutaneous LDE than in CLP.⁴⁶⁰ Many Allied troops developed a cutaneous LDE (called "New Guinea LP") after receiving quinacrine as malaria prophylaxis while serving in the South Pacific during World War II. Follicular involvement frequently ensued, leading to alopecia. The lesions commonly start some months after administration of the drug.⁴⁶¹ Histopathological features more indicative of a cutaneous LDE than of CLP include the following: focal parakeratosis, focal interruption of the granular layer, colloid bodies situated higher in the granular and cornified layers, presence of a few eosinophils, exocytosis of lymphoid cells into the epidermis and a deeper perivascular infiltrate.⁴⁶² Moreover, plasma eosinophilia occurs more frequently in cutaneous LDE than in CLP.⁴⁶³ Unfortunately, cutaneous LDE may sometimes be difficult to distinguish from CLP both on clinical and histopathological grounds.^{26,266} Watanabe et al evaluated cutaneous LDE using direct immunofluorescence of the lesions and noted no significant differences from CLP.⁴⁶⁴ In 1974, Van Joost reported the presence of circulating antibodies reactive with basal cells of the skin in drug eruptions.⁴⁷¹ This was shown to be a useful corroborative test of LDE, but its full implications are not yet understood.

The list of drugs that may produce a cutaneous LDE is extensive and continues to increase steadily (Table VIII). Several groups of drugs may be involved: analgesics, antibiotics, antimalarials, antirheumatics, cardiovascular drugs, oral antidiabetics, psychotropic and neurological agents.^{465,466} The resolution of the lesions after withdrawal of the specific drug can take several months.²⁶⁶ Therefore, it is often difficult to determine if a specific drug is responsible for the lichenoid cutaneous reaction, particularly when a patient uses several different drugs at the same time.

Photosensitive cutaneous LDEs particularly occur in patients treated with tetracyclines, thiazide diuretics, anti-malarials, and diltiazem. Photosensitive cutaneous LDEs occur more commonly in patients with a dark skin type (Type VI, Fitzpatrick) or in patients with advanced HIV infection.⁴⁶⁷

Oral lichenoid drug eruptions

Generally, the reports on oral lichenoid drug eruptions (oral LDEs) are considerably fewer than those on cutaneous LDEs and fewer drugs have been reported as causing oral LDEs rather than cutaneous LDEs. However, data

Table VIII. List of drugs associated with cutaneous and/or oral lichenoid eruptions (LDEs).^{46,458-460,466,468-470}

Acebutolol		Fluribiprofen	
Acetazolamide		Furosemide	+ oral
Acetylsalicylic acid		Gold (salts)	+ oral
Aciclovir		Griseofulvin	+ oral
Allopurinol	oral	Guanethidine	oral
Aminophenazone	+ oral	Hepatitis B vaccine	
Amiphenazole	+ oral	Hydralazine	+ oral
Arsenic		Hydrochlorothiazide	+ oral
Atenolol	+ oral	Hydroxyquinidine	
BCG vaccine		Hydroxyurea [**]	
Benoxaprofen		Ibuprofen	+ oral
Benzylhydrochlorothiazide	+ oral	Indomethacin	+ oral
Bismuth	+ oral	Interferons	
Bleomycine	oral	Isoniazide (INH)	+ oral
Captopril	+ oral	Ketoconazole	+ oral
Carbamazepine	+ oral	Labetalol	+ oral
Chlordiazepoxide	oral	Levomepromazine	
Chlorpromazine	oral	Levamisole	oral
Chlorprotixene	oral	Levodopa	+ oral
Chloralhydrate	oral	Lithium	+ oral
(hydroxy)Chloroquine	+ oral	Lorazepam	oral
Chlorothiazide		Mercaptopropionylglycine	
Chlorpropamide	+ oral	Mesalazine	+ oral
Cholera vaccine		Methenamine	
Cinnarizine		Methycran	
Clofibrate	oral	Methyldopa (alpha)	+ oral
Colchicine		Methylthiouracil	oral
Copyrimedoxine	oral	Metoprolol	+ oral
Cotrimoxazole	+ oral	Metopromazine	+ oral
Cyanamide	oral	Naproxen	+ oral
Dapsone	+ oral	Nifedipine	oral
Demeclocycline [*]		Nitrofurantoin	oral
Diazoxide	+ oral	Oral contraceptive	oral
Diffunisal		Oxprenolol	+ oral
Diltiazem		Para-amino salicylic acid	+ oral
Doxycycline		Penicillamine	+ oral
Enalapril	+ oral	Penicillins	+ oral
Ethambutol	+ oral	Phenothiazine	oral
Fenbufen		Phenylbutazone	+ oral
Fenclofenac	oral		
Flunarizine	+ oral		

Phenytoin	+ oral	Spironolactone	+ oral
Pindolol	+ oral	Streptomycin	+ oral
Piroxicam		Sulindac	
Practolol	+ oral	Sulphamethoxazole	oral
Prazosine	+ oral	Sulphasalazine	+ oral
Primidon	oral	Sulphonylureas	
Probenecid		Temazepam	+ oral
Procainamide	oral	Testosterone	
Propranolol	+ oral	Tetracyclines	+ oral
Propylthiouracil	oral	Thiacetazone	
Pyrimethamine	+ oral	Tick-borne	
Pyrithioxine		meningoencephalitis vaccine	
Pyritinol	+ oral	Tiopronine	
Quinacrine (Mepacrine)	+ oral	Tolamulol	
Quinidine	+ oral	Tolazamide	+ oral
Quinine	+ oral	Tolbutamide	+ oral
Radiocontrast media (iodine)	+ oral	Trihexyphenidyl	
Reserpine	oral	Tripolidine	
Simvastatin		Verapamil	
Smallpox vaccine			

Drug: capable of inducing cutaneous lichenoid eruption.

Drug + oral: capable of inducing oral and/or cutaneous lichenoid eruption.

Drug oral: capable of inducing oral lichenoid eruption.

[*]: requires exposure to light.

[**]: induces ulcerative LP on the hands and the feet.

searches on LDEs showed that many drugs may also be involved in oral LDEs (Table VIII).^{157,465,467-469} Nevertheless, many of the reports on oral LDEs are anecdotal, or do not state histological verification, or do not specify the details of the oral cases in reports on both cutaneous LDEs and oral LDEs.^{10,157} Moreover, sometimes it may be impossible to attribute the causative drugs or histological findings to individual cases.¹⁵⁷ Occasionally, oral LDE can be severe and may also involve the esophagus.⁴⁶⁰ Some histopathological features may occur more often in oral LDE than in OLP: a more diffuse and more deeply extending subepithelial infiltrate containing eosinophils, a perivascular infiltrate, parakeratosis, and the presence of colloid bodies higher in the epithelium.^{462,467} However, histopathological and immunological examinations of oral LDE generally show features identical or very similar to those of OLP and such investigations cannot be used reliably to distinguish between oral LDE and OLP.^{462,464,467} Lamey et al suggested that the clinical feature of unilateral-ity occurred more commonly in oral LDE.⁴⁷⁰ Labial LDE has been reported to occur more frequently in patients with HIV infection.⁴⁶⁷

There is as yet no specific test for the diagnosis of oral LDE.¹⁵⁷ Although, resolution and recurrence of oral LDE on withdrawal and re-exposure to the drug is probably diagnostic.^{10,65} However, oral LDE may persist for a long period after the withdrawal of the drug.⁹ This makes the distinction between oral LDE and OLP very difficult in clinical practice.

The exact cause of oral LDE remains unclear. The adulteration of cellular molecules by the offending agents may be operative.²⁶ The etiopathogenic pathways of oral LDE show many striking similarities with those in OLP (Figure 12).^{30,157,266}

References

1. Scalf LA, Fowler JF, Morgan KW et al. Dental metal allergy in patients with oral, cutaneous, and genital lichenoid reactions. *Am J Contact Dermatitis* 2001; 12: 146-50.
2. Yiannias JA, el-Azhary RA, Hand JH et al. Relevant contact sensitivities in patients with the diagnosis of oral lichen planus. *J Am Acad Dermatol* 2000; 42: 177-82.
3. Camisa C, Taylor JS, Bernat JR et al. Contact hypersensitivity to mercury in amalgam restorations may mimic oral lichen planus. *Cutis* 1999; 63: 189-92.
4. Pecegueiro M, Sachse MF, Amaro J et al. Oral lichen planus versus oral lichenoid eruption as a manifestation of contact allergy. *Contact Dermatitis* 1999; 40: 333-4.
5. Dunsche A, Kastel I, Terheyden H et al. Oral lichenoid reactions associated with amalgam. *Br J Dermatol* 2003; 148: 70-6.
6. Scully C, Beyli M, Ferreiro MC et al. Update on oral lichen planus: etiopathogenesis and management. *Crit Rev Oral Biol Med* 1998; 9: 86-122.
7. Vincent SD, Fotos PG, Baker KA et al. Oral lichen planus: the clinical, historical and therapeutic features of 100 cases. *Oral Surg Oral Med Oral Pathol* 1990; 70: 165-71.
8. Silverman S, Gorsky M, Lozada-Nur F. A prospective follow-up study of 570 patients with oral lichen planus. *Oral Surg Oral Med Oral Pathol* 1985; 60: 30-4.
9. Conklin RJ, Blasberg B. Oral lichen planus. *Dermatol Clin* 1987; 5: 663-73.
10. Eisen D. The clinical manifestations and treatment of oral lichen planus. *Dermatol Clin* 2003; 21: 79-89.
11. Alam F, Hamburger J. Oral mucosal lichen planus in children. *Int J Paed Dent* 2001; 11: 209-14.
12. Pindborg JJ, Mehta FS, Daftary DK et al. Prevalence of oral lichen planus among 7639 Indian villagers in Kerala, South India. *Acta Derm Venereol (Stockholm)* 1972; 52: 216-20.
13. Axell T, Rundquist L. Oral lichen planus - a demographic study. *Comm Dent Oral Epidemiol* 1987; 15: 52-6.
14. WHO Collaborating centre for oral precancerous lesions. Definition of leukoplakia and related lesions: an aid to studies on oral precancer. *Oral Surg Oral Med Oral Pathol* 1978; 46: 518-39.
15. Thorn JJ, Holmstrup P, Rindum J et al. Course of the various clinical forms of oral lichen planus. *J Oral Pathol* 1988; 17: 213-8.
16. Andreasen JO. Oral lichen planus. A clinical evaluation of 115 cases. *Oral Surg Oral Med Oral Pathol Oral Radiol Endod* 1968; 61: 373-81.

17. Eisen D. The clinical features, malignant potential, and systemic associations of oral lichen planus: a study of 723 patients. *J Am Acad Dermatol* 2002; 46: 207-14.
18. Mollaoglu N. Oral lichen planus: A review. *Br J Oral Maxillofac Surg* 2000; 38: 370-7.
19. Lozada-Nur F, Miranda C. Oral lichen planus: epidemiology, clinical characteristics and associated diseases. *Semin Cutan Med Surg* 1997; 16 (4): 273-7.
20. Cram DL, Muller SA. Unusual variations of lichen planus. *Mayo Clin Proc* 1966; 41: 677-88.
21. Laskaris G. Skin Diseases. In: *Color Atlas of Oral Diseases*. Edited by Thieme. 3rd edn. 2003; 24: 264-8.
22. Voute ABE. Thesis. Oral lichen planus: a clinical study. University of Amsterdam. Elinkwijk BV, Utrecht 1994.
23. Scully C. The oral cavity. In: *Rook/Wilkinson/Ebling. Textbook of Dermatology*. Champion RH, Burton JL, Burns DA, Breathnach SM. 6th edn. Vol 4. Oxford: Blackwell Science Ltd 1998: 3081-3.
24. Eisen D. The evaluation of cutaneous, genital, scalp, nail, esophageal, and ocular involvement in patients with oral lichen planus. *Oral Surg Oral Med Oral Pathol Oral Radiol Endod* 1999; 88: 431-6.
25. Silverman S, Bahl S. Oral lichen planus update: clinical characteristics, treatment responses, and malignant transformation. *Am J Dent* 1997; 10: 259-63.
26. Boyd AS, Neldner KH. Lichen planus. *J Am Acad Dermatol* 1991; 25: 593-619.
27. Axell T. A preliminary report of prevalence of oral mucosal lesions in a Swedish population. *Comm Dent Oral Epidemiol* 1975; 3: 143-5.
28. Hellgrin L. Prevalence of lichen ruber planus in different geographic areas of Sweden. *Derm Venereol* 1970; 50: 374-80.
29. Walsh LJ, Savage NW, Ishii T et al. Immunopathogenesis of oral lichen planus. *J Oral Pathol Med* 1990; 19: 389-96.
30. Tank B, van Joost Th. Lichen planus and Graft-vs-Host disease. In: *Skin Immune System (SIS). Cutaneous immunology and clinical immunodermatology*. Edited by Bos JD. 2nd edn. CRC Press, Boca Raton, Florida, U.S.A. 1997: 531-41.
31. Clausen J, Kjaergaard J, Bierring F. Ultrastructure of the dermo-epidermal junction in lichen planus. *Acta Derm Venereol (Stockholm)* 1981; 61: 101-6.
32. Walton LJ, Thornhill MH, Farthing PM. VCAM-1 and ICAM-1 are expressed by Langerhans cells, macrophages and endothelial cells in oral lichen planus. *J Oral Pathol Med* 1994; 23: 262-8.
33. Nickoloff BJ, Lewinsohn DM, Butcher EC. Enhanced binding of peripheral blood mononuclear leukocytes to gamma-interferon-treated cultured keratinocytes. *Am J Dermatopathol* 1987; 9: 413-8.
34. Eversole LR. Immunopathogenesis of oral lichen planus and recurrent aphthous stomatitis. *Semin Cutan Med Surg* 1997; 16: 284-94.
35. Porter SR, Kirby A, Olsen I et al. Immunologic aspects of dermal and oral lichen planus: a review. *Oral Surg Oral Med Oral Pathol Oral Radiol Endod* 1997; 83: 358-66.
36. Porter K, Klouda P, Scully C et al. Class I and II antigens in British patients with oral lichen planus. *Oral Surg Oral Med Oral Pathol* 1993; 75: 176-80.
37. Lowe NJ, Cudworth AG, Woodrow JC. HLA antigens in lichen planus. *Br J Dermatol* 1976; 96: 169-71.
38. Lin SC, Sun A. HLA-DR and DQ antigens in Chinese patients with oral lichen planus. *J Oral Pathol Med* 1990; 19: 298-300.

39. Harper JL. Genetics and genodermatoses. In Rook/Wilkinson/Ebling. Textbook of Dermatology. Champion RH, Burton JL, Burns DA, Breathnach SM. 6th edn. Vol 1. Oxford: Blackwell Science Ltd 1998; 371-2.
40. Simon M, Djawari D, Schonberger A. HLA-antigens associated with lichen planus. Clin Exp Dermatol 1984; 9: 435.
41. Powell FC, Rogers RS, Dickson ER et al. An association between HLA-DR1 and lichen planus. Br J Dermatol 1986; 114: 473-8.
42. Copeman PWM, Tan RSH, Timlin D et al. Familial lichen planus. Br J Dermatol 1978; 98: 573-7.
43. Mahood JM. Familial lichen planus. Arch Dermatol 1983; 119: 292-4.
44. Grunnet N, Schmidt H. Occurrence of lichen planus in a family. Genetic susceptibility or coincidence? Clin Exp Dermatol 1983; 8: 397-400.
45. Hampf GC, Malmstrom JM, Aalberg VA et al. Psychiatric disturbance in patients with oral lichen planus. Oral Surg Oral Med Oral Pathol 1987; 63: 429-32.
46. Altman J, Perry HO. The variations and course of lichen planus. Arch Dermatol 1961; 84: 179-91.
47. McCartan BE. Psychological factors associated with oral lichen planus. J Oral Pathol Med 1995; 24: 273-5.
48. Shafer WG, Hine MK, Levy BM. A textbook of oral pathology. 4th edn. WB Saunders. Philadelphia 1983.
49. Lowenthal U, Pisanti S. Oral lichen planus according to the modern model. J Oral Med 1984; 39: 224-6.
50. Allen CM, Beck FM, Rossie KM et al. Relation of stress and anxiety to oral lichen planus. Oral Surg Oral Med Oral Pathol 1986; 61: 44-6.
51. Rojo-Moreno JL, Bagan JV, Rojo-Moreno J et al. Psychologic factors and oral lichen planus. A psychometric evaluation of 100 cases. Oral Surg Oral Med Oral Pathol Oral Radiol Endod 1998; 86: 687-91.
52. Ostman PO, Anneroth G, Johansson I et al. Life-style survey of patients with oral lichenoid reactions. Acta Odontol Scand 1996; 54: 96-101.
53. Neumann-Jensen B, Holmstrup P, Pindborg JJ. Smoking habits of 611 patients with oral lichen planus. Oral Surg 1977; 43: 410-5.
54. Murti PR, Daftary DK, Bhonsle RB et al. Malignant potential of oral lichen planus: observation in 722 patients from India. J Oral Pathol 1986; 15: 71-7.
55. Schlecht NF, Franco EL, Pintos J et al. Interaction between tobacco and alcohol consumption and the risk of cancers of the upper aerodigestive tract in Brazil. Am J Epidemiol 1999; 150: 1129-37.
56. van der Waal I. Tumoren van het mondslijmvlies. [Dutch]. Tumors of the oral mucosa. Ned Tijdschr Derm Venereol 2002; 12: 368-70.
57. Katz J, Goultschin J, Benoliel R et al. Lichen planus evoked by periodontal surgery. J Clin Periodontol 1988; 15: 263-5.
58. Scully C. The oral cavity. In: Rook/Wilkinson/Ebling. Textbook of Dermatology. Champion RH, Burton JL, Burns DA, Breathnach SM. 6th edn. Vol 4. Oxford: Blackwell Science Ltd 1998; 3054-5.
59. Ramon-Fluixa C, Bagan-Sebastian J, Milian-Masanet M et al. Periodontal status in patients with oral lichen planus: a study of 90 cases. Oral Diseases 1999; 5: 303-6.
60. Jacob FM, Helmbold TR. Bacteriologic studies on lichen planus: preliminary report. Arch Derm Syphilol 1933; 27: 472.
61. Lehnhoff C. Spirochaetes in aetiologically obscure diseases. Acta Derm Venereol (Stockholm) 1948; 28: 295.

62. Lochner JC, Pomeranz JR. Lichenoid secondary syphilis. *Arch Dermatol* 1974; 109: 81-3.
63. Shelley WB, Shelley ED. Urinary tract infection as a cause of lichen planus: metronidazole therapy. *J Am Acad Dermatol* 1989; 10: 905-7.
64. Wahba-Yahav AV. Intestinal amebiasis, lichen planus and treatment with metronidazole. *J Am Acad Dermatol* 1989; 20: 1128-9.
65. Scully C, El-Kom M. Lichen planus: review and update in pathogenesis. *J Oral Pathol Med* 1985; 14: 431-8.
66. Ficarra G, Flaitz CM, Gaglioti D et al. White lichenoid lesions of the buccal mucosa in patients with HIV infection. *Oral Surg Oral Med Oral Pathol* 1993; 76: 460-6.
67. Maitland NJ, Cox MV, Lynas C et al. Detection of human papillomavirus DNA in biopsies of human oral tissue. *Br J Cancer* 1987; 56: 245-9.
68. Jontell M, Watts S, Wallstrom M et al. Human papilloma virus in erosive oral lichen planus. *J Oral Pathol Med* 1990; 19: 273-7.
69. Walsh LJ, Ishii T, Savage NW et al. Immunohistologic analysis of epithelial cell populations in oral lichen planus. *J Oral Pathol Med* 1990; 19: 177-81.
70. Lodi G, Porter SR. Hepatitis C virus infection and lichen planus: a short review. *Oral Diseases* 1997; 3: 77-81.
71. van der Meij EH, van der Waal I. Hepatitis C virus infection and oral lichen planus: a report from the Netherlands. *J Oral Pathol Med* 2000; 29: 255-8.
72. Imhof M, Popal H, Lee JH et al. Prevalence of hepatitis C virus antibodies and evaluation of hepatitis C virus genotypes in patients with lichen planus. *Dermatology* 1997; 195(1): 1-5.
73. Ingafou M, Porter SR, Scully C et al. No evidence of HCV infection or liver disease in British patients with oral lichen planus. *Int J Oral Maxillofac Surg* 1998; 27: 65-6.
74. Mignogna MD, Lo Muzio L, Lo Rosso L et al. Oral lichen planus: different clinical features in HCV-positive and HCV-negative patients. *Int J Dermatol* 2000; 39: 134-9.
75. Figueiredo LC, Carrilho FJ, de Andrade HF et al. Oral lichen planus and hepatitis C virus infection. *Oral Diseases* 2002; 8: 42-6.
76. GISED (Gruppo Italiano Studi Epidemiologici in Dermatologia). Lichen planus and liver disease: a multicentre case-control study. *Br Med J* 1990; 300: 227-30.
77. Rebora A, Robert E, Rongioletti F. Clinical and laboratory presentation of lichen planus patients with chronic liver disease. *J Dermatol Sci* 1992; 4: 38-41.
78. Pemberton MN, Sloan P, Thakker NS. Oral lichenoid lesions after hepatitis B vaccination. *Oral Surg Oral Med Oral Pathol Oral Radiol Endod* 2000; 89: 717-9.
79. Al-Khenaizan S. Lichen planus occurring after hepatitis B vaccination: a new case. *J Am Acad Dermatol* 2001; 45: 614-5.
80. Lundstrom IM, Anneroth GB, Holmberg K. Candida in patients with oral lichen planus. *Int J Oral Surg* 1984; 13: 226-38.
81. Holmstrup P, Dabelsteen E. The frequency of Candida in oral lichen planus. *Scand J Dent Res* 1974; 82: 584-7.
82. Simon M, Hornstein OP. Prevalence rate of Candida in the oral cavity of patients with oral lichen planus. *Arch Dermatol Res* 1980; 267: 317-8.
83. Hatchuel DA, Peters E, Lemmer J et al. Candidal infection in oral lichen planus. *Oral Surg Oral Med Oral Pathol* 1990; 70: 172-5.
84. Krogh P, Hald B, Holmstrup P. Possible mycological etiology of oral mucosal cancer: catalytic potential of infecting *Candida albicans* and other yeasts in production of N-nitrosobenzylmethylamine. *Carcinogenesis* 1987; 8: 1543-8.

85. McCreary CE, McCartan BE. Clinical management of oral lichen planus. *Br J Oral Maxillofac Surg* 1999; 37: 338-43.
86. Rietschel RL, Fowler JF. The pathogenesis of allergic contact hypersensitivity. In: *Fisher's Contact Dermatitis*. 5th edn. Philadelphia. Lippincott Williams & Wilkins 2001; 1-26.
87. Rietschel RL, Fowler JF. Contact stomatitis and cheilitis. In: *Fisher's Contact Dermatitis*. 5th edn. Philadelphia. Lippincott Williams & Wilkins 2001; 663-85.
88. van Loon LA. Allergic contact stomatitis to metals in dentistry: an empirical-clinical investigation. Thesis. University of Amsterdam 1989.
89. van Joost Th, Laeijendecker R. Amalgam. VI. Allergie voor kwik in tandheelkundig materiaal; orale en systemische reacties [Dutch]. *Amalgam*. VI. Allergy to mercury in dental materials: oral and systemic reactions. *Ned Tijdschr Tandheelkd* 1993; 100: 303-7.
90. Schiller PI, Flaig MJ, Puchta U et al. Detection of clonal T cells in lichen planus. *Arch Dermatol Res* 2000; 292: 568.
91. Rajagopalan R, Kallal JE, Fowler JF et al. A retrospective evaluation of patch testing in patients diagnosed with allergic contact dermatitis. *Cutis* 1996; 57: 360.
92. Mills JA. The immunologic significance of antigen induced lymphocyte transformation in vitro. *J Immunol* 1966; 97: 239-47.
93. Al Tawil NG, Marcusson JA, Moller E. Lymphocyte transformation test in patients with nickel sensitivity: an aid to diagnosis. *Acta Derm Venereol (Stockholm)* 1981; 61: 511-5.
94. Wilkinson JD, Shaw S. Allergic contact dermatitis. In: *Rook/Wilkinson/Ebling. Textbook of Dermatology*. Champion RH, Burton JL, Burns DA, Breathnach SM. 6th edn. Vol 1. Oxford: Blackwell Science Ltd 1998; 814-5.
95. Hietanen J, Pihlman K, Forstrom L et al. No evidence of hypersensitivity to dental restorative metals in oral lichen planus. *Scand J Dent Res* 1987; 95: 320-7.
96. Eisen D, Eisenberg E. Oral lichen planus and the Burning mouth syndrome. Is there a role for patch testing? *Am J Contact Dermatitis* 2000; 11(2): 111-4.
97. Laine J, Kalimo K, Forssell H et al. Resolution of oral lichenoid lesions after replacement of amalgam restorations in patients allergic to mercury compounds. *Br J Dermatol* 1992; 126: 10-5.
98. Laeijendecker R, Heule F, van Joost Th. Orale lichen ruber planus: klinische en immunologische aspecten. [Dutch]. *Oral lichen planus: clinical and immunological aspects*. *Ned Tijdschr Geneeskde* 1992; 136: 2167-71.
99. Koch P, Bahmer FA. Oral lesions and symptoms related to metals used in dental restorations. *J Am Acad Dermatol* 1999; 41(1): 422-30.
100. Smart ER, Macleod RI, Lawrence CM. Resolution of lichen planus following removal of amalgam restorations in patients with proven allergy to mercury salts: a pilot study. *Br Dent J* 1995; 178: 108-12.
101. Holmstrup P, Schiotz AW, Hyug D et al. Effect of dental plaque control on gingival lichen planus. *Oral Surg Oral Med Oral Pathol* 1990; 69: 585-90.
102. Erpenstein H. Periodontal and prosthetic treatment in patients with oral lichen planus. *J Clin Periodontol* 1985; 12: 104-12.
103. Holmstrup P. Reactions of the oral mucosa related to silver amalgam. *J Oral Pathol Med* 1991; 20: 1-7.
104. Ostman PO, Anneroth G, Skoglund A. Oral lichen planus lesions in contact with amalgam fillings. *Scand J Dent Res* 1994; 102: 172-9.
105. Lundstrom IMC. Allergy and corrosion of dental materials in patients with oral lichen planus. *Int J Oral Surg* 1984; 13: 16-24.

106. Martin MD, Broughton S, Drangsholt M. Oral lichen planus and dental materials: a case-control study. *Contact Dermatitis* 2003; 48: 331-6.
107. Wiesenfeld D, Ferguson MM, Forsyth A et al. Allergy to dental gold. *Oral Surg Oral Med Oral Pathol* 1984; 57: 158.
108. Jameson MW, Kardos TB, Kirk EEJ et al. Mucosal reactions to amalgam restorations. *J Oral Rehabil* 1990; 17: 293-301.
109. Kubicka-Muranyi M, Behmer O, Uhrberg M et al. Murine systemic autoimmune disease induced by mercuric chloride (HgCl_2): Hg-specific helper T-cells react to antigen stored in macrophages. *Int J Immunopharm* 1993; 15: 151-61.
110. Stejskal VDM, Forsbeck M, Cederbrant KE et al. Mercury-specific lymphocytes: an indication of mercury allergy in man. *J Clin Immunol* 1996; 16(1): 31-40.
111. Torresani C, Nannini R, Bondi A et al. Erosive lichen planus due to sensitization to cobalt chloride. *Clin Exp Dermatol* 1994; 19: 535-6.
112. Bergman N. American dental association status report on the occurrence of galvanic corrosion in the mouth and its potential effects. *JADA* 1987; 115: 783-7.
113. Frykholm KO, Frithiof A, Fernstrom AI et al. Allergy to copper derived from dental alloys as a possible cause of oral lesions of lichen planus. *Acta Derm Venereol* 1969; 49: 268.
114. Koch P, Baum HP. Contact stomatitis due to palladium and platinum in dental alloys. *Contact Dermatitis* 1996; 34: 253-7.
115. Mizoguchi S, Setoyama M, Kanzaki T. Linear lichen planus in the region of the mandibular nerve caused by an allergy to palladium in dental metals. *Dermatology* 1998; 196: 268-70.
116. Feilzer AJ. Materiaalanalyse in het kader van de diagnostiek van toxische en allergische reacties in de Tandheelkunde. [Dutch]. Analysis of dental materials in toxic and allergic reactions in dentistry. *Ned Tijdschr Allergie* 2004; 5: 168-73.
117. van Loon LA, van Elsas PW, van Joost Th et al. Test battery for metal allergy in dentistry. *Contact Dermatitis* 1986; 14: 158-61.
118. Geurtsen W. Biocompatibility of dental casting alloys. *Crit Rev Oral Biol Med* 2002; 13: 71-84.
119. Garner LA. Contact dermatitis to metals. *Dermatol Ther* 2004; 17(4): 321-7.
120. Garhammer P, Schmalz G, Hiller KA et al. Patients with local adverse effects from dental alloys: frequency, complaints, symptoms, allergy. *Clin Oral Investig* 2001; 5: 240-9.
121. Bates MN, Fawcett J, Garrett N et al. Health effects of dental amalgam exposure: a retrospective cohort study. *Int J Epidemiol* 2004; 33(4): 894-902.
122. Lamster IB, Kalfus DI, Steigerwald PJ et al. Rapid loss of alveolar bone associated with nonprecious alloy crowns in two patients with nickel hypersensitivity. *J Periodontol* 1987; 58: 486-92.
123. Wirz J, Schmidli F. Clinical testing of alloys. *Quintessenz* 1990; 41: 1875-80.
124. Bergdahl BJ, Anneroth G, Anneroth I. Clinical study of patients with burning mouth. *Scand J Dent Res* 1994; 102: 299-305.
125. Yip HK, Li DK, Yau DC. Dental amalgam and human health. *Int Dent J* 2003; 53(6): 464-8.
126. Todd P, Garioch J, Lamey PJ et al. Patch testing in lichenoid reactions of the mouth and oral lichen planus. *Contact Dermatitis* 1990; 23: 300-1.
127. Eisen D. The therapy of oral lichen planus. *Crit Rev Oral Biol Med* 1993; 4: 141-58.
128. Allen CM, Blozis GG. Oral mucosal reactions to cinnamon-flavored chewing gum. *J Am Dent Assoc* 1988; 116: 664-7.

129. Lind P. Oral lichenoid reactions related to composite restorations. *Acta Odontol Scand* 1988; 46: 63-5.
130. Hensten-Pettersen C. Dermatitis and dental materials. *Contact Dermatitis* 1981; 7: 174.
131. Kanerva L, Jolanki R, Estlander T. 10 years of patch testing with the (meth)acrylate series. *Contact Dermatitis* 1997; 37: 255-8.
132. Henriks-Eckerman ML, Suuronen K, Jolanki R et al. Methacrylates in dental restorative materials. *Contact Dermatitis* 2004; 50: 233-7.
133. Carrozzo M, Gandolfo S. Review: the management of oral lichen planus. *Oral Diseases* 1999; 5: 196-205.
134. Lozada-Nur F, Miranda C. Oral lichen planus: topical and systemic therapy. *Semin Cutan Med Surg* 1997; 16(4): 295-300.
135. van der Meij EH, Schepman KP, Plonait DR et al. Interobserver and intraobserver variability in the clinical assessment of oral lichen planus. *J Oral Pathol Med* 2002; 31: 95-8.
136. Eisen D. The oral mucosal punch biopsy: a report of 140 cases. *Arch Dermatol* 1992; 128: 815-7.
137. Cerio R. Histopathology of the skin: general principles. In: Rook/Wilkinson/Ebling. *Textbook of Dermatology*. Champion RH, Burton JL, Burns DA, Breathnach SM. 6th edn. Vol 4. Oxford: Blackwell Science Ltd 1998; 159-203.
138. Helander SD, Rogers RS. The sensitivity and specificity of direct immunofluorescence testing in disorders of mucous membranes. *J Am Acad Dermatol* 1994; 30: 65-75.
139. Karabulut A, Reibel J, Therkildsen MH et al. Observer variability in the histologic assessment of oral premalignant lesions. *J Oral Pathol Med* 1995; 24: 198-200.
140. Taaffe A. Currents concepts in lichen planus. *Int J Dermatol* 1979; 18: 533-8.
141. Konrad K, Pehamberger H, Holubar K. Ultrastructural localization of immunoglobulin and fibrin in lichen planus. *J Am Acad Dermatol* 1979; 1: 233-9.
142. Rogers RS, Jordon RE. Immunopathology of oral mucosal inflammatory diseases. *Clin Exp Dermatol* 1977; 2: 97-107.
143. Shklar G, Meyer I. The histopathology and histochemistry of dermatologic lesions in the mouth. *Oral Surg Oral Med Oral Pathol* 1961; 14: 1069-81.
144. Eerdekens M, Matthieu L, Jacob W et al. Lichen ruber planus.[Dutch]. *Lichen planus. Cilag. Kaatsheuvel. Derma Forum* 1989, 13 H.
145. Ellis FA. Histopathology of lichen planus based on analysis of one hundred biopsy specimens. *J Invest Dermatol* 1967; 48: 143-8.
146. Zegarelli DJ. Lichen planus: a simple and reliable biopsy technique. *J Oral Med* 1981; 36: 18-20.
147. Ryan TJ. Lichen planus, Wickham's striae and blood vessels. *Br J Dermatol* 1971; 85: 497-8.
148. van der Meij EH, Reibel J, Slootweg PJ et al. Interobserver and intraobserver variability in the histologic assessment of oral lichen planus. *J Oral Pathol Med* 1999; 28: 274-7.
149. Pullon PA. Ultrastructure of oral lichen planus. *Oral Surg Oral Med Oral Pathol* 1969; 28(3): 365-71.
150. Hashimoto K, Dibella RJ, Shklar G et al. Electron microscopic studies of oral lichen planus. *Giornale Italiano di Dermatologia* 1966; 107: 765-88.
151. Walker DM. The inflammatory infiltrate in lichen planus lesions. *J Oral Pathol* 1976; 5: 277-86.

152. Tyldesly WR, Appleton J. Observations on the ultrastructure of the epithelium in oral lichen planus. *J Oral Pathol* 1973; 2: 46-57.
153. Johnson FR, Fry L. Ultrastructural observations on lichen planus. *Arch Dermatol* 1967; 95: 596-607.
154. Nieboer C. The reliability of immunofluorescence and histopathology in the diagnosis of discoid lupus erythematosus and lichen planus. *Br J Dermatol* 1987; 116: 189-98.
155. Baart de la Faille-Kuyper EH, Baart de la Faille H. An immunofluorescence study of lichen planus. *Br J Dermatol* 1974; 90: 365-71.
156. Schiodt M, Holmstrup P, Dabelsteen E et al. Deposits of immunoglobulins, complement, and fibrinogen in oral lupus erythematosus, lichen planus, and leukoplakia. *Oral Surg Oral Med Oral Pathol* 1981; 51: 603-8.
157. McCartan BE, McCreary CE. Oral lichenoid drug eruptions. *Oral Diseases* 1997; 3: 58-63.
158. Kilpi AM, Rich AM, Radden BG et al. Direct immunofluorescence in the diagnosis of oral mucosal diseases. *Int J Oral Maxillofac Surg* 1988; 17: 6-10.
159. Eversole LR. Immunopathology of oral mucosal ulcerative, desquamative and bullous diseases. Selective review of the literature. *Oral Surg* 1994; 77: 555-7.
160. Firth NA, Reade PC. Angiotensin-converting enzyme inhibitors implicated in oral mucosal lichenoid reactions. *Oral Surg* 1989; 67: 41-4.
161. De Panfilis G, Manara G, Sansoni P et al. T-cell infiltrate in lichen planus. Demonstration of activated lymphocytes using monoclonal antibodies. *J Cutan Pathol* 1983; 10: 52-8.
162. Bhan AK, Harist TJ, Murphy GF et al. T cell subsets and Langerhans cells in lichen planus: in situ characterization using monoclonal antibodies. *Br J Dermatol* 1981; 105: 617-22.
163. Takeuchi Y, Tohnai I, Kaneda T et al. Immunohistochemical analysis of cells in mucosal lesions of oral lichen planus. *J Oral Pathol* 1988; 17: 367-73.
164. Boisnic S, Frances C, Branchet MC et al. Immunohistochemical study of oral lesions of lichen planus: diagnostic and pathophysiologic aspects. *Oral Surg Oral Med Oral Pathol* 1990; 70: 462-5.
165. Regezi J, Stewart J, Lloyd R et al. Immunohistochemical staining of Langerhans cells and macrophages in oral lichen planus. *Oral Surg* 1985; 60: 396-402.
166. Simon M. Lesional keratinocytes express OKM5, Leu-8 and Leu-11b antigens in lichen planus. *Dermatologica* 1988; 177: 152-8.
167. Farthing PM, Cruchley AT. Expression of MHC class II antigens (HLA-DR, DP and DQ) by keratinocytes in oral lichen planus. *J Oral Pathol Med* 1989; 18: 305-9.
168. Olsen RG, Du Plessis DP, Barron C et al. Lichen planus dermatopathy: demonstration of a lichen planus specific epidermal antigen in affected patients. *J Clin Lab Immunol* 1983; 10: 103-6.
169. Olsen RG, du Plessis DP, Schultz EJ et al. Indirect immunofluorescence microscopy of lichen planus. *Br J Dermatol* 1984; 110: 9-15.
170. Camisa C, Allen CM, Bowen B et al. Indirect immunofluorescence of oral lichen planus. *J Oral Pathol* 1986; 15: 218-20.
171. Kwee DJ, Dufresne RG, Ellis DL. Childhood bullous lichen planus. *Pediatr Dermatol* 1987; 4: 325-7.
172. Black MM. The pathogenesis of lichen planus. *Br J Dermatol* 1972; 86: 302-5.
173. Ryan M, Phiackerley PJR, Ryan TJ et al. Glucose-6-phosphate dehydrogenase in lichen planus skin. *Br J Dermatol* 1976; 94: 607-10.

174. Hammar H. β -Hydroxyacyl-CoA dehydrogenase and glucose-6-phosphate dehydrogenase in normal human skin and in some papulosquamous diseases of the skin. *Acta Derm Venereol* (Stockholm) 1971; 51: 93-7.
175. Cotton DWK, van den Hurk JJMA, van der Staak WBJM. Lichen planus: an inborn error of metabolism. *Br J Dermatol* 1972; 87: 341-6.
176. Black MM, Wilson-Jones E. The role of the epidermis in the histopathogenesis of lichen planus. *Arch Dermatol* 1972; 105: 81-6.
177. Heyden G, Arwill T, Gisslen H. Histochemical studies on lichen planus. *Oral Surg Oral Med Oral Pathol* 1974; 37: 239-48.
178. Holmstrup P, Dabelsteen E. Changes in carbohydrate expression of lichen planus affected oral epithelial cell membranes. *J Invest Dermatol* 1979; 73: 364-7.
179. Parish WE, Breathnach SM. Clinical immunology and allergy. In: Rook/Wilkinson/Ebling. *Textbook of Dermatology*. Champion RH, Burton JL, Burns DA, Breathnach SM. 6th edn. Vol 1. Oxford: Blackwell Science Ltd 1998; 277-336.
180. Scully C. Serum IgG, IgA, IgD and IgE in lichen planus: no evidence for a humoral immunodeficiency. *Clin Exp Dermatol* 1982; 7: 163-70.
181. Sklavounova AD, Laskaris G, Angelopoulos AP. Serum immunoglobulins and complement (C3) in oral lichen planus. *Oral Surg Oral Med Oral Pathol* 1983; 55: 47-51.
182. Sallay K, Kovesi G, Dori F. Circulating immune complex studies on patients with oral lichen planus. *Oral Surg Oral Med Oral Pathol* 1989; 68: 567-70.
183. Mahood JM. Serum immunoglobulins in lichen planus. *Br J Dermatol* 1981; 104: 207-8.
184. Cottoni F, Solinas A, Piga MR et al. Lichen planus and chronic liver disease, and immunologic involvement. *Arch Dermatol Res* 1988; 280: 55-60.
185. Gilhar A, Pillar T, Winterstein G et al. The pathogenesis of lichen planus. *Br J Dermatol* 1989; 120: 541-4.
186. Tammi R, Hyyrylainen A, Fraki JE. Histologic characteristics of lichen planus transplanted onto nude mice and cultured in vitro. *Arch Dermatol Res* 1988; 280: 23-8.
187. Morhenn VB. Etiology of lichen planus. *Am J Dermatopathol* 1986; 8: 154-6.
188. Shiohara T. The lichenoid tissue reaction. An immunological perspective. *Am J Dermatopathol* 1988; 10: 252-6.
189. Sugarman PB, Satterwhite K, Bigby M. Autocytotoxic T-cell clones in lichen planus. *Br J Dermatol* 2000; 142: 449-56.
190. Walsh LJ, Lavker RM, Murphy GF. Determinants of immune cell trafficking in the skin. *Lab Invest* 1990; 63: 592-600.
191. Kupper TS. Production of cytokines by epithelial tissues. A new model for cutaneous inflammation. *Am J Dermatopathol* 1989; 11: 69-73.
192. Miller MD, Krangel MS. Biology and biochemistry of the chemokines: a family of chemotactic and inflammatory cytokines. *Crit Rev Immunol* 1992; 12: 17-46.
193. De Panfilis G, Manara GC, Ferrari C et al. Adhesion molecules on the plasma membrane of epidermal cells. II. The intercellular adhesion molecule-1 is constitutively present on cell surface of human resting Langerhans cells. *J Invest Dermatol* 1990; 94(3): 317-21.
194. King PD, Katz DR. Human tonsillar dendritic cell-induced T-cell responses: analysis of molecular mechanisms using monoclonal antibodies. *Eur J Immunol* 1989; 19: 581-7.
195. Stingel G, Katz SI, Clement L et al. Immunologic functions of IIa bearing epidermal Langerhans cells. *J Immunol* 1978; 121: 2005-13.

196. Nickoloff BJ. Role of interferon-gamma in cutaneous trafficking of lymphocytes with emphasis on molecular and cellular adhesion events. *Arch Dermatol* 1988; 124: 1835-43.
197. Korkij W, Chuang TY, Soltani K. Liver abnormalities in patient with lichen planus. A retrospective case-control study. *J Am Acad Dermatol* 1984; 11: 609-15.
198. Shiohara T, Moriya N, Nagashima M. The lichenoid tissue reaction. A new concept of pathogenesis. *Int J Dermatol* 1988; 27: 365-74.
199. Ishii T. Immunohistochemical demonstration of T cell subsets and accessory cells in oral lichen planus. *J Oral Pathol* 1987; 16: 356-61.
200. Reinhold U, Pawelec G, Fratila A et al. Phenotypic and functional characterisation of tumor infiltrating lymphocytes in mycosis fungoides: continuous growth of CD4+CD45RA+T-clones with suppressor-inducer activity. *J Invest Dermatol* 1990; 94: 304-9.
201. Sugerman PB, Savage NW, Seymour GJ. Phenotype and suppressor activity of T-lymphocyte clones extracted from lesions of oral lichen planus. *Br J Dermatol* 1994; 131: 319-24.
202. Yamamoto T, Osaki T, Yoneda K et al. Cytokine production by keratinocytes and mononuclear infiltrates in oral lichen planus. *J Oral Pathol Med* 1994; 23: 309-15.
203. Sugerman PB, Savage NW, Xu LJ et al. Heat shock protein expression in oral lichen planus. *J Oral Pathol Med* 1995; 24: 1-8.
204. Chaiyarit P, Kafrawy AH, Miles DA et al. Oral lichen planus: an immunohistochemical study of heat shock proteins (HSPs) and cytokeratins (CKs) and a unifying hypothesis of pathogenesis. *J Oral Pathol Med* 1999; 28: 210-5.
205. Wantzin GL, Ralfkiaer E, Lisby S et al. The role of intercellular adhesion molecules in inflammatory skin reactions. *Br J Dermatol* 1988; 119: 141-5.
206. Bayramgurler D, Ozkara SK, Apaydin R et al. Heat shock proteins 60 and 70 expression of cutaneous lichen planus: comparison with normal skin and psoriasis vulgaris. *J Cutan Pathol* 2004; 31: 586-94.
207. Fernandez-Bussey RA, Schmitt D, Gaucherand M et al. Lichen planus: evaluation of cells in skin lesions and of T-lymphocyte subsets in blood. *J Dermatol (Tokyo)* 1983; 10: 17-24.
208. Lin SC, Hahn LJ, Kwan HW. Subsets of T-lymphocytes in peripheral blood of patients with oral lichen planus. *Int J Oral Maxillofac Surg* 1988; 17: 84-6.
209. Simon M, Hunyadi J, Fickentscher H et al. Basic and interleukin-2-augmented natural killer cell activity in lichen planus. *Dermatologica* 1989; 178: 141-4.
210. Scully C, Boyle P. β_2 -microglobulin in lichen planus. *J Dent Res* 1982; 61: 758-60.
211. Tan RSH. Thymoma, acquired hypogammaglobulinaemia, lichen planus, alopecia areata. *Proc R Soc Med* 1974; 67: 196-8.
212. Powell FC. Lichen planus and chronic active hepatitis. *J Am Acad Dermatol* 1984; 10: 841.
213. Grupper C, Bourgeois Spinasse J, Buisson J. Duhring-Brocq disease followed by or associated with lichen planus. *Bull Soc Fr Dermatol Syph* 1972; 79: 231-2.
214. Nigam PK, Sharma L, Agrawal JK et al. Glucose tolerance studies in lichen planus. *Dermatologica* 1987; 175: 284-9.
215. Lundstrom IMC. Incidence of diabetes mellitus in patients with oral lichen planus. *Int J Oral Surg* 1983; 12: 147-52.
216. Lozada-Nur F, Luangjarmekorn L, Silverman S et al. Assessment of plasma glucose in 99 patients with oral lichen planus. *J Oral Med* 1985; 40: 60-1.

217. Voltz MJ. Flow cytometric analysis of peripheral blood lymphocyte subsets in oral lichen planus (thesis). University of Queensland. Queensland. Australia 1989.
218. Rebora A, Rongioletti F, Canepa A. Chronic active hepatitis and lichen planus. *Acta Derm Venereol* 1982; 62: 351-2.
219. El-Kabir M, Scully C, Porter S et al. Liver function in UK patients with oral lichen planus. *Clin Exp Dermatol* 1993; 18: 12-6.
220. Okochi H, Nashiro K, Tsuchida T et al. Lichen planus pemphigoides: case report and results of immunofluorescence and immunoelectron microscopic study. *J Am Acad Dermatol* 1990; 22: 626-31.
221. Edwards L, Friedrich EG. Desquamative vaginitis: lichen planus in disguise. *Obstet Gynecol* 1988; 71: 832-6.
222. van Dis ML, Parks ET. Prevalence of oral lichen planus in patients with diabetes mellitus. *Oral Surg Oral Med Oral Pathol* 1995; 79: 696-700.
223. Grinspan D, Diaz J, Vollapol LO et al. Lichen ruber planus de la muqueuse buccale. Son association à un diabète. [French]. *Bull Soc Franc Dermatol Syph* 1966; 73: 898-9.
224. Christensen E, Holmstrup P, Wiberg-Jorgensen F et al. Arterial blood pressure in patients with oral lichen planus. *J Oral Pathol* 1977; 6: 139-42.
225. Lamey PJ, Gibson J, Barclay SC et al. Grinspan's syndrome: a drug-induced phenomenon? *Oral Surg Oral Med Oral Pathol* 1990; 70: 184-5.
226. Mann RJ, Wallington TB, Warin RP. Lichen planus with late onset hypogammaglobulinaemia: a causal relationship? *Br J Dermatol* 1982; 106: 357-60.
227. Zijdenbos LM, Starink TM, Spronk CA. Ulcerative lichen planus with associated sicca syndrome and good therapeutic result of skin grafting. *J Am Acad Dermatol* 1985; 13: 667-8.
228. Davies MG, Gorkiewicz A, Knight A et al. Is there a relationship between lupus erythematosus and lichen planus? *Br J Dermatol* 1977; 96: 145-54.
229. van der Horst JC, Cirkel PS, Nieboer C. Mixed lichen planus-lupus erythematosus disease. A distinct entity? Clinical, histopathological, immunopathological studies in six patients. *Clin Exp Dermatol* 1983; 8: 631-40.
230. Helm TM, Camisa C, Liu AY et al. Lichen planus associated with neoplasia: a cell-mediated immune response to tumor antigens? *J Am Acad Dermatol* 1994; 30: 219-24.
231. Magnusson B. Lichen ruber bullosus and tumors in internal organs. *Dermatologica* 1967; 134: 166-72.
232. Jansen T, Plewig G, Anhalt GJ. Paraneoplastic pemphigus with clinical features of erosive lichen planus associated with Castleman's tumor. *Dermatol* 1995; 190: 245-50.
233. Brenner W, Diem E, Gschnait F. Coincidence of vitiligo, alopecia areata, onychodystrophy, localized scleroderma and lichen planus. *Dermatologica* 1979; 159: 356-60.
234. Aronson IK, Soltani K, Paik KI et al. Triad of lichen planus, myasthenia gravis, and thymoma. *Arch Dermatol* 1978; 114: 255-8.
235. Miller TN. Myasthenia gravis, ulcerative colitis and lichen planus. *Proc R Soc Med* 1971; 64: 37-8.
236. Neumann-Jensen B, Worsaae N, Dabelsteen E et al. Pemphigus vulgaris and pemphigus foliaceus coexisting with oral lichen planus. *Br J Dermatol* 1980; 102: 585-90.
237. Lee CW. Pemphigus vulgaris coexisting with generalized lichen planus. *J Dermatol* 1987; 14: 388-91.

238. Rustin MH. A case of atrophic lichen planus in association with Addisonian pernicious anaemia. *Clin Exp Dermatol* 1986; 11: 188-90.
239. Lundstrom WI, Anneroth GC, Bergsted HF. Salivary gland function and changes in patients with oral lichen planus. *Scand J Dent Res* 1982; 90: 443-58.
240. Mobacken H, Nilsson LA, Olsson R et al. Incidence of liver disease in chronic lichen planus of the mouth. *Acta Derm Venereol* 1984; 64: 70-3.
241. Powell FC, Rogers RS, Dickson ER. Primary biliary cirrhosis and lichen planus. *J Am Acad Dermatol* 1983; 9: 540-5.
242. Graham-Brown RAC, Sarkany I, Sherlock S. Lichen planus and primary biliary cirrhosis. *Br J Dermatol* 1982; 106: 699-703.
243. GISED (Gruppo Italiano Studi Epidemiologici in Dermatologia). Epidemiological evidence of the association between lichen planus and two immune-related diseases: Alopecia areata and ulcerative colitis. *Arch Dermatol* 1991; 127: 688-91.
244. Cusano F, Errico G. Lichen planus and ulcerative colitis. *Arch Dermatol* 1984; 120: 994-5.
245. Marren P, Millard P, Chia Y et al. Mucosal lichen sclerosus/lichen planus overlap syndromes. *Br J Dermatol* 1994; 131: 118-23.
246. Fortune F, Buchanan JAG. Oral lichen planus and coeliac disease. *Lancet* 1993; 341: 1154-5.
247. Kano J, Shiohara T, Yagita A et al. Erythema nodosum, lichen planus and lichen nitidus in Crohn's disease: report of a case and analysis of T cell receptor V gene expression in the cutaneous and intestinal lesions. *Dermatology* 1995; 190: 59-63.
248. Jolly M, Nobile S. Vitamin status of patients with oral lichen planus. *Aust Dent* 1977; 22: 446-50.
249. Berger RS, Hayes TJ, Dixon SL. Erythema dyschromicum perstans and lichen planus: are they related? *J Am Acad Dermatol* 1989; 21: 438-42.
250. Cottoni F, Tedde G, Solinas A et al. Lichen planus associated with anti-liver-kidney microsome-positive chronic active hepatitis and hyperthyroidism. *Arch Dermatol* 1991; 127: 1730-1.
251. Naldi L, Sena P, Cainelli T. About the association of lichen planus and psoriasis. *Dermatologica* 1990; 181: 79-80.
252. Kurgansky D, Burnett JW. Widespread lichen planus in association with Turner's syndrome and multiple endocrinopathies. *Cutis* 1994; 54: 108-10.
253. Halevy S, Feuerman EJ. Urolithiasis in lichen planus (letter). *Arch Dermatol* 1983; 119: 364.
254. Powell FC. Lichen planus and chronic active hepatitis. *J Am Acad Dermatol* 1984; 10: 841.
255. Powell F, Rogers R, Dickson E. Lichen planus, primary biliary cirrhosis and penicillamine. *Br J Dermatol* 1983; 9: 540-5.
256. Bagan JV, Aquirre JM, del Olmo JA et al. Oral lichen planus and chronic liver disease: a clinical and morphometric study of the oral lesions in relation to transaminase elevation. *Oral Surg Oral Med Oral Pathol* 1994; 78: 337-42.
257. Rebora A, Patri P, Rampini E et al. Erosive lichen planus and cirrhosis hepatitis. *Ital Gen Rev Dermatol* 1978; 15: 123-31.
258. Ayala F, Balato N, Tranfaglia A et al. Oral erosive lichen planus and chronic liver disease. *J Am Acad Dermatol* 1986; 14: 139-40.
259. Nagao Y, Sata M, Tanikawa K et al. Lichen planus and hepatitis C virus in the Northern Kyushu region of Japan. *Eur J Clin Invest* 1995; 25: 910-4.
260. Wiles JC, Lynch PJ. Lichen planus and liver disease. *J Am Acad Dermatol* 1984; 10: 671-2.

261. Choudhary SD, Gupta S, Jain VK. Lichen planus hypertrophicus with carcinoma breast in a male patient (a case report). *Indian J Dermatol* 1988; 33: 40-1.
262. Goihman-Yahr M, Essenfeld-Yahr E, Rojas-Martinez G et al. Erosive lichen planus and fibroxanthosarcoma (malignant fibrohistiocytoma): coincidence or association? *Cutis* 1980; 26: 506-8, 515-6.
263. Magnusson B. Lichen ruber and syphaticoblastoma. *Acta Derm Venereol* (Stockh) 1955; 35: 74.
264. Feuerman E, Sandbank M. Lichen planus pemphigoides with extensive melanosis. *Arch Dermatol* 1971; 104: 61-7.
265. Sigurgeirsson B, Lindehof B. Lichen planus and malignancy. *Arch Dermatol* 1991; 127: 1684-8.
266. Black MM. Lichen planus and lichenoid disorders. In: Rook/Wilkinson/Ebling. *Textbook of Dermatology*. Champion RH, Burton JL, Burns DA, Breathnach SM. 6th edn. Vol 3. Oxford: Blackwell Science Ltd 1998; 1899-926.
267. Shuttleworth D, Graham-Brown RAC, Campbell A. The autoimmune background in lichen planus. *Br J Dermatol* 1986; 115: 199-203.
268. Jolly M. Lichen planus and its association with diabetes mellitus. *Med J Aust* 1972; 1: 990-2.
269. Blasberg B, Dorey JL, Stein HB et al. Lichenoid lesions of the oral mucosa in rheumatoid arthritis patients treated with penicillamine. *J Rheum* 1984; 11: 348-51.
270. Bagan JV, Donat JS, Penarrocha M et al. Oral lichen planus and diabetes mellitus. A clinico-pathological study. *Bull Group Int Rech Sci Stomatol et Odontol* 1993; 36: 3-6.
271. Powell SM, Ellis JP, Ryan TJ et al. Glucose tolerance in lichen planus. *Br J Dermatol* 1974; 91: 71-5.
272. Chattopadhyay A. Arterial blood pressure and blood glucose levels in oral lichen planus patients in Calcutta (India). *Indian J Dent Res* 1992; 3: 84-9.
273. Blanco Carrion A, Gandara Rey JM, Rodriguez Nunez A et al. Biochemical alterations and their clinical correlation to oral lichen planus. *Med Oral* 2000; 5(4): 238-49.
274. Bermejo Fenoll A, Lopez Jornet MP. [Spanish]. Oral lichen planus and Sjögren's syndrome. 2 cases of association. *Avances en Odontostomatol* 1991; 7: 29-33, 36, 38.
275. Scully C. The oral cavity. In: Rook/Wilkinson/Ebling. *Textbook of Dermatology*. Champion RH, Burton JL, Burns DA, Breathnach SM. 6th edn. Vol 4. Oxford: Blackwell Science Ltd 1998; 3074-147.
276. Jungell P, Malmstrom M, Wartiovaara J et al. Ultrastructure of oral leukoplakia and lichen planus. I. Basal region and inflammatory cells. *J Oral Pathol* 1987; 16: 170-8.
277. Jungell P, Malmstrom M, Wartiovaara J et al. Ultrastructure of oral leukoplakia and lichen planus. II. A correlated scanning and transmission electron microscopic study of epithelial surface cells. *J Oral Pathol* 1987; 16: 287-93.
278. van Joost Th, Knecht PPM, Stolz E et al. Oral lupus erythematosus with lichen planus-like manifestations: report of a case. *J Head & Neck Pathol* 1985; 4: 21-3.
279. Luker J. Diseases of the oral mucosa and tongue. In: *Textbook of pediatric Dermatology*. Harper J, Oranje AP, Prose N. Edn 1. Vol 2. Oxford: Blackwell Science Ltd 2000; 1435-59.
280. Lavelle CLB. A study in the differential diagnosis of white lesions of the buccal mucosa. *J Oral Med* 1983; 38: 135-40.

281. Jungell P. Oral lichen planus: a review. *Int J Oral Maxillofac Surg* 1991; 20: 129-35.
282. Setterfield JF, Black MM, Challacombe SJ. The management of oral lichen planus. *Clin Exp Dermatol* 2000; 25: 176-82.
283. Yaacob HB, Tan PL, Ngeow WC. Malignancy in oral lichen planus: a review of a group from the Malaysian population. *J Oral Sci* 2002; 44: 65-71.
284. van der Meij EH, Schepman KP, Smeele LE et al. A review of the recent literature regarding malignant transformation of oral lichen planus. *Oral Surg Oral Med Oral Pathol Oral Radiol Endod* 1999; 88: 307-10.
285. Silverman S, Gorsky M, Lozada-Nur F et al. A prospective study of findings and management in 214 patients with oral lichen planus. *Oral Surg Oral Med Oral Pathol* 1991; 72: 665-70.
286. Lozada-Nur F. Oral lichen planus and oral cancer: Is there enough epidemiologic evidence? *Oral Surg Oral Med Oral Pathol Oral Radiol Endod* 2000; 89: 265-6.
287. Lacy MF, Reade PC, Hay KD. Lichen planus: a theory of pathogenesis. *Oral Surg Oral Med Oral Pathol* 1983; 56: 521-6.
288. Farmacotherapeutisch kompas 2004. [Dutch]. Pharmacotherapeutic compass 2004. College voor zorgverzekeringen. 20th edn. van Loenen AC. Bohn Stafleu Van Loghum, Naarden.
289. Hay RJ, Greaves MW, Warin AP. Systemic therapy. In: Rook/Wilkinson/Ebling. *Textbook of Dermatology*. Champion RH, Burton JL, Burns DA, Breathnach SM. 6th edn. Vol 4. Oxford: Blackwell Science Ltd 1998; 3311-48.
290. Wilkinson JD. Formulary of topical applications. In: Rook/Wilkinson/Ebling. *Textbook of Dermatology*. Champion RH, Burton JL, Burns DA, Breathnach SM. 6th edn. Vol 4. Oxford: Blackwell Science Ltd 1998; 3631-8.
291. Rodstrom PO, Hakeberg M, Jontel M et al. Erosive oral lichen planus treated with clobetasol propionate and triamcinolone acetonide in orabase: a double-blind clinical trial. *J Dermatol Treat* 1994; 5: 7-10.
292. Thongprasom K, Luangjarmekorn L, Sererat T et al. Relative efficacy of fluocinolone acetonide compared with triamcinolone acetonide in treatment of oral lichen planus. *J Oral Pathol Med* 1992; 21: 456-8.
293. Greenspan JS, Yeoman CM, Harding SM. Oral lichen planus. A double-blind comparison of treatment with betamethasone valerate aerosol and pellets. *Br Dent J* 1978; 144: 83-4.
294. Oliver GF, Winkelmann RK. Treatment of lichen planus. *Drugs* 1993; 45(1): 56-65.
295. Cribier B, Frances C, Chosidow O. Treatment of lichen planus. *Arch Dermatol* 1998; 134: 1521-30.
296. Tyldesley WR, Harding SM. Betamethasone valerate aerosol in the treatment of oral lichen planus. *Br J Dermatol* 1977; 96: 659-62.
297. Plemons JM, Rees TD, Zachariak NY. Absorption of topical steroid and evaluation of adrenal suppression in patients with erosive lichen planus. *Oral Surg Oral Med Oral Pathol* 1990; 69: 688-93.
298. Carbone M, Conrotto D, Carrozzo M et al. Topical corticosteroids in association with miconazole and chlorhexidine in the long-term management of atrophic-erosive oral lichen planus: a placebo-controlled and comparative study between clobetasol and fluocinonide. *Oral Diseases* 1999; 5: 44-9.
299. Lozada-Nur F, Huang MZ. Open preliminary clinical trial of clobetasol propionate ointment in adhesive paste for treatment of chronic oral vesiculo-erosive diseases. *Oral Surg Oral Med Oral Pathol* 1991; 71: 283-7.

300. Lozada-Nur F, Miranda C, Maliksi R. Double-blind clinical trial of 0.05% clobetasol propionate ointment in orabase and 0.05% fluocinonide ointment in orabase in the treatment of patients with oral vesiculoerosive diseases. *Oral Surg Oral Med Oral Pathol* 1994; 77: 598-604.
301. Burgess JA, Johnson BD, Sommers E. Pharmacological management of recurrent oral mucosal ulceration. *Drugs* 1990; 39(1): 54-65.
302. Hegarty AM, Hodgson TA, Lewsey JD et al. Fluticasone propionate spray and betametasone sodium phosphate mouthrinse: a randomized crossover study for the treatment of symptomatic oral lichen planus. *J Am Acad Dermatol* 2002; 47: 271-9.
303. Lehner T, Lyne C. Adrenal function during topical oral corticosteroid treatment. *BMJ* 1969; iv: 138-41.
304. Beckman BI. Valisone aerosol spray contraindicated in mucous membranes (letter). *J Am Acad Dermatol* 1981; 4: 233.
305. Dusek JJ, Frick WG. Lichen planus - oral manifestations and suggested treatments. *J Oral Maxillofac Surg* 1982; 40: 240-4.
306. Lozada F, Silverman J. Topically applied fluocinonide in an adhesive base in the treatment of oral vesiculoerosive diseases. *Arch Dermatol* 1980; 116: 190-201.
307. Zegarelli DJ. Multimodality steroid therapy of erosive and ulcerative oral lichen planus. *J Oral Med* 1983; 38: 127-30.
308. Goldstein B, Goldstein A. Practical dermatology. St Louis, USA, MO, Mosby 1996; 13-22.
309. Katzung BG. Basic and clinical pharmacology. 2nd edn, Lange Medical Publications, Los Altos, California 94022, U.S.A., 1984.
310. Lozada F, Silverman J, Migliorati C. Adverse side effects associated with prednisone in the treatment of patients with oral inflammatory ulcerative diseases. *J Am Dent Assoc* 1984; 109: 269-70.
311. Eisen D, Ellis CN, Duell EA et al. Effect of topical cyclosporine rinse on oral lichen planus.: a double-blind analysis. *N Engl J Med* 1990; 323: 290-4.
312. Frances C, Boisnic S, Etienne S et al. Effect of the local application of cyclosporine A on chronic erosive lichen planus of the oral cavity. *Dermatologica* 1988; 177: 194-5.
313. Pacor ML, Biasi D, Urbani G et al. The efficacy of cyclosporin for topical use in oral lichen planus. *Minerva Stomatol* 1994; 43: 129-32.
314. Harpeneau LA, Plemons JM, Rees TD. Effectiveness of a low dose of cyclosporine in the management of patients with oral erosive lichen planus. *Oral Surg Oral Med Oral Pathol* 1995; 80: 161-7.
315. Ho VC, Conklin RJ. Effect of topical cyclosporine rinse on oral lichen planus (letter). *N Engl J Med* 1991; 325: 435.
316. Dartanel S, Sahin M, Eksioğlu M et al. Behandlung des oralen erosiven lichen planus mit topischem Cyclosporin A (Cs-A). [German]. Treatment of erosive oral lichen planus with topical cyclosporin. *Z Hautkr* 1991; 66: 148-9.
317. Levell NJ, MacLeod RI, Marks JM. Lack of effect of cyclosporin mouthwash in oral lichen planus. *Lancet* 1991; 337: 796-7.
318. Voute ABE, Schulten EAJM, Langendijk PNJ et al. Cyclosporin A in an adhesive base for the treatment of recalcitrant oral lichen planus. *Oral Surg Oral Med Oral Pathol* 1994; 78: 437-41.
319. Surber C, Itin P, Buchner S. Clinical controversy on the effect of topical cyclosporin: what is the target site? *Dermatology* 1992; 185: 242-5.

320. Page EH, Wexler DM, Guenther LC. Cyclosporin A. *J Am Acad Dermatol* 1986; 14: 785-91.
321. Mozzanica N, Cattaneo A, Legori A et al. Immunohistologic evaluation of the effect of cyclosporine treatment on the lichen planus immune infiltrate. *J Am Acad Dermatol* 1991; 24: 550-4.
322. Balato N, De Rosa S, Bordone S et al. Dermatological application of cyclosporine. *Arch Dermatol* 1989; 125: 1430-1.
323. Sloberg K, Hersie K, Mobacken H et al. Topical tretinoin therapy and oral lichen planus. *Arch Dermatol* 1979; 115: 716-8.
324. Buajeeb W, Kraivaphan P, Pobruska C. Efficacy of topical retinoid acid compared with topical fluocinolone acetonide in the treatment of oral lichen planus. *Oral Surg Oral Med Oral Pathol Oral Radiol Endod* 1997; 83: 21-5.
325. Giustina TA, Stewart JCB, Ellis CE et al. Topical application of isotretinoin gel improves oral lichen planus: A double-blind study. *Arch Dermatol* 1986; 122: 534-6.
326. Tradati N, Chiesa F, Rossi N et al. Successful topical treatment of oral lichen planus and leukoplakias with fenretinide (4-HPR). *Canc Lett* 1994; 76: 109-11.
327. Ferguson MM, Simpson NB, Hammersley N. The treatment of erosive lichen planus with a retinoid: etretinate. *Oral Surg Oral Med Oral Pathol* 1984; 58: 283-7.
328. Baudet-Pommel M, Janin-Mercier A, Souteyrand P. Sequential immunopathologic study of oral lichen planus treated with tretinoin and etretinate. *Oral Surg Oral Med Oral Pathol* 1991; 71: 197-202.
329. Bollag W, Ott F. Treatment of lichen planus with temarotene. *Lancet* 1989; ii: 974.
330. Hersle K, Mobacken H, Sloberg K et al. Severe oral lichen planus: treatment with an aromatic retinoid (etretinate). *Br J Dermatol* 1982; 106: 77-80.
331. Camisa C, Allen CM. Treatment of oral erosive lichen planus with systemic isotretinoin. *Oral Surg Oral Med Oral Pathol* 1986; 62: 393-6.
332. Laurberg G, Geiger JM, Hjorth N et al. Treatment of lichen planus with acitretin. *J Am Acad Dermatol* 1991; 24: 434-7.
333. Lozada F. Prednisolone and azathioprine in the treatment of patients with vesiculo-erosive oral diseases. *Oral Surg Oral Med Oral Pathol* 1981; 52: 257-60.
334. Lear JT, English JSC. Erosive and generalised lichen planus responsive to azathioprine. *Clin Exp Dermatol* 1996; 21: 56-7.
335. Jansen CT, Lehtinen R, Happonen RR et al. Mouth PUVA: new treatment for recalcitrant oral lichen planus. *Photodermatology* 1987; 4: 165-6.
336. Lundquist G, Forsgren H, Gajecki M et al. Photochemotherapy of oral lichen planus: a controlled study. *Oral Surg* 1995; 79: 554-8.
337. Yoke PC, Machin D. Photochemotherapy of oral lichen planus. *Oral Surg Oral Med Oral Pathol Oral Radiol Endod* 1998; 85: 2-4.
338. Kuusilehto A, Lehtinen R, Jansen CT. Comparison of the minimal phototoxic dose in topical 4,5,8-trimethylpsoralen PUVA treatment of Caucasian skin and of oral mucous membrane. *Acta Derm Venereol (Stockh)* 1990; 70: 508-9.
339. Lindelof B, Sigurgeirsson B, Tegner E et al. PUVA and cancer: a large scale epidemiologic study. *Lancet* 1991; 338: 91-3.
340. Holmstrup P, Thorn JJ, Rindrum J et al. Malignant development of lichen planus-affected oral mucosa. *J Oral Pathol* 1988; 17: 219-25.
341. Emslie ES, Hardman FG. The surgical treatment of oral lichen planus. *Trans St John's Hosp Dermatol Soc* 1970; 56: 43-4.
342. Hovick CI, Kalkwarf KL. Treatment of localised oral erosive lichen planus lesions with free soft tissue grafts. *Periodont Case Rep* 1987; 9: 21-4.

343. Tal H, Rafkin B. Cryosurgical treatment of gingival lichen planus: report of a case. *J Am Dent Assoc* 1986; 113: 629-31.
344. Leopard PJ, Poswillo DE. Practical cryosurgery for oral lesions. *Br Dent J* 1974; 136: 185-96.
345. Malurstrom M, Leikomaa H. Experiences with cryosurgery in the treatment of oral lesions. *Proc Finn Dent Soc* 1980; 76: 117-23.
346. Frame JW, Das Gupta AR, Dalton GA. Use of the carbon dioxide laser in the management of premalignant lesions of the oral mucosa. *J Laryngol Otol* 1984; 98: 1251-60.
347. Horch H, Gerlach KL, Schaefer HE. CO₂ laser surgery of oral premalignant lesions. *Oral Maxillofac Surg* 1986; 15: 19-24.
348. Chen HR. A newly developed method for treatment of oral lichen planus with ultraviolet irradiation. *J Formosan Med Assoc* 1989; 88: 248-52.
349. Nagao Y, Sata M, Tanikawa K et al. A case of oral lichen planus with chronic hepatitis C successfully treated by glycyrrhizin. *J Jpn Assoc Infect Dis* 1995; 69: 940-4.
350. Sehgal VN, Abraham GJS, Malik GB. Griseofulvin therapy in lichen planus. A double-blind control trial. *Br J Derm* 1972; 87: 383-5.
351. Sehgal VN, Bikhchandani R, Koranne RV et al. Histopathological evaluation of griseofulvin therapy in lichen planus - a double-blind controlled study. *Dermatologica* 1980; 161: 22-7.
352. Aufdemorte TB, DeVillez RL, Giesecker DR. Griseofulvin in the treatment of three cases of oral lichen planus. *Oral Surg Oral Med Oral Pathol* 1983; 55: 459-62.
353. Bagan JV, Silvestre FJ, Mestre S et al. Treatment of lichen planus with griseofulvin. Report of seven cases. *Oral Surg Oral Med Oral Pathol* 1985; 60: 608-10.
354. Naylor GD. Treating erosive lichen planus with griseofulvin: a report of four cases. *Quintessence Int* 1990; 21: 943-7.
355. Matthews RW, Scully C. Griseofulvin in the treatment of oral lichen planus: adverse drug reactions but little beneficial effect. *Ann Dentistry* 1992; 51: 10-1.
356. Colquhoun AN, Ferguson MM. An association between oral lichen planus and a persistently dry mouth. *Oral Surg Oral Med Oral Pathol Oral Radiol Endod* 2004; 98(1): 60-8.
357. Falk DK, Latour DL, King LE. Dapsone in the treatment of erosive lichen planus. *J Am Acad Dermatol* 1985; 12: 560-70.
358. Matthews RW, Pinkney RC, Scully C. The management of desquamative gingivitis with dapsone. *Ann Dent* 1991; 48: 41-3.
359. Bogaert H, Sanchez E. Lichen planus: treatment of thirty cases with systemic and topical phenytoin. *Int J Dermatol* 1990; 29: 157-8.
360. Humphris G, Field EA. Psychological factors in oral lichen planus. *Br Dent J* 1992; 173: 331.
361. Robinson HM. Aureomycin treatment of some dermatoses. *Arch Dermatol Syph* 1950; 61(3): 84-96.
362. Walchner M, Messer G, Salomon N et al. Topical tetracycline treatment of erosive oral lichen planus. *Arch Dermatol* 1999; 135: 92-3.
363. Loh HS. A clinical investigation of the management of oral lichen planus with CO₂ laser surgery. *J Clin Laser Med & Surg* 1992; 10(6): 445-9.
364. Pelisse M. The vulvo-vaginal-gingival syndrome: a new form of erosive lichen planus. *Int J Dermatol* 1989; 28: 381-4.
365. Sun A, Chiang CP, Chiou PS et al. Immunomodulation by levamisole in patients with recurrently aphthous ulcers or oral lichen planus. *J Oral Pathol Med* 1994; 4: 172-7.

366. Sharps RS. Lichen planus treated with levamisole. *J Cont Educ Dermatol* 1978; 17: 32.
367. Lu SYM, Chen WJ, Eng HL. Dramatic response to levamisole and low-dose prednisolone in 23 patients with oral lichen planus. *Oral Surg Oral Med Oral Pathol* 1995; 80: 705-9.
368. Hard S, Holmberg P. Penicillin treatment of lichen ruber planus. *Acta Derm Venereol (Stockh)* 1954; 34: 72.
369. MRC (Medical Research Council). Systemic antibiotics in certain dermatoses (abstract). *Br Med J* 1954; 1: 856.
370. Eisen D. The vulvovaginal-gingival syndrome of lichen planus. *Arch Dermatol* 1994; 130: 1379-82.
371. Ronbeck BVA, Lind PO, Thrane PS. Desquamative gingivitis: preliminary observations with tetracycline treatment. *Oral Surg Oral Med Oral Pathol* 1990; 69: 694-7.
372. Eisen D. Hydroxychloroquine sulfate (Plaquenil) improves oral lichen planus: an open trial. *J Am Acad Dermatol* 1993; 28: 609-12.
373. Sato M, Yoshida H, Yanagawa T et al. Therapeutic effect of human fibroblast interferon on premalignant lesions arising in the oral mucosa. *Int J Oral Surg* 1985; 14: 184-94.
374. Doutre MS, Beylot C, Couzigou P et al. Lichen planus and virus C hepatitis: disappearance of the lichen under interferon alpha therapy (letter). *Dermatology* 1992; 184: 229.
375. Hildebrand A, Kolde G, Luger T et al. Successful treatment of generalized lichen planus with recombinant interferon alpha-2b. *J Am Acad Dermatol* 1995; 33: 880-3.
376. Protzer U, Ochsendorf ER, Leopolder-Ochsendorf A et al. Exacerbation of lichen planus during interferon alfa-2a therapy for chronic active hepatitis C. *Gastroenterol* 1993; 104: 903-5.
377. Nagao Y, Sata M, Ide T et al. Development and exacerbation of oral lichen planus during and after interferon therapy for hepatitis C. *Eur J Clin Invest* 1996; 26: 1171-4.
378. Shiohara T, Nickoloff BJ, Moriya N et al. In vivo effects of interferon-gamma and anti-interferon-gamma antibody on the experimentally induced lichenoid tissue reaction. *Br J Dermatol* 1988; 119: 199-206.
379. Naafs B, Faber WR. Thalidomide therapy. An open trial. *Int J Dermatol* 1985; 24: 131-4.
380. Dereure O, Basset-Seguin N, Guilhou J. Erosive lichen planus: dramatic response to thalidomide. *Arch Dermatol* 1996; 132: 1392-3.
381. Popovsky JL, Camisa C. New and emerging therapies for diseases of the oral cavity. *Dermatol Clin* 2000; 18(1): 113-25.
382. Hodak E, Yosipovitch G, David M et al. Low-dose low-molecular-weight heparin (enoxaparin) is beneficial in lichen planus: a preliminary report. *J Am Acad Dermatol* 1998; 38: 564-8.
383. Sun M, Qian DH, Chen YH. Effect of diethyldithiocarbamate on interleukin-2 production of patients with oral lichen planus and its clinical therapeutic efficacy. *Chung Kuo Yao Li Hsueh Pao* 1991; 12: 378-80.
384. Barer GM, Polovets ML. The use of eiconol in the combined treatment of lichen ruber planus of the oral mucosa. *Stomatologiia (Mosk)* 1995; 74: 22-5.
385. Kupriianova TA, Markov BP, Vilkova LA et al. The use of permanent magnetic field in the combined treatment of lichen ruber planus of the oral mucosa. *Stomatologiia* 1989; 68: 33-4.

386. Maksimovskaia LN, Barashkov GN, Trestov NG et al. The methods of modern reflexotherapy in the combined treatment of patients with erosive-ulcerative process of the oral mucosa. *Stomatologiya (Mosk)* 1991; 4: 36-7.
387. Fullin HJ. Cancer development in oral lichen planus: a follow-up study of 327 patients. *Arch Dermatol* 1973; 108: 667-9.
388. Mattsson U, Jontell M, Holmstrup P. Oral lichen planus and malignant transformation: is a recall of patients justified? *Crit Rev Oral Biol Med* 2002; 13: 390-6.
389. van der Meij EH, Schepman KP, van der Waal I. The possible premalignant character of oral lichen planus and oral lichenoid lesions: A prospective study. *Oral Surg Oral Med Oral Pathol Oral Radiol Endod* 2003; 96: 164-71.
390. Mignogna MD, Lo Muzio L, Lo Russo L et al. Clinical guidelines in early detection of oral squamous cell carcinoma arising in oral lichen planus: a 5-year experience. *Oral Oncol* 2001; 37: 262-7.
391. Voute ABE, de Jong WFD, Schulten EAJM et al. The possible premalignant character of oral lichen planus: the Amsterdam experience. *J Oral Pathol Med* 1992; 21: 326-9.
392. van der Meij EH, Bezemer PD, van der Waal I. Cost-effectiveness of screening for the possible development of cancer in patients with oral lichen planus. *Comm Dent Oral Epidemiol* 2002; 30: 342-51.
393. Allen CM. Is lichen planus really malignant? *Oral Surg Oral Med Oral Pathol Oral Radiol Endod* 1998; 85: 347.
394. Pelisse M, Leibowitch M, Sedel D et al. Un nouveau syndrome vulvo-vaginal-gingival: lichen plan erosif plurimuqueux. [French]. *Ann Dermatol* 1982; 109: 797-8.
395. Gougerot H, Burnier R. Lichen plan du col utérin, accompagnant un lichen plan jugal et un lichen plan stomacal: lichen plurimuqueux sans lichen cutané. [French]. *Bull Soc Fr Dermatol Syphiligr* 1937; 44: 637-40.
396. Bermejo A, Bermejo MD, Roman P et al. Lichen planus with simultaneous involvement of the oral cavity and genitalia. *Oral Surg* 1990; 69: 209-16.
397. Ramer MA, Altchek A, Deligdisch L et al. Lichen planus and the vulvovaginal-gingival syndrome. *J Periodontol* 2003; 74: 1385-93.
398. Mous HVH, Helmerhorst TJM, den Hollander JC et al. Vulvovaginale klachten, dyspareunie en orale mucosa-afwijkingen: erosieve lichen planus. [Dutch]. *Vulvovaginal symptoms, dyspareunia and oral mucosal disorders: erosive lichen planus. Ned Tijdschr Geneesk* 2002; 146(19): 881-5.
399. Cribier B, Ndiaye I, Grosshans E. The penogingival syndrome: an equivalent of the vulvo-vagino-gingival syndrome in males? *Rev Stomatol Chir Maxillofac* 1993; 94: 148-51.
400. Byrd JA, Davis MDP, Rogers RS. Recalcitrant symptomatic vulvar lichen planus. *Arch Dermatol* 2004; 140: 715-20.
401. Walsh DS, Dunn CL, Konzelman J et al. A vaginal prosthetic device as an aid in treating ulcerative lichen planus of the mucous membrane. Successful combination therapy with a corticosteroid-bioadhesive compound and iontophoresis. *Arch Dermatol* 1995; 131: 265-7.
402. Dwyer CM, Kerr RE, Millan DW. Squamous carcinoma following lichen planus of the vulva. *Clin Exp Dermatol* 1995; 20: 171-2.
403. Franck JM, Young AW. Squamous cell carcinoma in situ arising within lichen planus of the vulva. *Dermatol Surg* 1995; 21: 890-4.
404. Lewis FM, Harrington CI. Squamous cell carcinoma arising in vulval lichen planus. *Br J Dermatol* 1994; 131: 703-5.

405. Ball SB, Wojnarowska F. Vulvar dermatoses: lichen sclerosus, lichen planus, and vulvar dermatitis/lichen simplex chronicus. *Semin Cutan Med Surg* 1998; 17: 182-8.
406. Ridley CM, Neill SM. Non-infectious cutaneous conditions of the vulva. In: Ridley CM, Neill SM. *The vulva*. Oxford, Blackwell Science 1999; 164-8.
407. Bain L, Geronemus R. The association of lichen planus of the penis with squamous cell carcinoma in situ and with verrucous squamous cell carcinoma. *J Dermatol Surg Oncol* 1989; 15: 413-7.
408. Cox NH. Squamous cell carcinoma arising in lichen planus of the penis during topical cyclosporin therapy. *Clin Exp Dermatol* 1996; 21: 323-4.
409. Ive FA. The umbilical, perianal and genital regions. In: Rook/Wilkinson/Ebling. *Textbook of Dermatology*. Champion RH, Burton JL, Burns DA, Breathnach SM. 6th edn. Vol 4. Oxford: Blackwell Science Ltd 1998; 3163-238.
410. Neumann R, Dutt CJ, Foster CS. Immunohistopathologic features and therapy of conjunctival lichen planus. *Am J Ophthalmol* 1993; 115: 494-500.
411. Dhermy P, Haye C, Pouliquen Y et al. Le lichen de la conjunctive. [French]. *J Fr Ophtalmol* 1983; 6: 51-7.
412. Burton JL, Scully C. The lips. In: Rook/Wilkinson/Ebling. *Textbook of Dermatology*. Champion RH, Burton JL, Burns DA, Breathnach SM. 6th edn. Vol 4. Oxford: Blackwell Science Ltd 1998; 3125-47.
413. Itin PH, Schiller P, Gilli L et al. Isolated lichen planus of the lip. *Br J Dermatol* 1995; 132: 1000-2.
414. Allan SJR, Buxton PK. Isolated lichen planus of the lip. *Br J Dermatol* 1996; 135: 145-6.
415. Parkin DM, Whelan SL, Ferlay J et al. *Cancer incidence in five continents, Vol VII (IARC Scientific publications Nr. 143)*. Lyon: IARC. 1997.
416. Pindborg JJ, Reichart PA, Smith CJ et al. *International histological classification of tumours. Histological typing of cancer and precancer of the oral mucosa*. 2nd edn. World Health Organization. Berlin Heidelberg New York: Springer-Verlag. 1997.
417. Dickens CM, Heseltine D, Walton S et al. The oesophagus in lichen planus: an endoscopic study. *Br Med J* 1990; 300: 84.
418. Souto P, Sofia C, Cabral JP et al. Oesophageal lichen planus. *Eur J Gastroenterol Hepatol* 1997; 9: 725-7.
419. Arndt KA. Lichen planus. In: *Dermatology in general medicine*. 3rd edn. Fitzpatrick TB, Eisen AZ, Wolff K, editors. New York: McGraw-Hill, 1987; 967-73.
420. Harman RRM. Letter from Ibadan. *Br J Dermatol* 1962; 74: 416-20.
421. Beer WE, Machin D. The seasonal incidence of lichen planus. *Trans St Johns Hosp Dermatol Soc* 1960; 54: 69-72.
422. Solomon LM, Zubkov B. Lichen planus and lichen nitidus. In: *Textbook of Pediatric Dermatology*. Harper J, Oranje AP, Prose N. Edn 1. Vol 1. Oxford: Blackwell Science Ltd 2000; 678-95.
423. Burton JL, Holden CA. Eczema, lichenification and prurigo. In: Rook/Wilkinson/Ebling. *Textbook of Dermatology*. Champion RH, Burton JL, Burns DA, Breathnach SM. 6th edn. Vol 1. Oxford: Blackwell Science Ltd 1998; 667-70.
424. Basarab T, Poon E, Griffiths WAD. A review of the clinical spectrum of lichen planus. *Retinoids* 1998; 14(3): 99-104.
425. Castano E, Lopez-Rios F, Alvarez-Fernandez JG et al. Verrucous carcinoma in association with hypertrophic lichen planus. *Clin Exp Dermatol* 1997; 22: 23-5.

426. Gougerot H. Formes atypiques, non papuleuses du lichen plan. Prurit lichénien sans éruption. Formes érythémateuses et érythématosquameuses sans papules. Glossodynies et neuralgies des muqueuses sans lichen muqueux. [French]. *J Praticien* 1926; 39: 614-46, 658-62.
427. Agaki A, Ohnishi Y, Tajima S et al. Linear hyperpigmentation with extensive epidermal apoptosis: a variant of linear lichen planus pigmentosus. *J Am Acad Dermatol* 2004; 50: 78-80.
428. Little EG. Lichen spinulosus with folliculitis decalvans. *Proc Roy Soc Med* 1921; 14: 67-72.
429. Tegner E. Solitary lichen planus simulating malignant lesions. *Acta Derm Venereol (Stockh)* 1958; 159: 263-6.
430. Belaich S, Bonvalet D, Civatte J. Lichen plan folliculaire tumidus rétroauriculaire. [French]. *Ann Dermatol Venereol* 1977; 104: 147-50.
431. Gupta AK, Gorsulowsky DC. Unilateral lichen planus - an unusual presentation. *Arch Dermatol* 1987; 123: 295-6.
432. Marks R. The pathology and the pathogenesis of lichen planus. *Retinoids* 1998; 14(4): 123-6.
433. Copeman PWM, Schroeter AL, Kierland RR. An unusual variant of lupus erythematosus. *Arch Dermatol* 1970; 83: 269-72.
434. Romero RW, Nesbitt LT, Reed RJ. Unusual variant of lupus erythematosus or lichen planus. *Arch Dermatol* 1977; 113: 741-8.
435. Kaposi M. Lichen ruber pemphigoides. *Arch Dermatol Syphilol* 1892; 24: 343-6.
436. Barrett AJ. Graft-versus-host disease: a review. *J R Soc Med* 1987; 80: 370-3.
437. Barrett AP. Oral complications of bone marrow transplantation. *Aust NZ J Med* 1986; 16: 239-40.
438. Epstein JLM, Deeg HJ. Graft-versus-host disease. *New Engl J Med* 1991; 324: 667-74.
439. Saurat JH, Didier-Jean L, Gluckman E et al. Graft versus host reaction and lichen planus-like eruption in man. *Br J Dermatol* 1975; 92: 591-2.
440. Graham-Brown RAG, Jones JAG, Shaw PV et al. A graft-versus-host disease-like syndrome with carcinomatosis. *Br J Dermatol* 1987; 116: 249-52.
441. Sale GE, Shulman HM, Schubert MM. Oral and ophthalmic pathology of graft-versus-host disease in man: predictive value of the lip biopsy. *Hum Pathol* 1981; 12: 1022-30.
442. Lerner KG, Kau GF, Storb R et al. Histopathology of graft-versus-host reaction in human recipients of marrow from HLA matched sibling donors. *Transplant Proc* 1974; 6: 367-71.
443. Howe NR, Lang PG. Squamous cell carcinoma of the sole in a patient with chronic graft-versus-host disease. *Arch Dermatol* 1988; 124: 1244-5.
444. Harper JI. Cutaneous graft versus host disease. *Br J Dermatol* 1987; 295: 401-2.
445. Lombardi P, Campolmi P, Sertoli A. Lichenoid dermatitis caused by nickel salts? *Contact Dermatitis* 1983; 9: 520-1.
446. Taaffe A, Wyatte E. The red tattoo and lichen planus. *Int J Dermatol* 1980; 19: 394-6.
447. Lembo G, Balato N, Patruno C et al. Lichenoid contact dermatitis due to aminoglycoside antibiotics. *Contact Dermatitis* 1987; 17: 122-3.
448. Kawamura T, Fukuda S, Ohtake N et al. Lichen planus-like contact dermatitis due to methacrylic acid esters. *Br J Dermatol* 1996; 134: 358-60.
449. Lichter M, Drury D, Remlinger K. Lichenoid dermatitis caused by epoxy resin. *Contact Dermatitis* 1992; 26: 275.

450. Canizares O. Lichen planus-like eruption caused by color developer. *Arch Dermatol* 1959; 80: 81.
451. Rietschel RL, Fowler JF. Noneczematous contact dermatitis. In: *Fisher's Contact Dermatitis*. 5th edn. Philadelphia. Lippincott Williams & Wilkins 2001; 76-7.
452. De Graciansky P, Bouille S. Skin disease from colour developers. *Br J Dermatol* 1966; 78: 297-8.
453. Sharma VK, Mandal SK, Sethuraman G et al. Para-phenylenediamine-induced lichenoid eruptions. *Contact Dermatitis* 1999; 41: 40.
454. Calnan CD. Lichenoid dermatitis from isopropylaminodiphenylamine. *Contact Dermatitis Newsletter* 1971; 10: 237.
455. Liden C. Lichen planus in relation to occupational and non-occupational exposure to chemicals. *Br J Dermatol* 1986; 115: 23-31.
456. Winkelmann RK, Harris RB. Lichenoid delayed hypersensitivity reactions in tattoos. *J Cutan Pathol* 1979; 6: 59-65.
457. Parodi G, Guarrera M, Rebora A. Lichenoid photocontact dermatitis to musk ambrette. *Contact Dermatitis* 1987; 16: 136-8.
458. Almeyda J, Levantine A. Lichenoid drug eruptions. *Br J Dermatol* 1971; 85: 604-7.
459. Bauer F. Quinacrine hydrochloride drug eruption (tropical lichenoid dermatitis). *J Am Acad Dermatol* 1981; 4: 239-48.
460. Torrelo A, Sonia C, Rocamora A et al. Lichen planus-like eruption with esophageal involvement as a result of cyanamide. *J Am Acad Dermatol* 1990; 23: 1168-9.
461. Schmitt CL, Alpins O, Chambers G. Clinical investigations of a new cutaneous entity. *Arch Dermatol Syph* 1945; 52: 226-38.
462. van den Haute V, Antoine JL, Lachapelle JM. Histopathological discriminant criteria between lichenoid drug eruption and idiopathic lichen planus: retrospective study on selected samples. *Dermatologica* 1989; 179: 10-3.
463. Firth NA, Reade PC. Comparison of eosinophil densities in oral mucosal lichen planus and lichenoid drug reactions. *J Oral Pathol Med* 1990; 19: 86-8.
464. Watanabe C, Hayashi T, Kawada A. Immunofluorescence study of drug-induced lichen planus-like lesions. *J Dermatol (Tokyo)* 1981; 8: 473-7.
465. Zurcher K, Krebs A. Cutaneous drug reactions. An integral synopsis of today's systemic drugs. Kärger, 2nd edn, 1992.
466. Bruinsma W. Oral lesions. In: *A guide to drug eruptions*. Edited by File of Medicines. 6th edn. 1995; 23, 27-8.
467. Berger TG, Dhar A. Lichenoid photo-eruptions in human immunodeficiency virus infection. *Arch Dermatol* 1994; 130: 609-13.
468. Halevy S, Shai A. Lichenoid drug eruptions. *J Am Acad Dermatol* 1993; 29: 249-55.
469. van Joost Th, Bruynzeel DP. Geneesmiddelen op de slijmvliezen grenzend aan de huid. In: *Huidafwijkingen door geneesmiddelen*. [Dutch]. Drugs and mucosal membranes adjacent to the skin. Skin diseases caused by drugs. Edited by Glaxo B.V., Zeist, The Netherlands. 1st edn. 1995; 195-206.
470. Lamey PJ, McCartan BE, MacDonald DG et al. Basal cell cytoplasmic autoantibodies in oral lichenoid reactions. *Oral Surg Oral Med Oral Pathol Oral Radiol Endod* 1995; 79: 44-9.
471. van Joost Th. Incidence of circulating antibodies reactive with basal cells of skin in drug reactions. *Acta Derm Venereol (Stockholm)* 1974; 54: 183-8.
472. Eversole LR, Miyasaki KT, Christensen RE. Keratinocyte expression of calprotectin in oral inflammatory mucosal diseases. *J Oral Pathol Med* 1993; 22: 303-7.

- 473. Walton LJ, Thornhill MH, Macey MG et al. Cutaneous lymphocyte associated antigen (CLA) and alpha beta 7 integrins are expressed by mononuclear cells in skin and oral lichen planus. *J Oral Pathol Med* 1997; 26: 402-7.
- 474. Sklavounou A, Chrysomali E, Scorilas A et al. TNF-alpha expression and apoptosis-regulating proteins in oral lichen planus: a comparative immunohistochemical evaluation. *J Oral Pathol Med* 2000; 29: 370-5.
- 475. Trehan M, Taylor CR. Low-dose excimer 308-nm laser for the treatment of oral lichen planus. *Arch Dermatol* 2004; 140(4): 415-20.
- 476. Wongwatana S, Leao JC, Scully C et al. Oxpentifylline is not effective for symptomatic oral lichen planus. *Oral Pathol Med* 2005; 34(2): 106-8.

CHAPTER 3

A: ORAL LICHEN PLANUS AND ALLERGY TO DENTAL AMALGAM RESTORATIONS

R. LAEIJENDECKER, MD¹ (and formerly³),
S.K. DEKKER, MD, PhD¹,
P.M. BURGER, MD¹,
P.G.H. MULDER, PhD²,
Th. VAN JOOST, MD, PhD (formerly³), and
H.A.M. NEUMANN, MD, PhD³.

ARCHIVES OF DERMATOLOGY 2004; 140: 1434-8.

Funding: None.

Conflict of interest: None.

Corresponding author: R. Laeijendecker, Department of Dermatology (location Dordwijk), Albert Schweitzer Hospital, P.O. Box 444, 3300 AK Dordrecht, The Netherlands.

Tel: 00 31 78 6541111. Fax: 11 31 78 6523866.

E-mail: R.Laeijendecker@asz.nl

¹ Department of Dermatology, Albert Schweitzer Hospital, locations Dordwijk and Sliedrecht, Albert Schweitzerplaats 25, 3318 AT Dordrecht, The Netherlands.

² Department of Epidemiology and Biostatistics, Erasmus University Rotterdam, P.O. Box 1738, 3000 DR Rotterdam, The Netherlands.

³ Department of Dermatology and Venereology, Erasmus MC, University Medical Center Rotterdam, Dr Molewaterplein 40, 3015 GD Rotterdam, The Netherlands.

ABSTRACT

Background: The subject of oral lichen planus and allergy to dental amalgam restorations is still controversial.

Objectives: To determine contact allergies in patients with oral lichen planus and to monitor the effect of partial or complete replacement of amalgam fillings following a positive patch test reaction to ammoniated mercury, metallic mercury, or amalgam.

Methods: In group A (20 patients), the oral lesions were confined to areas in close contact with amalgam fillings. In group B (20 patients), the lesions extended 1 centimeter beyond the area of contact with amalgam fillings. In group C (20 patients), the oral lesions had no topographic relationship with amalgam fillings. Partial or complete replacement of amalgam fillings was recommended if there was a positive patch test reaction to ammoniated mercury, metallic mercury, or amalgam. Control group D (20 patients) had signs of allergic contact dermatitis .

Results: Amalgam fillings were replaced in 13 patients of group A, with significant improvement. Dental amalgam was replaced in 8 patients of group B, with significant improvement. In group C, amalgam replacement in 2 patients resulted in improvement in 1 patient. These results were evaluated after 3 months. No positive patch tests to mercury compounds were found in patients with concomitant cutaneous lichen planus and in group D.

Conclusions: Contact allergy to mercury compounds is important in the pathogenesis of oral lichen planus, especially if there is close contact with amalgam fillings and if no concomitant cutaneous lichen planus is present. In cases of positive patch test reactions to mercury compounds, partial or complete replacement of amalgam fillings will lead to a significant improvement in nearly all patients.

Keywords: Allergy, Dental amalgam, Mercury, Oral lichen planus

Introduction

Oral lichen planus (OLP) has a prevalence of about 0.5 to 2%. Generally, it is a disease of the middle-aged and the elderly and the female-to-male ratio is about 2: 1.¹⁻⁴ OLP can be categorized into several clinical variants. The hyperkeratotic variant is usually asymptomatic. The atrophic or erythematous variant and the erosive or ulcerative variant mostly have persistent symptoms of pain or stinging. The various terms for OLP in the literature are oral lichenoid lesions, lichenoid contact lesions, and lichenoid contact stomatitis and are used interchangeably, which is confusing. In this study, we only use the term oral lichen planus (OLP) because there is no reliable difference in clinical practice based on the symptoms of the disease, clinical examination and histopathological findings.^{5-8,13} Oral lichen planus is usually a very persistent disorder and may last many years, despite several kinds of treatment.⁹ The exact cause of OLP remains unknown, but an immune-mediated (T-cell dependant) pathogenesis is proposed.^{1,3,12}

The concept of contact allergy to dental restorative materials aggravating or inducing OLP is well recognized but somewhat controversial.^{14,18,29} However, several authors have reported resolution of signs and symptoms in OLP after replacement of amalgam, particularly if there was a positive patch test result to mercury, which is the most important allergen in amalgam.^{6,15-17}

The aim of this study was to determine contact allergies in patients with OLP and amalgam fillings and to investigate whether there are specific subgroups of patients with OLP, based on differences in the relationship between oral lesions and amalgam fillings. A second objective was to monitor the effect of partial or complete replacement of dental amalgam restorations following a positive patch test reaction to ammoniated mercury, metallic mercury, or amalgam.

Patients and methods

This prospective non-randomized control study included 80 white patients who were older than 18 years with one or more silver amalgam fillings. Sixty patients had the diagnosis of OLP established on the basis of medical history, physical examination and histopathological evaluation. They were categorized into 3 equal groups based on the topographic relationship between the oral lesions and the amalgam fillings. In group A (20 patients), the oral lesions were confined to areas in close contact with amalgam fillings. In group B (20 patients), the lesions extended 1 cm beyond the area of contact with amalgam. In group C (20 patients), the oral lesions had no topographic relationship with dental amalgam restorations. A control group D (20 patients) had allergic contact dermatitis without any oral pathologic evidence of OLP. Patient recruitment ended when

there were 20 patients in each group. Six (7.5 %) patients (1 each in groups A and B, and 2 each in groups C and D) were lost to follow-up prematurely, and another 6 patients were substituted. The study was carried out from 1991-1993 at the Department of Dermatology and Venereology, Erasmus Medical Center, University Hospital Rotterdam, and continued from 1994-2001 at the Department of Dermatology, Albert Schweitzer Hospital.

Patch tests with a standard series (according to the European standard series) and a dental metal series (Table I) were occluded with Finn-chambers on the skin and evaluated after 72 hours. The reactions were read 30 minutes after removal of the patches to minimize false-positive readings. Erythematous and indurated test results were regarded as positive. If there was only an erythema-

Table I: Patch test antigens

Standard series

Potassium dichromate 0.5% pet	Mercapto mix 1% pet
Neomycin sulfate 20 % pet	Epoxy resin 1% pet
Thiuram mix 1% pet	Paraben mix 16% pet
Paraphenylenediamine 1% pet	Paratertiary butylphenol formaldehyde resin 1% pet
Cobalt chloride 1% pet	Fragrance mix 8% pet
Benzocaine 5% pet	Quaternium-15 1% pet
Formaldehyde 1% aq	Nickel sulfate 5% pet
Colophony 20 % pet	Kathon CG (methyl[chloro]isothiazoline) 0.01% aq
Clioquinol 5% pet	Mercaptobenzothiazole 2% pet
Balsam of Peru 25% pet	Sesquiterpene lactone mix 0.1% pet
N-isopropyl-N-phenylparaphenylenediamine 0.1% pet	Primine 0.01% pet
Wool alcohols 30% pet	Cocamidopropyl betaine 1% aq

Dental metal series

Ammoniated mercury 1% pet (*) (1)	Zinc chloride 2.5% pet
Copper sulfate 2% pet	Copper oxide 5% pet
Potassium dicyanoaurate 0.002% aq	Aluminium chloride hexahydrate 2% pet
Sodium thiosulfatoaurate 0.25% pet	Tin 50% pet
Ammonium tetrachloroplatinate 0.25% pet	Thimerosal 0.1% pet (**) (2)
Metallic (elementary) mercury 0.5 % pet (*)	Ferrous sulfate 5% pet
Gold sodium thiosulfate 0.5% pet	Gallium oxide 1% pet
Palladium chloride 1% pet	Titanium oxide 1% pet
Cadmium chloride 1% aq	Zirconium oxide 0.1% pet
Silver nitrate 1% aq	Amalgam 5% pet (*) (= pulverized amalgam powder)
Gold(tri)chloride 0.5% aq	

(*) : inorganic mercury compounds

(**): organic mercury compounds

(1) : mercury ammoniumchloride

(2) : thiomersal or merthiolate

pet : in petrolatum

aq : aqueous solution

tous patch test reaction (which was regarded as negative), another evaluation was made after three days and, if necessary, several days or weeks later. Patients were instructed to return if there was a possible late positive reaction. Replacement of amalgam fillings was recommended in case of a positive patch test reaction to ammoniated mercury, metallic mercury, or amalgam. Alternative dental restorations consisted of composite resins, glass-ionomers, ceramics (porcelain) and gold.

If there was a positive patch test reaction to ammoniated mercury, metallic mercury, or amalgam in groups A and B, the advice was first given to replace the amalgam fillings in close contact with the oral lesions. If there was a significant improvement in the lesions, the patients were advised to replace any remaining part of the amalgam in the dental fillings in the future, but only for dental reasons. In group C, all dental amalgam was replaced if there was a positive patch test reaction to the allergens. In group D, no advice on replacement of amalgam fillings was given. In all groups, participants were advised to desist from new dental amalgam restorations in the future if there was a positive reaction to one or more mercury compounds.

One or two 3-mm punch biopsy specimens for histopathological examination were taken from the hyperkeratotic or erythematous lesions and if there was an erosion or ulceration at the edge of the lesions from all patients in groups A, B and C. The biopsy specimens were fixed in buffered 4% formalin and stained with hematoxylin-eosin and the periodic acid-Schiff reaction. If there were obvious erosions in OLP, the biopsy specimens were transported in physiological isotonic sodium chloride to the laboratory for direct immunofluorescence to exclude a bullous auto-immune disease or lupus erythematosus.

Histopathological changes in OLP comprise varying degrees of focal hyperkeratosis or parakeratosis, irregular acanthosis or atrophy, liquefaction degeneration of the basal cell layer and, characteristically, a dense band-like lymphocytic infiltrate high in the lamina propria. Hyaline (Civatte's) bodies, which represent degenerated basal cells, are occasionally seen in the epithelium. If the histopathological changes in the mucosa were less pronounced (especially the basal cell layer degeneration and the inflammatory infiltrate), the diagnosis of "compatible with OLP" was made. If there were more aspecific changes, this was diagnosed as "non-specific". If there were signs of cutaneous lichen planus (CLP), histopathological examination of the skin lesions was performed.

The clinical effect of treatment in the patients with OLP was graded as worse (-), unchanged (\pm), improved (+) and healed (++)

Statistical analysis of the results was performed by means of the exact chi-square test for trend, the Fisher's exact test, the one-way ANOVA test, and the Kruskal-Wallis test, in which two-sided P values were calculated (with a statistical significance set at $P < 0.05$).

Results

The basic characteristics, such as sex, age, duration of the lesions before patch testing, and number of dental amalgam fillings, in groups A, B, C and D are shown in Table II and did not differ significantly ($P > 0.05$). The most commonly affected areas in OLP were the buccal mucosa, the lateral part of the tongue, and, less frequently, the gingiva. In the groups A, B, and C, histopathological examination led to a diagnosis of OLP in 30% (18/60) of the patients, a diagnosis compatible with OLP in 35% (21/60) of the patients, and a diagnosis of non-specific changes in 35% (21/60) of the patients. These results were irrespective of positive or negative patch test reactions to mercury compounds. Direct immunofluorescence was performed in 6 patients, and the results were not compatible with a diagnosis other than OLP. In the 3 groups with oral lesions, the clinical variant of OLP and the histopathological examinations were not significantly different. Seven (11.7%) patients from among 60 patients with OLP had concomitant CLP (Table II). The exact chi-square test for trend in groups A, B and C showed a statistically significant difference ($P = 0.024$) in the concomitance of CLP. Moreover, no positive patch test reactions to mercury compounds were found in the patients with concomitant CLP. The positive patch test reactions to the organic or inorganic mercury compounds are shown in Table III. No positive patch test reactions to organic and inorganic mercury compounds were found in group D. Partial or complete

Table II. Clinical characteristics of the patients.

Patients	Group A	Group B	Group C	Group D (Control)
Women/men (total)	15/5 (20)	14/6 (20)	13/7 (20)	13/7 (20)
Age range (mean) in years	28-75 (50)	32-76 (53)	34-79 (56)	26-70 (47)
Duration of lesions before patch testing in years (mean)	0.5-4 (2)	0.4-4.5 (2)	0.5-6 (3)	0.4-4 (2)
Number of amalgam fillings (mean)	2-11 (6)	2-12 (6)	2-11 (5)	1-12 (5)
OLP: mainly hyperkeratotic variant (1)	11	10	10	–
„ erosive or atrophic “ (2)	3	2	1	–
„ a combination of (1) and (2)	6	8	9	–
CLP	–	2	5	–
Histopathological examination				
evident OLP	5	7	6	–
compatible with OLP	6	7	8	–
nonspecific changes	9	6	6	–
evident CLP	–	2	5	–

– = not present

Table III. Incidence of positive patch test reactions to organic and inorganic mercury compounds.

(Group)	A	B	C	D
Number of tested patients	20	20	20	20
1. Ammoniated mercury	5	3	1	–
2. Metallic mercury	2	1	1	–
3. Amalgam	–	–	–	–
4. Thimerosal	–	–	–	–
1, 2 and 3. (Ammoniated mercury, metallic mercury and amalgam)	2	2	–	–
1 and 2. (Ammoniated mercury and metallic mercury)	3	1	–	–
1, 2 and 4. (Ammoniated mercury, metallic mercury and thimerosal)	1	1	–	–
Number of patients with one or more positive patch test reactions	13	8	2	0

Table IV. Clinical results of partial or complete replacement of dental amalgam restorations in patients with OLP with positive patch test reactions to one or more mercury compounds.

Group	A	B	C
Healed (++)	11	5	–
Improved (+)	2	3	1
Unchanged (±)	–	–	1
Worse (–)	–	–	–
Number of patients	13	8	2

replacement of amalgam fillings in patients with OLP with positive patch test reactions to mercury compounds was successful in nearly all patients (Table IV). All patients with OLP without positive patch test reactions to mercury compounds and without the recommendation of replacement of amalgam fillings had unchanged oral lesions. One patient in group A had an amalgam replaced of his own accord, despite a negative patch test reaction to inorganic mercury compounds. His oral lesions did not change at all.

Statistical analysis was performed in an overall test per mercury compound (exact chi-square test) in the 4 groups, with a significant difference for ammoniated mercury and metallic mercury ($P < 0.0005$). There were no significant differences for amalgam ($P = 0.109$) and thimerosal ($P = 0.373$) (Table III). In the Fisher's exact test, comparisons in pairs were performed for ammoniated mercury and metallic mercury, with significant differences between the groups A and D ($P < 0.0005$ and $P < 0.003$) and groups B and D ($P < 0.008$ and $P < 0.047$) (Table III). In the exact chi-square test (linear-by-linear association), there was a significant dif-

ference ($P = 0.01$) in the tendency of healing whether the amalgam fillings were more associated with OLP and whether there was a positive patch test reaction to ammoniated mercury or metallic mercury (Table IV).

Other positive reactions occurred in group A to nickel sulfate (2 patients), fragrance mix (1 patient), silver nitrate (1 female patient, who also had a positive reaction to ammoniated mercury) and thiuram mix (1 patient). Other positive reactions occurred in group B to nickel sulfate (1 patient), fragrance mix (1 patient), Kathon CG (5-chloro-2-methyl-4-isothiazolin-3-one and 2-methyl-4-isothiazolin-3-one) (1 patient), potassium dichromate (1 patient) and palladium chloride (1 patient). Other positive reactions occurred in group C to nickel sulfate (1 patient), fragrance mix (1 patient), balsam of Peru (1 patient) and neomycin sulfate (1 patient). There were no significant differences between the occurrence of positive reactions and the specific variant of OLP.

In group D, positive reactions occurred to nickel sulfate (4 patients), fragrance mix (3 patients), formaldehyde (2 patients), colophony (2 patients), balsam of Peru (2 patients), paraben mix (1 patient), Quaternium-15 (1 patient), cocamidopropyl betaine (2 patients), benzocaine (1 patient) and cobalt chloride (1 patient).

In 8 (35%) of 23 patients, positive patch test reactions to ammoniated mercury, metallic mercury or amalgam only occurred after the regular 3-day evaluation, with a variation of 5 to 18 days (mean, 8 days). Moreover, there were persistent patch test reactions in 6 (26%) of 23 patients, with a variation of 4 to 24 days (mean, 10 days).

The effects of replacements of amalgam fillings were mostly seen after 1 to 4 months (mean, 3 months).

If there was a positive effect of the replacement of amalgam fillings in patients with OLP, this effect did not change significantly during the follow-up of 2 to 7 years (mean, 4 years). In the patients without replacement of dental amalgam restorations, the lesions remained unchanged during the follow-up. No malignant transformation of OLP was observed in this study.

Discussion

Amalgam has been used as a dental restorative material since its inception in 1831 for people all over the world, with few adverse effects.¹⁹ It is good for dental use because it is strong, long lasting, well fitting, easy to handle, and cheap. Conventional silver amalgam fillings consist of about 50% mercury and about 50% alloy powder containing silver, tin, copper and zinc.^{16,32} Mercury and mercury compounds appear to be the most common allergens in amalgam, with the other metals being rarely responsible for allergic reactions.^{6,31} Contact sensitivity to mercury in amalgam confirmed by patch testing was previously reported by Shovelton.²⁰ Amalgam in the oral cavity is prone to corrosion,

and by releasing metal ions, may be responsible for sensitization and allergic reactions (type IV, T-cell dependant).^{19,25} This process may lead to long-term antigenic stimulation, with mucosal changes, and ultimately to OLP. A less favorable hypothesis is that close contact between dissimilar metals (eg, amalgam and gold) may produce different potentials and lead to electrochemical reactions (electrogalvanism), corrosion, and increased release of metal ions, also leading to mucosal changes.^{6,27} Martin et al reported that the presence of amalgam or gold was not associated with increased risk of OLP, but that the corrosion of amalgam and the presence of electrogalvanism from dissimilar dental materials in continuous contact (bimetallism) were associated with increased risk of OLP.³⁴ The incidence of positive patch test reactions to mercury compounds and OLP varied considerably in several studies and depended largely on whether the mucosal lesions were in direct contact with amalgam (34%-85%) (65% [13/20] in our study) or not (0% -33%) (10% [2/20] in our study) and on the specific allergens and the concentrations that were used to detect allergy to mercury.^{14,21,26} Mercury is able to penetrate the healthy and the compromised mucosa, but the circumstances in which sensitization occurs are not exactly known. It is reasonable to say that possible involved allergens are dissolved and spread via saliva; therefore, mucosal reactions may extend beyond the contact areas.^{22,26}

From our study, it appeared that there were essential differences in the incidence of contact allergy to mercury compounds between the groups A, B and C based on the topographic relationship of amalgam and OLP (especially if there is an asymmetry). Moreover, no positive patch test reactions to mercury compounds were found in group D. In the case of positive patch test reactions to ammoniated mercury, metallic mercury or amalgam, partial or complete replacement of amalgam fillings is beneficial after several months. This suggests that, in these cases, contact allergy is an important etiologic factor in OLP. Moreover, there is frequently more than one positive reaction to mercury compounds, which favors true sensitization and underlines the clinical importance.^{6,21,30} The most reliable allergen for silver dental amalgam allergy in our study was ammoniated mercury. Less reliable allergens are (in diminishing frequency) metallic (elementary) mercury, amalgam, and thimerosal (thiomersal). Mercury chloride was used in patch tests in some studies if there was a suspicion of allergy to mercury.^{6,23} However, in our opinion, it is not a reliable allergen because the literature also states that it is a strong sensitizer and often produces a non-specific pustular or an irritant reaction even when diluted to a 0.05% aqueous solution. It is wise to test ionized mercury (ammoniated mercury or mercury chloride [0.1% mercury chloride in petrolatum is perhaps better than a 0.05% mercury chloride aqueous solution]) and nonionized mercury (metallic mercury and amalgam).²³ An important issue is that positive reactions to inorganic mercury compounds may occur after the regular evaluation of 3 days, a finding in 35% (8/23) of the patients in our study. This may be a major cause of the

different frequencies of positive reactions in the literature. The same phenomenon may occur with several other allergens such as gold, palladium chloride, potassium dichromate, neomycin sulfate, and paraphenylenediamine.^{17,21,23} Histopathological examination of the positive patch test specimens in these cases often shows lichenoid in addition to eczematous changes.²¹ In some cases, there is also a different time of occlusion of the allergens. In the study by Koch and Bahmer, there was an occlusion only during 1 day, with histopathological examination of the oral lesions performed in a small number of patients.¹⁷ The clinical relevance of the remaining positive patch test reactions to other allergens in relation to OLP is not clear. Gold, palladium, copper, silver and acrylates may also be responsible in the pathogenesis of OLP.¹⁸ We could not confirm the finding by Yiannias et al that allergy to flavorings may also be important in the pathogenesis of OLP. In our experience, this may be relevant in the diagnosis of allergic contact stomatitis.⁶ In the study by Yiannias et al an important aspect may be that macular erythema as a result of the patch test was regarded as positive.⁶ Dunsche et al reported that the removal of amalgam fillings should be recommended to all patients with symptomatic OLP associated with amalgam fillings if no concomitant CLP is present, regardless of patch test results to amalgam and other inorganic mercury compounds, because almost all patients (97.1%) benefited from amalgam removal. However, patients with a positive patch test reaction to amalgam showed complete healing more frequently than those with a negative patch test reaction, and in about 8% of the patients, the lesions recurred after a mean period of 14.6 months.¹³ Wong and Freeman reported that, in patients with a negative patch test result who improve after amalgam replacement, mercury may act as an irritant factor in the pathogenesis of OLP.³³ In our opinion, several other aspects may play a role in these cases, such as “ill-fitting” amalgam fillings leading to OLP by the isomorphic response or Koebner’s phenomenon (which is a common feature in lichen planus), “missed” late (after 3 days) positive patch test reactions to inorganic mercury compounds, concomitant improvement in oral hygiene during amalgam removal, possible variations in the specific allergens and concentrations, and the time of occlusion used in the patch tests.

It is reported in the literature that the inorganic mercurials (ammoniated mercury, metallic mercury and amalgam) may cross-react with the organic mercurials (thimerosal and the phenylmercuric salts).^{5,23} In this study, there was a cross-sensitivity between thimerosal (containing an organic mercury compound and a thiosalicylate) which is used as an antiseptic and as a preservative, and the inorganic mercurials, ammoniated mercury and metallic mercury in two patients. The results of this study also indicate that there are several subtypes in the 3 different groups of OLP based on accompanying aspects as CLP, because none of the patients with OLP and CLP had positive reactions to one or more organic or inorganic mercury compounds. In these patients, other factors played a major role in the pathogenesis of OLP. Replacement of amal-

gam fillings should be undertaken for good reasons with a proper diagnosis of symptomatic OLP, because it is inconvenient, annoying, time-consuming and often expensive for the patient.^{10,26}

Histopathological examination in OLP is important to exclude other diseases, but in this study, less specific or nonspecific changes were often noted in mucosal lesions irrespective of the clinical variant and the severity. This is in contrast to results of histopathological examination in CLP.^{24,28}

The possible premalignant character of OLP is still debated.²⁴ No malignancy was encountered in this study.

In conclusion, we advise that patch tests should be performed in patients with OLP especially if the lesions are in close contact with amalgam fillings and partial or complete replacement of such fillings should only be recommended if there is a positive patch test reaction to ammoniated mercury, metallic mercury, or amalgam and if there are no signs of concomitant CLP. This leads to healing or a significant improvement in the oral lesions in nearly all patients within several months.

References

1. Vincent SD, Fotos PG, Baker KA, Williams TP. Oral lichen planus: the clinical, historical and therapeutic features of 100 cases. *Oral Surg Oral Med Oral Pathol* 1990; 70: 165-71.
2. Silverman S, Gorsky M, Lozada-Nur F. A prospective follow-up study of 570 patients with oral lichen planus: persistence, remission, and malignant association. *Oral Surg Oral Med Oral Pathol* 1985; 60: 30-4.
3. Scully C, Beyli M, Ferreiro MC, Ficarra G, Gill Y, Griffiths M, et al. Update on oral lichen planus: etiopathogenesis and management. *Crit Rev Oral Biol Med* 1998; 9: 86-122.
4. Conklin RJ, Blasberg B. Oral lichen planus. *Dermatol Clin* 1987; 5: 663-73.
5. Scalf LA, Fowler JF, Morgan KW, Looney SW. Dental metal allergy in patients with oral, cutaneous, and genital lichenoid reactions. *Am J Contact Dermatitis* 2001; 12: 146-50.
6. Yiannias JA, el-Azhary RA, Hand JH, Pakzad SY, Rogers RS. Relevant contact sensitivities in patients with the diagnosis of oral lichen planus. *J Am Acad Dermatol* 2000; 42: 177-82.
7. Camisa C, Taylor JS, Bernat JR, Helm TN. Contact hypersensitivity to mercury in amalgam restorations may mimic oral lichen planus. *Cutis* 1999; 63: 189-92.
8. Pecegheiro M, Sachse MF, Amaro J, Farinha P, Fonseca I. Oral lichen planus versus oral lichenoid eruption as a manifestation of contact allergy. *Contact Dermatitis* 1999; 40: 333-4.
9. Thorn JJ, Holmstrup P, Rindum J, Pindborg JJ. Course of various clinical forms of oral lichen planus. A prospective follow-up study of 611 patients. *J Oral Pathol* 1988; 17: 213-8.
10. Laeijendecker R, Heule F, van Joost Th. [Dutch]. Oral lichen planus: clinical and immunological aspects. *Ned Tijdschr Geneeskunde* 1992; 136(44): 2167-71.

11. Eisen D. The clinical features, malignant potential, and systemic associations of oral lichen planus: a study of 723 patients. *J Am Acad Dermatol* 2002; 46: 207-14.
12. Boyd AS, Neldner KH. Lichen planus. *J Am Acad Dermatol* 1991; 25: 593-619.
13. Dunsche A, Kastel I, Terheyden H, Springer ING, Cristophers E, Brasch J. Oral lichenoid reactions associated with amalgam: improvement after amalgam removal. *Br J Dermatol* 2003; 148(1): 70-6.
14. Hietanen J, Pihlman K, Forstrom L, Linder E, Reunala T. No evidence of hypersensitivity to dental restorative metals in oral lichen planus. *Scand J Dent Res* 1987; 95: 320-7.
15. Laine J, Kalimo K, Forssell H, Happonen RP. Resolution of oral lichenoid lesions after replacement of amalgam restorations in patients allergic to mercury compounds. *Br J Dermatol* 1992; 126: 10-5.
16. Jameson MW, Kardos TB, Kirk EEJ, Ferguson MM. Mucosal reactions to amalgam restorations. *J Oral Rehabilitation* 1990; 17: 293-301.
17. Koch P, Bahmer FA. Oral lesions and symptoms related to metals used in dental restorations: a clinical, allergological, and histologic study. *J Am Acad Dermatol* 1999; 41: 422-30.
18. Laeijendecker R, van Joost Th. Oral manifestations of gold allergy. *J Am Acad Dermatol* 1994; 30: 205-9.
19. Smart ER, Macleod RI, Lawrence CM. Resolution of lichen planus following removal of amalgam restorations in patients with proven allergy to mercury salts: a pilot study. *Br Dent J* 1995; 178: 108-12.
20. Shovelton DS. Silver amalgam and mercury allergy. *Oral Surg Oral Med Oral Pathol* 1968; 25: 29-30.
21. Mollaoglu N. Oral lichen planus: a review. *Br J Oral Maxillofac Surg* 2000; 38: 370-7.
22. Bolewska J, Holmstrup P, Moller-Madsen B, Kenrad B, Danscher G. Amalgam associated mercury accumulations in normal oral mucosa, oral mucosal lesions of lichen planus and contact lesions associated with amalgam. *J Oral Pathol Med* 1990; 19: 39-42.
23. Rietschel RL, Fowler JF. Mercury. In: Fisher's Contact Dermatitis. 5th edn. Lippincott Williams & Wilkins, Philadelphia, U.S.A.; 2001: 153-4, 636, 667-9, 740, 779.
24. van der Meij EH, Schepman KP, Smeele LE, van der Wal JE, Bezemer PD, van der Waal I. A review of the recent literature regarding malignant transformation of oral lichen planus. *Oral Surg Oral Med Oral Pathol Oral Radiol Endod* 1999; 88: 307-10.
25. Ostman PO, Anneroth G, Skoglund A. Oral lichen planus lesions in contact with amalgam fillings: a clinical, histologic, and immunohistochemical study. *Scand J Dent Res* 1994; 102: 172-9.
26. Laine J, Kalimo K, Happonen RP. Contact allergy to dental restorative materials in patients with oral lichenoid lesions. *Contact Dermatitis* 1997; 36: 141-6.
27. Lundstrom IMC. Allergy and corrosion of dental materials in patients with oral lichen planus. *Int J Oral Surg* 1984; 13: 16-24.
28. van der Meij EH, Reibel J, Slootweg PJ, van der Wal JE, de Jong WFB, van der Waal I. Interobserver and intraobserver variability in the histologic assessment of oral lichen planus. *J Oral Pathol Med* 1999; 28: 274-7.
29. Bolewska J, Hansen HJ, Holmstrup P, Pindborg JJ, Sangerup M. Oral mucosal lesions related to silver amalgam restorations. *Oral Surg Oral Med Oral Pathol* 1990; 70: 55-8.

30. van Joost Th, Laeijendecker R. [Dutch]. Amalgam. VI. Allergy for mercury in dental materials; oral and systemic reactions. *Ned Tijdschr Tandheelkd* 1993; 100(7): 303-7.
31. Pang BK, Freeman S. Oral lichenoid lesions caused by allergy to mercury in amalgam fillings. *Contact Dermatitis* 1995; 33: 423-7.
32. Bircher AJ, von Schulthess A, Henning G. Oral lichenoid lesions and mercury sensitivity. *Contact Dermatitis* 1993; 29: 275-6.
33. Wong L, Freeman S. Oral lichenoid lesions (OLL) and mercury in amalgam fillings. *Contact Dermatitis* 2003; 48(2): 74-9.
34. Martin MD, Broughton S, Drangsholt M. Oral lichen planus and dental materials: a case-control study. *Contact Dermatitis* 2003; 48(6): 331-6.

B: LICHENOID CONTACT STOMATITIS. IS INORGANIC MERCURY THE CULPRIT?

R.S. ROGERS III, MD¹
A.J. BRUCE, MD¹

ARCHIVES OF DERMATOLOGY 2004; 140: 1524-5.

(EDITORIAL)

Permission granted. Copyright© (2004), American Medical Association. All rights reserved.

Financial disclosure: none.

¹ Department of Dermatology, Mayo Clinic, 200 First St SW, Rochester, MN 55905-0002, U.S.A. (bruce.alison@mayo.edu).

The article by Laeijendecker et al¹ in this month's Archives on the relationship between oral lesions of lichen planus and allergy to amalgam dental restorations is another attempt to resolve some of the controversies surrounding this topic. The issues are several. First, what should we call these lesions: oral lichenoid lesions (OLL), oral lichenoid reactions, oral lichenoid tissue reactions, lichenoid contact stomatitis, lichen planus-like lesions, or oral lichen planus (OLP)?

Second, is the clinical benefit from removal related to the removal of a long-term source of antigen stimulation, producing a delayed hypersensitivity reaction, or to the removal of a source of trauma such as friction or bimetallism, producing a Koebner phenomenon?

Third, what role does patch testing play?

Nomenclature is always fun and often controversial. Some would be rigid and consider that OLP represents only those lesions for which no trigger can be identified and are "idiopathic". This excludes drug-induced OLP and OLP associated with chronic liver disease, food or flavor allergies, hypertension, and diabetes mellitus, as well as other conditions. The oral mucosa has, like the skin, a limited repertoire of reactions, one of which is a hyperkeratotic, white, thickened, inflammatory reaction said to be "lichenoid". Therefore, the terms OLL, oral lichenoid reactions, oral lichenoid tissue reactions, lichenoid contact stomatitis, lichen planus-like lesions, and OLP have all been used in describing this reaction.

It is difficult, if not impossible, to distinguish these lesions from one another.²⁻⁶ Dunsche et al² concluded that an unambiguous distinction between the lesions of amalgam-associated tissue changes compared with OLP in edentulous patients without dental amalgam was impossible not only clinically but also histologically. Therefore, all these terms are describing the same tissue changes. We prefer the term lichenoid contact stomatitis⁷ when the allergen and the clinical relevance are identified and OLP as the overarching rubric.

Is inorganic mercury, contained in dental amalgams, a sensitizer, and can it cause allergic contact stomatitis or lichenoid contact stomatitis? Fernstrom et al⁸ were the first to claim a connection between type IV allergy to mercurial compounds released from dental amalgam and OLP. Others have agreed.^{3,5-17}

Koch and Bahmer¹⁷ reported that 15 (78.9%) of 19 patients with OLL in close apposition to amalgam dental fillings were sensitized to inorganic mercury compounds. They noted that positive patch test readings may be delayed until days 10 or 17 and that patients often had positive reactions to multiple mercury allergens. Furthermore, they noted that positive patch test reactions were less common in those patients with OLL distant from amalgam (3/25 [12.0%]), patients with other oral diseases (2/29 [6.9%]), and control subjects (2/59 [3.4%]).

These authors noted that 13 of 15 patients with positive patch test reactions for inorganic mercury experienced OLL clearance when the dental amalgam was removed.

Scalf et al³ studied 51 patients with OLL, of whom 38 had 1 or more positive patch test reactions to a dental metal and 28 had a positive patch test reaction to inorganic mercury. When the dental metals were removed in 9 patients with positive patch test reactions, all experienced clearance, as did 1 patient with negative patch test reactions.

On the other hand, it has been proposed that bimetallism or the continuous contact of dissimilar dental metals produces electrogalvanism, which might produce OLP by a Koebner phenomenon.¹⁰ The restoration may become worn and rough, leading to friction and the Koebner phenomenon. Wong and Freeman¹⁸ reported that patients who improve after amalgam dental restoration removal and who have negative patch test reactions may be responding to the removal of an irritant, thereby reducing the element of the Koebner phenomenon.

The study by Laeijendecker et al¹ concludes that allergic contact stomatitis is important in the pathogenesis of OLP, especially when the lesions of OLP are in apposition to dental amalgam restorations. They note that those patients with positive patch test reactions to inorganic mercury whose amalgams were in close apposition had uniformly excellent outcomes after removal of dental amalgams and replacement with composite resins, glass ionomers, ceramics (porcelain), or gold, with complete clearing after a mean of 3 months in 11 of 13 patients and substantial improvement in the remaining 2 patients. These patients remained clear of lesions in follow-up for 2 to 7 years (mean, 4 years).

In addition, patients with the OLP lesions in direct apposition (tongue and buccal mucosal surfaces) to the amalgam dental restorations were more likely to have positive patch test reactions and improvement when the amalgam was removed. Those with the amalgam within 1.0 cm had fewer positive patch test reactions, but among patients with positive reactions, the results were excellent, with 5 of 8 healed and the remaining 3 substantially improved. Notably, all patients with OLP without positive patch test reactions to mercury compounds and who did not have replacement of their amalgam restorations underwent no change in their condition during the long follow-up. Laeijendecker et al¹ conclude that, if there is a positive patch test reaction to inorganic mercury, the replacement of dental amalgam restorations is beneficial and the result is noted within 1 to 4 months. The authors state that contact allergy is an important etiological factor in OLP.

Dunsche et al² evaluated 134 patients who had 467 individual oral lichenoid reactions. Biopsy specimens of 159 oral lichenoid reactions were similar to 47 OLP specimens in edentulous patients, as already noted. Of these patients, 119 had patch tests to the inorganic mercury series performed. Among them, 33 (27.7%) had positive patch test reactions. Notably, of the 134 patients, 29 refused patch testing and did not have amalgam dental restorations removed.

They served as controls. Only 2 (6.9%) of the 29 “control” patients improved with long-term follow-up. Amalgam dental restorations were removed in 105 patients regardless of patch test results. Restorations were replaced with gold, composite resins, glass ionomers, ceramics (porcelain), metal or ceramic crowns, or titanium. Clinical evaluations were carried out at 6 and 12 months and yearly thereafter.

Several important observations were made by Dunsche and coauthors.² Among patients whose amalgam dental restorations were removed, 97.1% (102/105) improved regardless of patch test results. Those with positive patch test reactions improved most. Overall, 31 (29.5%) of 105 had complete clearance. The rest demonstrated partial improvement, with a “subtotal cure” in 8 (7.6%) and “improvement” in 63 (60.0%). Those with tongue lesions (in apposition with amalgam) also experienced greater improvement. After complete remission, 8 patients (7.6%) had a recurrence during a mean of 14.6 months. These authors noted that amalgam dental restoration removal had little effect on patients with oral and cutaneous lichen planus. Because 97.1% of patients benefited from the removal of amalgam dental restorations regardless of patch test results, Dunsche et al recommend removal of amalgam dental restorations if no cutaneous lichen planus is present.

What is the value of patch testing in patients with lesions of OLP in close apposition to dental metal restorations? There may be less value if cutaneous lichen planus coexists. If the clinical manifestations are limited to the oral mucosa, patch testing to dental metals serves several functions.

First, positive patch test reactions to inorganic mercury compounds identify a subset of OLP patients with lichenoid contact stomatitis who have a high probability of benefiting from amalgam dental restorations removal, particularly if the oral lesions are in close apposition and involve the tongue or buccal mucosa.

Second, positive patch test reactions to inorganic mercury compounds identify a subset of OLP patients who are likely to benefit from removal of amalgam dental restorations that are within 1.0 cm of lesions of OLP.

Third, patch testing for all dental metals can identify not only amalgam dental metal hypersensitivity but also dental metal hypersensitivity to gold, palladium, beryllium, and other dental metals that can cause a lichenoid contact stomatitis.^{3,4,6,7,16,17}

Fourth, patch test reactions should be read at 7, 10, or 14 days to identify “late” reactions that occur with dental metals and may be missed otherwise.

Finally, because lichenoid contact stomatitis can be caused by other dental metals such as gold and palladium, patch testing can be used to exclude these metals when choosing a dental metal (or other) restoration to replace the offending one. Removal and replacement of dental metal restorations is a costly and time-consuming procedure. Removal should be considered based on objective evidence of symptomatic lichenoid tissue changes in apposition to or close to a dental metal restoration. The strong probability of long-term clearing, with a

small probability of relapse of the lichenoid tissue changes, can be assessed by performing patch testing to dental metals. Laeijendecker and colleagues¹ are to be commended for their careful study and follow-up of patients with OLP associated with amalgam dental restorations.

References

1. Laeijendecker R, Dekker SK, Burger PM, Mulder PGH, van Joost Th, Neumann HAM. Oral lichen planus and allergy to dental amalgam restorations. *Arch Dermatol* 2004; 140: 1434-8.
2. Dunsche A, Kastel I, Terheyden H, Springer ING, Christophers E, Brasch J. Oral lichenoid reactions associated with amalgam. *Br J Dermatol* 2003; 148: 70-6.
3. Scalf LA, Fowler JF Jr, Morgan KW, Looney SW. Dental metal allergy in patients with oral, cutaneous, and genital lichenoid reactions. *Am J Contact Dermatitis* 2001; 12: 146-50.
4. Yiannias JA, el-Azhary RA, Hand JH, Pakzad SY, Rogers RS III. Relevant contact sensitivities in patients with the diagnosis of oral lichen planus. *J Am Acad Dermatol* 2000; 42: 177-82.
5. Camisa C, Taylor JS, Bernat JR, Helm TN. Contact hypersensitivity to mercury in amalgam restorations may mimic oral lichen planus. *Cutis* 1999; 63: 189-92.
6. Pecegheiro M, Sachse MF, Amaro J, Farinha P, Fonseca I. Oral lichen planus versus oral lichenoid eruption as a manifestation of contact allergy. *Contact Dermatitis* 1999; 40: 333-4.
7. Rogers RS III. Lichenoid contact stomatitis. *Ann Dermatol Venereol* 2002; 129. Abstract. SY0805.
8. Fernstrom AIB, Frykholm KO, Huldt S. Mercury allergy with eczematous dermatitis due to silver-amalgam fillings. *Br Dent J* 1962; 18: 204-6.
9. Shovelton DS. Silver amalgam and mercury allergy. *Oral Surg Oral Med Oral Pathol* 1968; 25: 29-30.
10. Lundstrom IM. Allergy and corrosion of dental materials in patients with oral lichen planus. *Int J Oral Surg* 1984; 13: 16-24.
11. Jameson MW, Kardos TB, Kirk EE, Ferguson MM. Mucosal reactions to amalgam restorations. *J Oral Rehabil* 1990; 17: 293-301.
12. Bolewska J, Jansen HJ, Holmstrup P et al. Oral mucosal lesions related to silver amalgam restorations. *Oral Surg Oral Med Oral Pathol* 1990; 70: 55-8.
13. Holmstrup P. Oral mucosa and skin reactions related to amalgam. *Adv Dent Res* 1992; 6: 120-4.
14. Ostman PO, Anneroth G, Skoglund A. Oral lichen planus lesions in contact with amalgam fillings. *Scand J Dent Res* 1994; 102: 172-9.
15. Smart ER, Macleod RI, Lawrence CM. Resolution of lichen planus following removal of amalgam restorations in patients with proven allergy to mercury salts: a pilot study. *Br Dent J* 1995; 178: 108-12.
16. Laine J, Kalimo K, Happonen RP. Contact allergy to dental restorative materials in patients with oral lichenoid lesions. *Contact Dermatitis* 1997; 36: 141-6.
17. Koch P, Bahmer FA. Oral lesions and symptoms related to metals used in dental restorations. *J Am Acad Dermatol* 1999; 41: 422-30.
18. Wong L, Freeman S. Oral lichenoid lesions (OLL) and mercury in amalgam fillings. *Contact Dermatitis* 2003; 48: 74-9.

CHAPTER 4

A. ORAL MANIFESTATIONS OF GOLD ALLERGY

R. LAEIJENDECKER, MD¹
Th. VAN JOOST, MD, PhD¹

JOURNAL OF THE AMERICAN ACADEMY OF DERMATOLOGY
1994; 30: 205-9.

¹ Department of Dermatology and Venereology, Erasmus University Rotterdam, University Hospital Rotterdam - Dijkzigt, Dr. Molewaterplein 40, 3015 GD Rotterdam, The Netherlands.

ABSTRACT

- Background:** Sensitization to gold in large populations suspected of clinical allergy to this metal has not been reported.
- Objective:** Two hundred patients with symptoms of persistent oral mucosal or cutaneous lesions that were possibly related to allergy to constituents of gold alloys or gold jewelry were patch tested to determine the frequency of sensitization.
- Methods:** Patch testing was performed with the European standard series and a series of dental materials including three different salts of gold. A persistent papular reaction to gold(tri)chloride was considered to be a positive reaction.
- Results:** In 17 (8.5%) patients, all women (mean age 50 years), persistent papular patch test reactions to both 0.5% and 1% gold(tri)chloride were observed. In 5 of the 7 patients with oral lichen planus (OLP) and in 1 of the 6 patients with the burning mouth syndrome (BMS), dental gold was replaced. A significant but variable improvement was observed particularly in patients with OLP. The patients were sensitized to 0.5% gold(tri)chloride in all cases in which gold was replaced and the lesions improved. One patient with allergic contact stomatitis and one patient with allergic contact dermatitis healed completely after gold had been replaced.
- Conclusions:** Sensitization to gold should be considered as a possible cause of allergic contact dermatitis, allergic contact stomatitis and also as a pathogenic or triggering factor in OLP.

Introduction

Gold salts are potentially strong sensitizers as shown by the “maximization test”¹, but delayed hypersensitivity to metallic gold and to gold salts has been reported infrequently.¹⁻⁵ One reason could be that an insufficient amount of gold salt leaches from materials resulting in an inadequate concentration of antigen to produce clinical allergy.

Patch testing with gold presents problems with irritant and false negative reactions. Various gold salts such as gold(tri)chloride (0.5%, 1% and 2% chloroauric acid), 0.5% aurothiomalate, 0.5% gold sodium thiosulfate, 0.1% sodium chloroaurate, 0.002% potassium dicyanoaurate and 1% gold potassium chloride have been used and recommended to establish “true allergy” to gold in patch test procedures.^{1,3,4,6,7} It has been suggested that true allergy to gold may only be established when there are definite reactions to at least two gold salts coupled with a relevant clinical history.¹ Fowler considered gold sodium thiosulfate (0.5% in petrolatum) and potassium dicyanoaurate (0.002% in water) as reliable markers for gold allergy.³ Fisher regarded gold(tri)chloride at a concentration of 1% or lower in water as a reliable test allergen.⁴ Positive patch test reactions of the eczematous type are possible, but in the majority of cases persistent infiltrated papular reactions have been observed that are considered to be primarily of an immunological origin.^{4,6,8,10,11} Probably because of accumulation of the allergen in the dermis, gold allergic contact dermatitis may show a marked dermal involvement with little or no changes in the epidermis and may persist for a long period even after exposure to gold is avoided.^{4,7,8} Gold is mostly alloyed with other metals.^{1,4} High carat yellow gold contains copper and silver. Low carat yellow gold also contains zinc and a small amount of nickel. White gold usually contains palladium and nickel. Nickel in white gold alloys may be responsible for “white gold dermatitis”.¹⁻⁴ Dental gold is an alloy that may also contain uncommon, but definite sensitizers such as copper, platinum and palladium.⁵ It is important to establish which particular gold alloy has been used. Therefore, patch testing with a range of metals usually present in gold alloys is essential.^{5,12-17} Oral lesions attributed to gold allergy are described as stomatitis and lichen planus or lichenoid reactions in close approximation to gold dentures.^{5,15}

The aim of this study was to determine the role of gold as an allergen in 200 selected patients.

Materials and methods

The population studied consisted of 200 patients. The majority was clinically diagnosed as oral lichen planus (OLP), burning mouth syndrome (BMS), aller-

gic contact stomatitis (ACS) and less frequently allergic contact dermatitis or contact urticaria. They were suspected to have an allergy to materials containing gold. The patients were patch tested with the European standard series¹ and with the series of metals^{16,17} used in case of a possible allergy to metals other than nickel, cobalt and chromium (Table I). The gold salts used as test allergens were 0.5% and 1% gold(tri)chloride in water, 0.001% potassium dicyanoaurate in water and 0.1% sodium tetrachloroaurate in water. The gold(tri)chloride test solution did not contain nickel as a contaminant and was prepared by dissolving AuCl₃ in water resulting in an aqueous solution of HAuCl₄ that was highly acidic. Patch tests were performed with Finn-chambers and read after 48 and 72 hours. In addition, the patients were instructed to contact us when positive reactions to allergens developed at a later stage. A persistent papular reaction was considered to be positive.

When a clinical correlation was suspected between a positive patch test reaction to gold and the oral symptoms, especially when gold was in close contact with the oral lesions, the patient was advised to have replaced the dental gold alloy. If patch tests to other allergens in the dental materials were found, patients were advised to have these allergens substituted as well. The replacements of gold consisted of composite resin materials, glass ionomer and porcelain. After a follow-up period varying between 2 months and 6 years (mean 2 years) the patients were re-evaluated. Their own subjective assessment by

Table I. Dental material test series.

1	Gold(tri)chloride	0.5% in aqua
2	Gold(tri)chloride	1% in aqua
3	Sodium tetrachloroaurate	0.1% in aqua
4	Potassium dicyanoaurate	0.001% in aqua
5	Nickel sulfate	5% in aqua
6	Cobalt chloride	1% in aqua
7	Magnesium sulfate	5% in aqua
8	Potassium dichromate	0.5% in aqua
9	Palladium sulfate	1.5% in aqua
10	Ferric chloride	2% in aqua
11	Copper sulfate	2% in aqua
12	Palladium chloride	2.5% in aqua
13	Zinc chloride	2.0% in aqua
14	Gallium chloride	10% in aqua
15	Phenylmercuric nitrate	0.05% petrolatum
16	Mercury (metallic)	0.5% petrolatum
17	Thimerosal	0.1% petrolatum
18	Stannous chloride	0.5% in aqua
19	Silver nitrate	1% in aqua
20	Toluene sulfonamide	0.1% alcohol

comparing the symptoms before and after gold had been replaced was graded as symptom-free, improved, unchanged or worse. The lesions were objectively evaluated and compared with the pre-treatment condition and graded as healed, improved, unchanged or worse.

Results

In 17 (8.5%) of the 200 patients a positive patch test reaction to 1% and 0.5% gold(tri)chloride was observed (Table II). In all, except one case, the reactions showed a moderate or marked induration with persistent papules varying in duration from about one to several weeks (mean 4 weeks). One positive patch test reaction even persisted for 3 months. In 3 patients, the positive patch tests with 0.5% and 1% gold(tri)chloride developed after the regular 3-day evaluation (after 5, 6 and 14 days respectively). Another patient developed a reaction to 1% gold(tri)chloride that was characterized by infiltration and purpura after one month. Histologically, the reaction was classified as a contact allergic reaction with vasculitis. Positive reactions to sodium tetrachloroaurate and potassium dicyanoaurate were not observed in any of the patients.

Seven (41.2%) of the 17 patients who were reactive to gold(tri)chloride had positive reactions to other metals including palladium (4 patients), nickel (3 patients), cobalt (2 patients) and mercury (1 patient). Sensitization to gold(tri)chloride without other positive patch tests was observed in 8 (47.1%) patients.

All 17 patients were women, aged 28 to 71 years (mean 50 years). Within this group, 7 (41.2 %) patients had OLP and 6 (35.3%) patients had BMS. The remaining 4 (23.5%) patients had allergic contact stomatitis, allergic contact dermatitis, chronic urticaria or a relapsing angioedema.

In 7 patients aged 39 to 70 years (mean 49 years) with a persistent papular patch test to gold(tri)chloride, the clinical diagnosis of OLP (5 with erosive OLP, 1 with hyperkeratotic OLP and 1 with a plurimucosal form of lichen planus) was confirmed by histopathological examination (Table II). Five patients with OLP had gold-containing dental alloys corresponding to the site of the oral lesions. Four patients with OLP had also positive patch test reactions to cobalt and mercury (1 patient), nickel (1 patient) and palladium (2 patients). The 7 patients were treated with various agents including topical corticosteroids, topical retinoids and cyclosporin mouthwash with a mean period of about 2 years (range 3 months to 4 years). Three patients were treated with systemic retinoids (mean dose 0.5 mg/kg/day) for about 3 months and 2 patients were treated with cyclosporin mouthwash for 2 months. However, no significant long-term improvement was achieved.

Gold-containing dental materials were replaced in 5 patients with OLP (in 2 patients together with replacements of amalgam (cobalt and mercury) and

Table II. Clinical characteristics of the patients.

Pat. Age (Diagnosis)	Positive patch tests	48 hrs	72 hrs	>72 hrs	Therapy	Course Subj/ Obj	Remarks
1. 39 (hyper- keratotic OLP)	goldchloride 0.5% goldchloride 1.0% palladium sulfate p.toluenediamine p.aminoazobenzene p.tert.butyl. formal.	– – – – 3+ +	2+ 2+ 2+ 2+ 4+ 3+		Removal of dental palladium	+ / +	No dental gold. Complaints of gold earrings
2. 52 (Plurimuco- sal LP)	goldchloride 0.5% goldchloride 1.0% nickel sulfate colofonium p.tert.butyl. formal. woodtar mix	– – + – – –	2+ 2+ 2+ 2+ 3+ 2+		Replacement of gold and nickel containing dental material. Vulva: topical corticosteroids	+ / + + / +	No complaints of gold jewelry
3. 45 (erosive OLP)	goldchloride 0.5% goldchloride 1.0% fragrance mix cinnamaldehyde	– – 2+ 2+	2+ 2+ 3+ 3+		Topical: cortico- steroids, cyclo- sporin. Systemic: vit A acid, isoniazide	+/- +/-	No dental gold. No complaints of gold jewelry
4. 52 (erosive OLP)	goldchloride 0.5% goldchloride 1.0% palladium chloride	– 2+ –	2+ 3+ 2+		Replacement of dental gold (crown)	+ / +	No complaints of gold jewelry
5. 42 (erosive OLP)	goldchloride 0.5% goldchloride 1.0% p.aminobenzene	– – –	– – –	2+ 2+ 2+	Replacement of dental gold	+ / +	No complaints of gold jewelry
6. 70 (erosive OLP)	goldchloride 0.5% goldchloride 1.0%	– –	2+ 2+		Replacement of dental gold (crowns)	++/++	Complaints of gold earrings
7. 43 (erosive OLP)	goldchloride 0.5% goldchloride 1.0% mercury 0.5% am.mercury 1% cobalt chloride	– – – – –	+ + – – 2+	2+ 2+ 2+ 2+ 2+	Replacement of dental gold and amalgam	+ / +	No complaints of gold jewelry
8. 53 (BMS)	goldchloride 0.5% goldchloride 1.0%	– –	2+ 2+		Replacement of dental gold (crowns)	+ / ?	No complaints of gold jewelry
9. 28 (BMS)	goldchloride 0.5% goldchloride 1.0% nickel sulfate cobalt chloride	– – + +	2+ 2+ 2+ 2+		Replacement of nickel and cobalt containing dental material	+ / ?	No dental gold. Complaints of gold jewelry
10. 54 (BMS)	goldchloride 0.5% goldchloride 1.0%	– –	– tox.	2+ 2+ vasc ulitis	No replacement	+/- ?	Complaints of gold jewelry

Pat. Age (Diagnosis)	Positive patch tests	48 hrs	72 hrs	>72 hrs	Therapy	Course Subj/ Obj	Remarks
11. 71 (BMS)	goldchloride 0.5% goldchloride 1.0%	– –	2+ 2+		No replacement	+/- ?	No complaints of gold jewelry
12. 65 (BMS)	goldchloride 0.5% goldchloride 1.0%	– –	2+ 2+		No replacement	+/- ?	No complaints of gold jewelry
13. 58 (BMS)	goldchloride 0.5% goldchloride 1.0%	– –	– –	2+ 2+	Folic acid 10 mg/day (minimal deficiency)	+/- ?	No dental gold. No complaints of gold jewelry
14. 51 (angio- edema)	goldchloride 0.5% goldchloride 1.0% palladium sulfate	– 2+ –	2+ 3+ 2+		Systemic anti- histamines. No replacement necessary	+ / +	No dental gold. Complaints of gold jewelry
15. 53 (contact dermatitis)	goldchloride 0.5% goldchloride 1.0%	– –	2+ 2+		Replacement of gold jewelry	++/++	No dental gold.
16. 29 (chronic urticaria)	goldchloride 0.5% goldchloride 1.0% palladium chloride nickel sulfate	– – – 2+	2+ 2+ 3+ 3+		Systemic anti- histamines. No request of dental gold replacement.	+ / +	No complaints of gold jewelry
17. 48 (contact stomatitis)	goldchloride 0.5% goldchloride 1.0%	– –	2+ 2+		Replacement of dental gold (crown)	++/++	No complaints of gold jewelry

Evaluation of patch tests after 48, 72 and > 72 hrs (hrs = hours):

– = negative, + = erythema (no allergy), 2+ = erythema with induration (= contact allergy), 3+ = erythema with vesicles (= contact allergy).

Subj (= subjective, symptoms). Obj (= objective, signs): +/- = unchanged, + = improved

++ = healed. ? = uncertain. p = para, Pat = patient number, am.= ammoniated,

p-tert.butyl.formal = paratertiary butylphenol formaldehyde resin.

nickel, respectively). In 1 patient with OLP, palladium was replaced. All patients with replacements showed significant subjective and objective improvement after 2 weeks to 6 months (mean 3 months) and remained so afterwards (mean follow-up time 1 year, range 6 months to 2 years). In 1 patient, OLP healed completely after replacement.

Two of the 7 OLP patients with a gold allergy, suffered concomitantly from allergic contact dermatitis when they wore gold earrings. In the 5 patients with OLP and dental gold, OLP developed after 3 weeks to 3 years (mean 4 months) after placement of dental gold. None of these patients were on any systemic medication that could be responsible for an oral lichenoid drug eruption. One patient had plurimucosal lichen planus and had sensitization to gold

and nickel. The oral manifestations improved significantly after both dental gold and nickel were replaced. However, the lesions on the vulva improved only after treatment with topical corticosteroids.

Six patients aged 28 to 71 years (mean 55 years) with a positive patch test reaction to gold had a diagnosis of BMS (Table II). In this group, all patients had an isolated positive patch test reaction to gold(tri)chloride, except one who also had a positive patch test reaction to nickel and cobalt. The symptoms had persisted for several years and topical treatment had been ineffective. Four patients with BMS had gold containing dental alloys. Dental gold was replaced in one patient and nickel and cobalt containing dental materials were replaced in another patient, who had no dental gold. In both patients, there was an improvement in the symptoms some weeks after replacement. In 3 patients with BMS, dental gold had not yet been replaced and their symptoms remained unchanged. The 4 patients with dental gold began to complain of BMS after 1 month to 4 years (mean 6 months) after receiving gold alloys in the mouth. One patient was clinically suspected to have allergic contact stomatitis for one year. This patient had an isolated positive patch test reaction to gold-(tri)chloride (1% and 0.5%). Allergic contact stomatitis developed 2 months after a gold crown had been placed. The lesions resolved completely three weeks after the gold crown was replaced. This patient had no complaints when gold jewelry was worn (Table II).

A second patient had a relapsing angioedema of the mucous membranes of the mouth and the tongue for 2 years and also had a positive patch test reaction to palladium. She had no dental gold and treatment with systemic antihistamines was effective. She also complained of an itchy contact dermatitis at sites where gold jewelry was worn (Table II).

Another patient with gold allergy had chronic urticaria of unknown cause for 5 years. There were also positive patch test reactions to nickel and palladium. Treatment with an antihistamine was effective.

A fourth patient without dental gold only had a positive patch test to gold-(tri)chloride and had allergic contact dermatitis on the arms, the hands and the legs for several months even at sites not in close contact with gold jewelry. The eruptions resolved completely within 4 weeks without additional treatment once gold jewelry was avoided (Table II).

Discussion

The objective and subjective improvement or healing in 7 patients (5 with OLP, 1 with BMS and 1 with allergic contact stomatitis) after dental gold alloys were replaced and the resolution of allergic contact dermatitis after avoiding gold jewelry in 1 patient, supported the clinical value of persistent papular patch test reactions as diagnostic markers of true gold sensitization.

Metallic gold alone is not a reliable test allergen, because the time required for converting metallic gold into gold salts is longer than 48 hours.^{3,5} Irritant reaction to 1% gold(tri)chloride is considered to be caused by the acidic nature of the vehicle.^{1,4,5,13} In a small number of patients, the patch test with 1% gold(tri)chloride resulted in a slight irritant reaction that disappeared within a few days. Irritant reaction to 0.5% gold(tri)chloride was not seen in any of the patients tested. All patients with a positive patch test with 1% gold(tri)chloride also reacted adequately to 0.5% gold(tri)chloride. Therefore, the latter concentration should be considered as the concentration of choice for patch testing. Positive patch test reactions to gold(tri)chloride persisted for periods of one to several weeks. We hypothesize that this type of patch test reaction together with a relevant clinical history may be important in the clinical diagnosis of gold allergy. In nearly all patients, clinically relevant sensitization at sites of contact (oral cavity or skin) was obvious. Late positive patch test reactions to gold(tri)chloride may occur and can easily be missed if the last reading is done at 72 hours. In 1 patient, a positive patch test reaction developed after 14 days, whereas in another patient it developed after 1 month. It seems likely that the latter patient was sensitized during the patch test procedure, and in whom we observed the clinical and histological features of a allergic contact reaction with vasculitis.

Pseudolymphomatous lesions induced by gold have been reported in a patient in whom a persistent infiltrative patch test reaction to 1% gold(tri)chloride with pseudolymphomatous features was observed.¹⁰ Lymphocytoma cutis of the earlobes induced by gold earrings had been reported.¹⁸

Only 5 (33.3%) out of the 15 patients with oral symptoms and gold sensitization developed contact dermatitis when they wore gold jewelry. It is likely that the humid environment, pressure and friction in the oral cavity permit slow leaching of gold salts capable of provoking an allergic reaction in sensitized individuals.⁵ This process of leaching may be hastened by galvanic forces induced by different metals in the mouth.⁵ Penetration into the mucosal membranes is easier than into the skin and this may explain the concomitant absence of allergic reactions to gold jewelry and the presence of only oral symptoms in most patients.^{1,2}

The development of oral mucosal disorders because of contact sensitization to allergic dental materials other than gold (especially amalgam) and the benefit of replacing such materials was reported.^{14,15,17,19,20} An oral lichenoid drug eruption caused by systemic gold therapy has been described.²¹⁻²³ Data in favor of T-cell mediated injury in lichen planus have been published.²³ The results of the present study indicate that apparently OLP may be related to an allergy to dental gold.

In all 8 patients, including the patient with allergic contact dermatitis, in whom metallic gold was replaced, the lesions improved or resolved completely. Oral symptoms also improved significantly in 2 patients in whom palladium, nickel

and cobalt containing dental materials were replaced. Only in a few patients out of the group of 183 patients in whom no positive patch test reactions to gold(tri)chloride were observed, sensitization to nickel, cobalt, chromium, palladium, mercury or dental acrylates was observed.¹⁷ In 2 patients with OLP, dental replacements included gold and other metals. Therefore, the role of gold replacement could not be established with certainty in those cases.

Replacing dentures, crowns or bridges is an expensive intervention and therefore, the decision to do so must be based on definite reasons. Replacement should only be recommended to patients with chronic disabling oral symptoms, who respond insufficiently to therapy, who have positive patch test reactions to dental metal(s) and in whom there is a relation between the site of the lesions and the site of the specific dental materials.^{2,5,14,15} However, in spite of these criteria, there is no certainty that BMS will resolve completely after removal of the allergens. Even when gold sensitization is a prime suspect other still unidentified factors may be responsible for perpetuating the disease.¹⁷

All our patients with gold allergy were women. It is possible that this may be partly explained by the manner of sensitization (in analogy to nickel), namely early and frequent contact of the skin with jewelry (golden earrings in particular). Sensitization may also be induced by exposure to dental gold (salts), gold injections and gold salts used in certain professions.^{1,4,10} None of the patients in this study had professional exposure to gold salts. Only one patient with BMS had received several gold injections for arthritis in the past. None of the patients in this study had a positive reaction to sodium tetrachloroaurate 0.1% aq or potassium dicyanoaurate 0.001% aq (Table II). Two patients with BMS in whom positive reactions to gold(tri)chloride occurred after 14 and 30 days may have been sensitized during patch testing. No replacement was done in these patients.

Histologically, allergic gold dermatitis is characterized by marked dermal involvement in the near absence of epidermal changes.^{4,8} These features, also observed by us in biopsy specimens of positive patch tests, may have been caused by a persistent presence of gold in the dermis and may explain the atypical, non-eczematous appearance of the positive patch tests.

We believe that immune-mediated injury in the oral cavity caused by local hypersensitivity to gold salts is underestimated. In patients with gold dental alloys and mucosal disorders of suspected immune-mediated origin, especially allergic contact stomatitis and OLP, patch testing with gold salts in addition to other metal allergens should be performed.

References

1. Cronin E. Metals. In: Cronin E ed. Contact Dermatitis, Edinburgh, London and New York. Churchill Livingstone; 1980: 328-35.

2. Fregert S, Kollander M, Poulsen J. Allergic contact stomatitis from gold dentures. *Contact Dermatitis* 1979; 5: 63-4.
3. Fowler JF. Selection of patch test materials for gold allergy. *Contact Dermatitis* 1987; 17: 23-5.
4. Fisher AA. Dermatitis and discolorations from metals. In: Fischer AA. ed. *Contact Dermatitis*. Philadelphia: Lea & Febiger, 3rd edn, 1986: 729-32.
5. Wiesenfeld D, Ferguson MM, Forsyth A, MacDonald DG. Allergy to dental gold. *Oral Surg* 1984; 57: 158-60.
6. Shelley WB, Epstein E. Contact-sensitivity to gold as a chronic papular eruption. *Arch Dermatol* 1963; 87: 388-91.
7. Bowyer A. Epidermal reactions and prolonged dermal reactions to patch testing with goldsalts. *Acta Derm Venereol* (Stockholm) 1967; 47: 9-14.
8. Petros H, MacMillan AL. Allergic contact sensitivity to gold with unusual features. *Br J Dermatol* 1973; 88: 505-8.
9. Young E. Contact hypersensitivity to metallic gold. *Dermatologica* 1974; 149: 294-8.
10. Monti M, Berti E, Cavicchini S, Sala F. Unusual cutaneous reaction after a gold chloride patch test. *Contact Dermatitis* 1983; 9: 150-1.
11. Silvennoinen-Kassinen S, Niinimäki A. Gold sensitivity blast formation. *Contact Dermatitis* 1984; 11: 156-8.
12. Elgart M. Allergic contact dermatitis to gold. *Arch Dermatol* 1972; 106: 254.
13. Axell T, Björkner B, Fregert S, Niklasson B. Standard patch test series for screening of contact allergy to dental materials. *Contact Dermatitis* 1983; 9: 82-4.
14. Laine J, Kalimo K, Forssell H, Risto-Pekka H. Resolution of oral lichenoid lesions after replacement of amalgam restorations in patients allergic to mercury compounds. *Br J Dermatol* 1992; 126: 10-5.
15. Jameson MW, Kardos TB, Kirk EEJ, Ferguson MM. Mucosal reactions to amalgam restorations. *J Oral Rehabil* 1990; 17: 293-301.
16. van Loon LAJ, van Elsar PW, van Joost Th, Davidson CL. Test battery for metal allergy in dentistry. *Contact Dermatitis* 1986; 14: 158-61.
17. Dutrée-Meulenber ROGM, Kozel MMA, van Joost Th. Burning Mouth Syndrome: A possible etiologic role for local contact hypersensitivity. *J Am Acad Dermatol* 1992; 26: 935-40.
18. Kobayashi Y, Nanko H, Nakamura J, Mizoguchi M. Lymphocytoma cutis induced by gold pierced earrings. *J Am Acad Dermatol* 1992; 27: 457-8.
19. Bolewska J, Hansen HJ, Holmstrup P, Pindborg JJ, Stangerup M. Oral mucosal lesions related to silver amalgam restorations. *Oral Surg Oral Med Oral Pathol* 1990; 70: 55-8.
20. Lind PO. Oral lichenoid reactions related to composite restorations. Preliminary report. *Acta Odontol Scand* 1988; 46: 63-5.
21. Bruinsma W. Lichenoid eruptions In: Bruinsma W. ed. *A guide to drug eruptions -the file of side effects in dermatology*, 5th edn Oosthuizen: The file of Medicines, 1990: 450.
22. Martindale W. Metals and some metallic salts. In: Wade A. ed. *Martindale: The Extra Pharmacopeia*. London. The pharmaceutical press, 27th edn, 1979: 896-7.
23. Boyd AS, Neldner KH. Lichen Planus. *J Am Acad Dermatol* 1991; 25: 593-619.

B. AN UPDATE ON GOLD ALLERGY

APRIL, 2005. R. LAEIJENDECKER.

Traditionally, gold allergy has been regarded as a rare entity.¹ However, more recent studies have shown that gold allergy is more common than was previously recognized.¹⁻⁴ There are probably several reasons for this underestimation. Gold allergy was rarely tested and poor quality allergens were often used in patch tests.^{1,16}

Moreover, late positive reactions occur frequently and can be easily missed.^{2,5-7} Gold is metallurgically inert and therefore, it was assumed to be immunologically inert.¹ Gold as a metal is inert.⁷ Gold, like other metals, has to be ionized prior to acting as a sensitizer.⁷ Gold has three oxidation states including metallic gold (Au 0), monovalent (Au I) and trivalent (Au III).⁸ Ionized gold is chemically very reactive.⁷ Gold seems to be able to bind directly to the MHC class II molecule. This inflammatory response is indistinguishable from the traditional hapten-peptide conjugate-induced contact hypersensitivity.^{9,10}

Vamnes et al reported the value of the lymphocyte transformation test in the diagnosis of contact hypersensitivity to gold in 8 patients. Gold sodium thiosulfate and gold chloride were added to lymphocyte cultures and labeled with tritiated (3H)-thymidine.⁸

Fowler et al reported allergic reactions to gold in 9.5% of more than 4,000 patients with suspected contact dermatitis.¹¹ Björkner et al reported a gold allergy prevalence of 9% and gold was the second most common allergen after nickel.¹² Most studies demonstrated a strong female predominance for gold allergy, probably because of gold jewelry, which is commonly used.^{11,13-15} Moreover, most female patients with gold allergy also have gold-containing dental materials.^{2,4} The most common sites of dermatitis in patients with positive patch tests to gold were the hands, the neck, and the face (the eyelids and the ears).^{11,13,14}

Exposure to gold may usually occur via dental gold alloys, jewelry and gold therapy.^{3,4,15} Soluble gold salts may cause occupational dermatitis. Occupational exposure to gold salts may occur via porcelain, gold plating, gilding glass and photographic developers.^{1,16}

In the literature, gold sodium thiosulfate (0.5% in petrolatum), also known as sodium thiosulfatoaurate, is regarded as the most reliable reagent for patch testing in suspected cases of gold allergy.^{2,4,12,15,17} However, Fisher regarded gold(tri)chloride as a reliable test allergen.¹⁸ Since 1994, gold sodium thiosulfate (0.5% pet and 0.25% pet) has been added to our dental metal series. Furthermore, gold(tri)chloride 0.5% aq and potassium dicyanoaurate 0.002% aq are also tested. We used gold(tri)chloride 0.5% aq for many years with good and reproducible results. However, the acidic nature of the vehicle may predispose to irritant reactions.^{16,17,19} Patch tests for gold allergy should include gold salts because gold leaf, metallic gold, and gold scrapings are poorly soluble and may lead to false negative results in gold-sensitized patients.¹ Koch et al

reported that gold sodium thiosulfate at 0.5% pet versus 0.25% pet was twice as likely to lead to positive results.²⁰

The gold allergens that have been used in the literature are summarized in Table I.^{16,17,22} Positive reactions to gold may appear late and may be long-lasting.^{7,12,21} Active sensitization to gold in patients with late positive reactions cannot always be excluded with certainty.⁷

Systemic therapy with gold for rheumatic or dermatological diseases, is often complicated by adverse reactions including oral and/or cutaneous lichenoid drug eruptions.²³⁻²⁶ The deposition of gold in the skin, leading to blue-gray pigmentation, is termed chrysiasis.¹ Miller et al reported a case of chrysiasis. Gold microparticles were identified in the superficial dermis.²⁷

In 1999, Koch and Bahmer reported allergy to gold in 28 out of 194 patients.² Eleven (39%) of these 28 patients complained of skin lesions because of gold jewelry. In 2 patients with oral lichen planus and in 2 patients with gingivostomatitis, dental gold was in close contact with the lesions. Patch tests to gold sodium thiosulfate 0.5% pet were positive in 28 patients, but were first observed as positive on day 10 after the initial occlusion in 9 (32%) patients and on day 17 in 4 (14%) patients. Therefore, late positive patch test results occur

Table I. Gold allergens used in patch testing in the literature.

Contactant	Concentration and vehicle	Comments
Gold sodium thiosulfate (Sodium thiosulfatoaurate)	0.5% pet, 0.25% pet 0.5% aq, 2% aq	Most commonly used 0.5% pet
Gold(tri)chloride	0.5% aq, 1% aq, 0.25% aq 1.0% pet	Reliable allergen 0.5% aq
Potassium dicyanoaurate (Sodium dicyanoaurate)	0.002% aq, 0.01% aq 0.05% alc, 0.001% alc, 0.002% pet	Acceptable allergen 0.002% aq
Potassium bromoaurate	0.1% aq	Rarely used
Sodium tetrachloroaurate	0.1% aq	Rarely used
Gold potassium chloride	1% aq	Rarely used
Gold sodium thiomalate	0.5% aq	Rarely used
Gold leaf, metallic gold and gold scrapings	as is	Not reliable (should not be used in patch tests)

Pet = petrolatum

Aq = aqua (water)

Alc = alcohol 70% (ethanol)

frequently to gold sodium thiosulfate and may be easily missed in routine patch testing. In 12 (43%) of the 28 patients, irrespective of the diagnosis, the patch tests showed a persistent positive reaction which occurred varying from 3 to 17 days.² Histologically, allergic patch test reactions to gold sodium thiosulfate may not only show eczematous but also lichenoid changes. In addition, a marked dermal reaction with perivascular lymphocytic infiltrate predominantly around the deeper dermal vessels was reported in persistent positive patch tests to gold sodium thiosulfate, indicating a “dermal” contact dermatitis.¹⁻³ Bowyer already reported the same reaction for gold chloride.²⁸ Koch and Bahmer concluded that sensitization to gold sodium thiosulfate reflected a true gold allergy and should be considered as a cause of oral diseases in some patients.²

Bruze et al reported that only 65% of the positive patch reactions to gold sodium thiosulfate appeared within seven days. They suggested that patch tests in such cases should be read on day 3, day 7 and day 21.⁵

Gold was formerly used to stain Langerhans cells in histological preparations. The hypothesis that these cells may play a role in the persistent nature of gold patch test reactions by slowing the elimination of the allergen at the site of reaction has been reported.⁵

In 2003, Lazarov et al described a patient with oro-facial granulomatosis associated with contact allergy to gold in dental crowns. Marked improvement of oro-facial granulomatosis was noted 3 months after the gold crown had been replaced. Total involution was observed after 5 months.²⁹

References

1. Rietschel RL, Fowler JF. Contact dermatitis and other reactions to metals. In: Fisher's Contact Dermatitis. 5th edn. Philadelphia. Lippincott Williams & Wilkins; 2001: 631-3.
2. Koch P, Bahmer FA. Oral lesions and symptoms related to metals used in dental restorations. *J Am Acad Dermatol* 1999; 41(1): 422-30.
3. Sperber BR, Allee J, Elenitsas R et al. Papular dermatitis and a persistent patch test reaction to gold sodium thiosulfate. *Contact Dermatitis* 2003; 48: 204-8.
4. Bruze M, Edman B, Björkner B et al. Clinical relevance of contact allergy to gold sodium thiosulfate. *J Am Acad Dermatol* 1994; 31: 579-83.
5. Bruze M, Hedman H, Björkner B et al. The development and course of test reactions to gold sodium thiosulfate. *Contact Dermatitis* 1995; 33: 386-91.
6. Koch P, Pönnighaus J, John S. Patch testing with gold sodium thiosulfate. Case control study and clinical relevance of the patch tests. *Dermatosen* 1997; 45: 12-6.
7. Bruze M, Andersen KE. Gold – a controversial sensitizer. *Contact Dermatitis* 1999; 40: 295-9.
8. Vamnes JS, Gjerdet NR, Morken T et al. In vitro lymphocyte reactivity to gold compounds in the diagnosis of contact hypersensitivity. *Contact Dermatitis* 1999; 41: 156-60.

9. Romagnoli P, Spinass GA, Sinigaglia F. Gold-specific T cells in rheumatoid arthritis patients treated with gold. *J Clin Invest* 1992; 89: 254-8.
10. Sinigaglia F. The molecular basis of metal recognition by T cells. *J Invest Dermatol* 1994; 102: 398-401.
11. Fowler JF, Taylor J, Storss F et al. Gold allergy in North America. *Am J Contact Dermatitis* 2001; 12: 3-5.
12. Björkner B, Bruze M, Moller H. High frequency of contact allergy to gold sodium thiosulfate. An indication of gold allergy? *Contact Dermatitis* 1994; 30: 144-51.
13. McKenna KE, Dolan O, Walsh MY et al. Contact allergy to gold sodium thiosulfate. *Contact Dermatitis* 1995; 32: 143-6.
14. Fleming C, Forsyth A, MacKie R. Prevalence of gold contact hypersensitivity in the west of Scotland. *Contact Dermatitis* 1997; 36: 3024.
15. Sabroe RA, Sharp LA, Peachey RDG. Contact allergy to gold sodium thiosulfate. *Contact Dermatitis* 1996; 34: 345-8.
16. Cronin E. Metals. In: *Contact Dermatitis*, Edinburgh, London and New York. Churchill Livingstone; 1980; 328-35.
17. Fowler JF. Selection of patch test materials for gold allergy. *Contact Dermatitis* 1987; 17: 23-5.
18. Fisher AA. Dermatitis and discolorations from metals. In: *Contact Dermatitis*. 3rd ed. Philadelphia. Lea & Febiger; 1986: 729-32.
19. Goh CL. Occupational dermatitis from gold plating. *Contact Dermatitis* 1988; 18: 122-3.
20. Koch P, Kiehn M, Frosch P. Epikutane Testung mit Goldsalzen. Zwei Multicenterstudien der Deutschen Kontaktallergiegruppe. [German]. *Hautarzt* 1997; 48: 812-6.
21. Aro T, Kanerva L, Häyrynen-Immonen R et al. Long-lasting allergic patch test reaction caused by gold. *Contact Dermatitis* 1993; 28: 276-81.
22. Rietschel RL, Fowler JF. Appendix: list of allergens. In: *Fisher's Contact Dermatitis*. 5th edn. Philadelphia. Lippincott Williams & Wilkins; 2001: 736-816.
23. van Gestel A, Koopman R, Wijnands M et al. Mucocutaneous reactions to gold: a prospective study of 74 patients with rheumatoid arthritis. *J Rheumatol* 1994; 21: 1814-9.
24. Swanbeck G, Dahlberg E. Cutaneous drug reactions. An attempt to quantitative estimation. *Arch Dermatol Res* 1992; 284: 215-8.
25. Zürcher K, Krebs A. In: *Cutaneous drug reactions. An integral synopsis of today's systemic drugs*. Karger, 2nd edn. 1992; 260-1.
26. McCartan BE, McCreary CE. Oral lichenoid drug eruptions. *Oral Diseases* 1997; 3: 58-63.
27. Miller M, Harford R, Yeager J et al. A case of chrysiasis. *Cutis* 1997; 59: 256-8.
28. Bowyer A. Epidermal reactions and prolonged dermal reactions to patch testing with goldsalts. *Acta Derm Venereol (Stockholm)* 1967; 47: 9-14.
29. Lazarov A, Kidron D, Tulchinsky Z et al. Contact oro-facial granulomatosis caused by delayed hypersensitivity to gold and mercury. *J Am Acad Dermatol* 2003; 49: 1117-20.

CHAPTER 5

PREMALIGNANT NATURE OF ORAL LICHEN PLANUS.

R. LAEIJENDECKER, MD¹ (and formerly²),
Th. VAN JOOST, MD, PhD (formerly²),
M.C. KUIZINGA, MD, PhD³,
B. TANK, PhD², and
H.A.M. NEUMANN, MD, PhD²

ACTA DERMATO-VENEREOLOGICA, IN PRESS

¹ Department of Dermatology, Albert Schweitzer Hospital, Albert Schweitzerplaats 25, 3318 AT Dordrecht, The Netherlands.

² Department of Dermatology and Venereology, Erasmus MC, University Medical Center Rotterdam, Dr. Molewaterplein 40, 3015 GD Rotterdam, The Netherlands.

³ Department of Pathology, Albert Schweitzer Hospital, P.O. Box 444, 3300 AK Dordrecht, The Netherlands.

ABSTRACT

Background: The issue whether oral lichen planus is a premalignant disorder is still controversial.

Objective: To examine oral malignancies associated with oral lichen planus and to investigate whether oral lichen planus has an intrinsic malignant potential or whether there are also contributing external risk factors.

Methods: A retrospective cohort study in 200 Caucasian patients with oral lichen planus was conducted between 1991-2003. Aspects such as sex, age, clinical variant, affected anatomical sites, duration of the disease, histopathology, prior immunosuppressive treatment, exposure to potential carcinogens and possible concomitant diseases were examined. Histopathological examination was repeated during the follow-up if a malignancy was suspected.

Results: Three (1.5%) of the 200 patients developed an oral squamous cell carcinoma at the same site following the initial diagnosis of oral lichen planus after a period of 3-6 years (mean 4.3 years). Contributing external risk factors were also noted in two of these three patients. One male patient had smoked approximately 25 cigarettes a day during 20 years. One female patient had received a systemic immunosuppressive treatment for 2 years for oral lichen planus. There were no contributing external risk factors in another female patient with an oral squamous cell carcinoma.

Conclusions: Our investigations provide some, but not convincing support to the notion that oral lichen planus is a premalignant condition. However, the exact incidence of malignant transformation is difficult to establish, because of the low number of patients and because of the possible contribution of external risk factors, which may be relevant in oral malignancy.

Keywords: Oral lichen planus, Oral malignancy, Oral squamous cell carcinoma, Premalignancy.

Introduction

Oral lichen planus (OLP) has a prevalence of about 0.5 to 2% in the general population. It is a disease affecting the middle-aged and the elderly and the female-to-male ratio is about 2: 1. The diagnosis of OLP is based on a combination of characteristic clinical findings, history and histopathology.¹⁻³ Oral lichen planus can be categorized into several clinical variants. These are usually an asymptomatic, hyperkeratotic (white) variant: reticular with Wickham's striae, papular or plaque-like. The atrophic or erythematous (red) variant and the erosive or ulcerative (yellow) variant usually have persistent symptoms of pain or stinging and very often minor signs of the hyperkeratotic (reticular) variant in the surrounding mucosa are also observed.^{1,2} Generally, it is a disease that persists for many years despite several modes of treatment.³

In Europe, the incidence of malignancies of the oral mucosa is about 4 (0.004%) per 100,000 individuals per year, which represents approximately 1 to 2% of the total number of malignancies. More men than women are affected (ratio 2 to 3 :1). An oral squamous cell carcinoma (OSCC) is encountered in about 80% of the cases.^{4,7,8} The clinical presentation of an OSCC may vary from indurated, non-healing ulcers to exophytic, hyperkeratotic masses and, less frequently, as red, submucosal and slightly indurated lesions with an apparently intact epithelium.^{7,13} A verrucous carcinoma is a specific variant of OSCC.²⁰ Histopathological examination generally shows a well-differentiated OSCC. The essential features of OSCC are invasion through the basement membrane and epithelial dysplasia.^{5,13} Red areas, rather than white areas, should preferentially be biopsied because of the more frequent dysplastic features.²³

Tobacco exposure, alcohol abuse (and especially the combination of the two), poor nutrition, leucoplakia and erythroplakia are known to be contributing risk factors in OSCC.^{6,7} The predilection sites are the lower lip, the lateral parts of the tongue and the floor of the mouth. The risk of metastasis is largely related to the size of the primary tumor. The average 5-year survival rate is about 50%, in spite of surgery and radiotherapy. An early detection of this malignancy favors the prognosis significantly.^{7,8,23} The possible malignant transformation of OLP still remains a controversial issue in the literature.^{2,9-12,17,21} The incidence of malignant transformation of OLP into an OSCC is reported to range from 0 to 10%.¹³ The possible premalignant nature of OLP is very important for the information that should be provided to the patient, the recognition of possible risk factors, the necessity for meticulous clinical and histopathological examination, adequate treatment and the schedule of follow-up.

The aim of this study was to determine the incidence of oral malignancies associated with OLP and to investigate whether OLP is intrinsically premalignant or whether there are also contributing external risk factors.

Patients and methods

We conducted a retrospective cohort study in 200 Caucasian patients with a confirmed diagnosis of OLP based on medical history, physical and histopathological examination. Special attention was paid to aspects such as sex, race, age, clinical variant of OLP, involved anatomical site, duration of OLP, histopathology, prior treatment (topical and systemic immunosuppressive medication), exposure to tobacco, alcohol abuse, candidosis, concomitant extra-oral lichen planus and associated systemic diseases.

This study was conducted from 1991-1993 at the Department of Dermatology, Erasmus MC, University Medical Center, Rotterdam, The Netherlands and continued from 1994-2003 at the Department of Dermatology, Albert Schweitzer Hospital, Dordrecht, The Netherlands.

Exclusion criteria were an age younger than 18 years, a first histopathological examination with atypical or (lichenoid) dysplastic or even malignant features, a follow-up period of less than 2 years and an oral malignancy in the past.

One or more 3-mm diameter punch biopsies were taken from the hyperkeratotic, the atrophic or the erythematous lesions and in case of erosions or ulcers from the edge of the lesions from all patients for histopathological examination. The biopsy specimens were fixed in buffered 4% formalin and sections were stained with hematoxylin and eosin. Sections were also stained with period acid-Schiff (PAS) reagent. If there were obvious erosions or ulcers in OLP, the biopsy specimens were transported in physiological saline for direct immunofluorescence examination to exclude a bullous auto-immune disease or lupus erythematosus. Histopathological examination was repeated if there was a clinical suspicion of malignancy during the follow-up period.

Histopathological features of "evident OLP" comprise a varying degree of focal hyperkeratosis or parakeratosis, irregular acanthosis or atrophy, liquefaction degeneration of the basal cell layer and a dense band-like lymphocytic infiltrate high in the lamina propria. Hyaline (Civatte's) bodies, which represent degenerated basal cells, are occasionally seen in the epithelium. If the histopathological changes were less pronounced, especially the basal cell layer degeneration and the inflammatory infiltrate, the diagnosis "compatible with OLP" was established. If there were more aspecific changes, then this was diagnosed as "non-specific", but only after other diagnoses had been excluded. Special attention was paid to atypical and (lichenoid) dysplastic changes and signs of malignancy. If there were signs of cutaneous lichen planus (CLP), histopathological examination of the skin lesions was also undertaken.

All patients were followed-up at least once a year and more often if necessary depending on the symptomatology, the extent and the severity of OLP and the possible accompanying external risk factors. The patients were requested to consult us earlier than the regular visit if the oral lesions progressed significantly. Candidosis superposed on OLP was treated adequately. If there were

influenceable external contributory risk factors such as exposure to tobacco or alcohol abuse for malignancy, the patient was strongly urged to discontinue the (bad) habit. Moreover, patients were also provided with information on possible aggravating factors for OLP such as stress, specific foods (citrus and spicy ingredients), mechanical traumata, irritation or allergy to dental restorations and poor oral hygiene.

In case of an oral malignancy, the patient was referred to the Department of Head & Neck Oncology of the Erasmus MC, University Medical Center, Rotterdam, for further evaluation and treatment.

Statistical analysis of the results was performed using the exact chi-square test and by assuming a negative exponential distribution of time to the incidence of OSCC in person-years, which is identical to a Poisson distribution for the number of incidences (with a statistical significance set at $P < 0.05$).

Results

A total of 200 Caucasian patients, 132 (66%) women and 68 (34%) men, aged 25 to 83 years (mean age 53 years), were evaluated in this study. The hyperkeratotic variant of OLP was predominantly seen in 92 (46%) patients (61 women and 31 men), the erosive or ulcerative variant in 67 (33.5%) patients (41 women and 26 men) and the atrophic or erythematous variant in 41 (20.5%) patients (30 women and 11 men). The sites affected by OLP were, in diminishing frequency, the buccal mucosa (symmetrical), the lateral margins of the tongue, the gingiva, the labial mucosa and the dorsal part of the tongue. Lesions on the palate and the floor of the mouth were observed only in 5 patients.

Histopathological examination showed “evident OLP” in 89 patients, “compatible with OLP” in 88 patients and “non-specific changes” in 23 patients without a significant difference between men and women. Based on clinical and histopathological examination, 38 (19%) patients also had CLP and 12 (9%) women with OLP had symptomatic vulvar and vaginal lichenoid lesions.

The follow-up period ranged from 7 to 13 years (mean 10 years) and an OSCC was encountered at the same site of OLP in 3 of the 200 patients with OLP after a mean period of 4.3 years. The characteristics of these 3 patients are shown in Table I. Histopathological examination was repeated in 4 other patients during the follow-up period, because a malignancy was suspected. However, none of these 4 patients had an OSCC. There was no substantial change in the symptoms of OLP in the 3 patients at the time when an OSCC was detected. All the 3 patients were effectively treated for OSCC. The exact treatment regime is beyond the scope of this study. In the follow-up period of 3 to 5 years (mean 4 years), no indications of tumor recurrences or metastases were observed.

Table I. Clinical characteristics of the 3 patients with OLP in whom an OSCC was diagnosed.

Patient	A	B	C
- sex/age (years)	F ; 67	M ; 59	F ; 78
- variant of OLP	erosive/ulcerative	hyperkeratotic	atrophic/erythematous
- histopathology	evident OLP	evident OLP	evident OLP
- prior immunosuppressive			
- treatment: topical	corticosteroids, cyclosporin	corticosteroids	corticosteroids
systemic	corticosteroids, cyclosporin (during 2 years)	–	–
- OSCC (type and stage)	ulcer, stage III (T2N1M0)	keratotic/ exophytic stage I (T1N0M0)	ulcer, stage II (T2N0M0)
- histopathology	moderately differentiated	well differentiated	well differentiated
- interval oral lesions/ diagnosis of OLP	0.5 year	1 year	0.5 year
- interval OLP/OSCC	4 years	3 years	6 years
- affected site OLP	buccal, tongue, gingiva	buccal (reticular), tongue (plaque)	buccal mucosa (symmetr)
- site of OSCC	lateral part of the tongue	lateral part of the tongue	buccal mucosa (one side)
- extra-oral LP	–	–	–
- tobacco exposure	–	25 cigarettes/day for 20 years; stopped smoking, 0.5 years after the diagnosis of OLP	–
- alcohol abuse	–	–	–
- poor oral hygiene	–	moderately	–
- denture	–	–	yes
- candidosis	–	–	–
- positive patch test (dental metal or acrylates)	–	–	–
- concomitant diseases	osteoporosis	hypertension	(hypo)thyroid disease, diabetes mellitus type II.

Statistical analysis was based on the incidence of 4 oral malignancies per 100,000 individuals per year in Europe versus 1, 2 or 3 cases of OSCC of 2000 person-years in our study.

The probability of at least one case of OSCC in our cohort study is $P = 0.08$ according to the Poisson distribution, which could be attributed to chance alone. However, the probability of at least two or three cases is $P = 0.003$ and $P = 0.00008$, respectively, which is statistically significant. This means that it is highly improbable that at least two or three cases of OSCC in our study were encountered by chance alone.

Discussion

Hallopeau already reported a case of OLP with malignant degeneration in 1910.¹⁴ Krutchkoff et al criticized the literature on the malignant transformation of OLP from the period 1950-1976 and accepted only 15 (7%) of the 223 published cases as adequately documented.¹⁵ As shown in Table II, Van der Meij et al used the same criteria from the period 1977-1999 and accepted 33 (34%) of 98 reported cases as adequately documented.¹¹ Their objections were largely based on the uncertainty of the initial diagnosis of OLP on clinical and histopathological grounds, the occurrence of oral cancers remote from the anatomic site of OLP and the frequently inadequate information on prior exposure to potentially carcinogenic substances.^{11,15} Several remarks can be made on these objections.

Even if a reliable biopsy is obtained from the patient at the first visit to confirm the initial diagnosis of OLP, there is a significant inter- and intra-observer variation in the interpretation of the criteria for establishing the diagnosis of OLP despite the criteria by the WHO.^{9,16} Moreover, important aspects such as dysplastic or atypical changes are not always clearly and carefully detailed in the histopathological reports. Therefore, the results reported in different studies are not always easy to compare. If an OSCC occurs at a site remote from OLP, the direct relationship between the two may be disputed, because an OSCC

Legends to Table I:

- = none; F = female; M = male
- T = primary tumor
- T1 = tumor size < 2 centimeters
- T2 = tumor size between 2 and 4 centimeters
- N = regional lymph nodes
- N0 = no indication for lymph node metastases
- N1 = homolateral lymph node metastases < 3 centimeters
- M = distant metastases
- M0 = no indication for distant metastases
- symmetr = symmetrical

Table II. Criteria for acceptance of reported cases of OLP undergoing malignant transformation modified from Krutchkoff et al¹⁵ and Van der Meij et al.¹¹

-
- A: The original, clinical diagnosis must have been properly verified with histopathological evidence demonstrating at least the last 2 of the 4 following features:
- 1: Hyperkeratosis or parakeratosis.
 - 2: Saw-tooth rete pegs.
 - 3: Superficial infiltrate of lymphocytes.
 - 4: Basal cell liquefaction.
- B: History and follow-up:
- 1: Clinical and historical features of alleged transformation must have been adequately described (information such as age, gender, precise location and clinical description of lesions are necessary).
 - 2: Reported transformation should have had a proper follow-up (minimum of 2 years), with all changes in clinical features properly recorded.
- C: Tobacco exposure should have been properly documented for distinguishing between true malignant transformations and conventional oral carcinomas occurring in patients who happen to have OLP.
-

may obviously occur in the absence of OLP.^{11,15} Exposure to potentially carcinogenic substances could have occurred several years earlier, so that it could be easily missed as a relevant contributing external risk factor because OLP persists for many years. It is difficult to establish whether there is a synergistic premalignant effect in case of exposure to potentially carcinogenic substances (contributing external risk factors) and the persistence of OLP (intrinsic risk factor). Moreover, the mucosa is more vulnerable, particularly in the erosive and atrophic variants of OLP.^{3,10,29} The treatment of symptomatic OLP often consists of topical or systemic immunosuppressive medication, which may also increase the chances of developing an OSCC. The influence of immunosuppressive medication in a specific case is difficult to establish because the number of malignancies is relatively low.²⁹ The prevalence of oral cancer varies widely in different parts of the world. Its prevalence is high in parts of south-east Asia, especially in India, where the high prevalence is most likely related to tobacco exposure, betel nut chewing or “reverse” smoking.²³ It is reasonable to assume that the prevalence of OLP also varies significantly in various parts of the world; therefore, the prevalence of malignant transformation would also vary.⁹ A comparison between studies from different geographical areas of the world may thus be very problematic.

Nevertheless, there are other important contributing external risk factors such as alcohol abuse, exposure to tobacco, candidosis and poor nutrition for oral malignancy. These can be identified rather easily and are also easy to influence.^{3,18} It has been suggested that human papilloma virus and herpes simplex virus are also implicated as risk factors in oral carcinogenesis.³ Aggravating factors such as stress, specific foods (citrus and spicy ingredients), mechani-

cal traumata, irritation or allergy related to dental restorations and poor oral hygiene are also important in OLP.^{2,3}

Zhang et al examined 33 cases of OLP for allelic loss at nine loci located on chromosomes 3p, 9p, and 17p.²⁴ Loss of heterozygosity on these three arms frequently occurs in oral tumors and the presence of these alterations in premalignant lesions suggests that they may play an important role in tumor progression. The lesions in OLP showed minimal genetic deviations, scoring even lower than reactive oral lesions which are not deemed to be precancerous. However, epithelial dysplasia and malignant oral lesions had significantly increased genetic alterations. These findings did not support the hypothesis that OLP is a disorder with an increased intrinsic malignant potential.²⁴

Nevertheless, it has also been postulated that prostaglandines play a significant role in the regulation of the local immune response as well as carcinogen activation and tumor initiation. The inflammatory environment in OLP with cytokines may be particularly favorable for tumor promotion. Interleukin-1 leads to an activation of several prostaglandines-mediated events via the action of cyclooxygenase-2 (COX-2) on arachidonic acid.²⁵ Increased prostaglandin E2 levels have been demonstrated in tumor specimens of patients with squamous cell carcinoma, and COX-2 has been shown to be overexpressed nearly 100-fold in squamous cell carcinomas of the head and the neck.^{26,27} Theoretically, these data could suggest that more aggressive treatment in OLP against the increased inflammatory response in OLP may restore normal immunological surveillance and possibly interrupt the progression into invasive cancer.²

Valente et al reported in a study with 28 patients an overexpression of p53 gene mutations investigated by immunohistochemistry in cases of OLP with a high risk of neoplastic transformation.²⁸

If the criteria by Krutchkoff et al (Table II) are applied in our study, then patient B who smoked heavily should be considered as a drop-out.^{11,15} In that case, 2 out of the 200 patients investigated in this study developed an OSCC. Patient A had also received systemic immunosuppressive medication (corticosteroids and cyclosporin) during a period of about 2 years, which could have increased the chance of developing a malignancy. In that case, only 1 out of the 200 patients may be regarded as a real intrinsic malignancy. Therefore, it still remains unclear whether OLP has an intrinsic malignant potential because a single OSCC may occur by chance alone. In that case, OLP does not fulfill the WHO criterion of a precancerous condition: "a generalized state associated with a significant increased risk of cancer".^{3,22} In our opinion, it is very likely that there is a synergy between intrinsic (chronic inflammatory features in OLP) and contributing external risk factors in possible malignant transformation in OLP. It has been reported that a specific clinical variant of OLP (either hyperkeratotic or erosive) had a higher chance of transformation into an OSCC.^{3,10,29} The results of other studies including our study fail to support this because of the low number of patients. The follow-up period also varied from 1 to 4 visits per year in other

studies.^{9,19} A more frequent follow-up visit does not necessarily lead to an improved prognosis for OLP patients with an OSCC.⁹ We recommend a follow-up of at least one or two visits per year as long as OLP persists. A careful physical examination at each visit is imperative and histopathological examination should be repeated if a malignancy is suspected. From a practical point of view, we concur with Voûte et al in that we are also somewhat reluctant to routinely inform each patient with OLP on the possible premalignant character of their lesions, particularly if contributing external risk factors are also involved.¹⁹

The results of this study showed that it is mandatory to establish a correct diagnosis of OLP based on history, clinical examination and histopathology. Nonetheless, the results failed to provide an answer to the controversial issue of whether OLP has an intrinsic malignant potential. The exact incidence of OSCC in patients with OLP is difficult to establish, because of the low number of patients involved and because other contributing external risk factors may also be relevant for developing an oral malignancy. Further larger cohort studies are necessary to resolve this issue.

References

1. Vincent SD, Fotos LPG, Baker KA et al. Oral lichen planus: the clinical, historical, and therapeutic features of 100 cases. *Oral Surg Oral Med Oral Pathol* 1990; 70: 165-71.
2. Eisen D. The clinical features, malignant potential and systemic associations of oral lichen planus: a study of 723 patients. *J Am Acad Dermatol* 2002; 46: 207-14.
3. Scully C, Beyli M, Ferreiro MC et al. Update on oral lichen planus: etiopathogenesis and management. *Crit Rev Oral Biol Med* 1998; 9: 86-122.
4. Parkin DM, Whelan SL, Ferlay J et al. Cancer incidence in five continents, Vol. VII (IARC Scientific publications No. 143). Lyon: IARC. 1997.
5. Pindborg JJ, Reichart PA, Smith CJ et al. International histological classification of tumours. Histological typing of cancer and precancer of the oral mucosa. 2nd edn. World Health Organization. Berlin Heidelberg New York: Springer-Verlag. 1997.
6. Schlecht NF, Franco EL, Pintos J et al. Interaction between tobacco and alcohol consumption and the risk of cancers of the upper aerodigestive tract in Brazil. *Am J Epidemiol* 1999; 150: 1129-37.
7. van der Waal I. Tumoren van het mondslijmvlies. [Dutch]. Tumors of the oral mucosa. *Ned Tijdschr Derm Venereol* 2002; 12: 368-70.
8. van der Meij EH, Bezemer PD, van der Waal I. Cost-effectiveness of screening for the possible development of cancer in patients with oral lichen planus. *Comm Oral Dent Epidemiol* 2002; 30: 342-51.
9. Mattsson U, Jontell M, Holmström P. Oral lichen planus and malignant transformation; Is a recall of patients justified? *Crit Rev Oral Biol Med* 2002; 13: 390-6.
10. Yaacob HB, Tan PL, Ngeow WC. Malignancy in oral lichen planus: a review of a group from the Malaysian population. *J Oral Sci* 2002; 44: 65-71.

11. van der Meij EH, Schepman KP, Smeele LE et al. A review of the recent literature regarding malignant transformation of oral lichen planus. *Oral Surg Oral Med Oral Pathol Oral Radiol Endod* 1999; 88: 307-10.
12. Rajenthiran R, McLean NR, Kelly CG et al. Malignant transformation of oral lichen planus. *Eur J Surg Oncol* 1999; 25: 520-3.
13. Mignogna MD, Lo Muzio L, Lo Russo L et al. Clinical guidelines in early detection of oral squamous cell carcinoma arising in oral lichen planus: a 5-year experience. *Oral Oncol* 2001; 37: 262-7.
14. Hallopeau H. Sur un cas de lichen de Wilson gingival avec neoplasie voisine dans la region maxillaire. [French]. *Bull Soc Fr Derm Syph* 1910; 17: 33.
15. Krutchkoff DJ, Cutler L, Laskowski S. Oral lichen planus: the evidence regarding potential malignant transformation. *J Oral Pathol* 1978; 7: 1-7.
16. van der Meij EH, Reibel J, Slootweg PJ et al. Interobserver and intraobserver variability in the histologic assessment of oral lichen planus. *J Oral Pathol Med* 1999; 28: 274-7.
17. Allen CM. Is lichen planus really premalignant? *Oral Surg Oral Med Oral Pathol Oral Radiol Endod* 1998; 85: 347.
18. Lozada-Nur F. Oral lichen planus and oral cancer: is there enough epidemiologic evidence? *Oral Surg Oral Med Oral Pathol Oral Radiol Endod*; 89: 265-6.
19. Voûte ABE, de Jong WFD, Schulten EAJM et al. The possible premalignant character of oral lichen planus; The Amsterdam experience. *J Oral Pathol Med* 1992; 21: 326-9.
20. Warshaw EM, Templeton SF, Washington CV. Verrucous carcinoma occurring in a lesion of oral lichen planus. *Cutis* 2000; 65: 219-22.
21. Eisenberg E, Krutchkoff DJ. Lichenoid lesions of the oral mucosa. *Oral Surg Oral Med Oral Pathol* 1992; 73: 699-704.
22. Holmstrup P, Thorn JJ, Rindum J et al. Malignant development of lichen planus-affected oral mucosa. *J Oral Pathol* 1988; 17: 219-25.
23. Scully C. The oral cavity. In: *Textbook of Dermatology*. Champion RH, Burton JL, Burns DA, Breathnach SM. 6th edn, Vol 4. Oxford: Blackwell Science Ltd 1998; 3074-6.
24. Zhang L, Michelsen C, Cheng X et al. Molecular analysis of oral lichen planus: a premalignant lesion? *Am J Pathol* 1997; 151: 323-7.
25. Noguchi K, Shitashige M, Ishikawa I. Involvement of cyclooxygenase-2 in interleukin-1 alpha-induced prostaglandin production by human periodontal ligament cells. *J Periodontol* 1999; 70: 902-8.
26. Pinto S, Gallo O, Dilaghi M et al. Prostaglandines in peritumor synthesis. *Prostaglandines Leukot Essent Fatty Acids* 1990; 39: 53-7.
27. Mestre JR, Chan G, Zhang F et al. Inhibition of cyclooxygenase-2 expression: an approach to preventing head and neck cancer. *Ann N Y Acad Sci* 1999; 889: 62-71.
28. Valente G, Pagano M, Carrozzo M et al. Sequential immunohistochemical p53 expression in biopsies of oral lichen planus undergoing malignant evolution. *J Oral Pathol Med* 2001; 30: 135-40.
29. van der Meij EH, Schepman KP, van der Waal I. The possible premalignant character of oral lichen planus and oral lichenoid lesions: a prospective study. *Oral Surg Oral Med Oral Pathol Oral Radiol Endod* 2003; 96: 164-71.

CHAPTER 6

ORAL LICHEN PLANUS AND HEPATITIS C VIRUS INFECTION

R. LAEIJENDECKER, MD¹ (and formerly ²),
Th. VAN JOOST, MD, PhD (formerly²),
B. TANK, PhD², and
H.A.M. NEUMANN, MD, PhD²

ARCHIVES OF DERMATOLOGY 2005; 141: 906-7.

Funding: None.

Conflict of interest: None.

Corresponding author: R. Laeijendecker, Department of Dermatology, Albert Schweitzer Hospital, P.O. Box 444, 3300 AK Dordrecht, The Netherlands.

Tel: 00 31 78 6523330. Fax: 11 31 78 6523866.

E-mail: R.Laeijendecker@asz.nl

¹ Department of Dermatology, Albert Schweitzer Hospital, locations Dordwijk and Sliedrecht, Albert Schweitzerplaats 25, 3318 AT Dordrecht, The Netherlands.

² Department of Dermatology and Venereology, Erasmus MC, University Medical Center Rotterdam, Dr. Molewaterplein 40, 3015 GD Rotterdam, The Netherlands.

ABSTRACT

- Background:** The possible association between oral lichen planus and hepatitis C virus infection is still debated in the literature.
- Objectives:** To determine the possible relationship between oral lichen planus and hepatitis C virus infection in The Netherlands and to investigate whether routine screening for anti-hepatitis C virus antibodies and liver enzymes is necessary in these patients. Moreover, attempts were made to clarify the discrepant results reported in the literature on the association of oral lichen planus with hepatitis C virus infection.
- Methods:** A prospective study in a group of 100 patients with oral lichen planus and a control group of 100 patients with psoriasis vulgaris was carried out from 1995 to 2002. All patients were at least screened for liver enzymes and anti-hepatitis C virus antibodies.
- Results:** In both groups, each with 65 women and 35 men, there was no serological evidence of antibodies against hepatitis C virus at all. In the group of oral lichen planus, there were 2 (2%) patients with significant elevated liver enzyme levels, and in the control group of psoriasis vulgaris, there were also 2 (2%) patients with elevated liver enzyme levels, which was not a statistically significant difference ($P > 0.99$). In these 4 patients, there was also no evidence of hepatitis A virus and hepatitis B virus infections.
- Conclusions:** Our study suggests that there is no indication for routinely screening for anti-hepatitis C virus antibodies in patients with oral lichen planus in The Netherlands. Liver enzyme values should be determined only in a relevant, clinical situation. The discrepancies in the literature regarding the possible association of oral lichen planus and hepatitis C virus are largely based on the differences in prevalence of both hepatitis C virus infection and possibly also of oral lichen planus world-wide with a population of different genetic make-up, different environmental conditions and possible variations in hepatitis C virus infection and host immune responses.
- Keywords:** Oral lichen planus, Hepatitis C virus infection, Liver enzymes.

Introduction

Oral lichen planus (OLP) has a prevalence of about 0.5 to 2%. Generally, it is a disease of the middle-aged and the elderly and the female-to-male ratio is about 2: 1.¹ The diagnosis of OLP is based on a combination of characteristic clinical findings, history and histopathological examination. Oral lichen planus can be categorized into a hyperkeratotic (white) variant often without symptoms. The atrophic or erythematous (red) variant and the erosive or ulcerative (yellow) variant commonly have persistent symptoms of pain or stinging.¹⁻³ The exact etiopathology of OLP is unknown, but an immune-mediated (T-cell dependant) pathogenesis has been proposed.¹⁻⁴

Several possible causes, aggravating factors and associations have been suggested. These include specific medication, auto-immunity, graft-versus-host disease, trauma, (emotional) stress, infections by plaque-causing micro-organisms, hepatitis B – and especially hepatitis C viruses.³

Hepatitis C virus (HCV) is an RNA virus, which was identified in 1989. It is a major cause of acute and chronic hepatitis which may often be asymptomatic.^{5,6} Modes of transmission are transfusion of blood, injection with dirty needles and, in lower frequency, sexual or vertical transmission.^{5,6} Chronic hepatitis C virus infection develops in about 75% of those who are infected and may lead to cirrhosis which may culminate in liver failure or even hepatocellular carcinoma.⁵ Hepatitis C virus infection seems to be the main cause of liver disease in patients with OLP.^{7,12} The possible relationship between OLP and HCV infection has been studied extensively but the results are rather discrepant and controversial.⁷⁻¹⁷

The aim of this study was to determine the possible relationship between OLP and HCV in The Netherlands and to investigate whether screening for anti-HCV antibodies and liver enzymes is necessary in these patients. Moreover, attempts were made to clarify the discrepant results reported in the literature on the association of OLP with HCV.

Patients and methods

A prospective study in group (I) of 100 Caucasian patients with a confirmed diagnosis of OLP based on medical history, physical and histopathological examination according to the diagnostic criteria defined by the WHO was performed. The control group (II) consisted of 100 Caucasian patients with psoriasis vulgaris matched for sex in clusters of 10 patients. The diagnosis of psoriasis vulgaris was made mainly on clinical grounds and if necessary with additional histopathological examination. The study was carried out from 1995 to 2002 at the Department of Dermatology, Albert Schweitzer Hospital, Dor-

drecht, The Netherlands. Exclusion criteria in both groups were an age younger than 18 years, the occurrence of OLP and psoriasis vulgaris in the same patient, prior treatment with potentially hepatotoxic agents such as methotrexate and treatment with PUVA, retinoids, cyclosporin or fumaric acid derivatives in the past two years.

All patients were screened for liver enzyme levels including total bilirubin (TB) (reference values, < 17 microMol/l or < 1.0 mg/dL), aspartate aminotransferase (ASAT) (reference value, < 30 U/l), alanine aminotransferase (ALAT) (reference value, < 30 U/l), gamma-glutamyl transpeptidase (GGT) (reference values, < 40 U/l (men), < 25 U/l (women)) and alkaline phosphatase (ALP) (reference value, < 100 U/l). Deviations were considered clinically relevant when two or more liver enzyme values were abnormal or if at least one value exceeded the upper limit by more than two times. In case of deviations, the determination of liver enzyme levels was repeated after 3 weeks. These patients were also tested for possible HAV and HBV infections.

Anti-HCV antibodies were determined with a third-generation enzyme-linked immunosorbent assay (ELISA), the results of which were confirmed by immunoblotting technique.

Statistical analysis of the results was performed by means of the exact stratified 2x2 (contingency) table analysis and the Unpaired t-test in which two-sided P-values were calculated, with statistical significance set at $P < 0.05$.

Results

The OLP group (I) comprised 65 women and 35 men, aged 26 to 77 years (mean 54 years). A hyperkeratotic variant of OLP was diagnosed in 68 patients (42 F and 26 M). The erosive or ulcerative variant was observed in 22 patients (14 F and 8 M) and the atrophic or erythematous variant in 10 patients (9 F and 1 M).

The control group (II) comprised 65 women and 35 men, aged 19 to 82 years (mean 51 years). The mean ages in the two groups did not differ significantly ($P > 0.99$).

There was no serological evidence of antibodies against HCV in either group. In group I, there were 2 (2%) patients (1 and 2) with the hyperkeratotic variant of OLP with several slightly elevated liver enzyme levels (< 2 times the normal upper limit) (Table I). In group II, there were also 2 (2%) patients with several elevated liver enzyme levels. One patient (3) had slightly elevated liver enzyme levels (< 2 times the normal, upper limit) and another patient (4) had abnormal liver enzyme levels with values of ALAT, ASAT and GGT between 2 and 3 times the normal upper limit (Table I). These abnormalities in liver enzyme values did not change significantly in the second determination after 3 weeks.

Table I. Results in 4 patients with elevated liver enzyme levels and determination of serological evidence of hepatitis A, B or C virus infection.

	Age	TB	ASAT	ALAT	GGT	ALP	HAV	HBV	HCV
Group I (OLP)	(years)	(micro-mol/l) (mg/dL)	(U/l)	(U/l)	(U/l)	(U/l)			
1-F	48	16 (0.9)	35	35*	40*	80	–	–	–
2-M	66	20* (1.2*)	45*	45*	65*	100	–	–	–
Group II (psoriasis vulgaris)									
3-F	42	30* (1.8*)	50*	52*	45*	110*	–	–	–
4-M	54	25* (1.5*)	65**	65**	110**	120*	–	–	–

– = negative.

* = less than 2 times the normal upper limit.

** = between 2 and 3 times the normal upper limit.

F = Female

M = Male

After consultation with the Department of Internal Medicine and echographic liver examination, no conclusive explanation could be found for the results in patients 1 and 2 in group I or for those in patient 3 in group II. In group II, patient 4 was an excessive alcohol user (about 12 units/day). Moreover, there were also no signs of HAV- and HBV-infections in these 4 patients. The variations in the liver enzyme values between the 2 groups after adjusting for sex were not considered as statistically significant ($P > 0.99$).

Discussion

Chronic hepatitis C virus infection has been associated with several extra-hepatic diseases, many of which may be seen by dermatologists. The following manifestations have been mentioned: antiphospholipid syndrome, auto-immune thrombocytopenia, autoimmune thyroiditis, B-cell lymphoma, Behçet syndrome, canities (= graying of hair), glomerulonephritis, leukocytoclastic vasculitis, LP, MALT lymphoma (mucosal-associated lymphoid tumors), mixed type cryoglobulinemia, Mooren's corneal ulcer, plasmacytoma, polyarteritis nodosa, porphyria cutanea tarda, prurigo nodularis, sialoadenitis (Sjögren's-like) and vitiligo.^{3,5}

World-wide, it has been estimated that approximately 170,000,000 individuals are infected with HCV. This is about 3% of the world population.⁵ Hepatitis C virus infection is prevalent in individuals older than 40 years, but is uncommon in those younger than 20 years.⁵ The prevalence of both HCV and OLP showed considerable geographic variations.^{6,7,14,17} In The Netherlands, the prevalence of HCV has been estimated at between 0.1% and 0.7%.¹⁸ However, the prevalence is as high as 62% in some regions in Japan.¹⁹ In parts of the world with a high prevalence of HCV, for example in Brazil, Japan, Italy and Spain, a positive correlation between HCV and OLP has been reported.^{13,15,17,20} In these countries, HCV may play a role in the pathogenesis of OLP. However, the exact etiopathogenic relationship between OLP and liver disease remains unknown. In regions with a low prevalence of HCV, for example the United Kingdom, Scandinavia and The Netherlands, no correlation between OLP and HCV was found, but conflicting results were reported from Germany.^{7,9,10,16,21,22} It has been suggested that the erosive variant of OLP may have a higher correlation with HCV than the hyperkeratotic variant of OLP.^{13,23} The lack of a control group was present in certain other studies making the correct interpretation of the results rather difficult.^{7,23} However, our study has a larger group of patients with OLP with an adequate control group. In the pathogenesis of OLP in relation to HCV, several aspects such as differences in prevalence of OLP and HCV, differences in the genetic make-up and age of the involved population, environmental factors and possibly the variation in the infection with a specific HCV subtype and the host immune responses may play a role.^{3,5,7,17}

In a few studies, HCV RNA was isolated from the oral mucosal tissue in patients with HCV regardless of OLP. No HCV RNA was isolated from patients who were not infected with HCV. These findings indicate that HCV alone is not sufficient for the development of OLP, but that other factors may also play an important role.^{17,26,27}

In our study, there was no correlation between OLP (or a specific variant of OLP) and HCV. Our findings indicate that screening for anti-HCV antibodies in a comparative population is not required in The Netherlands. The prevalence of HCV appears to be too low and the probability that HCV plays an etiopathogenic role in OLP in The Netherlands is negligible. This advice could possibly be different if more patients with OLP from the Mediterranean region with a probably higher prevalence of HCV are investigated.

Two (2%) of 100 patients with OLP and 2 (2%) of the patients in the control group (Table I) had several abnormal asymptomatic liver enzyme values. However, a direct relationship between liver function and the pathogenesis or persistence of OLP is unclear. In our opinion, determination of liver enzyme levels should be performed selectively, especially before starting or evaluating a systemic treatment or for investigation of possible known risk factors such as alcohol abuse, cholestasis, specific infections and prior systemic medication with possible hepatotoxic effects.

The conclusions of this study are that screening for anti-HCV antibodies in patients with OLP in The Netherlands is unwarranted and that liver enzyme levels should be determined only in a clinically relevant situation. The discrepancies in the literature regarding the possible association of OLP and HCV are largely based on the prominent world-wide differences in the prevalence of both HCV infection and possibly also of OLP among populations with different genetic make-up, different environmental conditions and possible variations in HCV infection and host immune responses.

References

1. Vincent SD, Fotos LPG, Baker KA et al. Oral lichen planus: the clinical, historical, and therapeutic features of 100 cases. *Oral Surg Oral Med Oral Pathol* 1990; 70: 165-71.
2. Eisen D. The clinical features, malignant potential and systemic associations of oral lichen planus: a study of 723 patients. *J Am Acad Dermatol* 2002; 46: 207-14.
3. Scully C, Beyli M, Ferreiro MC et al. Update on oral lichen planus: etiopathogenesis and management. *Crit Rev Oral Biol Med* 1998; 9: 86-122.
4. Boyd AS, Neldner KH. Lichen planus. *J Am Acad Dermatol* 1991; 25: 593-619.
5. Bonkovsky HL, Mehta S. Hepatitis C: A review and update. *J Am Acad Dermatol* 2001; 44: 159-79.
6. Lodi G, Porter SR. Hepatitis C virus infection and lichen planus: a short review. *Oral Diseases* 1997; 3: 77-81.
7. van der Meij EH, van der Waal I. Hepatitis C virus infection and oral lichen planus: a report from the Netherlands. *J Oral Pathol Med* 2000; 29: 255-8.
8. Bellman B, Reddy RK, Falanga V. Lichen planus associated with hepatitis C (letter). *Lancet* 1995; 346: 1234.
9. Imhof M, Popal H, Lee JH et al. Prevalence of hepatitis C virus antibodies and evaluation of hepatitis C virus genotypes in patients with lichen planus. *Dermatology* 1997; 195(1): 1-5.
10. Grote M, Reichart PA, Berg T et al. Hepatitis C virus (HCV)-infection and oral lichen planus. *J Hepatol* 1998; 29: 1034-5.
11. Ingafou M, Porter SR, Scully C et al. No evidence of HCV infection or liver disease in British patients with oral lichen planus. *Int J Oral Maxillofac Surg* 1998; 27: 65-6.
12. Del Olmo JA, Pascual I, Bagan JV et al. Prevalence of hepatitis C virus in patients with lichen planus of the oral cavity and chronic liver disease. *Eur J Oral Sci* 2000; 108: 378-82.
13. Sanchez-Perez J, Castro M de, Buezo GF et al. Lichen planus and hepatitis C virus: prevalence and clinical presentation of patients with lichen planus and hepatitis C virus infection. *Br J Dermatol* 1996; 134: 715-9.
14. Mignogna MD, Lo Muzio L, Lo Russo L et al. Oral lichen planus: different clinical features in HCV-positive and HCV-negative patients. *Int J Dermatol* 2000; 39: 134-9.
15. Mignogna MD, Lo Muzio L, Favia G et al. Oral lichen planus and HCV infection: a clinical evaluation of 263 cases. *Int J Dermatol* 1998; 37: 575-8.

16. Roy KM, Dickson EM, Spiteri Staines K et al. Hepatitis C virus and oral lichen planus/ lichenoid reactions: Lack of evidence for an association. *Clin Lab* 2000; 46: 251-4.
17. Figueiredo LC, Carrilho FJ, de Andrade HF et al. Oral lichen planus and hepatitis C virus infection. *Oral Diseases* 2002; 8: 42-6.
18. van der Poel CL, Reesink HWQ, Mauser-Bunschoten EP et al. Prevalence of anti-HCV antibodies confirmed by recombinant immunoblot in different population subsets in The Netherlands. *Vox Sang* 1991; 61: 30-6.
19. Nagao Y, Sata M, Tanikawa K et al. Lichen planus and hepatitis C virus in the Northern Kyushu region of Japan. *Euro J Clin Invest* 1995; 25: 910-4.
20. Nagao Y, Sata M, Abe K et al. Immunological evaluation in oral lichen planus with chronic hepatitis C. *J Gastroenterol* 1997; 32: 324-9.
21. Tucker SC, Coulson IH. Lichen planus is not associated with hepatitis C virus infection in patients from northwest England. *Acta Derm Venereol* 1999; 79: 378-9.
22. Mobacken H, Nilsson LA, Olsson R et al. Incidence of liver disease in chronic lichen planus of the mouth. *Acta Derm Venereol* 1984; 64: 70-3.
23. Gandolfo S, Carbone M, Carrozzo M et al. Oral lichen planus and hepatitis C virus (HCV) infection: is there a relationship? A report of 10 cases. *J Oral Pathol Med* 1994; 23: 119-22.
24. Lozada-Nur F, Miranda C. Oral lichen planus: epidemiology, clinical characteristics, and associated diseases. *Semin Cutan Med Surg* 1997; 4: 273-7.
25. Lodi G, Carrozzo M, Hallett R et al. HCV genotypes in Italian patients with HCV-related oral lichen planus. *J Oral Pathol Med* 1997; 26: 381-4.
26. Arrieta JJ, Rodrigues-Inigo E, Casqueiro M et al. Detection of hepatitis C virus replication by in situ hybridization in epithelial cells of anti-hepatitis C virus-positive patients with and without oral lichen planus. *Hepatology* 2000; 32: 97-103.
27. Nagao Y, Sata M, Noguchi S et al. Detection of hepatitis C virus RNA in oral lichen planus and oral cancer tissues. *J Oral Pathol Med* 2000; 29: 259-66.

CHAPTER 7

ORAL LICHEN PLANUS IN CHILDHOOD

R. LAEIJENDECKER, MD¹ (and formerly²),
Th. VAN JOOST, MD, PhD (formerly²),
B. TANK, PhD²,
A.P. ORANJE, MD, PhD², and
H.A.M. NEUMANN, MD, PhD²

PEDIATRIC DERMATOLOGY 2005; 22(4): 299-304.

Funding: None.

Conflict of interest: None.

Corresponding author: R. Laeijendecker, Department of Dermatology, Albert Schweitzer Hospital, P.O. Box 444, 3300 AK Dordrecht, The Netherlands.

Tel: 00 31 78 6523330. Fax: 11 31 78 6523866.

E-mail: R.Laeijendecker@asz.nl

¹ Department of Dermatology, Albert Schweitzer Hospital, locations Dordwijk and Sliedrecht, Albert Schweitzerplaats 25, 3318 AT Dordrecht, The Netherlands.

² Department of Dermatology and Venereology, Erasmus MC, University Medical Center Rotterdam, Dr. Molewaterplein 40, 3015 GD Rotterdam, The Netherlands.

ABSTRACT

Background: Oral lichen planus is rare in childhood and there are only scarce reports on this subject in the literature.

Objectives: To report individual cases of oral lichen planus in childhood from our practice and to review the literature on this subject.

Methods: Patients younger than 18 years with oral lichen planus were included. Several clinical aspects, histopathology, patch test reactions and routine blood examination were investigated.

Results: Three patients from about 10,000 dermatological patients younger than 18 years were included from 1994 to 2003. An Asian girl aged 11 years had an asymptomatic reticular variant of oral lichen planus, which disappeared without any treatment after one year. An Asian boy aged 16 years had an erosive variant oral lichen planus with severe pain, which healed after intensive topical and systemic treatment in two years. A Caucasian girl aged 14 years had a reticular variant of oral lichen planus with a little soreness, which disappeared with topical treatment after three months.

Conclusions: Oral lichen planus in childhood is rare and therefore, at present it is not possible to draw firm conclusions on this subject. Oral lichen planus in childhood seems to occur preferentially in those of Asian race. The clinical features resemble those of oral lichen planus in adulthood. However, generally, the prognosis of oral lichen planus in childhood seems to be more favorable.

Keywords: Oral lichen planus, Childhood.

Introduction

Oral lichen planus (OLP) is a rather common disease in the middle-aged and elderly population and has a prevalence of about 0.5 to 2% with a female-to-male ratio of approximately 2: 1.^{1,2} In the contrast, oral lichen planus in childhood (OLPc) is rare and only a few reports are available in the literature.³⁻⁸

Oral lichen planus can be categorized into a hyperkeratotic (white) variant commonly without symptoms including reticular with Wickham's striae, papular or plaque-like forms. The atrophic or erythematous (red) variant and the erosive or ulcerative (yellow) variant often have persistent symptoms of pain or stinging aggravated during eating and drinking.¹⁻³ These variants may occur together in one patient or may transform into each other. The lesions were found (in diminishing frequency) on the buccal mucosa (often symmetrical), the lateral margins of the tongue, the gingiva, the lips and the palatum durum.^{2,3,9} Whereas CLP is self-limiting, OLP is chronic and rarely undergoes spontaneous remission. Oral lichen planus may be a potential source of significant morbidity.³ The family history of LP is more commonly positive in patients with LP in childhood than in adulthood.⁹ The exact cause of OLP remains unknown, but an immune-mediated (T-cell dependant) pathogenesis has been proposed.^{1,2,9} Possible causes such as an allergy to dental restorative materials (amalgam, gold), local trauma (Koebner's phenomenon) and several infections (plaque-causing micro-organisms and hepatitis B or C virus infection) of OLP have been reported. Moreover, genetic factors, lifestyle and (emotional) stress may be contributing factors in the pathogenesis of OLP. An increased association between LP and several auto-immune diseases, such as ulcerative colitis, myasthenia gravis, lupus erythematosus and alopecia areata, and perhaps also with systemic diseases, such as diabetes mellitus and hypertension has been reported. Many drugs are capable of producing a lichenoid drug eruption (LDE). Moreover, a lichenoid eruption may occur in graft-versus-host disease.^{2,3,9-11}

In this communication, three new cases of OLPc from our practice are reported together with a review of the current literature. Moreover, possible clinical differences between OLPc and OLP in adulthood (OLPa) are reported.

Patients and methods

We conducted a retrospective non-randomized study from 1994 to 2003 at the Department of Dermatology, Albert Schweitzer Hospital, Dordrecht, The Netherlands. It is a full-time practice with three dermatologists. One of them is especially interested in OLP. The hospital serves a region of about 500,000 inhabitants with a representative demographical structure. About 1% of the

inhabitants are of Asian race. Inclusion criterion was an age younger than 18 years. All patients were referred by a dentist or a physician. The diagnosis of OLP was based on a combination of characteristic clinical findings, history and histopathology. Investigations on possible signs of extra-oral LP, routine blood examination including liver enzymes, hepatitis B- and C-serology, glucose, thyroid-stimulating hormone (TSH) and antinuclear antibodies (ANA's) were performed. Items such as age, sex, race, oral hygiene, candidosis and family history of LP were also investigated. Patch testing with a standard series (according to the guidelines of the European standard series) and a dental metal series was performed and evaluated at least after three days.

One or two 3-mm punch biopsies for histopathological examinations were taken from the hyperkeratotic lesions from each of the three children and if there was an erosion or ulceration at the edge of the lesions. The biopsies were fixed in buffered 4% formalin and stained with hematoxylin and eosin and also with the periodic acid-Schiff (PAS) reagent. If there were obvious erosions in OLP, the biopsies were transported in physiological saline for direct immunofluorescence to exclude a bullous auto-immune disease or lupus erythematosus.

Histopathological criteria of OLP comprised varying degree of focal hyperkeratosis or parakeratosis, irregular acanthosis or atrophy, liquefaction degeneration of the basal cell layer and a dense band-like lymphocytic infiltrate high in the lamina propria. Hyaline (Civatte's) bodies, which represent degenerated basal cells, were occasionally seen in the epithelium. In case of less pronounced changes in the mucosa, especially the basal cell layer degeneration and the inflammatory infiltrate, the diagnosis "compatible with OLP" was given.

Statistical analysis of the results was performed by a Poisson distribution for the number of incidences of OLPc in the Asian race in the population (with statistical significance set at $P\text{-value} < 0.05$).

Results

In this study of 10 years approximately 10,000 patients younger than 18 years with a boy-to-girl ratio of about 1:1 visited our department and only 3 patients (0.03%) with OLPc could be included. The characteristics of the three patients are detailed in Table I. The patients were born and bred in The Netherlands. Their mean age was 13.7 years and the mean duration of OLPc was about 20 months. The mean follow-up period after the diagnosis of OLPc was 3 years. In patient A, an Asian girl, the duration of OLPc could not be established exactly because there were no symptoms. The regular examination by the dentist gave an indication of duration. The patient was not treated because of the lack of symptoms (Table I).

Table I. Clinical characteristics of the three patients with OLPC.

Patient	A	B	C
Sex/age (years)	F/ 11/ Asian	M/ 16/ Asian	F/ 14/ Caucasian
Predominantly variant of OLP	reticular (hyperkeratotic)	erosive/ ulcerative	reticular (hyperkeratotic)
Histopathology	compatible OLP	OLP	OLP
Duration before diagnosis/ Character of symptoms	6 months (?)/ asymptomatic	4 months/ severe oral pain and stinging	12 months/ soreness
Location of OLPC	buccal mucosa (symmetrical)	buccal mucosa, gingiva (asymmetrical)	buccal mucosa and lateral part of tongue (sym.)
Extra-oral LP	–	–	–
Oral hygiene/candidosis	normal/ -	poor/ -	good/ -
Amalgam fillings/ orthodontic retainer	4/ -	8/ -	- / + (without nickel)
Positive patch test reaction	Fragrance mix 8% pet	–	Nickel sulfate 5% pet
Blood examination deviations	–	–	–
Systemic medication	–	–	regularly cetirizine
Concomitant diseases	–	–	atopic dermatitis, allergic rhinitis
Family history of LP	–	–	–
Duration of OLPC (after diagnosis)	1 year	2 years	3 months
Treatment of OLPC	–	Topical steroids (classes II and IV), Lidocaine gels, Tacrolimus ointment. Systemic corticoste- roids and Systemic cyclosporin.	Topical tretinoin 0.05% ointment, Topical corticoste- roids (class II) (Triamcinolone acetonide 0.1% ointment)
Follow-up period (after diagnosis OLPC)	3 years	4 years	2 years

– = not present. + = present. F = female (girl). M = male (boy). Pet = petrolatum. Sym. = symmetrical.

In patient B, an Asian boy, there were severe persistent symptoms of oral pain and stinging which interfered with eating, talking and functioning for two years. The lesions of the gingiva showed the signs of a desquamative gingivitis. Oral hygiene was improved but did not influence the oral lesions significantly. He was treated with topical corticosteroids (classes II and IV), lidocaine gels and tacrolimus ointment during several months without significant improvement. He was subsequently treated with systemic corticosteroids (30 mg per day for 6 weeks) and systemic cyclosporin (4 mg per kilogram per day for 3 months) with remissions and exacerbations.

In patients A and B, there was no close contact between the amalgam fillings and the oral lesions.

Patient C, a Caucasian girl, had an OLPC with a little soreness. The treatment with topical tretinoin 0.05% ointment and topical corticosteroids (class II) was successful after 3 months. The clinical relevance of an allergy to nickel sulfate could not be demonstrated and a LDE to cetirizine was excluded because the OLPC healed in spite of continued cetirizine therapy. About 6 months after she developed symptoms of OLPC, she was fitted with an orthodontic retainer which remained during two years. Measures were taken to avoid local trauma of the oral mucosa by the orthodontic retainer in order to minimize the risk of aggravating or inducing OLPC via the Koebner's phenomenon. In this study the girl-to-boy ratio in the patients with OLPC was 2: 1. No relapses of OLPC were seen in these patients during the follow-up period. A malignant transformation of OLPC was also not observed (Table I).

The probability of at least one patient of the Asian race with OLPC could be attributable to chance according to the Poisson distribution ($P > 0.05$). However, the probability of at least two Asian patients equals $P = 0.0006$ (two-sided) which is statistically significant. This means that it is highly improbable that at least two Asian patients in our study are encountered on the basis of chance. An estimation of the relative risk for an Asian versus a non-Asian is 198, with a 95% confidence interval of 10.3-11678.

Discussion

Oral lichen planus in childhood (OLPC) was first described in 1920 and since then only a few articles in the literature have been published.^{4-6,12} Predisposing conditions such as GVHD, active hepatitis and hepatitis B immunization are rather frequently mentioned in these reports.¹³⁻¹⁵ It is suggested that childhood LP is more common in the tropics.¹⁶ Handa and Sahoo reported 87 cases of childhood LP in India. Seven patients showed concomitant involvement of the oral mucosa and only one patient had an isolated OLPC.¹⁷ Kumar et al reported involvement of the oral mucosa in only one of 25 children with cutaneous lesions.⁸ However, Sharma and Maheshwari reported 50 children with CLP and

there were concomitant oral lesions in 15 of them.¹⁸ Generally, the oral mucosa seems to be less commonly involved in children with LP than in adults.⁷

This study comprised a period of 10 years and also showed that OLPc is rare, because only three cases were encountered. It is not possible to draw firm conclusions on many aspects of OLPc especially on associated factors, treatment, prognosis, age of preference and the boy-to-girl ratio, because of the low numbers of OLPc both in this study and those reported in the literature. This study describes the clinical aspects of the patients with OLPc more extensively than any other previously reported study^{4,5} (Tables I and II). There are not many accompanying factors in our patients, which could contribute in the pathogenesis of OLPc (Table I).

Alam and Hamburger from the United Kingdom reported six cases of boys aged 6 to 14 years with OLPc over a 20-year period in 2001. Four of them were of Asian origin. However, two cases were not histologically proven.⁴ In contrast, in 1994, Scully et al reported three girls, one of whom was of Asian origin with OLPc.⁵ In our study 2 of the 3 patients were of Asian origin which is not in line with the proportion of Asians of about 1.0% in the population in our region. This possibly indicates that a specific genetic predisposition (HLA-dependant) in the Asian race, in spite of a negative family history, may be important in the pathogenesis of OLPc.^{2,4} The very high incidence of hepatitis C virus infection may play a role in OLPa in Japan. Nevertheless, hepatitis C virus infection is rare both in children and in The Netherlands.¹⁹⁻²¹ Yiannias et al reported that allergy to flavorings may be important in the pathogenesis of OLP.¹⁰ However, in our opinion, allergy to flavorings may be relevant in the diagnosis of allergic contact stomatitis.

There are also some controversies on the clinical features of OLPc. Some authors reported that the clinical features of OLPc and the affected sites of preference in the oral cavity (the buccal mucosa, the lateral part of the tongue and the gingiva) are essentially the same as those in OLPa.^{4,5} The affected sites in the oral cavity in this study are also the same. Others suggested that childhood LP is usually atypical with a positive family history and that OLPc often has asymptomatic lesions.^{4,6,14,15,17} In our opinion, the prognosis and the effect of treatment in OLPc seems to be more favorable than in OLPa which usually persists for many years in spite of intensive treatment and thorough investigation of associated factors.^{3,4,22} The treatment in symptomatic OLPc generally consists of topical treatments because of both the general improvement and the possible side effects of systemic therapy.^{2,4,5} Recently, there was a report on the beneficial effect of topical tacrolimus ointment 0.1% two to three times daily in erosive OLPa during three months.²³

The large difference in the prevalence of OLPc (0.03%) versus OLPa (0.5-2%) can only partially be explained by a low number of associated systemic diseases, auto-immune phenomena, infections (HBV and HCV), drugs and dental restorations in childhood, which may reduce the risk for developing OLPc.^{3,4,6}

Moreover, the diagnosis of OLPc may be missed because of irregular dental check ups, lack of symptoms and ignorance. The pathogenesis of OLP in short is proposed as follows: there is an antigenic reaction stimulated by endogenous and exogenous factors in a genetically predisposed patient whereby, the antigen-presenting cells in the epithelium activate CD4⁺ T-cells with an increased cytokine production (interleukine-1 and interferon-gamma) finally resulting in the activation of CD8⁺ T-cells, which cause damage to the mucosa featured in OLP.^{1,2,4}

The differential diagnosis of OLPc may be quite extensive and depends on the age of the patient, the clinical variant of OLPc, the severity and the persistence

Table II. Clinical characteristics of the patients with OLPc reported by Alam and Hamburger⁴ (D, E, F, G, H, I) and by Scully et al⁵ (J, K, L).

Patient	D	E	F	G	H
Sex/ age	M/ 8	M/ 6	M/ 7	M/ 14	M/ 14
Race	C	A	A	A	A
Variant of OLPc	Erosive/ ulcerative	Ulcerative	Atrophic/ hyperkeratotic	Hyperkeratotic	Hyperkeratotic
Histopathology	n.i.	OLP	OLP	Comp. OLP	OLP
Duration of OLPc/ character of symptoms	6 weeks pain	4 months ?	? soreness	? mild pain	? –
Location of OLPc	Buccal mucosa (a), gingiva	Lateral part of the tongue (a)	Buccal mucosa, gingiva	Buccal mucosa (s), tongue	Buccal mucosa (a)
CLP	–	–	–	n.i.	n.i.
Oral hygiene	Poor	n.i.	Poor	n.i.	n.i.
Blood deviations	n.i.	–	n.i.	–	–
Medication	–	–	–	Inhalers	–
Concomitant diseases	Congenital heart disease	–	–	Asthma	–
Family LP	–	+	–	n.i.	–
Duration of OLPc	2 months	2 years	4 years	2 years (?)	?
Treatment	Improvement of oral hygiene, Chlorhexidine gel	?	Chlorhexidine and corticosteroid mouthwashes	–	–

Table II (continued)

Patient	I	J	K	L
Sex/ age	M/ 11	F/ 10	F/ 11	F/ 10
Race	C	A	C	C
Variant of OLPC	Hyperkeratotic	Hyperkeratotic	Erosive	Erosive
Histopathology	n.i.	n.i.	OLP	OLP
Duration of OLPC/	6 months	3 months	?	?
Character of symptoms	–	soreness	soreness	pain (?)
Location of OLPC	Buccal mucosa (s), tongue	Buccal mucosa	Tongue	Floor of mouth
CLP	–	–	–	–
Oral hygiene	n.i.	n.i.	n.i.	n.i.
Blood deviations	n.i.	n.i.	n.i.	n.i.
Medication	–	–	–	–
Concomitant diseases	–	Vitiligo	–	–
Family LP	–	–	–	–
Duration of OLPC	?	?	?	?
Treatment	–	Topical corticosteroids (Beclomethasone)	Topical corticosteroids (Beclomethasone)	Topical corticosteroids, Intralesional Triamcinolone acetonide

– = not present. + = present. ? = unknown/not reported. n.i. = not investigated.

a = asymmetrical. s = symmetrical. Age is given in years. F = female (girl). M = male (boy).

A = Asian. C = Caucasian. Comp. = compatible with.

of the lesions and includes candidosis, morsicatio buccarum, leucoplakia, lingua geographica, bullous auto-immune diseases, lupus erythematosus, several viral infections (Herpes simplex, Epstein-Barr, Coxsackie, HIV), recurrent aphthous stomatitis, (caustic) traumata, erythema multiforme (major), allergic gingivostomatitis, gluten sensitivity enteropathy and less commonly M. Crohn, M. Behçet, oral lesions in immunodeficiencies, dyskeratosis follicularis, pachyonychia congenita, dyskeratosis congenita and white sponge naevus.²⁴ The possible malignant transformation of OLPC still remains a controversial issue in the literature.^{2,3} To our knowledge, no malignant transformation of OLPC has yet been reported.

Nevertheless, in our opinion, the schedule of follow-up of OLPC should be at least one or two visits per year as long as OLPC persists and even more frequently in symptomatic OLPC, in line with OLPa.

In summary, oral lichen planus in childhood is rare and therefore at present it is not possible to draw firm conclusions on this subject. Oral lichen planus in childhood seems to occur preferentially in those of Asian race. The clinical features resemble those of oral lichen planus in adulthood. However, generally, the prognosis of oral lichen planus in childhood seems to be more favorable.

References

1. Vincent SD, Fotos PG, Baker KA, Williams TP. Oral lichen planus: the clinical, historical and therapeutic features of 100 cases. *Oral Surg Oral Med Oral Pathol* 1990; 70: 165-71.
2. Scully C, Beyli M, Ferreiro MC, Ficarra G, Gill Y, Griffiths M et al. Update on oral lichen planus: etiopathogenesis and management. *Crit Rev Oral Biol Med* 1998; 9: 86-122.
3. Eisen D. The clinical features, malignant potential, and systemic associations of oral lichen planus: A study of 723 patients. *J Am Acad Dermatol* 2002; 46: 207-14.
4. Alam F, Hamburger J. Oral mucosal lichen planus in children. *Int J Paed Dent* 2001; 11: 209-14.
5. Scully C, de Almeida OP, Wellbury R. Oral lichen planus in childhood. *Br J Dermatol* 1994; 134: 131-3.
6. Rybojad M, Moraillon I, Laglenne S et al. Lichen plan de l'enfant. [French]. *Ann Dermatol Venerol* 1998; 125: 679-81.
7. Kanwar AJ, Handa S, Ghosh S et al. Lichen planus in childhood: a report of 17 patients. *Pediatr Dermatol* 1991; 8(4): 288-91.
8. Kumar FV, Garg BR, Baruah MC et al. Childhood lichen planus. *J Dermatol* 1993; 20: 175-7.
9. Boyd AS, Neldner KH. Lichen planus. *J Am Acad Dermatol* 1991; 25: 593-619.
10. Yiannias JA, el-Azhary RA, Hand JH, Pakzad SY, Rogers RS. Relevant contact sensitivities in patients with the diagnosis of oral lichen planus. *J Am Acad Dermatol* 2000; 42: 177-82.
11. Miles DA, Howard MM. Diagnosis and management of oral lichen planus. *Dermatol Clin* 1996; 14: 281-90.
12. Culver GDA. Clinical study of lichen planus. *Arch Derm Syphilol* 1920; 1: 43.
13. Nicolatou-Galitis O, Kitra V, van Vliet-Constantinidou C et al. The oral manifestations of chronic graft-versus-host disease (cGVHD) in paediatric allogeneic bone marrow transplant recipients. *J Oral Pathol Med* 2000; 30: 148-53.
14. Cottoni F, Ena P, Tedde G et al. Lichen planus in children: a case report. *Pediatr Dermatol* 1993; 10(2): 132-5.
15. Mériçou D, Léauté-Labrèze C, Louvet S et al. Lichen plan de l'enfant: Rôle des campagnes de vaccination anti hépatite B ? [French]. *Ann Dermatol Venerol* 1998; 125: 399-403.
16. Ramsay DL, Hurley HJ. Papulosquamous eruptions and exfoliative dermatitis. In: Moschella SL, Hurley HJ. (eds) *Dermatology*, Vol 1. 2nd edn, Philadelphia: W.B. Saunders, 1985: 529-35.

17. Handa S, Sahoo B. Childhood lichen planus: a study of 87 cases. *Int J Dermatol* 2002; 41: 423-7.
18. Sharma R, Maheshwari V. Childhood lichen planus: a report of fifty cases. *Pediatr Dermatol* 1999; 16: 345-8.
19. Nagao Y, Sata M, Tanikawa K et al. Lichen planus and hepatitis C virus in the Northern Kyushu region of Japan. *Euro J Clin Invest* 1995; 25: 910-4.
20. van der Poel CL, Reesink HWQ, Mauser-Bunschoten EP et al. Prevalence of anti-HCV antibodies confirmed by recombinant immunoblot in different population subsets in The Netherlands. *Vox Sang* 1991; 61: 30-6.
21. Bonkovsky HL, Mehta S. Hepatitis C: A review and update. *J Am Acad Dermatol* 2001; 2: 159-79.
22. Silverman S, Gorsky M, Lozada-Nur F. A prospective follow-up study of 570 patients with oral lichen planus: persistence, remission, and malignant association. *Oral Surg Oral Med Oral Pathol* 1985; 60: 30-4.
23. Rozycki TW, Rogers RS, Pittelkow MR et al. Topical tacrolimus in the treatment of symptomatic oral lichen planus: A series of 13 patients. *J Am Acad Dermatol* 2002; 46: 27-34.
24. Luker J. Diseases of the oral mucosa and tongue. In: *Textbook of Pediatric Dermatology* (Harper J, Oranje AP, Prose N). Edn 1. Vol 2. Blackwell Science Ltd, Oxford 2000: 1435-59.

CHAPTER 8

A COMPARISON OF TREATMENT OF ORAL LICHEN PLANUS WITH TOPICAL TACROLIMUS AND TRIAMCINOLONE ACETONIDE OINTMENT

R. LAEIJENDECKER, MD¹,
B. TANK, PhD²,
S.K. DEKKER, MD, PhD¹, and
H.A.M. NEUMANN, MD, PhD²

ACCEPTED IN: ACTA DERMATO-VENEREOLOGICA

Funding: none

Conflict of interest: none

Corresponding author: R. Laeijendecker, Department of Dermatology, Albert Schweitzer Hospital, P.O. Box 444, 3300 AK Dordrecht, The Netherlands.

Tel: 00 31 78 6523330. Fax: 11 31 78 6523866.

E-mail: R.Laeijendecker@asz.nl

¹ Department of Dermatology, Albert Schweitzer Hospital, Albert Schweitzerplaats 25, 3318 AT Dordrecht, The Netherlands.

² Department of Dermatology and Venereology, Erasmus MC, University Medical Center Rotterdam, Dr. Molewaterplein 40, 3015 GD Rotterdam, The Netherlands.

ABSTRACT

Background: Treatment of symptomatic oral lichen planus remains a challenging problem.

Objectives: To compare the efficacy of treatment with topical tacrolimus ointment with that of triamcinolone acetonide ointment in patients with symptomatic OLP. The periods of remission after cessation of both the treatments were also compared.

Methods: A prospective randomized study was conducted in 40 patients with the diagnosis of symptomatic OLP. In group I, 20 patients were treated with topical tacrolimus 0.1% ointment, which was applied 4 times a day onto the oral lesions. In group II, 20 patients were treated with triamcinolone acetonide 0.1% ointment in the same way. The clinical effect was graded after 6 weeks. The follow-up period was for at least 3 months.

Results: The clinical effects of treatment in group I were significantly better than in group II. In group I, 6 patients healed, 12 patients showed an improvement and 2 patients showed no improvement at all. In group II, 2 patients healed, 7 patients showed an improvement and 11 patients showed no improvement at all. The most commonly reported side effect in both groups was temporary burning or stinging at the site of application, but it did not lead to discontinuation of the treatment. Unfortunately, symptomatic oral lesions recurred within 3 to 9 weeks after the cessation of the treatment in 13 of the 18 patients who had initially shown an improvement or were healed in group I, and in 7 of the 9 patients in group II. This difference was not statistically significant.

Conclusions: Topical tacrolimus 0.1% ointment four times daily induced a better initial therapeutic response than triamcinolone acetonide 0.1% ointment in patients with symptomatic OLP. However, relapses occurred frequently within several weeks after the cessation of both the treatments. The most common side effect was a transient burning or stinging at the site of application, but did not lead to discontinuation of the treatment.

Keywords: Oral lichen planus, Tacrolimus, Triamcinolone acetonide.

Introduction

Oral lichen planus (OLP) is a common benign inflammatory disease mainly affecting the middle-aged and the elderly and has a prevalence of about 0.5 to 2%. The disease has a female-to-male ratio of about 2: 1 and may persist for many years.¹ The diagnosis of OLP is based on a combination of characteristic clinical findings, history and histopathological examination. The hyperkeratotic (white) variant of OLP is often symptomless. The atrophic or the erythematous (red) variant and the erosive or the ulcerative (yellow) variant of OLP generally have persistent symptoms.^{1,5}

Oral lichen planus (OLP) may be associated with burning pain or chronic irritation. Treatment of symptomatic OLP is challenging and several drugs have been used with varying results.^{1,3} Specific treatment includes corticosteroids (topical, intralesional, or systemic), retinoids, cyclosporin, PUVA, griseofulvin, hydroxychloroquine and dapsone.^{1,3}

Recently, topical tacrolimus was reported to be effective in the treatment of patients with OLP in a number of pilot studies.²⁻⁶ However, these studies lacked adequate control groups, and relapses of symptomatic OLP were also reported to occur frequently, generally within several weeks after the cessation of topical tacrolimus treatment.²⁻⁶

The aim of this prospective randomized study was to compare the efficacy of treatment with topical tacrolimus 0.1% ointment with that of triamcinolone acetonide 0.1% ointment in patients with symptomatic oral lichen planus. The possible side effects of the treatment in each group and the periods of remission after the cessation of therapy were also compared.

Patients and methods

A prospective randomized study was conducted between 2001 and 2004 in 40 Caucasian patients (30 women and 10 men) aged 32 to 82 years (mean 58 years), all with a histopathologically confirmed diagnosis of symptomatic OLP at the Department of Dermatology of the Albert Schweitzer Hospital, Dordrecht, The Netherlands.

Exclusion criteria were an age younger than 18 years, histopathological examination with atypical or lichenoid dysplastic features, asymptomatic oral lesions and specific treatment within 4 weeks prior to the study. The extent and the severity of OLP and the prior treatment schedules in the 40 recruited patients were comparable and showed no statistically significant difference ($P > 0.99$). All patients were treated for 6 weeks. Treatment was discontinued earlier when patients showed a complete healing. The follow-up period was for at least 3 months. Treatments were randomly allocated to patients in order of inclusion

according to a predetermined randomisation-list stratified by sex. The patients were divided into 2 groups. Each patient was provided with detailed verbal and written information on the study protocol.

In Group I, 20 patients were treated with topical tacrolimus 0.1% ointment (Protopic® 0.1%, Astellas Pharma Netherlands), which was applied 4 times a day onto the symptomatic oral lesions. In Group II, 20 patients were treated with triamcinolone acetonide 0.1% in hypromellose (= hydroxypropylmethylcellulose) 20% ointment which was also applied 4 times a day. The reasons for this administration schedule in both groups were to achieve a comparable level of patient compliance and to achieve an effective number of applications of the ointments because topical agents do not easily adhere to the moist mucous membranes.

The clinical effect of treatment in the patients was graded after 6 weeks by the treating physician using a ranked score and was recorded as worse, unchanged, improved and healed. The ranked scoring involved assessing the severity and the extent of the disease. An improvement of less than 30% in the extent and the severity of the lesion was scored as unchanged. An improvement of more than 30% in the extent and the severity of the lesions was scored as improved and as healed when the lesion had resolved completely. No blood samples were taken for determining the levels of tacrolimus and cortisol.

Statistical analysis of the results was performed by means of the exact chi-square trend test and the Fisher's exact test with a statistical significance set at $P < 0.05$.

Results

The results are shown in Table I. One patient in group I had the vulvovaginal-gingival syndrome and one patient in group II also had cutaneous LP. The two groups were similar for characteristics such as the sex, the age, the symptoms and the duration of the disease, the histopathology, the predominant form of OLP and the involved anatomical site. The initial results of the treatment in group I were better than in group II (exact chi-square trend test: $P = 0.007$). Side effects were temporary and more common in group I, but the difference was not statistically significant (Fisher's exact test: $P = 0.16$). The most frequent side effect was transient irritation including burning or stinging at the site of application lasting for about 10 to 30 minutes. It occurred primarily in patients with the erosive or ulcerative form of OLP in both groups, but it did not lead to discontinuation of the treatment in any patient. Moreover, the local irritation after treatment was significantly reduced when the oral lesions became less erosive or ulcerative. Unfortunately, oral lesions recurred within 3 to 9 weeks (mean 5 weeks) after the

Table I. Treatment with topical tacrolimus 0.1% ointment and triamcinolone acetonide 0.1% ointment in 40 patients with symptomatic OLP.

Patients	Group I (Tacrolimus)	Group II (Triamcinolone acetonide)
F/M	15/5	15/5
Age (mean)	32-82 years (57)	36-78 years (58)
Duration of OLP (mean)	0.5-7 years (3)	0.5-8 years (3.5)
Symptoms	P(16), B(10)	P(15), B(11)
Extra-oral LP	1 vulva	1 cutaneous LP
Histopathology:		
OLP	13 (65%)	12 (60%)
Compatible OLP	7 (35%)	8 (40%)
Predominant form:		
- erosive/ ulcerative	14 (70%)	15 (75%)
- atrophic/erythematous	4 (20%)	3 (15%)
- hyperkeratotic	2 (10%)	2 (10%)
Affected site of OLP	B*(16), T(8), G(10)	B*(17), T(8), G(8)
Results:		
- healing	6 (30%)	2 (10%)
- improvement	12 (60%)	7 (35%)
- no improvement	2 (10%)	11 (55%)
- worse	—	—
Side-effects	8 (40%)	3 (15%)
Follow-up	3-24 months	3-24 months
(Mean)	(15 months)	(14 months)

F = female; M = male; LP = lichen planus; B = burning; P = pain; B* = buccal mucosa; G = gingiva; T = tongue.

cessation of the treatment in 13 (72%) of the 18 patients in group I and in 7 (78%) of the 9 patients in group II, who initially showed improvement or healing.

Discussion

Tacrolimus is an immunosuppressive macrolide drug produced by *Streptomyces Tsukubaensis* and used to prevent transplant rejection.^{2,7} In vitro, tacrolimus exerts an activity that is 10 to 100 times higher than that of cyclosporin.² Topical tacrolimus (FK 506, Protopic® 0.1% or 0.03% ointment) was approved as a safe treatment for atopic dermatitis.⁴

Tacrolimus is a smaller molecule and penetrates better into the skin and the mucosa than cyclosporin.^{2,3} Generally, no systemic blood levels of tacrolimus were detected in most patients with OLP.^{2,4} However, systemic absorption of tacrolimus may occur with low, but measurable blood levels through absorption via the oral mucosa or ingestion.^{6,8} A contributing therapeutic systemic effect cannot be excluded with certainty in such cases.⁸ Side effects such as burning sensation at the site of application, transient taste disturbance, intermittent headaches, and rarely patchy hyperpigmentation of the oral mucosa as a result of topical tacrolimus treatment in OLP were reported.^{2,4,5,8,9}

Although its exact mechanism of action in OLP remains unknown, topical tacrolimus was shown to inhibit T-lymphocyte activation by inhibiting the phosphatase activity of calcineurin. Without calcineurin to dephosphorylate the nuclear factor of activated T-cells, gene transcription for lymphokines, IL-2, and gamma-IFN is inhibited leading to a decrease in the number of lymphocytes.^{3,7}

Recently, topical tacrolimus was also reported to be a safe and effective treatment in vulvar lichen planus.⁷ The results of this study allow the conclusion that treatment with topical tacrolimus 0.1% ointment 4 times daily induced a better initial therapeutic response than triamcinolone acetonide 0.1% ointment in patients with symptomatic OLP. However, relapses occurred frequently in both groups within several weeks after the cessation of both the treatments. Transient irritation at the site of application was common in both groups of patients, but did not lead to discontinuation of the treatment. It is noteworthy that in this study, tacrolimus was applied 4 times daily.⁶ This was because topical agents adhere poorly to the moist mucous membranes.¹⁰

Prolonged or intermittent use of topical tacrolimus 0.1% ointment in patients with symptomatic OLP may be useful, but remains to be clearly established in large, well-designed clinical studies. Nonetheless, at present, topical tacrolimus may be a valuable addition to the already existing therapeutic modalities for treating patients with OLP.

References

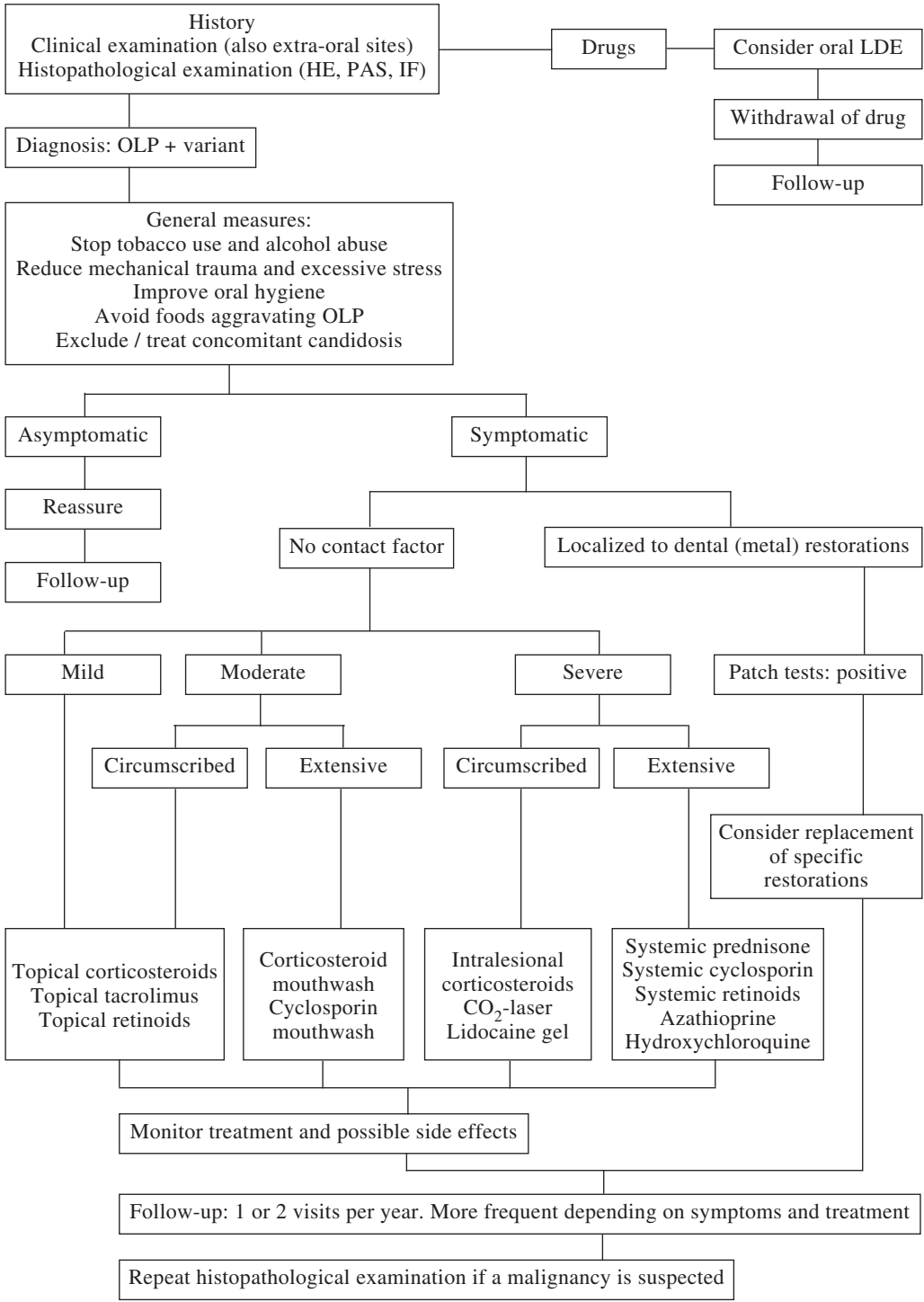
1. Setterfield JF, Black MM, Challacombe SJ. The management of oral lichen planus. *Clin Exp Dermatol* 2000; 25: 176-82.
2. Vente C, Reich K, Rupprecht R, Neumann C. Erosive mucosal lichen planus: response to topical treatment with tacrolimus. *Br J Dermatol* 1999; 140: 338-42.
3. Rozycki TW, Rogers RS, Pittelkow MR, McEvoy MT, el-Azhary RA, Bruce AJ, Fiore JP, Davis MDP. Topical tacrolimus in the treatment of symptomatic oral lichen planus: A series of 13 patients. *J Am Acad Dermatol* 2002; 46: 27-34.
4. Kaliakatsou F, Hodgson TA, Lewsey JD, Hegarty AM, Murphy AG, Porter SR. Management of recalcitrant ulcerative oral lichen planus with topical tacrolimus. *J Am Acad Dermatol* 2002; 46: 35-41.

5. Byrd JA, Davis MDP, Bruce AJ, Drage LA, Rogers RS III. Response of oral lichen planus to topical tacrolimus in 37 patients. *Arch Dermatol* 2004; 140: 1508-12.
6. Morrison L, Kratochvil III FJ, Gorman A. An open trial of topical tacrolimus for erosive oral lichen planus. *J Am Acad Dermatol* 2002; 47: 617-20.
7. Byrd JA, Davis MDP, Rogers RS. Recalcitrant symptomatic vulvar lichen planus. *Arch Dermatol* 2004; 140: 715-20.
8. Hodgson TA, Sahni N, Kaliakatsou F, Buchanan JA, Porter SR. Long-term efficacy and safety of topical tacrolimus in the management of ulcerative/erosive oral lichen planus. *Eur J Dermatol* 2003; 13: 466-70.
9. Shen JT, Pedvis-Leftick A. Mucosal staining after using topical tacrolimus to treat erosive oral lichen planus. *J Am Acad Dermatol* 2004; 50: 326.
10. Carrozzo M, Gandolfo S. The management of oral lichen planus (review). *Oral Diseases* 1999; 5: 196-205.

CHAPTER 9

CLINICAL GUIDELINES ON THE MANAGEMENT OF ORAL LICHEN PLANUS

ALGORITHM FOR THE MANAGEMENT OF ORAL LICHEN PLANUS



I History

A thorough history should be obtained from the patient. The following aspects are important.

Duration of lesions, oral symptoms, severity and duration of the symptoms, involved sites, aggravating factors, medication, extra-oral LP involvement (e.g. skin, genital region and esophagus), associated diseases, prior treatment, response to treatment, recent dental interventions, oral hygiene, mechanical traumata (lip chewing, cheek biting, friction from dental restorations, ill-fitting dentures), tobacco exposure, alcohol abuse, abnormal food pattern, stress factors and lifestyle, affected family members and patient characteristics (sex, age and origin).

II Clinical examination

Meticulous inspection of the oral cavity is necessary. The following aspects are important.

Affected oral sites, variant of OLP, candidosis, dental metal restorations, contact with dissimilar metals, relationship between dental restorations and oral lesions, dentures, other dental restoration materials, mechanical traumata including friction of sharp cusps, rough dental restorations, oral habits (lip chewing, cheek biting), poorly fitting dental prostheses, oral hygiene, extra-oral LP involvement, associated diseases, atypical oral lesions and general health of the patient. The erosive and the atrophic variants of OLP often also have minor signs of the hyperkeratotic (reticular) variant in the surrounding mucosa. This may be an additional clue in the clinical diagnosis of OLP.

III Histopathological examination

Generally, histopathological examination is necessary to establish the diagnosis of OLP. However, the histopathological features may be less distinct in OLP than in CLP.

Punch biopsies should be obtained from hyperkeratotic or erythematous lesions and from the edge of the lesions in case of erosions or ulcerations to avoid non-specific histopathological features (HE and PAS-reagent staining). In erosive, ulcerative, or bullous variants of OLP without concomitant signs of the hyperkeratotic (reticular) variant in the surrounding mucosa, a biopsy for direct immunofluorescence examination should be taken to exclude bullous autoimmune diseases and lupus erythematosus.

Direct immunofluorescence examination should also be performed in lesions confined to the gingiva for a correct diagnosis, particularly when clinically a desquamative gingivitis is present. Generally, it is much easier to biopsy non-gingival lesions. Direct immunofluorescence examination may also be valuable in distinguishing the plaque variant of OLP from leucoplakia.

In case of concomitant CLP, a 3-mm diameter biopsy of the skin can be easily obtained (HE and PAS).

No biopsy is necessary in case of the typical clinical presentation of the reticular variant of OLP with circumscribed lesions in absence of contributing external risk factors.

IV Diagnosis

The diagnosis of OLP and the specific variant of OLP should be established. However, the different variants of OLP may occur together in one patient or may transform into each other. Pay attention to the differential diagnosis of OLP, probably concomitant candidosis and extra-oral LP.

V Additional investigations

Blood examination may be necessary in case of (possibly) associated diseases or for monitoring specific treatment. Patch tests with dental metal series for contact allergy to dental metal restorations should be performed particularly if there is a close contact between the dental metal restorations and the oral lesions. Be aware of late positive patch test reactions (> 3 days), that occur frequently and can be missed easily. Patch tests with acrylic denture materials or flavorings such as vanillin, cinnamic aldehyde, fragrance mix and balsam of Peru may also be performed if aggravation of symptoms of OLP after exposure to these allergens is suspected.

Consultations with other medical specialisms may also be necessary for additional evaluation and treatment of extra-oral LP (e.g. esophageal LP).

VI General measures

The following instructions to the patients with OLP are important.

Stop tobacco use and alcohol abuse, reduce mechanical traumata (rough dental restorations, ill-fitting dentures, lip chewing and cheek biting), relieve local irritants, improve oral hygiene, reduce excessive stress, avoid possible aggravating foods such as citrus juices, tomatoes, spicy ingredients and crisp foods (corn chips and toasts).

Verbal and written general information on OLP including diagnosis, symptoms, probable aggravating factors such as specific foods, mechanical trauma, irritation or allergy to dental restorations, poor oral hygiene, treatment options, contributing risk factors, the possible risk of malignant transformation, possible extra-oral LP involvement and the schedule of follow-up should be provided to the patient.

Written information on OLP of the patient including diagnosis, symptoms, probable aggravating factors, results of further investigations, possible extra-oral LP involvement, recommendations, possible risk of malignant transformation, current treatment and the schedule of follow-up should also be provided to the dentist, the general practitioner and other possibly involved dental and medical specialists.

VII Specific treatment

Withdrawal of a specific drug should be considered if an oral LDE is suspected. In practice, it is generally very difficult to distinguish between OLP and an oral LDE. The clinical and histopathological features of oral LDE may be identical or very similar to those of “idiopathic” OLP.

Topical or systemic antifungal treatment is necessary in case of concomitant candidosis and OLP.

Partial or complete replacement of specific dental metal restorations should be performed when there is a relevant positive patch test reaction and there is close contact between the oral lesions and the dental restorations. Moreover, no concomitant CLP should generally be present in such cases.

Replacing dentures should also be considered when the oral lesions are related to poorly fitting dentures or contact allergy to acrylic materials is suspected.

Generally, no specific treatment is necessary in patients with asymptomatic OLP (particularly in the papular and in the reticular variants of OLP).

Oral lichen planus with mild symptoms may be treated with drugs such as topical corticosteroid ointments (classes II, III and IV), fluticason propionate spray, topical tacrolimus, and topical retinoids (or combinations).

Topical agents are generally applied 4 times daily for several weeks onto the lesions.

Oral lichen planus with moderate symptoms and extensive lesions may be treated with corticosteroid mouthwash (Betametasone sodium phosphate

tablets 0.5 mg dissolved in 10 ml water), cyclosporin mouthwash (5 ml of 100 mg/ml cyclosporin). Both drugs are used 3 to 4 times daily for about 5 minutes for several weeks. (Table I)

Oral lichen planus with severe symptoms and persistent, circumscribed lesions may be treated with intralesional corticosteroids (every 3 to 4 weeks, maximum 3 to 4 times), lidocaine gel (about 4 times daily) and carbon dioxide laser (1 to 2 treatments).

Oral lichen planus with severe symptoms and extensive lesions may be treated with systemic prednisone (30-80 mg once daily or in alternate-day therapy, particularly for short periods), systemic cyclosporin (doses ranging from 3-5 mg/kg/day) and systemic retinoids (acitretin 0.5 mg/day).

Systemic treatment may also be combined with topical treatment.

When there is an insufficient response to different treatments, other drugs may also be used including azathioprine, hydroxychloroquine, dapsone, oral PUVA, mycophenolate mofetil and thalidomide.

Monitoring of contra-indications, interactions or adverse effects of a specific treatment is very important.

VIII Response to treatment

When there is a complete response to treatment in patients with symptomatic OLP, the specific drug may be reduced and eventually be discontinued.

When there is only a partial response to treatment, several options are available including continuation of current therapy, lower dose of systemic drug or lower application frequency of topical drug or switching to a treatment with less potential adverse effects.

When there is no response to treatment at all, several items should be considered. These include: Is the diagnosis of OLP correct? Is there a superinfection with candida albicans? Is new histopathological investigation necessary? Is the strength or the frequency of the therapy adequate? Is the period of treatment sufficient? How is the treatment compliance? Are there any other associated disorders? Should a second or expert opinion be recommended?

IX Follow-up

Generally, the schedule of follow-up should be at least 1 or 2 visits per year as long as OLP persists. A careful history and physical examination at each visit

Table I. Summary on the management of OLP.

History	Symptoms	Drugs
Clinical examination	Oral cavity	Extra-oral manifestations
Histopathological examination	HE, PAS	IF
Diagnosis	OLP	Specific variant
General measures:		
Stop tobacco use and alcohol abuse		
Reduce mechanical trauma		
Improve oral hygiene		
Reduce excessive stress		
Avoid foods aggravating OLP		
OLP related to dental restorations	Patch testing	Replacement of specific restorations
Medication	Oral LDE	Withdrawal of specific drug
OLP	Concomitant candidosis	Antifungal treatment

Asymptomatic OLP	Symptomatic OLP			
Reassure	Mild symptoms	Moderate, extensive lesions	Circumscribed, severe lesions	Severe, extensive lesions
No treatment	Topical corticosteroids (II-IV)	Corticosteroid mouthwash	Intralesional corticosteroids	Systemic prednisone
	Topical tacrolimus	Cyclosporin mouthwash	Carbon dioxide laser	Systemic cyclosporin
	Topical retinoids		Lidocaine gel	Systemic retinoids
	Azathioprine			
	Hydroxychloroquine			
	Oral PUVA			
	Dapsone, Thalidomide, Mycophenolate mofetil			
	Intermittent antifungal treatment (?)			

Monitoring of treatment	Contra-indications	Interactions	Side effects
Follow-up	1 or 2 visits per year More frequent depending on symptoms, treatment or associated diseases		
Histopathological examination should be repeated if a malignancy is suspected			

in patients with OLP are mandatory. More frequent visits may be necessary depending on the symptomatology, the extent and the severity of OLP, the possible extra-oral involvement of LP, associated diseases, the necessity to monitor a specific treatment and the possible accompanying risk factors of an oral malignancy. It is important to give notice of significant changes in the specific variant of OLP which commonly occur in one patient during the follow-up.

Histopathological examination should be repeated if a malignancy is suspected, because an early detection of an OSCC favors the prognosis significantly. The clinical presentation of an OSCC may vary from indurated, non-healing ulcers to exophytic, hyperkeratotic masses and less frequently as red, submucosal and slightly indurated lesions with apparently intact epithelium.

The patients are strongly urged to disengage from tobacco use and alcohol abuse. Oral candidosis is a common complication of OLP, particularly when topical or systemic immunosuppressive drugs are used.

Persistent, symptomatic OLP may cause chronic discomfort, nutritional deficiencies, reduced oral hygiene, increased anxiety and stress. Moreover, it may cause difficulties with speech and overall functioning and may negatively influence the quality of life. A multi-disciplinary approach may be necessary when there is extra-oral LP involvement.

CHAPTER 10

SUMMARY, GENERAL DISCUSSION AND RECOMMENDATIONS FOR FURTHER RESEARCH

Summary and general discussion

In **chapter 1**, a general introduction on oral lichen planus (OLP), the aim of the thesis, and a short treatise on the history of medicine, dermatology and lichen planus (LP) are described. Moreover, several aspects of the oral cavity including the histology of the oral mucosa, the immunity of the oral cavity and the dentition are described.

Erasmus Wilson (1809-1884) initially coined the term lichen planus (LP) in 1869. In a study of 50 patients with LP, three patients also had involvement of the oral mucosa. Wilson considered it to be the same disease as “leichen ruber” described by F. (von) Hebra in 1860. L.F. Wickham noted the punctations and striae atop the lesions of LP that currently bear his name in 1895. W. Dubreuilh defined the histopathological characteristics of OLP in 1906. H. Hallopeau reported a case of OLP with malignant degeneration in 1910. H. Gougerot and A. Civatte described the presence of colloid or cytooid bodies (Civatte’s bodies) in the microscopical examination of LP in 1953.

A review of the literature on OLP is given in **chapter 2**.

The clinical spectrum of LP may involve the skin, the mucous membranes, the hair and the nails. Oral lichen planus may affect up about 0.5 to 2% of the population. Generally, it is a disease of the middle-aged and the elderly with females being affected more than men. Oral lichen planus can be categorized into different subtypes namely reticular, papular, plaque, erosive, ulcerative or bullous, and atrophic or erythematous. The atrophic, erosive or ulcerative variants generally have persistent symptoms including pain or stinging, which may be extremely distressing and even disabling. The lesions are often found (symmetrical) on the buccal mucosa, the lateral margins of the tongue and the gingiva. Approximately 15 to 35% of the patients with OLP have concomitant cutaneous lichen planus (CLP). Oral lichen planus has been reported to be associated with a variety of disorders and particularly with disorders involving altered or disturbed immunity. However, it may be difficult to determine whether there is a causal or a purely fortuitous association.

Generally, the diagnosis of OLP is based on a combination of characteristic clinical findings, history and histopathological examination. The exact cause of OLP is unknown, but an immune-mediated (T-cell dependant) pathogenesis has been proposed. Oral lichen planus may be aggravated by stress, mechanical traumata, specific foods (crisp foods, citrus juices and spicy ingredients), poor oral hygiene, irritation or allergy to dental (metal) restorations.

Many drugs may be involved in an oral lichenoid drug eruption (oral LDE), which shows features identical or very similar to those of OLP.

Histologically, the principal features of OLP are a dense band-like inflammatory infiltrate in the lamina propria that mainly consists of T-cells and a liquefaction degeneration of the basal epithelial cells.

Oral lichen planus is usually a persistent disorder, despite different kinds of treatment. Asymptomatic reticular (often symmetrical) buccal lesions of OLP do not need treatment in contrast with symptomatic variants of OLP.

Topical treatment may include corticosteroids, antifungals, retinoids, tacrolimus and cyclosporin. Persistent circumscribed lesions may also be treated with analgesics, intralesional corticosteroids, carbon dioxide laser or local PUVA. In severe symptomatic OLP with extensive lesions, systemic therapy with corticosteroids, retinoids, cyclosporin, hydroxychloroquine and azathioprine may be necessary. Combinations of therapeutic agents are also possible.

Generally, OLP follows a chronic course, with periods of quiescence and flare ups.

Oral candidosis is a common complication of OLP, particularly when topical or systemic immunosuppressive therapeutic agents are used. The possible malignant transformation of OLP into an oral squamous cell carcinoma (OSCC) still remains controversial.

Generally, the schedule of follow-up of patients with OLP should be at least one or two visits per year as long as OLP persists. A careful physical examination at each visit is imperative and histopathological examination should be repeated if a malignancy is suspected.

Other variants of LP such as the vulvovaginal-gingival syndrome (VVGs), genital LP, LP of the lips and LP of the esophagus were also reported. Moreover, the clinical aspects of CLP with different variants were described.

The classical form of CLP comprises pruritic, faintly erythematous to violaceous, flat-topped papules which are usually symmetrically distributed with fine white lines (Wickham's striae) on the surface of the lesions. The lesions have a predilection for the flexor parts of the wrists and the forearms, the ankles, the lumbar area, the (male) genitals and the shins.

Overlap-syndromes including lichen planus-lupus erythematosus (LP-LE) overlap-syndrome and LP pemphigoides were reported. Lichenoid reactions such as graft-versus-host disease (GVHD), lichenoid contact dermatitis, oral and cutaneous lichenoid drug eruptions (LDEs) were also described.

In **chapter 3**, a prospective non-randomized study in 80 patients with one or more silver amalgam fillings is described. Sixty patients had OLP and were categorized into 3 groups based on the topographic relationship between the oral lesions and the amalgam fillings. In group A (20 patients), the oral lesions were confined to areas in close contact with amalgam fillings. In group B (20 patients), the lesions extended 1 cm beyond the area of contact with amalgam fillings. In group C (20 patients), the oral lesions had no topographic relationship with amalgam fillings. Control group D (20 patients) had an allergic contact dermatitis without any pathologic evidence of OLP. Patch tests were performed with a standard and a dental metal series in all patients. Partial or complete replacement of amalgam fillings was recommended in case of

a positive patch test reaction to ammoniated mercury, metallic mercury, or amalgam.

In group A, 13 patients had positive patch test reactions to one or more mercury compounds. Partial or complete replacement of dental amalgam resulted in at least a significant improvement in these 13 patients. In group B, 8 patients had positive patch test reactions to one or more mercury compounds. Partial or complete replacement resulted in at least a significant improvement in these 8 patients. In group C, 2 patients had positive patch test reactions to one or more mercury compounds. Replacement of dental amalgam fillings in these 2 patients resulted in improvement in 1 patient.

In 8 (35%) of these 23 patients, positive patch test reactions to ammoniated mercury, metallic mercury, or amalgam occurred after the regular 3-day evaluation with a variation of 5 to 18 days (mean 8 days). The effect of replacements of amalgam was generally observed after 1 to 4 months (mean 3 months). No positive patch test reactions to mercury compounds were observed in patients with OLP and concomitant CLP.

It was concluded that contact allergy to mercury compounds is important in the pathogenesis of OLP, especially if there is a close contact between the oral lesions and the dental amalgam fillings and if no concomitant CLP is present. In case of a positive patch test reaction to ammoniated mercury, metallic mercury, or amalgam, partial or complete replacement of amalgam fillings will lead to a significant improvement in nearly all patients with OLP.

In **chapter 4**, a retrospective non-randomized study on oral manifestations of gold allergy and an update on gold allergy are presented. Generally, gold allergy is more common than was previously recognized. In the literature, gold sodium thiosulfate (0.5% in pet), also known as sodium thiosulfatoaurate, is regarded as the most reliable reagent for patch testing in suspected cases of gold allergy. However, Fisher regarded gold(tri)chloride as a reliable test allergen. Positive reactions to gold may appear after the regular 3-day evaluation and may be long-lasting.

Two hundred patients with symptoms of persistent oral mucosal or cutaneous lesions that were possibly related to allergy to constituents of dental gold alloys or gold jewelry were patch tested to determine the frequency of sensitization. In 17 (8.5%) patients, all women, with a mean age of 50 years, positive patch test reactions to gold(tri)chloride 0.5% aq and 1.0% aq were observed. Positive reactions to sodium tetrachloroaurate and potassium dicyanoaurate were not observed. In 5 of the 7 patients with OLP and in 1 of the 6 patients with the burning mouth syndrome, dental gold restorations were replaced. Particularly in patients with OLP, a significant but variable improvement was observed. In all cases in which gold was replaced and improvement occurred, the patients were sensitized to gold(tri)chloride 0.5% aq. One patient with allergic contact stomatitis and 1 patient with allergic contact dermatitis healed completely after

gold had been replaced. No replacement of gold was recommended in a patient with relapsing angioedema and in another patient with chronic urticaria. In all, except one case, the patch test reactions were persistently positive varying from one to several weeks (mean 4 weeks). In 3 patients, only late positive reactions occurred and were observed after respectively 5, 6 and 14 days. In another patient, a reaction to gold(tri)chloride 1% aq characterized by infiltration and purpura, developed after 1 month.

It was concluded that sensitization to gold should be considered as a possible cause of allergic contact dermatitis, allergic contact stomatitis and as a pathogenic or triggering factor in OLP.

A historical cohort study in 200 Caucasian patients with a confirmed diagnosis of OLP is described in **chapter 5**.

The study was conducted to examine oral malignancies associated with OLP and to investigate whether OLP has an intrinsic malignant potential or whether there are also contributing external risk factors.

In the literature, the possible malignant transformation of OLP still remains controversial. The transformation of OLP into an oral malignancy ranges from 0 to 10%. Tobacco exposure, alcohol abuse, poor nutrition, leucoplakia and erythroplakia are known risk factors for oral cancer.

The follow-up in the study included at least one or two visits per year and ranged from 7 to 13 years (mean 10 years). Histopathological examination was repeated if a malignancy was suspected. Three (1.5%) of the 200 patients developed an oral squamous cell carcinoma (OSCC) after a period of 3 to 6 years (mean 4 years) following the initial diagnosis of OLP. Possible contributing external risk factors were also noted in two of these three patients. One male patient (59 years) with hyperkeratotic OLP (plaque and reticular lesions) had smoked approximately 25 cigarettes a day during 20 years. One female patient (67 years) with erosive OLP had received systemic immunosuppressive treatment for 2 years for OLP. There were no contributing external risk factors in another female patient (78 years) with the atrophic variant of OLP and an OSCC. The probability of at least one case of OSCC in our study according to the Poisson distribution could have been by chance alone. However, it is highly improbable (statistically significant) that at least 2 or 3 cases of oral malignancy in our study were encountered by chance alone.

The investigations provided some, but not convincing support for the notion that OLP is a premalignant condition. However, the exact incidence of malignant transformation is difficult to establish, because of the low number of patients and the possible contribution of external risk factors, which may also be relevant in oral malignancy.

In **chapter 6**, a prospective study in 100 patients with OLP and a control group of 100 patients with psoriasis vulgaris is described. The study was conducted

to determine the possible relationship between OLP and hepatitis C virus infection in The Netherlands and to investigate whether routine screening for anti-hepatitis C virus antibodies and liver enzymes is necessary in these patients.

In both groups, there was no serological evidence of antibodies against hepatitis C virus (HCV) at all. In each group, there were 2 patients with elevated liver enzyme levels, but the difference was not statistically significant.

A definite conclusion could not be established in three of these patients. One male patient with psoriasis vulgaris was an alcohol abuser which could explain the abnormal liver enzyme values. In these 4 patients, there was also no evidence of either hepatitis A virus infection or hepatitis B virus infection.

In the literature, the results of the possible relationship between OLP and HCV infection are rather discrepant and controversial. In parts of the world for example Brazil, Japan and Spain with a high prevalence of HCV infection a positive relationship has been reported. No correlation between OLP and HCV infection was found in the United Kingdom and Scandinavia where the prevalence of HCV infection is low. However, conflicting results have been reported from Germany.

The results of our study suggested that there is no indication for routinely screening for anti-hepatitis C virus antibodies in patients with OLP in The Netherlands. Liver enzyme values should only be determined if warranted. The discrepancies in the literature on the possible association of OLP and hepatitis C virus are largely based on the differences in prevalence of both hepatitis C virus infection and possibly also of OLP world-wide with a population of different genetic make-up, different environmental conditions and possible variations in hepatitis C virus infection and host immune responses.

In **chapter 7**, individual cases of OLP in childhood from our practice together with a review of the literature on this subject are reported. A retrospective non-randomized study was conducted during a period of 10 years.

Approximately 10,000 dermatological patients younger than 18 years visited our department. Only three (0.03%) patients with OLP in childhood were encountered.

An Asian girl aged 11 years had an asymptomatic reticular variant of OLP, which resolved without any treatment after one year. An Asian boy aged 16 years had an erosive variant of OLP with severe pain, which healed after intensive topical and systemic treatment for two years. A Caucasian girl aged 14 years had a reticular variant of OLP with a little soreness, which resolved after topical treatment for three months.

Literature on OLP in childhood is scarce and there are only a few reports on this subject. Generally, the oral mucosa seems to be less commonly involved in children than in adults with LP. The large differences in the prevalence of OLP in childhood versus OLP in adulthood can only be explained partially by a low number of associated systemic diseases, auto-immune phenomena,

infections, drugs and dental restorations in childhood, which may reduce the risk for developing OLP. Moreover, the diagnosis may be missed because of irregular dental check ups, lack of symptoms and ignorance. In the literature, the prevalence of OLP in childhood seems to be significantly higher in those of the Asian race. It is highly unlikely (statistically significant) according to the Poisson distribution that 2 Asian patients in our study were encountered by chance alone. This indicates that a specific genetic predisposition (HLA-dependant) in the Asian race, despite a negative family history, may possibly be important in the pathogenesis of OLP in childhood.

It was concluded that oral lichen planus in childhood is rare. Therefore, at present it is not possible to draw firm conclusions on this subject. Oral lichen planus in childhood seems to occur preferentially in those of the Asian race. The clinical features resemble those of oral lichen planus in adulthood. However, the prognosis of oral lichen planus in childhood generally seems to be more favorable than oral lichen planus in adulthood.

In **chapter 8**, a prospective randomized study in 40 patients with a confirmed diagnosis of symptomatic OLP is described. The aim of the study was to compare the treatment of OLP with topical tacrolimus ointment and triamcinolone acetonide ointment. The periods of remission after cessation of both the treatments were also compared. Twenty patients (group I) were treated with topical tacrolimus 0.1% ointment and 20 patients (group II) were treated with triamcinolone acetonide 0.1% ointment. The ointments were applied 4 times per day onto the symptomatic oral lesions for a period of 6 weeks. In group I, 6 (30%) patients healed, 12 (60%) patients showed an improvement and 2 (10%) patients showed no improvement at all. In group II, 2 (10%) patients healed, 7 (35%) patients showed an improvement and 11 (55%) patients showed no improvement at all. The results of the treatment in group I were statistically significant better than in group II.

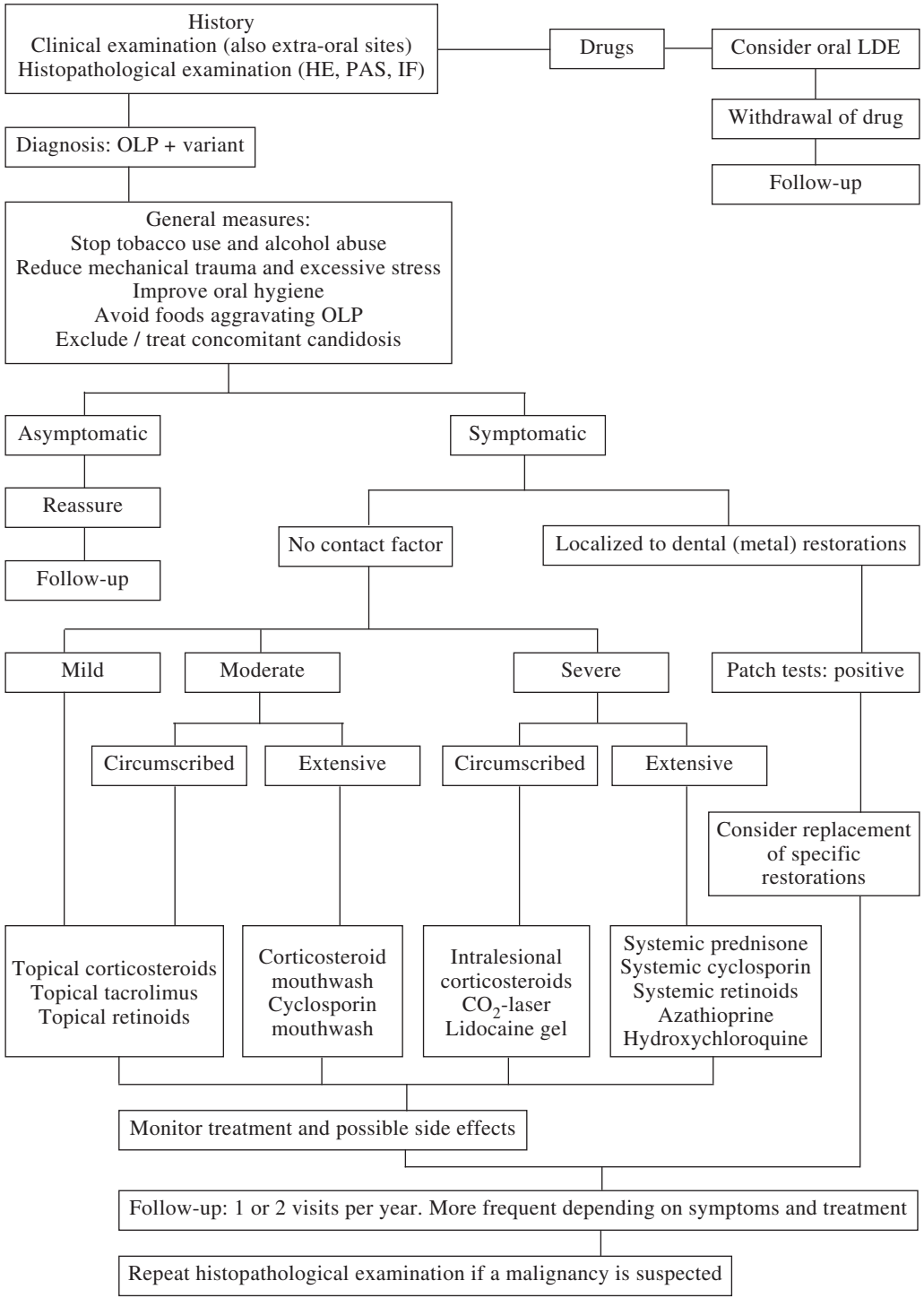
Side effects of treatment were temporary and occurred in 8 (40%) patients of group I and in 3 (15%) patients of group II. However, the differences in the side effects were not statistically significant. Local irritation (burning and stinging) at the site of application persisting for about 10 to 30 minutes was the most commonly reported side effect. This side effect particularly occurred in patients with the erosive or ulcerative variants of OLP in both groups, but did not lead to discontinuation of the treatment. Unfortunately, oral lesions recurred within 3 to 9 weeks (mean 5 weeks) after the cessation of treatment in 13 (72%) of the 18 patients in group I and in 7 (78%) of the 9 patients in group II, who initially showed improvement or healing.

It was concluded that treatment with topical tacrolimus 0.1% ointment showed a better initial therapeutic response than treatment with triamcinolone acetonide 0.1% ointment in patients with symptomatic OLP. The most common side effect was a transient burning or stinging at the site of application, but did

not lead to discontinuation of the treatment. Unfortunately, relapses occurred within several weeks after the cessation of the treatment in both groups.

In **chapter 9**, clinical guidelines on the management of OLP are described. Several important aspects such as history, clinical examination, histopathological examination, diagnosis, additional investigations, general measures, specific treatment, response to treatment and follow-up are described.

ALGORITHM FOR THE MANAGEMENT OF ORAL LICHEN PLANUS



Recommendations for further research

Well-designed studies in patients with OLP and control groups should be undertaken to elucidate the exact cause of OLP. Contact allergies to other allergens may possibly be relevant in the pathogenesis of OLP. In the literature, there is insufficient consensus on the time of occlusion of patch tests, particularly for metal allergens.

Moreover, the optimum reading times of patch tests for these allergens showed significant differences and there is also a significant variation in the allergens and the concentrations that were used in studies in the literature.

Therefore, those studies are difficult to compare and the relevant positive patch test reactions may have been missed.

Histopathological features in OLP should be described more accurately to reduce intra- and interobserver variation. New immunopathological techniques may be useful for a more accurate diagnosis of OLP.

Large studies are necessary to investigate the possible associations between other diseases with altered or disturbed immunity and OLP. At the moment, it may be difficult to determine whether there is a causal or a purely fortuitous association with other diseases. Furthermore, it may be impossible to distinguish between an oral LDE and OLP on the currently available clinical, histopathological and immunological grounds.

Many of the current treatments of OLP are empirical, based on anecdotal reports or open clinical trials without adequate control groups. Results of different studies cannot be compared because of the heterogeneity of the publications, the exact definition of OLP, the design of the studies, associated disorders, the therapeutic response and the follow-up. Randomized controlled clinical trials in larger populations are necessary to determine adequate treatment regimes for patients with OLP.

The possible malignant transformation of OLP is a very important issue and, although there are many articles on this subject including our study, it still remains highly controversial. Large cohort studies in patients with a confirmed diagnosis of OLP with a long-term follow-up including identification of intrinsic and contributing external risk factors are necessary.

In many studies on OLP, insufficient attention has possibly been paid to the occurrence of extra-oral manifestations of LP, which may lead to inadequate diagnosis and treatment in some patients with LP.

CHAPTER 11

SAMENVATTING, ALGEMENE DISCUSSIE EN AANBEVELINGEN VOOR VERDER ONDERZOEK

Samenvatting en algemene discussie

In **hoofdstuk 1** worden een algemene inleiding over orale lichen planus (OLP), de doelstellingen van dit proefschrift en een korte verhandeling over de geschiedenis van de geneeskunde, dermatologie en lichen planus (LP) beschreven.

Erasmus Wilson (1809-1884) introduceerde de term “lichen planus” in 1869. In een studie met 50 patiënten met LP hadden 3 patiënten naast huidafwijkingen ook afwijkingen van het mondslijmvlies passend bij OLP. Wilson dacht dat LP dezelfde ziekte was als “leichen ruber” beschreven door F. (von) Hebra in 1860. L.F. Wickham beschreef in 1895 de witte punten en strepen op de afwijkingen, die ook tegenwoordig nog Wickhamse striae worden genoemd. W. Dubreuilh definieerde de histopathologische kenmerken van OLP in 1906. H. Hallopeau rapporteerde in 1910 een casus van OLP met maligne ontaarding. H. Gougerot en A. Civatte beschreven in 1953 de aanwezigheid van colloïd- of cytoïdlichaampjes (Civatte’s bodies) in microscopische preparaten van LP.

In **hoofdstuk 2** wordt een overzicht van de literatuur over OLP gegeven. Het klinische spectrum van LP kan de huid, de aangrenzende slijmvliesen, het haar en de nagels omvatten.

De prevalentie van OLP varieert van ongeveer 0,5 tot 2% in de algehele bevolking. In het algemeen is het een aandoening die vaker gezien wordt bij vrouwen dan bij mannen en meestal bij mensen van middelbare of oudere leeftijd. Er bestaan verschillende klinische varianten van OLP zoals de reticulaire en papuleuze vorm en de vorm met plaques. Deze varianten geven meestal weinig of geen klachten. Daarnaast bestaan er de erosieve, de ulceratieve of bulleuze en de erythemateuze of atrofische varianten van OLP, die veelal hardnekkige symptomen van pijn of branderigheid in de mondholte geven, hetgeen erg belastend en zelfs invaliderend voor de patiënt kan zijn. De afwijkingen bij OLP zijn vaak (symmetrisch) gelokaliseerd op de binnenzijden van het wang-slijmvlies, de zijkanten van de tong en op het tandvlees. Ongeveer 15 tot 35% van de patiënten met OLP hebben ook afwijkingen op de huid, passend bij LP. Er zijn associaties beschreven tussen OLP en diverse andere ziekten met name aandoeningen die zijn gekenmerkt door een gewijzigde of verstoorde immuniteit. Het is echter vaak moeilijk te bepalen of er een oorzakelijk verband bestaat of dat er sprake is van een toevallige samenhang.

De diagnose “OLP” wordt in het algemeen gesteld op grond van anamnese, lichamelijk onderzoek en histopathologisch onderzoek. De exacte oorzaak van OLP is niet bekend, maar er wordt een immuungemedieerde (T-cel afhankelijke) pathogenese verondersteld. Orale lichen planus kan worden verergerd door diverse factoren zoals stress, specifieke voedingsbestanddelen (b.v. sappen van citrusvruchten, kruidige ingrediënten en knapperig voedsel), mechani-

sche traumata, slechte mondhygiëne en door irritatie of allergie voor (metalen) tandheelkundige materialen.

Vele soorten geneesmiddelen kunnen betrokken zijn bij een orale lichenoid geneesmiddeleruptie. Hierbij worden afwijkingen gezien die niet of nauwelijks te onderscheiden zijn van OLP.

De essentiële kenmerken van OLP bij histopathologisch onderzoek zijn een dicht bandvormig ontstekingsinfiltraat in de lamina propria voornamelijk bestaand uit T-lymfocyten en een liquefactiedegeneratie van de basale epitheliale cellen.

Orale lichen planus is gewoonlijk een gedurende vele jaren bestaande aandoening ondanks diverse vormen van behandeling. De reticulair variant van OLP met asymptomatische afwijkingen, symmetrisch op de wangslimvliezen, behoeft geen behandeling in tegenstelling tot de diverse andere, veelal symptomatische vormen van OLP.

Lokale behandeling kan bestaan uit corticosteroïden, fungistatische of fungicide middelen, vitamine-A-zuren, tacrolimus en ciclosporine. Persisterende, omschreven letsels kunnen ook worden behandeld met analgetica, intralesionale corticosteroïden, CO₂-laser of locale PUVA. Systemische therapie met corticosteroïden, retinoïden, ciclosporine, hydroxychloroquine of azathioprine kan noodzakelijk zijn bij uitgebreide, ernstige symptomatische vormen van OLP. Combinaties van diverse middelen bij de behandeling van OLP zijn ook mogelijk. Orale lichen planus vertoont meestal een chronisch verloop met remissies en exacerbaties.

Orale candidiasis is een frequent voorkomende complicatie in OLP, met name wanneer er behandeling plaatsvindt met lokale of systemische immunosuppressieve middelen. De mogelijke maligne ontaarding van OLP in een plaveiselcelcarcinoom blijft helaas nog steeds een controversieel onderwerp.

Patiënten met OLP dienen in het algemeen een of twee keer per jaar gecontroleerd te worden zolang er afwijkingen bestaan. Nauwkeurige inspectie van de mondholte is noodzakelijk bij iedere controle.

Histopathologisch onderzoek dient te worden herhaald wanneer er een klinische verdenking op maligniteit bestaat.

Andere varianten van LP zoals het vulvovaginaal-gingivaal syndroom (VVGGS), genitale LP, LP van de lippen en LP van de oesophagus worden ook besproken. Daarnaast worden de klinische aspecten van cutane LP (CLP) met de verschillende varianten beschreven.

De klassieke vorm van CLP wordt gekenmerkt door jeukende, erythemateuze of livide, vlakke papels die meestal symmetrisch zijn gerangschikt met op de oppervlakte fijne witte lijntjes vaak als netwerk aanwezig (Wickhamse striae). De voorkeurslokalisaties zijn de buigzijden van de polsen en onderarmen, de enkels, de onderrug, de (mannelijke) genitaliën en de scheenbenen.

Mengbeelden zoals het lichen planus-lupus erythematosus (LP-LE) overlapsyndroom en LP pemphigoides worden beschreven. Lichenoid reacties

ties zoals “graft-versus-host ziekte” (GVHD), lichenoid contactdermatitis, orale en cutane lichenoid geneesmiddelreacties worden eveneens beschreven.

In **hoofdstuk 3** wordt een prospectieve, onwillekeurig verdeelde studie met 80 patiënten met een of meer amalgaamvullingen beschreven. Zestig patiënten met OLP werden verdeeld in 3 groepen met een gelijk aantal patiënten, gebaseerd op de relatie van de slijmvliesafwijkingen en de amalgaamvullingen. Groep A met 20 patiënten had mondafwijkingen beperkt tot gebieden in direct contact met het amalgaam. Groep B met 20 patiënten vertoonde afwijkingen ook buiten een gebied van een centimeter van de amalgaamvullingen. In groep C met eveneens 20 patiënten hadden de mondafwijkingen geen directe topografische relatie met de amalgaamvullingen.

Twintig patiënten in groep D (controlegroep) vertoonden het beeld van een allergisch contacteczeem zonder enige aanwijzing voor OLP. Epicutane tests werden bij alle 80 patiënten uitgevoerd met een standaardreeks en een tandheelkundige metalenreeks. Bij een positieve uitslag bij plakproeven voor geammonieerd kwik, elementair kwik of amalgaam werd geadviseerd om de amalgaamvullingen gedeeltelijk of geheel te vervangen.

In groep A vertoonden 13 (65%) patiënten een of meer positieve reacties op de bovengenoemde kwikbestanddelen. Partiële of complete vervanging van de amalgaamvullingen bij deze 13 patiënten leidde tenminste tot een significante verbetering van de afwijkingen van OLP. In groep B vertoonden 8 (40%) patiënten een of meer positieve reacties op de kwikbestanddelen. Gedeeltelijke of gehele vervanging van het amalgaam bij deze 8 patiënten leidde tenminste tot een significante verbetering van de mondafwijkingen. In groep C hadden 2 (10%) patiënten een of meer positieve reacties op de kwikbestanddelen. Vervanging van de amalgaamvullingen leidde slechts bij 1 patiënt tot verbetering.

In 8 (35%) van de 23 patiënten werden positieve uitslagen voor geammonieerd kwik, elementair kwik of amalgaam bij epicutane tests pas gezien na het reguliere aflezen op de derde dag, variërend van 5 tot 18 dagen (gemiddeld 8 dagen). Het positieve resultaat van het vervangen van amalgaamvullingen werd meestal gezien na 1 tot 4 maanden (gemiddeld 3 maanden). Positieve uitslagen bij plakproeven voor kwikbestanddelen werden niet gezien bij patiënten met OLP die ook CLP hadden.

Conclusies: een contactallergie voor kwikbestanddelen kan van belang zijn in de pathogenese van OLP, met name wanneer er een nauw contact bestaat tussen de mondafwijkingen en de amalgaamvullingen en er geen bijkomende CLP bestaat. Wanneer er een positieve uitslag voor geammonieerd kwik, elementair kwik of amalgaam bestaat bij epicutane tests, zal gedeeltelijke of gehele vervanging van de amalgaamvullingen leiden tot een significante verbetering bij nagenoeg alle patiënten met OLP.

In **hoofdstuk 4** wordt er een recent overzicht gegeven over allergie voor goud en wordt er een studie overwegend over mondafwijkingen in relatie tot allergie voor goud beschreven.

Goudallergie blijkt in het algemeen veel meer voor te komen dan men voorheen dacht. In de literatuur wordt goudnatriumthiosulfaat (0,5% in vaseline), ook bekend onder de naam natriumthiosulfatoauraat, beschouwd als het meest betrouwbare allergeen bij epicutane tests om een goudallergie aan te tonen. Het meest betrouwbare allergeen volgens Fisher was echter goud(tri)chloride. Positieve reacties bij plakproeven op goud kunnen op een later tijdstip dan het reguliere aflezen op de derde dag voorkomen en kunnen langer blijven bestaan.

In een retrospectieve, onwillekeurig verdeelde studie werden 200 patiënten met persisterende afwijkingen van de mondholte of van de huid, mogelijk gerelateerd aan een allergie voor tandheelkundige gouden materialen of voor gouden sieraden, onderzocht met epicutane tests om de frequentie van sensibilisatie vast te stellen.

Bij 17 vrouwelijke patiënten (8.5%) met een gemiddelde leeftijd van 50 jaar werden positieve uitslagen gevonden voor goud(tri)chloride 0,5% en 1% in water. Positieve uitslagen voor natriumtetrachloroauraat en kaliumdicyanoauraat werden niet gezien. Tandheelkundig goud in de mond (met name gouden kronen) werd bij 5 van de 7 patiënten met OLP en bij 1 van de 6 patiënten met het zogenoemde “brandend mondsyndroom” (BMS) vervangen. In het bijzonder bij patiënten met OLP werd een significante maar wisselende verbetering geconstateerd. Alle patiënten bij wie het goud werd vervangen en een verbetering werd gezien, vertoonden positieve uitslagen voor goud(tri)chloride 0,5% en 1% in water. Een patiënt met een allergische contactstomatitis en een patiënt met allergisch contacteczeem vertoonden een volledige genezing na het vermijden van het directe contact met goud. Verwijdering van goud was niet noodzakelijk en werd dan ook niet geadviseerd aan een patiënt met recidiverend angio-oedeem en aan een patiënt met chronische urticaria.

Positieve uitslagen voor goud(tri)chloride bij plakproeven waren persisterend positief bij 16 patiënten, variërend van een tot verscheidene weken (gemiddeld 4 weken). Bij 3 patiënten werden slechts laat positieve uitslagen voor goud gezien na respectievelijk 5, 6 en 14 dagen. Bij een andere patiënt werd pas na een maand een reactie op goud(tri)chloride 1% in water gezien, gekenmerkt door infiltratie en purpura.

Conclusie: sensibilisatie voor goud kan als mogelijke oorzaak worden beschouwd bij patiënten met allergisch contacteczeem en allergische contactstomatitis en als een pathogenetische of verergerende factor in OLP.

In **hoofdstuk 5** wordt een historische cohortstudie beschreven met 200 patiënten met OLP. Hierbij werd onderzocht of orale maligniteiten geassocieerd kunnen zijn met OLP en of er een intrinsiek maligne potentieel van OLP bestaat

of dat er andere, bijkomende externe factoren ook verantwoordelijk kunnen zijn.

De mogelijke maligne ontaarding van OLP blijft nog steeds een controversieel onderwerp. De percentages in de literatuur die worden opgegeven voor maligne ontaarding van OLP in een plaveiselcelcarcinoom variëren van 0 tot 10%. Bekende risicofactoren voor orale maligniteiten zijn roken, alcoholmisbruik, ondervoeding, leukoplakie en erythroplakie.

De periode van het vervolgen van de patiënten varieerde van 7 tot 13 jaar (gemiddeld 10 jaar). Histopathologisch onderzoek werd herhaald indien er op klinische gronden een maligniteit werd vermoed. Drie (1,5%) patiënten ontwikkelden een plaveiselcelcarcinoom in de mondholte op de aanvankelijke plaats van OLP na een periode van 3 tot 6 jaar (gemiddeld 4 jaar). Twee patiënten hadden aantoonbare externe risicofactoren. Een patiënt (59 jaar) met de hyperkeratotische vorm (met plaques en reticulaire afwijkingen) van OLP rookte ongeveer 25 sigaretten per dag gedurende 20 jaar. Een patiënte (67 jaar) met de erosieve vorm van OLP had gedurende 2 jaar een systemische immunosuppressieve behandeling voor OLP gehad. Bij een andere patiënte (78 jaar) met de atrofische vorm van OLP konden geen extrinsieke risicofactoren worden vastgesteld.

De kans dat er tenminste 1 patiënt met een plaveiselcelcarcinoom van de mondholte in deze studie aanwezig is, zou op grond van de Poisson-verdeling door het toeval kunnen komen. Het is echter heel onwaarschijnlijk (statistisch significant), dat er tenminste 2 of 3 patiënten in de studie zouden voorkomen op grond van het toeval.

Conclusies: de resultaten van deze studie geven enig, maar geen overtuigend bewijs voor het feit dat OLP een premaligne aandoening is. Het exacte percentage van eventuele maligne ontaarding van OLP is moeilijk vast te stellen, enerzijds omdat er relatief weinig patiënten aanwezig zijn en anderzijds omdat de mogelijke rol van externe risicofactoren voor orale maligniteiten lastig te bepalen is.

In **hoofdstuk 6** wordt een prospectieve studie beschreven met een groep van 100 patiënten met OLP en een controlegroep van 100 patiënten met psoriasis vulgaris. De doelstellingen waren om de mogelijke relatie in Nederland vast te stellen tussen OLP en hepatitis-C-virusinfectie en om te kijken of routinematig onderzoek op hepatitis-C-antilichamen en leverenzymen noodzakelijk is.

In beide groepen werden in het serum in het geheel geen antilichamen tegen het hepatitis-C-virus aangetroffen.

In elk van beide groepen werden 2 patiënten gezien met enkele verhoogde leverenzymwaarden, hetgeen niet statistisch significant verschillend is. Een passende verklaring voor de bovengenoemde afwijkingen kon bij 3 patiënten niet worden gegeven. Een patiënt met psoriasis vulgaris gebruikte overmatig veel alcohol, hetgeen de afwijkingen kon verklaren. Bij deze 4 patiënten werden ook geen aanwijzingen gezien voor hepatitis-A- of hepatitis-B-virusinfecties.

In de literatuur wordt de mogelijke relatie tussen OLP en hepatitis-C-virusinfectie nogal verschillend en tegenstrijdig opgegeven. In bepaalde delen van de wereld met een hoge prevalentie van hepatitis-C-virusinfecties, zoals bijvoorbeeld Brazilië, Japan en Spanje, wordt een positief verband beschreven.

Geen positief verband tussen OLP en hepatitis-C-virusinfectie wordt vermeld in gebieden met een lage prevalentie van hepatitis-C-virusinfecties zoals bijvoorbeeld het Verenigd Koninkrijk en Scandinavië.

In Duitsland zijn er tegenstrijdige berichten over dit onderwerp beschreven.

Conclusies: onze studie suggereert dat er geen indicatie is voor routinematig onderzoek op antilichamen tegen hepatitis-C-virus bij patiënten met OLP in Nederland. Leverenzymwaarden dienen alleen te worden bepaald in specifieke, klinisch relevante situaties. De discrepantie in de literatuur omtrent het mogelijke verband tussen OLP en hepatitis-C-virusinfectie zijn grotendeels te verklaren op grond van substantiële verschillen in prevalentie van zowel hepatitis-C-virusinfecties en mogelijk ook van OLP in de wereld. Bovendien spelen een verschillende genetische achtergrond van de diverse volkeren, uiteenlopende omgevingsfactoren en mogelijke verschillen in hepatitis-C-virusinfecties zelf en in de immuunrespons van de gastheer een rol.

In **hoofdstuk 7** worden de individuele gevallen van OLP op kinderleeftijd en een beschouwing van de literatuur over dit onderwerp beschreven. Een retrospectieve studie werd verricht over een periode van 10 jaar. Ongeveer 10.000 patiënten jonger dan 18 jaar werden gezien op onze polikliniek dermatologie. In die tijd kon slechts bij 3 patiënten OLP op kinderleeftijd worden vastgesteld. Een 11-jarig Aziatisch meisje had de asymptomatische, reticulaire variant van OLP. De afwijkingen verdwenen zonder behandeling na 1 jaar.

Een 16-jarige Aziatische jongen had de erosieve vorm van OLP met veel pijnklachten. Na intensieve lokale en systemische behandeling trad er in 2 jaar tijd een volledige genezing op. Een 14-jarig meisje van Nederlandse afkomst vertoonde de reticulaire variant van OLP met geringe pijnklachten. De afwijkingen verdwenen met lokale behandeling na 3 maanden.

Ook in de literatuur is OLP op kinderleeftijd zeldzaam en er zijn dan ook maar enkele artikelen over dit onderwerp geschreven. Het mondslijmvlies is bij kinderen met LP in het algemeen ook minder vaak aangedaan dan bij volwassenen. De grote verschillen in de prevalentie van OLP op kinderleeftijd t.o.v. OLP op volwassen leeftijd kunnen slechts ten dele worden verklaard door een lager aantal geassocieerde aandoeningen, auto-immuun fenomenen, infecties, medicamenten en tandheelkundige vullingsmaterialen bij kinderen, die het risico op het ontwikkelen van OLP kunnen verminderen. Daarenboven zou de diagnose OLP gemist kunnen worden door onregelmatig bezoek aan de tandarts, het ontbreken van symptomen en door onwetendheid. In de literatuur blijkt OLP op kinderleeftijd meer bij kinderen van Aziatische afkomst voor te komen. Ook in onze studie waren 2 van de 3 kinderen van Aziatische afkomst hetgeen

volgens de Poisson-verdeling (statistisch significant) zeer onwaarschijnlijk is op grond van het toeval. Dit geeft wellicht aan dat een specifieke genetische predispositie (afhankelijk van het HLA-systeem) in het Aziatische ras, ondanks een negatieve familieanamnese, belangrijk zou kunnen zijn in de pathogenese van OLP op kinderleeftijd.

Conclusies: orale lichen planus op kinderleeftijd is zeldzaam en daarom is het niet goed mogelijk om definitieve uitspraken te doen over diverse aspecten van dit onderwerp. Orale lichen planus op kinderleeftijd blijkt met name voor te komen bij Aziatische kinderen. De klinische presentatie van OLP op kinderleeftijd lijkt overeen te komen met de presentatie van OLP op volwassen leeftijd. De prognose van OLP op kinderleeftijd lijkt echter in het algemeen gunstiger te zijn dan van OLP op volwassen leeftijd.

In **hoofdstuk 8** wordt een prospectieve, willekeurig verdeelde studie beschreven met 40 patiënten met een symptomatische vorm van OLP. Het doel van de studie was het vergelijken van de behandelingsresultaten tussen lokale behandeling met tacrolimuszalf en triamcinolonacetonidezalf en het beoordelen of er verschillen zijn in de perioden van remissie tussen de beide vormen van behandeling. Groep I met 20 patiënten werd behandeld met 0,1% tacrolimuszalf en groep II met eveneens 20 patiënten werd behandeld met 0,1% triamcinolonacetonide in 20% hypromellosezalf. De zalven werden gedurende 6 weken 4 keer per dag aangebracht op de afwijkingen van het mondslijmvlies.

In groep I genazen 6 (30%) patiënten, vertoonden 12 (60%) patiënten een verbetering en lieten 2 (10%) patiënten geen verbetering zien. In groep II genazen 2 (10%) patiënten, vertoonden 7 (35%) patiënten een verbetering en lieten 11 (55%) patiënten geen verbetering zien. De (initiële) resultaten van behandeling in groep I waren significant beter dan die in groep II. Bijwerkingen van de behandeling waren van voorbijgaande aard en traden op in 8 (40%) patiënten van groep I en in 3 (15%) patiënten van groep II. Deze verschillen tussen beide groepen zijn statistisch echter niet significant. Irritatie in de vorm van een branderig of prikkelend gevoel op de plaats van de aangebrachte zalf gedurende ongeveer 10 tot 30 minuten was de meest voorkomende bijwerking. Deze bijwerking trad met name op bij patiënten met de erosieve of ulceratieve variant van OLP in beide groepen, maar leidde in geen van de gevallen tot het voortijdig onderbreken van de behandeling. Helaas recidiveerden de afwijkingen binnen 3 tot 9 weken (gemiddeld 5 weken) na het beëindigen van de behandeling in 13 (72%) van de 18 patiënten in groep I en in 7 (78%) van de 9 patiënten van groep II, die aanvankelijk volledig of aanzienlijk waren verbeterd.

Conclusies: behandeling met 0,1% tacrolimuszalf is aanvankelijk effectiever dan behandeling met 0,1% triamcinolonacetonidezalf bij patiënten met een symptomatische vorm van OLP. Tijdelijke irritatie op de plaats van applicatie van beide zalven komt regelmatig voor, maar leidt niet tot het voortijdig stoppen van de behandeling. Helaas treden er frequent recidieven op binnen enkele

weken na het beëindigen van de behandeling in beide groepen van patiënten met OLP.

In **hoofdstuk 9** worden klinische richtlijnen voor de benadering van patiënten met OLP beschreven. Diverse belangrijke aspecten zoals anamnese, lichamelijk onderzoek, histopathologie, diagnose, aanvullend onderzoek, algemene adviezen, specifieke behandeling, resultaat van behandeling en het vervolgen van de patiënten met OLP worden in het kort besproken.

Aanbevelingen voor verder onderzoek

De exacte oorzaak van OLP kan alleen worden opgehelderd wanneer er goed opgezette studies met adequate controlegroepen worden verricht. Contactallergieën voor andere allergenen dan tot dusver beschreven kunnen mogelijk ook van belang zijn in de pathogenese van OLP. In de literatuur is er onvoldoende overeenstemming over de tijd van occlusie van allergenen bij plakproeven, in het bijzonder van metaalallergenen. De diverse studies in de literatuur kunnen opvallend verschillende tijdstippen van aflezen van de epicutane tests vertonen. Bovendien bestaan er vaak substantiële verschillen in de concentraties en de allergenen die worden gebruikt. Sommige studies zijn daarom moeilijk met elkaar te vergelijken.

Bovendien kunnen relevante positieve uitslagen bij plakproeven tamelijk eenvoudig worden gemist door het pas laat positief worden van de test.

Histopathologische kenmerken van OLP dienen nog nauwkeuriger te worden gedefinieerd om verschillen tussen de beoordeling van dezelfde preparaten tussen specialisten te verminderen. Nieuwe immunopathologische technieken zouden hiertoe wellicht in de toekomst kunnen bijdragen. Studies met vele patiënten zijn nodig om eventueel relevante associaties vast te leggen tussen diverse ziekten, in het bijzonder met een gewijzigde of verstoorde immuniteit, en OLP. Op dit moment is het namelijk veelal moeizaam vast te stellen of er sprake is van een oorzakelijk verband of van een toevallige samenhang tussen OLP en de diverse aandoeningen.

Daarnaast is het op dit moment veelal onmogelijk om op grond van klinisch, histopathologisch en immunologisch onderzoek een onderscheid te maken tussen OLP en een orale lichenoïde geneesmiddelreactie.

Vele huidige behandelingsmethoden van OLP zijn helaas vaak slechts gebaseerd op empirie, anekdotische gevallen of open klinische onderzoeken zonder adequate controlegroepen. Vele gegevens van patiëntengroepen met OLP kunnen onvoldoende met elkaar worden vergeleken door essentiële verschillen in het type van de publicaties, de exacte definitie van OLP, de opzet van de studies, eventueel bijkomende geassocieerde afwijkingen, de resultaten van behandeling en de periode van vervolgen van de patiënten.

Klinische, statistisch verantwoorde onderzoeken met grote groepen patiënten en controlegroepen zijn noodzakelijk om goede behandelingsmethoden te vinden bij patiënten met symptomatische vormen van OLP.

De mogelijke maligne ontaarding van OLP blijft helaas nog steeds een controversieel onderwerp, ondanks diverse gepubliceerde artikelen hierover, inclusief een hoofdstuk in dit proefschrift. Grote, langdurige vervolgstudies met patiënten met een goed gedocumenteerde diagnose van OLP en een nauwkeurige vaststelling van intrinsieke en extrinsieke risicofactoren zijn noodzakelijk.

In vele studies over OLP is er mogelijk onvoldoende aandacht besteed aan het eventueel voorkomen van LP op andere plaatsen van het lichaam, hetgeen bij sommige patiënten de betrouwbaarheid van de diagnose negatief zou kunnen beïnvloeden en een andere behandeling zou kunnen rechtvaardigen.

FIGURES AND LEGENDS TO THE FIGURES




Figure A: Statue of Hippocrates (460-377 B.C.).

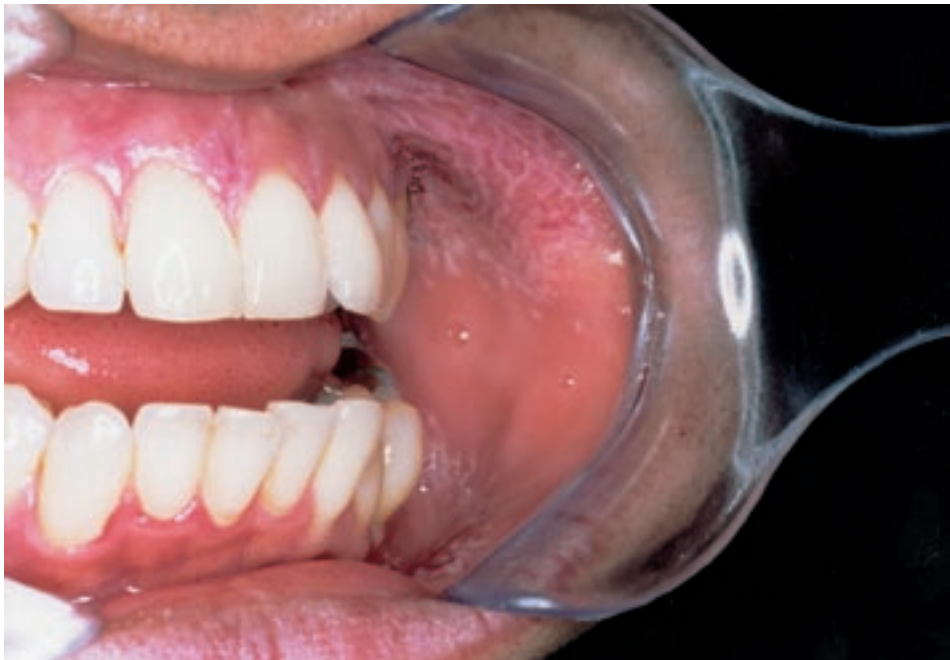

Figure 1: Characteristic reticular variant of OLP with Wickham's striae on the left buccal mucosa, and (less obvious) on the upper gingiva.

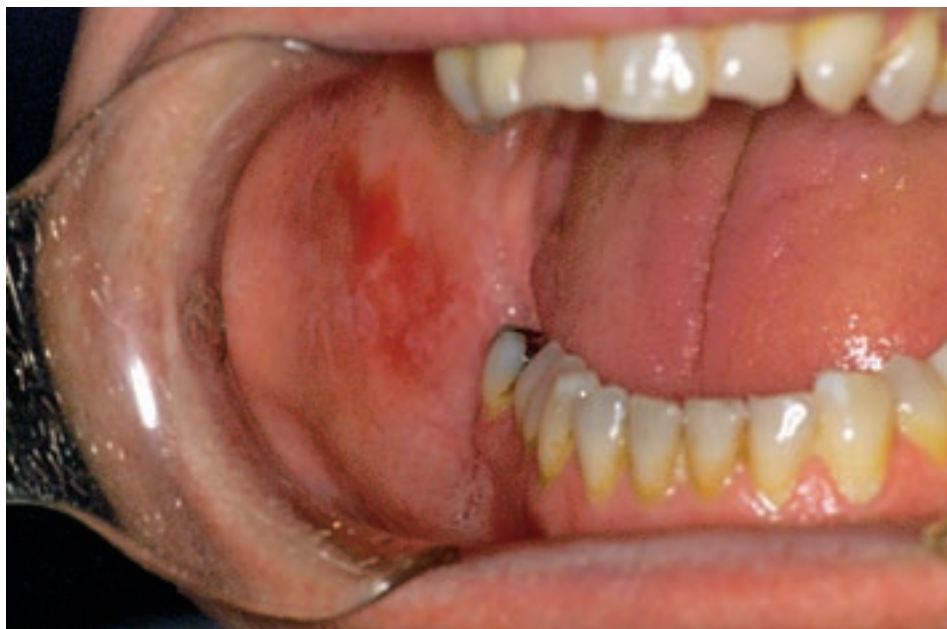

Figure 2: The erythematous or atrophic variant of OLP on the right buccal mucosa. There are also signs of the reticular variant of OLP in the surrounding mucosa.

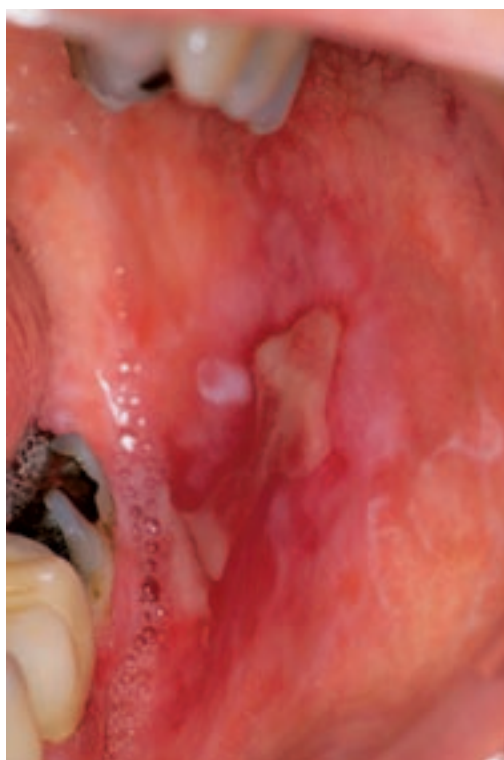

Figure 3: The erosive or ulcerative variant of OLP on the left buccal mucosa. There are also signs of the reticular variant of OLP in the surrounding mucosa. This patient complained of persistent pain in the oral cavity.

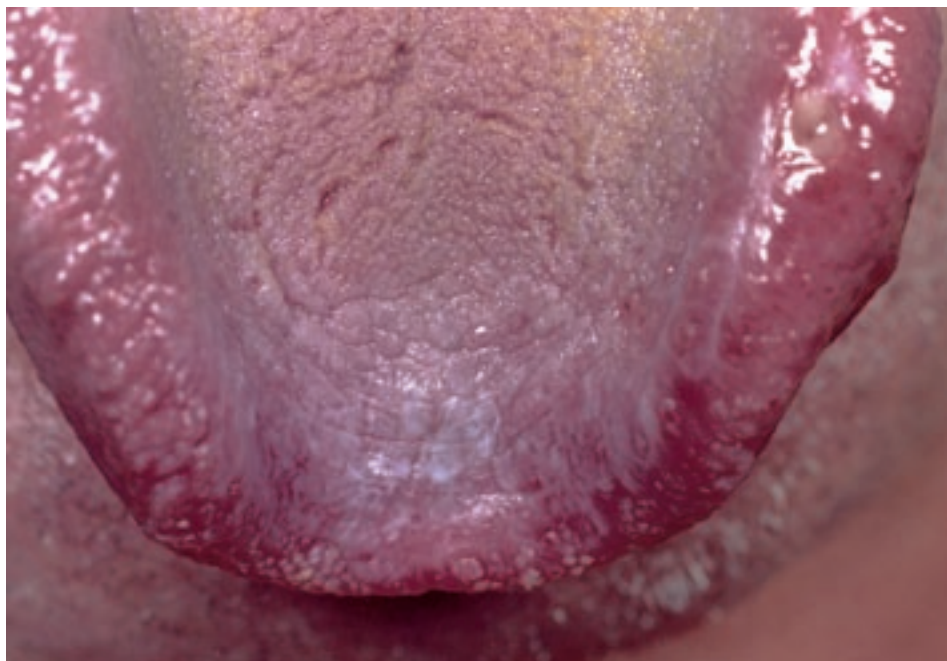

Figure 4: The reticular variant of OLP on the dorsal side of the tongue, which may lead to taste disturbance.

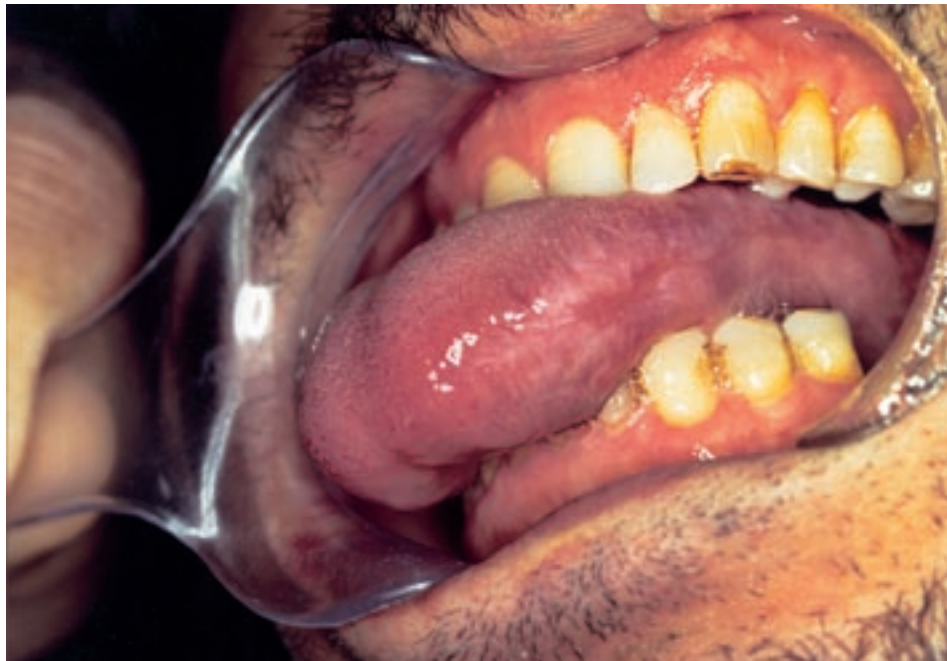

Figure 5: The erythematous or atrophic variant of OLP on the lateral part of the tongue with reticular OLP lesions in the surrounding mucosa. Oral hygiene is also decreased.

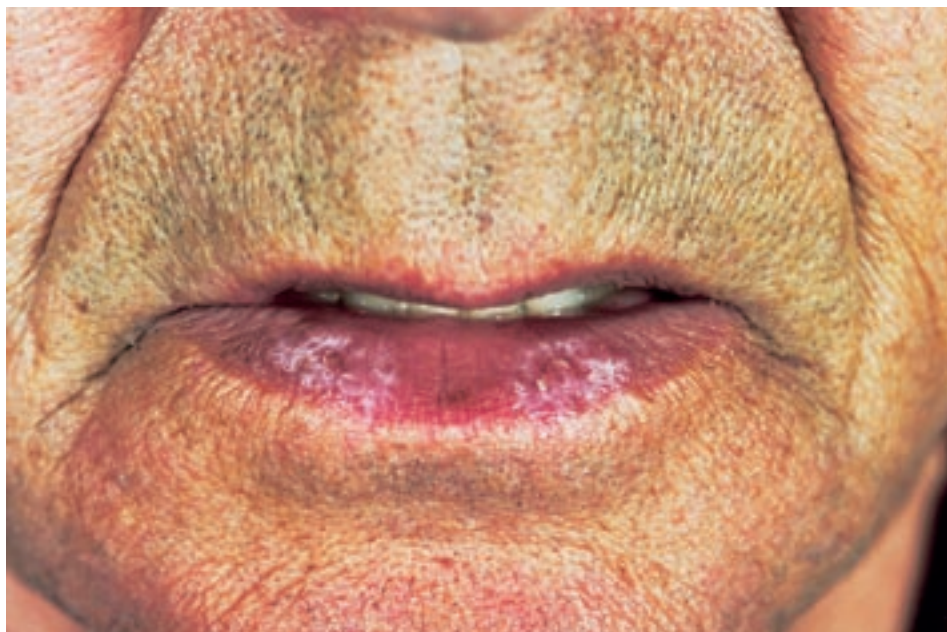

Figure 6: Reticular variant of OLP on the vermilion of the lower lip.

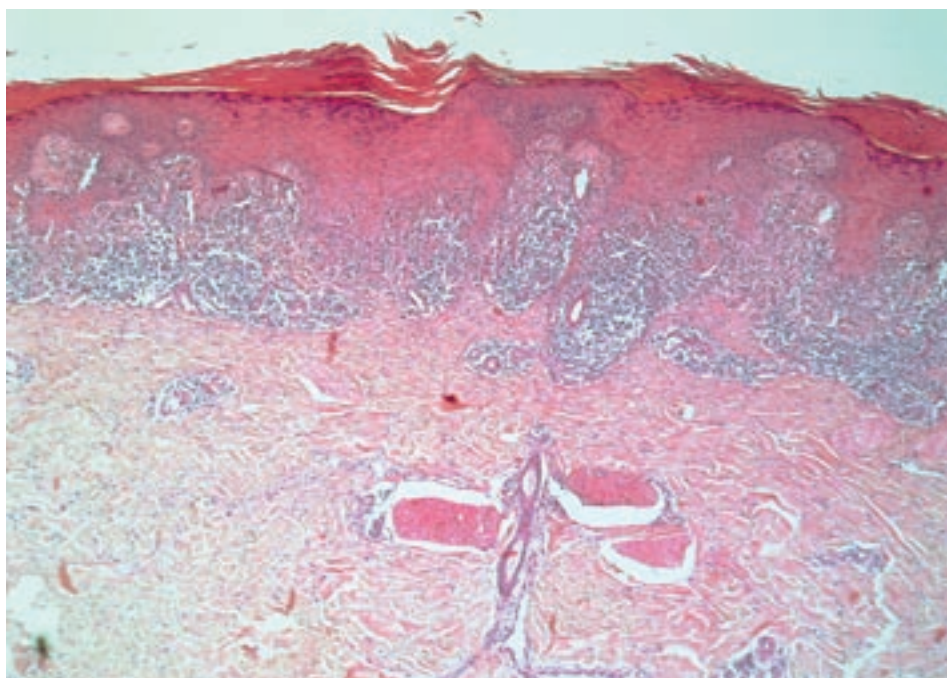


Figure 7: An overview of the histopathology in CLP. The epidermis and the dermis may be identified. There is hyperkeratosis, wedge-shaped hypergranulosis, irregular acanthosis with a saw-toothed appearance, and a typical band-like inflammatory infiltrate in the upper part of the dermis. (HE staining, magnification 100 \times).

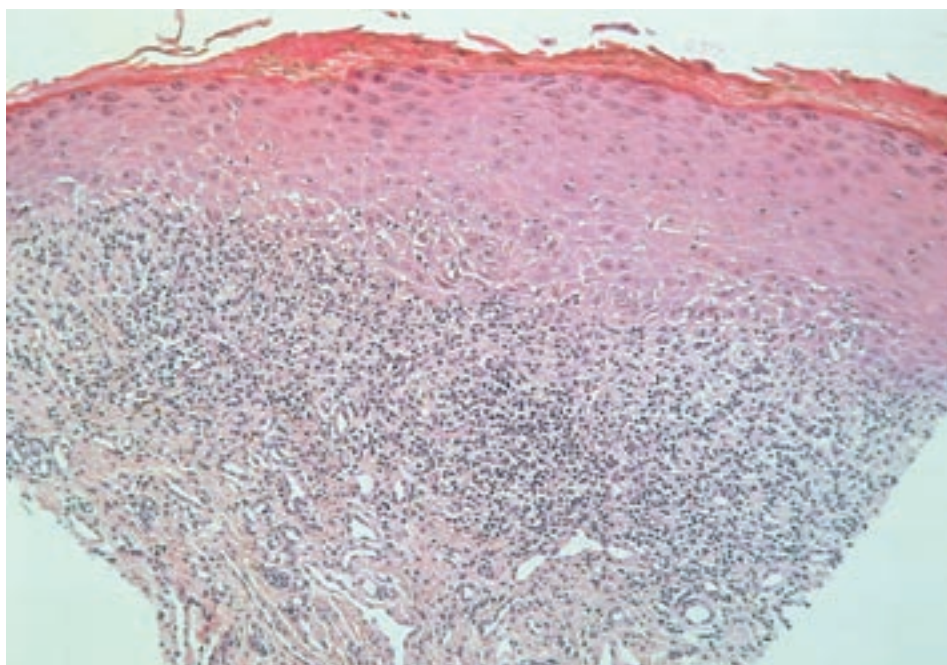


Figure 8: An overview of the histopathology in OLP. The epithelium shows a slight parakeratosis and the basal epithelial cells show liquefaction degeneration. There is a dense band-like inflammatory infiltrate mainly consisting of T-lymphocytes and a low number of histiocytes in the lamina propria and the BMZ. (HE staining, magnification 100×).

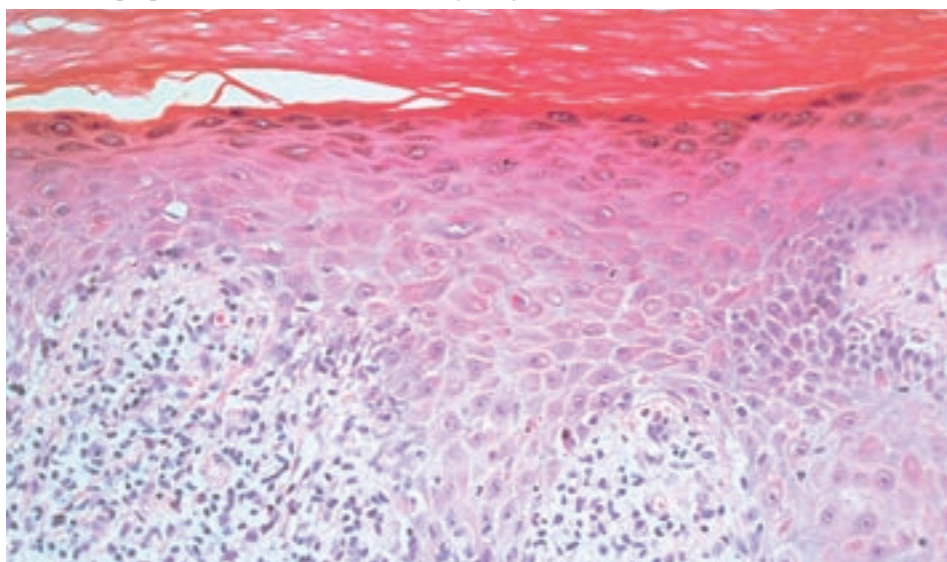


Figure 9: Histopathology of CLP. There is hyperkeratosis and hypergranulosis in the epidermis. A dense inflammatory infiltrate and liquefaction degeneration are present. Furthermore, there are a few Civatte's bodies (cytoid or colloid bodies), which represent dyskeratotic basal epithelial cells that have undergone premature keratinization in the BMZ. Civatte's bodies are considered to be among the earliest histopathological changes in LP. (HE staining, magnification 200×).

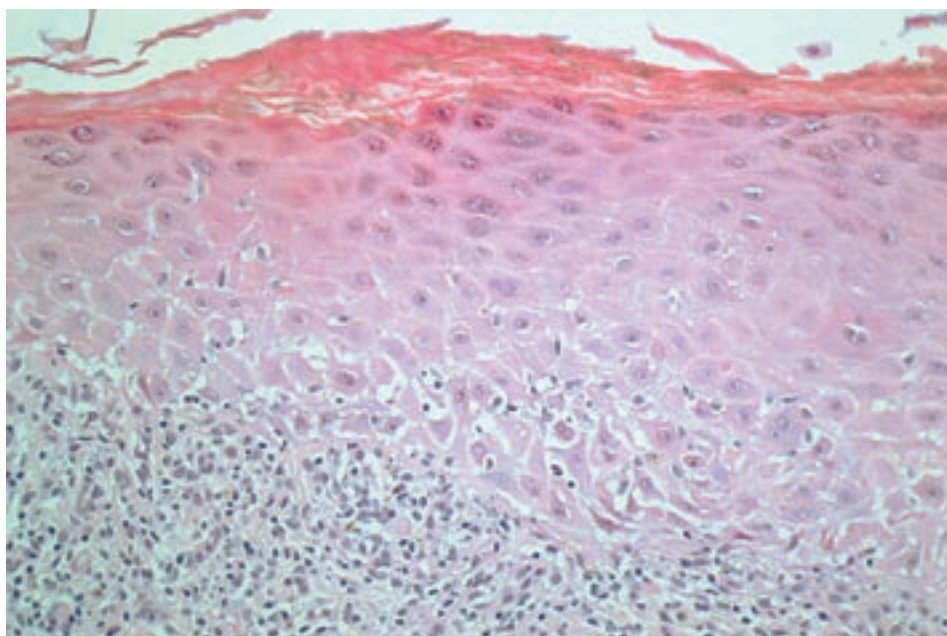


Figure 10: Histopathology of OLP. The epithelium shows a slight parakeratosis and a thickening of the stratum granulosum. There is a dense band-like inflammatory infiltrate mainly consisting of T-lymphocytes in the lamina propria with liquefaction degeneration of the basal epithelial cells. (HE staining, magnification 200×).

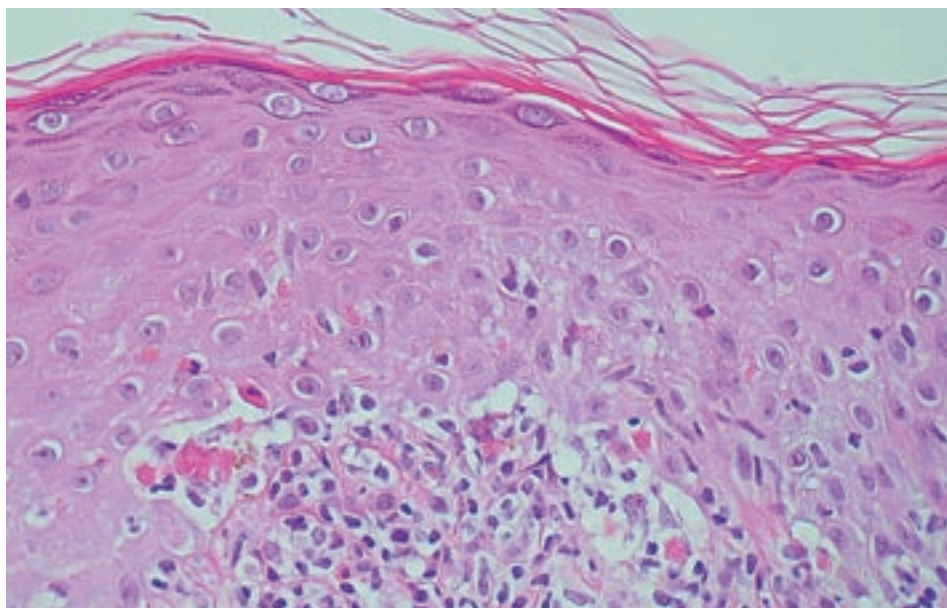


Figure 11: Histopathology of OLP. Several Civatte's bodies are present. As the BMZ becomes vacuolated, fluid accumulates and leads to the formation of small clefts known as Max Joseph spaces or Caspary-Joseph spaces. Dense inflammatory infiltrate mainly consisting of T-lymphocytes and a low number of histiocytes. (HE staining, magnification 400×).

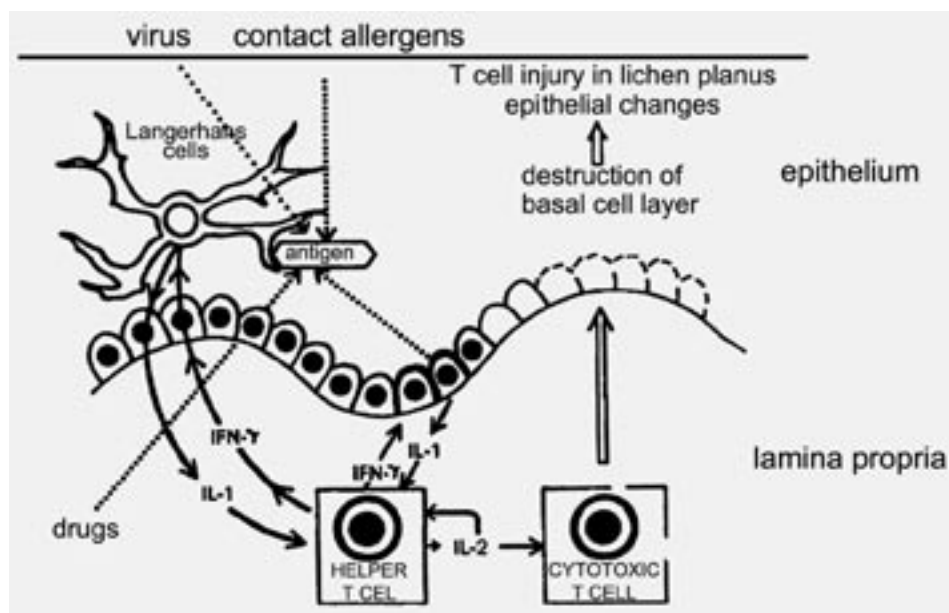


Figure 12: A diagrammatic representation of the proposed pathogenesis of OLP (modified from Morhenn and Shiohara et al^{187,188,198}, and Boyd and Neldner²⁶).

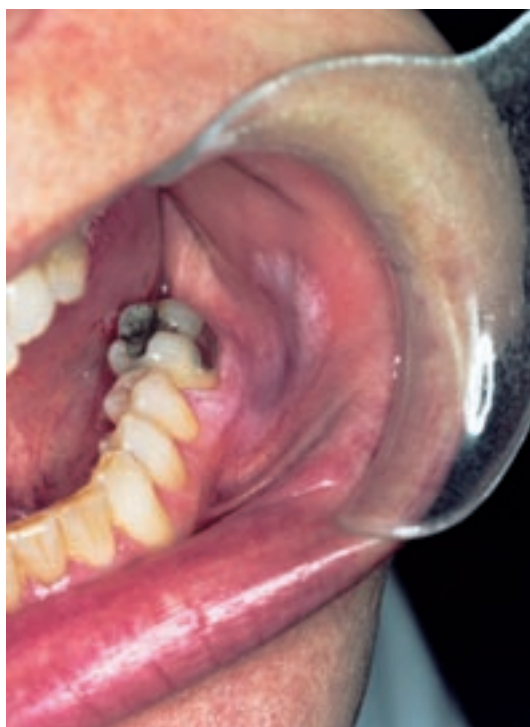

Figure 13: A patient with the hyperkeratotic form of OLP in close contact with amalgam fillings on the occlusal and buccal sides of element 36 with a small extension of the oral lesions beyond the area of the contact. Patch test reactions were positive to ammoniated mercury, metallic mercury and amalgam.

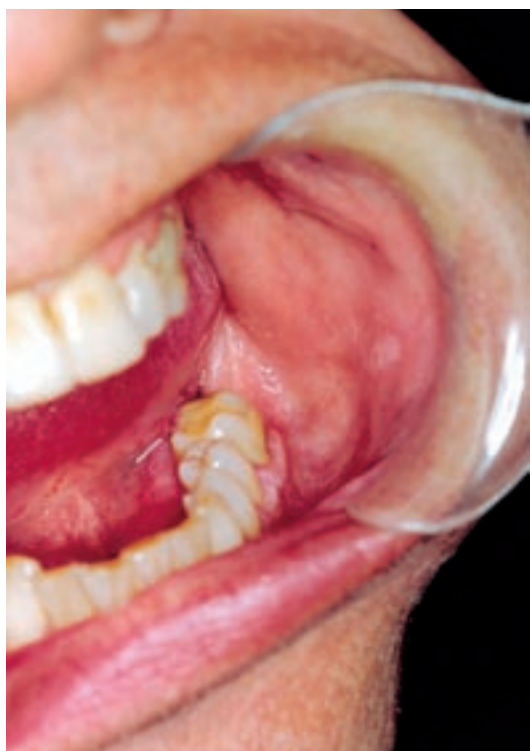

Figure 14: The same patient as in Figure 13. Replacement of the dental amalgam fillings with composite resins led to a significant improvement in OLP after 6 weeks. There was no recurrence during the follow-up for 2 years.

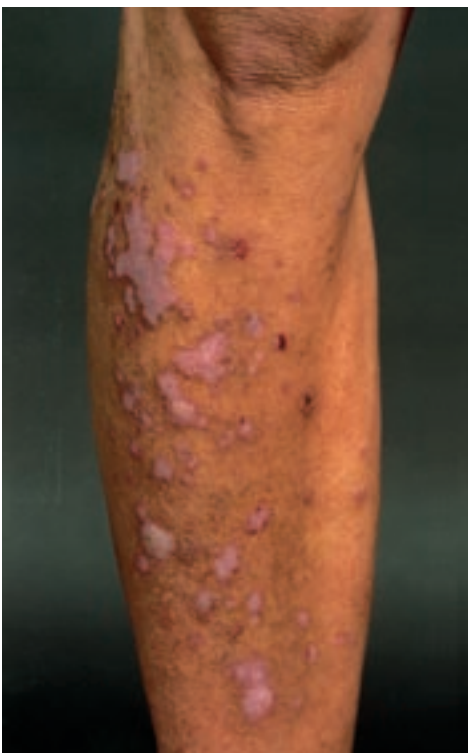

Figure 15: The ventral part of the lower leg of a patient with CLP. There are many pruritic, erythematous to violaceous papules and polygonal plaques present. Wickham's striae are also visible on the surface of the lesions. The focal increase in thickness of the granular layer and inflammatory infiltrate corresponds to the presence of the Wickham's striae.

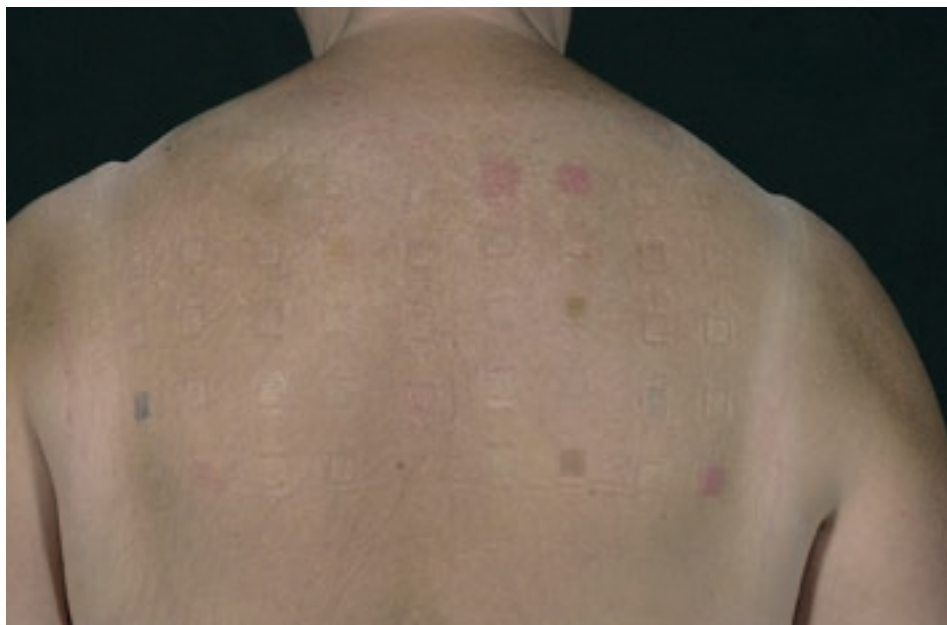

Figure 16: Positive patch test reactions to ammoniated mercury, metallic mercury and amalgam on the back of a patient with OLP. These reactions were not observed at the regular 3-day evaluation, but were positive after 1 week and persisted for 2 weeks.

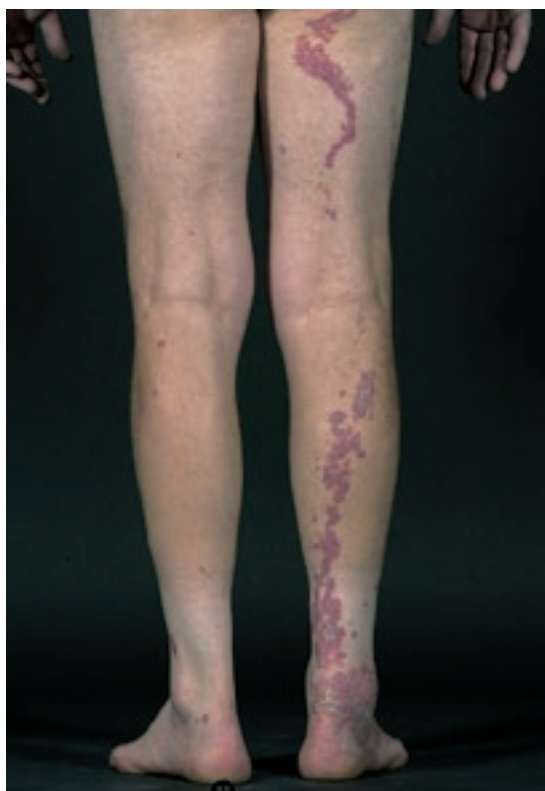


Figure 17: A patient with a linear LP with narrow linear lesions on the whole length of the dorsal part of the right limb. The distribution of the lesions follows the Blaschko's lines.

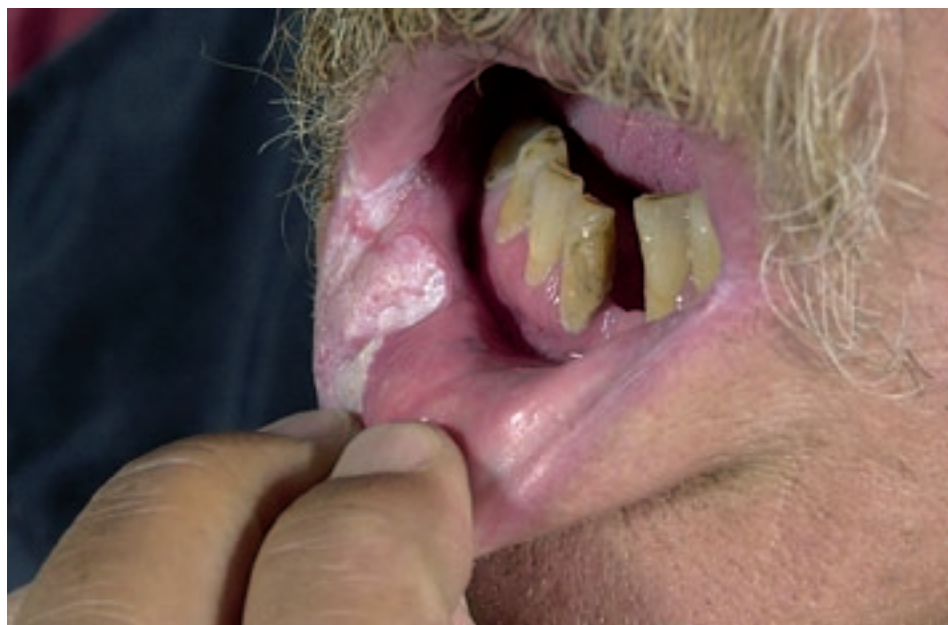

Figure 18: A patient with an OSCC of the lower lip. There is an indurated, hyperkeratotic tumor. Histopathological examination showed a well-differentiated OSCC.

DANKWOORD

Graag wil ik iedereen bedanken die, direct of indirect, heeft bijgedragen aan de totstandkoming van dit proefschrift.

Mijn promotor, Prof.dr. H.A.M. Neumann, wil ik hartelijk danken voor zijn bijdrage aan dit proefschrift.

Hoewel het onderwerp niet direct binnen de huidige onderzoekslijn van de afdeling Dermatologie en Venereologie van het Erasmus Medisch Centrum Rotterdam lag, was u direct enthousiast en vol vertrouwen dat het een leuk en goed proefschrift kon worden. Gelukkig werd ik heel vrij gelaten in de onderwerpen die volgens mij behandeld en beschreven moesten worden. Het overzicht heeft u echter goed behouden met passende adviezen voor een adequate voortgang in het schrijven.

Mijn copromotor, dr. B. Tank, wil ik hartelijk danken voor zijn enorme inzet bij het schrijven van dit proefschrift. Het zeer nauwkeurig corrigeren van het “US English” van alle teksten met het bekende rode potlood telkens binnen enkele dagen is een enorm werk geweest. Mijn hiaten in de kennis van woordkeuze, zinsopbouw en grammatica waren helaas veelvuldig aanwezig. Goede adviezen en correcties voor de opbouw en indeling van de artikelen waren nodig om ze klaar te maken voor publicatie in de diverse internationale tijdschriften.

Mijn opleider, Prof.dr. Th. van Joost, wil ik hartelijk danken voor het feit dat hij mij in 1989 in Rotterdam in opleiding voor dermatoloog heeft genomen en voor de oprechte vriendschap die er tussen ons is ontstaan. In 1991 raakten we door enkele patiënten op de polikliniek dermatologie geïnteresseerd in de eventuele oorzaak en behandeling van orale lichen planus (OLP). We waren beiden vrij snel overtuigd dat een allergie voor tandheelkundige materialen, in het bijzonder voor amalgaamvullingen en gouden kronen, bij een substantieel deel van de patiënten met OLP klinisch relevant was. Plakproeven met uiteenlopende tandheelkundige metalen en concentraties van allergenen werden bij vele patiënten uitgevoerd. Gedeeltelijke of volledige vervanging van het betreffende tandheelkundig materiaal gaf bij meerdere patiënten een aanzienlijke vermindering van de klachten. Vanaf die tijd zijn we vele gegevens van patiënten met OLP systematisch gaan verzamelen en werden er diverse onderzoeksprotocollen opgesteld. Hoewel u al enkele jaren met emeritaat bent, bleef u steeds

enthousiast en vol waardevolle adviezen toen ik besloot de vele gegevens te bundelen om een proefschrift te schrijven. Dat niet alles altijd succesvol was tijdens het onderzoek naar OLP, illustreert wel het feit dat we een keer ruim een kwartier zwijgzaam en wat stuurs voor ons uit zaten te kijken in uw kamer in het ziekenhuis met een speciale pleister in onze mond die geschikt zou zijn om slijmvliesafwijkingen te behandelen. Na korte tijd echter voelden we dat de pleister voortijdig los ging laten door de toename van speeksel en door kleine mondbewegingen. Dat die pleister “het niet ging worden” voor de patiënt werd ons spoedig duidelijk en nadien hebben we natuurlijk kostelijk gelachen over het door ons uitgevoerde experiment.

De promotiecommissie bestaande uit Prof.dr. J.W. Oosterhuis, Prof.dr. E.P. Prens en Prof.dr. I. van der Waal wil ik hartelijk danken voor hun gewaardeerde beoordeling van het proefschrift.

Mijn directe collegae en maten in het Albert Schweitzer ziekenhuis, Piet Burger en Sybren Dekker, wil ik bedanken voor de loyaliteit, het vertrouwen en de vriendschap in onze maatschap. Goede patiëntenzorg en humor blijken heel goed samen te gaan. Zij hebben in de loop van de jaren vele patiënten met OLP voor mijn onderzoek verzameld, hetgeen noodzakelijk is om tot statistisch verantwoorde aantallen te komen. Daarnaast hebben ze mij ook gestimuleerd om dit proefschrift te schrijven.

Dr. P.G.H. Mulder van de afdeling Epidemiologie en Biostatistiek van de Erasmus Universiteit Rotterdam wil ik hartelijk danken voor zijn hulp voor de noodzakelijke statistische bewerkingen van al het onderzoek. Zoals jij reeds vooraf aankondigde zijn dergelijke statistische handelingen voor een “gewone” medisch specialist veel te ingewikkeld.

Dr. Marti C. Kuizinga en andere collegae van het Pathologisch Anatomisch Laboratorium in Dordrecht wil ik hartelijk danken voor het beoordelen van de vele histologische coupes en het beschikbaar stellen van de foto's met histopathologische beschrijvingen voor dit proefschrift. Veelvuldig telefonisch overleg over patiënten verliep altijd prima.

Esther Teerds-van 't Hoog, secretaresse van onze maatschap, wil ik hartelijk danken voor haar inzet en het verrichten van het vele werk voor de maatschap. Het bewerken van de artikelen volgens de uiteenlopende richtlijnen van de diverse internationale tijdschriften was bij jou in goede handen.

Wil Lokkerbol, voormalig secretaresse van Prof.dr. Th. van Joost en thans secretaresse van Prof.dr. H.A.M. Neumann in het Erasmus Medisch Centrum, wil ik hartelijk danken voor het vele typewerk tijdens mijn opleiding tot dermatoloog en de coördinatie van alle noodzakelijke documenten om te kunnen promoveren.

Alle doktersassistenten, verpleegkundigen (en invalkrachten), huidtherapeuten, arts-assistenten en overige medewerkers, in het bijzonder werkzaam op of voor onze polikliniek dermatologie van het Albert Schweitzer ziekenhuis, heb-

ben vaak extra werk bij patiënten met OLP verricht, waarvoor dank. De “care” en de “cure” voor de patiënt staan op onze polikliniek dermatologie gelukkig nog steeds centraal.

Alfons Jannink, medisch fotograaf, wil ik hartelijk danken voor de vele scherpe foto’s van patiënten met OLP en het verzorgen van de foto’s voor dit proefschrift.

A.P. Djajadiningrat, dermatoloog, wil ik bedanken voor zijn collegialiteit en grote inzet voor onze praktijk op de hem kenmerkende, bescheiden wijze en U.R. Quast, kaakchirurg, voor onze collegiale vriendschap en het verwijzen van vele patiënten met OLP voor mijn onderzoek.

Irene van Loon van de medische bibliotheek van het Albert Schweitzer ziekenhuis wil ik bedanken voor het verzamelen van de vele artikelen over OLP die soms van ver aangevraagd dienden te worden.

Alle dermatologen, kaakchirurgen, huisartsen en tandartsen die patiënten met OLP, ook van buiten het directe verzorgingsgebied van het Albert Schweitzer ziekenhuis, naar mij hebben verwezen, wil ik bedanken voor het vertrouwen dat ze in mij stelden op dit terrein.

Mijn paranimfen, Maarten Lequin en Douwe van der Werf, wil ik hartelijk danken voor onze trouwe en plezierige vriendschap, al daterend van de middelbare school en voor het feit dat ze mij vandaag bij willen staan.

Mijn vader en moeder wil ik oprecht bedanken voor de onvoorwaardelijke steun, zorg en liefde gedurende heel mijn leven. Zij hebben het mogelijk gemaakt dat ik geneeskunde kon studeren en mij altijd gemotiveerd om medisch specialist te worden. Trots en dankbaar ben ik dat we samen deze dag mogen vieren. Mijn vader wil ik verder nog bedanken voor de juiste spellingsadviezen volgens het “Groene boekje” in de Nederlandse teksten in dit proefschrift.

Mijn broer Harry wil ik bedanken voor zijn continue beschikbaarheid met name op het gebied van de automatisering (het verhelpen en voorkomen van storingen van de laptop en de printer) en mijn zus Helma voor het vroegtijdig in contact brengen met de studie geneeskunde en het studentenleven.

Marjon wil ik intens bedanken voor de onvoorwaardelijke liefde en steun in het dagelijks leven. Ons “thuis” is met name door jou al vele jaren een gelukkige, gastvrije, rustige en stabiele basis. Daarnaast heb je me altijd de benodigde ruimte in het werk gegeven en me gestimuleerd om dit proefschrift te schrijven.

Trots ben ik ook op onze lieve kinderen Annelien, Michiel en Esther. Jullie dragen voor een belangrijk deel bij aan het dagelijks geluk in ons gezin. Heel bijzonder vind ik het dat jullie er vandaag bij zijn.

CURRICULUM VITAE

Ronald Laeijendecker was born on the 29th of March 1963 in Dordrecht, The Netherlands, and was the youngest of the 4 children in a general practitioner's family. He attended the Johan de Witt gymnasium in Dordrecht and obtained high school diploma (gymnasium β) in 1981. He studied Economy at the Erasmus University Rotterdam (EUR) from 1981 to 1982.



He commenced medical studies at the faculty of Medicine, Erasmus University Rotterdam in 1982 and received his medical degree (MD) in 1988. He worked as a resident not in training (AGINO) at the Department of Surgery of the Eudokia Hospital in Rotterdam (head: A. Zwaan) (currently: IJsselland Hospital, Capelle aan de IJssel) from 1988 to 1989. He commenced residency in Dermatology at the Academic Hospital Dijkzigt in Rotterdam, The Netherlands (Heads: Prof.dr. Th. van Joost and Prof.dr. E. Stolz), currently known as the Erasmus MC, University Medical Center Rotterdam (present head of the Department of Dermatology: Prof.dr. H.A.M. Neumann) in 1989 and participated in several investigations on the treatment of psoriasis vulgaris with cyclosporin during the residency. He was the chairman of the National Society for residents in Dermatology and Venereology from 1990 to 1993 and was registered as a Dermatologist in 1993.

Investigations into various clinical aspects of patients with oral lichen planus were initiated at the Department of Dermatology of the Academic Hospital Dijkzigt in Rotterdam in 1991 and continued later at the Albert Schweitzer Hospital in Dordrecht cumulating in the investigations described in this thesis.

He has worked as a dermatologist at the Albert Schweitzer Hospital in Dordrecht and Sliedrecht, The Netherlands (previously known as: Merwede Hospital Dordrecht and Sliedrecht) since 1993.

Marjon is married to Ronald since 1990. They have three children Annelien (13), Michiel (11) and Esther (9).

CURRICULUM VITAE

Ronald Laeijendecker werd geboren op 29 maart 1963 te Dordrecht, als jongste van 4 kinderen in een huisartsengezin. In 1981 werd het eindexamen gymnasium- β behaald aan het Johan de Witt-gymnasium te Dordrecht. Van 1981 tot 1982 studeerde hij Economie aan de Erasmus Universiteit Rotterdam (EUR).

In 1982 begon hij met de studie Geneeskunde aan de Erasmus Universiteit Rotterdam. Het artsexamen werd behaald in 1988. Van 1988 tot 1989 was hij arts-assistent chirurgie (niet in opleiding) in het Eudokia ziekenhuis te Rotterdam (hoofd: A. Zwaan) (thans: IJsselland ziekenhuis, Capelle aan de IJssel). In 1989 werd begonnen met de opleiding Dermatologie in het Academisch ziekenhuis Rotterdam Dijkzigt (opleiders: Prof.dr. Th. van Joost en Prof.dr. E. Stolz) (thans: Erasmus Medisch Centrum Rotterdam. Opleider: Prof.dr. H.A.M. Neumann).

Tijdens de studie en opleiding participeerde hij in enkele onderzoeken met name over de behandeling van psoriasis vulgaris met ciclosporine. Van 1990 tot 1993 was hij voorzitter van de landelijke Vereniging van Arts-assistenten Dermatologie en Venereologie. In 1993 werd de opleiding tot dermatoloog voltooid.

In 1991 werd begonnen met onderzoek naar diverse klinische aspecten van patiënten met orale lichen planus op de afdeling Dermatologie in het Academisch ziekenhuis Rotterdam en later werd dit voortgezet in het Albert Schweitzer ziekenhuis, hetgeen heeft geresulteerd in dit proefschrift.

Sinds 1993 is hij werkzaam als dermatoloog in het Albert Schweitzer ziekenhuis in Dordrecht en Sliedrecht. (Voorheen: Merwede ziekenhuis Dordrecht en Sliedrecht).

Sinds 1990 is Marjon getrouwd met Ronald. Zij hebben drie kinderen: Annelien (13), Michiel (11) en Esther (9).

BIBLIOGRAPHY

Publications:

1. Laeijendecker R, Oranje AP, van Joost Th. Parapemphigus en varianten; klinische en immunologische aspecten. [Dutch]. Bullous pemphigoid: clinical and immunological aspects. Ned Tijdschr Geneesk 1989; 133 (35): 1741-4.
2. Laeijendecker R, Oranje AP, van Joost Th. Ingezonden. Parapemphigus en varianten; klinische en immunologische aspecten. [Dutch]. Letter. Bullous pemphigoid; clinical and immunological aspects. Ned Tijdschr Geneesk 1989; 133 (44): 2194.
3. Heule F, Bousema MT, Laeijendecker R, van Joost Th. Three long-term regimens with cyclosporin for psoriasis vulgaris. Acta Derm Venereol. Suppl (Stockh) 1989; 146: 171-5.
4. Laeijendecker R, Heule F, van Joost Th. Orale lichen planus: klinische en immunologische aspecten. [Dutch]. Oral lichen planus: clinical and immunological aspects. Ned Tijdschr Geneesk 1992; 136 (44): 2167-71.
5. Heule F, Laeijendecker R, van Joost Th. Topical cyclosporin A treatment in psoriasis and other dermatological diseases: theoretical and practical aspects. J Dermatol Treatm 1992; 2: 149-53.
6. van Joost Th, Laeijendecker R. Amalgaam. VI. Allergie voor kwik in tandheelkundig materiaal; orale en systemische reacties. [Dutch]. Allergy to mercury in dental materials; oral and systemic reactions. Ned Tijdschr Tandheelk 1993; 100 (7): 303-7.
7. Laeijendecker R, van Joost Th. Oral manifestations of gold allergy. J Am Acad Dermatol 1994; 30: 205-9.
8. Laeijendecker R. Orale lichen planus; kan er sprake zijn van een allergie? [Dutch]. Oral lichen planus: Is there a possible role for allergy? Ned Tijdschr Chron Ziekten 1995; 2: 16-7.
9. Schuttelaar ML, Laeijendecker R, Heinhuis RJ, van Joost Th. Erythema multiforme and persistent erythema as early cutaneous manifestations of Lyme disease. J Am Acad Dermatol 1997; 37: 873-5.
10. Verwoerd-Verhoef HL, Adriaansen FCPM, Laeijendecker R, van Osch GJ, Verwoerd CDA. Growth dynamics of the cricoid cartilage and subglottic injury. An autoradiographic and histometric study in the rabbit. Eur Arch Otorhinolaryngol 1997; 254 (1): 101-4.
11. Laeijendecker R. Orale lichen planus. [Dutch]. Oral lichen planus. Ned Tijdschr Dermatol & Venereol 1999; 9: 356-7.

12. Nijssen A, Laeijendecker R, Heinhuis RJ, Dekker SK. Polypoid clear cell acanthoma of unusual size. *J Am Acad Dermatol* 2001; 44 (2): 314-6.
13. Mulas MW, Dekker SK, Laeijendecker R. CO₂-laserbehandeling: effectief in Morbus Hailey-Hailey. [Dutch]. CO₂-lasertreatment: effective in Morbus Hailey-Hailey. *Ned Tijdschr Dermatol & Venereol* 2002; 12: 129-31.
14. Laeijendecker R, Dekker SK, Burger PM, Mulder PGH, van Joost Th, Neumann HAM. Oral lichen planus and allergy to dental amalgam restorations. *Arch Dermatol* 2004; 140: 1434-8.
15. Laeijendecker R, van Joost Th, Tank B, Neumann HAM. Oral lichen planus and hepatitis C virus infection. *Arch Dermatol* 2005; 141: 906-7.
16. Laeijendecker R, van Joost Th, Tank B, Oranje AP, Neumann HAM. Oral lichen planus in childhood. *Pediatr Dermatol* 2005; 22(4): 299-304.

Abstracts:

1. Heule F, Bousema MT, Laeijendecker R, van Joost Th. Three long-term regimes with cyclosporin for psoriasis vulgaris. III European Symposium on Psoriasis. September 23-25, 1988. Trieste. Italy.
2. Heule F, Laeijendecker R, van Joost Th. Cyclosporin A (CYA) therapy for psoriasis masks delayed type hypersensitivity (DTH). International Symposium on Irritant Contact Dermatitis. October 3-5, 1991. Groningen. The Netherlands.
3. Heule F, Bousema MT, Laeijendecker R, van Joost Th. Long-term, continuous and intermittent treatment regimes with cyclosporin for psoriasis compared. Congress: Clinical Dermatology in the year 2000. May 22-25, 1990. London. United Kingdom.

