

Secondary interventions in patients with autologous infrainguinal bypass grafts strongly improve patency rates.

Hidde Jongsma, MD^a

Joost A. Bekken, MD^a

Fons van Buchem^a

Wouter Bekkers^a

Fahim Azizi, MD^b

Bram Fioole, MD PhD^a

Departments of Vascular Surgery^a and Radiology^b,

Maastad Hospital, Rotterdam, the Netherlands.

Jongsma H, Bekken JA, Van Buchem F, Bekkers WJJ, Azizi F, Fioole B. Secondary interventions in patients with autologous infrainguinal bypass grafts strongly improve patency rates. J Vasc Surg. 2016;63(2):385–90.

ABSTRACT

Objectives

This study describes the patency of percutaneous transluminal angioplasty (PTA) of autologous infrainguinal bypasses at risk.

Methods

This was a retrospective single-center cohort study of consecutive patients undergoing primary PTA of an infrainguinal autologous bypass at risk from January 2009 to December 2013. Duplex ultrasound surveillance was performed for at least 1 year after PTA. The primary study endpoints was the number of secondary interventions. Secondary endpoints were freedom from recurrent stenosis or bypass occlusion and the patency of the infrainguinal autologous bypass at 1 year after primary PTA.

Results

A total of 69 infrainguinal bypasses at risk in 69 patients were identified and treated with PTA. Technical success was achieved in 91%. Median follow-up was 17 months (range, 1-58 months). During follow-up, 30 bypasses (43%) remained free of significant stenosis or bypass occlusion, 29 bypasses (42%) developed recurrent stenosis, and 10 bypasses (14%) occluded. Rates of primary assisted, and secondary patency at 1 year were 84%, and 86%. Five (7%) major amputations were performed, all after bypass occlusion.

Conclusions

Secondary interventions after PTA of a BAR are common. However, repeated secondary interventions of autologous infrainguinal bypasses at risk result in patency rates of more than 80% at 1 year.

INTRODUCTION

According to the TransAtlantic Inter-Society Consensus for the Management of Peripheral Arterial Disease (TASC II) guidelines, autologous infrainguinal bypasses are the treatment of choice in patients with multilevel and complicated peripheral arterial occlusive disease¹. Autologous infrainguinal bypasses show excellent long-term patency rates, and 5-year patency rates up to 80% have been reported^{2,3}. However, a vein graft stenosis will develop in one-third of patients with an autologous infrainguinal bypass^{4,5}. Stenosis formation is a continuous process, and if a stenosis is >70%, the bypass will eventually occlude^{6,7}. Infrainguinal bypass occlusion is associated with poor outcome^{8,9}; therefore, autologous infrainguinal bypass surveillance by duplex ultrasound imaging is widely accepted¹⁰⁻¹³. Stenoses detected by duplex ultrasound imaging can be treated by percutaneous transluminal angioplasty (PTA) or surgical revision.

The aim of this study was to describe the patency of primary PTA of autologous infrainguinal bypasses at risk.

MATERIALS AND METHODS

Patient identification

All patients with peripheral arterial occlusive disease treated with an autologous infrainguinal bypass were monitored for at least 1 year. Duplex ultrasound surveillance was performed at 6 and 12 months by ultrasound technicians from an accredited vascular laboratory. Thereafter duplex ultrasound was performed if the patient became symptomatic. A bypass with a stenosis of >70% was considered a bypass at risk (BAR). A >70% stenosis was defined as a peak systolic velocity of >300 cm/s or a peak systolic velocity ratio >3.0. All consecutive patients from a single center undergoing PTA of a significant stenosis in an autologous infrainguinal bypass from January 2009 until December 2013 were included. Data were collected retrospectively from the electronic medical records. The local ethics commission approved this retrospective case study and issued a waiver for patient informed consent.

Comorbidity

Hyperlipidemia was defined as elevated triglycerides, low-density lipoprotein cholesterol, or total cholesterol, or use of a cholesterol-lowering drug for this condition. Hypertension was defined as a systolic blood pressure >140 mm Hg or use of antihypertensive drugs. Patients were considered diabetic when glycated hemoglobin was elevated (HbA1c >7%) or when patients used oral hypoglycemic agents or insulin. Patients with a history of transient ischemic attack or cerebrovascular accident were considered to have history

of cerebral artery disease. Patients with a history of angina pectoris, myocardial infarction, percutaneous transluminal coronary angioplasty, or coronary artery bypass grafting were considered as having a history of coronary artery disease. Patients with a GFR below 60 were considered as having renal failure. A history of smoking or current smoking was recorded.

Intervention

The primary treatment of a BAR was PTA. Patients with a BAR were scheduled for angiography, and the stenosis or multiple stenoses in the bypass were identified and classified as anastomotic or nonanastomotic. After angiography, the bypass diameter proximal and distal to the stenosis was measured. A balloon catheter with a diameter similar to the bypass diameter was used for angioplasty. In selected patients with a residual stenosis of >30% a second PTA was performed with a larger balloon diameter. All stenoses were treated by PTA using plain balloon angioplasty. Treatment was considered a technical success if PTA resulted in a residual stenosis of <30%, measured by angiography during the procedure. If a flow-limiting dissection occurred or a residual stenosis of >30% persisted, a self-expanding stent was placed. Obstructive lesions in other arterial segments (ie iliac or tibial) were treated simultaneously with PTA and optional stenting.

Follow-up

All patients were monitored for at least 1 year after PTA of the BAR. Postoperatively, patients were scheduled for an ankle-brachial index after six weeks. Patients with an inadequate ankle-brachial index or patients showing symptoms of ischemia were scheduled for a duplex ultrasound or direct angiography. Otherwise duplex ultrasound surveillance was performed at 6 and 12 months according to guidelines of the Dutch vascular society. According to guidelines of the Dutch vascular society, all patients were treated with anticoagulation therapy for at least 2 years after autologous bypass surgery. Whenever anticoagulation therapy was not eligible, patients were treated with antiplatelet therapy. All patients were treated with statins for secondary prevention. Patients with a recurrent significant stenosis in the bypass during follow-up were rescheduled for angiography. At our institution an endovascular-first approach is adopted for primary and recurrent stenoses. Patients with bypass occlusion during follow-up were treated with thrombolytic therapy or surgical embolectomy. When occluded bypasses were not treated or treatment was not successful, the bypass was considered a failure. Major amputations (above the ankle) and minor amputations (below the ankle) were recorded during follow-up.

Study end points

The primary study endpoints was the number of secondary interventions. Secondary endpoints were freedom from recurrent stenosis or bypass occlusion and the patency of

the infrainguinal autologous bypass at 1 year after primary PTA. Freedom from recurrent stenosis was defined as duplex peak systolic velocity of > 300 cm/s at the treated site or anywhere within the graft or its anastomosis. Assisted primary patency was defined as any treatment of a significant stenosis preventing bypass occlusion. Secondary patency was defined as bypass patency after occlusion when treated successfully with thrombolytic therapy or surgery¹⁴.

Statistical analysis

Data were collected and stored in an online eCRF (Castor edc, Ciwit BV, Amsterdam, the Netherlands). SPSS 22 software (IBM, Armonk, NY, USA) was used for data analysis. Kaplan-Meier survival analysis was used to estimate patency rates. Differences were considered significant if the P value was <.05

RESULTS

Patient selection

We identified 69 infrainguinal BARs in 69 patients treated with PTA. In this period no primary surgical revision has been performed. In the past decade an average of 63 patients per year underwent infrainguinal, autologous bypass surgery in our institution. This results in an estimated primary revision rate of 22%. Baseline characteristics are reported in Table I and bypass characteristics are reported in Table II. No in situ bypasses were performed.

Table I. Baseline characteristics

Variables	No (%) or Mean \pm SD
	(N = 69)
Age, years	71 \pm 9.1
Male	40 (58)
Diabetes	26 (38)
Hypertension	53 (77)
Dyslipidemia	43 (62)
Coronary artery disease	27 (39)
Cerebral artery disease	14 (20)
Renal failure (GFR<60)	9 (14)
Smoking	
No	3 (4)
Past	8 (12)
Current	24 (35)

SD, standard deviation.

Table II. Bypass characteristics

Type	No. (%)
	(N = 69)
Indication	
Claudication	31 (45)
Critical limb ischemia	38 (55)
Femoropopliteal bypass	
Suprageniculate	21 (30)
Infrageniculate	29 (42)
Femoroanterior tibial bypass	3 (4)
Femoroposterior tibial bypass	11 (16)
Femoroperoneal bypass	5 (7)
Single segment great saphenous vein bypasses	
Reversed	12 (17)
Non reversed	49 (71)
Spliced vein bypasses	
Great saphenous veins	6 (9)
Arm veins	2 (3)

In case of a non-reversed bypass either an expandable or Mills valvulotome was used to destruct the valves. The distal anastomosis was infragenicular in 48 bypasses (70%).

Procedure

The median number of days from the bypass operation until the primary PTA of the BAR was 233 days (range, 42-6238 days). Fifty patients (72%) had an isolated stenosis in the bypass. A stenosis was located at the proximal anastomosis in 13 patients (19%) and was located at the distal anastomosis in 38 (55%). Technical success was achieved in 63 patients (91%). Bailout stenting was performed for a residual stenosis in two patients and for a flow-limiting dissection after PTA in two other patients. In one patient a residual stenosis was accepted due to unavailability of the appropriate stent. A rupture of the BAR occurred in one patient, which was successfully controlled with a covered stent.

A postoperative complication occurred in four patients (6%). Three patients developed a hematoma after manual compression of the access site, one of whom needed surgical exploration to control the bleeding. A pseudoaneurysm developed at the access site in one patient and was treated successfully with an ultrasound-guided thrombin injection. Procedural characteristics can be found in Table III.

Table III. Treatment and stenosis characteristics

Variables	No. (%)
	(N = 69)
Distribution	
Solitary	50 (72)
Multiple	19 (28)
Location	
Proximal anastomosis	13 (19)
Proximal third of the bypass	9 (13)
Middle third of the bypass	9 (13)
Distal third of the bypass	21 (30)
Distal anastomosis	38 (55)
Technical success	63 (91)
Postoperative complication	4 (6)
Concomitantly treated lesions	
Inflow	6 (9)
Outflow	11 (16)

Follow-up after primary PTA

Median follow-up was 17 months (range 1-58 months), during which time 30 of the 69 bypasses (43%) remained free from recurrent stenosis or bypass occlusion (figure 1). Recurrent stenosis developed in 29 patients (42%) after a median of 214 days (range 63 to 865), 26 of whom underwent a successful second PTA. In one patient, a second PTA was not technically successful and the stenosis was successfully treated by creating a jump graft from the bypass to the posterior tibial artery. In another patient, recurrent significant stenosis was treated with an interposition graft. Another patient was scheduled for a second PTA; however, the procedure was terminated due to pectoral angina during the procedure. The patient was not scheduled for a reintervention and died several months later. Six patients also underwent a third PTA for recurrent stenosis, two patients underwent four PTAs, and one patient five PTAs, all successfully. In all but three patients, recurrent stenosis occurred at the same site. During secondary revision of stenoses at a new site in the bypass, no indication for recurrent stenosis was identified at the site previously treated. In patients with recurrent stenosis in the bypass, the preoperative duplex ultrasound showed diameters of <3.5mm in 4 of the 9 patients, in 3 patients we could not retrieve preoperative data.

During follow-up, 10 bypasses (14%) occluded. Four patients were asymptomatic and were not scheduled for a reintervention. In one patient the superficial femoral artery was successfully recanalized and the bypass remained occluded. Three patients were treated with thrombolytic therapy. In one patient this was successful, however a re-occlusion 4

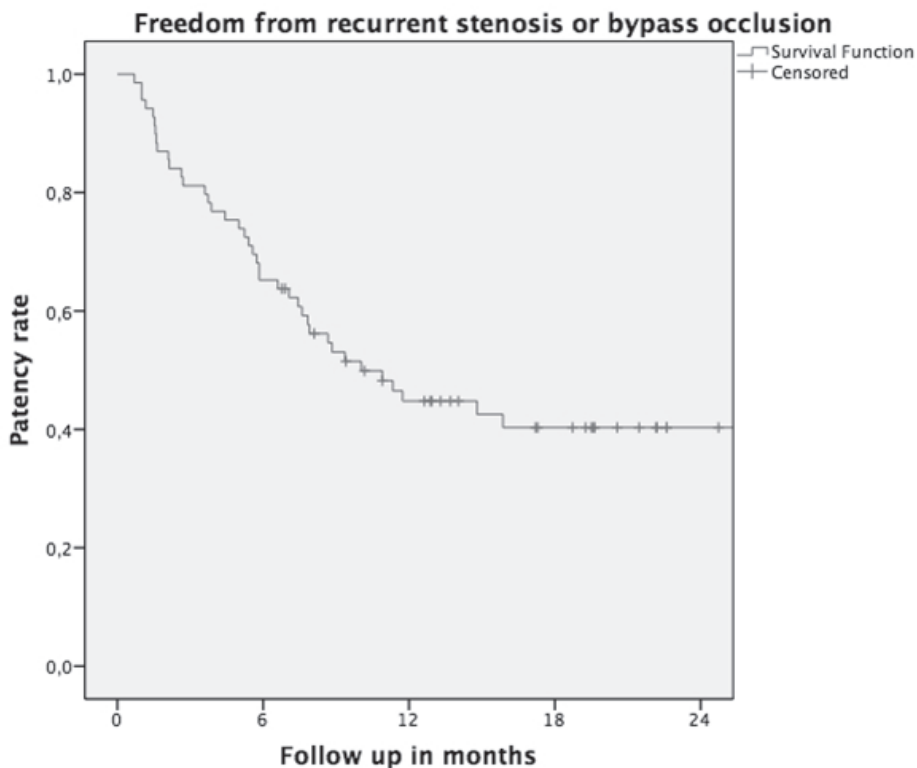


Figure 1. Freedom from recurrent stenosis or bypass occlusion.

N at risk	69	45	26	16	5
N event	0	24	37	39	39

Kaplan-Meier analysis of freedom from recurrent stenosis or bypass occlusion. The number at risk at each time interval is shown below each figure. Standard errors exceeding 10% are not shown.

months later resulted in major amputation. In two patients thrombolytic therapy was not successful and resulted in major amputation. Surgical embolectomy in one patient was unsuccessful, resulting in major amputation. Direct major amputation was performed after bypass occlusion in one patient due to poor quality of the bypass. Eight bypass occlusions occurred within 6 months after primary PTA for BAR. The conduit of nine occluded bypasses was the greater saphenous vein, of which eight non reversed. One occluded bypass was a composite arm vein bypass. Preoperative duplex ultrasounds showed diameters < 3.5 mm in 6 patients. Of the six amputations (8.7%) that were performed, five were major amputation after bypass failure. Four of those were within 6 months after bypass placement.

No significant difference in the smallest vein graft diameter at duplex ultrasound prior to bypass surgery was observed between bypasses developing recurrent stenosis or occlusion

and bypasses remaining free from recurrent stenosis or occlusions (mean 3.0 mm (range 2.1 to 4.8mm) vs. 2.9 mm (range 2.0 to 4.4mm) ($P=0.205$)). No significant difference in PSV measurements prior to primary PTA of BAR was observed between bypasses developing recurrent stenosis or occlusion and bypasses remaining free from recurrent stenosis or occlusions (mean 349 cm/s (range 177 to 600cm/s) vs. 379 cm/s (range 178 to 792cm/s) ($P=0.618$)). Bypasses with a PSV < 300 cm/s at the revision site prior to PTA had a PSV ratio > 3.0.

Primary assisted, and secondary patency rates at 1 year were 83%, and 86%, respectively. (Figures 2 and 3). A total of 12 patients (17%) died during follow-up. Five died of cardiologic causes and seven of unknown causes.

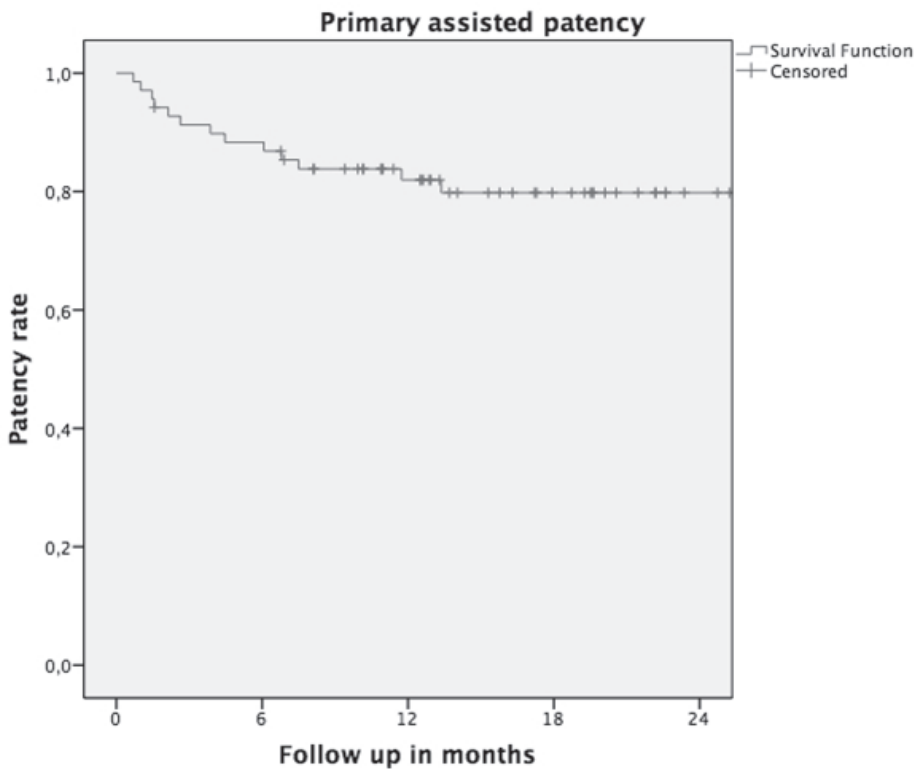


Figure 2. Primary assisted patency

N at risk	69	60	44	29	16
N event	0	8	12	13	13

Kaplan-Meier analysis of primary assisted patency. The number at risk at each time interval is shown below each figure. Standard errors exceeding 10% are not shown.

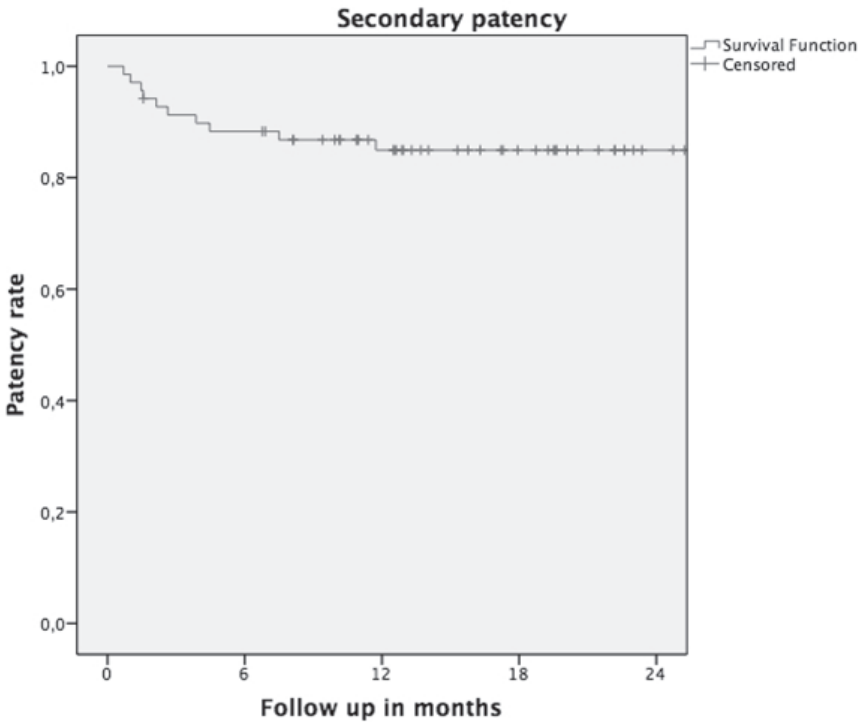


Figure 3. Secondary patency

N at risk	69	60	46	32	18
N event	0	8	10	10	10

Kaplan-Meier analysis of secondary patency. The number at risk at each time interval is shown below each figure. Standard errors exceeding 10% are not shown.

DISCUSSION

Autologous bypass grafting is still the treatment resulting in the best long-term patency rates. However, autologous bypasses may develop stenoses, which may result in bypass failure. PTA has become an established treatment in vascular surgery and is also increasingly used in the treatment of BAR, ¹⁵⁻¹⁷. We have shown that secondary interventions after PTA of a BAR are common. However, repeated interventions will result in primary-assisted and secondary patency rates of >80%. Other studies support the concept of PTA as a safe and durable treatment for BAR. A recent study assessing PTA treatment of anastomotic lesions in infrainguinal autologous and prosthetic grafts bypasses described primary assisted, and secondary patency rates of 85%, and 88%, respectively at 2 years ¹⁷. In patients with in-graft stenosis, overall assisted patency rates up to 65% at 5 years have been described ¹⁸.

The value of duplex surveillance after bypass surgery still may be questionable^{10-13, 19-22}. Randomized controlled trials and meta-analyses comparing duplex surveillance and wait-and-see follow-up showed an increase in detected significant stenosis and even an improvement in assisted patency²⁰ and secondary patency¹¹. However, an increase in freedom from amputation has not been reported¹⁹. Also, early postoperative duplex ultrasound may tend to overestimate clinical relevance of stenoses while 38% may resolve spontaneously in time²³. Remarkably in the present study, all major amputations were associated with bypass occlusion. In 8 patients bypass occlusions occurred within 6 months after primary PTA of BAR. The Kaplan-Meier curves (Figure 2 and 3) flatten after 1 year. While most events take place during first year after the initial PTA, duplex surveillance for at least 1 year after PTA of a BAR seems justified.

The great saphenous vein is considered the optimal conduit for in infrainguinal bypass grafting. A diameter of <3.5 mm or a spliced vein graft are associated with early graft failure^{24, 25}; In our series no significant difference in the smallest vein graft diameter at duplex ultrasound prior to bypass surgery was observed between bypasses developing recurrent stenosis or occlusion and bypasses remaining free from recurrent stenosis or occlusions.

Technical innovations are continuously changing the field of endovascular therapy. Drug-eluting balloons (DEBs) and drug-eluting stents are increasingly used in the treatment of peripheral arterial occlusive disease. Multiple randomized controlled trials show a reduction in late lumen loss and improved patency rates in femoropopliteal atherosclerotic lesions treated with DEBs compared with conventional PTA^{26, 27}. Stenoses in autologous bypass grafts, however, are different from atherosclerotic stenoses. Lesions in venous bypasses develop as a result of technical reasons, such as improper suturing and instrument trauma, and because of intrinsic tissue changes, including subendothelial hypertrophy, layering of intimal thrombi, fibrosis of venous valves, and atherosclerosis²⁸. The outcome of treatment of autologous bypass stenoses with DEBs may differ from the use in an arterial lesion. A recently published series of 43 patients with prosthetic or autologous infrainguinal BAR showed promising secondary patency rates at 1 year of 90%, after treatment with DEBs²⁹. Airoidi et al³⁰ described a 1-year patency of 91% in 11 patients with drug-eluting stents implanted in infrainguinal bypasses. Because of the fibrotic nature of the lesions in venous bypasses, the use of a cutting balloon may improve the technical success and patency rates. Two different studies on the use of cutting balloons in the treatment of bypass stenoses reported improvement of patency rates^{31, 32}. In the future, randomized controlled trials should be conducted to prove whether these innovative techniques can improve the patency rates of endovascular treatment of BAR.

CONCLUSIONS

Secondary interventions after PTA of a BAR are common. However, repeated secondary interventions of autologous infrainguinal BAR result in patency rates of >80% at 1 year.

AUTHOR CONTRIBUTIONS

Concept and design: HJ, BF

Analysis and interpretation: HJ, BF

Data collection: HJ, FB, WB, FA

Writing the article: HJ, BF

Critical revision: HJ, JB, FB, WB, FA, BF

Final approval: HJ, JB, FB, WB, FA, BF

Statistical analysis: HJ

Funding: not applicable

Overall responsibility: BF

REFERENCES

1. Norgren L, Hiatt WR, Dormandy JA, Nehler MR, Harris KA, Fowkes FG, et al. Inter-Society Consensus for the Management of Peripheral Arterial Disease (TASC II). *J Vasc Surg.* 2007;45 Suppl S:S5-67.
2. Klinkert P, Post PN, Breslau PJ, van Bockel JH. Saphenous vein versus PTFE for above-knee femoropopliteal bypass. A review of the literature. *Eur J Vasc Endovasc Surg.* 2004;27:357-62.
3. Londrey GL, Ramsey DE, Hodgson KJ, Barkmeier LD, Sumner DS. Infrapopliteal bypass for severe ischemia: comparison of autogenous vein, composite, and prosthetic grafts. *J Vasc Surg.* 1991;13:631-6.
4. Mills JL, Sr., Wixon CL, James DC, Devine J, Westerband A, Hughes JD. The natural history of intermediate and critical vein graft stenosis: recommendations for continued surveillance or repair. *J Vasc Surg.* 2001;33:273-8; discussion 8-80.
5. Wilson YG, Davies AH, Currie IC, Morgan M, McGrath C, Baird RN, et al. Vein graft stenosis: incidence and intervention. *Eur J Vasc Endovasc Surg.* 1996;11:164-9.
6. Buth J, Disselhoff B, Sommeling C, Stam L. Color-flow duplex criteria for grading stenosis in infrainguinal vein grafts. *J Vasc Surg.* 1991;14:716-26; discussion 26-8.
7. Idu MM, Blankenstein JD, de Gier P, Truyen E, Buth J. Impact of a color-flow duplex surveillance program on infrainguinal vein graft patency: a five-year experience. *J Vasc Surg.* 1993;17:42-52; discussion -3.
8. Efficacy of oral anticoagulants compared with aspirin after infrainguinal bypass surgery (The Dutch Bypass Oral Anticoagulants or Aspirin Study): a randomised trial. *Lancet.* 2000;355:346-51.
9. Jackson MR, Johnson WC, Williford WO, Valentine RJ, Clagett GP. The effect of anticoagulation therapy and graft selection on the ischemic consequences of femoropopliteal bypass graft occlusion: results from a multicenter randomized clinical trial. *J Vasc Surg.* 2002;35:292-8.
10. Ho GH, Moll FL, Kuipers MM, Van de Pavoordt ED, Algra A. Long-term surveillance by duplex scanning of nonrevised infragenicular graft stenosis. *Ann Vasc Surg.* 1995;9:547-53.
11. Lundell A LB, Bergqvist D, Hansen F. Femoropopliteal-crural graft patency is improved by an intensive surveillance program: a prospective randomized study. *J Vasc Surg.* 1995.
12. Mofidi R, Kelman J, Berry O, Bennett S, Murie JA, Dawson AR. Significance of the early post-operative duplex result in infrainguinal vein bypass surveillance. *Eur J Vasc Endovasc Surg.* 2007;34:327-32.
13. Golledge J, Beattie DK, Greenhalgh RM, Davies AH. Have the results of infrainguinal bypass improved with the widespread utilisation of postoperative surveillance? *Eur J Vasc Endovasc Surg.* 1996;11:388-92.
14. Rutherford RB, Baker JD, Ernst C, Johnston KW, Porter JM, Ahn S, et al. Recommended standards for reports dealing with lower extremity ischemia: revised version. *J Vasc Surg.* 1997;26:517-38.
15. Hoksbergen AW, Legemate DA, Reekers JA, Ubbink DT, Jacobs MJ. Percutaneous transluminal angioplasty of peripheral bypass stenoses. *Cardiovasc Intervent Radiol.* 1999;22:282-6.
16. Mofidi R, Flett M, Nagy J, Ross R, Griffiths GD, Chakraverty S, et al. Balloon angioplasty as the primary treatment for failing infra-inguinal vein grafts. *Eur J Vasc Endovasc Surg.* 2009;37:198-205.

17. van Oostenbrugge TJ, de Vries JP, Berger P, Vos JA, Vonken EP, Moll FL, et al. Outcome of endovascular reintervention for significant stenosis at infrainguinal bypass anastomoses. *J Vasc Surg*. 2014;60:696-701.
18. Muller-Hulsbeck S, Order BM, Jahnke T. Interventions in infrainguinal bypass grafts. *Cardiovasc Intervent Radiol*. 2006;29:17-28.
19. Davies AH, Hawdon AJ, Sydes MR, Thompson SG, Participants V. Is duplex surveillance of value after leg vein bypass grafting? Principal results of the Vein Graft Surveillance Randomised Trial (VGST). *Circulation*. 2005;112:1985-91.
20. Ihlberg L, Luther M, Alback A, Kantonen I, Lepantalo M. Does a completely accomplished duplex-based surveillance prevent vein-graft failure? *Eur J Vasc Endovasc Surg*. 1999;18:395-400.
21. Lindsay TF, Dueck AD. Is duplex surveillance of value after leg vein bypass grafting? Davies AH, Hawdon AJ, Sydes MR, Thompson SG, on behalf of the VGST participants. *circulation* 2005; 112: 1985-91. *Vasc Med*. 2006;11:137-8.
22. Healy DA, Keogh C, Bashar K, Sahebally SM, Clarke Moloney M, Walsh SR. Should patients with infrainguinal arterial bypasses using autologous vein conduit undergo follow-up surveillance with duplex ultrasound? *Int J Surg*. 2015;13:38-41.
23. Ferris BL, Mills JL, Sr., Hughes JD, Durrani T, Knox R. Is early postoperative duplex scan surveillance of leg bypass grafts clinically important? *J Vasc Surg*. 2003;37:495-500.
24. Conte MS. Technical factors in lower-extremity vein bypass surgery: how can we improve outcomes? *Semin Vasc Surg*. 2009;22:227-33.
25. Schanzer A, Hevelone N, Owens CD, Belkin M, Bandyk DF, Clowes AW, et al. Technical factors affecting autogenous vein graft failure: observations from a large multicenter trial. *J Vasc Surg*. 2007;46:1180-90; discussion 90.
26. Liistro F, Grotti S, Porto I, Angioli P, Ricci L, Ducci K, et al. Drug-eluting balloon in peripheral intervention for the superficial femoral artery: the DEBATE-SFA randomized trial (drug eluting balloon in peripheral intervention for the superficial femoral artery). *JACC Cardiovasc Interv*. 2013;6:1295-302.
27. Werk M, Albrecht T, Meyer DR, Ahmed MN, Behne A, Dietz U, et al. Paclitaxel-coated balloons reduce restenosis after femoro-popliteal angioplasty: evidence from the randomized PACIFIER trial. *Circ Cardiovasc Interv*. 2012;5:831-40.
28. Szilagyi DE, Elliott JP, Hageman JH, Smith RF, Dall'olmo CA. Biologic fate of autogenous vein implants as arterial substitutes: clinical, angiographic and histopathologic observations in femoro-popliteal operations for atherosclerosis. *Ann Surg*. 1973;178:232-46.
29. San Norberto EM, Taylor JH, Carrera S, Vaquero C. Percutaneous transluminal angioplasty with drug-eluting balloons for salvage of infrainguinal bypass grafts. *J Endovasc Ther*. 2014;21:12-21.
30. Airoldi F, Baldino G, Mortola P, Losa S, Clerici G, Tavano D, et al. Nitinol stents with polymer-free paclitaxel coating for stenosis of failing infrainguinal bypass grafts. *J Cardiovasc Surg (Torino)*. 2013;54:441-5.
31. Schneider PA, Caps MT, Nelken N. Infrainguinal vein graft stenosis: cutting balloon angioplasty as the first-line treatment of choice. *J Vasc Surg*. 2008;47:960-6; discussion 6.
32. Engelke C, Morgan RA, Belli AM. Cutting balloon percutaneous transluminal angioplasty for salvage of lower limb arterial bypass grafts: feasibility. *Radiology*. 2002;223:106-14.