

# How to Measure Mitral Annulus Size with Two-dimensional Transthoracic Echocardiography

Lotte E. de Groot - de Laat, Ben Ren, Jackie S. McGhie, Ellen J.A. Wiegers-Groeneweg, Osama I.I. Soliman, Ad J.J.C. Bogers and Marcel L. Geleijnse.

*J Heart Vasc Dis 2019;1(1):100005*

## ABSTRACT

### Aim

Dilatation of the mitral annulus (MA) is a main mechanism of mitral regurgitation (MR). Unfortunately, there is a lack of recommendations in which transthoracic two-dimensional echocardiographic view and specific time point in the cardiac cycle MA size should be measured.

### Methods

The MA was measured during different time points in the cardiac cycle in 50 subjects (40 patients with MR and 10 healthy subjects). Measurements were done in the parasternal long-axis (PSLAX) and apical 2, 3, and 4-chamber views. Validation was done against measurements of the 3D transoesophageal echocardiographic (TOE) MA area.

### Results

MA annulus dimensions were significantly different in the different views. The difference in MA dimension between control subjects and patients with mitral regurgitation was best recognized in the PSLAX view: enlargement 36.5% versus 21.3% in the 2-chamber view, 28.8% in the 3-chamber view and 26.5% in the 4-chamber view. In end-diastole the respective correlations against the 3D TOE MA area were for the 4CH, 2CH, 3CH and PS LAX views were 0.404, 0.620, 0.625 and 0.625, respectively. In end-systole these numbers were 0.595, 0.499, 0.555 and 0.559, respectively. Normal MA values in the PSLAX view were in end-systole  $28.2 \pm 3.0$  mm and in end-diastole  $25.5 \pm 2.8$  mm.

### Conclusion

MA measurement with 2D-echocardiography should be done in the PSLAX view at a fixed time point in the cardiac cycle. Because of the functional component of the MA the end-systolic time-point may be preferred with an upper limit of normal of 35mm.

## INTRODUCTION

The mitral annulus (MA) is an anatomically well-defined D-shaped fibrous structure<sup>1,2</sup>. It is a vital component of the mitral valve apparatus<sup>3</sup> and dilatation of the MA is one of the main mechanisms of mitral regurgitation (MR)<sup>4</sup>. Because the MA is not circular in shape<sup>1,3</sup>, dilates in an asymmetric manner<sup>5</sup> and is dynamic in the cardiac cycle<sup>6</sup>, it seems essential to define the transthoracic echocardiographic cross-sections and the specific time point in the cardiac cycle at which the MA diameter should be measured. However, in most echocardiographic textbooks there is no recommendation where to measure the MA diameter<sup>7,8</sup>. Alternatively, it is recommended to use the apical 4-chamber view<sup>9</sup>, although it is well known that this view does not represent the true major or minor axis of the MA<sup>10-12</sup> and may be more prone to variation in acquisition, or the parasternal long-axis view<sup>13</sup>. Intriguingly, also in none of the echocardiographic textbooks a recommendation is given at which specific time point in the cardiac cycle the MA diameter should be routinely measured. This is a potentially important issue because the normal MA is a dynamic structure with a continuously changing area during the cardiac cycle<sup>6</sup>. This study sought to establish which transthoracic two-dimensional echocardiographic view and specific time point in the cardiac cycle are the most reproducible in terms of inter-observer variability, accurate compared to a gold standard and representative for dilatation direction of the MA diameter.

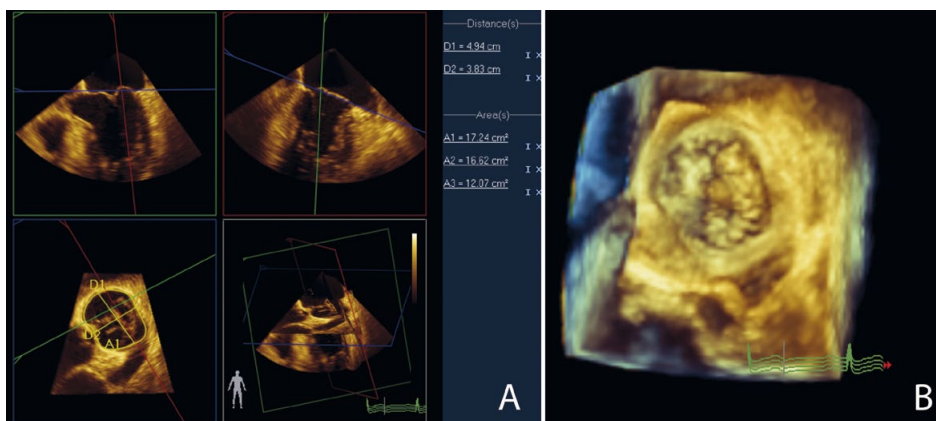
## METHODS

Fifty subjects (28 men, mean age  $61 \pm 12$  years) were analysed: 40 consecutive patients (23 men, mean age  $63 \pm 11$  years) with moderate or severe MR, and 10 healthy subjects (5 men, mean age  $51 \pm 9$  years). Healthy subjects were recruited from our department (personnel), or were family members or friends of the authors. All had normal left atrial and left ventricular (LV) dimensions, normal systolic and diastolic LV function, and no valvular abnormalities. None of these healthy subjects used cardiovascular medications, and all had a normal 12-lead electrocardiogram. Normal values of the 3D MA area were assessed in 10 subjects referred for analysis of a cardiac source of embolus but with normal cardiac findings (4 men, mean age  $49 \pm 14$  years) with optimal 2D and 3D quality images. All echocardiograms in these subjects were made by one single, highly experienced sonographer (JMG). In the standard parasternal long-axis (PSLAX) and apical 2, 3, and 4-chamber views one physician (LGL) assessed the overall image quality defining it as good (quality score 1), moderate (quality score 2) or poor (quality score 3). Good image quality was defined as a clear definition of both sides of MA attachment / hinge points on a moving image in the whole cycle. Moderate image quality was defined when one of both sides of MA attachment / hinge points on the moving image was less visible in a part of

the cycle. Poor image quality was defined when one or both sides of the MA attachment / hinge points on a moving image were not visible in a part of cycle. The presence of MA calcification was noted. To study MA dynamics, the MA diameter was measured at six different time points in the cardiac cycle: early systole (ES) the frame after MV closure, late or end systole (LS) the frame before MV opening, mid systole (MS) midway between ES and LS, early diastole (ED) the frame after MV opening, late or end diastole (LD) the frame before mitral valve closure and mid diastole (MD) midway between ED and LD. Subsequently, a second physician (BR) also scored the overall image quality, the presence of MA calcification, and the MA diameter from the identical images (frames).

### Validation of the 2D MA measurements with 3D echocardiography

In the 3D MA validation study, 30 of the 40 subjects (17 men, mean age  $63 \pm 11$  years) with moderate or severe MR and same-day adequate three-dimensional (3D) transoesophageal echocardiographic (TOE) images of the mitral annulus available, and 10 subjects (4 men, mean age  $49 \pm 14$  years) that underwent two-dimensional (2D) and 3D transthoracic echocardiography (TTE) and TOE because of analysis of source of emboli with normal findings were included. To validate the 2D mitral annular measurements, the end-diastolic and end-systolic frames were correlated to 3D mitral annular areas (Figure 1).



**Figure 1.** Measurements of the mitral annular area and major and minor dimension from 3D TOE in end-systolic frame. The 3D dataset (B) is displayed as three orthogonal images of the mitral annulus (A). The blue plane shows the “en face” view of the mitral annulus in which the inner border of the cross-sectional area was traced manually.

Three-dimensional TOE imaging was performed using the iE33 ultrasound system with the X7-2t matrix-array transducer. Electrocardiographically gated full-volume data sets were acquired at the midesophageal level during breath-hold with the ultrasound focus on the MV in the four-chamber view. Care was taken to include the complete mitral annular circumferences throughout the acquisition. Each full-volume data set was digitally stored

and exported to QLAB 9.0 3DQ software (Philips Medical Systems) for offline analysis. The “en face” views of the MA was revealed at time points during the cardiac cycle similar as for the 2D TTE measurements. Subsequently, the major-axis and minor-axis diameters of the MA were measured.

### **Normal MA values**

After definition of the optimal MA measurement normal values were established in 50 healthy subjects (26 men, mean age  $49 \pm 12$  years). Also, these healthy subjects had normal left atrial and LV dimensions, normal systolic and diastolic LV function, and no valvular abnormalities.

### **Statistical Analysis**

Categorical data are presented as numbers and percentages. Normality of continuous variables was evaluated by Shapiro-Wilk tests, and data were then presented as mean  $\pm$  standard deviation (SD) or median and interquartile range (IQR) in case of a significant test.

Interobserver variability was defined as the absolute difference between measurements divided by the mean. To compare this interobserver variability between two different echocardiographic views paired Student-T tests or, if the distribution was not normal, Wilcoxon signed-rank test was used. We compared also the MA dimension in these views by the same tests. The mean values of the MA dimension in MR patients were compared with healthy controls by unpaired Student-T tests. Correlations between the 2D annular measurement and the 3D mitral annular areas were performed using the Pearson correlation test.

All statistical tests were two-sided and a p-value  $<0.05$  was considered statistically significant. Analyses were performed using SPSS version 21.0.0.1 (SPSS, IBM, Armonk, NY).

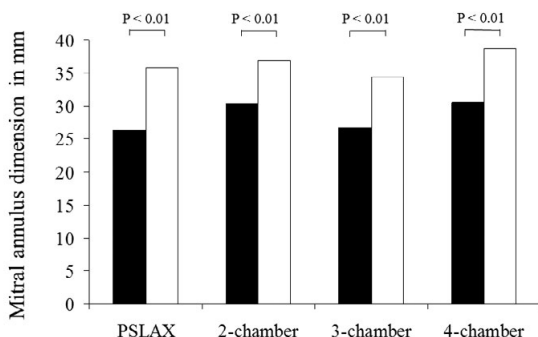
## **RESULTS**

### **MA dimensions in the different views**

Average (all time points) values of the MA annulus in the 4 different cross sections in the 50 subjects were  $34.0 \pm 6.2$  mm in the PSLAX,  $35.7 \pm 6.5$  mm in the 2-chamber view,  $32.9 \pm 6.2$  mm in the 3-chamber view and  $37.0 \pm 6.6$  mm in the 4-chamber view. All MA annulus dimensions were significantly different ( $P < 0.001$ ).

### Differences in MA dimensions in normal subjects and mitral regurgitation patients

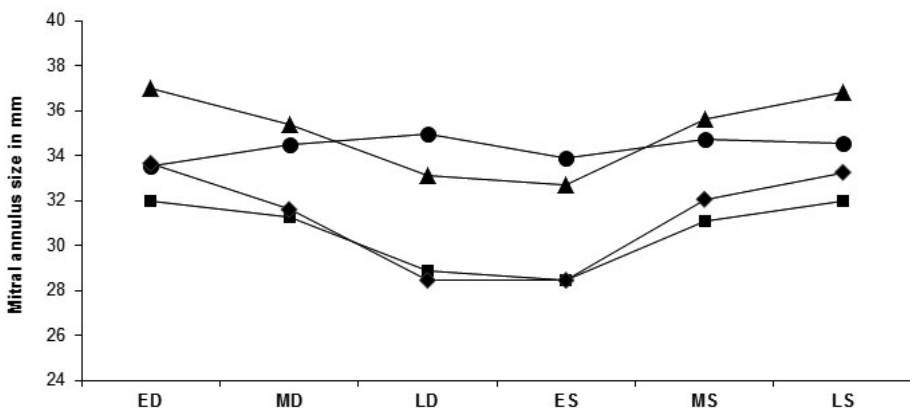
As seen in Figure 2, in all views the MA was larger in patients with mitral regurgitation compared to control subjects. The difference in MA dimension between control subjects and patients with mitral regurgitation was best recognized in the PSLAX view: enlargement 36.5% versus 21.3% in the 2-chamber view, 28.8% in the 3-chamber view and 26.5% in the 4-chamber view.



**Figure 2.** Measurements of mitral annular dimension in patients with mitral regurgitation (white bars) and control subjects (black bars).

### MA dimensions during the cardiac cycle

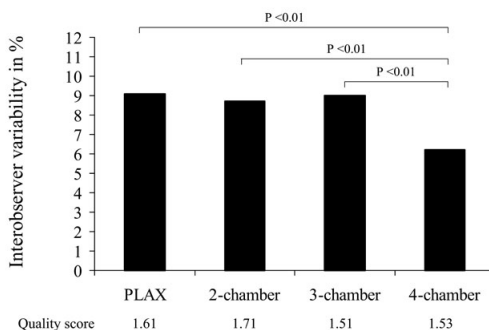
As seen in Figure 3, the MA showed in the PSLAX and apical 3 and 4 chamber views a progressive decrease in size during diastole and a progressive increase in size during systole, whereas changes in size in the apical 2-chamber view were not significant.



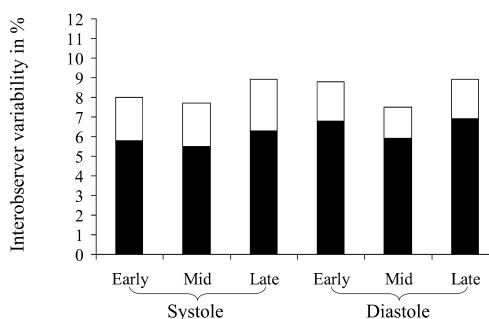
**Figure 3.** Measurements of mitral annular dimension in 6 phases of the cardiac cycle: early, mid and late diastole (ED, MD, and LD) and systole (ES, MS, LS) in the parasternal long-axis (diamonds) and three apical views: 2-chamber view (dots), 3-chamber view (squares), and 4-chamber view (triangles).

## Interobserver variability in MA measurements

As seen in Figure 4, when considering all available views the apical 4-chamber view showed the best inter-observer variability in MA dimensions (6.2% vs. 9.1% for the PSLAX view, 8.7% for the apical 2-chamber view, and 9.0% for the apical 3-chamber view). As seen in Figure 5, there were no significant differences in inter-observer variability between the different time points in the cardiac cycle. This was true when all views were taken together but also for the view with the best inter-observer variability, the apical 4-chamber view.



**Figure 4.** Interobserver variability of mitral annular measurements in the parasternal long-axis (PLAX), apical 2-chamber, apical 3-chamber, and apical 4-chamber views. Image quality score: 1 = good, 2 = moderate, 3 = poor.



**Figure 5.** Interobserver variability of mitral annular measurements in the different time points in the cardiac cycle (white bars: average of all views, black bars: apical 4-chamber view).

## Validation of the 2D MA measurements with 3D echocardiography

In end-diastole the respective correlations of the 2D annular measurement with the 3D mitral annular areas for the 4CH, 2CH, 3CH and PSLAX views were 0.404, 0.620, 0.625 and 0.625. In end-systole these numbers were 0.595, 0.499, 0.555 and 0.559, respectively.

## Normal MA values

Normal MA values in the PSLAX view were in end-systole  $28.2 \pm 3.0$  mm and in end-diastole  $25.5 \pm 2.8$  mm.

## DISCUSSION

According to Carpentier *et al.*<sup>4</sup> dilatation of the MA is one of the main mechanisms of MR. Because the MA is not circular in shape<sup>1,2</sup>, is dynamic in the cardiac cycle<sup>6</sup> and dilates asymmetrically<sup>5</sup>, it seems essential to define the transthoracic echocardiographic cross-sections and the specific time point in the cardiac cycle at which the MA diameter should be measured. The main finding of this study is that in the PSLAX view enlargement of the MA is best identified and correlation to the 3D MA area is also optimal whereas the specific measurement time point in the cardiac cycle seems less relevant.

It is well known that the MA is not circular but oval in shape<sup>1,2,12</sup>. In our study different values were consequently seen in the different views. Surprisingly, in the 4-chamber view the largest values were measured. The MA in this particular view is, however, variably in between the shortest (best identified in the PSLAX view) and largest (best identified in the 2-chamber view) axes of the oval MA<sup>12</sup>. The actual measurement can thus only be explained by a mistake in measurement in this view (which seems unlikely since this measurement showed actually the best inter-observer variability) or a structural MA underestimation in the 2-chamber view. Indeed, when the 2D 2-chamber measurements were compared to the major-axis of the 3D annulus a bias of -12mm was found (in contrast the 2D 3-chamber measurements showed compared to the minor-axis of the 3D annulus only a bias of -1mm).

Some have claimed that the MA dilates mostly in the anterior-posterior direction<sup>5</sup> and in one study control subjects could be differentiated from patients with functional mitral regurgitation in all cross-sections apart from the so-called “intervalley” distance, equaling the diameter in the 2-chamber view<sup>14</sup>. Indeed in our study in the PSLAX view (best representing the anterior-posterior direction) the greatest MA enlargement in patients versus control subjects was seen. Providing further arguments to measure the MA in the PSLAX view.

As seen in this study and described by others, the MA is a dynamic structure changing in size during the cardiac cycle, in particular in the non-commissural (2-chamber) views<sup>6,15</sup>. Although discrepant findings have been reported, the progressive increase in MA size during systole described in our study was also seen in studies by others<sup>6,15</sup>. In our study there were no differences in inter-observer variability between any of the six time points during the cardiac cycle. The most commonly used end-diastolic and end-systolic time-points seems most attractive because of their clear, uniform definitions. In our opinions the end-systolic time-point has the additional advantage that it intuitively seems very attractive



from a functional point of view combining information of both MA size and function (which is very important during mitral regurgitation) we therefore suggest to use the end-systolic MA diameter from the PSLAX view as the preferred one. Based on our normal values the upper limit of normal of the PSLAX end-systolic MA diameter is 35mm.

### **Limitations**

Our study concentrated on real-world measurements of the MA with 2D echocardiography. 3D-echocardiography clearly offers a better, “en-face” view of the MA <sup>1,2,12</sup> and may be the optimal way of measuring the MA, not only providing representative dimensions but also a circumference or area rather than a dimension with unknown exact representation. However, in daily routine practice and certainly the initial assessment is virtually always done with 2D echocardiography.

### **CONCLUSIONS**

MA measurement with 2D-echocardiography should be done in the PSLAX view at a fixed time point in the cardiac cycle. Because of the functional component of the MA the end-systolic time-point may be preferred with an upper limit of normal of 35mm.

## REFERENCES

1. Anwar AM, Soliman OI, ten Cate FJ, et al. True mitral annulus diameter is underestimated by two-dimensional echocardiography as evidenced by real-time three-dimensional echocardiography and magnetic resonance imaging. *Int J Cardiovasc Imaging* 2007;23:541-7.
2. Anwar AM, Soliman OI, Nemes A, et al. Assessment of mitral annulus size and function by real-time 3-dimensional echocardiography in cardiomyopathy: comparison with magnetic resonance imaging. *J Am Soc Echocardiogr* 2007;20:941-8.
3. Van Mieghem NM, Piazza N, Anderson RH, et al. Anatomy of the mitral valvular complex and its implications for transcatheter interventions for mitral regurgitation. *J Am Coll Cardiol* 2010;56:617-26.
4. Carpentier A. Cardiac valve surgery--the "French correction". *J Thorac Cardiovasc Surg* 1983;86:323-37.
5. He Z, Bhattacharya S. Mitral valve annulus tension and the mechanism of annular dilation: an in-vitro study. *J Heart Valve Dis* 2010;19:701-7.
6. Grewal J, Suri R, Mankad S, et al. Mitral annular dynamics in myxomatous valve disease: new insights with real-time 3-dimensional echocardiography. *Circulation* 2010;121:1423-31.
7. Oh JK, Seward, J.B., Tajik, A.J. The echo manual. 3rd ed: Lippincott Williams & Wilkins; 2006:211.
8. Galiuto L. BL, Fox K., Sicari R., Zamorano J.L. In: Galiuto L. BL, Fox K., Sicari R., Zamorano J.L., ed. *The EAE Textbook of Echocardiography*: Oxford; 2011:38-9.
9. Otto CM. *Textbook of clinical echocardiography*. 4th ed: Saunders Elsevier; 2009:35-60.
10. Anwar AM, Attia WM, Nosir YF, et al. Validation of a new score for the assessment of mitral stenosis using real-time three-dimensional echocardiography. *J Am Soc Echocardiogr* 2010;23:13-22.
11. Foster GP, Dunn AK, Abraham S, Ahmadi N, Sarraf G. Accurate measurement of mitral annular dimensions by echocardiography: importance of correctly aligned imaging planes and anatomic landmarks. *J Am Soc Echocardiogr* 2009;22:458-63.
12. Ren B, De Groot - de Laat LE, McGhie JS, Vletter WB, Ten Cate FJ, Geleijnse ML. Geometric errors of the pulsed wave doppler flow method in quantifying degenerative mitral valve regurgitation: a three-dimensional echocardiography study. *J Am Soc Echocardiogr* in press.
13. Lancellotti P, Moura L, Pierard LA, et al. European Association of Echocardiography recommendations for the assessment of valvular regurgitation. Part 2: mitral and tricuspid regurgitation (native valve disease). *Eur J Echocardiogr* 2010;11:307-32.
14. Kaplan SR, Bashein G, Sheehan FH, et al. Three-dimensional echocardiographic assessment of annular shape changes in the normal and regurgitant mitral valve. *Am Heart J* 2000;139:378-87.
15. Kwan J, Jeon MJ, Kim DH, Park KS, Lee WH. Does the mitral annulus shrink or enlarge during systole? A real-time 3D echocardiography study. *J Korean Med Sci* 2009;24:203-8.