

# Dynamics of Endo- and Epicardial Focal Fibrillation Waves at the Right Atrium in a Patient with Advanced Atrial Remodelling

Lisette van der Does

Charles Kik

Ad Bogers

Maurits Allessie

Natasja de Groot

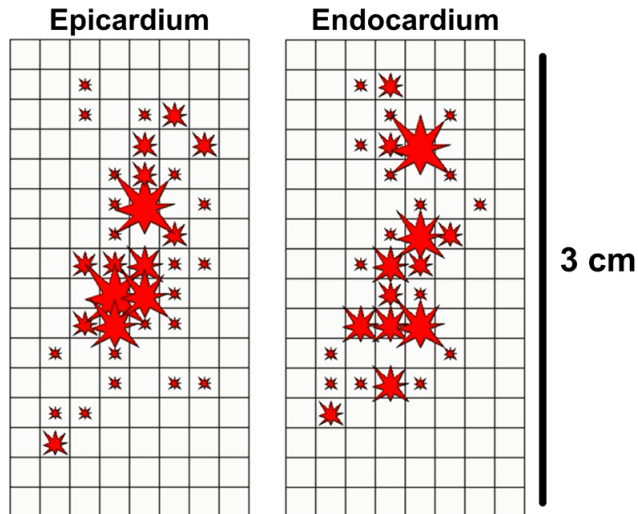
## ABSTRACT

Focal waves appear frequently at the epicardium during persistent atrial fibrillation (AF), however, the origin of these waves is under debate. We performed simultaneous endo-epicardial mapping of the right atrial wall during longstanding persistent AF in a patient undergoing cardiac surgery. During 10 seconds 53 and 59 focal waves appeared at random at respectively the endocardium and epicardium. Repetitive focal activity did not last longer than 3 cycles. Transmural asynchrony and conduction might be the origin of focal waves. Asynchronous propagation of fibrillation waves in three dimensions would stabilize the arrhythmia and could explain the limited success of persistent AF ablation.

Persistent atrial fibrillation (AF) is associated with the frequent occurrence of epicardial fibrillation waves presenting focally which may represent important drivers for the perpetuation of AF. These focal waves appear mainly as single events widely spread over the epicardial surface without any clear preferential site.<sup>1</sup> However, not much is known about the occurrence of focal waves at the endocardial side and the interplay between both sides. This could provide more insights into the origin of focal fibrillation waves. In this report we demonstrate the dynamics of focal fibrillation waves at the epicardium and endocardium simultaneously in a patient with longstanding persistent AF.

A 63-year-old female patient underwent mitral and tricuspid valve surgery due to rheumatic mitral valve disease with severe insufficiency. A preoperative echocardiogram showed a mildly reduced left ventricular function and an enlarged left atrium. AF had been persistent for 1.5 years and was medically treated with digoxin and verapamil. Before surgery, the patient gave informed consent for a mapping study approved by the local ethics committee. Before the start of cardiopulmonary bypass, the endo- and epicardial side of the right atrial free wall were simultaneously mapped during longstanding persistent AF. Mapping was performed with two 8x16 electrode arrays (2 mm interelectrode distance) positioned precisely opposite to each other in a clamp, and inserted in the right atrium through the incision for the venous cannula. Ten-second recordings of the endo- and epicardium were analyzed with custom-made software for focal fibrillation waves that appear within the mapping area as previously described in detail.<sup>1,2</sup> Figure 1 shows the appearance of focal fibrillation waves at the endocardium and epicardium during 10 seconds of longstanding persistent AF. Each star represents an emerging focal wave and the star size increases each time another focal wave presents at the same location. Focal waves appear equally frequent at the endocardium and the epicardium (53 vs 59). Mostly, they appear at random either on one side, or at different locations on both sides. A few appear at the same time and location on the epicardial and endocardial side. Repetitive focal

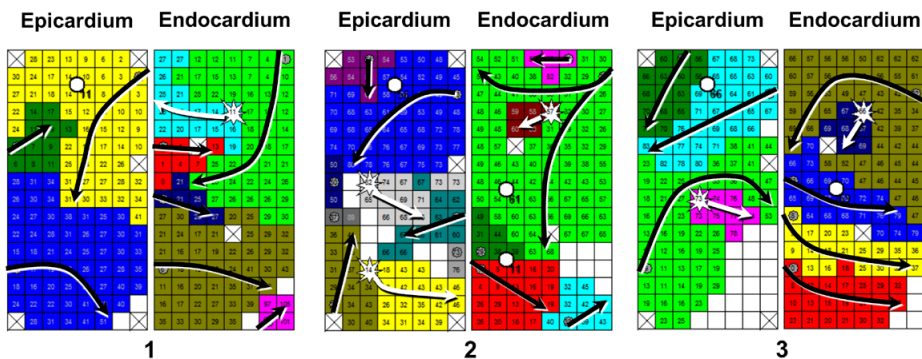
## 112 Endo-Epicardial Focal Waves in 10 seconds



**Figure 1.** Focal fibrillation waves during 10 seconds of atrial fibrillation. Summary of the 112 focal fibrillation waves (red stars) that occurred during 10 seconds of longstanding persistent atrial fibrillation at the endocardium and epicardium. The size of the star is proportional to the number of focal waves that appeared (size increases with each focal wave).

activation at a single location is seen at most for only 3 cycles with a variable cycle length. Rotor activity was not responsible for these repetitive focal waves as shown in Figure 2.

Several mechanisms for focal waves have been proposed such as re-entry, rotors, ectopic foci and endo-epicardial breakthrough.<sup>1,3</sup> The random appearance of focal waves pleads against stable ectopic foci or fixed rotors being the source for focal fibrillation waves in this example. Furthermore, most focal waves appear as single events on only one side instead of both sides, which translates either to an ectopic focus/ re-entry or rotor with transmural conduction block or transmural conduction of an opposite traveling wave. Both explanations suggest the occurrence of dissociative endo-epicardial conduction. Previously, a correlation was demonstrated between the anatomy of the right atrial appendage with the pectinate muscles and endo-epicardial conduction delay and epicardial focal waves.<sup>4,5</sup> The distinctive architecture of the right atrial appendage may be an important contributor to the occurrence of endo-epicardial breakthroughs, though, perhaps not always in the way of stable intramural re-entry circuits acting as drivers.<sup>5</sup> Theoretically, if random endo-epicardial breakthroughs indeed occur this frequently in longstanding persistent AF, it might offer an explanation why therapies for persistent AF are not always effective even after the elimination of AF drivers. After all, a 3-dimensional source for new fibrillation waves would highly stabilize the process of AF.



**Figure 2.** Three repetitive focal waves.

Three repetitive focal waves (white star) on the endocardial side demonstrated in 3 consecutive wave maps. Different colors illustrate the different fibrillation waves. Activation times are depicted in each electrode and are in respect to the first activated electrode ( $T=0$ ). White circles refer to the site from where transmural conduction could theoretically be responsible for the opposite focal wave. Rotor activity was not the cause of the only repetitive focal activity that was observed in this patient. This is mostly clearly demonstrated in the second and third set of maps where the focal wave appears much later than the surrounding tissue with only limited conduction.

A mitral valve and tricuspid valve repair was performed in combination with cryoablation of the right and left atrium following a Cox-Maze III pattern. The patient developed episodes of postoperative AF with spontaneous conversions to sinus rhythm. During the last days before discharge there were no more AF episodes.

## REFERENCES

1. de Groot NMS, Houben RPM, Smeets JL, Boersma E, Schotten U, Schalij MJ, Crijns H, Allessie MA. Electropathological substrate of longstanding persistent atrial fibrillation in patients with structural heart disease: epicardial breakthrough. *Circulation*. 2010;122:1674-82.
2. Allessie MA, de Groot NM, Houben RP, Schotten U, Boersma E, Smeets JL, Crijns HJ. Electropathological substrate of long-standing persistent atrial fibrillation in patients with structural heart disease: longitudinal dissociation. *Circ Arrhythm Electrophysiol*. 2010;3:606-15.
3. Baykaner T, Lalani GG, Schricker A, Krummen DE, Narayan SM. Mapping and ablating stable sources for atrial fibrillation: summary of the literature on Focal Impulse and Rotor Modulation (FIRM). *J Interv Card Electrophysiol*. 2014;40:237-44.
4. Gray RA, Pertsov AM, Jalife J. Incomplete reentry and epicardial breakthrough patterns during atrial fibrillation in the sheep heart. *Circulation*. 1996;94:2649-61
5. Hansen BJ, Zhao J, Csepe TA, Moore BT, Li N, Jayne LA, Kalyanasundaram A, Lim P, Bratasz A, Powell KA, Simonetti OP, Higgins RS, Kilic A, Mohler PJ, Janssen PM, Weiss R, Hummel JD, Fedorov VV. Atrial fibrillation driven by micro-anatomic intramural re-entry revealed by simultaneous sub-epicardial and sub-endocardial optical mapping in explanted human hearts. *European Heart J*. 2015;36:2390-2401.