

Annals of Surgery

Issue: Volume 225(4), April 1997, pp 365-369

Copyright: © Lippincott-Raven Publishers.

Publication Type: [Advances in Surgical Technique]

ISSN: 0003-4932

Accession: 00000658-199704000-00004

[Advances in Surgical Technique]

The Low Transverse Pfannenstiel Incision and the Prevalence of Incisional Hernia and Nerve Entrapment

Luijendijk, Roland W. M.D.*; Jeekel, Johannes M.D., Ph.D.†; Storm, Remmert K. M.D.†; Schutte, Pieter J. M.D.†; Hop, Wim C.J. Ph.D.‡; Drogendijk, Arie C. M.D., Ph.D.§; Huikeshoven, Frans J.M. M.D., Ph.D.§

Author Information

From the Department of General Surgery,* Leyenburg Hospital, The Hague, The Netherlands; the Departments of General Surgery† and Obstetrics and Gynecology,§ University Hospital Rotterdam - Dijkzigt, The Netherlands; and the Department of Epidemiology and Biostatistics,‡ Medical School, Erasmus University, Rotterdam, The Netherlands

Address reprint requests to Johannes Jeekel, M.D., Department of General Surgery, University Hospital Rotterdam -Dijkzigt, The Netherlands.

Accepted for publication September 18, 1996.

Abstract

Objective: The authors determined the prevalence of incisional hernia and nerve entrapment in patients with a low transverse Pfannenstiel incision.

Summary Background Data: The literature on the Pfannenstiel incision suggests an incisional hernia rate of 0.0% to 0.5%. However, in these series, physical examination, which is essential in the authors' view, was not performed. To the authors' knowledge, the prevalence of nerve entrapment after the Pfannenstiel incision is not known or has never been published.

Methods: All adult women, operated on between 1986 and 1992 using a Pfannenstiel incision and not having had another lower abdominal incision other than for laparoscopy, were invited for follow-up at the outpatient department. All patients were interviewed and subjected to a physical examination, with special interest to the presence of incisional hernia or nerve entrapment.

Results: In patients having had a Pfannenstiel incision, no incisional hernias were found. In patients also having had a laparoscopy, the incisional hernia rate was 3.5%. Nerve entrapment was found in 3.7%. The length of the incision was identified as a risk factor ($p = 0.02$).

Conclusions: Incisional hernia is a rare complication of the Pfannenstiel incision. Complications of nerve damage, however, are not uncommon and should be recognized. When possible, nerves should be identified and preserved, especially when extending the incision more laterally.

Incisional hernias occur in at least 10% of patients with midline laparotomies.¹ Patients with an incisional hernia often report an aesthetic appearance or suffer from discomfort, pain, or, occasionally, intestinal obstruction.² Moreover, after first incisional hernia repair, recurrence rates up to 53% have been described.³ Therefore, preventing an incisional hernia is mandatory, and surgical methods should be developed and used to lower the incidence of incisional hernias.

In 1900, Hermann Johannes Pfannenstiel (1862-1909) described a low transverse abdominal incision to prevent incisional hernia.^{4,5} The incision that bears his name is the incision of choice for a variety of gynecologic operations.⁶⁻¹⁰ An aesthetically more pleasing "bikini-line" scar^{5,6,8,11,12} and less postoperative complications^{5-8,13} are mentioned as additional advantages of this technique. Nerve entrapment, however, can be a disadvantage.¹⁴⁻¹⁸ In general surgery, a midline incision generally is used.

In this study, we evaluate the prevalence of incisional hernia and nerve entrapment after the Pfannenstiel incision in a large series.

PATIENTS AND METHODS

All adult women, operated on between 1986 and 1992 using a Pfannenstiel incision (Department of Gynecology, University Hospital Rotterdam) and not having had another lower abdominal incision other than for laparoscopy, were invited for follow-up at the outpatient department. The following data were noted: date of birth, date of operation, height, weight, presence of cough or constipation or both, incision length, postoperative complications (wound-infection, hematoma), postoperative pregnancy, postoperative pain (localization, period, radiation, triggering, character), and numbness. Thereafter, the scar and the lower midline of the abdomen were examined for the presence of an incisional hernia, which was defined as any palpable fascial defect of the abdominal wall. Investigation included palpation of the area while the patient raised the extended legs in the supine position.

Furthermore, patients were asked about reports of pain, with special reference to signs of entrapment of the ilioinguinal (I-I) or iliohypogastric (I-H) nerve or both. These signs are an activity-induced sharp pain, felt around the incision site or a deeper abdominal region, which radiates to the labium or the medial parts of the thigh or both, later followed by a continuous burning pain in the same region.¹⁴⁻¹⁸ In this study, entrapment was defined when such reports still were present more than 5 weeks after surgery or when reports started after a pain-free period. If pain was localized at the scar site and clearly was triggered by touch or pressure, the pain was attributed to a neuroma.

The Pfannenstiel incision was made 2 to 3 cm above the symphysis pubis at the border of the pubic hair. The incision, 8- to 12-cm long, extended through skin, subcutaneous fat, and rectus sheath and laterally through the fasciae of the internal and external oblique and transversus muscles. Thereafter, the anterior fascia and linea alba were separated from the underlying rectus and pyramidalis muscles, from symphysis to umbilicus. Then, the muscles were separated in the midline (dividing the fascia transversalis, and, cranially from the arcuate line, the posterior rectus fascia), and finally also the peritoneum was divided. The incision was closed in layers (Vicryl, polyglactin 910, Ethicon, Somerville, NJ), the peritoneum with a continuous suture, the rectus muscles, when appropriate, with one to three interrupted approximating sutures. The transversely incised fascia was closed with one continuous suture. The technique of closure of the skin varied with the surgeons' preference.

For statistical analysis, comparison of percentages was done with Fisher's exact test. Medians were compared with the Mann-Whitney *U* test. A *p* value (two-sided) of 0.05 was considered the limit of significance.

RESULTS

A total of 346 patients were invited to participate, of whom 300 (87%) were willing to visit the outpatient clinic. Reasons not to participate included having to go to work ($n = 15$), not having any reported problems about the scar ($n = 10$), distance to the hospital ($n = 10$), reported problems about waiting times ($n = 8$), and simple lack of interest ($n = 3$). Another 28 patients, initially willing to participate, did not show up without explanation. Of the 272 patients examined, 29 patients did not meet inclusion criteria, leaving 243 patients for evaluation.

The mean age was 35 years (range, 16 to 57 years). The mean postoperative follow-up was 60 months (range, 19 to 94 months). Five patients (2.1%) had an incisional hernia. In all cases, a palpable fascial defect of approximately 1 cm² was located in the midline, just caudal to the umbilicus. For none of these patients had the hernia been the cause of any reported problems. In one patient, a bulge on the abdomen was visible on examination. The Quetelet-index ($\text{weight}[\text{kg}]/\text{length}[\text{m}]^2$), cough, constipation, postoperative infection, hematoma, and pregnancy could not be identified as risk factors.

Of the women who were examined, 146 ($146/235 = 62\%$, 8 missing data) had had a laparoscopic procedure performed through an extraumbilical incision. All patients presenting with an incisional hernia had a history of laparoscopy. Consequently, 5 (3.5%) of 146 of the women with a previous laparoscopy were found to have an incisional hernia, whereas no incisional hernias were found in women without previous laparoscopic investigation ($p = 0.08$).

Long-term reported problems of pain were experienced by 57 (23%) of 243 of the patients. In 9 patients ($9/243 = 3.7\%$), these reported problems could be attributed to entrapment of the I-I or I-H nerve or both, and in 5 patients ($5/243 = 2.1\%$), these reported problems could be attributed to a neuroma. In 61 patients ($61/243 = 25.1\%$), reported problems of numbness were present. Two patients had reported a neuroma as well as numbness. Four patients had reported nerve entrapment as well as numbness. The length of the incision could be identified as a risk factor for nerve entrapment ($p = 0.02$), but did not correlate with neuroma ($p = 0.99$) or numbness ($p = 0.60$).

DISCUSSION

Incisional Hernia

In this series, the Pfannenstiel laparotomy (in patients with or without laparoscopy) has an incisional hernia rate of 2.1%. Compared to midline laparotomy hernia percentages reported in literature, of up to 46%,^{1,3,19} this rate is low. Obviously, in the current study, the distribution of age, gender, and disease is quite different from most studies on midline incisions. Therefore, conclusions from this study must be interpreted with care. With respect to incisional hernia, however, we think that the difference is striking. Other series on the Pfannenstiel incision also suggest a low prevalence, with incisional hernia rates from 0.0% to 0.5%,^{4,6,8,20} but in these series, no physical examination was performed.

All incisional hernias were found just caudal to the umbilicus. In the Pfannenstiel incision, the anterior rectus fascia and linea alba are separated from the underlying muscles up to the umbilicus, and so the rectus fascia may be damaged at the umbilical level. However, because all the patients with an incisional hernia also had had laparoscopy, whereas no hernias were found in 169 patients with no laparoscopy, the hernias may very well be the result of laparoscopy. When an incision of approximately 1.5 cm is made for laparoscopy and only the skin is sutured, the chances of developing an incisional hernia increase significantly.²¹ Still, without suturing the fascia, incisional hernia is a rare complication in literature (0.01% to 0.17%).²¹⁻²³ In our series, in patients having had a Pfannenstiel incision as well as laparoscopy, the hernia rate is 3.5%. Because several cases of incarceration of incisional hernias have been reported as a complication of laparoscopy,²²⁻²⁵ we subscribe to the advice to close the fascia.

Various factors may contribute to the fact that the Pfannenstiel incision performs better with respect to occurrence of incisional hernias. First and most obvious, in the Pfannenstiel incision, the skin, subcutaneous tissue, and fascial defect are remote from the muscle defect, which is covered by healthy nonincised tissue, whereas in the low midline incision, all layers are incised in one plane, making, for instance, contamination more easy. Second, the linea alba, into which the oblique muscles insert, is not incised with the Pfannenstiel incision. Strong contractions of these muscles are necessary during coughing, vomiting, and defecation.¹² Moreover, the linea alba has the poorest blood supply of any area in the abdominal wall, and this may contribute to deficient healing.¹² Third, use of the Pfannenstiel incision obeys all principles regarding atraumatic surgery without tension. The skin incision is along Langer's lines, resulting in reduced traction at the skin edges. The division of the external oblique aponeurosis is parallel to its fibers, along the lines of tension.^{5,26} The force required to approximate the edges of a vertical incision is approximately 30 times greater than the force required to approximate a transverse incision.^{12,26} Fourth, damage to nerve supply and venous and lymphatic drainage may differ and may thereby also influence wound healing.¹²

Therefore, to prevent incisional hernias, we might have to consider the use of a transverse skin and anterior fascia incision combined with a vertical muscle incision in other parts of the abdomen as well.

Nerve Entrapment

The essential nerves of the groin are the I-H, I-I, and genitofemoral (G-F) nerves (Fig. 1). Communication between their branches and overlap in sensory innervation is common.¹⁵ The I-H and the I-I nerves run an inferomedial course within the internal and external oblique muscles and travel through the inguinal canal.¹⁶ The medially running I-H nerve supplies the skin of the overlying pubis (Fig. 2).^{15,16} The laterally running I-I nerve innervates the inguinal region, labium, and upper inner thigh. This area also is innervated by the genital branch of the G-F nerve. The femoral G-F branch passes under the inguinal ligament and supplies the anterior proximal aspect of the thigh.^{15,16} Entrapment of the G-F nerve is rare.¹⁶ Injury to the I-H and I-I nerves by the Pfannenstiel incision is more likely to occur because of the nerves' superficial course.¹⁶⁻¹⁸

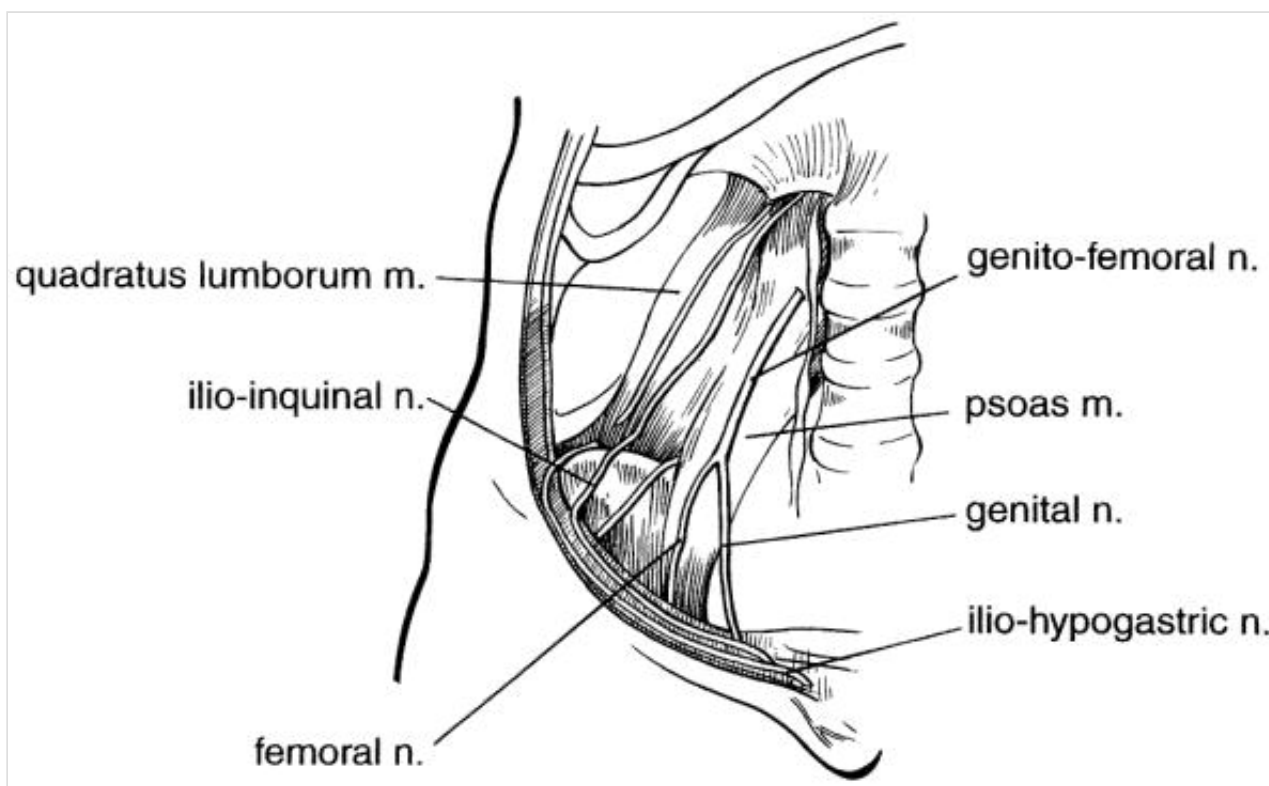


Figure 1. The essential nerves of the groin.

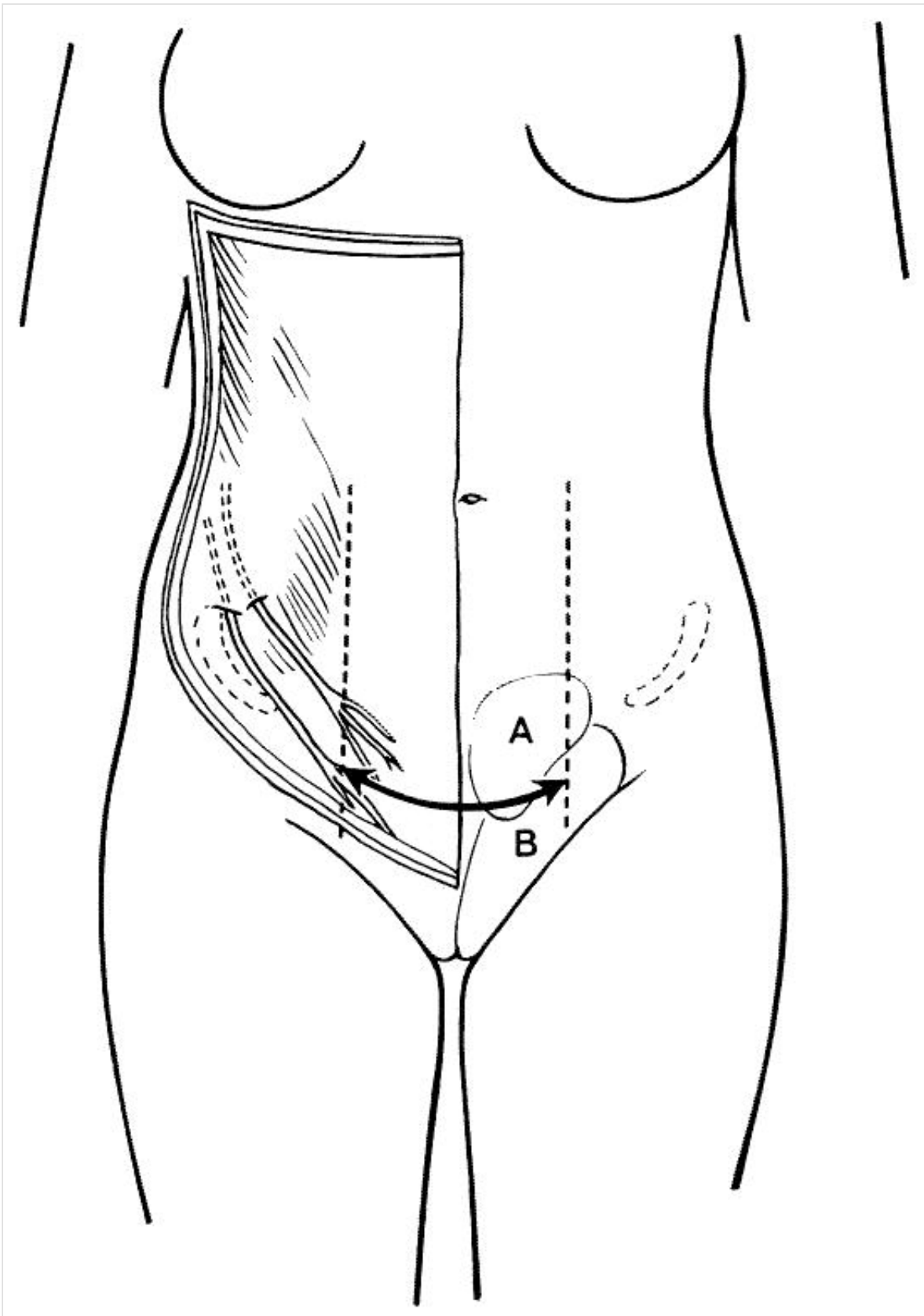


Figure 2. Nerve entrapment significantly is seen more often when the incision is extended more laterally. (A) Area innervated by iliohypogastric nerve. (B) Area innervated by ilioinguinal and genital branch of genitofemoral nerve. Communication between branches and overlap in sensory innervation is common.

In this series, 9 (3.7%) patients had symptoms of nerve entrapment. Nerve entrapment significantly was seen more often when the incision was extended laterally, beyond the lateral edge of the rectus sheath, confirming the observation of others (Fig. 2).¹⁴ Nerve entrapment can result from incision of the nerve followed by neuroma formation, incorporation of the nerve by a suture in the closure of the fascia, or the tethering or constriction of the nerve in the surrounding scar tissue.^{14,21} The symptoms may begin early or commence many years after surgery.¹⁴⁻¹⁷ Surgeons not familiar with this entrapment neuralgia may not recognize the syndrome and judge reported problems to be psychosomatic.^{15-17,27}

Other complications of nerve damage due to the Pfannenstiel incision are neuroma formation (2.1%) and numbness (25.1%). As a conclusion, ideally, when using the Pfannenstiel incision, and extending laterally, the nerves should be identified and spared.²⁸

The Pfannenstiel Incision for General Surgery

Although some authors think that access is obtained more easily^{2,12} and is less time consuming⁵ by a low midline incision, many others claim sufficient access to the operating area^{6,9,11-13,26} and do not find a significant difference in operating time.^{6,9,29} Experience might be of influence. Appendectomies,^{6,11,13} prostatectomies,^{20,29} inguinal hernia repairs,^{20,29} and sigmoid resections for colocolponeopoesis³⁰ have been described using the Pfannenstiel incision. Advantages of this incision are a lower incisional hernia rate (none in this series, in patients without a history of laparoscopy), less wound infection,^{6,7,13} hematoma formation,^{6,7} and direct postoperative pain,^{7,13} and the better aesthetic appearance.^{5,6,8,11-13} A disadvantage, however, is the possibility of nerve complications.^{14,27} Furthermore, in patients with ovarian or other tumors, its use might be contraindicated because proper exploration of the upper abdomen for tumor expansion is not adequate.³¹

CONCLUSION

Wherever feasible, we recommend the use of the Pfannenstiel incision in lower abdominal surgery, because incisional hernia is a rare complication, and the incision allows for excellent cosmetic results. Complications of nerve damage, however, are not uncommon, and should be recognized. When possible, nerves should be identified and preserved, especially when extending the incision more laterally. Depending on the operation to be performed, however, the advantages may counterbalance the disadvantages.

Acknowledgments

The authors thank Professor H. Ellis of the University of London and Dr. J. J. Hage of the Academic Hospital Free University of Amsterdam for careful and critical reading of the manuscript and valuable advice.

References

1. Cahalane MJ, Shapiro ME, Silen W. Abdominal incision: decision or indecision? *Lancet* 1989; 21:146-148. [\[Context Link\]](#)
2. Mudge M, Hughes LE. Incisional hernia: a 10 year prospective study of incidence and attitudes. *Br J Surg* 1985; 72:70-71. [Full Text @ EUR](#) | [Bibliographic Links](#) | [\[Context Link\]](#)
3. Luijendijk RW, Lemmen MHM, Hop WCJ, Wereldsma JCJ. Incisional hernia recurrence following "vest-over-pants" or vertical Mayo repair of primary hernias of the midline. *World J Surg* 1997; 21:62-66. [Full Text @ EUR](#) | [Bibliographic Links](#) | [\[Context Link\]](#)
4. Pfannenstiel HJ. Über die Vortheile des suprasymphysären Fascien-querschnitts für die gynäkologischen Köliotomien, zugleich ein Beitrag zu der Indikationsstellung der Operationswege.

Sammlung Klinischer Vorträge N.F. no. 268, Gynäkologie (Leipzig) 1900; 97:1735-1756. [\[Context Link\]](#)

5. Easton L. Hermann Johannes Pfannenstiel (1862-1909). Br J Obstet Gynaecol 1984; 91:538-541.

[Full Text @ EUR](#) | [Full Text](#) | [Bibliographic Links](#) | [\[Context Link\]](#)

6. Biswas KD. Why not Pfannenstiel's incision? Obstet Gynecol 1973; 41:303-307. [Ovid Full Text](#) | [Full](#)

[Text @ EUR](#) | [Bibliographic Links](#) | [\[Context Link\]](#)

7. Coeverden de Groot van HA, Jeeva MA, Gunston KD. Morbidity after total abdominal hysterectomy. S

Afr Med J 1983; 63:515-516. [Full Text @ EUR](#) | [Bibliographic Links](#) | [\[Context Link\]](#)

8. Pietrantonio M, Parsons MT, O'Brien WF, et al. Peritoneal closure or non-closure at Cesarean. Obstet

Gynecol 1991; 77:293-296. [Ovid Full Text](#) | [Full Text @ EUR](#) | [Full Text](#) | [Bibliographic Links](#) |

[\[Context Link\]](#)

9. Hetzel H, Bichler A, Geir W, Dapunt O. Sectio Caesarea: Pfannenstiel- oder Längsschnitt? Z Geburtsh

u Perinat 1979; 183:128-135. [\[Context Link\]](#)

10. Daye SS, Barone JE, Lincer RM, et al. Pfannenstiel Syndrome. The American Surgeon 1993;

59:459-460. [Full Text @ EUR](#) | [Bibliographic Links](#) | [\[Context Link\]](#)

11. Saetta JP, Abel KP. The use of the Pfannenstiel incision in the female with presumed appendicitis.

Br J Clin Pract 1990; 44:145-147. [Full Text @ EUR](#) | [Bibliographic Links](#) | [\[Context Link\]](#)

12. Tollefson DG, Russell KP. The transverse incision in pelvic surgery. Am J Obstet Gynecol 1954;

68:411-422. [Full Text @ EUR](#) | [\[Context Link\]](#)

13. El-Boghdady SA, Abel K. Pfannenstiel incision for appendectomy in females. Br J Clin Pract 1984;

38(1):17-19. [Full Text @ EUR](#) | [Bibliographic Links](#) | [\[Context Link\]](#)

14. Sippo WC, Captain MC, Burghardt A, Gomez A. Nerve entrapment after Pfannenstiel incision. Am J

Obstet Gynecol 1987; 157:420-421. [Full Text @ EUR](#) | [Full Text](#) | [Bibliographic Links](#) | [\[Context Link\]](#)

15. Starling JR, Harms BA, Schroeder ME, Eichman PL. Diagnosis and treatment of genitofemoral and

ilioinguinal entrapment neuralgie. Surgery 1987; 102:581-586. [Full Text @ EUR](#) | [Bibliographic Links](#) |

[\[Context Link\]](#)

16. Sippo WC, Gomez AC. Nerve-Entrapment Syndromes From Lower Abdominal Surgery. J Fam Pract

1987; 25:585-587. [Full Text @ EUR](#) | [Bibliographic Links](#) | [\[Context Link\]](#)

17. Hahn L. Clinical findings and results of operative treatment in ilioinguinal nerve entrapment

syndrome. Br J Obstet Gynaecol 1989; 96:1080-1083. [Full Text @ EUR](#) | [Full Text](#) | [Bibliographic](#)

[Links](#) | [\[Context Link\]](#)

18. Melville K, Schultz EA, Dougherty JM. Ilioinguinal-iliohypogastric nerve entrapment. Ann Emerg Med

1990; 19:925-929. [Full Text @ EUR](#) | [Full Text](#) | [Bibliographic Links](#) | [\[Context Link\]](#)

19. Hesselink VJ, Luijendijk RW, Wilt JHW de, et al. Incisional hernia recurrence; an evaluation of risk

factors. Surg Gynecol Obstet 1993; 176:228-234. [\[Context Link\]](#)

20. Griffiths DA. A reappraisal of the Pfannenstiel incision. *Br J Urol* 1976; 48:469-474. [Full Text @ EUR](#) | [Bibliographic Links](#) | [\[Context Link\]](#)
21. Kadar N, Reich H, Liu CY, et al. Incisional hernias after major laparoscopic gynecologic procedures. *Am J Obstet Gynecol* 1993; 168:1493-1495. [Full Text @ EUR](#) | [Full Text](#) | [Bibliographic Links](#) | [\[Context Link\]](#)
22. Sauer M, Jarrett II JC. Small bowel obstruction following diagnostic laparoscopy. *Fertil Steril* 1984; 42:653-654. [Full Text @ EUR](#) | [Full Text](#) | [Bibliographic Links](#) | [\[Context Link\]](#)
23. Høgdall C, Roosen JU. Incarcerated hernia following laparoscopy. *Acta Obstet Gynecol Scand* 1987; 66:735-736. [Full Text @ EUR](#) | [Bibliographic Links](#) | [\[Context Link\]](#)
24. Schlossnickel B, Leibl B, Bittner R. Incarcerierte Narbenhernie in einem Nebenarbeitskanal nach laparoskopischer Cholecystektomie eine seltene Komplikation? *Chirurg* 1993; 64:666-667. [Full Text @ EUR](#) | [Bibliographic Links](#) | [\[Context Link\]](#)
25. Kurtz BK, Daniell JF, Spaw AT. Incarcerated incisional hernia after laparoscopy. *J Reprod Med* 1993; 38:643-644. [Full Text @ EUR](#) | [Bibliographic Links](#) | [\[Context Link\]](#)
26. Daversa B, Landers D. Physiological advantages of the transverse incision in gynecology. *Obstet Gynecol* 1961; 17:305-310. [Ovid Full Text](#) | [Full Text @ EUR](#) | [Bibliographic Links](#) | [\[Context Link\]](#)
27. Piura B. Nerve entrapment after Pfannenstiel incision (comment and reply). *Am J Obstet Gynecol* 1989; 161:499-500. [Full Text @ EUR](#) | [Full Text](#) | [Bibliographic Links](#) | [\[Context Link\]](#)
28. Liszka TG, Dellon AL, Manson PN. Iliohypogastric nerve entrapment following abdominoplasty. *Plast Reconstr Surg* 1994; 93:181-184. [Ovid Full Text](#) | [Full Text @ EUR](#) | [Bibliographic Links](#) | [\[Context Link\]](#)
29. Abarbanel J, Kimche D. Combined retropubic prostatectomy and preperitoneal inguinal herniorrhaphy. *J Urol* 1988; 140:1442-1444. [Full Text @ EUR](#) | [Bibliographic Links](#) | [\[Context Link\]](#)
30. Freundt I, Toolenaar TAM, Huikeshoven FJM, et al. A modified technique to create a neovagina with an isolated segment of sigmoid colon. *Surg Gynecol Obstet* 1992; 174:11-16. [Full Text @ EUR](#) | [Bibliographic Links](#) | [\[Context Link\]](#)
31. Mc Gowan L. Abdominal incisions and staging in ovarian cancer. *Arch Surg* 1986; 121:800-802. [Full Text @ EUR](#) | [Bibliographic Links](#) | [\[Context Link\]](#)

IMAGE GALLERY

[Select All](#)

 [Export Selected to PowerPoint](#)

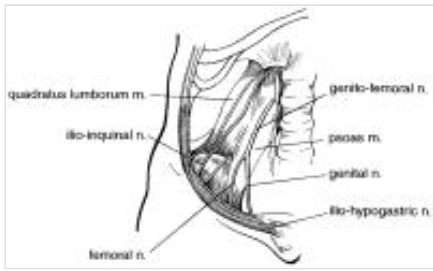


Figure 1

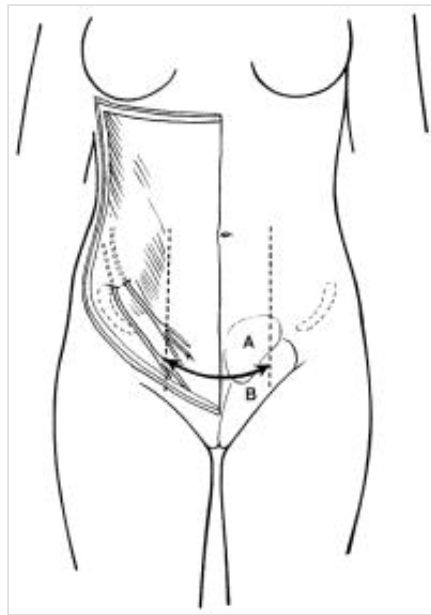


Figure 2

[Back to Top](#)

© 2016 Ovid Technologies, Inc. All rights reserved.

[About Us](#) | [Contact Us](#) | [Terms of Use](#)

OvidSP_UI03.20.00.112, SourceID 105955