

# Cutis Marmorata Telangiectatica Congenita

## Clinical Features in 35 Cases

Arjan C. A. Devillers; Flora B. de Waard-van der Spek, MD; Arnold P. Oranje, MD, PhD

**Objective:** To evaluate the distribution of skin lesions, clinical features, and associated abnormalities in children with cutis marmorata telangiectatica congenita at onset and during follow-up.

**Design:** Retrospective survey of the available medical data with an average follow-up of 1 year 5 months (range, 0-7 years).

**Setting:** Pediatric Dermatology Unit (Department of Dermatovenereology) of the Sophia Children's Hospital in Rotterdam, the Netherlands.

**Patients:** The diagnosis of cutis marmorata telangiectatica congenita was clinically established in 35 patients between July 1988 and February 1997. In 33 cases, the typical mottled, blue-violet pattern was present from birth and was readily visible at rest. In 2 cases, the skin lesions initially appeared less reticulated, mimicking a capillary malformation.

**Results:** The skin lesions were almost generalized in 4 children (11%), whereas they were more localized in the other 31 children (89%). Associated anomalies, usually minor and sometimes questionable, were noted in 80% of the patients. Most patients showed a definite improvement of their mottled vascular skin lesions within 2 years. The lesions had totally disappeared, or only faded residual lesions remained.

**Conclusions:** We believe that cutis marmorata telangiectatica congenita is a relatively mild condition. The prognosis is usually good, with minor associated anomalies. Improvement of the mottled, vascular pattern is usually observed within 2 years. We recommend careful clinical examination of all patients to exclude any associated anomalies. Patients should be referred to a neurologist or an ophthalmologist only if symptoms are present or if vascular lesions are present around the eyes.

*Arch Dermatol.* 1999;135:34-38

**C**UTIS MARMORATA telangiectatica congenita (CMTC) was first described by the Dutch pediatrician van Lohuizen<sup>1</sup> in 1922. It is defined as a localized or generalized reticulated, vascular, blue-violet network that is usually present at birth. This marbled pattern is always visible, but may be enhanced by cold temperatures or distress. In the first weeks of life, when the lesions may appear less reticulated, CMTC may look very similar to a capillary malformation. The skin lesions show a marked improvement over time, with the greatest improvement occurring during the first and second years of life.

The pathogenesis of CMTC is unknown. A number of hypotheses have been proposed. These include environmental factors, autosomal dominant inheritance with low or variable penetrance, a multifactorial cause, or a lethal gene surviving by mosaicism.<sup>2-6</sup>

The diagnosis is established on clinical grounds. Histopathologic examination of biopsy specimens may show an in-

crease in the number and the size of capillaries and veins but is usually not necessary to confirm the diagnosis.<sup>2,7,8</sup>

Additional anomalies have been frequently reported in association with CMTC. Most of the congenitally associated anomalies are minor and sometimes questionable.<sup>8-12</sup> The most commonly associated findings include body asymmetry (usually limb hyperplasia or hypoplasia), other vascular anomalies (mostly capillary malformation), glaucoma, hypoplasias or aplasias (ranging from transverse limb defects to localized aplasia cutis congenita to a cleft palate), and, infrequently, psychomotor and/or mental retardation.<sup>12</sup> Cutaneous atrophy and ulcerations may also be observed. These are not always regarded as associated anomalies, but are included in the specific skin findings in CMTC.<sup>1,2,6,8,10,11</sup>

## RESULTS

The group of 35 children consisted of 13 boys and 22 girls. The age at the first visit ranged from 1 day to 8 years. Twenty-two children

From the Department of Dermatovenereology, University Hospital Rotterdam, Rotterdam, the Netherlands.

## PATIENTS AND METHODS

We studied the medical records of 35 patients who were seen at the Pediatric Dermatology Unit of the Sophia Children's Hospital in Rotterdam, the Netherlands, between July 1988 and February 1997. The diagnosis of CMTC had been clinically established in all cases. In 33 cases, the typical mottled, blue-violet pattern was present from birth and was readily visible at rest. In 2 cases, the skin lesions initially appeared less reticulated and evolved into the typical CMTC lesions in the first few weeks of life. A skin biopsy specimen was obtained in only 1 case but showed no abnormalities. We examined the extent and the distribution of the CMTC lesions, the associated anomalies, the features, and the observations that were recorded during the follow-up.

were seen before the age of 6 months; 5 children were seen between the ages of 6 months and 1 year; and 8 children were seen after the age of 1 year. All the cases were sporadic, with 1 possible exception. One patient with multiple congenital abnormalities and psychomotor retardation had a mother with some of the same congenital abnormalities and a sister with slow motor development, abnormal hair, and possible mild cutis marmorata. Two other patients were each dizygotic twins, but in both cases the other twin had no signs of CMTC or any other vascular skin lesion.

**Figure 1** shows the extent of the observed skin lesions. In 4 children (11%), the skin disease appeared to be almost generalized, with more than 90% of the skin surface being affected. However, in no patient were the lesions completely generalized. More localized lesions were observed in the other patients (89%). The distribution of the lesions did not seem to follow any particular pattern (**Figure 2** through **Figure 5**). However, in 3 cases, the lesions were sharply demarcated at the midline of the trunk.

The associated anomalies that were observed in the patients are listed below:

| Associated Anomalies     | No. of Patients (N = 35) |
|--------------------------|--------------------------|
| Body asymmetry           | 15 (43)                  |
| Other vascular anomalies | 13 (37)                  |
| Neurological anomalies   | 5 (14)                   |
| Ocular anomalies         | 3 (9)                    |
| Cutaneous atrophy        | 3 (9)                    |
| Other                    | 15 (43)                  |

Although cutaneous atrophy is listed above, it may be included in the skin manifestations of CMTC rather than as an associated anomaly.

Other than 1 boy with hyperplasia of his left cheek, all patients with body asymmetry had hypoplasia or hyperplasia of an extremity. Hypoplasia was observed in 8 cases, hyperplasia in 5 cases, and both in 2 cases. A difference in circumference was observed in 6 cases, in length in 2 cases, and in both circumference and in length in 7 cases. The degree of the asymmetry varied, with a maximum difference in length of 4 cm in one patient and a maximum difference in circumference of 3 cm in another patient. In both cases, the affected limb was hyperplastic.

Cutaneous atrophy was not included in the group with body asymmetry. However, we encountered 2 patients with limb hypoplasia (a difference in circumference in both cases) who also had cutaneous atrophy.

All cases showed vascular lesions overlying the body asymmetry. The lesions of CMTC were observed in 14 children, including 1 child with an almost generalized distribution. A capillary malformation was present in 1 girl, overlying a hyperplasia in width of her left leg. Nine patients had an accompanying capillary malformation, 2 had a hemangioma, 1 had a capillary malformation and a twin spot, and 1 had a capillary malformation and a hemangioma. The pale pinkish red capillary malformations located on the nape ("stork bite") and on the glabella and/or eyelid ("angel's kiss") were not included in the group of capillary malformations because of the high incidence of these vascular anomalies in the general population. Thus, the term *capillary malformation* includes the typical port-wine stain and the pale pinkish red capillary malformations located elsewhere on the body other than the nape and glabella and/or eyelid.

Neurological abnormalities were noted in 5 cases. One child had triventricular hydrocephalus without functional complaints. He showed macrocephaly, frontal bossing, and hypertelorism. One child had psychomotor retardation. She also had extensive congenital abnormalities, including hypertelorism, brittle hair, low-set ears, a flat face, and small teeth. Her mother had the same facial features as our patient, and her older sister demonstrated slow motor development along with dry hair and, possibly, mild cutis marmorata. One patient had febrile seizures, psychomotor and mental retardation, corpus callosum agenesis, cerebral atrophy, and dilated ventricles. He also showed multiple congenital abnormalities: hypertelorism, low-set ears, large supraorbital ridges, and club feet. He was the son of consanguineous parents (his father and mother were cousins).

Another child was admitted because of seizures. His electroencephalogram was abnormal, with erratic disturbances demonstrated only once. The electroencephalographic findings normalized after 1 week. During the follow-up, there was no visible neurological damage and the seizures did not return. The last child had a possible afebrile seizure. No abnormalities were found on neurological examination, and there were no seizures during the follow-up.

An ocular anomaly was found in the boy with triventricular hydrocephalus. He had persisting arteria hyaloidea, an artery that supplies the developing lens during the embryonic period but usually degenerates before birth. A second ocular anomaly was found in a girl. She had granular retinal pigmentation, which remained stationary during the follow-up. A third ocular anomaly was found in the boy with the corpus callosum agenesis and cerebral atrophy. He had small optic discs. All 3 ocular anomalies were present without functional complaints.

The child with the retinal pigmentation showed CMTC lesions on the left side of his face. However, the retinal pigmentation was present in both eyes. No CMTC or other vascular lesions in the area around the eyes were observed in the other 2 cases. Three other children had periocular vascular lesions, without any ocular anomalies.

Other observed anomalies were syndactyly (2 cases); tendinitis stenans (diagnosed in a patient who had difficulty in extending the middle finger of both hands); a




Figure 1. The extent and distribution of the lesions of cutis marmorata telangiectatica congenita in 35 patients.

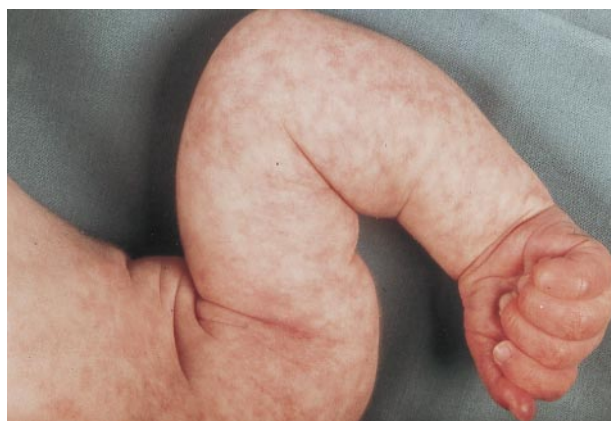

Figure 2. The typical reticulated blue-violet vascular network is present on the right arm.

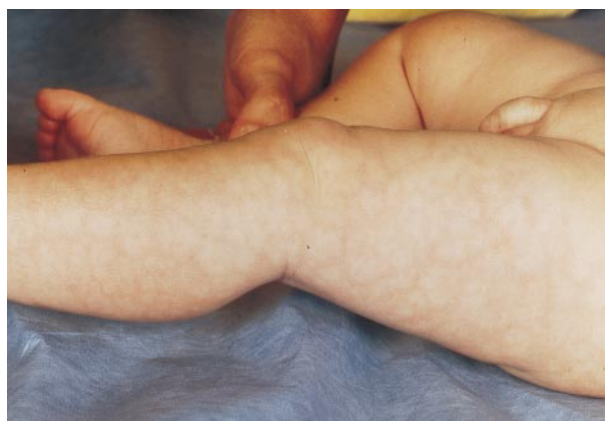

Figure 3. Mottled vascular lesions on the left leg. The upper part of the leg and the pubic region are free of skin lesions.

dysplastic hip; club feet; maldescended testes; an inguinal hernia; lymphangioma; torticollis (2 cases); an enlarged kidney; a malrotated bowel; an asymmetrical skull; a varus-like bowing in the lower legs due to the soft tissue (radiography showed normal skeletal structures); febrile convulsions (also found in the patient's brother, who did

not have CMTC); difference in the blood pressure between the arms and legs (e causa ignota and coarctatio aortae were excluded by a cardiologist); scoliosis; and multiple congenital abnormalities, including hypertelorism, low-set ears, abnormal hair, and small teeth. The diagnosis of Adams-Oliver syndrome was suspected in 1 patient who

had aplasia cutis congenita of the scalp along with syndactyly (digits 2 and 3) of both feet.

The follow-up records of the patients indicated a marked improvement of the mottled vascular pattern, with the greatest improvement in the first 2 years of life. The lesions had totally disappeared, or only faded residual lesions remained.

#### COMMENT

Cutis marmorata telangiectatica congenita appears to be a distinct clinical entity. Some overlapping features and clinical similarities to the Klippel-Trenaunay-Weber and Sturge-Weber syndromes have been observed. It has been suggested that these 3 entities should be classified as a group of vascular diseases associated with other developmental defects representing defects of the mesodermal system during embryonic life.<sup>6</sup>

Differential diagnosis is seldom difficult. Physiological cutis marmorata, which is caused by cold temperatures or distress, may be seen on the skin of healthy children and is not present during rest. In the first weeks after birth, when the lesions may appear less reticulated, CMTC may look very similar to a capillary malformation. During the follow-up, the difference between these vascular anomalies becomes clear when the CMTC lesions become characteristic in their appearance. Genuine diffuse phlebectasia of Bockenheimer is a deep venous malformation that is not present at birth, but starts in childhood. It is characterized by the gradual development of large multiple venous sinusoids. The lesions usually involve an extremity and are associated with a poor prognosis because of the frequent occurrence of thrombosis, bleeding, ulceration, infection, and gangrene. Disorders such as homocystinuria, Down syndrome, and de Lange syndrome are associated with cutis marmorata. Although patients with these disorders may have bluish mottled skin, other typical clinical features distinguish them from patients with CMTC.

Associated anomalies have been reported by many authors. The **Table** compares the associated anomalies reported in 3 studies<sup>8,10,11</sup> and a review of the literature<sup>12</sup> with those observed in the present study.<sup>8,10-12</sup>

Piscascia and Esterly<sup>11</sup> described 1 child (5%) with porencephaly in a group of 22 patients. Powell and Su<sup>10</sup> described 1 child with delayed motor development due to congenital rubella whom we did not include in the group of patients with associated motor retardation. South and Jacobs<sup>8</sup> described 2 children who developed behavioral problems, one in com-

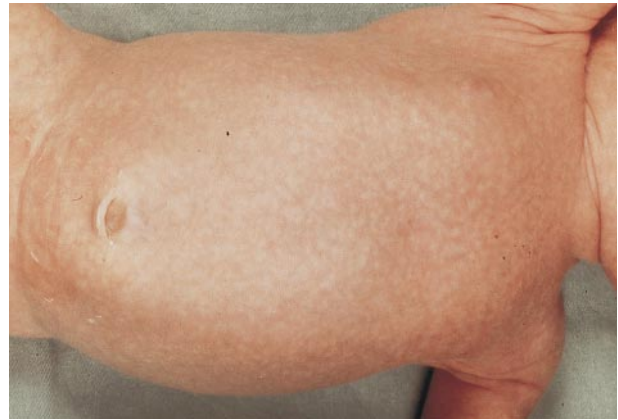

Figure 4. A child with lesions of cutis marmorata telangiectatica congenita that are almost generalized.

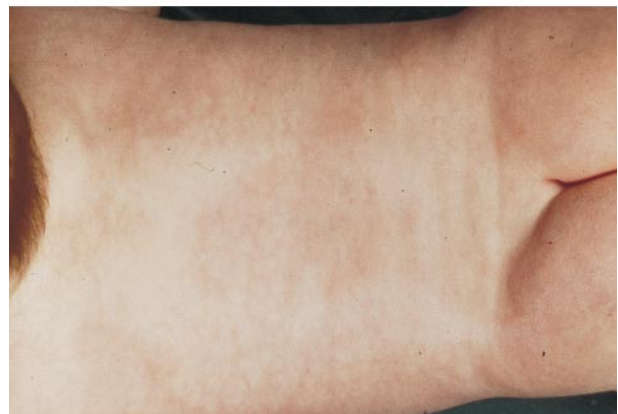
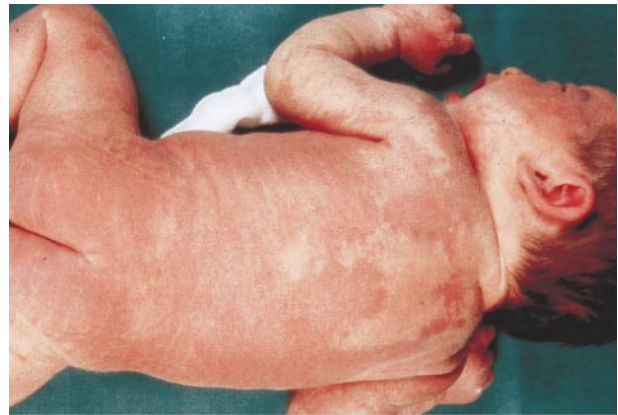
Figure 5. A 1-day-old girl with lesions of cutis marmorata telangiectatica congenita that resemble nevi flammei.

#### Summary of the Most Commonly Associated Anomalies in the Present Study Compared With 3 Other Reported Series and a Review of the Literature

| Source, y<br>(No. of Patients)                     | No. (%)              |                |                        |                                       |          |
|--|----------------------|----------------|------------------------|---------------------------------------|----------|
|  | Associated Anomalies | Body Asymmetry | Other Vascular Lesions | Psychomotor and/or Mental Retardation | Glaucoma |
| South and Jacobs, <sup>8</sup> 1978 (N = 13)       | 7 (54)               | 2 (15)         | 2 (15)                 | 0                                     | 0        |
| Powell and Su, <sup>10</sup> 1984 (N = 9)          | 8 (89)               | 5 (56)         | 0                      | 0                                     | 0        |
| Piscascia and Esterly, <sup>11</sup> 1989 (N = 22) | 6 (27)               | 1 (5)          | 4 (18)                 | 1 (5)                                 | 2 (9)    |
| Pehr and Moroz, <sup>12</sup> 1993 (N = 126*)      | 86 (68)              | 39 (31)        | 19 (15)                | 8 (6)                                 | 12 (10)  |
| Present study (N = 35)                             | 28 (80)              | 15 (43)        | 13 (37)                | 2 (6)                                 | 0        |

\*Review which includes the 3 previously mentioned series.

bination with incontinence and decreased sensation in the right side of the body and the other in combination with seizures (his mother had known epilepsy). The 2 children did not show psychomotor or mental retardation.

Two children in the present study also showed multiple congenital abnormalities. One of them was the son of consanguineous parents, and the other had a mother with some of the same congenital abnormalities and a sister with slow motor development along with abnormal hair and, possibly, mild cutis marmorata. Unfortunately, we were not able to examine her sister. These findings may indicate that both children were suffering from a specific syndrome with CMTC lesions as one of the symptoms. In the last case, the mother and her 2 daughters would show slightly different phenotypes of such a syndrome.

In this study, apart from the 2 previously mentioned children, we also noted 1 child with hydrocephalus who did not show any functional complaints and 2 children with afebrile seizures who did not show any recurrence of the seizures or any lasting neurological damage. We did not observe any child with glaucoma. This anomaly has been described in the literature by a number of authors.<sup>11-13</sup> However, all the reported cases of glaucoma associated with CMTC were accompanied by a periorcular vascular lesion, either CMTC or an associated capillary malformation.<sup>13</sup> The ocular anomalies in the patients in our study did not cause any functional complaints and had a questionable association. Standard ophthalmologic examination in all cases of CMTC seems unnecessary and should be limited to the cases in which there are vascular lesions around the eyes.

Other associated anomalies were seen in 43% of the patients. These anomalies, some of which have been reported in other studies, form a very diverse group: syndactyly, dysmorphic conditions, an asymmetrical skull, lymphangioma, and aplasia cutis congenita in combination with limb defects (in our case, syndactyly), leading to the diagnosis of Adams-Oliver syndrome.<sup>9-11,14,15</sup> The other anomalies that were observed in our study have not been reported previously as far as we know, but may be incidental and do not provide new insight regarding the cause of CMTC. The only anomalies with a clear association are the body asymmetry and the other vascular anomalies. We noted 3 children with cutaneous atrophy (9%), but observed no ulcerations. Both of these complications have been reported in combination with CMTC by other authors.<sup>1,2,6,8,10,11</sup>

The distribution of the skin lesions were very widespread in 11% of the cases but in no patient were completely generalized. The other children (89%) showed more localized lesions. This scattered pattern of lesions and the fact that the extent of the lesions varied considerably may suggest that the lethal gene theory proposed by Happle<sup>16</sup> may be applied to this disorder. Happle proposed that lethal genes surviving by mosaicism may be a possible explanation for a number of sporadic birth defects involving the skin, eg, Klippel-Trenaunay-Weber and Sturge-Weber syndromes. Two other characteristics of CMTC also seem to meet the criteria set for a lethal gene surviving by mosaicism. First, the disease always occurs sporadically, with a few possible exceptions.<sup>3,4</sup> Second, a complete diffuse involvement of the skin was not observed in any patient in our study. The 4 cases that we listed under generalized skin lesions all showed some small areas of unaffected skin. In the present study, there was no cor-

relation between the observed skin lesions and the number or severity of the associated anomalies. The last clinical criterion suggesting a lethal gene surviving by mosaicism is that the underlying gene affects males and females with the same frequency, and therefore the sex ratio should be 1:1. However, we found that 63% (22) of the girls and 37% (13) of the boys were affected, percentages that are in agreement with those noted by Pehr and Moroz<sup>12</sup> in their literature review (girls, 60%; boys, 40%).

The prognosis of CMTC is good. In the present study, we observed a rapid improvement of the skin lesions within 2 years either leading to a total disappearance of the lesions or markedly improved residual lesions, a finding that agrees with those of other studies.

In conclusion, we believe that CMTC is a relatively mild condition. The prognosis is usually good, with minor associated anomalies and an improvement of the mottled, vascular pattern within 2 years. We recommend careful clinical examination of all patients to exclude possible associated anomalies. Patients should be referred to a neurologist only if neurological symptoms or suggestions of a more complex syndrome are present. Standard referral to an ophthalmologist seems unnecessary and should be limited to the cases involving vascular lesions around the eyes.

Accepted for publication May 27, 1998.

Presented in part at the Fifth Congress of the European Society for Pediatric Dermatology, Rotterdam, the Netherlands, September 7, 1996.

Reprints: Arnold P. Oranje, MD, PhD, Department of Dermatovenereology, University Hospital Rotterdam, dr Molewaterplein 60, 3015 GJ Rotterdam, the Netherlands.

## REFERENCES

1. van Lohuizen CHJ. Über eine seltene angeborene Hautanomalie (Cutis marmorata telangiectatica congenita). *Acta Derm Venereol (Stockh)*. 1922;3:201-211.
2. Rogers M, Poyzer KG. Cutis marmorata telangiectatica congenita. *Arch Dermatol*. 1982;118:895-899.
3. Andreev JC, Pramatarov K. Cutis marmorata telangiectatica congenita in two sisters. *Br J Dermatol*. 1979;101:345-350.
4. Kurczynski TW. Hereditary cutis marmorata telangiectatica congenita. *Pediatrics*. 1982;70:52-53.
5. Way BH, Hermann J, Gilbert EF, Johnson SA, Opitz JM. Cutis marmorata telangiectatica congenita. *J Cutan Pathol*. 1974;1:10-25.
6. Kennedy C, Oranje AP, Keizer K, van den Heuvel MM, Catsman-Berrevvoets CE. Cutis marmorata telangiectatica congenita. *Int J Dermatol*. 1992;31:249-252.
7. Selvaag E, Thune P, Larsen TE. A case of cutis marmorata telangiectatica congenita (van Lohuizen syndrome). *Acta Derm Venereol*. 1994;74:333.
8. South DA, Jacobs AH. Cutis marmorata telangiectatica congenita (congenital generalized phlebectasia). *J Pediatr*. 1978;93:944-949.
9. Del Giudice SM, Nydorf ED. Cutis marmorata telangiectatica congenita with multiple congenital anomalies. *Arch Dermatol*. 1986;122:1060-1061.
10. Powell ST, Su WPD. Cutis marmorata telangiectatica congenita: report of nine cases and review of the literature. *Cutis*. 1984;34:305-312.
11. Picascia DD, Esterly NB. Cutis marmorata telangiectatica congenita: report of 22 cases. *J Am Acad Dermatol*. 1989;20:1098-1104.
12. Pehr K, Moroz B. Cutis marmorata telangiectatica congenita: long-term follow-up, review of the literature, and report of a case in conjunction with congenital hypothyroidism. *Pediatr Dermatol*. 1993;10:6-11.
13. Weillepp AE, Eichenfield LF. Association of glaucoma with cutis marmorata telangiectatica congenita: a localized anatomic malformation. *J Am Acad Dermatol*. 1996;35:276-278.
14. Frank RA, Frosch PJ. Adams-Oliver syndrome: cutis marmorata telangiectatica congenita with multiple anomalies. *Dermatology*. 1993;187:205-208.
15. Küster W, Lenz W, Kääriäinen H, Majewski F. Congenital scalp defects with distal limb anomalies (Adams-Oliver syndrome): report of ten cases and review of the literature. *Am J Med Genet*. 1988;31:99-155.
16. Happle R. Lethal genes surviving by mosaicism: a possible explanation for sporadic birth defects involving the skin. *J Am Acad Dermatol*. 1987;16:899-906.