

# EUR Research Information Portal

## The fetal lung 2: pulmonary hypoplasia

**Published in:**

Ultrasound in Obstetrics & Gynecology

**Publication status and date:**

Published: 01/01/2000

**DOI (link to publisher):**

[10.1046/j.1469-0705.2000.00252.x](https://doi.org/10.1046/j.1469-0705.2000.00252.x)

**Document Version**

Publisher's PDF, also known as Version of record

**Citation for the published version (APA):**

Laudy, JAM., & Wladimiroff, J. (2000). The fetal lung 2: pulmonary hypoplasia. *Ultrasound in Obstetrics & Gynecology*, 16, 482-494. <https://doi.org/10.1046/j.1469-0705.2000.00252.x>

[Link to publication on the EUR Research Information Portal](#)

**Terms and Conditions of Use**

Except as permitted by the applicable copyright law, you may not reproduce or make this material available to any third party without the prior written permission from the copyright holder(s). Copyright law allows the following uses of this material without prior permission:

- you may download, save and print a copy of this material for your personal use only;
- you may share the EUR portal link to this material.

In case the material is published with an open access license (e.g. a Creative Commons (CC) license), other uses may be allowed. Please check the terms and conditions of the specific license.

**Take-down policy**

If you believe that this material infringes your copyright and/or any other intellectual property rights, you may request its removal by contacting us at the following email address: [openaccess.library@eur.nl](mailto:openaccess.library@eur.nl). Please provide us with all the relevant information, including the reasons why you believe any of your rights have been infringed. In case of a legitimate complaint, we will make the material inaccessible and/or remove it from the website.

# The fetal lung 2: pulmonary hypoplasia

J. A. M. LAUDY and J. W. WLADIMIROFF

Department of Obstetrics and Gynecology of the University Hospital Rotterdam and the Erasmus University Medical School Rotterdam, The Netherlands

**KEYWORDS:** Doppler, Human fetus, Lung development, Oligohydramnios, Prenatal prediction, Premature rupture of membranes (PROM), Pulmonary hypoplasia

## ABSTRACT

*This review describes the pathogenesis of pulmonary hypoplasia and highlights its clinical, radiological and pathologic features, with emphasis on oligohydramnios-related pulmonary hypoplasia. Since pulmonary hypoplasia may lead to severe respiratory distress immediately after birth and even to neonatal death, an accurate and patient-friendly prenatal test for early detection and distinction between lethal and non-lethal pulmonary hypoplasia is still highly desirable. An extended overview of the proposed methods for the prenatal prediction of pulmonary hypoplasia is presented.*

## INTRODUCTION

Having previously presented morphologic and physiologic aspects of normal fetal development, this overview will give an outline of abnormal lung development, i.e. of pulmonary hypoplasia in particular. Further, from an obstetrician's and pediatrician's point of view, knowledge of the clinical course and of pre and postnatal diagnostic procedures and characteristics is mandatory to cope with the various ways pulmonary hypoplasia may present itself.

## ABNORMAL LUNG DEVELOPMENT: PULMONARY HYPOPLASIA

### Definition and morphologic features

Pulmonary hypoplasia, either unilateral or bilateral, is a poorly defined condition of incomplete development of the lung, so that it fails to reach adult size<sup>2,3</sup>. This defective development is due to a decrease in the number of lung cells, airways and alveoli, with a resulting decrease in organ size and weight<sup>4–11</sup>. Based on a study of Nakamura *et al.*<sup>8</sup> it has been postulated that impairment of pulmonary development during the pseudoglandular stage (before 16 weeks' gestation) causes reduced bronchiolar branching,

cartilage development, acinar complexity and maturation, and retarded vascularization and thinning of the air–blood barrier. Insults occurring after the pseudoglandular stage (after 16 weeks' gestation) impair acinar complexity and maturation<sup>8</sup>. In a morphometric and biochemical study on hypoplastic lungs from human fetuses associated with oligohydramnios, Wigglesworth *et al.*<sup>6</sup> as well as Nakamura *et al.*<sup>12,13</sup> confirmed not only lung growth arrest but also impairment of lung maturation based on low surfactant phospholipid concentrations. Reale *et al.*<sup>11</sup> stated that changes in the histologic appearance were correlated with severity and were independent of the type of associated malformations.

Since growth of the pulmonary blood vessels parallels development of the airways (pre-acinar blood vessels with the conducting airways and intra-acinar blood vessels with alveolar development), it is not surprising that disturbance of the pulmonary vascular bed coincides with pulmonary hypoplasia. A decrease in total size of the pulmonary vascular bed, a decrease in the number of vessels per unit of lung tissue and increased pulmonary arterial smooth muscle have been described<sup>14</sup>. The latter has been expressed in an increased medial wall thickness as percentage of the external thickness<sup>15,16</sup>. Peripheral extension of muscle into arteries smaller than normal have been observed<sup>7,9,15,16</sup> and the intrapulmonary arteries are smaller than normal but appropriate for the reduced volume of the lung<sup>7,9</sup>. These features form the morphologic basis for the increased pulmonary vascular resistance.

### Epidemiology

The reported incidence of pulmonary hypoplasia in the general population ranges from 9 to 11 per 10 000 livebirths and is 14 per 10 000 of all births<sup>17,18</sup>. This must be an underestimate of the true incidence since infants with lesser degrees of hypoplasia undoubtedly survive the neonatal period. The reported prevalence of this condition in autopsies ranges from 7.8 to 22%<sup>3,17–21</sup> and more than 85% of those cases will display significant associated

Correspondence: J. A. M. Laudy, M.D., Department of Obstetrics and Gynecology, University Hospital Rotterdam, Erasmus University, School of Medicine and Health Sciences, Dr Molewaterplein 40, 3015 GD Rotterdam, The Netherlands

Received 29-2-00, Revised 9-8-00, Accepted 1-9-00

**Table 1** Anomalies associated with pulmonary hypoplasia

Intrathoracic masses	Congenital diaphragmatic hernia, congenital cystic adenomatoid malformation, bronchogenic cyst, etc.
Oligohydramnios based on renal or urinary tract anomalies	Bilateral renal agenesis or dysplasia, bladder outlet obstruction, etc.
Non-renal oligohydramnios	Prolonged preterm rupture of membranes
Skeletal malformations	Osteogenesis imperfecta, thanatophoric dwarfism, etc.
Neuromuscular and central nervous system anomalies	Fetal akinesia, anencephaly, etc.
Pleural effusions	Rhesus and non-rhesus hydrops, etc.
Cardiac lesions	Hypoplastic right or left heart, pulmonary stenosis, etc.
Abdominal wall defects	Omphalocele, gastroschisis, etc.
Syndromes associated with pulmonary hypoplasia	Trisomy 13, 18, 21, Robert syndrome, etc.

anomalies<sup>3</sup>. Perinatal mortality is high, approximately 70% in most series (55–100%)<sup>22–27</sup>.

### Etiology

Pulmonary hypoplasia may be a primary or secondary phenomenon. Bilateral pulmonary hypoplasia occurring as an isolated anomaly has been considered as extremely rare<sup>28,29</sup>. It has been suggested that infants with primary pulmonary hypoplasia represent a group of infants subject to decreased respiratory activity *in utero*, although the amount of amniotic fluid at delivery was not described in these instances<sup>28–30</sup>. Most cases of pulmonary hypoplasia are secondary to congenital anomalies or pregnancy complications that inhibit lung development. Factors important in lung growth are discussed in a previous overview recently published in this journal<sup>1</sup>. Several authors have reported on various anomalies associated with pulmonary hypoplasia<sup>2,3,5,7–13,20,22,23,29,31–39</sup>. An exhaustive list of the numerous conditions reportedly associated with pulmonary hypoplasia was compiled by Sherer *et al.*<sup>32</sup>. Based on this list the following categories can be grouped as shown in Table 1. Most cases, such as renal anomalies, congenital diaphragmatic hernia and hydrops fetalis, indicate interference with lung growth during the early developmental stage mainly before 16 weeks of gestation, whereas oligohydramnios due to prolonged rupture of membranes possibly impairs pulmonary development after 16 weeks<sup>8</sup>. Wigglesworth *et al.*<sup>6</sup> could detect no difference between structural appearance of the lungs after rupture of the membranes dating from before 20 weeks' gestation in the presence of normal kidneys and that seen in cases of bilateral renal agenesis.

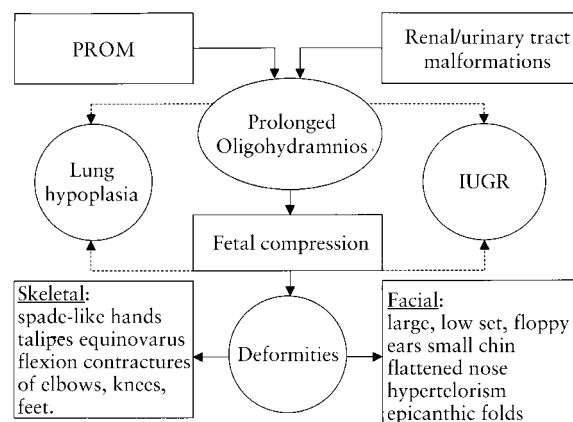
### Oligohydramnios-related pulmonary hypoplasia

Renal and non-renal prolonged oligohydramnios are one of the major causes of pulmonary hypoplasia. The occurrence of bilateral renal agenesis and pulmonary hypoplasia was first recognized by Potter in 1946<sup>34</sup>. Later it became apparent that lethal pulmonary hypoplasia was also a consistent feature in babies with no renal function at birth because of bilateral renal dysplasia with or without cyst formation<sup>10,40</sup>. The common features associated with these anomalies, are known as the Potter's syndrome: profound oligohydramnios, characteristic facial

and limb deformities and pulmonary hypoplasia<sup>35,36,41,42</sup>. Growth deficiency, if delivered after 34 weeks, is also reported to be a common, although not a major feature in association with Potter's syndrome<sup>40,42</sup>. The facial abnormalities (Potter facies) include large, low-set, floppy ears, a small chin, a flattened nose, hypertelorism, epicanthic folds<sup>43</sup>. Limb defects such as spade-like hands, talipes equinovarus and flexion contractures at the level of the elbows, knees and feet are described<sup>22,23,26,40</sup>.

There is no evidence that pulmonary hypoplasia is genetically or teratologically related to the various urinary tract anomalies<sup>13,35,44</sup>. One hypothesis for the development of Potter's syndrome is that it is the consequence of multiple early mesodermal defects<sup>41</sup>, although the widely accepted view is that the structural abnormalities of the face, lungs and limbs are secondary to oligohydramnios<sup>35,36</sup>. Also other non-renal causes of prolonged oligohydramnios such as chronic amniotic fluid leakage may lead to the described non-renal features of the Potter's syndrome<sup>35–37</sup>. Therefore, these secondary features are also known as the oligohydramnios sequence or oligohydramnios tetrad<sup>36,37,45</sup> (Figure 1).

It has been reported that oligohydramnios due to prolonged premature rupture of membranes (PROM) may be associated with pulmonary hypoplasia<sup>22–26,37–39,46</sup> even in the absence of the full complex of malformations connected with the oligohydramnios tetrad<sup>23,25,47</sup>. Premature



**Figure 1** Features of the Potter syndrome or oligohydramnios tetrad. PROM, premature rupture of membranes; IUGR, intra-uterine growth restriction.

rupture of membranes mostly defined as rupture of the fetal membranes prior to the onset of labor, is a common obstetric problem which occurs in approximately 10% of all pregnancies with world-wide reports varying between 5 and 45%<sup>48,49</sup>. Ninety percent of the patients who present with this problem have a latent phase of less than one week<sup>50</sup>. The other 10%, who are largely preterm patients, present a dilemma in management<sup>22,49,51,52</sup>. Prolonged PROM is associated with increased chance of infection in both the mother and the fetus, perinatal death as a result of prematurity, and fetal distress during labor because of cord compression<sup>25,51,52,53</sup>. The risks of early delivery and hyaline membrane disease must be weighed against those of expectant management like pulmonary hypoplasia, sepsis and fetal deformities. The incidence of neonatal infection following preterm membrane rupture has been reported to be between 0.5 and 25%<sup>49</sup>. It was demonstrated by McIntosh *et al.*<sup>26</sup> that death from pulmonary hypoplasia is a much more serious problem than infection following preterm prolonged membrane rupture. This was confirmed by Tibboel *et al.*<sup>38</sup> who emphasized that in cases of prolonged PROM, prenatal care should not merely focus on the occurrence and prevention of infections, but rather on the occurrence of oligohydramnios because of the risk of pulmonary hypoplasia increasing with the duration of the latter.

Even a period of oligohydramnios as short as 6 days may interfere with fetal lung development and cause pulmonary hypoplasia<sup>23,54</sup>. The reported incidence of pulmonary hypoplasia due to oligohydramnios based on chronic amniotic leakage varies between 8 and 26% of which 55–100% was lethal<sup>22–26</sup>. The overall mortality rate after prolonged preterm PROM in these studies ranges between 17 and 41% with a mortality rate due to pulmonary hypoplasia between 29 and 58%.

## POSTNATAL DIAGNOSIS OF PULMONARY HYPOPLASIA

### Clinical and radiologic criteria

In most cases, pulmonary hypoplasia is lethal. However, sublethal forms of lesser severity (usually proportional to the severity of the underlying etiologic condition) exist and they present a spectrum of clinical presentation, course, prognosis and eventual outcome. Clinical manifestations of pulmonary hypoplasia in neonates range from severe respiratory failure leading to neonatal death (lethal form) to respiratory insufficiency associated with pulmonary hypertension with persistent fetal circulation, pulmonary hemorrhage, bronchopulmonary dysplasia, or subacute lung disease, to mild or transient respiratory disease (non-lethal form)<sup>22,25,32,39</sup>. Presently, the clinical diagnosis of pulmonary hypoplasia is difficult to make as no tissue is available for histologic examination. Although there is no extensive prospective study of neonatal findings suggestive of pulmonary hypoplasia, there are several case series describing clinical and/or radiologic findings<sup>22,23,25,28,37,55–57</sup>. The clinical features of infants with pulmonary hypoplasia are

characterized by an immediate onset of severe respiratory insufficiency after birth, with small lung capacity and requiring high ventilatory pressures in the absence of obstruction or atelectasis. The radiologic criteria for pulmonary hypoplasia include small lung fields with diaphragmatic domes elevated up to the seventh rib, downward sloping ribs, a bell-shaped thorax, pneumothorax or pneumomediastinum. In a study of Leonidas *et al.*<sup>55</sup> pneumomediastinum/pneumothorax was diagnosed in 82% of 17 infants dying from oligohydramnios related pulmonary hypoplasia and a bell-shaped chest contour in 59%. Both features were present in 53%. The bell-shaped thorax is valuable in predicting the most severe degrees of lung growth impairment and was present in all cases in which oligohydramnios was caused by bilateral renal agenesis. However, either pneumomediastinum/pneumothorax or the bell-shaped chest, when present alone, were of low diagnostic value (6.4 and 4.5%, respectively), whereas the chance of oligohydramnios-related pulmonary hypoplasia is much higher when both X-ray manifestations were present (around 30%).

Other additional neonatal signs secondary to prolonged oligohydramnios are facial (Potter's facies) and skeletal deformities with a reported incidence of 21–28%<sup>22,23,26,27,58</sup>. Their presence correlates most strongly with the degree and duration of oligohydramnios. Thibeault *et al.*<sup>23</sup> showed that from a group of 76 preterm infants  $\leq$  34 weeks' gestation associated with premature rupture of membranes (PROM) for longer than 5 days, 21 infants displayed oligohydramnios and deformities at birth. Twenty of these infants showed clinical evidence of pulmonary hypoplasia. The duration of PROM was longest in infants with deformities, and the mortality in these infants was 86% compared to 52% in infants without deformities who required mechanical ventilation. In a series by McIntosh *et al.*<sup>26</sup> 15 out of 16 infants with pulmonary hypoplasia displayed compression deformities but nine infants with compression deformities did not show maldevelopment of the lungs. Rotschild *et al.*<sup>25</sup> confirmed the presence of a strong correlation between skeletal deformities and pulmonary hypoplasia, since all cases of severe skeletal deformities in their study were associated with pulmonary hypoplasia. In their study development of skeletal deformities was associated with severe oligohydramnios and duration of PROM, but not with gestational age at PROM. Nevertheless, pulmonary hypoplasia can also occur in isolation with little or no compression<sup>23,25</sup>.

### Pathologic criteria

Several pathological criteria of pulmonary hypoplasia are well established, although presently there is still uncertainty as to which method is most reliable<sup>20</sup>.

### Lung weight or lung weight to body weight ratio

The direct measurement of lung weight and comparison of that weight with expected values is the simplest

**Table 2** Guidelines for diagnosis of pulmonary hypoplasia according to Askenazi and Perlman<sup>19</sup>

<i>LW : BW ratio</i>	<i>Radial alveolar count</i>	<i>Pulmonary hypoplasia</i>
< 0.009	Not obligatory	Likely
0.010 to 0.012	Indicated for confirmation of diagnosis	Probable
0.013 to 0.017	Required	Possible
> 0.018	Probably not indicated	Unlikely

method to determine pulmonary hypoplasia<sup>34</sup>. The lung weight to body weight ratio (LW : BW ratio) is the most consistently used method of diagnosing pulmonary hypoplasia<sup>5,6,19,3-2,59</sup>. The normal LW : BW weight ratio at term is 0.018–0.022<sup>11,19</sup>. Wigglesworth *et al.*<sup>59</sup> proposed to use 0.012 as the lower limit of normality  $\geq$  28 weeks of gestation and 0.015 before 28 weeks' gestation. When either lung weight or LW : BW ratio is used to diagnose pulmonary hypoplasia, it is important to realize that lung weight is altered by conditions causing pulmonary congestion or edema. Postnatal absorption of fluid also effects lung weight. Askenazi and Perlman<sup>19</sup> suggested the combination of the LW : BW ratio with the radial alveolar count (see following paragraph) to address these confounding variables. They proposed the following guidelines for the diagnosis of pulmonary hypoplasia (Table 2).

#### Morphometric radial alveolar count

The radial alveolar count (RAC) offers a simple objective assessment of alveolar development, as originally proposed by Emery and Mithal<sup>60</sup>. They estimated the number of alveoli cut by a line which was dropped at right angles to the epithelium from the center of terminal respiratory bronchioles to the nearest connective tissue septum. At least 10 counts were made for each fetal lung, mainly from two to three histologic sections. The mean value for RAC is taken as a measure of lung maturation. They found an increase of the mean RAC in relation to gestational age, which has also been confirmed by other studies<sup>61,62</sup>. Askenazi and Perlman<sup>19</sup> used a modification of the method of Emery and Mithal, meaning that they counted the alveolar septi instead of alveoli (RAC = alveolar septal count – 1). In this study only two fetal age groups, less or more than 36 weeks of gestation, were evaluated and no differences between the groups were found. No detailed information on a fetal age-dependent increase in the RAC values was obtained. The mean RAC for controls was 5.3 (SD 0.6) in this study and an RAC value < 75% of the mean normal value as defined by each individual laboratory was recommended as diagnostic for pulmonary hypoplasia.

#### DNA estimation performed at autopsy

Although the amount of lung DNA increases with gestation, it decreases in proportion to total body weight. Lung hypoplasia defined in terms of LW : BW ratio was associated with low lung DNA content for gestation, even

when corrected for body weight<sup>59</sup>. Studies have shown that the lung DNA of infants with pulmonary hypoplasia delivered at 34–40 weeks' gestation is equivalent to the lung DNA of normal fetuses at 20–22 weeks. A cut-off of less than 100 mg DNA per kilogram of body weight has been proposed to diagnose pulmonary hypoplasia<sup>59</sup>.

#### PRENATAL PREDICTION OF PULMONARY HYPOPLASIA

An accurate prenatal test for detecting pulmonary hypoplasia is highly desirable from the obstetrician's point of view, because of the high perinatal mortality rate. Since the prediction of the non-lethal forms of pulmonary hypoplasia will not drastically change obstetric management, the reliable prenatal prediction of the lethal form might alter obstetric management. Therefore we need an accurate and patient-friendly method of separating lethal from non-lethal pulmonary hypoplasia. The following parameters/methods have been proposed.

#### Premature rupture of membranes and persistent oligohydramnios

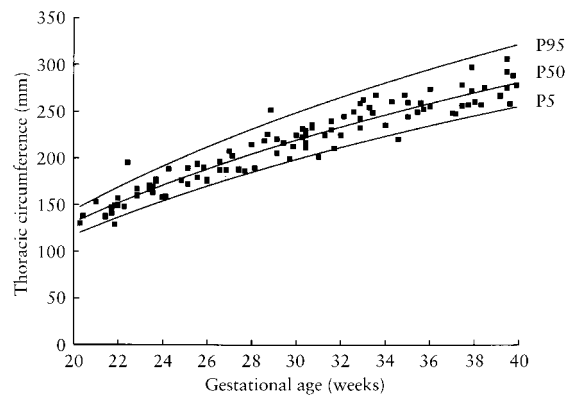
The relationship between premature rupture of membranes (PROM) and pulmonary hypoplasia was a subject of study of several authors<sup>22-25,27,39,51,63,64</sup>. Nimrod *et al.*<sup>22</sup> studied 100 singleton pregnancies in which PROM occurred more than 1 week prior to delivery. They revealed that the greatest impact of prolonged ruptured membranes on fetal development was seen in patients in whom membrane rupture occurred prior to 26 weeks' gestation and the duration of the rupture was more than 5 weeks. Rotschild *et al.*<sup>25</sup> reviewed 88 neonates who were born after prolonged PROM of  $\geq$  7 days with the onset of the rupture before 29 weeks' gestation and in 14 of them (16%) pulmonary hypoplasia was diagnosed. They revealed that gestational age at the time of rupture of the membranes was the best predictor of pulmonary hypoplasia, with no cases occurring with PROM after 26 weeks, whereas the duration and degree of oligohydramnios showed no correlation with pulmonary hypoplasia. These authors created a relating probability of pulmonary hypoplasia to gestational age at PROM derived from estimated logistic regression. According to this curve the probability of pulmonary hypoplasia in a patient with PROM at 19 weeks is 50%. Vergani *et al.*<sup>63</sup> calculated this estimated probability of 50% to develop pulmonary hypoplasia when the rupture of membranes occurs at

25 weeks of gestation. This difference may be due to the fact that the latter used a subgroup of patients who had amniotic fluid pockets of less than 2 cm during the latency period. In the study of Vergani *et al.*<sup>63</sup> with a prevalence of pulmonary hypoplasia of 28% in a group of women ( $n = 54$ ) with PROM < 29 weeks and delivery after 25 weeks, gestational age at premature rupture of membranes and oligohydramnios were independent predictors of the occurrence of pulmonary hypoplasia. This is in agreement with the data from Kilbride *et al.*<sup>27</sup> who studied 108 patients with PROM < 29 weeks. Of the 40 infants who died in this group, 23 had lung hypoplasia. The authors concluded that severe oligohydramnios > 14 days after premature rupture of membranes at < 25 weeks' gestation has a predicted neonatal mortality of > 90%. Of these infants 87% died of pulmonary hypoplasia. In a study of Van Dongen *et al.*<sup>24</sup>, however, neither the duration of PROM nor the gestational age at the time of rupture showed any impact on the occurrence of lung hypoplasia.

Persistent severe oligohydramnios appears to be a poor prognostic sign which is associated with a poor fetal outcome<sup>27,63,65-67</sup>. Whereas some authors revealed that persistent severe oligohydramnios is an independent significant predictor of lung hypoplasia<sup>27,63</sup>, others imply that this is co-dependent of gestational age at the time of PROM, and does not predict pulmonary hypoplasia when evaluated alone<sup>5,25,65,66,68</sup>.

#### Absence of fetal breathing movements

The relationship of fetal breathing movements and pulmonary hypoplasia has been vigorously disputed. However, data on the predictive value of the presence or absence of fetal breathing movements are still contradictory. Both Blott and Greenough<sup>69-71</sup> showed a sensitivity and predictive value of the absence of fetal breathing for pulmonary hypoplasia up to 100%. Although in a study of Roberts and Mitchell<sup>64</sup> breathing movements were seen in fetuses with pulmonary hypoplasia, they found a significant reduction in this group compared to those that did not develop pulmonary hypoplasia and controls. In contrast, others have demonstrated that fetuses with oligohydramnios and pulmonary hypoplasia spend significantly more time breathing when compared to fetuses with similar conditions and normal development<sup>72,73</sup>. Nevertheless, there are also reports that failed to determine any correlation between the absence of fetal breathing movements and pulmonary hypoplasia<sup>27,74-76</sup>. These conflicting findings are probably the result of different definitions of fetal breathing, different selection criteria resulting in different sample populations and different diagnostic criteria for pulmonary hypoplasia. The many factors which affect fetal breathing are also not always controlled<sup>5,77</sup>. Despite these differences most work supports the suggestion that the presence or absence of fetal breathing movements does not prevent or confirm pulmonary hypoplasia, especially in isolated examinations. Nevertheless, the persistent absence over several weeks is probably a poor prognostic sign<sup>5,74</sup>.



**Figure 2** Normal reference ranges (P95, P50, P5) of the thoracic circumference (TC, mm) in relation to gestational age (GA, weeks), constructed from 111 normal singleton pregnancies. Formula  $TC = -135.34 + 16.306 \times GA - 0.149 \times GA^2 \pm 1.645 \times [1.35 + (0.284 \times GA)] \times 1.2533$ . P, percentile.

A study of Fisk *et al.*<sup>78</sup> demonstrated that restitution of amniotic fluid volume in human pregnancies complicated by severe oligohydramnios does not acutely alter the incidence of fetal breathing movements, suggesting that impairment of fetal breathing is not the mechanism for oligohydramnios-related pulmonary hypoplasia.

#### Biometric indices

Since the fetal thorax normally grows at a regular rate from 16 to 40 weeks, a linear correlation exists between thoracic size and gestational age (Figure 2). Ratios between thoracic size and other biometric indices (biparietal, head circumference diameter, abdominal circumference and femur length) remain constant with a high correlation coefficient in normal pregnancies<sup>68,79-82</sup>. Measurements of the thoracic circumference are obtained in an axial section through the fetal thorax at the level of the four-chamber view of the heart, with the atrioventricular valves in diastole<sup>5</sup>. The reported measurements for thoracic circumference vary among different series, probably because of differences in the plane of section and the amount of tissue included in the measurement. For example, some series include the skin and subcutaneous tissues of the thorax in the measurements of thoracic circumference, while others measure the thoracic circumference at the outer, mid or inner perimeter of the rib cage<sup>82</sup>.

Several investigators have attempted to predict lethal pulmonary hypoplasia by using fetal two-dimensional biometric parameters such as thoracic circumference and lung length measurements, interthoracic relationship nomograms (thoracic circumference versus biparietal diameter, head circumference, abdominal circumference or femur length), thoracic circumference to abdominal circumference ratio, thoracic area (TA) minus heart area (HA), HA/TA ratio and  $(TA - HA) \times 100 / TA$ <sup>65,68,74,79,83-91</sup>. Although the first reports<sup>68,79,83-85</sup> on the application of fetal thoracic circumference measurements in the prediction of lung hypoplasia were quite

promising, other and some more recent studies revealed that this measurement has a lower sensitivity and accuracy compared with other methods in the prenatal prediction of lung hypoplasia<sup>64,86–88</sup>. Vintzileos *et al.*<sup>86</sup> compared six different ultrasonographic methods for predicting lethal fetal pulmonary hypoplasia and found that the  $(TA - HA) \times 100/TA$  parameter had the best diagnostic accuracy. Roberts and Mitchell<sup>74</sup> demonstrated that lung length measurements were superior to fetal chest circumference measurements in the identification of pulmonary hypoplasia. Yoshimura *et al.*<sup>87</sup> showed in 1996 that the application of lung area and the thoracic circumference/abdominal circumference ratio were the best clinical parameters for this purpose and that there were significant linear relationships between lung weight and lung area and between the LW : BW ratio and the thoracic circumference/abdominal circumference ratio. Lately, Merz *et al.*<sup>88</sup> displayed in 1999 that in comparison with other measured parameters, the lung diameter appears to be the only reliable parameter for detecting pulmonary hypoplasia.

It should be emphasized that most studies represent very heterogeneous and overall relatively small patient cohorts and use different definitions of thoracic circumference dimensions and lung hypoplasia. This makes it difficult to compare and consequently to select the best prenatal predicting test. The positive predictive prenatal value of any of these reported tests should be 100% accurate in order to alter the obstetric management as Vintzileos<sup>91</sup> stated in 1996. Therefore, biometry alone cannot achieve such a high degree of prediction, which is probably determined by the diversity of etiologies of lung hypoplasia.

Harstad *et al.*<sup>92</sup> compared the ultrasonographic circumference and area measurements and their ratios of the fetal chest and heart with magnetic resonance imaging (MRI) measurements performed in a fashion similar to sonography. They concluded that MRI does not offer any advantages over sonographic evaluation in the diagnosis of fetal pulmonary hypoplasia.

### Perinatal flow

Fetal upper respiratory tract function was studied by Fox *et al.*<sup>93</sup> using color flow Doppler in five cases of antenatally diagnosed congenital diaphragmatic hernia and in 16 cases of uncomplicated pregnancies at gestational ages ranging from 27 to 38 weeks. Fetal breathing related nasal and oropharyngeal fluid flow was seen at the level of the nose in all cases with uncomplicated pregnancies. Fetal breathing movements were present in all five cases of congenital diaphragmatic hernia, so its presence or absence did not help to distinguish between those infants that died and those that survived. This was consistent with previous work from this group<sup>73</sup>. However, four of the fetuses who survived, demonstrated perinatal fluid flow, whereas the fetus who died of pulmonary hypoplasia did not. These preliminary observations need to be further investigated by a larger case series to point out whether this technique can be a marker for prenatal prediction of pulmonary hypoplasia.

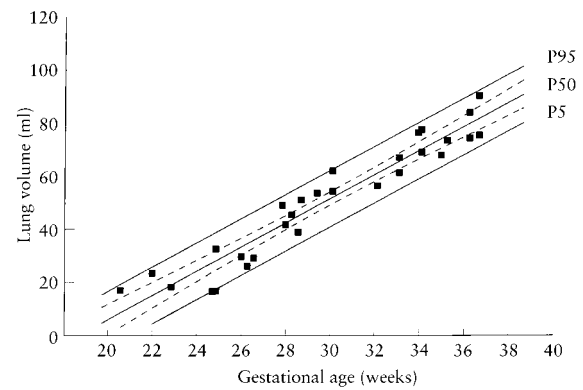


Figure 3 Normal reference ranges (P5, P50 and P95) of fetal lung volume (mL) relative to gestational age (weeks) with 95% confidence intervals for the P50 (dotted curves)<sup>98</sup>.

### Three-dimensional lung volume measurements

Adequate development and available volume are major contributors to total functional lung tissue<sup>94,95</sup>. Recent reports have demonstrated the possibility of fetal lung volume assessment using echo-planar magnetic resonance (MRI)<sup>96</sup>, or three-dimensional ultrasonography<sup>95,97–99</sup> and concluded that these techniques would have useful applications in the prenatal prediction of pulmonary hypoplasia. Fetal lung volume demonstrates a close association with the gestational age<sup>95–99</sup> (Figure 3) and fetal weight<sup>98</sup>. As expected, the right lung volume measured consistently greater than left lung volume<sup>95,99</sup>. Examinations of the fetus *in utero* by MRI are limited because of relatively long acquisition times, artifacts caused by fetal movements, high costs, and limited acceptance of pregnant women, whereas three-dimensional ultrasonography offers a fast and easy means with a high patient acceptability for both surface rendering and determination of fetal organ volume<sup>97–102</sup>. It should be realized that these measurements are indirect determinations of lung volume. In the studies of Lee *et al.*<sup>97</sup> and Laudy *et al.*<sup>98</sup> total fetal volume was calculated by subtracting fetal heart volume from thoracic volume using the three perpendicular transverse, sagittal and frontal planes of the fetus, whereas D'Arcy *et al.*<sup>95</sup> described a procedure based on direct contouring of both fetal lungs. Pöhls and Rempfen<sup>99</sup> introduced another, third method. They performed volumetric evaluation of each separate lung in each of the three perpendicular planes and point at the reduced imaging conditions which may occur in the frontal and sagittal planes of the fetal lung during the second and third trimesters of pregnancy. Underestimation of fetal lung volume in fetuses beyond 34 weeks of gestation occurred since complete volumes could not be obtained due to the swiveling angle of the probe being too small. It was suggested that wider scanning angles and faster scanning procedures are expected to improve the volumetric measurements. The volume data of Pöhls and Rempfen<sup>99</sup> were significantly small compared to data derived by the method of Lee and coworkers<sup>97</sup>. These differences may be due to inclusion of other mediastinal

organs such as the thymus, vessels, trachea and esophagus within the lung volume measurements performed by Lee *et al.*<sup>97</sup> Measurement variation may also be expected from cardiac volume measurements since they involve the beating fetal heart with varying volumes depending on the phase of the cardiac cycle at the time of the measurement.

General limiting factors of three-dimensional ultrasound result from non-favorable scanning conditions, such as oligohydramnios, severe obesity and the absence of tissue borderlines on the one hand and moving artifacts like body movements, breathing motion and heart action, on the other hand<sup>99,100</sup>.

The applicability of three-dimensional ultrasonography in the prediction of lung hypoplasia still needs to be determined.

### Doppler velocimetry

Doppler ultrasound is a technique for measuring the velocity of red blood cells or other moving fluid that reflects echoes from the area of insonation of the ultrasonic beam. The difference ( $f_D$ ) between the frequency of the ultrasound beam ( $f_0$ ) and the received echo is determined by the Doppler equation:  $f_D = (2f_0 \cos \alpha)/c$ , where  $\alpha$  is the solid three-dimensional angle between the ultrasonic beam and the direction of flow and  $c$  is the speed of ultrasound in the medium<sup>103,104</sup>. Flow velocities can be estimated from several Doppler shift frequency components of the Doppler power spectrum. The maximum waveform is the most convenient waveform to use and has been used to determine indices for downstream impedance<sup>105</sup>. These Doppler indices described as the pulsatility index [PI = (PSV - EDV)/TAV]<sup>106</sup>, resistance index [RI = (PSV - EDV)/PSV]<sup>107</sup> or systolic/diastolic ratio (S/D)<sup>108</sup>, are angle-independent and can determine the pulsatility of the Doppler waveform; (PSV, peak systolic velocity; EDV, end-diastolic velocity; TAV, maximum time-averaged velocity). These ratios describe the hemodynamic phenomena both proximal and distal to the point of measurement, such as peripheral resistance, cardiac contraction force, vessel compliance, blood viscosity and heart rate<sup>104</sup>.

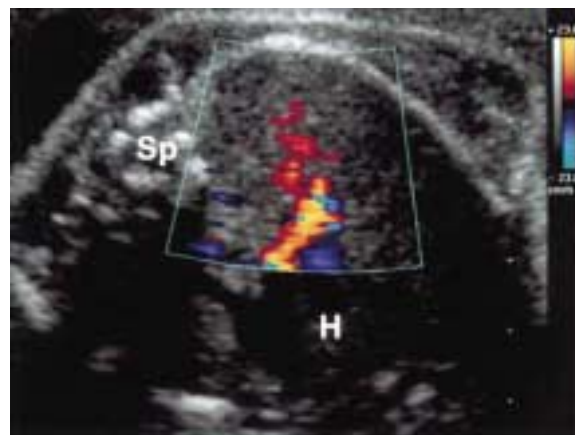
Combined two-dimensional real-time and Doppler sonography offers a unique non-invasive technology for investigation of the circulatory system. Since its introduction, a host of information has appeared relating to the early and late human fetal and placental blood flow under normal<sup>109-114</sup> and abnormal conditions<sup>115-118</sup>. It has been demonstrated that the normally developing fetus during the second half of gestation is characterized by a low fetoplacental vascular resistance with well-defined and reproducible arterial, cardiac and venous flow velocity waveforms<sup>111,119</sup>. The addition of color Doppler has made it possible to determine flow directions at cardiac and extra-cardiac levels<sup>120-122</sup>.

In 1990, Van Eyck *et al.*<sup>123</sup> reported on Doppler evaluation of the fetal ductus arteriosus in the prediction of pulmonary hypoplasia. Ductal blood flow in the fetal lamb is modulated by lung expansion<sup>124</sup>, as a result of opening of the pulmonary vascular bed with subsequent

reduced shunting of right ventricular output through the ductus arteriosus. In the study of Van Eyck<sup>123</sup>, breathing related modulation of blood flow was calculated by subtracting the peak systolic velocity during expiration from the peak systolic velocity during inspiration in the ductus arteriosus. Normal ductal blood flow velocity modulation values were associated with normal neonatal lung performance reflecting a decreased pulmonary vascular resistance during lung expansion. Reduced ductal blood flow velocity modulation values were associated with pulmonary hypoplasia which was hypothesized to result from impaired development of the pulmonary vascular bed.

Reed *et al.*<sup>125</sup> used two-dimensional and pulsed Doppler ultrasound techniques to examine the pulmonary artery and aorta. They revealed that the human fetal pulmonary artery is usually larger than the aortic outflow region (ratio 1.2 : 1), whereas maximal Doppler flow velocities are usually higher in the aortic outflow region (< 31 weeks ratio 1.1 : 1;  $\geq$  31 weeks ratio 1.2 : 1). Maximal and mean pulmonary artery and mean aortic outflow Doppler flow velocities did not change with advancing gestation, whereas maximal aortic outflow Doppler velocity increased with gestation. Overall, volume flow calculated across the pulmonary valve was greater than volume flow across the aortic valve (ratio 1.3 : 1). This is consistent with earlier work<sup>126</sup> demonstrating a 1.3 : 1 ratio of transvalvular volume across the tricuspid compared to the mitral valve and confirms the evidence of right-heart dominance in the human fetus. Blood flow through the lungs was investigated in 38 normal fetuses by St John Sutton *et al.*<sup>127</sup> and was assessed indirectly as the difference between flow in the pulmonary artery and ductal flow. This flow increased exponentially with gestational age by almost four-fold between 18 and 37 weeks of gestation.

The introduction of more sensitive color-coded Doppler systems has led to identification of the human fetal pulmonary circulation<sup>128-131</sup> (Figure 4). Consequently,



**Figure 4** The fetal pulmonary circulation visualized with color Doppler from a cross-section of the fetal chest at the level of the cardiac four chamber view. Sp, fetal spine; H, fetal heart.



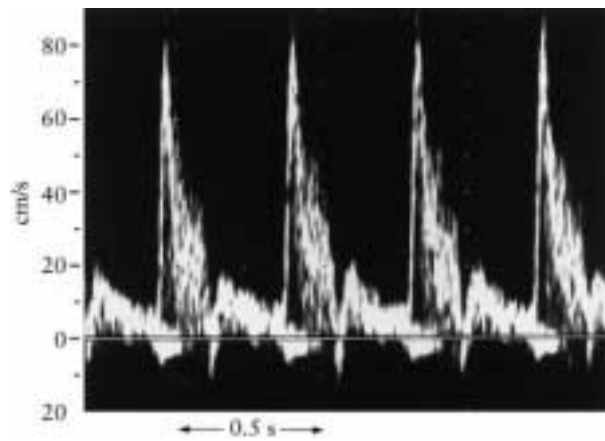


Figure 5 The characteristic Doppler flow velocity waveform obtained from the proximal branch of the pulmonary artery in the human fetus.

Doppler velocimetry has recently been used to study both the arterial<sup>128,132-144</sup> and venous<sup>128,145-149</sup> pulmonary circulations in normal human fetuses. Most Doppler studies of the human fetal pulmonary circulation have been performed in the proximal arterial pulmonary branches and have demonstrated a unique Doppler waveform pattern<sup>132-141</sup> (Figure 5). Agreement exists regarding the nature of the systolic component of the proximal arterial pulmonary waveform, which is characterized by a rapid initial flow acceleration phase followed by an equally rapid deceleration phase. However, opinions differ towards the end-diastolic component, ranging from forward flow being absent<sup>128</sup>, present<sup>134-136,140</sup> or a combination of present and absent flow<sup>133</sup>. Further, discrepancies appear to exist regarding reported peak systolic velocities in the proximal arterial pulmonary branches, which vary from a significant increase<sup>128,133,135,139,140</sup> to gestational age independency<sup>132,134</sup>. Finally, in the same vessel the pulsatility index together with the resistance index<sup>137,138</sup> have been described as remaining constant<sup>128,134,137,138,140,141</sup> or demonstrating a gestational age-related decrease<sup>133,135,138,139</sup>. Probably sample site and equipment-related differences (high-pass filter setting) play a role in the occurrence of these discrepancies. This emphasizes the need for standardizing recording techniques. The physical basis for the shape of the human fetal pulmonary arterial flow velocity waveform remains speculative, and is probably determined by several factors such as vascular pressure, resistance, impedance, vessel compliance and ventricular contractility<sup>128</sup>. This profile partly resembles the waveforms recorded in pulmonary arteries in fetal lambs by chronically implanted cuff-type electromagnetic flow transducers<sup>150</sup>. These profiles show forward flow with a sharp peak early in systole with almost no flow during mid-systole, and reverse flow during late systole and early diastole; throughout the remainder of diastole there is no significant forward or backward flow. This velocity pattern has been explained on the basis of a high (relative to systemic) pulmonary

vascular resistance and the presence of a patent ductus arteriosus<sup>150,151</sup>.

Several studies have reported on Doppler velocimetry of fetal peripheral arterial pulmonary branches in uncomplicated pregnancies<sup>133,138,142-144</sup>. Also here, methodological differences such as defining the Doppler sample site for distal pulmonary arteries have made a comparison difficult. Rasanen *et al.*<sup>133</sup> examined fetal distal branch pulmonary arterial vascular impedance and analyzed the relationships between proximal (after the bifurcation of the main pulmonary artery) and distal (beyond the first bifurcation of the branch pulmonary artery) pulmonary arterial blood velocity waveforms. Achiron *et al.*<sup>143</sup> defined peripheral pulmonary artery blood flow as flow located 10-15 mm beyond the first bifurcation of the pulmonary artery branch. Data in the study by Mitchell *et al.*<sup>138</sup> and Laudy *et al.*<sup>144</sup> were obtained in the middle portion of the fetal lung and by Rizzo *et al.*<sup>142</sup> and Laudy *et al.*<sup>144</sup> in the most distal area of the fetal lung. Nevertheless, Rasanen<sup>133</sup> observed a decrease in pulsatility index until 31 weeks of gestation followed by a constant pattern thereafter, whereas Mitchell<sup>138</sup> and Rizzo<sup>142</sup> established a significant reduction in pulsatility index (or resistance index) throughout the second half of gestational age. Achiron *et al.*<sup>143</sup> showed that the PI did not change with gestation, although there was a statistically significant increase when comparing the period of 14-17 weeks and the remainder of pregnancy. In the study of Laudy *et al.*<sup>144</sup>, the pulsatility index from the middle arterial pulmonary branches showed a significant decrease from 20 to 29 weeks followed by a significant increase from 32 weeks to term and from the distal arterial pulmonary branches a significant decrease from 20 to 26 weeks and a rise from 31 weeks until term. None of these Doppler flow velocity studies could detect significant differences between right and left arterial pulmonary branches.

Increased pulmonary vascular resistance and reduced pulmonary arterial compliance may be the result of underdevelopment and structural changes (decreased total size of the pulmonary vascular bed, reduced vessel count per unit of lung tissue and increased pulmonary vascular muscularization) of the pulmonary vascular bed as seen in postmortem findings of pulmonary hypoplasia<sup>14,15</sup>. These alterations could effect pulmonary blood flow and consequently induce changes in pulmonary flow velocity waveforms as recorded by Doppler ultrasonography. From this point of view, it has been hypothesized that fetal arterial pulmonary Doppler velocimetry may play a role in the prediction of pulmonary hypoplasia. So far, only a few papers including two abstracts have dealt with this particular issue<sup>138-141,143,152,153</sup>. Laudy and coworkers<sup>152</sup> observed a significant reduction in pulmonary artery systolic and diastolic velocities in a case of fetal pulmonary hypoplasia due to bilateral obstructive uropathy. Further, there were marked changes in the shape of the pulmonary arterial waveform, characterized by a second needle-shaped peak occurring during mid-systole, which was even higher than the first systolic peak. The presence of reduced volume flow and/or raised downstream impedance

may have been responsible for these Doppler velocity changes<sup>152</sup>. Mitchell and coworkers<sup>138</sup> studied a group of 10 fetuses with multicystic dysplastic kidney disease and pulmonary hypoplasia. This group did not have significantly different Doppler waveforms in the main pulmonary artery and in the proximal pulmonary arteries compared to the control group. However, Doppler recordings from the peripheral pulmonary arteries demonstrated a high-resistance pattern quite different from that of normal fetuses. Achiron *et al.*<sup>143</sup> demonstrated that PI measurements from the right peripheral pulmonary artery in four fetuses with proven lung hypoplasia were within the 95% confidence limits of those for normal fetuses ( $n = 96$ ). Based on these preliminary data, they suggest that the PI of the lung circulation is a poor indicator of lung hypoplasia. Two abstracts have appeared on the value of arterial pulmonary Doppler flow cases of lung hypoplasia associated with diaphragmatic hernia<sup>140,141</sup>. The first<sup>140</sup> reported reversed diastolic flow in the right pulmonary artery from three fetuses with diaphragmatic hernia, all of which died after birth from lung hypoplasia. In the second<sup>141</sup> five fetuses were examined with congenital diaphragmatic hernia, although the exact sampling size was not given. A normal or reduced pulsatility index was shown in two of these fetuses who died from hypoplasia, whereas increased PI was found in the other three fetuses which underwent surgery and had a good outcome. More recently, two other reports have questioned the usefulness of Doppler velocimetry of the proximal arterial pulmonary circulation in the prediction of pulmonary hypoplasia<sup>139,153</sup>. Yoshimura *et al.*<sup>139</sup> investigated five fetuses at risk for pulmonary hypoplasia (two hydrops fetalis, two thanatophoric dwarfism and one bilateral agenesis). They revealed that pulsatility index values were high and the peak systolic flow was significantly lower than in the healthy fetuses. In the group of Chaoui *et al.*<sup>153</sup> nine cases were examined with autopsy-proven lung hypoplasia after termination of pregnancy (19–23 weeks, four bilateral renal malformations, two diaphragmatic hernia, three miscellaneous malformations including heart defects). Normal values were found in the end-systolic reverse flow in all cases, decreased peak systolic velocity in three of nine cases and increased pulsatility index in six of nine cases. The latter six cases were all fetuses with renal malformations and diaphragmatic hernia and it was suggested that increased PI is the best parameter to detect flow abnormalities in this condition. It should be pointed out that all these reports present data from very small heterogeneous patient series and do not represent cases of premature rupture of membranes, which is considered one of the most common causes of pulmonary hypoplasia<sup>138–141,143,152,153</sup>. Nevertheless, they suggest that Doppler velocity waveform changes – although different in each of the papers – may occur in well-established cases of pulmonary hypoplasia. However, whether this implies that Doppler assessment of the fetal arterial pulmonary circulation allows accurate differentiation between lethal and non-lethal pulmonary hypoplasia, needs to be substantiated in prospective larger series. Only then can a more realistic view of the clinical

significance of Doppler velocimetry in the detection of lethal lung hypoplasia be obtained.

## REFERENCES

- 1 Laudy JAM, Wladimiroff JW. The fetal lung 1: developmental aspects. *Ultrasound Obstet Gynecol* 2000; 16: 284–90
- 2 Greenough A. Pulmonary hypoplasia. In: Chervenak FA, Isaacson GC, Campbell S. *Ultrasound in Obstetrics and Gynecology*. Boston: Little, Brown and Company, Corp, 1993: 903–8
- 3 Page DV, Stocker JT. Anomalies associated with pulmonary hypoplasia. *Am Rev Respir Dis* 1982; 125: 216–21
- 4 Thurlbeck WM. Prematurity and the developing lung. *Clin Perinatol* 1992; 19: 497–519
- 5 Lauria MR, Gonik B, Romero R. Pulmonary hypoplasia: pathogenesis, diagnosis and antenatal prediction. *Obstet Gynecol* 1995; 86: 466–75
- 6 Wigglesworth JS, Desai R, Guerrini P. Fetal lung hypoplasia: biochemical and structural variations and their possible significance. *Arch Dis Child* 1981; 56: 606–15
- 7 Chamberlain D, Hislop A, Hey E, Reid L. Pulmonary hypoplasia in babies with severe rhesus isoimmunisation: a quantitative study. *J Pathol* 1977; 122: 43–52
- 8 Nakamura Y, Harada K, Yamamoto I, Uemura Y, Okamoto K, Fukuda S, Hashimoto T. Human pulmonary hypoplasia. Statistical, morphological, morphometric and biochemical study. *Arch Pathol Lab Med* 1992; 116: 635–42
- 9 Kitagawa M, Hislop A, Boyden EA, Reid L. Lung hypoplasia in congenital diaphragmatic hernia. A quantitative study of airway, artery, and alveolar development. *Br J Surg* 1971; 58: 342–6
- 10 Hislop A, Hey E, Reid L. The lungs in congenital bilateral renal agenesis and dysplasia. *Arch Dis Child* 1979; 54: 32–8
- 11 Reale FR, Esterly JR. Pulmonary hypoplasia: a morphometric study of the lungs of infants with diaphragmatic hernia, anencephaly, and renal malformations. *Pediatrics* 1973; 51: 91–6
- 12 Nakamura Y, Yamamoto I, Funatsu Y, Motomura K, Fukuda S, Hashimoto T, Morimatsu M. Decreased surfactant level in the lung with oligohydramnios: a morphometric and biomedical study. *J Pediatr* 1988; 112: 471–4
- 13 Nakamura Y, Funatsu Y, Yamamoto I, Yamana K, Nishimura T, Hosokawa Y, Fukuda S, Nakashima H, Tsunosue M, Hashimoto T, Tanaka Y, Nakashima T. Potter's syndrome associated with renal agenesis or dysplasia. *Arch Pathol Lab Med* 1985; 109: 441–4
- 14 Levin DL. Morphologic analysis of the pulmonary vascular bed in congenital left-sided diaphragmatic hernia. *J Pediatr* 1978; 92: 805–9
- 15 Barth PJ, Rüschoff J. Morphometric study on pulmonary arterial thickness in pulmonary hypoplasia. *Pediatr Pathol* 1992; 12: 653–63
- 16 Tenbrinck R, Gaillard JLJ, Tibboel D, Kluth D, Lachmann B, Molenaar JC. Pulmonary vascular abnormalities in experimentally induced congenital diaphragmatic hernia in rats. *J Pediatr Surg* 1992; 27: 862–5
- 17 Knox WF, Barson AJ. Pulmonary hypoplasia in a regional perinatal unit. *Early Hum Dev* 1986; 114: 33–42
- 18 Moessinger AC, Santiago A, Paneth NS, Rey HR, Blanc WA, Driscoll JM Jr. Time trends in necropsy prevalence and birth prevalence of lung hypoplasia. *Pediatr Perinat Epidemiol* 1989; 3: 421–31
- 19 Askenazi SS, Perlman M. Pulmonary hypoplasia: lung weight and radial alveolar count as criteria of diagnosis. *Arch Dis Child* 1979; 54: 614–8
- 20 Husain AN, Hessel RG. Neonatal pulmonary hypoplasia: an autopsy study of 25 cases. *Pediatr Pathol* 1993; 13: 475–84
- 21 Wigglesworth JS, Desai R. Is fetal respiratory function a major determinant of perinatal survival? *Lancet* 1982; 30: 264–7

- 22 Nimrod C, Varela-Gittings F, Machin G, Campbell D, Wesenberg R. The effect of very prolonged membrane rupture on fetal development. *Am J Obstet Gynecol* 1984; 148: 540-3
- 23 Thibeault DW, Beatty EC, Hall RT, Bowen SK, O'Neill DH. Neonatal pulmonary hypoplasia with premature rupture of fetal membranes and oligohydramnios. *J Pediatr* 1985; 107: 273-7
- 24 Van Dongen PWJ, Antonissen J, Jongsma HW, Sporcken JMJ, Hein PR. Lethal lung hypoplasia in infants after prolonged rupture of membranes. *Eur J Obstet Gynecol Reprod Biol* 1987; 25: 287-92
- 25 Rotschild A, Ling EW, Puterman ML, Farquharson D. Neonatal outcome after prolonged preterm rupture of the membranes. *Am J Obstet Gynecol* 1990; 162: 46-52
- 26 McIntosh N, Harrison A. Prolonged premature rupture of membranes in the preterm infant: a 7 year study. *Eur J Obstet Gynecol Reprod Biol* 1994; 57: 1-6
- 27 Kilbride HW, Yeast J, Thibeault DW. Defining limits of survival: lethal pulmonary hypoplasia after premature rupture of membranes. *Am J Obstet Gynecol* 1996; 175: 675-81
- 28 Swischuk LE, Richardson J, Nichols MM, Ingman MJ. Primary pulmonary hypoplasia in the neonate. *J Pediatr* 1979; 95: 573-7
- 29 Swischuk LE, Richardson CJ, Nichols MM, Ingman MJ. Bilateral pulmonary hypoplasia in the neonate. *Am J Roentgenol* 79; 133: 1057-63
- 30 Inselman LS, Mellins RB. Growth and development of the lung. *J Pediatr* 1981; 98: 1-15
- 31 Wigglesworth JS. Pathology of the lung in the fetus and the neonate, with particular reference to problems of growth and maturation. *Histopathol* 1987; 11: 671-89
- 32 Sherer DM, Davis JM, Woods JR. Pulmonary hypoplasia: a review. *Obstet Gynecol Surv* 1990; 45: 792-803
- 33 Castillo RA, Devoe LD, Falls G, Holzman GB, Hadi HA, Fadel HE. Pleural effusions and pulmonary hypoplasia. *Am J Obstet Gynecol* 1987; 157: 1252-5
- 34 Potter EL. Bilateral renal agenesis. *J Pediatr* 1946; 29: 68-76
- 35 Perlman M, Levin M. Fetal pulmonary hypoplasia, anuria and oligohydramnios. Clinicopathologic observations and review of literature. *Am J Obstet Gynecol* 1974; 118: 1119-23
- 36 Thomas IT, Smith DW. Oligohydramnios, cause of the nonrenal features of Potter's syndrome, including pulmonary hypoplasia. *J Pediatr* 1974; 84: 811-4
- 37 Perlman M, Williams J, Hirsch M. Neonatal pulmonary hypoplasia after prolonged leakage of amniotic fluid. *Arch Dis Child* 1976; 51: 349-53
- 38 Tibboel D, Gaillard JJJ, Spritzer R, Wallenburg HCS. Pulmonary hypoplasia secondary to oligohydramnios with very premature rupture of fetal membranes. *Eur J Pediatr* 1990; 149: 496-9
- 39 Bhutani VK, Abbasi S, Weiner S. Neonatal pulmonary manifestations due to prolonged amniotic leak. *Am J Perinatol* 1986; 3: 225-30
- 40 Bain AD, Scott JS. Renal agenesis and severe urinary tract dysplasia. A review of 50 cases with particular reference to the associated anomalies. *Br Med J* 1960; 1: 841-6
- 41 Fitch N, Lachance RC. The pathogenesis of Potter's syndrome of renal agenesis. *Can Med Assoc J* 1972; 107: 653-6
- 42 Ratten G, Beischer N, Fortune D. Obstetric complications when the fetus has Potter's syndrome. *Am J Obstet Gynecol* 1973; 115: 890-5
- 43 Potter EL. Facial characteristics of infants with bilateral renal agenesis. *Am J Obstet Gynecol* 1946; 51: 885-8
- 44 Hack M, Jaffe J, Blankenstein R, Goodman M, Brish M. Familial aggregation in bilateral renal agenesis. *Clin Genet* 1974; 5: 173-7
- 45 Scott RJ, Goodburn SF. Potter's syndrome in the second trimester - Prenatal screening and pathological findings in 60 cases of oligohydramnios sequence. *Prenat Diagn* 1995; 15: 519-25
- 46 Bain AD, Smith II, Gauld IK. Newborn after prolonged leakage of liquor amnii. *Br Med J* 1964; 2: 598-9
- 47 Thibeault DW, Beatty EC, Hall RT, Bowen SK. Prolonged rupture of fetal membranes (PROM) and hypoplastic lungs without the oligohydramnios tetrad. *Pediatr Res* 1983; 17: 392A
- 48 Johnson JWC, Daikoku NH, Niebyl JR, Johnson TRB, Khouzami VA, Witter FR. Premature rupture of the membranes and prolonged latency. *Obstet Gynecol* 1981; 57: 547-56
- 49 Rudd EG. Premature rupture of the membranes. A review. *J Reprod Med* 1985; 30: 843-8
- 50 Garite TJ, Freeman RK, Linzey EM, Braly PS, Dorchester WL. Prospective randomized study of corticosteroids in the management of premature rupture of the membranes and the premature gestation. *Am J Obstet Gynecol* 1981; 141: 508-15
- 51 Morales WJ, Thomas T. Premature rupture of membranes at <25 weeks: a management dilemma. *Am J Obstet Gynecol* 1993; 168: 503-7
- 52 Beydoun SN, Yasin SY. Premature rupture of the membranes before 28 weeks: conservative management. *Am J Obstet Gynecol* 1986; 155: 471-9
- 53 Taylor J, Garite TJ. Premature rupture of membranes before fetal viability. *Obstet Gynecol* 1984; 64: 615-20
- 54 Moessinger AC, Collins MH, Blanc WA, Rey HR, James LS. Oligohydramnios-induced lung hypoplasia: the influence of timing and duration in gestation. *Pediatr Res* 1986; 20: 951-4
- 55 Leonidas JC, Bhan I, Beatty EC. Radiographic chest contour and pulmonary air leaks in oligohydramnios-related pulmonary hypoplasia (Potter's syndrome). *Invest Radiol* 1982; 17: 6-10
- 56 Leonidas JC, Fellows RA, Hall RT, Rhodes PG, Beatty EC. Value of chest radiography in the diagnosis of Potter's syndrome at birth. *Am J Roentgenol* 1975; 123: 716-23
- 57 Langer R, Kaufmann HJ, Vogel M, Vocks M. Röntgenbefunde bei primärer bilateraler Lungenhypoplasie - Korrelation mit pathologisch-anatomischen Befunden. *Klin Pädiat* 1985; 197: 427-30
- 58 Wenstrom KD. Pulmonary hypoplasia and deformities related to premature rupture of membranes. *Obstet Gynecol Clin North Am* 1992; 19: 397-408
- 59 Wigglesworth JS, Desai R. Use of DNA estimation for growth assessment in normal and hypoplastic fetal lungs. *Arch Dis Child* 1981; 56: 610-05
- 60 Emery JL, Mithal A. The number of alveoli in the terminal respiratory unit of man during late intrauterine life and childhood. *Arch Dis Child* 1960; 35: 544-7
- 61 Cooney TP, Thurlbeck WM. The radial alveolar count method of Emery and Mithal: a reappraisal 2 - Intrauterine and early postnatal lung growth. *Thorax* 1982; 37: 580-3
- 62 Betz P, Nerlich A, Bussler J, Hausmann R, Eisenmenger W. Radial alveolar count as a tool for the estimation of fetal age. *Int J Legal Med* 1997; 110: 52-4
- 63 Vergani P, Ghidini A, Locatelli A, Cavalonne MI, Ciarla I, Cappellini A, Lapinski RH. Risk factors for pulmonary hypoplasia in second trimester premature rupture of membranes. *Am J Obstet Gynecol* 1994; 170: 1359-64
- 64 Roberts AB, Mitchell J. Pulmonary hypoplasia and fetal breathing in preterm premature rupture of membranes. *Early Hum Dev* 1995; 41: 27-37
- 65 D'Alton M, Mercer B, Riddick E, Dudley D. Serial thoracic versus abdominal circumference ratios for the prediction of pulmonary hypoplasia in premature rupture of the membranes remote from term. *Am J Obstet Gynecol* 1992; 166: 658-63
- 66 Moore TR, Longo J, Leopold GR, Casola G, Gosink BB. The reliability and predictive value of an amniotic fluid scoring system in severe second-trimester oligohydramnios. *Obstet Gynecol* 1989; 73: 739-42
- 67 Chamberlain PF, Manning FA, Morrison I, Harman CR, Lange IR. Ultrasound evaluation of amniotic fluid, I The relationship of marginal and decreased amniotic fluid volumes to perinatal outcome. *Am J Obstet Gynecol* 1984; 150: 245-9
- 68 Nimrod C, Nicholson S, Davies D, Harder J, Dodd G, Dauve R. Pulmonary hypoplasia testing in clinical obstetrics. *Am J Obstet Gynecol* 1988; 158: 277-80

- 69 Blott M, Nicolaides KH, Gibb D, Greenough A, Moscoso G, Campbell S. Fetal breathing movements as predictor of favourable pregnancy outcome after oligohydramnios due to membrane rupture in second trimester. *Lancet* 1987; i: 129-31
- 70 Blott M, Greenough A, Nicolaides KH, Campbell S. The ultrasonography assessment of the fetal thorax and fetal breathing movements in the prediction of pulmonary hypoplasia. *Early Hum Dev* 1990; 21: 143-51
- 71 Greenough A, Blott M, Nicolaides K, Campbell S. Interpretation of fetal breathing movements in oligohydramnios due to membrane rupture. *Lancet* 1988; i: 182-3
- 72 Fox HE, Moessinger AC. Fetal breathing movements and lung hypoplasia: Preliminary human observations. *Am J Obstet Gynecol* 1985; 151: 531-3
- 73 Moessinger AC, Higgins A, Fox HE, Rey HR. Fetal breathing movements are not a reliable predictor of continued lung development in pregnancies complicated by oligohydramnios. *Lancet* 1987; ii: 1297-9
- 74 Roberts AB, Mitchell JM. Direct ultrasonographic measurement of fetal lung length in normal pregnancies complicated by prolonged rupture of membranes. *Am J Obstet Gynecol* 1990; 160: 1560-6
- 75 Sival DA, Visser GHA, Prechtl HFR. Fetal breathing movements are not a good indicator of lung development after premature rupture of membranes and oligohydramnios - a preliminary study. *Early Hum Dev* 1992; 28: 133-43
- 76 Ohlsson A, Fong K, Hannah M. Prediction of lethal pulmonary hypoplasia and chorioamnionitis by assessment of fetal breathing. *Br J Obstet Gynaecol* 1991; 98: 692-7
- 77 Greenough A. Opinion: Fetal respiratory activity and pulmonary hypoplasia. *Ultrasound Obstet Gynecol* 1993; 3: 159-62
- 78 Fisk NM, Talbert DG, Nicolini U, Vaughan J, Rodeck C. Fetal breathing movements in oligohydramnios are not increased by amniocentesis. *Br J Obstet Gynaecol* 1992; 99: 464-8
- 79 Fong K, Ohlsson A, Zalev A. Fetal thoracic circumference: a prospective cross-sectional study with real-time ultrasound. *Am J Obstet Gynecol* 1988; 158: 1154-60
- 80 Chitkara U, Rosenberg J, Chervenak FA, Berkowitz GS, Levine R, Fagerstrom RM, Walker B, Berkowitz RL. Prenatal sonographic assessment of fetal thorax: normal values. *Am J Obstet Gynecol* 1987; 156: 1069-74
- 81 DeVore GR, Horenstein J, Platt LD. Fetal echocardiography. VI. Assessment of cardiothoracic disproportion - A new technique for diagnosis of thoracic hypoplasia. *Am J Obstet Gynecol* 1986; 155: 1066-71
- 82 Hilpert PL, Pretorius DH. The thorax. In: Nyberg DA, Mahony BS, Pretorius DH, eds. *Diagnostic Ultrasound of Fetal Anomalies Text and Atlas*. Chicago: Year Book Medical Publishers, Inc., 1990: 262-99
- 83 Nimrod C, Davies D, Iwanicki S, Harder J, Persaud D, Nicholson S. Ultrasound prediction of pulmonary hypoplasia. *Obstet Gynecol* 1986; 68: 495-7
- 84 Songster GS, Gray DL, Crane JP. Prenatal prediction of lethal pulmonary hypoplasia using ultrasonic fetal chest circumference. *Obstet Gynecol* 1989; 73: 261-6
- 85 Ohlsson A, Fong K, Rose T, Hannah M, Black D, Heyman Z, Gonen R. Prenatal ultrasonic prediction of autopsy-proven pulmonary hypoplasia. *Am J Perinatol* 1992; 9: 334-7
- 86 Vintzileos AM, Campbell WA, Rodis JF, Nochimson DJ, Pinette MG, Petrikovsky BM. Comparison of six different ultrasonographic methods for predicting lethal fetal pulmonary hypoplasia. *Am J Obstet Gynecol* 1989; 161: 606-12
- 87 Yoshimura S, Masuzaki H, Gotoh H, Fukuda H, Ishimaru T. Ultrasonographic prediction of lethal pulmonary hypoplasia: Comparison of eight different ultrasonographic parameters. *Am J Obstet Gynecol* 1996; 175: 477-83
- 88 Merz E, Miric-Tesanic D, Bahlmann F, Weber G, Halermann C. Prenatal sonographic chest and lung measurements for predicting severe pulmonary hypoplasia. *Prenat Diagn* 1999; 19: 614-9
- 89 Callan NA, Colmorgen GHC, Weiner S. Lung hypoplasia and prolonged preterm ruptured membranes: a case report with implications for possible prenatal ultrasonic diagnosis. *Am J Obstet Gynecol* 1985; 151: 756-7
- 90 Johnson A, Callan NA, Bhutani VK, Colmorgen GHC, Weiner S, Bolognese RJ. Ultrasonic ratio of fetal thoracic to abdominal circumference: an association with fetal pulmonary hypoplasia. *Am J Obstet Gynecol* 1987; 157: 764-9
- 91 Vintzileos AM. Opinion: prenatal detection of lethal pulmonary hypoplasia. *Ultrasound Obstet Gynecol* 1996; 7: 163-4
- 92 Harstad TW, Twickler DM, Leveno KJ, Brown CEL. Antepartum prediction of pulmonary hypoplasia: an elusive goal? *Am J Perinatol* 1993; 10: 8-11
- 93 Fox HE, Timor-Trisch IE, Marks F, Stolar CJH. Fetal upper respiratory tract function in cases of antenatally diagnosed congenital diaphragmatic hernia: preliminary observations. *Ultrasound Obstet Gynecol* 1993; 3: 164-7
- 94 Langston C, Kida K, Reed M, Thurlbeck WM. Human lung growth in late gestation and in the neonate. *Am Rev Respir Dis* 1984; 129: 607-13
- 95 D'Arcy ThJ, Hughes SW, Chiu WSC, Clark T, Milner AD, Saunders J, Maxwell D. Estimation of fetal lung volume using enhanced 3-dimensional ultrasound: a new method and first result. *Br J Obstet Gynaecol* 1996; 103: 1015-20
- 96 Baker PN, Johnson IR, Gowland PA, Freeman A, Adams V, Mansfield P. Estimation of fetal lung volume using echo-planar magnetic resonance imaging. *Obstet Gynecol* 1994; 83: 951-4
- 97 Lee A, Kratochwil A, Stümpflen L, Deutinger J, Bernaschek G. Fetal lung volume determination by three-dimensional ultrasonography. *Am J Obstet Gynecol* 1996; 175: 588-92
- 98 Laudy JAM, Janssen MMM, Struijk PC, Stijnen T, Wladimiroff JW. Three-dimensional ultrasonography of normal fetal lung volume; a preliminary study. *Ultrasound Obstet Gynecol* 1998; 11: 13-6
- 99 Pöhls UG, Rempen A. Fetal lung volumetry by three-dimensional ultrasound. *Ultrasound Obstet Gynecol* 1998; 11: 6-12
- 100 Steiner H, Staudach A, Spitzer D, Schaffer H. Three-dimensional ultrasound in obstetrics and gynaecology: technique, possibilities and limitations. *Hum Reprod* 1994; 9: 1773-8
- 101 Nelson TR, Pretorius DH. Three-dimensional ultrasound of fetal surface features. *Ultrasound Obstet Gynecol* 1992; 2: 166-74
- 102 Chang FM, Hsu KF, Ko HC, Yao BL, Chang CH, Yu CH, Liang RI, Chen HY. Fetal heart volume assessment by three-dimensional ultrasound. *Ultrasound Obstet Gynecol* 1997; 9: 42-8
- 103 Huhta JC. Future Directions in noninvasive Doppler evaluation of the fetal circulation. *Cardiol Clin* 1989; 7: 239-53
- 104 Maulik D. Principles of Doppler signal processing and hemodynamic analysis. In: Copel JA, Reed KL. eds. *Doppler Ultrasound in Obstetrics and Gynecology*. New York: Raven Press Ltd, 1995: 1-18
- 105 Ursem NTC, Brinkman HJF, Struijk PC, Hop WCJ, Kempinski MH, Keller BB, Wladimiroff JW. Umbilical artery waveform analysis based on maximum, mean and mode velocity in early human pregnancy. *Ultrasound Med Biol* 1998; 24: 1-7
- 106 Gosling RG, King DH. Ultrasound angiology. In: Marcus AW, Adamson J. eds. *Arteries and Veins*. Edinburgh: Churchill-Livingstone, 1975: 61-98
- 107 Pourcelot L. Applications clinique de l'examen Doppler transcutané. In: Pourcelot L. ed. *Velocimetric Ultrasonore Doppler*. Paris: INSERM, 1974: 213
- 108 Stuart B, Drumm J, FitzGerald DE, Diugnan NM. Fetal blood flow velocity waveforms in normal pregnancy. *Br J Obstet Gynaecol* 1980; 87: 780-5
- 109 Van Splunder P, Huisman TWA, de Ridder MAJ, Wladimiroff JW. Fetal venous and arterial flow velocity wave forms between eight and twenty weeks of gestation. *Pediatr Res* 1996; 40: 158-62
- 110 Van Splunder P, Stijnen T, Wladimiroff JW. Fetal atrioventricular flow-velocity waveforms and their relation to arterial and venous flow-velocity waveforms at 8 to 20 weeks of gestation. *Circulation* 1996; 94: 1372-8

- 111 Hecher K, Campbell S, Snijders R, Nicolaides K. Reference ranges for fetal venous and atrioventricular blood flow parameters. *Ultrasound Obstet Gynecol* 1994; 4: 381-90
- 112 Huisman TWA, Stewart PA, Wladimiroff JW. Doppler assessment of the normal early circulation. *Ultrasound Obstet Gynecol* 1992; 2: 300-5
- 113 Van der Mooren K, Barendregt LG, Wladimiroff JW. Fetal atrioventricular and outflow tract flow velocity waveforms during normal second half of pregnancy. *Am J Obstet Gynecol* 1991; 165: 668-74
- 114 Campbell S, Griffin DR, Pearce JMF, Diaz-Recasens J, Cohen-Overbeek TE, Willson K. New Doppler technique for assessing uteroplacental blood flow. *Lancet* 1983; 1: 675-7
- 115 Hecher K, Campbell S, Doyle P, Harrington K, Nicolaides K. Assessment of fetal compromise by Doppler ultrasound investigation of the fetal circulation. *Circulation* 1995; 91: 129-38
- 116 Groenenberg IAL, Wladimiroff JW, Hop WCJ. Fetal cardiac and peripheral arterial flow velocity waveforms in intrauterine growth retardation. *Circulation* 1989; 81: 1711-7
- 117 Tonge HM, Wladimiroff JW, Noordam MJ, Van Kooten C. Blood flow velocity waveforms in the descending aorta of the human fetus in the third trimester of pregnancy: comparison between normal and growth-retarded fetuses. *Obstet Gynecol* 1986; 67: 851-5
- 118 Wladimiroff JW, Van der Wijngaard JAGW, Degani S, Noordam MJ, Van Eyck J, Tonge HM. Cerebral and umbilical arterial blood flow velocity waveforms in normal and growth retarded pregnancies. *Obstet Gynecol* 1987; 69: 705-9
- 119 Trudinger BJ. The umbilical circulation. *Sem Perinatol* 1987; 11: 311-21
- 120 DeVore GR. Color Doppler examination of the outflow tracts of the fetal heart: a technique for identification of cardiovascular malformations. *Ultrasound Obstet Gynecol* 1994; 4: 463-71
- 121 Stewart PA, Wladimiroff JW. Fetal echocardiography and color Doppler flow imaging: the Rotterdam experience. *Ultrasound Obstet Gynecol* 1993; 3: 168-75
- 122 Noordam MJ, Heydanus R, Hop WCJ, Hoekstra FME, Wladimiroff JW. Doppler colour flow imaging of fetal intracerebral arteries and umbilical artery in the small for gestational age fetus. *Br J Obstet Gynaecol* 1994; 101: 504-8
- 123 Van Eyck J, van der Mooren K, Wladimiroff JW. Ductus arteriosus flow velocity modulation by breathing movements as a measure of fetal lung development. *Am J Obstet Gynecol* 1990; 163: 558-66
- 124 Assali NS, Morris JA, Beck R. Cardiovascular hemodynamics in the fetal lamb before and after lung expansion. *Am J Physiol* 1965; 208: 122-9
- 125 Reed KL, Anderson CF, Shenker L. Fetal pulmonary artery and aorta: two-dimensional Doppler echocardiography. *Obstet Gynecol* 1987; 69: 175-8
- 126 Reed KL, Meijboom EJ, Sahn DJ, Scagnelli SA, Valdes Cruz LM, Shenker L. Cardiac Doppler flow velocities in human fetuses. *Circulation* 1986; 73: 41-6
- 127 St John Sutton M, Groves A, MacNeill A, Sharland G, Allan L. Assessment of changes in blood flow through the lungs and foramen ovale in the normal human fetus with gestational age: a prospective Doppler echocardiography study. *Br Heart J* 1994; 71: 232-7
- 128 Emerson DS, Cartier MS. The fetal pulmonary circulation. In: Copel JA, Reed KL. eds. *Doppler Ultrasound in Obstetrics and Gynecology*. New York: Raven Press Ltd, 1995: 307-23
- 129 DeVore GR. The use of color Doppler imaging to examine the fetal heart. Normal and pathologic anatomy. In: Jaffe R, Warsof SI. eds. *Color Doppler Imaging in Obstetrics and Gynecology*. New York: McGraw-Hill, 1992: 126-9
- 130 DeVore GR, Horenstein J. Simultaneous Doppler recording of the pulmonary artery and vein. *J Ultrasound Med* 1993; 12: 669-71
- 131 Anteby EY, Shimonovitz S, Yagel S. Fetal echocardiography: the identification of two of the pulmonary veins from the four-chamber view during the second trimester of pregnancy. *Ultrasound Obstet Gynecol* 1994; 4: 208-10
- 132 Stanley JR, Veille JC, Zaccaro D. Description of right pulmonary artery blood flow by Doppler echocardiography in the normal human fetus 17-40 weeks gestation. *J Matern Fetal Invest* 1994; 4: S14
- 133 Rasanen J, Huhta JC, Weiner S, Wood DC, Ludomirski A. Fetal branch pulmonary arterial vascular impedance during the second half of pregnancy. *Am J Obstet Gynecol* 1996; 174: 1441-9
- 134 Laudy JAM, De Ridder MAJ, Wladimiroff JW. Doppler velocimetry in branch pulmonary arteries of normal human fetuses during the second half of gestation. *Pediatr Res* 1997; 41: 897-901
- 135 Chaoui R, Taddei F, Rizzo G, Bast C, Lenz F, Bollmann R. Doppler echocardiography of the main stems of the pulmonary arteries in the normal human fetus. *Ultrasound Obstet Gynecol* 1997; 10: 1-7
- 136 Choi JY, Park JD, Jung MJ, Kim HS. Doppler flow velocity waveforms of the human fetal ductus arteriosus and branch pulmonary artery. *J Korean Med Sci* 1997; 12: 409-15
- 137 Cynober E, Cabrol D, Haddad B, Gabriel C, Moretti JL, Gamhui S, Jeny R. Fetal pulmonary artery Doppler waveform: a preliminary report. *Fetal Diagn Ther* 1997; 12: 226-31
- 138 Mitchell JH, Roberts AB, Lee A. Doppler waveforms from the pulmonary arterial system in normal fetuses and those with pulmonary hypoplasia. *Ultrasound Obstet Gynecol* 1997; 11: 1-6
- 139 Yoshimura S, Masuzaki H, Miura K, Muta K, Gotoh H, Ishimaru T. Diagnosis of fetal pulmonary hypoplasia by measurement of blood flow velocity waveforms of pulmonary arteries with Doppler ultrasonography. *Am J Obstet Gynecol* 1999; 180: 441-6
- 140 Tulzer G, Arzt W, Tews G, Schmitt K, Huhta JC. Peripheral pulmonary artery Doppler in normal fetuses and fetuses with hypoplastic lungs. *J Matern Fetal Invest* 1993; 3: 199
- 141 Twining P. The value of fetal pulmonary artery flow as a predictor of pulmonary hypoplasia in congenital diaphragmatic hernia. *Ultrasound Med Biol* 1997; 23: S106
- 142 Rizzo G, Capponi A, Chaoui R, Taddei F, Arduini D, Romanini C. Blood flow velocity waveforms from peripheral pulmonary arteries in normally grown and growth-retarded fetuses. *Ultrasound Obstet Gynecol* 1996; 8: 87-92
- 143 Achiron R, Heggesh J, Mashiach S, Lipitz S, Rotstein Z. Peripheral right pulmonary artery blood flow velocimetry: Doppler sonographic study of normal and abnormal fetuses. *J Ultrasound Med* 1998; 17: 687-92
- 144 Laudy JAM, de Ridder MAJ, Wladimiroff JW. Human fetal pulmonary artery velocimetry: repeatability and normal values with emphasis on middle and distal pulmonary vessels. *Ultrasound Obstet Gynecol* 2000; 15: 476-86
- 145 Laudy JAM, Huisman TWA, de Ridder MAJ, Wladimiroff JW. Normal fetal pulmonary venous blood flow velocity. *Ultrasound Obstet Gynecol* 1995; 6: 277-81
- 146 Better DJ, Kaufman S, Allan L. The normal pattern of pulmonary venous flow on pulsed Doppler examination of the human fetus. *J Am Soc Echocardiogr* 1996; 9: 281-5
- 147 Paladini D, Palmieri S, Celentano E, Guida F, Salviati M, Morra T, Martinelli P. Pulmonary venous blood flow in the human fetus. *Ultrasound Obstet Gynecol* 1997; 10: 27-31
- 148 Laudy JAM, Ursem NTC, Mulder PGH, Wladimiroff JW. Doppler velocimetry of normal human fetal venous intrapulmonary branches. *Ultrasound Obstet Gynecol* 1999; 13: 247-54
- 149 Hong Y, Choi J. Doppler study on pulmonary venous flow in the human fetus. *Fetal Diagn Ther* 1999; 14: 86-91

- 150 Lewis AB, Heymann MA, Rudolph AM. Gestational changes in pulmonary vascular responses in fetal lambs in utero. *Circ Res* 1976; 39: 536-41
- 151 Rudolph AM. Fetal and neonatal pulmonary circulation. *Ann Rev Physiol* 1979; 41: 383-95
- 152 Laudy JAM, Gaillard JLJ, Van den Anker JN, Tibboel D, Wladimiroff JW. Doppler ultrasound imaging: a new technique to detect lung hypoplasia before birth? *Ultrasound Obstet Gynecol* 1996; 7: 189-92
- 153 Chaoui R, Kalache K, Tennstedt C, Lenz F, Vogel M. Pulmonary arterial Doppler velocimetry in fetuses with hypoplasia. *Eur J Obstet Gynecol Repr Biol* 1999; 84: 179-85