



Case report

Delayed life-threatening subdural hematoma after minor head injury in a patient with severe coagulopathy: a case report

Marc Engelen¹, Paul J Nederkoorn¹, Marion Smits² and Diederik van de Beek^{1*}

Addresses: ¹Department of Neurology, Academic Medical Center, University of Amsterdam, 1100 DD, Amsterdam, The Netherlands

²Department of Radiology, Erasmus MC - University Medical Center Rotterdam, Rotterdam, The Netherlands

Email: ME - m.engelen@amc.uva.nl; PJN - p.j.nederkoorn@amc.uva.nl; MS - marion.smits@erasmusmc.nl;

DB* - d.vandebeek@amc.uva.nl

* Corresponding author

Received: 5 May 2009 Accepted: 21 July 2009 Published: 10 August 2009

Cases Journal 2009, **2**:7587 doi: 10.4076/1757-1626-2-7587

This article is available from: <http://casesjournal.com/casesjournal/article/view/7587>

© 2009 Engelen et al.; licensee Cases Network Ltd.

This is an Open Access article distributed under the terms of the Creative Commons Attribution License (<http://creativecommons.org/licenses/by/3.0>), which permits unrestricted use, distribution, and reproduction in any medium, provided the original work is properly cited.

Abstract

Minor head injury is a frequent cause for neurologic consultation and imaging. Most patients with minor head injury will make an uneventful recovery, but in a very small proportion of these patients life threatening intracranial complications occur. We describe a patient on oral anticoagulation therapy, and severely impaired coagulation, with normal head computed tomography on admission, who developed a subdural hematoma requiring surgery 12 hours later. Current guidelines and literature for the management of minor head injury are discussed.

Introduction

Minor head injury is a frequent cause for neurologic consultation in the emergency room. Most patients with minor head injury will make an uneventful recovery, but in a very small proportion of these patients life threatening intracranial complications requiring neurosurgical intervention do occur [1-3]. An interesting subgroup are patients with minor head injury who are on anticoagulant therapy. The NICE guidelines state it is most likely safe to discharge these patients if imaging is normal [4].

A guideline from the Dutch Neurology Association recommends clinical observation for at least 24 hours, even with normal findings on initial head CT [5]. In our experience, many Dutch clinicians feel that this is probably too strict and tend to deviate from this recommendation.

Here we describe a patient on anticoagulant therapy who developed a subdural hematoma several hours after admission for minor head injury.

Case presentation

A 57 year old Dutch Caucasian man was beaten by a group of youngsters. He had suffered brief loss of consciousness and was brought to the emergency room. He had a history of a mechanical aortic valve replacement and was therefore using acenocoumarol. He had no neurologic complaints and neurologic examination was unremarkable with a Glasgow Coma Scale score of 15. The laboratory workup revealed an INR of 5.1, much higher than the target of 2.5-3.5. Initial head CT on the Emergency Room was read as normal (Figure 1A and B). He was admitted to the neurological medium care unit for clinical observation

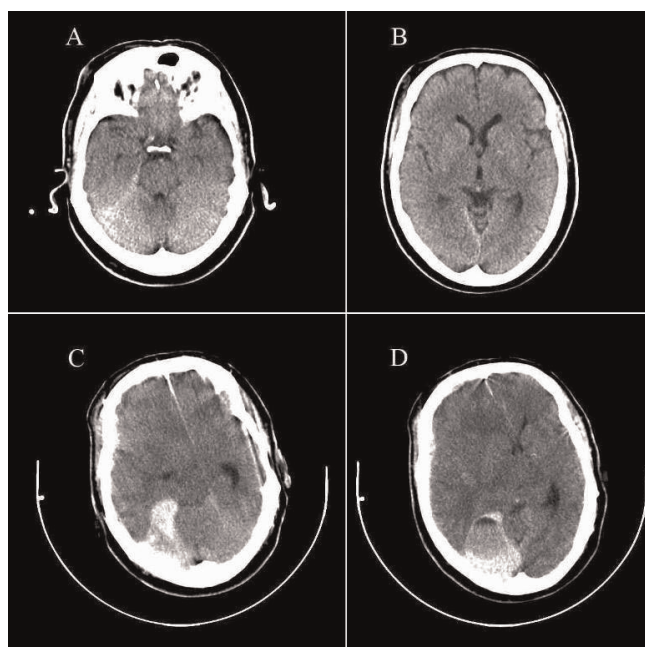


Figure 1. Non contrast enhanced CT scan at initial presentation on the emergency room (**A and B**) and 12 hours after admission (**C and D**).

according to our current guidelines [4,5]. Neurologic examination was normal 10 hours after admission, but 12 hours after admission he suddenly complained of severe headache and subsequently developed a rapidly decreasing level of consciousness. On neurologic examination he now had a score of 9 on the Glasgow Coma Scale and a dilated right-sided pupil that was unresponsive to light. Emergent head CT scan showed subdural hematoma around the tentorium cerebelli compressing the brain stem and causing substantial midline shift (Figure 1C and D). Coagulation was normalized with 2500 IU of human prothrombin complex and 10 mg vitamin K, and subsequently the patient underwent neurosurgery for evacuation of the hematoma. He made an excellent recovery.

Discussion

Our case illustrates the devastating late complication in a patient with minor head injury on anticoagulation therapy, with an INR above the target level of anticoagulation, and an initial normal head CT. In our patient, clinical observation allowed rapid evacuation of the subdural hematoma.

The idea that an early CT after minor head injury may be false negative for neurosurgical lesions is well recognized, and there are numerous reports on these so-called delayed hematomas. However, the incidence has been shown to be

extremely low (<0.02%) [6], indicating that the sensitivity of CT for detection of neurosurgical lesions approaches 100% and CT may therefore be used safely to triage minor head injury patients for clinical observation. In a recent study of discharge after initial normal head CT versus clinical observation after mild head injury, no differences in outcome between these groups were found on follow-up [7]. Also, there were no complications requiring neurosurgical intervention in the group discharged after normal initial head CT in this study [7].

In our patient, the preliminary reading of the CT scan was without abnormalities, while the second scan, performed after late clinical deterioration, showed an infratentorial subdural hematoma. The detection of infratentorial subdural hematoma on CT is difficult due to partial volume averaging effects and scanning artifacts related to the osseous skull. Small hyperdense streak lesions, indicating a small subdural hematoma, on the initial CT scan may thus have falsely been interpreted as the commonly encountered beam hardening artefacts. Such difficulties are present in any patient, and it is likely that small infratentorial subdural hematomas commonly remain unrecognized. In our patient, however, coagulation was - iatrogenically - severely impaired, and the small subdural hematoma that would have been clinically inconsequential under normal circumstances, turned into a life-threatening complication.

Oral anticoagulation is a well-recognized risk factor for intracranial traumatic complications after minor head injury. In a Dutch multicenter study of 3181 patients with minor head injury, oral anticoagulation was found to have an odds ratio of 2.4 for abnormal CT [8], but did not seem to alter outcome if the initial head CT is normal [9]. In this study, 243 (7.6%) patients had intracranial traumatic CT findings and 17 (0.5%) underwent neurosurgical intervention [3]. This study has led to the so-called CT in Head Injury Patients (CHIP) prediction rule, consisting of a set of risk factors including anticoagulant therapy, to select patients for head CT [8]. Nowadays, head CT is readily available in the emergency setting and the question arises whether subsequent admission to a neurological ward is necessary. Prediction rules such as the CHIP rule, as well as the New Orleans Criteria [1], and the Canadian CT Head Rule [2], can be used in clinical practice to triage patients for CT and subsequent discharge if CT and neurological examination are normal [7].

From the presented case, the question arises whether such policy is justified for all patients with minor head injury, particularly in those with severely impaired coagulation. Previous studies have not specifically addressed this issue. The number of patients on anticoagulants that was included in the Dutch study was small (218 of 3181

[7%]). The level of anticoagulation, however, was not taken into account, as blood coagulation tests were not formally recorded in this study. Delayed intracranial complications after mild head injury can be devastating and fatal if they occur outside the hospital. Guidelines to manage minor head injury will need to find a reasonable balance between use of health care resources, and detecting rare but serious complications. Our case report underlines the need for a more individualized approach towards patients with risk factors that increase their risk of complications severely, even if initial assessment is normal.

Abbreviations

CT, computed tomography; INR, international normalized ratio.

Consent

Written informed consent was obtained from the patient for publication of this case report and accompanying images. A copy of the written consent is available for review from the journal's Editor-in-Chief.

Competing interests

The authors declare that they have no competing interests.

Authors' contributions

ME, PJN, MS and DB critically reviewed the literature and all contributed to writing the manuscript. All authors read and approved the final manuscript.

References

- Haydel MJ, Preston CA, Mills TJ, Luber S, Blaudeau E, DeBlieux PM: **Indications for computed tomography in patients with minor head injury.** *N Engl J Med* 2000, **343**:100-105.
- Stiell IG, Wells GA, Vandemheen K, Clement C, Lesiuk H, Laupacis A, McKnight RD, Verbeek R, Brison R, Cass D, Eisenhauer ME, Greenberg G, Worthington J: **The Canadian CT Head Rule for patients with minor head injury.** *Lancet* 2001, **357**:1391-1396.
- Smits M, Dippel DW, de Haan GG, Dekker HM, Vos PE, Kool DR, Nederkoorn PJ, Hofman PA, Twijnstra A, Tanghe HL, Hunink MG: **External validation of the Canadian CT Head Rule and the New Orleans Criteria for CT scanning in patients with minor head injury.** *JAMA* 2005, **294**:1519-1525.
- NICE Guidelines: Head injuries** [<http://guidance.nice.org.uk/CG56>].
- Twijnstra A, Brouwer O, Keyser A, Lanser J, Poels E, Rinkel G: **Guidelines for diagnosis and management of patients with minor head injury. [Published in Dutch: Richtlijnen voor diagnostiek en behandeling van patiënten met een licht schedel-hersenletsel.]** [http://www.neurologie.nl/uploads/136/78/richtlijnen_-_LSHL.doc].
- af Geijerstam JL, Britton M: **Mild head injury: reliability of early computed tomographic findings in triage for admission.** *Emerg Med J* 2005, **22**:103-107.
- af Geijerstam JL, Oredsson S, Britton M: **Medical outcome after immediate computed tomography or admission for observation in patients with mild head injury: randomised controlled trial.** *BMJ* 2006, **333**:465.
- Smits M, Dippel DW, Steyerberg EW, de Haan GG, Dekker HM, Vos PE, Kool DR, Nederkoorn PJ, Hofman PA, Twijnstra A, Tanghe HL, Hunink MG: **Predicting intracranial traumatic findings on computed tomography in patients with minor**

head injury: the CHIP prediction rule. *Ann Intern Med* 2007, **146**:397-405.

- Smits M, Hunink MG, van Rijssel DA, Dekker HM, Vos PE, Kool DR, Nederkoorn PJ, Hofman PA, Twijnstra A, Tanghe HL, Dippel DW: **Outcome after complicated minor head injury.** *AJNR Am J Neuroradiol* 2008, **29**:506-513.

Do you have a case to share?

Submit your case report today

- Rapid peer review
- Fast publication
- PubMed indexing
- Inclusion in Cases Database

Any patient, any case, can teach us something



**CASES
NETWORK**

www.casesnetwork.com