

EUR Research Information Portal

Currarino's triad diagnosed in an adult woman

Published in:

European Spine Journal

Publication status and date:

Published: 01/01/2012

DOI (link to publisher):

[10.1007/s00586-012-2311-2](https://doi.org/10.1007/s00586-012-2311-2)

Document Version

Publisher's PDF, also known as Version of record

Citation for the published version (APA):

Berghauer Pont, L., Dirven, C., & Dammers, R. (2012). Currarino's triad diagnosed in an adult woman. *European Spine Journal*, 21(supp 4), 569-572. <https://doi.org/10.1007/s00586-012-2311-2>

[Link to publication on the EUR Research Information Portal](#)

Terms and Conditions of Use

Except as permitted by the applicable copyright law, you may not reproduce or make this material available to any third party without the prior written permission from the copyright holder(s). Copyright law allows the following uses of this material without prior permission:

- you may download, save and print a copy of this material for your personal use only;
- you may share the EUR portal link to this material.

In case the material is published with an open access license (e.g. a Creative Commons (CC) license), other uses may be allowed. Please check the terms and conditions of the specific license.

Take-down policy

If you believe that this material infringes your copyright and/or any other intellectual property rights, you may request its removal by contacting us at the following email address: openaccess.library@eur.nl. Please provide us with all the relevant information, including the reasons why you believe any of your rights have been infringed. In case of a legitimate complaint, we will make the material inaccessible and/or remove it from the website.

Currarino's triad diagnosed in an adult woman

Lotte M. E. Berghauser Pont · Clemens M. F. Dirven ·
Ruben Dammers

Received: 16 November 2011 / Accepted: 8 April 2012 / Published online: 24 April 2012
© The Author(s) 2012. This article is published with open access at Springerlink.com

Abstract

Purpose To report on a female patient diagnosed with Currarino's triad in adulthood.

Case report This case presents an adult patient with a medical history of a congenital anal atresia, a partial sacral agenesis, and a surgically treated ectopic anus. After a coincidentally observed presacral mass by MRI, due to unexplained constipation later in adulthood, Currarino's triad was suspected in this patient. This triad consists of anorectal malformation(s), sacrococcygeal defects and a presacral mass of various origin. Further investigation confirmed the mass to be a meningocele, and showed a tethered cord and a syrinx.

Conclusions In (young) patients with anorectal malformations, although having no other symptoms, further examination might be required to exclude Currarino's triad. Importance of early diagnosis and multidisciplinary assessment is recommended to establish adequate treatment if needed.

Keywords Currarino · Anorectal malformation · Sacrococcygeal agenesis · Presacral mass · Meningocele

Introduction

Constipation is a symptom commonly observed in neonates. Few patients suffering from constipation at young infancy, however, are diagnosed with Currarino's triad,

consisting of a malformation in the anorectal region, a (partial) sacral agenesis, and the occurrence of a presacral mass. It is caused by a deletion on chromosome 7q36 [1]. Since this deletion is rather scarce, it is difficult to obtain an accurate incidence. Isik et al. described 1.7 % patients with Currarino in a cohort of 234 cases with lipomeningomyelocele [2]. Up to date, about 270 cases have been reported since the pediatric radiologist Currarino and co-authors have described this triad in 1981 [3]. Earlier, in 1926 and 1974, similar cases have been described [4]. Although being a rare condition, large multicenter series have been published that intend to give more insight into the genetic aspects of Currarino's triad. Currarino's triad has several important diagnostic difficulties. Since the treatment decisions are predominantly based on the radiology, these aspects need to be examined carefully. The clinical, i.e., neurological state also plays a major part in decision making, although in case of threatening but asymptomatic abnormalities on radiological assessment, surgery might nevertheless be proposed.

In this report, we present an adult female with a history of congenital anal atresia and partial sacral agenesis. At a later age she presented with an anterior meningocele, highly suggestive of Currarino's triad. We discuss the diagnostic and optional treatment aspects of this case, thereby underlining the urgency for early diagnosis.

Case presentation

A 22-year-old Caucasian female was seen in the neurosurgical outpatient clinic. The family history was irrelevant. Her medical history revealed a congenital anal atresia and an ectopic anus. At the age of 3 years, the latter was corrected with an anterior sagittal anorectoplasty (ASARP)

L. M. E. Berghauser Pont · C. M. F. Dirven · R. Dammers (✉)
Department of Neurosurgery, Erasmus MC,
's Gravendijkwal 230, Office Hs-114,
P.O. Box B2040, 3000, CA, Rotterdam, The Netherlands
e-mail: r.dammers@erasmusmc.nl

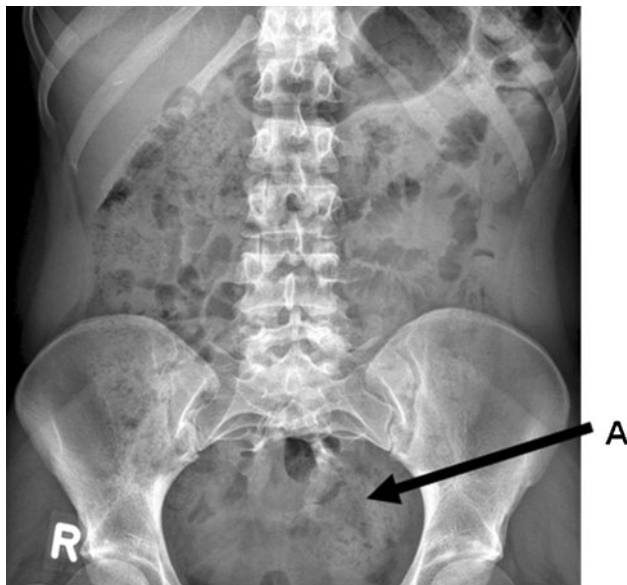

Fig. 1 Pelvic X-ray *Arrow A*: the partial sacral agenesis

procedure. Furthermore, she had suffered from grade III vesico-ureteral reflux. X-ray imaging of the lumbar spine confirmed a partial sacral agenesis, sickle-shaped sacrum (Fig. 1). After surgery, constipation resolved without fecal incontinence. She was followed-up by the pediatric surgeon. Otherwise, she was in healthy condition and is currently employed as a registered nurse.

During the second part of 2010, she experienced transient defecation difficulties. For that reason, the pediatric surgical team performed an MRI without contrast of the pelvic region. This showed the formerly known changes as expected from the ASARP procedure and the partial sacral agenesis. Coincidentally an anterior presacral mass of unknown origin, suggestive of a meningocele, as well as a bicornuate uterus was diagnosed (Fig. 2). Neurological examination did not reveal any deficits, explicitly there were neither pyramidal tract nor posterior column signs. The history of anorectal malformations, partial sacral agenesis and the presacral meningocele should prompt to the diagnosis of Currarino's triad. This syndrome can be accompanied by a tethered cord, and a presacral mass of another origin, such as a teratoma. Therefore, we decided to perform a contrast-enhanced MRI of the lumbosacral spine, to rule out any of the above. It confirmed the presacral mass to be a meningocele. Furthermore, a moderate tethered cord was observed with the medullary conus at level L3–4, as well as a small syrinx. The radiologic findings and the absence of symptoms showed no need for surgical intervention. We decided to pursue a conservative approach and follow her in the outpatient clinic. If complaints or neurological symptoms should occur, depending on the incident pathology, transdural ligation of the

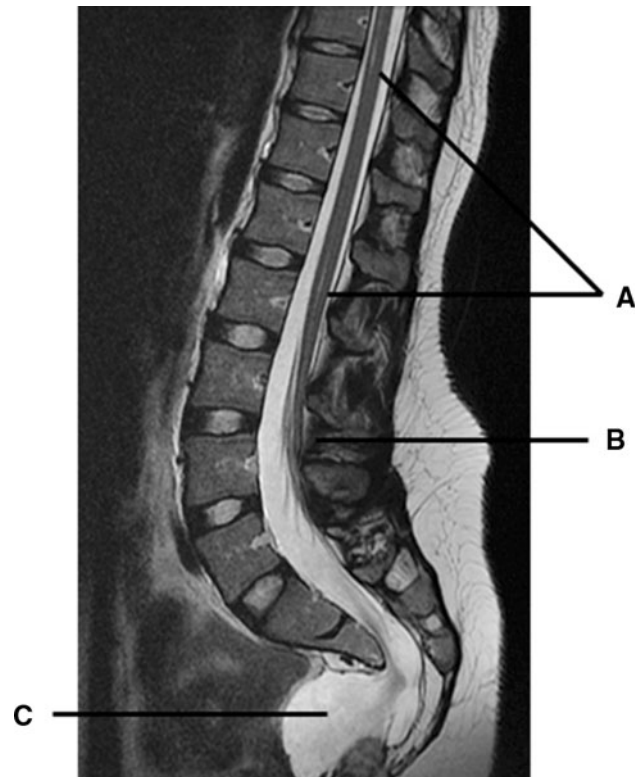


Fig. 2 MRI with contrast enhancement. *Arrow A*: mild syringomyelia. *Arrow B*: tethered cord with medullary conus at L3–4 level. *Arrow C*: anterior meningocele

meningocele or untethering of the spinal cord could be considered. Genetic counseling was initiated.

Discussion

Currarino's triad, although consisting of three groups of abnormalities, includes a wide variability of phenotypes [5]. It is usually diagnosed in childhood and females seem to be more affected [2, 5]. Recognition of the typical features of the triad and the Currarino syndrome itself is important for patient and family counseling. The earlier mentioned homeobox gene *HLXB9* on locus 7q36 [1, 6] was described various times in sacrococcygeal anomalies including partial sacral agenesis [7]. This mutation can be familial, or incidental [2, 8, 9]. Evaluation of the genetic status and screening family members is strongly advised.

The anorectal malformations occurring in this syndrome often include anal stenoses, sometimes accompanied by Hirschsprung's disease, or otherwise includes a form of anal agenesis or a ventrally displaced anus [2, 7, 8, 10]. Usually this translates into frequent constipation, as shown in our case, and painful defecation, a common symptom of Currarino's syndrome [2, 8]. Dilatation can be considered if laxatives or enemas do not solve this condition [2]. Our

patient was treated with an ASARP. Literature describes cases mainly treated with a posterior (PSARP) procedure. The reason to choose a posterior approach is that the anorectoplasty is often performed in combination with ligation of the meningocele [5, 11]. For anorectoplasty only, an ASARP procedure leads to comparable results as a PSARP. However, cosmetic satisfaction is higher and a trend of functional benefits has been found [12]. In this case, the anal atresia and ectopic anus present at birth were complicated by several urinary tract infections due to vesicoureteral reflux. Literature reports on other cases with recurrent urinary tract infections, which were usually caused by a neurogenic bladder dysfunction.

The sacrococcygeal agenesis in Currarino's triad is either complete, in which the sacrum is absent, or partial in which a hemisacrum with preservation of the first sacral vertebra. The latter is often scimitar-shaped and was observed in our patient. A lumbosacral X-ray (Fig. 1) is a good diagnostic tool to evaluate these sacral anomalies [2, 11].

Furthermore, our patient was diagnosed with a presacral mass of unknown origin at a later stage in life. A pelvic MRI was performed because of recurrent constipation in adulthood. Coincidentally a presacral mass was visualized (Fig. 2). MRI of the lumbosacral region is recommended to identify and differentiate the origin of the presacral mass, as well as other associated malformations. It can distinguish a teratoma (type IV) from an anterior meningocele, in view of the fact that the content of the cyst is characteristic of cerebrospinal fluid. A CT myelography can be helpful to illustrate relation to the thecal sac. Treatment of a presacral mass depends on the suspected diagnosis and symptoms. Since teratoma holds malignant potential, depending on maturity, this urges surgical excision with additional chemotherapy. Also in other cases like dermoid cyst, lipoma, leiomyosarcoma, or other malignant masses [5, 7], excision is recommended. Adson et al. described the posterior approach to the resection of an anterior meningocele. Via a lumbosacral partial laminectomy or laminoplasty, a transdural ligation of the neck of the meningocele can be performed [2, 13]. An alternative could be the posterior sagittal approach in between anus and coccyx, which is performed to remove the mass and concomitantly reconstruct the anus [9, 14].

Other common features of Currarino's syndrome are a tethered cord and syringomyelia, both present in the case presented [2, 15–19]. The incidence of a tethered cord varies highly between presented series from 18 to 83 % [2, 5, 19]. In our patient the conus medullaris was at L3–4 level, but may vary between patients [20]. Possible treatment options are a conservative observation or untethering through a (posterior) laminoplasty approach [21]. Nevertheless, no consensus exists on the surgical treatment of

non-symptomatic patients. Some surgeons recommend to perform surgery [2], whereas, others emphasize the risk of surgical complications in an otherwise non-symptomatic patient. More evidently, when progressive pyramidal tract signs or bladder dysfunction is observed, surgery is highly recommended to prevent further worsening.

Besides the described features, Currarino's syndrome can be accompanied by other pathologies like gynaecological abnormalities [5], reflected by a bicornuate uterus. Also other neurological anomalies may occur, one being holoprosencephaly, a condition in which the prosencephalon fails to develop into two hemispheres and which is related to a defect gene on chromosome 7q36 [22–24]. Therefore, in suspected cases, radiological cerebral examination is recommended.

Conclusions

Currarino's triad is a diagnosis made by physical and radiological examination, and diagnosis in adulthood is rare. Young patients with anorectal malformations or other suspicious symptoms should be further investigated. Essential elements include the pelvic X-ray, and lumbar and sacral MRI. Early diagnosis of Currarino's triad is important to be able to monitor these patients closely and prevent them from developing neurological deficits or worsening conditions. Decisions on treatment depend on two major aspects, namely the occurrence of (neurological) symptoms, and the radiological findings. We recommend an early and multidisciplinary approach if a patient is suspected to have Currarino's syndrome.

Conflict of interest None of the authors has any potential conflict of interest.

Open Access This article is distributed under the terms of the Creative Commons Attribution License which permits any use, distribution, and reproduction in any medium, provided the original author(s) and the source are credited.

References

1. Cretolle C, Pelet A, Sanlaville D, Zerah M, Amiel J, Jaubert F, Revillon Y, Baala L, Munnich A, Nihoul-Fekete C, Lyonnet S (2008) Spectrum of HLXB9 gene mutations in Currarino syndrome and genotype-phenotype correlation. *Hum Mutat* 29(7): 903–910. doi:10.1002/humu.20718
2. Isik N, Elmaci I, Gokben B, Balak N, Tosyali N (2010) Currarino triad: surgical management and follow-up results of four [correction of three] cases. *Pediatr Neurosurg* 46(2):110–119. doi: 10.1159/000319007
3. Currarino G, Coln D, Votteler T (1981) Triad of anorectal, sacral, and presacral anomalies. *AJR Am J Roentgenol* 137(2):395–398
4. Ashcraft KW, Holder TM (1974) Hereditary presacral teratoma. *J Pediatr Surg* 9(5):691–697 (pii: 0022-3468(74)90107-9)

5. Martucciello G, Torre M, Belloni E, Lerone M, Pini Prato A, Cama A, Jasonni V (2004) Currarino syndrome: proposal of a diagnostic and therapeutic protocol. *J Pediatr Surg* 39(9):1305–1311 (pii: S0022346804003422)
6. Hagan DM, Ross AJ, Strachan T, Lynch SA, Ruiz-Perez V, Wang YM, Scambler P, Custard E, Reardon W, Hassan S, Nixon P, Papapetrou C, Winter RM, Edwards Y, Morrison K, Barrow M, Cordier-Alex MP, Correia P, Galvin-Parton PA, Gaskill S, Gaskin KJ, Garcia-Minaur S, Gereige R, Hayward R, Homfray T (2000) Mutation analysis and embryonic expression of the HLXB9 Currarino syndrome gene. *Am J Hum Genet* 66(5):1504–1515 (pii: S0002-9297(07)62980-2)
7. Volk A, Karbasiyan M, Semmler A, Todt U, Urbach H, Klockgether T, Linnebank M (2007) Adult index patient with Currarino syndrome due to a novel HLXB9 mutation, c.336dupG (p.P113fsX224), presenting with Hirschsprung's disease, cephalgia, and lumbodysplasia. *Birth Defects Res A Clin Mol Teratol* 79(3):249–251. doi:10.1002/bdra.20340
8. Samuel M, Hosie G, Holmes K (2000) Currarino triad—diagnostic dilemma and a combined surgical approach. *J Pediatr Surg* 35(12):1790–1794. doi:10.1053/jpsu.2000.19258
9. Bunc G, Ravnik J, Vorsic M, Ravnik M (2009) Variable presentations of Currarino syndrome in three members of the same family. *Acta Neurochir (Wien)* 151(9):1169–1173. doi:10.1007/s00701-009-0220-x
10. Low G, Irwin GJ, Haddock G, Maroo SV (2006) Currarino triad: characteristic appearances on magnetic resonance imaging and plain radiography. *Australas Radiol* 50(3):249–251. doi:10.1111/j.1440-1673.2006.01572.x
11. Aslan A, Karaguzel G, Mihci E, Melikoglu M (2005) Currarino syndrome associated with penoscrotal inversion and perineal fissure. *Pediatr Surg Int* 21(9):733–735. doi:10.1007/s00383-005-1464-z
12. Shehata SM (2009) Prospective long-term functional and cosmetic results of ASARP versus PASRP in treatment of intermediate anorectal malformations in girls. *Pediatr Surg Int* 25(10):863–868. doi:10.1007/s00383-009-2434-7
13. Adson A (1938) Spina bifida cystica of the pelvis: diagnosis and surgical treatment. *Min Med* 21:468–475
14. Otagiri N, Matsumoto Y, Yoshida Y (2000) Posterior sagittal approach for Currarino syndrome with anterior sacral meningocele: a case report. *J Pediatr Surg* 35(7):1112–1114. doi:10.1053/jpsu.2000.7838
15. Pavone P, Ruggieri M, Lombardo I, Sudi J, Biancheri R, Castellano-Chiodo D, Rossi A, Incorpora G, Nowak NJ, Christian SL, Pavone L, Dobyns WB (2010) Microcephaly, sensorineural deafness and Currarino triad with duplication-deletion of distal 7q. *Eur J Pediatr* 169(4):475–481. doi:10.1007/s00431-009-1061-6
16. Suomalainen A, Wester T, Koivusalo A, Rintala RJ, Pakarinen MP (2007) Congenital funnel anus in children: associated anomalies, surgical management and outcome. *Pediatr Surg Int* 23(12):1167–1170. doi:10.1007/s00383-007-2024-5
17. Emans PJ, van Aalst J, van Heurn EL, Marcelis C, Kootstra G, Beets-Tan RG, Vles JS, Beuls EA (2006) The Currarino triad: neurosurgical considerations. *Neurosurgery* 58(5):924–929. doi:10.1227/01.NEU.0000209945.87233.6A (discussion 924–929)
18. Riebel T, Kochling J, Scheer I, Oellinger J, Reis A (2004) Currarino syndrome: variability of imaging findings in 22 molecular-genetically identified (HLXB9 mutation) patients from five families. *Rofo* 176(4):564–569. doi:10.1055/s-2004-812948
19. Lee SC, Chun YS, Jung SE, Park KW, Kim WK (1997) Currarino triad: anorectal malformation, sacral bony abnormality, and presacral mass—a review of 11 cases. *J Pediatr Surg* 32(1):58–61 (pii: S0022-3468(97)90094-4)
20. Turgut M, Cullu E, Ulucan H (2006) Incomplete Currarino triad as an embryological variant. Case report and review of the literature. *J Neurosurg* 105(6 Suppl):504–507. doi:10.3171/ped.2006.105.6.504
21. Walton M, Bass J, Soucy P (1995) Tethered cord with anorectal malformation, sacral anomalies and presacral masses: an under-recognized association. *Eur J Pediatr Surg* 5(1):59–62. doi:10.1055/s-2008-1066168
22. Treier M, O'Connell S, Gleiberman A, Price J, Szeto DP, Burgess R, Chuang PT, McMahon AP, Rosenfeld MG (2001) Hedgehog signaling is required for pituitary gland development. *Development* 128(3):377–386
23. Belloni E, Martucciello G, Verderio D, Ponti E, Seri M, Jasonni V, Torre M, Ferrari M, Tsui LC, Scherer SW (2000) Involvement of the HLXB9 homeobox gene in Currarino syndrome. *Am J Hum Genet* 66(1):312–319. doi:10.1086/302723
24. Horn D, Tonnie H, Neitzel H, Wahl D, Hinkel GK, von Moers A, Bartsch O (2004) Minimal clinical expression of the holoprosencephaly spectrum and of Currarino syndrome due to different cytogenetic rearrangements deleting the Sonic Hedgehog gene and the HLXB9 gene at 7q36.3. *Am J Med Genet A* 128A(1):85–92. doi:10.1002/ajmg.a.30031