

**Damage to the Superficial Peroneal Nerve in Operative treatment of fibula fractures: straight to the bone? - Case report and review of the literature**

J.A. Halm MD, PhD, T. Schepers MD, PhD

Erasmus MC, University Medical Center Rotterdam, Department of Surgery-Traumatology, Rotterdam, The Netherlands

Corresponding author:

T. Schepers

Erasmus MC, University Medical Center Rotterdam

Department of Surgery-Traumatology

Room H822-k

P.O. Box 2040

3000 CA Rotterdam

The Netherlands

Tel: +31-10-7031050

Fax: +31-10-7032396

E-mail: t.schepers@erasmusmc.nl

**Keywords:** Lateral malleolar fracture; Internal fixation; Superficial peroneal nerve; Intermediate dorsal cutaneous nerve; Neuroma

## **Abstract**

Ankle fractures are a significant part of the lower extremity trauma seen in the emergency department. Neurological complications of ankle fracture surgery are described infrequently, but account for significant morbidity. The risk for nerve injury is increased in Blair and Botte type-B pattern of the ICDN (intermediate cutaneous dorsal nerve) branch, crossing the distal fibula from posterior to anterior (at 5-7 cm from malleolar tip). This pattern is present in about 10-15% of patients. Injuries to the SPN and its branches negatively influence outcome. Early recognition and protection may reduce the incidence of SPN injuries during ORIF of lateral malleolus fractures. We describe two surgically treated ankle fractures with superficial peroneal nerve branch (ICDN) involvement and review the current literature.

## **Introduction**

Ankle fractures are a significant part of the lower extremity trauma seen in the emergency department. They represent approximately 10% of all fractures<sup>1</sup> and studies suggest that the incidence is rising<sup>2</sup>. Open reduction and internal fixation<sup>3</sup> as well as conservative treatment in selected cases can provide excellent results<sup>4</sup>. Neurological complications of ankle fracture surgery are described infrequently, but account for significant morbidity. Most commonly, a neuroma due to transection of the superficial peroneal nerve (SPN) is reported<sup>5</sup>. The current case reports and review of literature challenges the routine doctrine of cutting straight to the bone when approaching the fibula for open reduction and internal fixation (ORIF).

## Cases

### Case A

Male patient, 33 years of age, was referred to our clinic with complaints of a stiff ankle and impaired dorsiflexion of fifteen degrees and hyperesthesia in the superficial peroneal nerve area. The patient was previously treated for a Weber-B; Supination-ExoRotation (SER) 4, bimalleolar ankle fracture two years earlier. There was a positive Tinel's sign in the proximal part of the scar over the lateral malleolus (Figure 1a). The patient was scheduled for a posterior capsular release and an Achilles tendon lengthening. Because of the neurological complaints the proximal part of the initial incision was explored revealing a neuroma of the SPN (Figure 1b). The neuroma was resected and the nerve end was buried in the extensor digitorum longus muscle. Postoperatively the hyperesthesia made way for hypoesthesia, which was far less bothersome to the patient who made a full recovery with a good range of motion.

### Case B

Female patient, age 39, suffered a Weber-B trimalleolar ankle fracture-dislocation (SER-4) injury of the right ankle after a fall from stairs. The patient was scheduled for surgery on the same day. A standard lateral approach to the fibula was used, during which the superficial peroneal nerve was identified crossing the line of the incision (Figure 2a). The SPN was protected throughout the procedure. A lag-screw was placed accompanied by neutralisation plate. The anterior tibiofibular ligament of the syndesmosis was reinforced with a non-absorbable suture looped around the lag screw and a second screw in the anterior tibia (Figure 2b)<sup>6</sup>. Postoperatively the patient had normal sensation in the area of the SPN and made a full recovery.

## Literature review

### *Anatomy*

The common peroneal nerve is a branch of the sciatic nerve, which combines fibres from the lumbosacral trunk at L4 and L5 level as well as by fibres from S1-3. As described in a number of renowned textbooks the superficial peroneal nerve (SPN), also known as superficial fibular nerve (G. *perone*, = L. *fibula*, pin; hence pertaining to needle-shaped leg bone)<sup>7</sup>, runs between the fibula and the peroneus longus muscle. Distally, the SPN lies on the anterior intermuscular septum between either the peroneus longus muscle proximally and the extensor digitorum longus muscle, or the peroneus longus muscle and the peroneus brevis muscle. The superficial peroneal nerve supplies the peroneus brevis and longus muscles (motorbranch). At the distal third of the tibia, the SPN perforates the fascia of the lateral compartment adjacent to the intermuscular septum and undergoes division into two cutaneous branches to innervate the skin on the lateral side of the lower leg and the dorsum of the foot, more specifically: the medial dorsal cutaneous nerve (MDCN) and the intermediate dorsal cutaneous nerve (IDCN) branches supply the anterolateral skin of the leg and the dorsal skin of the hallux, second, third, and medial side of the fourth toe<sup>8</sup>. Detailed anatomical studies have been undertaken (Table 1) supplying us with valuable data concerning the course SPN and the sensory branches (MDCN/IDCN).

### *Lateral Surgical Approach*

A direct lateral approach has become the standard for open reduction and internal fixation of distal fibula fractures<sup>3</sup>. The dissection should be kept anterior to the peroneal tendons, which can be left undisturbed at the posterior aspect of the distal fibula. Proximally, enough muscle is dissected to expose the bone without stripping

periosteum. The dissection plane is between the peroneus tertius anteriorly and the peroneus longus and brevis posteriorly. The superficial peroneal nerve is close anteriorly, particularly in the proximal part of the incision, and when more proximal dissection is required for a proximal fibula fracture or when the incision is more anterior, it should be identified and protected. The sural nerve is posterior to the incision and the required plane of dissection. The standard lateral incision can be moved slightly anterior in order to reconstruct the anterior syndesmosis or fixate a Tillaux-Chaput fragment from the anterolateral tibia. During this approach, the superficial peroneal nerve should be identified and protected<sup>9-10</sup>.

#### *Avoiding Operative Complications*

Marsh and Saltzman recognize three types of operative complications in their chapter on ankle fractures in Rockwood and Greene's Fractures in Adults 6<sup>th</sup> ed. They are wound necrosis and/or infection, neurologic injury, and failure to reduce the talus in the ankle mortise<sup>9</sup>. Neurovascular complications are uncommon yet the superficial peroneal nerve is at risk during the lateral approach to the fibula as is the sural nerve. Kim et al. encountered Blair and Botte type B SPN in 7 out of 53 cases (12%) during operations for fibula fractures<sup>11</sup>. The IDCN was managed by dissection and transposition anteriorly before plating. The majority of patients (70%) did not show any neurologic deficit following anterior transposition during ORIF. Neuroma of the superficial peroneal nerve as a result of operative ankle fracture treatment has been reported in 27 patients by Chiodo et al who describe excellent results of transposition of the proximal nerve stump into bone<sup>12</sup>.

#### *Ankle fractures and associated SPN injuries*

As reported by Redfern et al. symptomatic injury to the SPN following ankle fracture

occurs in 15% of patients and is negatively associated with outcome as demonstrated by lower overall AOFAS scores, due to significant more pain<sup>5</sup>. The risk of symptomatic injury to this nerve appears significantly greater in patients undergoing open reduction and internal fixation via a lateral fibular approach compared to cast treatment (21 versus 9% respectively) emphasizing that injuries to the SPN also seem to occur in ankle fractures prior to surgical treatment, necessitating a thorough investigation prior to surgery. Primary transection of the SPN in a Weber B type ankle fracture due to the bony spike has also been reported in literature<sup>13</sup>.

## **Discussion**

Both cases presented here clearly show the importance of recognizing the alternative position/routes of the SPN. Huene et al. suggests that the incision used for the lateral approach to the distal part of the fibula should be made between the 95 per cent confidence intervals of the sural and superficial peroneal nerves<sup>14</sup>. The safest position for the incision is twelve millimeters posterior to the anterolateral border of the fibula at ten centimeters proximal to the tip and ten millimeters posterior to the anterolateral border at five centimeters proximal to the tip; the incision should be extended directly towards the tip of the malleolus. Even when this incision is used, however, careful dissection must be performed since cutaneous branches may still cross the operative field, especially over the distal three centimeters of the incision<sup>14</sup>. Treatment of SPN neuroma by resection and burial of nerve end in either bone or muscle as described by Chiodo et al was successfully employed in our patient<sup>12</sup>.

Blair and Botte type-B pattern of the ICDN branch crossing the distal fibula from posterior to anterior (at 5-7 cm from malleolar tip) increases the risk for nerve injury. Since this pattern is not uncommon, being present in about 10-15% of patients, thorough knowledge of anatomy around the ankle is of utmost importance in preventing injuries to the SPN and its branches as this negatively influences outcome. Recognition and transposition anteriorly of the Blair and Botte type B ICDN may reduce the incidence of SPN injuries during the ORIF of lateral malleolus fractures.



## References

1. Court-Brown CM, Caesar B. Epidemiology of adult fractures: A review. *Injury* 37:691-697, 2006.
2. Court-Brown CM, McBirnie J, Wilson G. Adult ankle fractures--an increasing problem? *Acta Orthop Scand* 69:43-47, 1998.
3. Hahn DM, Colton CL. Malleolar fractures. In: Rüedi TP, Murphy WM, editors. *AO Principles of Fracture Management*. New York: Thieme, 2001:583-584.
4. Dietrich A, Lill H, Engel T, Schonfelder M, Josten C. Conservative functional treatment of ankle fractures. *Arch Orthop Trauma Surg* 122:165-168, 2002.
5. Redfern DJ, Sauve PS, Sakellariou A. Investigation of incidence of superficial peroneal nerve injury following ankle fracture. *Foot Ankle Int* 24:771-774, 2003.
6. Nelson OA. Examination and repair of the AITFL in transmalleolar fractures. *J Orthop Trauma* 20:637-643, 2006.
7. Lisowski FP, Oxnard CE. *Anatomical Terms and their Derivation*, 2007.
8. Agur AMR, Dalley AF. *Grant's Atlas of Anatomy*, 12th Edition, 2009.
9. Marsh JL, Saltzman CL. Ankle Fractures. In: Bucholz RW, Heckman JD, Court-Brown CM, editors. *Rockwood & Green's Fractures in Adults*, 2006.
10. Davidovitch RI, Egol KA. Ankle Fractures. In: Bucholz RW, Heckman JD, Court-Brown CM, Tornetta P, 3rd, editors. *Rockwood And Green's Fractures In Adults*, 2010.
11. Kim HJ, Oh JK, Oh CW, Hwang JH, Biswal S. Anterior transposition of the superficial peroneal nerve branch during the internal fixation of the lateral malleolus. *J Trauma* 68:421-424, 2010.
12. Chiodo CP, Miller SD. Surgical treatment of superficial peroneal neuroma. *Foot Ankle Int* 25:689-694, 2004.
13. Pichler W, Clement H, Boldin C, Grechenig W, Tesch NP. Primary transection of the superficial peroneal nerve resulting from a distal fibula fracture. *J Orthop Trauma* 21:212-214, 2007.
14. Huene DB, Bunnell WP. Operative anatomy of nerves encountered in the lateral approach to the distal part of the fibula. *J Bone Joint Surg Am* 77:1021-1024, 1995.
15. Herron M, Langkamer V, Atkins R. The anatomical variations of the distal course of the superficial peroneal nerve: recommendations to avoid injury during surgical procedures. *The Foot* 3:38-42, 1993.
16. Blair JM, Botte MJ. Surgical anatomy of the superficial peroneal nerve in the ankle and foot. *Clin Orthop Relat Res*:229-238, 1994.

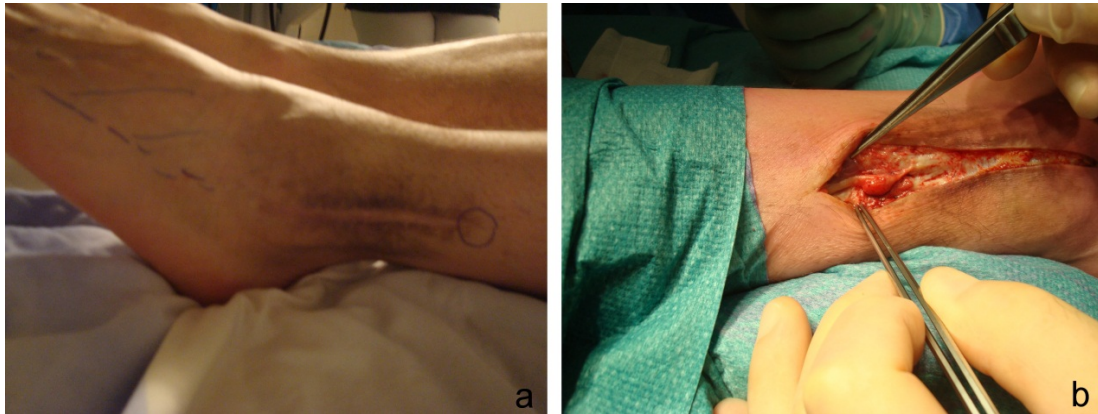
17. Apaydin N, Basarir K, Loukas M, Tubbs RS, Uz A, Kinik H. Compartmental anatomy of the superficial fibular nerve with an emphasis on fascial release operations of the leg. *Surg Radiol Anat* 30:47-52, 2008.
18. Şayli U, Tekdemir Y, Çubuk HE, Avci S, Tuccar E, Elhan H.A., Uz A. The course of the superficial peroneal nerve: an anatomical cadaver study. *Foot Ankle Surg* 4:63-69, 1998.
19. Solomon LB, Ferris L, Tedman R, Henneberg M. Surgical anatomy of the sural and superficial fibular nerves with an emphasis on the approach to the lateral malleolus. *J Anat* 199:717-723, 2001.
20. Mirza A, Moriarty AM, Probe RA, Ellis TJ. Percutaneous plating of the distal tibia and fibula: risk of injury to the saphenous and superficial peroneal nerves. *J Orthop Trauma* 24:495-498, 2010.
21. Neubauer T, Heidari N, Weinberg AM, Grechenig W, Tesch NP, Pichler W, Wagner M. The risk of nerve injury with minimally invasive plate osteosynthesis of distal fibula fractures: an anatomic study. *Arch Orthop Trauma Surg* 131:1409-1412, 2011.

**Table 1.** Anatomical studies of SPN and branches MDCN/ICDN

Author (Year)	N	Percentage	Surfacing of SPN (cm)	Branching MDCN/ICDN (cm)
<b>Herron et al (1993)<sup>15</sup></b> <b>UK</b>	20	Combined type 60%	9.4±3.3 above the malleolar line*	3.4±2.0 above the malleolar line
		Separate type 25%		
		Single type 15%		
<b>Blair and Botte (1994)<sup>16</sup></b> <b>USA</b>	25	Type A (72%)	12.3±2 proximal from ankle joint, anterior to fibula	4.4±2.9 proximal to ankle joint, anterior to fibula
		Type B (16%)	Branches penetrate separately; MDCN anterior to fibula, IDCN posterior to fibula	MDCN 12 ±1.7 IDCN 5.5±1 proximal to ankle joint IDCN crosses lateral fibula 4.5±0.9 to ankle joint
		Type C (12%)	Branches penetrate separately, anterior to fibula	MDCN 7.3±0.5 IDCN 4.9±0.1 proximal to ankle joint
<b>Huene et al (1995)<sup>14</sup></b> <b>USA</b>	50	22%	Substantial branch crosses anterolateral fibula 12.4±2.6	9.7±6.3
<b>Sayli et al (1998)<sup>18</sup></b> <b>Turkey</b>	30	Type A (73%)	10.4±2.3 proximal to ankle joint	3.7±0.9 proximal to ankle joint
		Type B (13%)	Branches penetrate separately; MDCN anterior to fibula, IDCN posterior to fibula	MDCN 11.2 ±2.1 IDCN 8.1±1.9 proximal to ankle joint IDCN crosses lateral fibula 5.1±1.0 to ankle joint
		Type C		MDCN 8.4±0.4 IDCN 6.4±1.0 proximal to ankle joint
<b>Solomon et al (2001)<sup>19</sup></b> <b>Australia</b>	68	100% IDCN absent in 35%	Branches penetrate separately, anterior to fibula	SPN/IDCN 9.1±2.3 proximal to the tip of the lateral malleolus
<b>Apaydin et al (2008)<sup>17</sup></b> <b>Turkey</b>	38	Type I (71%)	Lateral compartment 13.2 (10.9-15.3)	11 (8.6-15.3)
		Type II (23.7%)	Lateral to anterior compartment 8.3 (7.2-11.6)	MDCN 11.5 (10.3–12.7) IDCN 16.8 (15.4–18.2)
		Type III (5.3)	Lateral and anterior compartment 11.8 (9.8-13.5)	11 (8.6-15.3)
<b>Mirza et al (2010)<sup>20</sup></b> <b>USA</b>	10		11.6±3.4 proximal to lateral malleolus	
<b>Neubauer et al (2011)<sup>21</sup></b> <b>Austria</b>	20	In 8 cases (40%)	7.6 -13.7 crosses fibula proximal to lateral malleolus	

\* transverse line between tips of both malleoli, SPN superficial peroneal nerve, MDCN medial dorsal cutaneous nerve, IDCN intermediate dorsal cutaneous nerve

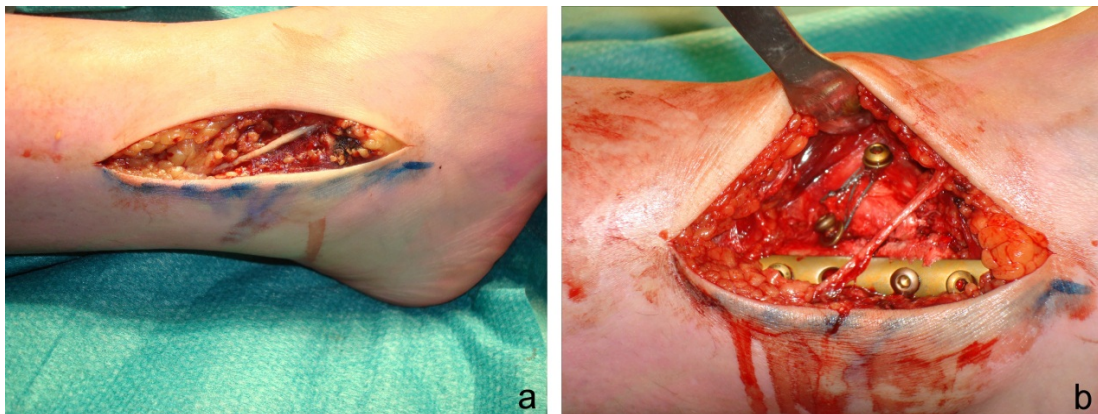
**Figure 1. Case A**



a. With the patient supine, the shaded area represents impaired sensation, and encircled is the location of positive Tinel's sign.

b. Per-operative situation with patient prone. Neuroma of superficial peroneal nerve identified.

**Figure 2. Case B**



a. Per-operative identification of Blair-Botte type-B branching of the SPN.

b. Preservation of nerve throughout procedure.