

Tracheal agenesis: approach towards this severe diagnosis. Case report and review of the literature

Maurike D. de Groot-van der Mooren · Monique C. Haak · Phillis Lakeman ·
Titia E. Cohen-Overbeek · J. Patrick van der Voorn · Jochen H. Bretschneider ·
Ruurd M. van Elburg

Received: 25 July 2011 / Accepted: 31 August 2011 / Published online: 15 September 2011
© The Author(s) 2011. This article is published with open access at Springerlink.com

Abstract Tracheal agenesis (TA) is a severe congenital disorder with often an unexpected emergency presentation. There is complete or partial absence of the trachea below the larynx, with presence or absence of a tracheoesophageal fistula (TOF). A neonate with TA is described, and another 48 cases found in literature are reviewed. Due to *absence* of a TOF, five cases were diagnosed prenatally because of

congenital high airway obstruction syndrome (CHAOS). When a TOF is *present*, polyhydramnion and several other congenital malformations seen on the ultrasound examination should alert clinicians of potential tracheal problems. Prenatal magnetic resonance imaging (MRI) may provide a definitive diagnosis. Postnatal diagnosis is based on recognition of specific clinical signs in the newborn with TA: respiratory distress with breathing movement without appropriate air entry, no audible cry, and failed endotracheal intubation. Despite progress in surgical interventions, mortality remains high. Prenatal diagnosis of TA is possible, but only if a TOF is absent resulting in CHAOS. Prenatal diagnosis of polyhydramnion and other congenital malformation should alert clinicians of potential tracheal problems. Prenatal MRI may provide a definitive diagnosis.

M. D. de Groot-van der Mooren · R. M. van Elburg (✉)
Department of Pediatrics, Subdivision of Neonatology,
VU University Medical Center,
De Boelelaan 1117,
1081 HV Amsterdam, The Netherlands
e-mail: rm.vanelburg@vumc.nl

M. C. Haak
Department of Obstetrics and Gynecology,
VU University Medical Center,
Amsterdam, The Netherlands

P. Lakeman
Department of Clinical Genetics, VU University Medical Center,
Amsterdam, The Netherlands

T. E. Cohen-Overbeek
Department of Obstetrics and Gynecology,
Erasmus Medical Center,
Rotterdam, The Netherlands

J. P. van der Voorn
Department of Pathology, VU University Medical Center,
Amsterdam, The Netherlands

J. H. Bretschneider
Department of Otolaryngology, VU University Medical Center,
Amsterdam, The Netherlands

Present Address:

M. C. Haak
Leiden University Medical Center,
Leiden, The Netherlands

Keywords Tracheal/abnormalities · Tracheal agenesis ·
Tracheal aplasia · Tracheal atresia · Newborn

Introduction

Tracheal agenesis (TA) is a rare congenital defect that confronts obstetricians, neonatologists, and anesthesiologists with an unexpected emergency presentation. This usually lethal defect has an incidence of 1 per 50,000 newborns and consists of complete or partial absence of the trachea below the larynx, with or without a concomitant tracheoesophageal fistula (TOF). In the third week of gestation, the laryngotracheal groove in the proximal foregut progresses caudally, where it develops two primordial buds, which will develop into the bronchi and lungs. Complete separation of the trachea and esophagus occurs by the sixth week. These relatively separate processes allow for malformations of the trachea in the presence of a normal larynx,

bronchi, and lungs. Different theories have been suggested to explain the cause of tracheoesophageal anomalies [12, 13, 25, 27, 34, 39, 41]. Besides environmental factors, animal models of different genetic defects, such as (conditional) inactivation of *Gli2*, *Gli3*, *Shh*, *Foxf1*, and *b-catenin*, show TA or incorrect septation of the foregut. A major role for the *BMP type I* receptor genes in mouse models is suggested [12]. However, no causal gene has been identified in human TA patients yet. TA was first described in 1900 by Payne and was classified based upon the presence and length of the tracheal remnant. Floyd's classification of TA [19] is used more often than the classification by Faro et al. (Fig. 1) [16]. We describe a case of TA Floyd Type II with a TOF in a male newborn with dysmorphic features and additional congenital malformations. Furthermore, we review the recent literature on cases of TA published between January 2005 until December 2010 taking into account the prenatal diagnosis, clinical presentation, management, and outcome of TA.

Case report

A healthy 34-year-old woman, gravida 2, para 1, was referred to our hospital at 22+2 of 7 weeks of gestation because of a double bubble sign on the standard anomaly scan. Third level ultrasonography revealed furthermore a

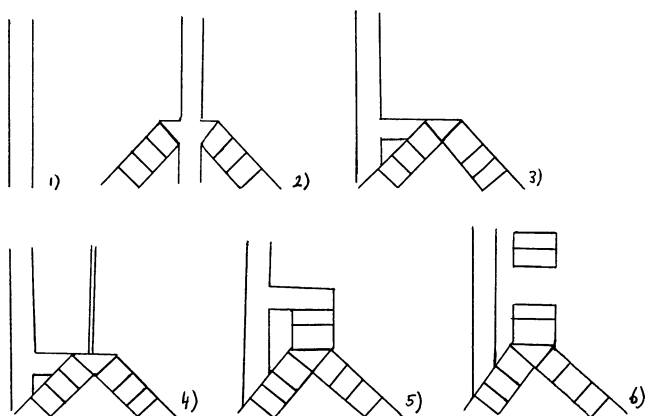


Fig. 1 Classification system of tracheal agenesis (TA). (1) Faro type A: total pulmonary agenesis. (2) Faro type B/Floyd type III: complete TA with a separate origin of the main bronchi from the esophagus. (3) Faro type C: total TA with normal main bronchi fusing in the midline at the carine; a trachea-esophageal fistula (TOF) is present. Floyd type II: total TA with normal main bronchi fusing in the midline at the carine; a TOF may or may not (not shown) be present. (4) Faro type D: larynx joined by atresic strand to distal trachea with a TOF present. (5) Faro type E/Floyd type I: agenesis of the proximal trachea with a normal caudal segment of the distal trachea and a TOF. Faro type F: agenesis of the proximal trachea with a normal caudal segment of the distal trachea and no TOF is present (not shown). (6) Faro type G: TA in a short segment

single umbilical artery, postaxial polydactyly of the left hand combined with a polyhydramnion. Amniocentesis showed a normal male karyotype (46,XY), and no subtelomeric and interstitial deletions and/or duplications were found with multiplex ligation-dependent probe amplification (MLPA) analysis. At 34+5 of 7 weeks of gestation, an emergency delivery by cesarean section was performed because of fetal distress. A hypotonic boy was born with no audible cry. The birth weight was 2,255 g (weight for gestational age, p25–50). Apgar scores were 5, 5, and 4 after 1, 5, and 10 min, respectively. His heart rate was 70 bpm. Spontaneous breathing movements were absent, and bag and mask ventilation was started. Several attempts for intubation failed, although there was clear vision of the vocal cords. Laryngoscopy by the ear–nose–throat surgeon showed no tracheal opening. Esophageal intubation improved oxygen saturation to 100%, suggesting the presence of a TOF. Tracheotomy was attempted, but no trachea could be identified. The tube was found in the esophagus, confirming TA. The boy died shortly after attempted tracheotomy. Clinical examination showed a premature boy with mild dysmorphic craniofacial features consisting of low implantation of both ears, a small folded right ear, flat face with small forehead, a relatively small head circumference of 23.7 cm (head circumference for gestational age, <p5), and microretrognathia. Furthermore, he had hypertrichosis, unilateral postaxial polydactyly type 1, hypoplastic toenails, and deep-seated hyperconvex finger nails (Fig. 2). At autopsy, the boy had a TA Floyd type II with a TOF (Fig. 3). Both lungs were bilobed with no other signs of left atrial isomerism. Total body X-ray showed fusion of the ninth till 12th rib and hemivertebra of the ninth thoracic vertebra. Furthermore, a duodenal atresia, an arteria lusoria, and a single umbilical artery were diagnosed. Postnatal array-based comparative genomic hybridization (array-CGH) showed no microdeletion or microduplication in the genome.

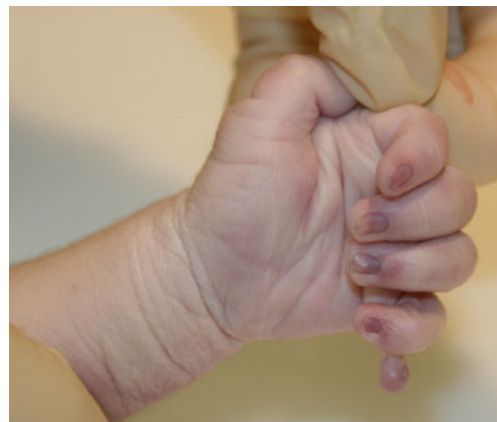

Fig. 2 Postaxial polydactyly type 1 of the left hand of the current case

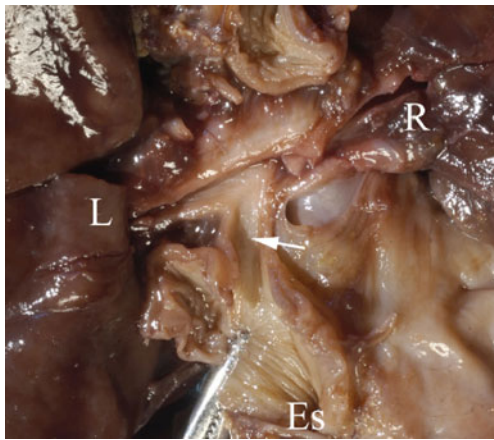


Fig. 3 Autopsy specimen of the current case. Showing a tracheoesophageal fistula (arrow) and bifurcation to the left (L) and right lung (R). Es esophagus

Methods

A Medline (PubMed) literature search was performed for all articles published between January 2005 until December 2010 with MeSH terms and key words including “tracheal/abnormalities,” “tracheal agenesis,” “tracheal aplasia,” “tracheal atresia,” “prenatal diagnosis,” “fetus,” and “newborn.” Titles and abstracts were examined to select potentially relevant studies specific about TA. Statistical analysis was performed using SPSS 17.0 (SPSS, Inc., Chicago, IL, USA). If data relevant for this review was missing, additional information was requested from the authors by e-mail.

Results

Forty-nine cases of TA, including our case, were found [1, 2, 4–7, 9–11, 14, 17, 18, 20, 23, 24, 26, 29–33, 35–38, 40, 42]. The perinatal characteristics, diagnostic investigations, and management are summarized (Table 1). In this review, diagnosis of TA was presumed prenatally in five cases based on congenital high airway obstruction syndrome (CHAOS). In four cases, CHAOS was seen on prenatal ultrasonography [7, 26, 38, 42]. Pregnancy was selectively terminated in two cases. Two newborns died shortly after birth. In one case, initially congenital cystic adenomatoid malformation (CCAM) was suspected on ultrasound; however, after fetal magnetic resonance imaging (MRI), TA was suspected, and an ex utero intrapartum therapy (EXIT) procedure was performed. The child died at the age of 3 months [38]. In another case, CCAM was also suspected, but fetal MRI was not carried out because of a non-reassuring cardiotocogram. The child died shortly after birth [9]. All five prenatal diagnosed cases of TA had no TOF; therefore, they presented as a classic CHAOS. In the

Table 1 Perinatal characteristics, diagnostic investigations, and management

	Outcome	<i>n</i>
Total (<i>x</i> (%))	49 (100)	49
Boy/girl (<i>x</i> (%))	33 (69)/15 (31)	48
Classification (<i>x</i> (%))		45
Floyd type I	11 (24)	
Floyd type II	17 (38)	
Floyd type III	10 (22)	
Faro’s classification	5 (11)	
No specification ^a	2 (5)	
Perinatal characteristics		
Mean maternal age (years (range))	27.5 (18–40)	28
Primigravida (<i>x</i> (%))	14 (58)	24
Twin pregnancy	5 (12)	42
Polyhydramnion (<i>x</i> (%))	28 (72)	39
Anhydramnion (<i>x</i> (%))	2 (5)	38
IUGR (<i>x</i> (%))	4 (11)	38
CHAOS (<i>x</i> (%))	5 (13)	38
CCAM suspicion (<i>x</i> (%)) ^b	2 (5)	38
Caesarean section (<i>x</i> (%))	16 (38)	42
Vaginal delivery (<i>x</i> (%))	26 (62)	42
Median GA (weeks (range))	34 (28–41)	45
Mean BW (gram (range))	2,048 (830–3,250)	38
Median AS (1/5 min)	3/5	25
Abnormal karyotype (<i>x</i> (%)) ^c	2 (11)	18
Diagnostic investigations (<i>x</i> (%))		
Laryngo-bronchoscopy	24 (57)	42
X-thorax	11 (26)	42
CT scan	6 (14)	42
Fetal MRI	1 (2)	42
Karyotyping	18 (58)	31
Management (<i>x</i> (%))		
Tracheotomy	18 (38)	48
Surgery after tracheotomy	10 (21)	48

Range: minimum–maximum; AS (1/5): Apgar score after respectively 1 and 5 min

n total amount of cases, *x* amount of selected cases, CHAOS congenital high airway obstruction syndrome, CCAM congenital cystic adenomatoid malformation, GA gestational age, BW birth weight

^a A patent segment of trachea which ended as a tracheoesophageal fistula (TOF) [20] or blind without a TOF [33]. In both cases, the esophagus continued as the only structure and then was totally replaced by the distal trachea and main bronchi

^b Suspected CCAM with ultrasonographic examination and suspected CHAOS on fetal MRI [38]

^c *mos 47,XY + mar (43,3)/46,XY (56,5)* [32] and *5q11.2* deletion [7]

cases without prenatal diagnosis, prenatal ultrasonography showed altered amniotic fluid status, mainly polyhydramnion. In 11 of 28 (39%) cases of polyhydramnion, no other

malformations besides TA were found. Commonly, clinical symptoms were respiratory distress with breathing movements without appropriate air entry, no audible cry, and failed intubation. In 18 of 31 cases (58.0%), chromosomal analysis was done, but in only two cases, an abnormal karyotype was found: *mos 47,XY + mar (43,3)/46,XY (56,5)* and *5q11.2* deletion [7, 32]. Associated anomalies were found in 32 (80%) of the cases (Table 2). Most frequent anomalies were cardiac septum defect, laryngeal defect, duodenal atresia, imperforate anus, and kidney and finger malformations. In the remaining eight (20%) cases, no associated malformations were identified by autopsy or computed tomography (CT scan). Mortality was high, as 34 of 40 (85%) children died within 2 days. After surgery, two children are still alive at 10 months and 4 years, respectively [37, 40].

Discussion

Prenatal diagnosis

TA is rarely suspected before birth; prenatal findings leading to the diagnosis of TA are only found when no TOF is present, consistent with the definition of CHAOS. CHAOS is characterized by enlarged hyperechogenic lungs, fluid filled dilated trachea, and bronchi demonstrating an absent flow in the trachea during fetal breathing, and in some cases, even the visualization of the obstruction, compression of the heart, with or without cardiac dysfunction, flattened diaphragm, and/or massive ascites. The classical signs of CHAOS are absent if a TOF is present because lung fluid can pass through the TOF to the stomach or amniotic sac. Therefore, the pressure in the lungs is normal, and the lungs will have a normal ultrasonographic appearance. In the present study, five of 49 cases were diagnosed prenatally because of symptoms related to CHAOS. Prenatal diagnosis in these five cases of TA was confirmed by fetal MRI or detailed ultrasound examination. Detailed ultrasound examination should be focused on abnormal fluid accumulations in the larynx or trachea. If uncertainty remains, fetal MRI can provide additional information [28]. If CHAOS is suspected, absence of amniotic phospholipids in amniotic fluid may support the diagnosis of TA because normally phospholipids are secreted into the amniotic fluid by the respiratory tract [8]. If TA is prenatally suspected, an EXIT procedure can be planned in a tertiary hospital as described by Vaikunth et al. [38]. They also suggested that infants with TA and a TOF may also benefit from the EXIT procedure by preventing hypoxia, but this has not been described as prenatal diagnosis of TA, and a TOF is still not yet possible. In this review, polyhydramnion was reported in 72% of the

cases. The presence of TA and a TOF may interfere with fetal swallowing because in 39% of the cases with polyhydramnion, no other congenital abnormalities interfering with fetal swallowing and/or absorption of fluid, such as gastrointestinal obstruction, were present. Development of polyhydramnion, particularly in combination with other frequent associated anomalies with TA, should alert clinician of the possibility of TA. Prenatal MRI may provide a definitive diagnosis.

Clinical presentation and diagnosis

Postnatal diagnosis can be established by recognition of the specific combination of clinical signs in the newborn: respiratory distress with breathing movements without appropriate air entry, no audible cry, and failed endotracheal intubation. Preterm labor and low birth weight (<2,500 g) and an Apgar score below 7 at 5 min are also common characteristics. If TA is accompanied by a TOF, bag and mask ventilation and (accidental) esophageal intubation may temporarily improve the respiratory status. After esophageal intubation, marked abdominal distension develops, and air passes through the fistula into the lungs that will give cycles of stabilization and deterioration. Laryngobronchoscopy can diagnose TA and a possible TOF. Radiographic findings may include posterior location of the endotracheal tube (esophageal intubation) and absence of the tracheal shadow. A CT scan is the procedure of choice for delineating the anatomy in newborns with suspected TA [36]. Contrast material may demonstrate a blind laryngeal sac and a TOF but are difficult to perform and unreliable due to potential airway compromise.

Management and outcome

In this review, tracheotomy was attempted in 38% of the cases to explore the options of surgical reconstruction. Often, no surgery could be performed because of severe asphyxia or death of the infant. Surgical management consists of esophageal ligation at the site distal to the TOF. This results in more effective ventilation because the esophagus can be used as a pseudo-trachea. The proximal part of the esophagus has to be taken out as a double barrel esophagostomy, with the distal end for intubation and the proximal end for salivary drainage. An external esophageal stent can prevent the esophagus from collapsing. Gastrostomy for feeding should be performed next. Reconstruction with small intestine, colon interposition, or gastric pull-up has been demonstrated to be feasible and compatible with survival [24]. Despite progress in surgical management, only two children are still alive and have a normal neurodevelopment after surgery [37, 40].

Table 2 Associated malformations

Malformations	<i>n</i>	(<i>x/n</i> (%))
Cardiovascular		
ODB	2	14/32
Hypoplastic left heart syndrome	1	(43.8)
ODB, TrA, transposition of the great arteries, pulmonary atresia, VSD, ASD, left superior vena cava to coronary sinus drainage	1	
VSD	4	
ASD	2	
ASD and VSD	1	
TOF	1	
Truncus arteriosus type 1	1	
Persistent vena cava superior, ASD	1	
Respiratory		
Incorrect amount of lung lobes	3	15/32
Laryngeal cleft	4	(46.9)
Laryngeal stenosis	4	
Choanal atresia	1	
Bronchial hypoplasia	1	
Enlarged lungs	1	
Laryngeal stenosis and bilobed right lung	1	
Gastro-intestinal		
Duodenal atresia	2	17/32
Imperforate anus and recto-urethral fistula	2	(53.1)
Imperforate anus and esophageal atresia	1	
Imperforate anus	6	
Esophageal atresia	2	
Duodenal atresia, pancreas annulare, malrotation of the bowel	2	
Duodenal atresia, gallbladder agenesis, Meckel's diverticulum	2	
Genitourinary		
Horseshoe kidney, hydroureters	1	9/32
Ureteral duplication left, hydronephrosis, and hydroureter right	1	(28.1)
Atrophic cystic kidney left en cystic kidney right	1	
Horseshoe kidney with hypoplasia right side and multicystic dysplasia with dilated ureters, undescended testis	1	
Horseshoe kidney	1	
Multi-dysplastic kidney	1	
Recto-vesical-urethral fistula	1	
Undescended testis	2	
Musculoskeletal		
Clubfoot	1	14/32
Clubfoot, micrognathia	1	(43.8)
Hemivertebra	2	
Hemivertebra, rib anomaly	1	
Skull asymmetry	1	
Fingers malformations	5	
Micro/retrognathia	1	
Micro/retrognathia, postaxial polydactyly, hemivertebrae, fused ribs	1	

Table 2 (continued)

Malformations	<i>n</i>	(<i>x/n</i> (%))
Micrognathia and muscular hypertrophy	1	
Nervous		
Macrocephaly	1	2/32
Microcephaly	1	(6.3)
Other		
Thymus agenesis	1	19/32
SUA	2	(59.4)
Low ear implant	1	
Malformed left ear	2	
Uterus agenesis	1	
SUA, thymus agenesis, polysplenia	2	
Arteria lusoria, hypertelorism	2	
Four finger line	1	
SUA, low ear implant, left ear malformation	1	
Low ear implant, arteria lusoria	1	
Low ear implant, small right ear, hypertrichosis, arteria lusoria, SUA, nail deformity	1	
Low ear implant, alopecia in left temporal area	1	
Prune belly like skin on abdomen	2	
Small left ear with closed meatus	1	

n total amount of cases, *x* amount of selected case, *ODB* open ductus

Classification of tracheal agenesis

Both the classifications of Floyd and Faro are inappropriate for all types of TA. This is due to the fact that a TOF, crucial for decision making, can not always be correctly classified, e.g., a Floyd type I without a TOF described in this review does not exist in the Floyd classification. Likewise, Floyd type II without a TOF is missing in the Faro's classification. We propose to use the Faro's classification system and add a Faro Type C without a TOF to it.

In the present review, Floyd type II was identified as the most common type of TA in line with the literature. The male:female ratio in this review was 2:1, similar to the literature [22, 39]. Further research is necessary to explain this male predominance of TA.

Associated malformations

Associated malformations can be part of the VACTERL association (Vertebral Defects, Anal Atresia, Cardiovascular Defects, Tracheoesophageal Fistula and/or Esophageal Atresia, Renal Defects, and Limb Defects) or TARCD association (Tracheal Agenesis/Atresia, Radial Ray Defects, Complex Congenital Cardiac Abnormalities, and Duodenal Atresia)15 [15]. Although TA and duodenal atresia are not

part of the acronym of VACTERL, tracheal *stenosis* and tracheal *atresia* have been described in fetuses with features of VACTERL [3], and duodenal atresia was found in 6.3% of children diagnosed with VACTERL association [21]. So far, no causal genes for these associations have been identified yet. TA can also be a part of Fraser syndrome, which is caused by mutations in *FRAS1* and *FREM2* genes [7]. Abnormal development of the larynx in combination with or without a TOF or other tracheal problems is also observed in several rare syndromes and in cases of chromosomal aneuploidy or interstitial (micro)deletions or (micro)duplications [5]. In one case, a de novo abnormal karyotype was found (*mos 47,XY + mar (43,3)/46,XY (56,5)*) as both parents had a normal karyotype. The marker chromosome was identified by FISH as a derivative from chromosome 22 and 15 [32]. This abnormal karyotype could contribute to the TA and associated malformations and may help to unravel the origin of the genetic cause of TA. A deletion on *5q11.2* region was found in another case, whose mother had normal karyotype while no paternal material was available [7]. Because TA is associated with other congenital anomalies, it is important to perform standard karyotyping as well as array-based comparative genomic hybridization (array-CGH) to detect microdeletions or duplications in the genome. Autopsy provides more details especially on malformations that cannot be detected by fetal ultrasound.

Conclusion

TA is a severe congenital defect with an unexpected emergency presentation. Prenatal diagnosis of TA is only possible in case of CHAOS. If a TOF is present, polyhydramnion and other congenital malformations on ultrasound should alert clinicians of potential tracheal problems. Prenatal MRI may provide a definitive diagnosis. Postnatal symptoms suggestive of the diagnosis are respiratory distress with strong respiratory efforts without good air entry, no audible cry, and failed endotracheal intubation. Associated malformations are often found and include cardiac septum defects, laryngeal defects, duodenal atresia, imperforate anus, kidney defects, and finger malformations. The diagnosis TA is often confirmed by laryngo-bronchoscopy, CT scan, and tracheotomy. Despite progress of surgical developments, the prognosis is poor. CGH array or genome wide assays, in addition to routine cytogenetic analysis, and autopsy are important to detect associated malformations and elucidate the cause(s) of TA.

Conflicts of interest The authors declare that they have no conflict of interest.

Open Access This article is distributed under the terms of the Creative Commons Attribution Noncommercial License which permits any noncommercial use, distribution, and reproduction in any medium, provided the original author(s) and source are credited.

References

1. Agarwal S, John S, Latta S, Sahni M, Kumar N (2006) Tracheal agenesis: two case reports. *Int J Pediatr Otorhinolaryngol* 70(4):737–739
2. Ahmad R, Abdullah K, Mokhtar L, Fadzil A (2009) Tracheal agenesis as a rare cause of difficult intubation in a newborn with respiratory distress: a case report. *J Med Case Reports* 3:105
3. Bercker S, Kornak U, Bühner C, Henrich W, Kerner T (2006) Tracheal atresia as part of an exceptional combination of malformations. *Int J Pediatr Otorhinolaryngol* 70(6):1137–1139
4. Bhattarai B, Pratap A, Yadav R, Pokharel K (2008) Anaesthetic management of tracheal agenesis. *J Nepal Med Assoc* 47(171):142–144
5. Bober K, Musialik-Swietlińska E, Adamiec-Poniewierka E, Pajak J, Bielecki I, Koszutski T, Więcek-Włodarska D, Goc B, Szydlowski L, Swietliński (2008) Tracheal agenesis: perioperative management of one stage correction. *Pediatr Anesth* 18(10):982–983
6. Chawla S, Natarajan G, Chouthai N, Kamat D (2009) CHAOS in the delivery room: a dire emergency. *J Pediatr* 155(5):756
7. de Jong EM, Douben H, Eussen BH, Felix JF, Wessels MW, Poddighe PJ, Nikkels PGJ, de Krijger RR, Tibboel D, de Klein A (2010) 5q11.2 deletion in a patient with tracheal agenesis. *Eur J Hum Genet* 18(11):1265–1268
8. de José MB, Drudis R, Monclús E, Silva A, Santander S, Cusi V (2000) Management of tracheal agenesis. *Pediatr Anesth* 10(4):441–444
9. de Luca D, de Carolis MP, Capelli A, Gallini F, Draisci G, Pinto R, Arena V (2008) Tracheal agenesis without esophageal fistula: genetic, resuscitative, and pathological issues. *J Pediatr Surg* 43(1):e29–e32
10. Demircan M, Aksoy T, Ceran C, Kafkasli A (2008) Tracheal agenesis and esophageal atresia with proximal and distal bronchoesophageal fistulas. *J Pediatr Surg* 43(8):e1–e3
11. Dijkman KP, Andriessen P, van Lijnschoten G, Halbertsma FJ (2009) Failed resuscitation of a newborn due to congenital tracheal agenesis; a case report. *Cases J* 2:7212
12. Domyan ET, Ferretti E, Throckmorton K, Mishina Y, Nicolis SK, Sun X (2011) Signaling through BMP receptors promotes respiratory identity in the foregut via repression of Sox2. *Development* 138(5):971–981
13. Effman EL, Spackman TJ, Berdon WE, Kuhn JP, Leonidas JC (1975) Tracheal agenesis. *Am J Roentgenol Radium Ther Nucl Med* 125(4):767–781
14. Erler T, Wetzel U, Biolik HB, Eichhorn T, Gurski A (2008) Tracheal aplasia—eine besonders seltene und dramatische fehlerbildung. *Klin Pädiatr* 220(4):271–274
15. Evans JA, Greenberg CR, Erdile L (1999) Tracheal agenesis revisited: analysis of associated anomalies. *Am J Med Gen* 82(5):415–422
16. Faro RS, Goodwin CD, Organ CH Jr, Hall RT, Holder TM, Ashcraft KW, Amoury RA (1979) Tracheal agenesis. *Ann Thorac Surg* 28(3):295–299
17. Felix JF, van Looij MA, Pruijsten RV, de Krijger RR, de Klein A, Tibboel D, Hoeve HLJ (2006) Agenesis of the trachea: phenotypic expression of a rare cause of fatal neonatal respiratory insufficiency in six patients. *Int J Pediatr Otorhinolaryngol* 70(2):365–370
18. Fischer D, Schloesser R, Veldman A (2007) Management of congenital tracheal agenesis. *Eur J Pediatr* 166(8):885

19. Floyd J, Campbell DC Jr, Dominy DE (1962) Agenesis of the trachea. *Am Rev Respir Dis* 86:557–560
20. Fraser N, Stewart RJ, Grant J, Martin P, Gibbin KP, Padfield CJH (2005) Tracheal agenesis with unique anatomy. *J Pediatr Surg* 40(10):e7–e10
21. Fujishiro E, Suzuki Y, Sato T, Kondo S, Miyachi M, Suzumori K (2004) Characteristic findings for diagnosis of baby complicated with both the VACTERL association and duodenal atresia. *Fetal Diagn Ther* 19(2):134–137
22. Haben CM, Rappaport JM, Clarke KD (2002) Tracheal agenesis. *J Am Coll Surg* 194(2):217–222
23. Heimann K, Bartz C, Naami A, Peschgens T, Merz U, Hörnchen H (2007) Three new cases of congenital agenesis of the trachea. *Eur J Pediatr* 166(1):79–82
24. Kanojia RP, Parikh M, Bhagat H, Bansal S, Menon P, Rao KLN (2009) Tracheal agenesis: case report with review of the current scenario and management reported over the past two decades. *Eur J Pediatr Surg* 19:1–3
25. Kluth D, Steding G, Seidl W (1987) The embryology of foregut malformations. *J Pediatr Surg* 22(5):389–393
26. Lupi M, Bonetti LR, Trani N, Maccio L, Maiorana A (2009) Congenital tracheal atresia in newborn: case report and review of the literature. *Pathologica* 101(6):235–239
27. Merei JM, Hutson JM (2002) Embryogenesis of trachea esophageal anomalies: a review. *Pediatr Surg Int* 18(5–6):319–326
28. Mong A, Johnson AM, Kramer SS, Coleman BG, Hedrick HL, Kreiger P, Flake A, Johnson M, Wilson RD, Adzick NS, Jaramillo D (2008) Congenital high airway obstruction syndrome: MR/US findings, effect on management, and outcome. *Pediatr Radiol* 38(11):1171–1179
29. Panthagani ID, Santos MC, D'Ángio CT (2009) Use of computed tomography to categorize the type of tracheal agenesis. *J Pediatr Surg* 44(5):1044–1046
30. Pragati S, Manisha K, Ruchi N (2007) Tracheal agenesis. *Indian J Pathol Microbiol* 50(4):848–849
31. Pratap A, Saha GS, Bhattarai BK, Rohit PY, Nepal A, Bajracharya A, Kumar A, Adhikary S (2007) Tracheal agenesis type B: further evidence to a lethal congenital tracheal malformation. *J Pediatr Surg* 42:1284–1287
32. Rupérez Lucas M, Bonet Serra B, Martínez Orgado JA, Guerrero Márquez C (2007) Agenesia traqueal asociada a malformaciones laríngeas como causa inusual de fracaso de la vía aérea. *An Pediatr* 67(3):236–239
33. Saccardi C, Ludwig K, Cosmi E, D'Antona D, Salmaso R, Fassina A (2010) Tracheal agenesis with bifurcating common airway arising from midesophagus. *Pediatr Dev Pathol* 13(3):252–254
34. Sandu K, Monnier P (2007) Congenital tracheal anomalies. *Otolaryngol Clin North Am* 40(1):193–217
35. Schummer W, Schummer C, Klemm P, Brodhun M, Neumann R, Bondartschuk M, Koscielny HA (2006) Trachealagenesie. Eine seltene Ursache der respiratorischen Insuffizienz des Neugeborenen. *Anaesthesist* 55(12):1259–1265
36. Strouse PJ, Newman B, Hernandez RJ, Afshani E, Bommaraju M (2006) CT of tracheal agenesis. *Pediatr Radiol* 36(9):920–926
37. Usui N, Kamiyama M, Tani G, Takama Y, Soh H, Uehara S, Fukuzawa M (2010) Three-stage reconstruction of the airway and alimentary tract in a case of tracheal agenesis. *Ann Thorac Surg* 89(6):2019–2022
38. Vaikunth SS, Morris LM, Polzin W, Gottliebson W, Lim FY, Kline-Faith B, Crombleholme TM (2009) Congenital high airway obstruction syndrome, due to complete tracheal agenesis: an accident of nature with clues for tracheal development and lessons in management. *Fetal Diagn Ther* 26(2):93–97
39. van Veenendaal MB, Liem KD, Marres HA (2000) Congenital absence of the trachea. *Eur J Pediatr* 159(1–2):8–13
40. Watanabe T, Okuyama H, Kubota A, Kawahara H, Hasegawa T, Ueno T, Saka R, Morishita Y (2008) A case of tracheal agenesis surviving without mechanical ventilation after external esophageal stenting. *J Pediatr Surg* 43(10):1906–1908
41. Zaw-Tun HA (1982) The trachea-esophageal septum—fact of fantasy? Origin and development of the respiratory primordium and esophagus. *Acta Anat (Basel)* 114(1):1–21
42. Zhou Q, Shi W, Zhang T, Tian L, Zeng S (2009) Prenatal diagnosis of type 1 tracheal agenesis without tracheoesophageal fistula. *J Obstet Gynaecol Res* 35(2):364–367