



Challenges of Diagnosing Viral Anterior Uveitis

Fahriye Groen-Hakan, Kalpana Babu, Ilknur Tugal-Tutkun, Kessara Pathanapithoon, Joke H. de Boer, Justine R. Smith, Jolanda D.F. de Groot-Mijnes & Aniki Rothova

To cite this article: Fahriye Groen-Hakan, Kalpana Babu, Ilknur Tugal-Tutkun, Kessara Pathanapithoon, Joke H. de Boer, Justine R. Smith, Jolanda D.F. de Groot-Mijnes & Aniki Rothova (2017) Challenges of Diagnosing Viral Anterior Uveitis, Ocular Immunology and Inflammation, 25:5, 710-720, DOI: [10.1080/09273948.2017.1353105](https://doi.org/10.1080/09273948.2017.1353105)

To link to this article: <http://dx.doi.org/10.1080/09273948.2017.1353105>



Published with license by Taylor & Francis©
Fahriye Groen-Hakan, Kalpana Babu, Ilknur Tugal-Tutkun, Kessara Pathanapithoon, Joke H. de Boer, Justine R. Smith, Jolanda D. F. de Groot-Mijnes, and Aniki Rothova.



Published online: 11 Oct 2017.



Submit your article to this journal [↗](#)



View related articles [↗](#)



View Crossmark data [↗](#)

ORIGINAL ARTICLE

Challenges of Diagnosing Viral Anterior Uveitis

Fahriye Groen-Hakan, MD¹, Kalpana Babu, MD, PHD², Ilknur Tugal-Tutkun, MD³, Kessara Pathanapithoon, MD, PHD⁴, Joke H. de Boer, MD, PHD⁵, Justine R. Smith, FRANZCO, PHD⁶, Jolanda D.F. de Groot-Mijnes, PHD⁷, and Aniki Rothova, MD, PHD¹

¹Department of Ophthalmology, Faculty of Medicine, Erasmus University, Rotterdam, The Netherlands, ²Prabha Eye Clinic & Research Centre, Vittala International Institute of Ophthalmology, Bangalore, India, ³Department of Ophthalmology, Istanbul Faculty of Medicine, Istanbul University, Istanbul, Turkey, ⁴Department of Ophthalmology, Faculty of Medicine, Chiang Mai University, Chiang Mai, Thailand, ⁵Department of Ophthalmology, Faculty of Medicine, Utrecht University, Utrecht, The Netherlands, ⁶Eye & Vision Health, Flinders University School of Medicine, Adelaide, Australia, and ⁷Department of Medical Microbiology, Utrecht University, Utrecht, The Netherlands

ABSTRACT

The viral causes of anterior uveitis (AU) emerged with the use of novel molecular diagnostic tests and serologic tests adapted for small volumes (Goldmann-Witmer Coefficient). The viral causes of AU may be underestimated, and some of the presumed idiopathic AU cases will probably be proven to be of viral origin in the coming years. So far, a viral origin of AU was suspected in patients who presented with unilateral hypertensive AU. It is not clear which clinical presentations should raise a suspicion of viral etiology. There is an overlap in the clinical manifestations of AU caused by viruses and other non-viral forms of AU. A viral cause of AU should be suspected in patients with unilateral AU, exhibiting small or medium sized KPs, some form of iris atrophy, high IOP and early development of a cataract and the definitive diagnosis can be proven by aqueous humor analysis.

Keywords: Anterior Uveitis, Clinical Features, Diagnosis, Viral Uveitis

INTRODUCTION

Anterior uveitis (AU) is the most common anatomic type of uveitis encountered by ophthalmologists.¹ Though traditionally reported that most cases of AU are of unknown origin, the specific etiology may presently be documented in a substantial number of cases. The AU has multiple causes and in adults, the most frequent entity is Human Leukocyte Antigen-B27 (HLA-B27)-associated uveitis, whilst juvenile idiopathic arthritis (JIA)-associated AU is the most frequent entity occurring in children.^{1,2} The viral causes of AU emerged with the use of novel molecular diagnostic tests and serologic tests adapted for small

volumes (Goldmann–Witmer Coefficient; GWC). The viral causes of AU may be underestimated, and some of the presumed idiopathic AU cases will probably be proven to be of viral origin in the coming years.

The most common AU-incident infections and associated systemic diseases are given in Tables 1 and 2. Herpes simplex virus (HSV) and varicella zoster virus (VZV) represent common viral causes of AU in the West, whilst cytomegalovirus (CMV) is more frequent in Asia.^{1,3,4} In contrast to decreasing prevalence of rubella virus (RV)-associated AU in vaccinated populations, novel uveitis entities, such as Ebola virus and Zika virus-associated uveitis, were discovered during recent epidemics.⁵

© Fahriye Groen-Hakan, Kalpana Babu, Ilknur Tugal-Tutkun, Kessara Pathanapithoon, Joke H. de Boer, Justine R. Smith, Jolanda D. F. de Groot-Mijnes, and Aniki Rothova.

This is an Open Access article distributed under the terms of the Creative Commons Attribution-NonCommercial-NoDerivatives License (<http://creativecommons.org/licenses/by-nc-nd/4.0/>), which permits non-commercial re-use, distribution, and reproduction in any medium, provided the original work is properly cited, and is not altered, transformed, or built upon in any way.

Received 8 June 2017; revised 5 July 2017; accepted 5 July 2017

Correspondence: Fahriye Groen, Department of Ophthalmology, Erasmus Medical Center, Erasmus University, Dr. Molewaterplein 50-60, 3015 GE Rotterdam, The Netherlands

Color versions of one or more of the figures in the article can be found online at www.tandfonline.com/oiioi.

TABLE 1. Common causes and associations with systemic diseases of patients with anterior uveitis.

	Most common	Less common
Infectious viral anterior uveitis	<i>Herpes simplex virus</i> <i>Varicella zoster virus</i> <i>Cytomegalovirus</i> <i>Rubella virus</i>	<i>Human T-cell lymphotropic virus type 1</i> <i>Human immunodeficiency virus</i> <i>Chikungunya virus</i> <i>Zika virus</i> <i>Ebola virus</i> Presumed viral causes: <i>Epstein–Barr virus</i> <i>Parvovirus</i>
Infectious Bacterial anterior uveitis	Bacterial causes: <i>Treponema pallidum</i> <i>Mycobacterium tuberculosis</i>	
Non-infectious Rheumatologic diseases	HLA-B27-associated uveitis JIA-associated uveitis	Psoriatic arthritis: <i>HLA-B27 positive and negative</i> Reactive arthritis Rheumatoid arthritis
Autoimmune systemic diseases	TINU syndrome	Vogt–Koyanagi–Harada syndrome Granulomatosis with polyangiitis Sjögren’s disease Systemic sclerosis Autoimmune hepatitis
Autoinflammatory systemic diseases	Sarcoidosis-associated uveitis	Inflammatory bowel disease: <i>Ulcerative colitis, Crohns’ disease</i> Systemic vasculitis: <i>Behcet’s disease</i> Relapsing polychondritis

HLA-B27 = Human Leukocyte Antigen B27, JIA = Juvenile Idiopathic Arthritis, TINU = Tubulointerstitial Nephritis and Uveitis Syndrome.

So far, a viral origin of AU was suspected in patients who were presented with unilateral hypertensive AU. Further, distinctive signs were described for separate viruses, but it is not clear which clinical presentations should raise a suspicion of viral etiology. Herein we summarize the typical clinical manifestations of the common types of AU encountered in clinical practice and attempt to delineate the clinical characteristics commonly seen in patients with viral AU.

CLINICAL FEATURES OF COMMON NON-INFECTIOUS ANTERIOR UVEITIS ENTITIES

Human Leukocyte Antigen-B27-Associated Anterior Uveitis

Human leukocyte antigen-B27-associated uveitis is characterized by unilateral alternating acute non-granulomatous AU with marked fibrinous reaction or hypopyon [Figure 1](#), occurring typically in young adults, and has a frequent association with seronegative arthritic syndromes, of which the most prevalent is ankylosing spondylitis. Patients typically present with sudden onset of a classic triad of pain, redness, and photophobia. The main external signs are conjunctival and perilimbal redness. The anterior segment shows diffuse cells and flare in the anterior chamber; sometimes with cells adhering to corneal endothelium, but large keratic precipitates (KPs) are not present. Intraocular pressure (IOP) often decreases in the

acutely inflamed eye, but in severe cases, a fibrinous exudate and posterior synechiae may occlude the entire pupil leading to iris bombé and dramatic elevations in IOP. Less typical presentations involve posterior segment involvement including vitritis with or without pars plana exudates, optic disc swelling or papillitis, and cystoid macular edema (CME). Chronic AU as well as episcleritis and scleritis are less typical.²

Sarcoidosis-Associated Anterior Uveitis

Sarcoidosis may be associated with all anatomical types of uveitis. Anterior uveitis due to sarcoidosis is typically seen in young adults, more often in non-Caucasian races. The patient with sarcoidosis-associated AU may present with a few complaints and a relatively white eye. Raised IOP is often noted. Sarcoidosis-associated AU shows predominantly bilateral granulomatous inflammation with large fatty KPs located in the inferior part of the cornea (Arlt’s triangle, [Figure 2](#)) and has sometimes also characteristic granulomatous lesions on the iris, such as Koeppe and/or Busacca nodules. Posterior and anterior synechiae are common in this entity, and may be associated with the development of glaucoma.⁶ Cystoid macular edema is a common complication of sarcoidosis-associated AU.^{7,8} The presence of systemic sarcoidosis in a patient with uveitis of unknown origin is generally accepted as a confirmation of sarcoidosis-associated AU. Ocular signs suggestive of sarcoidosis were assessed by the initiative to define clinical criteria for

TABLE 2. Clinical features of common anterior uveitis entities.

	HLA-B27-associated anterior uveitis	Sarcoidosis-associated anterior uveitis	JIA-associated anterior uveitis	TINU	Bacterial anterior uveitis	Viral AU
Redness	+++	-/+++	-	-/+++	+ /+++	- /+++
Laterality	Alternating bilateral	Unilateral + Bilateral ++	Unilateral- Bilateral ++	Unilateral- Bilateral++	Unilateral + Bilateral +	Unilateral
Cornea involvement	No	No	Band keratopathy common	No	Stromal opacities possible (tuberculosis)	Scars, maculae, active keratitis (HSV, VZV), endotheliitis (CMV, HSV)
KPs	Usually none or Non-granulomatous	Granulomatous mutton-fat	Usually none or fine deposits	Usually none	Granulomatous mutton-fat	Small/fine/stellate or mixed size (rubella)
Type/Morphology	Small/fine	Inferior	Variable		Inferior cornea	Coin lesions (CMV)
Location/Distribution	Variable					Mutton fat unusual
Pupil abnormalities	Miosis, posterior synechiae	Miosis, posterior synechiae	Miosis, posterior synechiae	Miosis, posterior synechiae	Miosis, posterior synechiae	Usually whole endothelium -or adjacent to old corneal scars
Iris atrophy	None	None	None	None	None	Miosis, irregular pupil, posterior synechiae (HSV, VZV)
Posterior synechiae	++	++	++	+	++	Occasionally anisocoria inversa (RV, CMV)
Vitritis	Sometimes in anterior part	Not applicable	Sometimes in anterior part	0/++	Not applicable	Diffuse (RV, CMV, HIV or sector atrophy (HSV, VZV)
Early development of cataract	-	-	++	-	-/+	- /+++ (absent in rubella associated uveitis)
High IOP during acute stage	-	- /++	-	+ /-	- /+++	- /+++

HLA-B27 = Human Leukocyte Antigen B27, JIA = Juvenile Idiopathic Arthritis, TINU = Tubulointerstitial Nephritis and Uveitis Syndrome, AU = Anterior Uveitis, HSV = Herpes Simplex Virus, VZV = Varicella Zoster Virus, CMV = Cytomegalovirus, KP = Keratic Precipitate, RV = Rubella Virus, HIV = Human immunodeficiency Virus, IOP = Intraocular Pressure.

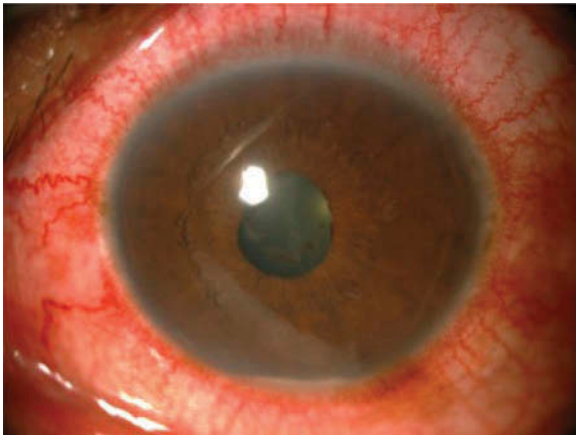


FIGURE 1. Conjunctival and perilimbal redness with fibrinous reaction seen in the pupil and hypopyon in patient with HLA-B27-associated AU

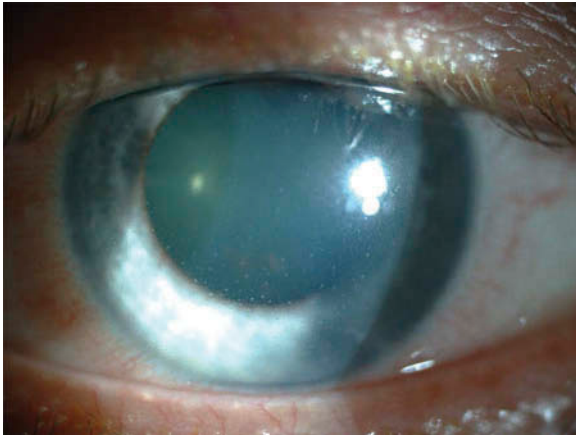


FIGURE 2. Keratic precipitates in sarcoidosis-associated anterior uveitis

the diagnosis of intraocular sarcoidosis (International Workshop on Ocular Sarcoidosis; IWOS).⁶

Juvenile Idiopathic Arthritis-Associated Anterior Uveitis

Anterior uveitis is the most common anatomic localization found in childhood uveitis and is associated with JIA in approximately 80% of the cases.⁹ Development of uveitis is most common among patients with oligoarticular, rheumatoid factor-negative and psoriatic arthritis subtypes. Antinuclear antibodies (ANAs) are positive in 90% of the patients.¹⁰ Clinical features of JIA-associated uveitis include mostly bilateral non-granulomatous inflammation, anterior in location, insidious at onset with chronic course. Juvenile idiopathic arthritis-associated AU is frequently initially asymptomatic. Uveitis in JIA can worsen over time as a result of many sight-threatening complications, such as band keratopathy in the visual

axis, posterior synechiae, cataract, secondary glaucoma, macular edema, hypotony, epiretinal membrane, and optic nerve edema. Different studies have pointed out that several factors are associated with poor prognosis, including young age at onset, male gender, short interval between diagnosis of arthritis and uveitis, severity of uveitis at onset and ANA positivity.^{11–14} Unilateral permanent visual loss at the age of 18 was observed in 33% of the patients and bilateral visual loss occurred in 4%.¹⁵ Although uveitis in JIA is considered a disease of childhood, the majority of the patients experience persistent ocular inflammation into adulthood.¹⁵

Tubulointerstitial Nephritis and Uveitis Syndrome

Tubulointerstitial nephritis and uveitis (TINU) syndrome affects mostly young patients with a peak incidence at the age of 14 years.¹⁶ It accounts for 1%–2% of all uveitis patients in specialized centers, but this number is probably underestimated since the nephritis component is often self-limiting and therefore not recognized.¹⁷ Uveitis in TINU syndrome has mostly a chronic bilateral course and is frequently classified as AU in the literature, however vitritis may be prominent.^{18,19} Definitive diagnosis of TINU syndrome is based on histopathological examination of renal tissue. However, renal biopsy is not being performed in mild cases, because of the associated risks.¹⁶ Probable TINU syndrome can be diagnosed by abnormal renal function urine analysis and systemic illness in the presence of uveitis.¹⁶ The combination of urinary β -2 microglobulin and serum creatinine is a relatively simple screening tool for renal dysfunction in order to diagnose probable TINU syndrome in young patients with uveitis.¹⁸

Toxic Uveitis

Past and current medication history may reveal an association of AU with the development of inflammatory or toxic reactions to diverse medications used by various routes.^{20–22} Topical prostaglandin analogues may cause an acute non-granulomatous or chronic granulomatous AU. Topical brimonidine has been associated with a chronic AU, characterized by diffusely distributed stellate or micro-granulomatous KPs and a mild anterior chamber reaction, with or without concurrent conjunctivitis.²³ Intravitreal triamcinolone acetonide or anti-vascular endothelial growth factor (VEGF) injections may cause a mild AU or a sterile endophthalmitis with hypopyon in more severe cases.²⁰ An acute bilateral hypopyon may develop in immunocompromised patients who receive rifabutin as prophylaxis against *Mycobacterium avium* complex.^{20,21} Biphosphonates

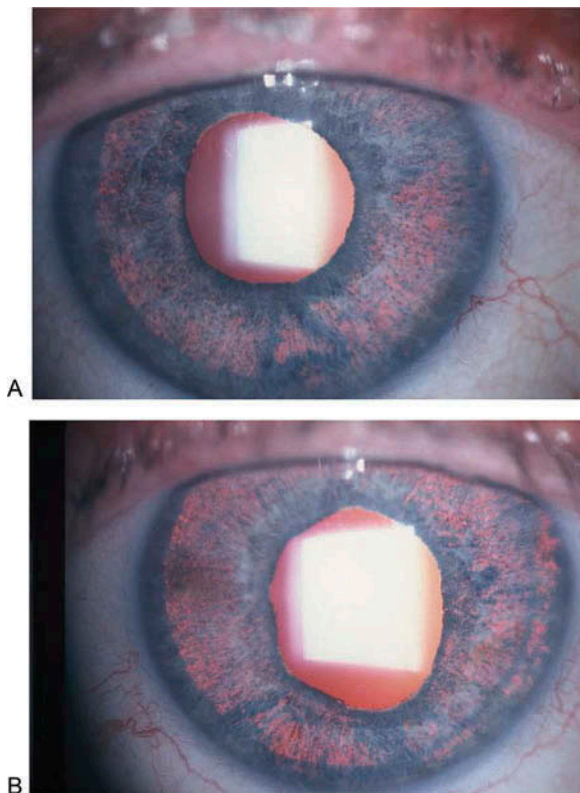


FIGURE 3. Diffuse iris transillumination and mild dilated distorted pupils in the right (A) and left (B) eye of a 56-year-old woman who had symptoms of bilateral acute iridocyclitis 1 month after the use of oral moxifloxacin for the treatment of urinary system infection

that are used for the treatment of osteoporosis may cause an acute bilateral nongranulomatous AU with or without scleritis.^{20–22} Intravenous or intravitreal administration of cidofovir, an antiviral agent used for the treatment of CMV retinitis, may cause non-granulomatous AU typically associated with ocular hypotony.^{20,21} Bacillus Calmette–Guérin (BCG) vaccination or intravesical BCG for the treatment of bladder cancer may rarely cause an acute bilateral non-granulomatous or granulomatous AU.²⁰ Melanoma or metastatic cancer patients receiving immune checkpoint inhibitors, such as ipilimumab, pembrolizumab, or nivolumab, may present with red eyes and mild or severe AU with posterior synechiae which may also be associated with keratitis.²² Antitumor necrosis factor (TNF) agents, particularly etanercept, may cause a paradoxical intraocular inflammation, which may sometimes present as a sarcoid-like granulomatous anterior uveitis.^{20,21} Bilateral acute iris transillumination (BAIT) syndrome, which can mimic acute iridocyclitis, has been linked to oral fluoroquinolones, especially moxifloxacin **Figure 3**. It is characterized by severe photophobia associated with bilateral pigment dispersion into the anterior chamber, diffuse iris transillumination, and atonic distorted pupils.²⁴

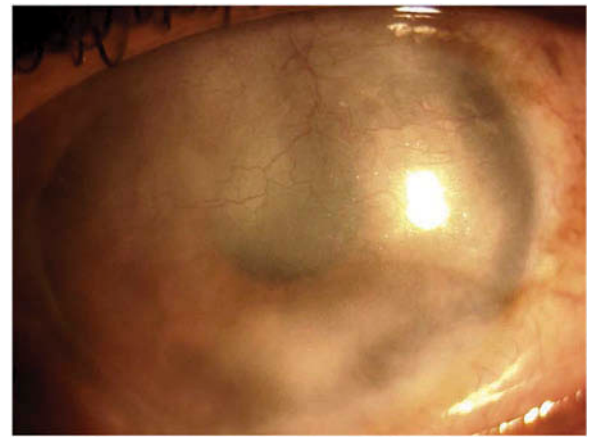


FIGURE 4. Interstitial keratitis due to tuberculosis

CLINICAL FEATURES OF COMMON BACTERIAL ANTERIOR UVEITIS ENTITIES

Syphilis-Associated Anterior Uveitis

Non-granulomatous as well as granulomatous inflammation with iris nodules and posterior synechiae may be the initial presentations of syphilis. Roseolae located on the iris represent a known feature in syphilis. Episcleritis, scleritis, keratitis, and hypopyon were also reported. Increase in IOP can occur during active inflammation. The diagnosis is usually based on serological tests. The Centers for Disease Control and Prevention currently recommends Enzyme Immunoassays (EIAs) and Chemiluminescent Immunoassays (CIAs) to detect antibodies to treponemal antigens as the best screening tests for syphilis followed by testing of positive specimens with the non-treponemal test, rapid plasma regain (RPR). Specimens positive by EIA and CIA and negative on RPR are submitted for a confirmatory *Treponema pallidum* particle agglutination test and if positive, the diagnosis of syphilis is confirmed.^{25,26}

Tuberculosis-Associated Anterior Uveitis

Intraocular inflammation secondary to tuberculosis (TB) is common in developing countries. Patients with AU due to TB present with unilateral or bilateral symptoms of redness, pain, photophobia, and floaters. Tuberculosis-associated AU can be markedly asymmetric. Adjacent ocular involvement in the form of scleritis, interstitial keratitis **Figure 4**, phlycten and chronic conjunctivitis may also be seen. Anterior uveitis is characterized by medium to large KPs **Figure 5**, which can be few or diffuse over the corneal endothelium. Pigmented hypopyon has also been reported in intraocular TB. Fibrin in anterior chamber may be seen in aggressive inflammation. Inflammation may also be accompanied by Koeppe or Busacca nodules, or by nodules located in the iridocorneal

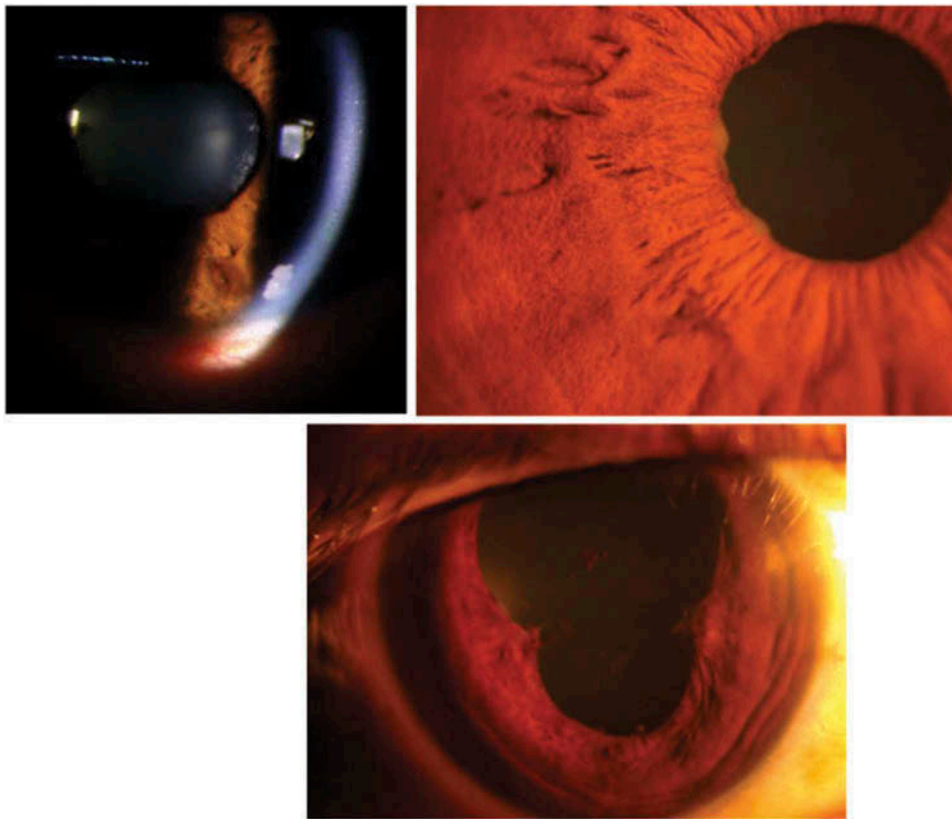


FIGURE 5. Large keratic precipitates with Koepple nodules on the pupillary margin and broad posterior synechiae in ocular tuberculosis

angle Figure 5, which may lead to secondary glaucoma. Broad-based posterior synechiae may also be seen Figure 5. Long standing chronic anterior uveitis may be associated with formation of pupillary membranes and iris neovascularization. Anterior uveitis may be accompanied by posterior segment involvement like choroiditis, retinal vasculitis, choroidal tuberculomas, optic nerve granulomas, and intermediate uveitis. Cataract and glaucoma are known complications seen in chronic AU. Confirmation of ocular TB is usually based on indirect evidence (diagnosis of systemic TB and/or good therapeutic response to anti-tuberculous therapy) and tests based on direct examinations of ocular tissues are less common. Molecular techniques performed on the intraocular fluids are becoming more widespread, but their clinical relevance is not yet clearly established).^{27,28}

CLINICAL FEATURES OF COMMON VIRAL ANTERIOR UVEITIS ENTITIES

Herpes Simplex Virus and Varicella Zoster Virus-Associated Anterior Uveitis

Herpes simplex virus and VZV, just as CMV belong to the Herpesviridae family. Following primary infection,

life-long latency is a characteristic feature of this virus family.^{29,30} These viruses may present with AU, keratitis, dermatitis and/or conjunctivitis.²⁹

Common features of AU due to HSV or VZV infection are the unilateral localization and acute course commonly associated with subsequent recurrences or development of chronicity. Anterior chamber inflammation may be severe, and KPs of diverse types and sizes have been reported. An irregular pupil is a typical finding and is caused by iris atrophy (typically sectoral in HSV or more diffuse in VZV), which is caused by ischemic necrosis of iris stroma.³¹ Intraocular pressure is usually elevated during the acute stage and subsequent development of glaucoma is common.

Associated corneal opacities in herpetic AU are commonly observed, but corneal involvement may be entirely absent. Herpes simplex virus-associated keratitis typically shows stromal inflammation with associated endotheliitis and fine corneal dendrites without elevated appearance, while VZV-associated keratitis is interstitial with corneal ring infiltrates and rough dendrites lacking terminal bulbs that can have an elevated appearance.^{29,30} Furthermore, patients with HSV or VZV-associated AU show decreased corneal sensation.^{30,32,33} In contrast to HSV, VZV may show involvement of the vitreous.³⁴ HSV usually affects children and young adults, VZV is more often

seen in elderly and immunocompromised patients. Primary infection with HSV is characterized by typical skin or mucosa lesions. Varicella zoster virus gives a skin rash with associated vesicles, preceded by pain, in the ipsilateral dermatome. In cases associated with uveitis, typically the tip of the nose is also affected (Hutchinson sign).

Cytomegalovirus-Associated Anterior Uveitis

Cytomegalovirus-associated anterior segment inflammation in non-human immunodeficiency virus (HIV)-infected patients has a spectrum of clinical presentations, including Posner–Schlossmann and Fuchs uveitis syndromes (FUS). Cytomegalovirus-associated AU may also present as corneal endotheliitis, with corneal edema ranging from a small localized area to diffuse bullous keratopathy, associated with mild AU. The IOP is often acutely or chronically elevated. Keratic precipitates may be non-granulomatous, granulomatous or stellate, and are usually located in the inferior half of the cornea. They may be diffuse, linear or show a ring pattern or may appear as a coin-like lesions. White, medium-sized, nodular lesions surrounded by a translucent halo are also possible. Vitritis or retinitis in these eyes is rare.^{35,36}

Rubella Virus-Associated Anterior Uveitis

Rubella virus-associated AU was reported as one of the causes of FUS.^{5,37,38} However, RV-associated AU does not always fulfill the criteria of FUS. Patients with RV-associated AU are usually young adults at time of first ophthalmological presentation, and at that time typically have mild uveitis without synechiae, but may already have a cataract causing visual impairment. Unilateral involvement, the presence of fine KPs and diffuse iris atrophy are typical for RV-associated AU.³⁹ Multiple iris nodules, easily visible in brown eyes, might be overlooked in patients with a light iris. The absence of redness and pain are typical. Focal “toxoplasmosis-like” chorioretinal scars may be seen.³⁴ The presence of vitritis is frequent, and RV-associated AU may be mistaken for idiopathic intermediate uveitis.

Human T-Cell Lymphotropic Virus Type 1-Associated Anterior Uveitis

Southern Japan and Africa are the endemic areas for human T-cell lymphotropic virus type 1 (HTLV-1) infection. Major ocular symptoms of HTLV-1-associated uveitis are sudden onset of floaters and blurred vision, but pain, itching, and foreign body sensation may also be reported.^{40–42} On examination, typically uni- or bilateral mild iritis is seen, frequently

associated with vitritis. Retinal vasculitis may also be seen.^{40–42} Graves’ disease is probably a risk factor for HTLV-1 associated uveitis and HTLV-1 associated uveitis appears to be related to HTLV-1 induced myelopathy, however these relationships require further investigation.^{42,43} In short, HTLV-1 associated uveitis is most frequently of intermediate type.

Human Immunodeficiency Virus-Associated Anterior Uveitis

Human immunodeficiency virus (HIV) causes a multi-system disease that may also involve the eyes. The presence of intraocular HIV-1 RNA was shown in about one-third of HIV-positive patients with infectious uveitis, but the HIV loads in the eye were typically lower than in plasma.⁴⁴ Human immunodeficiency virus-induced uveitis was reported in patients in whom HIV loads in intraocular fluids exceeded the plasma loads; these patients are typically highly active, anti-retroviral therapy (HAART)-naïve and have low CD4 counts.^{45,46} Patients with HIV-associated uveitis complain of decreased vision but pain or conjunctival hyperemia is characteristically absent. The anatomic location of uveitis is typically anterior associated with vitritis and resembles FUS, but is more frequently bilateral. There are no associated retinal lesions or scars, no findings suggestive of opportunistic infections, and patients do not respond to topical corticosteroid therapy. Anterior segment inflammation is mild; KPs are small and/or medium sized, and scattered on the whole corneal endothelium. After the administration of HAART, the intraocular inflammation disappears quickly, as the intraocular and plasma HIV loads decrease. Therefore, HIV-induced uveitis should be suspected in non-treated HIV-positive patients or in those in whom such treatment has failed or in HIV-positive patients who have AU without any retinal lesions, no proven infectious cause and exhibit no response to topical corticosteroids.⁴⁷

Chikungunya Virus-Associated Anterior Uveitis

Non-granulomatous AU may occur after a recent history of systemic chikungunya virus infection. Fine- to medium-sized KPs with pigmentation may be seen distributed all over the endothelium. The IOP may be increased at the time of active inflammation. A FUS pattern may also be seen in chikungunya virus-related AU.⁴⁸ Accompanying posterior segment involvement in the form of retinitis is seen in many cases. Confirmation is by polymerase chain reaction (PCR) for chikungunya viral RNA. Treatment is usually with anti-inflammatory agents, like non-steroidal anti-inflammatory drugs (NSAIDs) and topical corticosteroids.^{48–50}

Zika Virus-Associated Anterior Uveitis

Zika virus disease is a mosquito-borne infection transmitted by the *Aedes aegypti* mosquito. There are also reports describing infection following sexual, perinatal, and blood transfusions. The Zika virus infection was first reported in Uganda, clinically showing a similar presentation to Dengue virus.⁵¹ The disease is mild in adults with acute infection, and includes anterior uveitis with non-purulent conjunctivitis. It has a benign prognosis and is treated with topical steroids. In congenital infections, microcephaly is commonly described, and ocular findings include anterior segment abnormalities, such as iris coloboma and lens subluxation.^{52,53}

Ebola Virus-Associated Anterior Uveitis

Survivors of Ebola virus infection in convalescent phase suffer a slow and painful recovery with development of many complications. Around 20% of survivors of Ebola virus infection develop uveitis (after recovery of systemic disease), suggesting that the virus remains viable in the eye.⁵⁴ It remains unclear whether Ebola-associated AU is caused by cytopathic effect of the virus or represents an immune response, but one study reports on the detection of Ebola virus in aqueous humor of a patient with uveitis after the clearance of viremia.^{55,56} Anterior uveitis has been reported, which usually presents with KPs and posterior synechiae. Cataract and ocular hypertension may also occur in Ebola-associated AU.⁵⁴ Approximately 40% of eyes become blind according to the World Health Organization classification. There are no known demographic and physical risk factors for the development of uveitis in Ebola virus infection survivors, with the exception of higher viral blood load. Interestingly, optic neuropathy without uveitis was also reported.^{57–60}

Uncertain Viral Anterior Uveitis Entities

Epstein–Barr virus-associated anterior uveitis

Epstein–Barr-virus (EBV) is also a member of the herpes virus family. It has repeatedly been reported as a cause of diverse types of uveitis, but the role of EBV in uveitis is not entirely clear, since PCR in aqueous fluid can be positive in EBV-infected patients without uveitis.^{61–64} Evidence of intraocular EBV antibody synthesis in AU is scarce.^{65,66} However, antiviral treatment with valgancyclovir of presumed EBV uveitis has been reported to be beneficial in patients presenting with uveitis and positive EBV serology. Epstein–Barr-virus-associated AU can be preceded by a flu-like prodrome and manifest as severe AU with fibrinous exudate in the acute stage, associated also with hyperemia and edema of the optic disc.

Parvovirus-associated anterior uveitis

Acute parvovirus B19 infection causes erythema infectiosum or fifth disease in children, sometimes with polyarthritides. Interestingly, after acute infection, serum autoantibodies may be measured in these patients, such as ANAs and rheumatoid factor.⁶⁷ This similarity to JIA, in which patients may also have arthritis accompanied by ANA formation, raises the suspicion of a link between parvovirus B19 and JIA. Specific intraocular antibody production has been reported in patients with JIA-associated uveitis.⁶⁸ There is little evidence that parvovirus B19 is a direct cause of uveitis, however; in rare instances, parvovirus B19-associated uveitis has been reported.^{69–71} Parvovirus B19 DNA was detected in aqueous humor of occasional patients with uveitis, but was also found in patients with cataract and serous retinal detachment.^{70, 72}

CLINICAL SYNDROMES IN ANTERIOR UVEITIS

Fuchs Uveitis Syndrome and Posner–Schlossman Syndrome

Fuchs uveitis syndrome, which was first described in the medical literature almost 200 years ago, presents a clinical picture of unilateral chronic AU; although variations are described, typical features include small “stellate” KPs diffusely distributed across the corneal endothelium, low-grade anterior chamber cell and flare, absence of posterior synechiae, iris atrophy that ultimately results in the appearance of iris heterochromia, anterior vitreous cells, and secondary cataract and glaucoma.⁷³ Recently confocal scanning laser ophthalmoscopy has expanded on these features, including identification of dendritiform and stippled KPs by standard scanning, and of abnormalities in iris autofluorescence by near-infrared scanning.^{74,75} Posner–Schlossman syndrome, or glaucomato-cyclitic crisis, also was first recognized by ophthalmologists many generations ago, as a unilateral acute recurrent AU with few KPs, low-grade anterior chamber cells and flare, and markedly elevated IOP.⁷⁶ More recent descriptions have highlighted the potential for progressive glaucomatous optic disc and visual field changes.⁷⁷ Almost simultaneously, infectious causes now have been assigned to both FUS and Posner–Schlossman syndrome. Rubella virus has been recognized as a cause of FUS, with epidemiological evidence from the United States showing a decline in incidence since the introduction of the rubella vaccination and an increase in the percentage of cases in foreign-born residents, and detection of RV in aqueous humor by

GWC measurement and/or PCR.^{5,38,39} Separately, PCR analyses in aqueous humor have identified CMV in patients previously diagnosed with Posner–Schlossman syndrome or FUS.³⁶ It is likely that other viruses may cause clinical pictures that suggest one of these syndromes, as exemplified by the report from India, of a patient with bilateral FUS, whose aqueous fluid tested positively for Chikungunya viral, but not RV, DNA by PCR.⁴⁸ Although it should be noted that concomitant involvement of RV could not be excluded as GWC, which has a sensitivity of nearly 100%, compared to 10%–20% for PCR, was not performed.

Immune Recovery Uveitis

Immune recovery uveitis (IRU) may present as an isolated anterior uveitis or more commonly with concurrent vitritis and CME, following immune recovery after highly active antiretroviral therapy in HIV patients or after tapering or discontinuation of immunosuppressive therapy in non-HIV patients with CMV retinitis. The condition represents an active immune response to CMV antigens that persist in the eye.^{78–80} Posterior synechiae and posterior subcapsular cataract may develop, and after intraocular surgery, the post-operative course may be complicated by large inflammatory deposits on the surface of the intraocular lens.⁷⁸

LABORATORY DIAGNOSIS OF VIRAL UVEITIS

For the laboratory diagnosis of viral AU, one may perform blood analysis. However, serology at the most excludes a certain virus in the case of a negative result, or indicates whether a patient has ever been infected with the particular virus in the case of a positive result. In addition, most causes of viral AU have high seroprevalences in most parts of the world, particularly VZV and RV, rendering serology for these causes of little value. Polymerase chain reaction on peripheral blood is by no means conclusive, as negative results do not exclude an intraocular infection, and positive results do not prove one. A definitive diagnosis is only obtained by intraocular fluid analysis. Aqueous humor may be investigated by PCR or GWC analysis, to determine intraocular antibody production.^{37,38,81}

Depending on the immune status, time of sampling and type of uveitis (chronic or (sub)acute), PCR or GWC analysis may be more sensitive. However, as these data may not always be available, it is advisable to perform both assays if possible.^{82,83}

CONCLUSIONS

Viral AU is typified by unilateral mild AU with fine- or medium-sized KPs, some form of iris atrophy, and sometimes high IOP, see Table 2. Cataract and glaucoma are common complications in viral AU and presence of vitritis in specific viral entities is common. There is an overlap in the clinical manifestations of AU caused by viruses and other non-viral forms of AU. Moreover, there is no specific feature that is indicative of viral AU, as many signs and symptoms may vary between specific viral causes (pain, redness, synechiae, corneal, and vitreous involvement).

Several viral AU entities may be accompanied by a prominent vitritis (eg. RV, HTLV, and HIV), which can be misleading in making of correct diagnosis. FUS is usually also classified as AU, however vitreous involvement in FUS may be severe, and associated chorioretinal scars and papillitis also have been reported. It might be more correct to classify patients according to their actual presentations as intermediate or panuveitis.

In conclusion, a viral cause of AU should be suspected in patients with unilateral AU, exhibiting small- or medium-sized KPs, some form of iris atrophy, high IOP, and early development of a cataract. Whilst medical history, serologic results and clinical features might raise a suspicion of viral etiology, the definitive diagnosis can be proven by aqueous humor analysis.

DECLARATION OF INTEREST

The authors report no conflicts of interest. The authors alone are responsible for the content and writing of the paper.

FUNDING

Justine R. Smith was financially supported by the Australian Research Council (FT130101648). Fahriye Groen-Hakan was financially supported by AbbVie, the Netherlands.

REFERENCES

1. Tsirouki T, Dastiridou A, Symeonidis C, et al. A Focus on the Epidemiology of Uveitis. *Ocul Immunol Inflamm.* 2016;1–15.
2. Pathanapitoon K, Dodds EM, Cunningham ET Jr., Rothova A. Clinical Spectrum of HLA-B27-associated Ocular Inflammation. *Ocul Immunol Inflamm.* 2016;1–8.
3. Kongyai N, Sirirungsi W, Pathanapitoon K, et al. Viral causes of unexplained anterior uveitis in Thailand. *Eye (Lond).* 2012;26:529–534.

4. Acharya NR, Tham VM, Esterberg E, et al. Incidence and prevalence of uveitis: results from the Pacific Ocular Inflammation Study. *JAMA Ophthalmol.* 2013;131:1405–1412.
5. Birnbaum AD, Tessler HH, Schultz KL, et al. Epidemiologic relationship between Fuchs heterochromic iridocyclitis and the united states rubella vaccination program. *Am J Ophthalmol.* 2007;144:424–428.
6. Herborg CP, Rao NA, Mochizuki M. members of scientific committee of first international workshop on ocular S. International criteria for the diagnosis of ocular sarcoidosis: results of the first International Workshop on Ocular Sarcoidosis (IWOS). *Ocul Immunol Inflamm.* 2009;17:160–169.
7. Dana MR, Merayo-Lloves J, Schaumberg DA, Foster CS. Prognosticators for visual outcome in sarcoid uveitis. *Ophthalmology.* 1996;103:1846–1853.
8. Rochepeau C, Jamilloux Y, Kerever S, et al. Long-term visual and systemic prognoses of 83 cases of biopsy-proven sarcoid uveitis. *Br J Ophthalmol.* 2016;1–6.
9. Smith JA, Mackensen F, Sen HN, et al. Epidemiology and course of disease in childhood uveitis. *Ophthalmology.* 2009;116(1544–51):1551 e1.
10. Haasnoot AJ, Van Tent-Hoeve M, Wulffraat NM, et al. Erythrocyte sedimentation rate as baseline predictor for the development of uveitis in children with juvenile idiopathic arthritis. *Am J Ophthalmol.* 2015;159(372–7):e1.
11. Edelsten C, Lee V, Bentley CR, Kanski JJ, Graham EM. An evaluation of baseline risk factors predicting severity in juvenile idiopathic arthritis associated uveitis and other chronic anterior uveitis in early childhood. *Br J Ophthalmol.* 2002;86:51–56.
12. Kalinina Ayuso V, Ten Cate HA, Van Der Does P, Rothova A, De Boer JH. Male gender and poor visual outcome in uveitis associated with juvenile idiopathic arthritis. *Am J Ophthalmol.* 2010;149:987–993.
13. Ayuso VK, Ten Cate HAT, Van Der Does P, Rothova A, De Boer JH. Male gender as a risk factor for complications in uveitis associated with juvenile idiopathic arthritis. *Am J Ophthalmol.* 2010;149:994–999.
14. Moradi A, Stroh IG, Reddy AK, et al. Risk of hypotony in juvenile idiopathic arthritis-associated uveitis. *Am J Ophthalmol.* 2016;169:113–124.
15. Haasnoot AJ, Vernie LA, Rothova A, et al. Impact of juvenile idiopathic arthritis associated uveitis in early adulthood. *PLoS One.* 2016;11:e0164312.
16. Mandeville JT, Levinson RD, Holland GN. The tubulointerstitial nephritis and uveitis syndrome. *Surv Ophthalmol.* 2001;46:195–208.
17. Kump LI, Cervantes-Castaneda RA, Androudi SN, Foster CS. Analysis of pediatric uveitis cases at a tertiary referral center. *Ophthalmology.* 2005;112:1287–1292.
18. Hettinga YM, Scheerlinck LM, Lilien MR, Rothova A, De Boer JH. The value of measuring urinary beta2-microglobulin and serum creatinine for detecting tubulointerstitial nephritis and uveitis syndrome in young patients with uveitis. *JAMA Ophthalmol.* 2015;133:140–145.
19. Goda C, Kotake S, Ichiishi A, Namba K, Kitaichi N, Ohno S. Clinical features in tubulointerstitial nephritis and uveitis (TINU) syndrome. *Am J Ophthalmol.* 2005;140:637–641.
20. London NJ, Garg SJ, Moorthy RS, Cunningham ET. Drug-induced uveitis. *J Ophthalmic Inflamm Infect.* 2013;3:43.
21. Shifera AS, Kopplin L, Lin P, Suhler EB. Drug-induced uveitis. *Int Ophthalmol Clin.* 2015;55:47–65.
22. Cunningham ET Jr., London NJ, Moorthy R, Garg SJ, Zierhut M. Drugs, Inflammation, and the Eye. *Ocul Immunol Inflamm.* 2016;24:125–127.
23. Beltz J, Zamir E. Brimonidine Induced Anterior Uveitis. *Ocul Immunol Inflamm.* 2016;24:128–133.
24. Tugal-Tutkun I, Onal S, Garip A, et al. Bilateral Acute Iris Transillumination. *Arch Ophthalmol-Chic.* 2011;129:1312–1319.
25. Reddy S, Cubillan LD, Hovakimyan A, Cunningham ET Jr. Inflammatory ocular hypertension syndrome (IOHS) in patients with syphilitic uveitis. *Br J Ophthalmol.* 2007;91:1610–1612.
26. Davis JL. Ocular syphilis. *Curr Opin Ophthalmol.* 2014;25:513–518.
27. Tabbara KF. Ocular tuberculosis: anterior segment. *Int Ophthalmol Clin.* 2005;45:57–69.
28. Gupta V, Gupta A, Rao NA. Intraocular tuberculosis—an update. *Surv Ophthalmol.* 2007;52:561–587.
29. Jap A, Chee SP. Emerging forms of viral uveitis in the developing world. *Int Ophthalmol Clin.* 2010;50:155–171.
30. Lin P. Infectious Uveitis. *Curr Ophthalmol Rep.* 2015;3:170–183.
31. Takase H, Kubono R, Terada Y, et al. Comparison of the ocular characteristics of anterior uveitis caused by herpes simplex virus, varicella-zoster virus, and cytomegalovirus. *Jpn J Ophthalmol.* 2014;58:473–482.
32. Nalcacioglu-Yuksekkaya P, Ozdal PC, Teke MY, Kara C, Ozturk F. Presumed herpetic anterior uveitis: a study with retrospective analysis of 79 cases. *Eur J Ophthalmol.* 2014;24:14–20.
33. Van Der Lelij A, Ooijman FM, Kijlstra A, Rothova A. Anterior uveitis with sectoral iris atrophy in the absence of keratitis: a distinct clinical entity among herpetic eye diseases. *Ophthalmology.* 2000;107:1164–1170.
34. Wensing B, Relvas LM, Caspers LE, et al. Comparison of rubella virus- and herpes virus-associated anterior uveitis clinical manifestations and visual prognosis. *Ophthalmology.* 2011;118:1905–1910.
35. Chee SP, Bacsal K, Jap A, Se-Thoe SY, Cheng CL, Tan BH. Clinical features of cytomegalovirus anterior uveitis in immunocompetent patients. *Am J Ophthalmol.* 2008;145:834–840.
36. Chee SP, Jap A. Presumed fuchs heterochromic iridocyclitis and Posner-Schlossman syndrome: comparison of cytomegalovirus-positive and negative eyes. *Am J Ophthalmol.* 2008;146(883–9):e1.
37. De Groot-Mijnes JDF, De Visser L, Rothova A, Schuller M, Van Loon AM, Weersink AJL. Rubella virus is associated with Fuchs heterochromic iridocyclitis. *Am J Ophthalmol.* 2006;141:212–214.
38. Quentin CD, Reiber H. Fuchs heterochromic cyclitis: rubella virus antibodies and genome in aqueous humor. *Am J Ophthalmol.* 2004;138:46–54.
39. De Visser L, Braakenburg A, Rothova A, De Boer JH. Rubella virus-associated uveitis: clinical manifestations and visual prognosis. *Am J Ophthalmol.* 2008;146:292–297.
40. Yoshimura K, Mochizuki M, Araki S, et al. Clinical and Immunological Features of Human T-Cell Lymphotropic Virus Type-I Uveitis. *Am J Ophthalmol.* 1993;116:156–163.
41. Merle H, Cabre P, Olindo S, Merle S, Smadja D. Ocular lesions in 200 patients infected by the human T-cell lymphotropic virus type 1 in Martinique (French West Indies). *Am J Ophthalmol.* 2002;134:190–195.
42. Pinheiro SR, Martins-Filho OA, Ribas JG, et al. Immunologic markers, uveitis, and keratoconjunctivitis sicca associated with human T-cell lymphotropic virus type 1. *Am J Ophthalmol.* 2006;142:811–815.
43. Yamaguchi K, Mochizuki M, Watanabe T, et al. Human T lymphotropic virus type 1 uveitis after Graves' disease. *Br J Ophthalmol.* 1994;78:163–166.
44. Hsu WM, Chiou SH, Chen SS, et al. The HIV RNA levels of plasma and ocular fluids in AIDS patients with ophthalmic infections. *Ophthalmologica.* 2004;218:328–332.

45. Pathanapitoon K, Riemens A, Kongyai N, et al. Intraocular and plasma HIV-1 RNA loads and HIV uveitis. *Aids*. 2011;25:81–86.
46. Kunavisarut P, Sirirungsi W, Pathanapitoon K, Rothova A. Clinical manifestations of human immunodeficiency virus-induced uveitis. *Ophthalmology*. 2012;119:1455–1459.
47. Rothova A, Schneider M, De Groot-Mijnes JD. Human immunodeficiency virus-induced uveitis: intraocular and plasma human immunodeficiency virus-1 RNA loads. *Ophthalmology*. 2008;115:2062–2064.
48. Mahendradas P, Shetty R, Malathi J, Madhavan HN. Chikungunya virus iridocyclitis in Fuchs' heterochromic iridocyclitis. *Indian J Ophthalmol*. 2010;58:545–547.
49. Lalitha P, Rathinam S, Banushree K, Maheshkumar S, Vijayakumar R, Sathe P. Ocular involvement associated with an epidemic outbreak of chikungunya virus infection. *Am J Ophthalmol*. 2007;144:552–556.
50. Babu K, Kini R, Philips M, Subbakrishna DK. Clinical profile of isolated viral anterior uveitis in a South Indian patient population. *Ocul Immunol Inflamm*. 2014;22:356–359.
51. Agrawal R, Oo HH, Balne PK, Ng L, Tong L, Leo YS. Zika Virus and Eye. *Ocul Immunol Inflamm*. 2017;1–6.
52. Furtado JM, Esposito DL, Klein TM, Teixeira-Pinto T, Da Fonseca BA. Uveitis Associated with Zika Virus Infection. *N Engl J Med*. 2016;375:394–396.
53. Miranda-Filho Dde B, Martelli CM, Ximenes RA, et al. Initial description of the presumed congenital Zika Syndrome. *Am J Public Health*. 2016;106:598–600.
54. Hereth-Hebert E, Bah MO, Etard JF, et al. Ocular complications in survivors of the ebola outbreak in Guinea. *Am J Ophthalmol*. 2017;175:114–121.
55. Varkey JB, Shantha JG, Crozier I, et al. Persistence of Ebola virus in ocular fluid during convalescence. *N Engl J Med*. 2015;372:2423–2427.
56. Tiffany A, Vetter P, Mattia J, et al. Ebola virus disease complications as experienced by survivors in sierra leone. *Clin Infect Dis*. 2016;62:1360–1366.
57. Shantha JG, Crozier I, Hayek BR, et al. Ophthalmic manifestations and causes of vision impairment in ebola virus disease survivors in monrovia, liberia. *Ophthalmology*. 2017;124:170–177.
58. Kibadi K, Mupapa K, Kuvula K, et al. Late ophthalmologic manifestations in survivors of the 1995 Ebola virus epidemic in Kikwit, democratic republic of the congo. *J Infect Dis*. 1999;179(Suppl 1):S13–4.
59. Mattia JG, Vandy MJ, Chang JC, et al. Early clinical sequelae of Ebola virus disease in Sierra Leone: a cross-sectional study. *Lancet Infect Dis*. 2016;16:331–338.
60. Chancellor JR, Padmanabhan SP, Greenough TC, et al. Uveitis and systemic inflammatory markers in convalescent phase of Ebola virus disease. *Emerg Infect Dis*. 2016;22:295–297.
61. Peponis VG, Chatziralli IP, Parikakis EA, Chaira N, Katzakis MC, Mitropoulos PG. Bilateral multifocal chorioretinitis and optic neuritis due to Epstein-Barr virus: a case report. *Case Rep Ophthalmol*. 2012;3:327–332.
62. Ostler HB, Thygeson P. The ocular manifestations of herpes zoster, varicella, infectious mononucleosis, and cytomegalovirus disease. *Surv Ophthalmol*. 1976;21:148–159.
63. Sugiyama K, Ito M, Ichimi R, et al. A case of Epstein-Barr virus infection with exophthalmos and ocular muscle swelling. *Acta Paediatr Jpn*. 1997;39:694–697.
64. Wong KW, D'Amico DJ, Hedges TR 3rd, Soong HK, Schooley RT, Kenyon KR. Ocular involvement associated with chronic Epstein-Barr virus disease. *Arch Ophthalmol*. 1987;105:788–792.
65. Boonsopon S, Maghsoudlou A, Kombo NE, Foster CS. A therapeutic trial of valganciclovir in patients with uveitis and positive Epstein-Barr virus early antigen D IgG titers. *Eur J Ophthalmol*. 2016;26:30–35.
66. Usui M, Sakai J. Three cases of EB virus-associated uveitis. *Int Ophthalmol*. 1990;14:371–376.
67. Kerr JR, Boyd N. Autoantibodies following parvovirus B19 infection. *J Infect*. 1996;32:41–47.
68. De Groot-Mijnes JD, Dekkers J, De Visser L, Rothova A, Van Loon AM, De Boer JH. Antibody production against B19 virus in ocular fluid of JIA-associated uveitis patients. *Ophthalmology*. 2015;122(1270–1272):e1.
69. Corridan PG, Laws DE, Morrell AJ, Murray PI. Tonic pupils and human parvovirus (B19) infection. *J Clin Neuroophthalmol*. 1991;11:109–110.
70. Heinz C, Plentz A, Bauer D, Heiligenhaus A, Modrow S. Prevalence of parvovirus B19-specific antibodies and of viral DNA in patients with endogenous uveitis. *Graefes Arch Clin Exp Ophthalmol*. 2005;243:999–1004.
71. Maini R, Edelsten C. Uveitis associated with parvovirus infection. *Br J Ophthalmol*. 1999;83:1403–1404.
72. Suzuki J, Goto H, Usui M, Sakai J. Serous retinal detachment in a patient with aplastic anemia associated with parvovirus B19 infection. *Graefes Arch Clin Exp Ophthalmol*. 2007;245:324–326.
73. Jones NP. Fuchs' heterochromic uveitis: an update. *Surv Ophthalmol*. 1993;37:253–272.
74. Mocan MC, Kadayifcilar S, Irkec M. In vivo confocal microscopic evaluation of keratic precipitates and endothelial morphology in Fuchs' uveitis syndrome. *Eye (Lond)*. 2012;26:119–125.
75. Liu Q, Jia Y, Zhang S, et al. Iris autofluorescence in Fuchs' heterochromic uveitis. *Br J Ophthalmol*. 2016;100:1397–1402.
76. Megaw R, Agarwal PK. Posner-Schlossman syndrome. *Surv Ophthalmol*. 2017;62:277–285.
77. Jap A, Sivakumar M, Chee SP. Is Posner Schlossman syndrome benign? *Ophthalmology*. 2001;108:913–918.
78. Urban B, Bakunowicz-Lazarczyk A, Michalczyk M. Immune recovery uveitis: pathogenesis, clinical symptoms, and treatment. *Mediators Inflamm*. 2014;2014:971417.
79. Yeo TH, Yeo TK, Wong EP, Agrawal R, Teoh SC. Immune recovery uveitis in HIV patients with cytomegalovirus retinitis in the era of HAART therapy—a 5-year study from Singapore. *J Ophthalmic Inflamm Infect*. 2016;6:41.
80. Agarwal A, Kumari N, Trehan A, et al. Outcome of cytomegalovirus retinitis in immunocompromised patients without Human immunodeficiency virus treated with intravitreal ganciclovir injection. *Graefes Arch Clin Exp Ophthalmol*. 2014;252:1393–1401.
81. De Schryver I, Rozenberg F, Cassoux N, et al. Diagnosis and treatment of cytomegalovirus iridocyclitis without retinal necrosis. *Brit J Ophthalmol*. 2006;90:852–855.
82. De Groot-Mijnes JD, Rothova A, Van Loon AM, et al. Polymerase chain reaction and Goldmann-Witmer coefficient analysis are complimentary for the diagnosis of infectious uveitis. *Am J Ophthalmol*. 2006;141:313–318.
83. Westeneng AC, Rothova A, De Boer JH, De Groot-Mijnes JD. Infectious uveitis in immunocompromised patients and the diagnostic value of polymerase chain reaction and Goldmann-Witmer coefficient in aqueous analysis. *Am J Ophthalmol*. 2007;144:781–785.