

EUR Research Information Portal

Incidentally detected asplenia in a healthy 64-year-old female live kidney donor

Published in:

Oxford Medical Case Reports

Publication status and date:

Published: 01/01/2017

DOI (link to publisher):

[10.1093/omcr/omx012](https://doi.org/10.1093/omcr/omx012)

Document Version

Publisher's PDF, also known as Version of record

Citation for the published version (APA):

Wolff, LD., Nijboer, MN., van de Wetering, J., & Dor, F. (2017). Incidentally detected asplenia in a healthy 64-year-old female live kidney donor. *Oxford Medical Case Reports*, (4), 47-49. <https://doi.org/10.1093/omcr/omx012>

[Link to publication on the EUR Research Information Portal](#)

Terms and Conditions of Use

Except as permitted by the applicable copyright law, you may not reproduce or make this material available to any third party without the prior written permission from the copyright holder(s). Copyright law allows the following uses of this material without prior permission:

- you may download, save and print a copy of this material for your personal use only;
- you may share the EUR portal link to this material.

In case the material is published with an open access license (e.g. a Creative Commons (CC) license), other uses may be allowed. Please check the terms and conditions of the specific license.

Take-down policy

If you believe that this material infringes your copyright and/or any other intellectual property rights, you may request its removal by contacting us at the following email address: openaccess.library@eur.nl. Please provide us with all the relevant information, including the reasons why you believe any of your rights have been infringed. In case of a legitimate complaint, we will make the material inaccessible and/or remove it from the website.

CASE REPORT

Incidentally detected asplenia in a healthy 64-year-old female live kidney donor

Leoniek D. Wolff^{1,*}, Mijntje N. Nijboer², Jacqueline vd Wetering³
and Frank J.M.F. Dor¹

¹Department of Surgery, Division of HPB and Transplantation Surgery, Erasmus MC, University Medical Center, Rotterdam, The Netherlands, ²Department of Surgery, University Medical Center Groningen, Groningen, The Netherlands, and ³Department of Internal Medicine, Division of Nephrology, Erasmus MC, University Medical Center, Rotterdam, The Netherlands

*Correspondence address. Department of Surgery, Division of HPB and Transplantation Surgery, Erasmus MC, University Medical Center, Rotterdam, The Netherlands. Tel: +31-107031810; Fax: +31-107032396; E-mail: l.wolff@erasmusmc.nl

Abstract

Heterotaxia syndromes are rare birth defects which can result in developmental malformations. A 64-year-old woman presented to the hospital for preoperative screening for kidney donation; during which she was found to have no gallbladder and no spleen, without any signs of surgical removal. This could be a new description of a heterotaxia syndrome.

INTRODUCTION

Heterotaxia syndromes, also known as isomerism syndromes, are rare birth defects which are the result of a failure to establish normal left and right asymmetry during the development in intrauterine life [1, 2]. There are various outcomes of this congenital construction disorder, which include situs ambiguous, situs inversus, polysplenia syndrome and Ivemark syndrome [1, 3–6].

These developmental disorders can result in many malformations, such as pulmonary isomerism, four-lobed lungs, cardiac malformations, transposition of the great cardiac vessels, septal defects, midline liver, malrotation of the bowel, asplenia, renal agenesis and also an untraceable gallbladder. In short, all internal organs can be affected [3, 4]. In most of the described cases until now, anomalies in multiple organs are found. Anomalies in only two organs are a much more uncommon scenario.

This case report describes a case of a 64-year-old woman who presented in our centre for preoperative screening for kidney donation to her son. During the screening, she was found to have no spleen and no gallbladder on abdominal imaging. First, she was thought to have had a splenectomy and cholecystectomy, but her medical history was negative, she was *compos mentis*, and no operative scars compatible with cholecystectomy or splenectomy could be found. Therefore, this woman is thought to have both congenital asplenia and congenital agenesis of the gallbladder without any history of severe infections as can be observed in asplenia.

CASE REPORT

A 64-year-old Dominican woman presented to the Nephrology department because she wished to donate one of her kidneys to her son, who suffered from end stage hypertensive

Received: November 19, 2016. Revised: January 25, 2017. Accepted: February 28, 2017

© The Author 2017. Published by Oxford University Press.

This is an Open Access article distributed under the terms of the Creative Commons Attribution Non-Commercial License (<http://creativecommons.org/licenses/by-nc/4.0/>), which permits non-commercial re-use, distribution, and reproduction in any medium, provided the original work is properly cited. For commercial re-use, please contact journals.permissions@oup.com

nephropathy. Her medical history included a laparoscopic sterilization in 1981, mammary cyst removal in 1988, a vaginal hysterectomy in 1999, a tonsillectomy in 2004 and a right-sided tympanoplasty in 2005. She had not experienced severe illnesses in the past and therefore had not received additional vaccinations. She used Tramadol and Paracetamol two to three times a week because of incidental headaches. Her family history included cardiovascular disease and diabetes mellitus.

Physical examination showed a generally healthy woman. Her body mass index was 31 and she was normotensive. Head and neck examination revealed no abnormalities. Heart and lung examination were normal. Abdominal examination revealed scars of the laparoscopic sterilization. Liver and spleen could not be palpated.

She underwent a complete workup for kidney donation. Similar to her son, she was blood group O positive. Human leucocyte antigens mismatch was 1-1-1, and the crossmatch test with her son was negative. Blood tests revealed a hypothyroidism, as well as slightly elevated HbA1c-levels. The oral glucose tolerance test was normal and her hypothyroidism was medically corrected. Urinalysis showed no abnormalities and urine culture was negative. Virology reports showed no contraindication for kidney donation. A cardiac ultrasound and exercise stress test were normal.

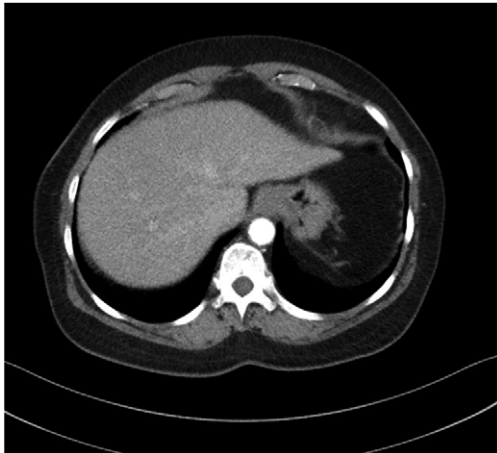

Figure 1: CT scan: no spleen can be detected in the left upper quadrant of the abdomen.

Finally, she had a plain chest radiography and a computed tomography scan of the abdomen. The chest X-ray showed no abnormalities. The computed tomography (CT) scan revealed no abnormalities of the kidneys. However, no gallbladder or spleen could be detected (Fig. 1) and the report mentioned a 'post-cholecystectomy and post-splenectomy situation'. After the initial screening, she was referred to the Transplant Surgery outpatient clinic for surgical screening for live kidney donation. The discrepancy between her medical history and physical examination on one hand and the CT scan report on the other hand was noticed, but was not felt to be a contraindication for kidney donation. After multidisciplinary team discussion, she was approved as a live kidney donor. The right-sided laparoscopic donor nephrectomy was scheduled with Cefazoline prophylaxis.

During the donor nephrectomy, we explored the abdomen in order to find signs of a gallbladder or a spleen, but both organs remained untraceable (Fig. 2). Also, no accessory spleen was seen. The donor nephrectomy was successful, as was the transplant procedure in her son, and postoperative recovery was uneventful.

To check whether the patient had a real asplenia, the presence of Howell-Jolly bodies in circulating erythrocytes was investigated. Howell-Jolly bodies are nuclear remnants of red blood cells which are removed from the blood while passing the spleen. In asplenia, Howell-Jolly bodies are visible on a standard hematoxylin- and eosin-stained blood smear as purple (basophilic) spots on pink (eosinophilic) erythrocytes. The result of her test was positive, indicating a lack of splenic tissue in her body.

As no splenic tissue had been detected, and she had not received any vaccinations against pneumococci, Haemophilus Influenza-B and meningococci as she was not aware of her asplenia, she was advised to get these vaccinations and receive a yearly vaccination against the common flu.

DISCUSSION

In conclusion, in our live kidney donor, an absent gallbladder and asplenia was detected incidentally. The asplenia was confirmed with the presence of Howell-Jolly bodies. Although she had never suffered from severe infections with polysaccharide encapsulated bacteria, we felt that it would be wise to counsel her on vaccination and antibiotic prophylaxis, following the existing Dutch guidelines for post-splenectomy patients [7].

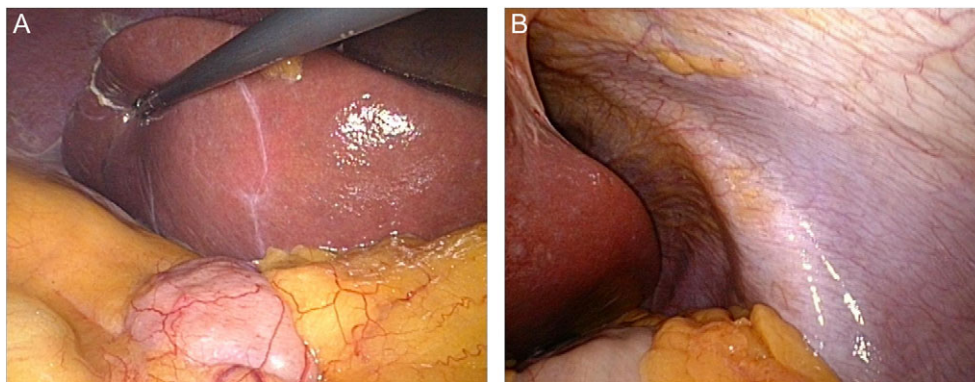


Figure 2: (A) View of the right upper quadrant of the abdomen during laparoscopic donor nephrectomy. Normally, the gallbladder would be found around the vertical line on the liver capsule. (B) View of the left upper quadrant of the abdomen. Part of segment 3 of the liver and part of the stomach can be seen. No spleen could be detected.

Heterotaxia syndromes have expressed themselves in various ways, but to this day no case has been described with just an absent gallbladder and asplenia. This could be a new presentation of a heterotaxia syndrome, as there are no signs of other underlying conditions.

CONFLICT OF INTEREST STATEMENT

None declared.

ETHICAL APPROVAL

Not required.

CONSENT

Yes.

GUARANTOR

Dr W.N. Nijboer.

REFERENCES

1. Zhu L, Belmont JW, Ware SM. Genetics of human heterotaxias. *Eur J Hum Genet* 2005;**14**:17–25.
2. Malde S. Gallbladder agenesis diagnosed intra-operatively: a case report. *J Med Case Rep* 2010;**4**:285.
3. Lowenthal A, Tacy T, Punn R. Anatomy, Clinical Manifestations and Diagnosis of Heterotaxy (isomerism of the atrial appendages). UpToDate [homepage on the Internet]. 2015 [cited 2015 May 4]. Available from: <http://http://www.uptodate.com/contents/anatomy-clinical-manifestations-and-diagnosis-of-heterotaxy-isomerism-of-the-atrial-appendages>
4. Stevenson RE, Hall JG. *Human Malformations and Related Anomalies*, 2nd ed. Oxford: Oxford University Press, 2005.
5. Brueckner M. Heterotaxia, congenital heart disease, and primary ciliary dyskinesia. *Circulation* 2007;**115**:2793–5.
6. Terslev E. A case of agenesis of the spleen, congenital heart disease and complete situs inversus. *Acta Paediatr* 1958;**47**:297–301.
7. Lammers AJ, van der Maas N, Peters EJ, Meerveld-Eggink A, Sanders EAM, Kroon FP. Voorkomen van ernstige infecties bij patiënten met hypo- of asplenie. *Ned Tijdschr Geneesk* 2012;**156**:A4857.