

Lymphoedema in patients with lentigo maligna treated with imiquimod: a long-term adverse effect

DOI: 10.1111/bjd.16267

DEAR EDITOR, Lentigo maligna (LM) is a potential precursor lesion of lentigo maligna melanoma (LMM). It is treated to prevent progression to LMM. A recent epidemiological study reports a progression rate of 2.0–2.6% over the course of 25 years.¹ The gold standard treatment is surgical excision with a 5-mm margin.² Topical application of imiquimod cream is an off-label alternative.^{2,3} Complete clinical response rates for LM treated with imiquimod vary from 37.1% to 100%.^{4–6} We report three patients with LM who developed lymphoedema following application of topical imiquimod.

Three consecutive patients with LM were treated according to our protocol. Patients were instructed to apply imiquimod once daily to the lesion with a 1- to 2-cm margin, for 12 weeks. The goal was to achieve at least 10 weeks of inflammation. Depending on the inflammatory reaction, the treatment schedule was adapted. If it was too intense, patients were instructed to apply imiquimod three times per week, or if the inflammation was insufficient, patients were instructed to apply imiquimod 2–3 times daily.⁷

The first patient was a 66-year-old woman with a 9 × 10 mm pigmented brown macule on the left cheek. The diagnosis of LM was confirmed by a punch biopsy. After 12 weeks of treatment with imiquimod 5%, no residual pigmentation was visible macroscopically or by dermatoscopy. Within days after starting treatment, the patient developed erythema, soreness and oedema at the site of application. The erythema partially subsided, the soreness quickly disappeared, but a nonpitting swelling persisted. A punch biopsy obtained 2 years post-treatment demonstrated fibrosis, with increased numbers of fibroblasts and a mild lymphohistiocytic infiltrate that had replaced the normal subcutaneous tissue (Fig. 1a, b). D2-40 immunostaining showed several compressed lymphatic vessels within this fibrotic tissue. Four years post-treatment, the lymphoedema was still present.

The second patient was a 68-year-old woman with a 14 × 14-mm irregularly pigmented macule on her right cheek. LM was confirmed histopathologically. She applied imiquimod once daily during the first 4 weeks of treatment. As a result of intense inflammation she was instructed to apply the imiquimod three times weekly for the remaining 8 weeks, for a total of 12 weeks. One month post-treatment a biopsy showed postinflammatory hyperpigmentation; no LM was found. In the dermis oedema was observed. Histologically it was unclear if the oedema was lymphoedema or residual oedema because

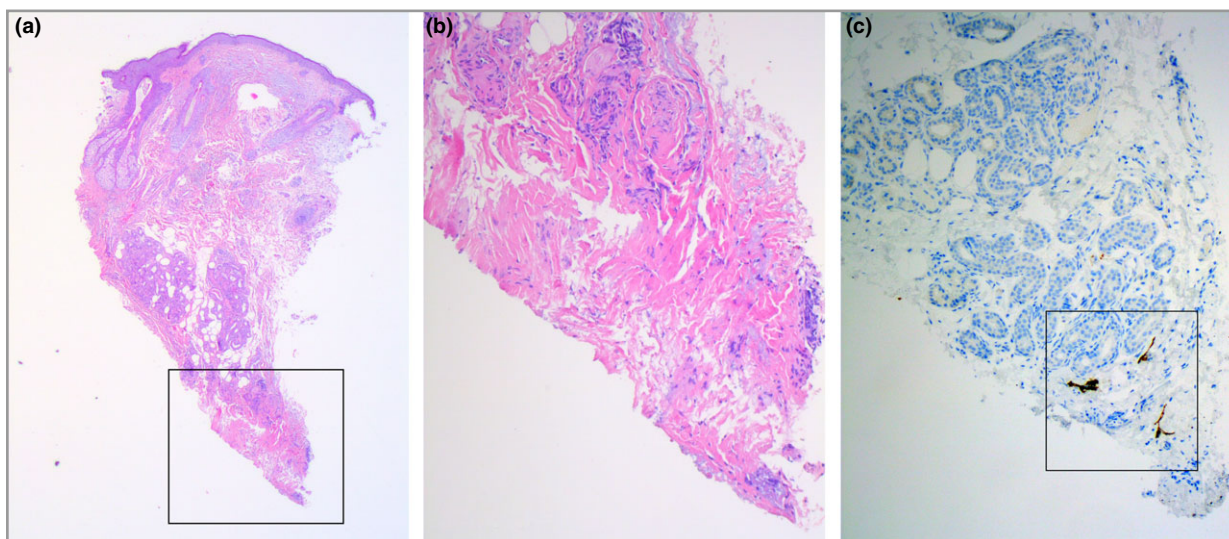


Fig 1. (a, b) Biopsy obtained from the left cheek, 2 years after treatment with imiquimod, demonstrating fibrosis and chronic inflammation. Haematoxylin and eosin stain, original magnification × 25 (a), × 100 (b). (c) D2-40 immunostaining of compressed lymphatic vessels in fibrotic tissue (original magnification × 100).

of inflammation. The oedema persisted for 3 years, after which it disappeared.

The third patient was a 69-year-old woman, who was referred following excision of a LMM on her right cheek. Histological examination of the excised lesion showed radically excised LMM with a Breslow thickness of 0.6 mm. Several years later, pigmentation measuring 15 × 15 mm appeared around the scar. A biopsy showed LM, without evidence of LMM. The patient declined surgical treatment because she found the potential scarring unacceptable. She was treated with off-label imiquimod. During treatment, the patient developed an inflammatory reaction with erythema, swelling, soreness and crusting. After treatment, no residual pigmentation was present. The erythema and soreness disappeared but lymphoedema persisted. The lymphoedema disappeared gradually after a year.

Topical imiquimod is an off-label option for the treatment of patients with LM who do not qualify for or do not opt for surgical treatment. Imiquimod is applied for a prolonged period of time to achieve a sufficient inflammatory response.⁵ We hypothesize that lymphoedema may complicate treatment of patients with LM using topical imiquimod. This adverse effect may be caused by the intense treatment regimen used in our patients, resulting in severe inflammation and significant dermal fibrosis, impairing normal tissue drainage by afferent lymphatic vessels.

In the two patients who had biopsies after imiquimod treatment (2 years post-treatment for one and 1 month after for the other), fibrosis was clearly present in the reticular dermis histologically. We hypothesize that in our patients, similar to the sequence of events during cutaneous wound healing, a late phase of remodelling (maturation) may have followed previous phases of inflammation and proliferation in response to imiquimod. The remodelling phase involves degradation of excess collagen and organization of fibrotic connective tissue, which may take several years.⁸ This may explain why lymphoedema persisted and only resolved in two of the three patients. Alternatively, the lymphoedema may have been related to other unknown or unrecognized factors.

In conclusion, topical imiquimod is an off-label alternative treatment option for the treatment of LM, for patients who

are ineligible or do not opt for surgical treatment. When prescribing topical imiquimod for a lesion located on the cheek for a prolonged period of time, patients should be informed about the risk of secondary lymphoedema.

¹Vrije Universiteit Medical Center,
Amsterdam, the Netherlands

²University Hospital of Marburg, Marburg,
Germany

³Erasmus Universiteit Medical Center,
Rotterdam, the Netherlands
E-mail: d.tio@vumc.nl

D. TIO¹ 

G. KIRTSCHIG²

R. HOEKZEMA¹

C. VAN MONTFRANS³

References

- 1 Greveling K, Wakkee M, Nijsten T et al. Epidemiology of lentigo maligna and lentigo maligna melanoma in the Netherlands, 1989–2013. *J Invest Dermatol* 2016; **136**:1955–60.
- 2 Garbe C, Peris K, Hauschild A et al. Diagnosis and treatment of melanoma. European consensus-based interdisciplinary guideline – Update 2016. *Eur J Cancer* 2016; **63**:201–17.
- 3 Ahmed I, Berth-Jones J. Imiquimod: a novel treatment for lentigo maligna. *Br J Dermatol* 2000; **143**:843–5.
- 4 Kai AC, Richards T, Coleman A et al. Five-year recurrence rate of lentigo maligna after treatment with imiquimod. *Br J Dermatol* 2016; **174**:165–8.
- 5 Tio D, van der Woude J, Prinsen CA et al. A systematic review on the role of imiquimod in lentigo maligna and lentigo maligna melanoma: need for standardization of treatment schedule and outcome measures. *J Eur Acad Dermatol Venereol* 2017; **31**:616–24.
- 6 Marsden JR, Fox R, Boota NM et al. Effect of topical imiquimod as primary treatment for lentigo maligna - the LIMIT-1 study. *Br J Dermatol* 2017; **176**:1148–54.
- 7 Kirtschig G, van Meurs T, van Doorn R. Twelve-week treatment of lentigo maligna with imiquimod results in a high and sustained clearance rate. *Acta Derm Venereol* 2015; **95**:83–5.
- 8 Reinke JM, Sorg H. Wound repair and regeneration. *Eur Surg Res* 2012; **49**:35–43.

Funding sources: none.

Conflicts of interest: none to declare.