

Triphalangeal thumb: clinical features and treatment

Steven E. R. Hovius^{1,2,3}, Jacob W. P. Potuijt¹ and Christianne A. van Nieuwenhoven¹

Journal of Hand Surgery

(European Volume)

2019, Vol. 44(1) 69–79

© The Author(s) 2018



Article reuse guidelines:

sagepub.com/journals-permissions

DOI: 10.1177/1753193418797922

journals.sagepub.com/home/jhs

Abstract

Triphalangeal thumb is a rare congenital anomaly in which the thumb has three phalanges. Clinical presentation of triphalangeal thumb can vary considerably and can be present in both hands or unilateral. The thumb can be long with a finger-like appearance. The presence of clinodactyly depends on the shape of the extra phalanx varying from wedge-shaped to rectangular. Various joints, ligaments, muscles, and tendons of the first ray can be hypoplastic or absent, with varying degrees of stiffness or instability. The aim of surgical treatment is to reconstruct or correct the anatomic anomalies to obtain greater function and a more acceptable appearance. In our series, operations varied from removal of the delta phalanx with ligament reconstruction to multiple osteotomies and rebalancing of soft tissues. Results in these often complex cases can be rewarding if the surgeon has sufficient knowledge of the underlying anatomic differences. This review summarizes our current concepts of presentation and management of the triphalangeal thumb.

Keywords

Congenital hand, triphalangeal thumb, reconstruction

Date received: 16th June 2018; revised: 7th August 2018; accepted: 7th August 2018

Introduction

Triphalangeal thumb (TPT) is a congenital hand anomaly in which the thumb has an additional phalanx, supposedly first described by Columbo in 1559 (Columbo-Cremonensis, 1559). Although TPT is a rare anomaly, with an estimated prevalence of 1 in 25,000 newborns, variable phenotypic features are common (Hovius et al., 2004; Lapidus et al., 1943). The additional phalanx can be present in different shapes and sizes. An additional preaxial polydactyly can be present together with syndactyly and ulnar polydactyly of the hands. TPT can be present in an isolated form; as part of a syndrome and may be inherited in a dominant manner. In sporadic cases the deformity is unilateral and the thumb will have a degree of opposition. When TPT is present in a syndrome, for example Holt–Oram Syndrome, the thumb is usually hypoplastic. Two-thirds of patients with TPT in our series have bilateral deformities and a family history of thumb abnormalities. Their thumbs are mostly non-opposable. The anomaly in this specific group is caused by an inherited dominant trait, of which the locus is mostly on chromosome 7q36 (Heutink et al., 1994; Zguricas et al., 1994).

Based on our results, the prevalence of TPT in the Netherlands is higher than stated in the literature (1:16,000).

Classification of TPT may be according to the three different shapes of the extra phalanx (wedge, trapezoidal, or rectangular) as described by Wood or by the different encountered shapes from small to large as reported by Buck-Gramcko who framed it as a ‘Teratologische reihe’ (teratologic row) (Buck-Gramcko, 2002; Wood, 1976). When radial polydactyly is present it may be classified according to Wassel

¹Department of Plastic, Reconstructive and Hand Surgery, Erasmus University Medical Center, Rotterdam, The Netherlands

²Department of Plastic and Reconstructive Surgery, Radboud University Medical Centre, Nijmegen, The Netherlands

³Xpert Clinic, Hand and Wrist surgery, Rotterdam, The Netherlands

Corresponding Author:

Steven E. R. Hovius, Department of Plastic, Reconstructive and Hand Surgery, Erasmus University Medical Center, Wytemaweg 50, 3015 GE, Rotterdam, The Netherlands.

Email: s.e.r.hovius@erasmusmc.nl

(1969) or the updated version by Zuidam et al. (2008b).

The aim of this article is to present an overview of the clinical presentation of TPT along with our suggested surgical treatments.

Clinical presentation

Thumb length varies depending on the size of the extra middle phalanx of the thumb. Mostly there is a degree of radial or ulnar clinodactyly due to the wedge or trapezoidal shape.

The thumb appearance can be thumb-like to more finger-like. The more the thumb looks like a finger the more the TPT is in the same plane of the hand instead of in palmar abduction. Flexor tendons can be present as flexor digitorum superficialis and profundus or as a single flexor pollicis longus. The first web can be normal to aberrant and the thenar muscles hypoplastic, malformed or absent. The degree of opposability of the thumb relates to the thenar muscle deficiency.

Depending on the length of the thumb and hypoplastic thenar musculature the TPT is hypermobile at the metacarpophalangeal (MP) joint. The carpometacarpal (CMC) joint can be hypoplastic, malformed, or even absent. In most cases the CMC joint is less mobile and less well-developed, particularly when the thumb is finger-like, when it is similar to the second CMC joint.

Depending on the presence of an extra ray, the trapezium and scaphoid are malformed or hypoplastic. If an extra ray is present, which is very common in bilateral, inherited cases, it may be as a full ray or with proximally or distally developed parts. Sometimes there is duplication of a malformed trapezium. With proximal radial polydactyly, the ulnar thumb is mostly better developed. Quite often we have encountered thumb triplication. All three are usually underdeveloped and often syndactylous. In radial polydactyly at the MP joint level, often so in syndromic presentations, the thumbs are mostly hypoplastic and often the middle phalanx (the triphalangeal part) is small.

Co-existence of ulnar syndactyly and ulnar polydactyly is common in the inherited, bilaterally affected patients. In syndromes, cleft hand and longitudinal radial deficiency can occur also. Congenital differences of the lower extremities, such as polydactyly or syndactyly, can be encountered. Details of the endless possibilities of other malformations is beyond the scope of this article. Interestingly, we have observed an increase in severity over succeeding generations in the patient group with a dominant inheritance trait and bilateral affected hands (Baas et al., 2017).

The functional problem that arises in many patients is deficient opposition resulting in difficulty with activities like writing, picking up smaller objects, etc. When radial polydactyly is also present, the function of the best thumb of the two or three is blocked by the presence of the other(s), especially if syndactyly between the thumbs is present.

However, the findings in 12 adults (23 hands) with untreated TPT, or with only resection of a polydactylous radial hypoplastic thumb, leaving the TPT thumb intact, are interesting. Patients functioned well although five thumbs had instability at the MP joint level. Palmar abduction strength, opposition strength, and flexion strength at the MP joint level were, respectively, 36%, 38%, and 39% of the strength of the average of the normal population. Patients scored lower for the domain of social functioning in the SF-36. Patients scored their function on average 7.7 using the visual analogue scores (VAS 0–10). On appearance however, it was 2.2 (Zuidam et al., 2010).

Therefore, parents mostly seek correction of the deformity for their children because of the appearance of the TPT. In the above study, the affected child had often suffered from intensive teasing at school. They and their parents wanted surgery before going to school. Requests to operate on children because of severe functional deficits were rare.

Case series

We have treated 131 patients with TPT (213 affected hands) from 1982–2016, with 148 hands operated in 225 procedures (Table 1). The non-operated patients were either not fit for operation; had a small anomaly; an operation was declined; or were parents of children who asked advice but did not proceed to operation. In this group, a high number of dominant-trait, hereditary TPTs with or without polydactyly was present, accounting for 66% of our total group.

Surgical considerations

It is important to do a thorough examination and record the different aspects of the anomalies in detail as treatment is directed as much as possible to the anatomical deficits encountered. In the treatment scheme appearance should be included.

Timing

For wedge-shaped phalanges with clear clinodactyly and in radial polydactylies, the authors would advise operation at the age of one year, to diminish the risk

Table 1. Surgical procedures performed in our case series (1982–2016).

225 procedures in 148 hands	
Removal of delta phalanx	41
DIP reduction and desis	65
PIP reduction and desis	4
Reduction-rotation osteotomy of MC	50
Pollicization	13
Opposition plasty	21
Sesamoidesis	25
Epiphysiodesis	6

DIP: distal interphalangeal; PIP: proximal interphalangeal; MC: metacarpal.

of general anesthesia. In the five-fingered hand or longer TPTs with only slight distal deviation there is no need for an early operation. Our goal was mostly to be finished with both hands before the children go to school. In the Netherlands, the entrance form starts when children are 4 years old.

Our opinion is in contrast to Bunnell and Campbell, advising that TPT patients did not have to be operated (Bunnell, 1944; Campbell, 1949).

Extra phalanx and adjacent joint

Authors who do operate have advocated the removal of the extra phalanx to reduce length and correct deviation, although the risk of an angulated joint has been reported after excision of the middle phalanx of the thumb (Cotta and Jager, 1965; Milch, 1951; Miura, 1976; Wood, 1976). Resection of the smaller extra phalanx and ligament reconstruction, as described by Buck-Gramcko, gave adequate results (Buck-Gramcko, 2002). For TPT with a trapezoidal or rectangular middle phalanx, several types of osteotomies are described, varying from excision of the proximal interphalangeal (PIP) joint to resection of the distal joint and part of the distal phalanx, followed by arthrodesis (Flatt, 1977; Peimer, 1985) (Figure 1).

Wedge-shaped extra phalanx

We have used two methods for the extra *wedge-shaped* phalanx. Generally, we resected the extra phalanx in small children up to about 3 years. The skin surplus was excised on the concave side and a Z-plasty was performed at the contracted side. The collateral ligament was reconstructed by releasing it in a V to Y fashion on the contracted, deviated side and shortening it on the non-contracted side. If the deviation is only slight, a release on the contracted

side is enough. We described this procedure as 'delta phalanx excision and ligament reconstruction' (DEL) (Figure 2).

In older children (>3 years old) the distal interphalangeal (DIP) joint is more asymmetric. We mostly performed an excision of the DIP joint and a reduction osteotomy at the distal part of the middle phalanx, followed by arthrodesis, which we called 'distal interphalangeal reduction arthrodesis' (DIPRAD). The reduction at the DIP joint is about 1 cm. The decision to perform DEL or DIPRAD procedures was not only related to the age of the patient, but also to the size of the extra phalanx. If the size was larger the decision to perform a DIPRAD was made easier.

In our series, we investigated 33 hands with a follow-up of an average of 7 years. Eighteen hands had a delta shaped extra phalanx and 15 had a trapezoidal extra phalanx. In 17, a DEL procedure was performed and in 16, a DIPRAD procedure. In the 17 thumbs with a DEL procedure, patients did not encounter any pain at follow-up, nor any joint instability at the DIP joint. Fourteen of 17 did not have any residual deviation. Two thumbs had nail deformities and in three thumbs deviation had a mean of 21° (range 15–25). Flexion at the interphalangeal joint was a mean of 35° (range 0–85). In the 15 thumbs with a DIPRAD procedure, no joint instability was encountered, no nail deformities and 11 out of 16 did not have any residual deviation. Pain was reported in two and in five thumbs mean residual deviation was 18° (range 5–25). Flexion at the residual interphalangeal joint was 46° (0–90) (Zuidam et al., 2016).

First metacarpal

The normal first metacarpal has a growth plate at the proximal end of the metacarpal. In patients with TPT, the first metacarpal can have a proximal, a distal, or proximal and distal growth plates, the proximal epiphysis resembling that of a thumb and the distal epiphysis that of a finger.

We were interested to determine whether the length of the first metacarpal in TPT was the same as in the normal hand. In 37 patients with 59 affected hands, we compared the length of the first metacarpal related to that of the second metacarpal. To prevent selection bias in bilateral symmetrical cases, ultimately 42 hands were included. A wedge-shaped delta phalanx was present in 52%, trapezoidal in 17%, and a full extra phalanx (five fingered hand) in 31%, using Wood's classification; in 52% the growth plate was positioned distally, in 33% proximally and in 14% at both ends (Wood, 1976; Zuidam et al., 2006). The

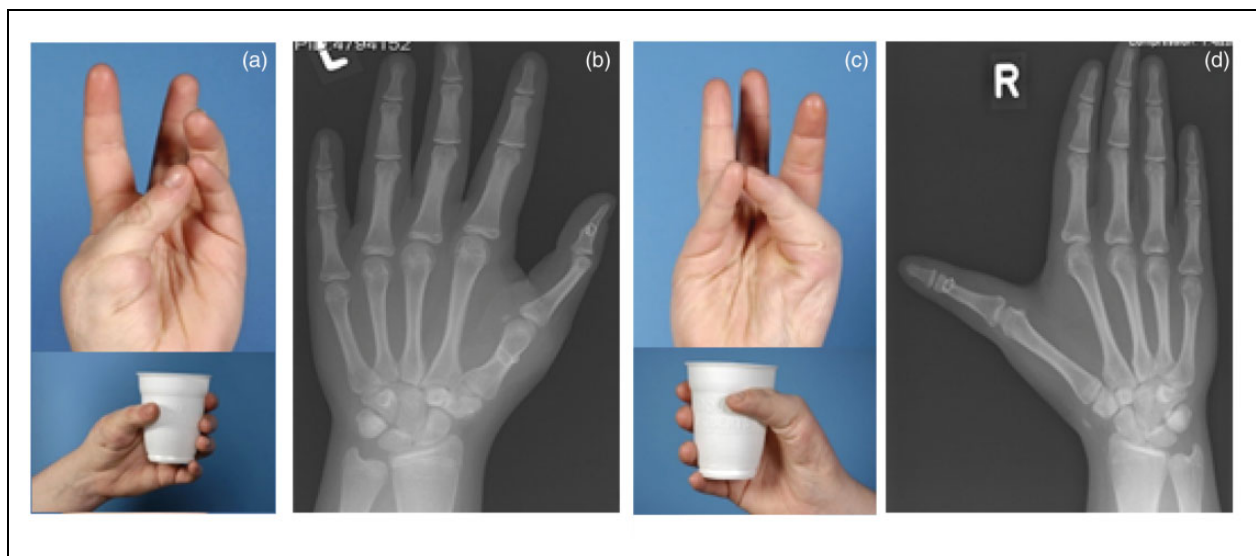


Figure 1. Postoperative images of a patient with TPT and radial polydactyly. (a) and (b) Postoperative results after DIP joint arthrodesis with metacarpal shortening. (c) and (d) Postoperative results after PIP joint arthrodesis. Note the difference in appearance and posture. PIP joint arthrodesis was subsequently abandoned although it was advised in literature.

TPT: triphalangeal thumb; PIP: proximal interphalangeal; DIP: distal interphalangeal.

ratio of the length of the second metacarpal divided by the length of the first metacarpal was compared with the same ratio in a normal population (Garn et al., 1972; Gefferth, 1972). This study resulted in a number of observations. First, all first metacarpals in patients with TPT were longer than in the normal population. Second, in patients with a proximal growth plate, the length approximated that in the normal population. Third, distal growth plates occurred more often in TPT patients with a full extra phalanx, but were also present in the other two groups. Fourth, during growth the first metacarpal became longer than normal in the group of patients with a trapezoidal or full extra phalanx. The pattern of growth followed the normal rate of growth within the reference group. This implies that the length of the triphalangeal thumb is a combination of both increased growth of the metacarpal and the length of the extra phalanx (Zuidam et al., 2006). The consequences of these observations were as follows: first, if the thumb was not too long, resection of the wedge shaped extra phalanx (DEL) or reduction arthrodesis at DIP level (DIPRAD) was performed, with an epiphysiodesis at a later stage. Epiphysiodesis was introduced later in our series, so not many have been performed; second, if the thumb was long in the case of a trapezoidal or full extra phalanx, we also performed a shortening at a metacarpal level (see below).

Trapezoidal or rectangular extra phalanx and first metacarpal

For a trapezoidal or full extra phalanx, a DIPRAD is performed. In these cases, especially in the long thumbs, this was always combined with a shortening osteotomy, with rotation and abduction at the metacarpal level. The rotation and abduction was to gain more opposition. We named this technique the 'rotation shortening osteotomy with abduction at metacarpal level' (ROAMC). Intrinsic shortening was not always performed in this last technique. In the very young child with a thick periosteal layer, an alternative osteotomy is to leave the periosteal layer as intact as possible, making a longitudinal cut and fracturing the metacarpal with rongeurs, after which the metacarpal can be placed in rotation and abduction (Ezaki and Oishi, 2012). Osteotomies were mostly fixed with K-wires and thin cerclage wires or sutures.

Although the aim is to have the tip of the thumb no longer than the level of the index PIP joint when the hand is flat on the table, the length of the thumb can be unpredictable because of the aberrant growth of the first metacarpal. In our series, we encountered some long thumbs despite shortening at both the DIP joint and metacarpal.

Hyperextension at the MP joint became more pronounced following metacarpal shortening, mostly without a functional problem. However, in 25 hands,

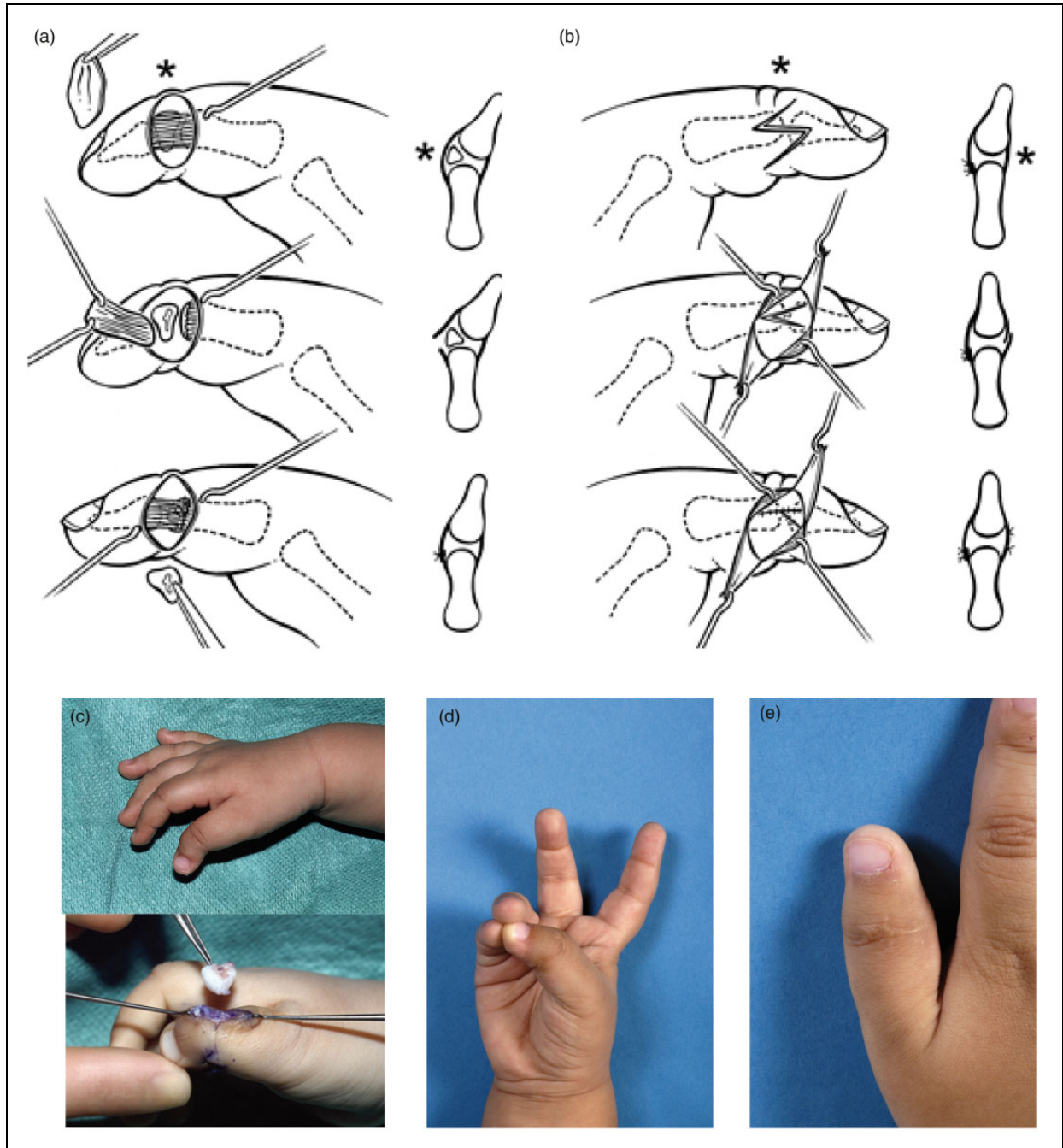


Figure 2. Preferred technique on the removal of the additional phalanx with ligament reconstruction. (a) The skin is removed in elliptical fashion on the concave side, the ligament turned over and the delta phalanx removed. (b) Subsequently a Z-plasty is performed on the contracted side with a release of the collateral ligament in a V to Y fashion. Finally, the collateral ligament is adjusted on the concave side and the skin closed. (c)–(e) Peri- and postoperative images following this procedure.

Reprinted with permission from: Hovius SER, Zuidam JM, de Wit T, 2004 and Neligan and Chang, 2018.

we stabilized the MP joint by volar plate plasty and later by sesamoidesis. Sesamoidesis is done via a radial mid-lateral approach where the radial sesamoid bone is fixed with a resorbable micro-anchor in the midline of the metacarpal, just proximal to the metacarpal head (Tonkin et al., 1995).

'Five-fingered' hand (first metacarpal and CMC1 joint)

Many authors advise pollicization in the 'five fingered' hand (Buck-Gramcko, 2002; Upton, 1999). In these patients, the long TPT is pollicized in the same manner as the index finger for a hypoplastic or absent thumb. The first metacarpal in a standard pollicization is substantially shortened, together with shortening of the extensor tendons, reinsertion of the intrinsics, and deepening of the web when necessary.

In our series in the earlier years, the thumbs of the five-fingered hands were pollicized as described above. However, after encountering an older boy who was much stronger with his long more stable thumb when compared with his more normal looking but hypermobile pollicized thumb, the first author switched to leaving the original CMC1 joint intact. In these cases, we then performed a ROAMC technique (Hovius et al., 2004) (Figure 3).

We investigated six patients (seven thumbs) with a pollicization and seven patients (nine thumbs) with DIPRAD and ROAMC procedures, with a mean follow-up of 7 years (range 3–11). All parameters of measurement were poorer in the pollicization group. Kapandji (opposition) scores were 6.1 and 6.8 for pollicization and ROAMC, respectively. For pollicizations, opposition strength was 48% and MP joint flexion strength was 49%, as against 64% and 50% in the ROAMC group. Subjective measurements were less in the pollicization group, namely 5.7 vs. 6.7 for ROAMC for function and 5.5 vs. 7.6 for appearance on a scale of 0–10. In one thumb instability was encountered at the MP joint after ROAMC.

Although the numbers are too small to prove superiority of the ROAMC, our results do tend to point in that direction. We advocate shortening, repositioning osteotomies rather than classical pollicization.

Radial polydactyly and TPT

For radial polydactyly, Wassel and Wood advised excision of the TPT component (Wassel, 1969; Wood, 1976). In their series, they were happy with the results of extirpation of the TPT. They advised this even when the other bi-phalangeal thumb was

more rudimentary. Wood also advocated transposition of the rudimentary bi-phalangeal thumb to the base of the TPT metacarpal, where it could grow further. Upton and Shoen, on the contrary, preserve and correct the TPT part and excise the rudimentary bi-phalangeal thumb (Upton, 1999).

In our series, 106 out of 148 hands had a radial polydactyly in conjunction with a TPT. In nearly all patients with radial polydactyly, the radial ray was less developed than the ulnar ray. Two kinds of polydactyly can be distinguished: the first has a polydactyly at the MP joint level. Mostly, the ulnar thumb has a small extra phalanx with deviation. These patients ($n=17$ hands) usually have a unilateral radial polydactyly and are mostly sporadic. They were treated according to the principle of making one thumb from two, reconstructing the best thumb with spare parts of the excised thumb (Dijkman et al., 2016a, 2016b); the second kind was the group of patients with the dominant trait, in which 73 hands were treated. In this group, thumb triplications were also encountered. From 1993 to 2005 we reported 11 triplications. Since then, we have treated many more (Zuidam et al., 2008a) (Figure 4). We also encountered an increase in severity of the congenital anomalies in patients with TPT in the dominant trait over the generations and, as a consequence, more children with triplications visited our outpatient clinic (Baas et al., 2017). For these patients, the radial ray(s) was (were) removed and subsequently a DEL or DIPRAD was performed, depending on the size and shape of the extra phalanx in the ulnar ray. This was mostly combined with a ROAMC of the ulnar ray together with web deepening if necessary (see first web). Syndactylies were reconstructed and, in triplications, additional osteotomies were performed. In patients with bifid distal phalanges, nails could be very broad. For these, the nails were narrowed, mostly by resecting part of the nail and underlying surplus of pulp at the ulnar side with subsequent nail fold reconstruction.

In five patients, the ulnar thumb was transposed to the proximal metacarpal of the radial ray. In these cases, the CMC joints and metacarpals of the radial rays were apparently well developed. In the hand of one patient with bilateral TPT and radial polydactyly, an adducted thumb with MP joint hyperextension resulted from a DIPRAD and transposition of the ulnar ray to radial ray at the proximal metacarpal level. This is a difficult situation to correct later on because the thenar musculature is also aberrant. In retrospect, this procedure is not advised as the radial CMC1 joint is nearly always less well developed than the ulnar CMC1 joint, even when the ulnar CMC1 joint resembles a CMC2 joint. In young children this can be

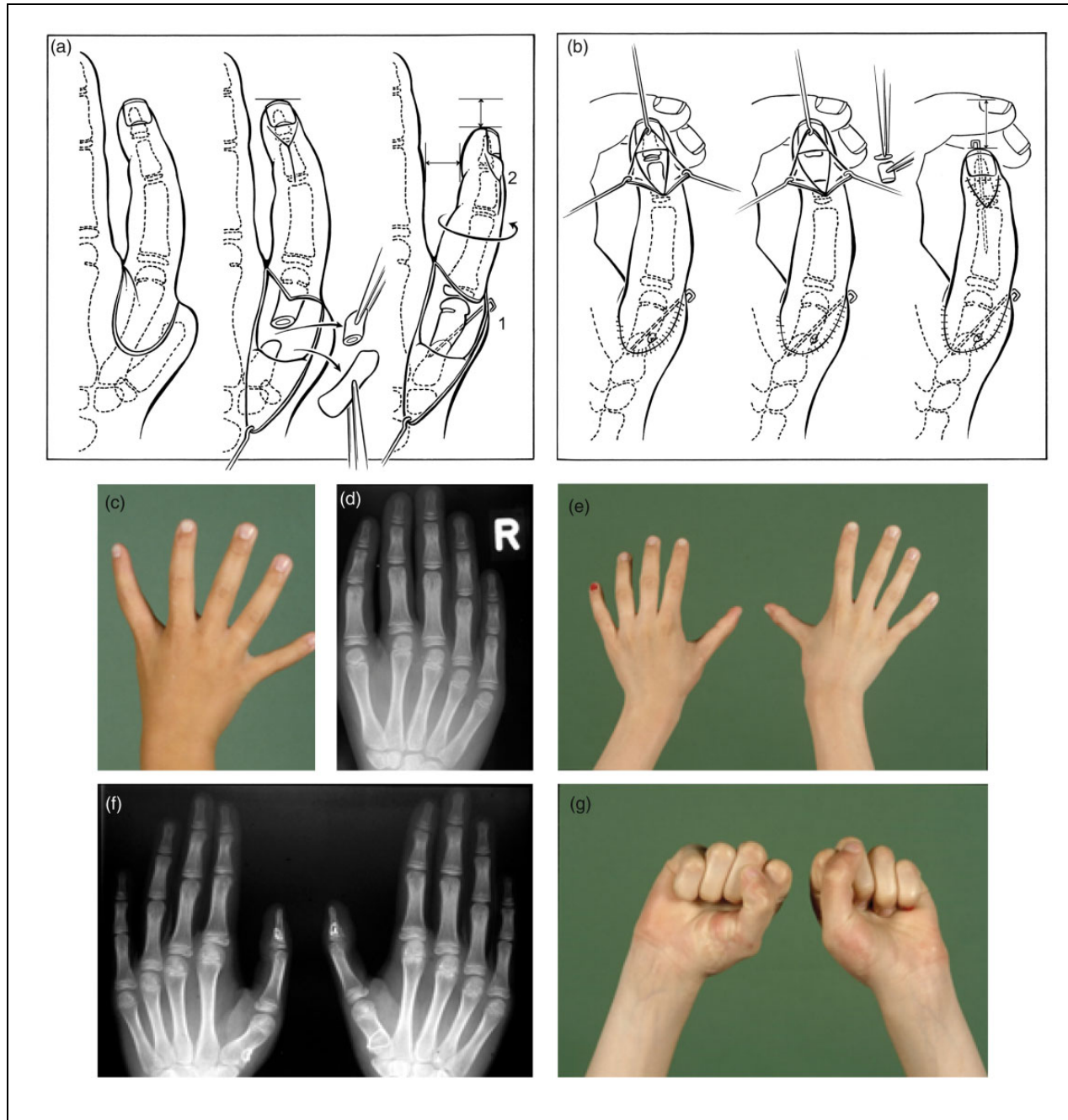


Figure 3. (a) At metacarpal level, osteotomies are performed followed by rotation, abduction, and shortening at the midshaft. Also K-wire and a cerclage wire were used (ROAMC). (b) The skin is incised in a Y over the DIP joint; following incision of the extensor tendon and collateral ligaments the middle phalanx is reduced substantially and the distal phalanx at its edge to prevent damaging nail growth. Fusion is accomplished with a cerclage wire and a K-wire. (c) and (d) Preoperative images of a patient with five-fingered hands. (e-g) Long-term follow-up after shortening at the DIP joint (DIPRAD) and rotation, abduction, and shortening osteotomy at metacarpal level (ROAMC). ROAMC: rotation osteotomy and abduction of the metacarpal; DIP: distal interphalangeal; DIPRAD: distal interphalangeal reduction and arthrodesis.

Reprinted with permission from: Hovius SER, Zuidam JM, de Wit T. 2004.

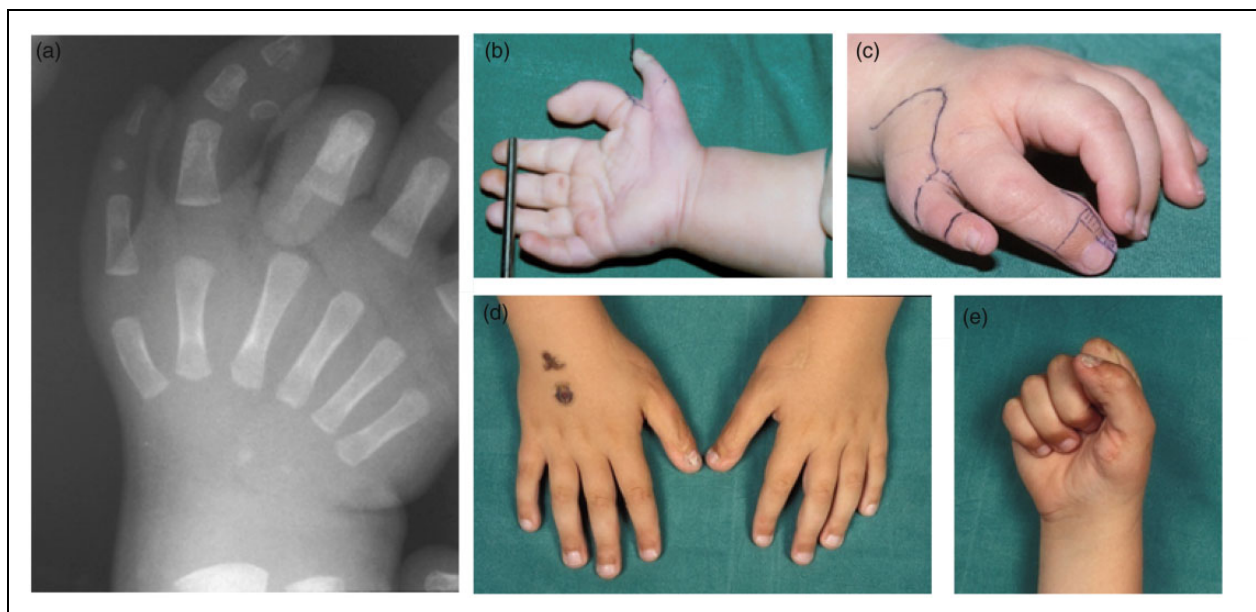


Figure 4. (a)–(c) Preoperative images of a patient with TPT and radial polydactyly. Note the bifid hypoplastic middle and distal phalanx in the ulnar thumb in the X-ray. (d) and (e) After correction at both sides at 6 years follow-up. TPT: triphalangeal thumb.

predicted when the ulnar TPT is more in the plane of the hand and fully developed.

Opposition plasties were always performed in a later stage and ultimately these were only performed in 20% of operated thumbs. Not all non-opposable thumbs therefore need an opposition plasty.

First web

When minor web deepening is indicated a four-flap or five-flap Z-plasty can be used (Glicenstein and Bonnefous, 1975; Woolf and Broadbent, 1972). A transposition flap from the dorsum is an alternative. The skin of the radial side of the index is used for web deepening and the donor defect closed primarily with transposition of skin originating from the area between the second and third ray (Foucher et al., 2001). Where deepening as well as lengthening is needed, as for a non-opposable TPT, a large rotation flap from the dorsum of the hand can be used (Tajima et al., 1967; Wood, 1976). In even larger first web defects, Upton used a distally based radial forearm fasciocutaneous flap for coverage (Upton, 1999).

When necessary we usually performed a five-flap Z-plasty for deepening of the web. When more tissue was needed for the first web, a transposition flap was used from the radial side of the index. Rarely did we need more extensive flaps. However, we did transpose redundant skin from the radial ray in radial polydactyly. Especially, this technique was used if there was deficient skin between the ulnar ray and

the index in TPT patients with radial polydactyly (Upton, 1999).

Thenar muscle deficiency

If opposition strength has to be improved due to thenar muscle deficiency, an opposition plasty can be performed. Many transfers are possible of which the abductor digiti minimi muscle is the most used (Huber, 1921). Other possibilities are the transfer of the flexor carpi ulnaris and the superficial flexor of the ring finger (FDS4) (Miura, 1976; Scharizer, 1965).

In our series, opposition plasties were performed mostly with the FDS4 transfer, which is brought around the flexor carpi ulnaris tendon and subsequently tunnelled subcutaneously to a separate incision at the MP joint of the thumb. One slip is attached to the radial side of the proximal phalanx and the other slip to the radio-dorsal side of the extensor pollicis longus. In contrast to the hypoplastic thumb, ulnar collateral ligament reconstruction was usually not necessary (de Kraker et al., 2016).

Following our surgical considerations, we have devised a flow chart for surgical treatment of patients with TPT (Figure 5).

Postoperative treatment

All the younger patients received a postoperative bandage as a boxer's glove, covered with and

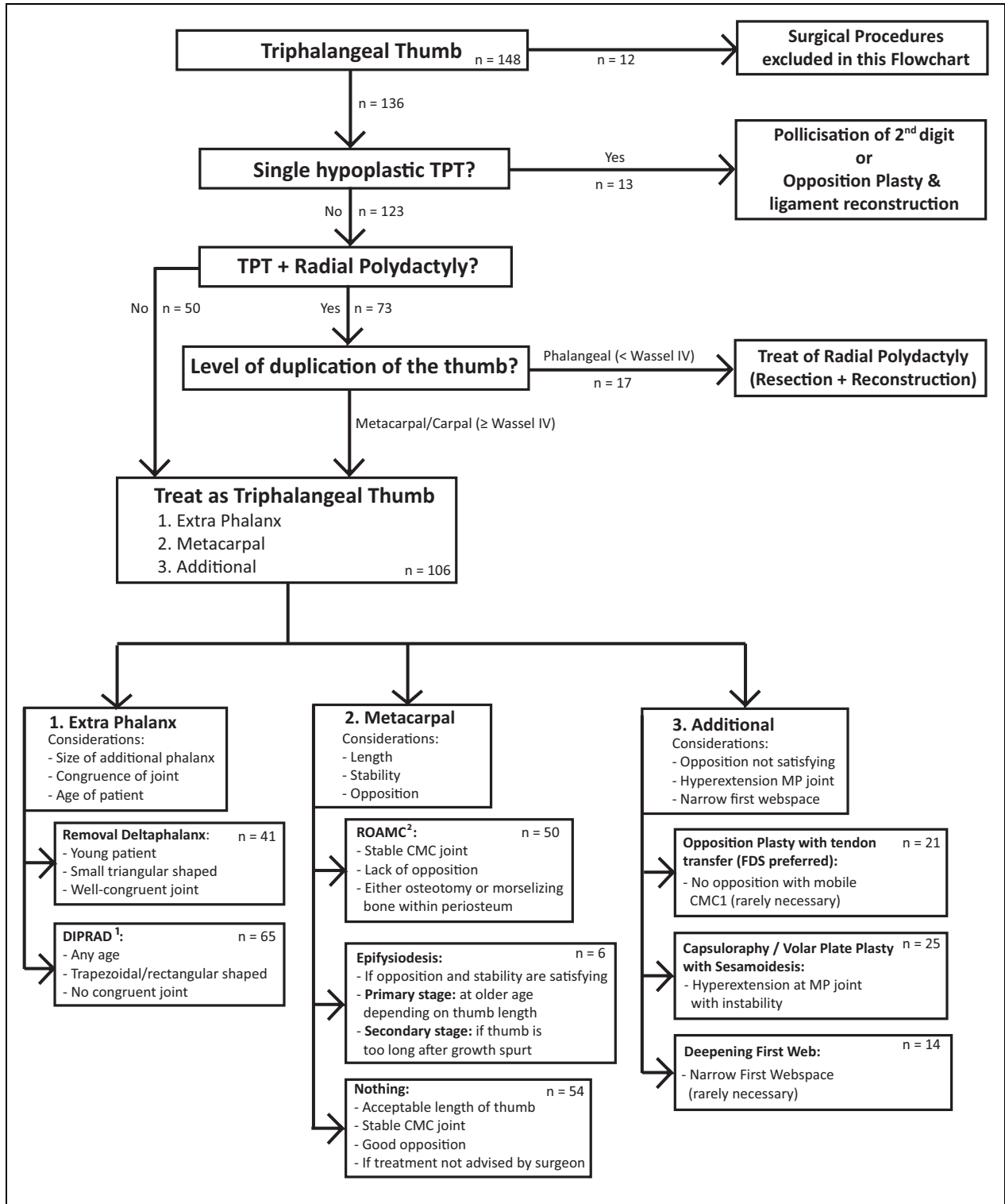


Figure 5. Flow chart for the surgical treatment of triphalangeal thumb. Selecting a treatment option for both 1. Additional Phalanx, and 2. Metacarpal, is mandatory. Surgical options in 3. Additional, have specific indications and are not always advised. They can be conducted in both primary stage or secondary stage surgeries. Combinations of multiple procedures of 1, 2 and 3 can be performed in the same thumb. PIPRAD + ROAMC has been carried out twice. Pollicization of the 1st digit was performed ten times before 2000. Both surgical techniques provided unsatisfactory outcomes for patient and surgeon and therefore are not included in the guidelines. PIPRAD: proximal interphalangeal reduction and arthrodesis; DIPRAD: distal interphalangeal reduction and arthrodesis; ROAMC: rotation osteotomy and abduction of the metacarpal; TPT: triphalangeal; MP: metacarpophalangeal; CMC: carpometacarpal; FDS: flexor digitorum superficialis.

fastened to the elbow with sticky tape in a sugar tongue fashion. K-wires, if used to immobilize joints or osteotomies, were removed after 6 weeks. Hand therapy is essential in providing instructions for subsequent mobilization to the parents and for custom-made removable splints after 6 weeks. Splints immobilize the thumb in palmar abduction with slight flexion in the MP joint and an extended 'new interphalangeal joint'. The splint was mostly continued for 3 months. Exercises in young children are scarcely necessary postoperatively. In older children, when for instance an opposition plasty was performed or hypermobility at the MP joint was corrected, a plaster of Paris was used followed by a splint and hand therapy if thumb use did not occur spontaneously.

General complications

Complications, such as skin problems, infection, or non-union, are very rare. The main issue is not to leave anomalies uncorrected; not to harm delicate tissues; and not to misjudge future growth. The preceding sections include management of complications relating to assessment of thumb length, management of MP joint hyperextension, stiffness, and nail deformities.

Summary

TPT is a rare anomaly, in which the thumb is longer than those of the normal population, not only because of the extra phalanx, but also because of the longer first metacarpal. There is a great variety of phenotypes, often with radial polydactyly next to the triphalangeal thumb. Although opposition is clearly affected, it is the appearance that is the main reason for the parents to come to the outpatient clinic. Treatment is not only directed at the extra phalanx, but also at the first metacarpal and the extra ray if present; to the hypermobility of the MP joint; and to the absence of opposition, if present. A flow chart is provided as a guideline for operative treatment for the various anomalies encountered. We are not in favour of performing a PIP joint arthrodesis for the extra phalanx, nor a pollicization for a five-fingered hand. Long-term follow-up demonstrated better opposition and a more acceptable length of the thumb. Patients were satisfied with their hand function, but more so with the new appearance of the thumb.

Declaration of conflicting interests The authors declared no potential conflicts of interest with respect to the research, authorship, and/or publication of this article.

Funding The authors received no financial support for the research, authorship, and/or publication of this article.

Ethical approval None required.

References

- Baas M, Potuijt JWP, Hovius SER, Hoogeboom AJM, Galjaard RH, van Nieuwenhoven CA. Intrafamilial variability of the triphalangeal thumb phenotype in a Dutch population: evidence for phenotypic progression over generations? *Am J Med Genet A*. 2017, 173: 2898–905.
- Brown, David L. M.D. *Plastic Surgery, 3rd Edition: Volume Six. Hand and Upper Extremity*. 2013, 132: 1377–1378.
- Buck-Gramcko D. Congenital malformations of the hand and forearm. *Chir Main*. 2002, 21: 70–101.
- Bunnell S. *Surgery of the hand*, 3rd Edn. London: J.P. Lippincott, 1944, p.641.
- Campbell W. *Campbell's operative orthopedics*, 2nd Edn. London: Henry Kimpton, 1949.
- Columbo-Cremonensis R. *De re anatomica libri xv*. Venice, ex typographia N. Beuilacquae, 1559.
- Cotta H, Jager M. [Familial triphalangism of the thumb and its surgical treatment]. *Arch Orthop Unfallchir*. 1965, 58: 282–90.
- de Kraker M, Selles RW, Zuidam JM, Molenaar HM, Stam HJ, Hovius SE. Outcome of flexor digitorum superficialis opponens-plasty for type II and IIIa thumb hypoplasia. *J Hand Surg Eur*. 2016, 41: 258–64.
- Dijkman R, Selles R, van Rosmalen J et al. A clinically weighted approach to outcome assessment in radial polydactyly. *J Hand Surg Eur*. 2016a, 41: 265–74.
- Dijkman RR, van Nieuwenhoven CA, Hovius SE, Hulsemann W. Clinical presentation, surgical treatment, and outcome in radial polydactyly. *Handchir Mikrochir Plast Chir*. 2016b, 48: 10–7.
- Ezaki M, Oishi SN. Technique of forearm osteotomy for pediatric problems. *J Hand Surg Am*. 2012, 37: 2400–3.
- Flatt A. *The care of congenital hand anomalies*. St. Louis, MO: Quality Medical Publishing Inc., 1977.
- Foucher G, Medina J, Navarro, Khouri RK. Correction of first web space deficiency in congenital deformities of the hand with the pseudokite flap. *Plast Reconstr Surg*. 2001, 107: 1458–63.
- Garn SM, Hertzog KP, Poznanski AK, Nagy JM. Metacarpophalangeal length in the evaluation of skeletal malformation. *Radiology*. 1972, 105: 375–81.
- Gefferth K. [Metric evaluation of the short tubular bones of the hand from birth to the end of puberty. Measurements of length]. *Acta Paediatr Acad Sci Hung*. 1972, 13: 117–24.
- Glicenstein J, Bonnefous G. [The three-pronged plasty]. *Ann Chir Plast*. 1975, 20: 257–60.
- Heutink P, Zguricas J, Van Oosterhout L et al. The gene for triphalangeal thumb maps to the subtelomeric region of chromosome 7q. *Nature Genetics*. 1994, 6: 287–92.
- Hovius SER, Zuidam JM, de Wit T. Treatment of the triphalangeal thumb. *Tech Hand Upper Extrem Surg*. 2004, 8: 247–56.

- Huber E. Hilfsoperation bei medianuslähmung. *Deutsche Zeitschrift Chirurgie* Huber. 1921, 126: 271–5.
- Lapidus PW, Guidotti FP, Colletti CJ. Triphalangeal thumb. Report of 6 cases. *Surg Gynecol Obstet*. 1943, 77: 178–86.
- Milch H. Triphalangeal thumb. *J Bone Joint Surg Am*. 1951, 33-A: 692–7.
- Miura T. Triphalangeal thumb. *Plast Reconstr Surg*. 1976, 58: 587–94.
- Neligan PC and Chang J. *Plastic Surgery*, 4th edition, Volume 6, Hand and Upper Extremity, Chapter 28. Neligan PC and Chang J (eds). 2018, Elsevier.
- Peimer CA. Combined reduction osteotomy for triphalangeal thumb. *J Hand Surg Am*. 1985, 10: 376–81.
- Scharizer E. On the Surgical Management of the 3-Joint Thumb. *Langenbecks Arch Klin Chir Ver Dtsch Z Chir*. 1965, 309: 47–51.
- Tajima T, Watanabe Y, Uchiyama J. [Treatment and study of the hypoplastic thumb]. *Keisei Geka*. 1967, 10: 227–34.
- Tonkin MA, Beard AJ, Kemp SJ, Eakins DF. Sesamoid arthrodesis for hyperextension of the thumb metacarpophalangeal joint. *J Hand Surg Am*. 1995, 20: 334–8.
- Upton JSS. Triphalangeal thumb. In: Gupta AE (ed.) *The growing hand*. St. Louis, MO, Mosby, 1999, p.255–68.
- Wassel HD. The results of surgery for polydactyly of the thumb. A review. *Clin Orthop Relat Res*. 1969, 64: 175–93.
- Wood VE. Treatment of the triphalangeal thumb. *Clin Orthop Relat Res Wood*, 1976, 120:188–209.
- Woolf RM, Broadbent TR. The four-flap z-plasty. *Plast Reconstr Surg*. 1972, 49: 48–51.
- Zguricas J, Snijders PJLM, Hovius SER, Heutink P, Oostra BA, Lindhout D. Phenotypic analysis of triphalangeal thumb and associated hand malformations. *J Med Gen*. 1994, 31: 462–7.
- Zuidam JM, Ananta M, Hovius SER. Triplicated thumbs: a rarity? *J Plast Reconstr and Aesthet Surg*. 2008a, 61: 1078–84.
- Zuidam JM, de Kraker M, Selles RW, Hovius SER. Evaluation of function and appearance of adults with untreated triphalangeal thumbs. *J Hand Surg Am*. 2010, 35: 1146–52.
- Zuidam JM, Dees EEC, Lequin MH, Hovius SER. The effect of the epiphyseal growth plate on the length of the first metacarpal in triphalangeal thumb. *J Hand Surg Am*. 2006, 31: 1183–8.
- Zuidam JM, Selles RW, Ananta M, Runia J, Hovius SER. A classification system of radial polydactyly: inclusion of triphalangeal thumb and triplication. *J Hand Surg Am*. 2008b, 33: 373–7.
- Zuidam JM, Selles RW, de Kraker M, Hovius SE. Outcome of two types of surgical correction of the extra phalanx in triphalangeal thumb: is there a difference? *J Hand Surg Eur*. 2016, 41: 253–7.