

# EUR Research Information Portal

## Muenke syndrome: long-term outcome of a syndrome-specific treatment protocol

**Published in:**

Journal of Neurosurgery-Pediatrics

**Publication status and date:**

Published: 01/01/2019

**DOI (link to publisher):**

[10.3171/2019.5.Peds1969](https://doi.org/10.3171/2019.5.Peds1969)

**Document Version**

Publisher's PDF, also known as Version of record

**Document License/Available under:**

Article 25fa Dutch Copyright Act

**Citation for the published version (APA):**

den Ottelander, B., de Goederen, R., van Veelen - Vincent, M. L. C., van de Beeten, S., Lequin, MH., Dremmen, M., Loudon, S., Telleman, M., Gier, J., Wolvius, E., Tjoa, S., Versnel, S., Joosten, K., & Mathijssen, I. (2019). Muenke syndrome: long-term outcome of a syndrome-specific treatment protocol. *Journal of Neurosurgery-Pediatrics*, 24(4), 415-422. <https://doi.org/10.3171/2019.5.Peds1969>

[Link to publication on the EUR Research Information Portal](#)

**Terms and Conditions of Use**

Except as permitted by the applicable copyright law, you may not reproduce or make this material available to any third party without the prior written permission from the copyright holder(s). Copyright law allows the following uses of this material without prior permission:

- you may download, save and print a copy of this material for your personal use only;
- you may share the EUR portal link to this material.

In case the material is published with an open access license (e.g. a Creative Commons (CC) license), other uses may be allowed. Please check the terms and conditions of the specific license.

**Take-down policy**

If you believe that this material infringes your copyright and/or any other intellectual property rights, you may request its removal by contacting us at the following email address: [openaccess.library@eur.nl](mailto:openaccess.library@eur.nl). Please provide us with all the relevant information, including the reasons why you believe any of your rights have been infringed. In case of a legitimate complaint, we will make the material inaccessible and/or remove it from the website.

## Muenke syndrome: long-term outcome of a syndrome-specific treatment protocol

Bianca K. den Ottelander, MD,<sup>1</sup> Robbin de Goederen, MD,<sup>1</sup> Marie-Lise C. van Veelen, MD, PhD,<sup>2</sup> Stephanie D. C. van de Beeten, BSc,<sup>1</sup> Maarten H. Lequin, MD, PhD,<sup>3</sup> Marjolein H. G. Dremmen, MD,<sup>4</sup> Sjoukje E. Loudon, MD, PhD,<sup>5</sup> Marieke A. J. Telleman, BHS,<sup>5</sup> Henriëtte H. W. de Gier, MD,<sup>6</sup> Eppo B. Wolvius, DDS, MD, PhD,<sup>7</sup> Stephen T. H. Tjoa, DDS, MSc, MS,<sup>7</sup> Sarah L. Versnel, MD, PhD,<sup>1</sup> Koen F. M. Joosten, MD, PhD,<sup>8</sup> and Irene M. J. Mathijssen, MD, PhD<sup>1</sup>

Departments of <sup>1</sup>Plastic and Reconstructive Surgery and Hand Surgery, Dutch Craniofacial Center, and <sup>2</sup>Neurosurgery, Erasmus MC–Sophia Children’s Hospital, University Medical Center Rotterdam; <sup>3</sup>Department of Radiology, University Medical Center–Wilhelmina Children’s Hospital, Utrecht; and Departments of <sup>4</sup>Radiology; <sup>5</sup>Ophthalmology; <sup>6</sup>Otorhinolaryngology; and <sup>7</sup>Oral and Maxillofacial Surgery, Special Dental Care and Orthodontics; and <sup>8</sup>Pediatric Intensive Care Unit, Erasmus MC–Sophia Children’s Hospital, University Medical Center Rotterdam, Rotterdam, the Netherlands

**OBJECTIVE** The authors evaluated the long-term outcome of their treatment protocol for Muenke syndrome, which includes a single craniofacial procedure.

**METHODS** This was a prospective observational cohort study of Muenke syndrome patients who underwent surgery for craniosynostosis within the first year of life. Symptoms and determinants of intracranial hypertension were evaluated by longitudinal monitoring of the presence of papilledema (fundoscopy), obstructive sleep apnea (OSA; with polysomnography), cerebellar tonsillar herniation (MRI studies), ventricular size (MRI and CT studies), and skull growth (occipital frontal head circumference [OFC]). Other evaluated factors included hearing, speech, and ophthalmological outcomes.

**RESULTS** The study included 38 patients; 36 patients underwent fronto-supraorbital advancement. The median age at last follow-up was 13.2 years (range 1.3–24.4 years). Three patients had papilledema, which was related to ophthalmological disorders in 2 patients. Three patients had mild OSA. Three patients had a Chiari I malformation, and tonsillar descent < 5 mm was present in 6 patients. Tonsillar position was unrelated to papilledema, ventricular size, or restricted skull growth. Ten patients had ventriculomegaly, and the OFC growth curve deflected in 3 patients. Twenty-two patients had hearing loss. Refraction anomalies were diagnosed in 14/15 patients measured at ≥ 8 years of age.

**CONCLUSIONS** Patients with Muenke syndrome treated with a single fronto-supraorbital advancement in their first year of life rarely develop signs of intracranial hypertension, in accordance with the very low prevalence of its causative factors (OSA, hydrocephalus, and restricted skull growth). This illustrates that there is no need for a routine second craniofacial procedure. Patient follow-up should focus on visual assessment and speech and hearing outcomes.

<https://thejns.org/doi/abs/10.3171/2019.5.PEDS1969>

**KEYWORDS** intracranial hypertension; craniosynostosis; Muenke syndrome; craniofacial

**M**UENKE syndrome is a type of syndromic craniosynostosis, with a prevalence of 0.1 per 10,000 live births.<sup>5</sup> It is defined by the presence of the P250R mutation in the *FGFR3* gene, one of the most common mutations described in the human genome.<sup>1,20</sup> Clinical features include sensorineural hearing loss; developmental delay; uni- or bicoronal synostosis, or macrocephaly

in the absence of craniosynostosis; hypertelorism; mild deformities of the hand; and behavioral disturbances.<sup>9,10,15–17</sup> However, due to incomplete penetrance and variable expressivity, Muenke syndrome has a wide spectrum of disease severity, and up to 20% of the patients have a mild presentation.<sup>13</sup>

Treatment of Muenke syndrome is, as in other cra-

**ABBREVIATIONS** D = diopters; FOA = fronto-supraorbital advancement; FOHR = frontal occipital horn ratio; ICH = intracranial hypertension; ICP = intracranial pressure; OAE = otoacoustic emission; oAHI = obstructive apnea–hypopnea index; OCT = optical coherence tomography; OE = occipital expansion; OFC = occipital frontal head circumference; OSA = obstructive sleep apnea; TH = tonsillar herniation; TRT = total retinal thickness.

**SUBMITTED** January 29, 2019. **ACCEPTED** May 14, 2019.

**INCLUDE WHEN CITING** Published online July 19, 2019; DOI: 10.3171/2019.5.PEDS1969.

niosynostosis syndromes, focused particularly on preventing intracranial hypertension (ICH). However, the reported risk of ICH, detected through funduscopy and invasive measurements, appears to be relatively low (0%–21%).<sup>7,14,29,33</sup> In the other craniosynostosis syndromes, the prevalence varies between 21% and 83%.<sup>7,18,24,29</sup> For Muenke syndrome, fronto-supraorbital advancement (FOA) is our preferred surgical procedure, because it restores the facial profile. Some centers, however, routinely perform a two-stage procedure, with posterior vault expansion as the first craniofacial intervention, followed by FOA.<sup>22</sup>

This prospective study gives an overview of children with Muenke syndrome treated at our hospital, the only national referral center for syndromic craniosynostosis. We determined the long-term outcomes after routine single FOA.

## Methods

We included all consecutive patients with Muenke syndrome born between January 1990 and June 2016 who were treated at Erasmus MC–Sophia Children’s Hospital, the Netherlands. Children born after 2005 were prospectively included. IRB approval was obtained (MEC-2005-273, 2016-312). The *FGFR3* P250R mutation was confirmed in all patients.

According to protocol, the routine vault expansion procedure is FOA performed in patients between 6 and 12 months old. The orbital rim is advanced approximately 1.5 cm, thereby taking into consideration that the facial profile should not be significantly disturbed.

## Intracranial Hypertension

Patients were screened for signs of ICH, including evaluation of the following 4 features:<sup>29</sup> 1) bulging of the fontanel in babies; 2) skull growth, which was assessed by measuring the occipital frontal head circumference (OFC). The OFC was measured preoperatively, every 3 months until the age of 2 years, every 6 months until the age of 4 years, and from then on yearly until the age of 18 years. Growth curve deflection was defined as  $\geq 0.5$  standard deviation (SD) fall from baseline over 2 years. As OFC reliably predicts intracranial volume in syndromic craniosynostosis,<sup>25</sup> OFC curve deflection is a risk factor for ICH.<sup>29</sup> 3) Funduscopy was performed to screen for papilledema and was primarily used to indicate ICH. Patients were screened once preoperatively and at the ages of 2, 4, and 6 years. 4) Optical coherence tomography (OCT) was performed in children  $\geq 4$  years old, using the Spectralis OCT scanner (Heidelberg Engineering). This examination was added to the protocol in 2014. The total retinal thickness (TRT) was analyzed using our normative reference values, which were derived from OCT data of 67 healthy children (aged 4–12 years). Abnormal values included TRT  $< 276 \mu\text{m}$  and TRT  $> 503 \mu\text{m}$  (van de Beeten et al., 2019, submitted), indicating either atrophy or papilledema.

When ICH was suspected based on clinical symptoms such as daily headaches, but papilledema was absent, including during repeated funduscopy after 6 weeks, invasive intracranial pressure (ICP) monitoring was performed. This 24-hour examination was evaluated accord-

ing to the following criteria:<sup>32</sup> 1) Baseline ICP during the day and overnight ( $< 10 \text{ mm Hg}$ , normal; 10–15 mm Hg, borderline abnormal depending on the height and duration of abnormal plateaus;  $> 15 \text{ mm Hg}$ , abnormal). Additionally, the trend of ICP values was evaluated, to check for any increase overnight. 2) Number of abnormal plateau waves based on height ( $< 25 \text{ mm Hg}$ , normal; 25–35 mm Hg, borderline;  $> 35 \text{ mm Hg}$ , abnormal) and duration ( $< 10$  minutes, normal; 10–20 minutes, borderline;  $> 20$  minutes, abnormal).

Patients with papilledema and/or abnormal ICP measurement were all considered to have ICH.

## Sleep Study

Obstructive sleep apnea (OSA) was diagnosed with clinical and ambulatory sleep studies. The obstructive apnea–hypopnea index (oAHI) was calculated as follows: the number of obstructive and mixed apneas and obstructive hypopneas with desaturation/arousal, divided by the total sleep time. Patients were classified as having either no (oAHI  $< 1$ ), mild (oAHI  $\geq 1$ –5), moderate (oAHI  $\geq 5$ –10), or severe OSA (oAHI  $\geq 10$ ).

## Neuroimaging

Tonsillar position was reviewed on MR images and ventricular size on MR images and CT scans. All imaging studies were reviewed in a 3D reformatting platform (AquariusNET; TeraRecon, Inc.) to align scans in all planes. The presence and extent of tonsillar herniation (TH) was evaluated on midsagittal and adjacent slices and was classified as follows: 1) no tonsillar descent, 2) tonsillar descent  $< 5 \text{ mm}$ , or 3) herniation  $> 5 \text{ mm}$ , i.e., Chiari I malformation. For these measurements, the position of the lowest tonsil was evaluated with respect to the foramen magnum.

The size of the lateral ventricles was evaluated on axial planes using the frontal occipital horn ratio (FOHR); ventricles were considered enlarged when the FOHR was  $> 0.34$ .<sup>27</sup> Hydrocephalus was present when ventricles were progressively enlarged on  $\geq 2$  MR images or CT scans.

The correlation between FOHR and tonsil position was evaluated using a linear mixed model. R statistical programming was used (v3.4.4). Statistical significance was set at  $p < 0.05$ .

## Audiometry

Hearing capacity in children  $\geq 4$  years old was assessed by pure-tone audiometry and was classified as follows: 1) no hearing loss: an average pure-tone loss  $< 20 \text{ dB}$ ; 2) mild hearing loss: an average pure-tone loss of 20–40 dB; 3) moderate hearing loss: an average pure-tone loss of 41–70 dB; or 4) severe hearing loss: an average pure-tone loss  $\geq 70 \text{ dB}$ . Both ears were analyzed separately.

Patients  $< 4$  years old underwent otoacoustic emission (OAE) testing, which is considered deviant when emissions are absent in 3/5 frequencies (e.g., 1.0, 1.4, 2.0, 2.8, and 4.0 kHz). Data for the standard newborn hearing screening in the Netherlands, performed by OAE testing within 1 week postpartum, were collected. The use of hearing aids was reported, as well as the placement of

tympanostomy tubes in patients with chronic serous otitis media with effusion. Speech and language development was routinely monitored.

### Ophthalmological Evaluation

Visual acuity was established by an orthoptist and was evaluated at the latest available follow-up, since the possible effect of papilledema on vision is a long-term effect.<sup>24</sup> The eye with the best visual acuity was used in the analysis, to prevent confounding caused by strabismus and/or amblyopia. Visual acuity was expressed using the logMAR scale.

Cycloplegic refraction was measured in diopters (D) and classified into the following categories:<sup>21</sup> myopic,  $\leq -0.50\text{D}$ ; highly myopic,  $\leq -6.00\text{D}$ ; emmetropic,  $> -0.50\text{D}$  to  $\leq +0.50\text{D}$ ; mildly hyperopic,  $> +0.50\text{D}$  to  $+2.00\text{D}$ ; hyperopic,  $+2.00\text{D}$  to  $+6.00\text{D}$ ; and highly hyperopic,  $> +6.00\text{D}$ .

Refraction was analyzed at 2 time points. Refraction analysis was performed in children aged  $< 6$  years, when they were at risk of developing ICH,<sup>29</sup> because hyperopia  $\geq 3.00\text{D}$  is associated with a crowded optic disc appearance, which can mimic papilledema.<sup>3,34</sup> Consequently, we used refraction data to interpret funduscopy results in these children. Refraction analysis was also performed in children at the age of  $\geq 8$  years, since visual development continues up to 7–8 years.<sup>35</sup>

### Neuropsychological Functioning

For all patients, the educational level was monitored at visits to the outpatient clinic.

## Results

### Patient Characteristics

The study included 38 patients, of whom 22 were female. Thirty-five patients primarily underwent FOA in our treatment center. Two patients were referred to our center after endoscopic strip craniectomy elsewhere, and these patients subsequently underwent FOA in our treatment center. One patient primarily underwent occipital expansion (OE) because of papilledema. A second vault expansion was indicated in 3 patients; 2 of these patients had a severe phenotype, and 1 patient had recurring papilledema.

The median age at the first surgery was 8.5 months for the whole group (range 2.3–18.3 months), while it was 9.0 months (range 3.4–18.3 months) for patients primarily referred to our center. The mean estimated blood loss was 490 ml (range 100–900 ml). The median age at last follow-up was 13.2 years (range 2.0–24.44 years).

### Intracranial Hypertension

See Table 1 for an overview of factors involving ICH. There were no babies in this study with bulging of the fontanel.

### Skull Growth

Two patients had a deflecting OFC growth curve. OFC deflection occurred 3 years after the first surgery in 1 pa-

tient, and it was diagnosed 1.8 years after the second skull surgery in the other (patient 1, Table 1).

### Fundoscopy

Twenty-eight patients underwent repeated funduscopies. Three had bilateral papilledema before vault expansion, which recurred in 1 patient postoperatively. The first patient (patient 6, Table 1) had mild papilledema before vault expansion, which disappeared postoperatively. Hyperopia  $+3.00\text{D}$  was diagnosed in this patient at the age of 12 months. The second patient (patient 7, Table 1) had mild papilledema preoperatively, which disappeared after occipital expansion. The third patient (patient 1, Table 1) had papilledema preoperatively. Papilledema initially disappeared after surgery, but recurred 6 months later. At this time, the OFC growth curve and ventricle size were normal. Subsequently, the patient underwent invasive ICP monitoring, which showed that the mean ICP overnight was 10 mm Hg with an increase to 13 mm Hg. There were 5 plateau waves during rapid eye movement (REM) sleep, with a maximal peak of 27 mm Hg, although peaks were rarely  $> 20$  mm Hg. Considering the patient's young age (1.5 years), this finding was evaluated as borderline abnormal, and the patient underwent reoperation (occipital decompression), after which the papilledema resolved. Hyperopia  $\geq 3.00\text{D}$  was diagnosed at the age of 2 years.

### Optical Coherence Tomography

Seven patients underwent OCT scanning; none had abnormal TRT. The patient with papilledema at the age of 6.9 and 18 months (patient 1, Table 1) showed a sloping optical disc on the OCT scan performed at the age of 12 years, which mimics blurring of the optical disc. This anomaly was congenital, and probably influenced the funduscopy evaluation.

### Obstructive Sleep Apnea

Twenty-nine patients underwent a routine sleep study. The 9 patients who did not undergo a polysomnography were asymptomatic. Four patients had mild OSA (Table 1).

### Neuroimaging

Thirty patients underwent MRI (median age 4.9 years, range 0.3–24.13 years). Three patients had a Chiari I malformation, and tonsillar descent  $< 5$  mm was present in 6 patients. The first tonsillar descent  $< 5$  mm was diagnosed in a 4-year-old patient. Three patients with tonsillar descent through the foramen magnum had repetitive scans; the tonsillar position progressively lowered in 2 patients, and was stable in 1 patient.

The lateral ventricles were evaluated on 68 scans in 36 patients (MRI,  $n = 41$ ; CT,  $n = 27$ ). The mean age at evaluation was 6.0 years (range 0.03–24.13 years). The mean FOHR was 0.33 (range 0.19–0.42). FOHR was  $> 0.34$  in 10 patients; see Table 1 for detailed information. Tonsil position and FOHR were not significantly correlated ( $p = 0.37$ ).

### Hearing Capacity and Speech Development

Twenty-eight patients underwent audiological evalua-

TABLE 1. Overview of risk factors and ICH

Pt No.	Involved Suture(s)	Op Type (age in yrs)	OFC Before 1st Op, SD	Deflecting OFC Growth Curve Postop	OSA	Neuroimaging			Papilledema Preop/FU	Hyperopia ≥3.00D
						Cerebellar TH in mm, age in yrs	Highest FOHR (age in yrs)*	Cerebellar TH (tonsil position in mm, age in yrs)		
1	Bicoronal	FOA (0.6), OE (1.6)	0.08	+†	-	Mild tonsillar descent (4.2, 5.5)†	0.32 (11.0)	+/-	+	
2	Bicoronal	FOA (0.5)	-5.82	-	-	-	0.40 (6.3)	-/-	-	
3	Bicoronal	FOA (0.6)	-1.46	-	Mild†	CMI (7.7, 4.6)	0.33 (3.1)	-/-	-	
4	Unicoronal	FOA (1.0)	Missing	-	Missing	Mild tonsillar descent (2.6, 6.0)	0.30 (6.0)	-/-	-	
5	Unicoronal	FOA (1.0)	0.21	-	-	-	0.39 (0.4)	-/-	-	
6	Bicoronal	FOA (0.6)	-1.06	+	-	-	0.42 (0.3)	+/-	+	
7	Bicoronal	OE (0.7)§	-1.05	-	-	-	0.28 (0.3)	+/-	-	
8	Bicoronal	FOA (0.9)	-0.55	-	Missing	-	0.34 (6.3)	-/-	-	
9	Unicoronal	FOA (0.9)	-0.06	-	-	Missing	Missing	-/-	+	
10	Unicoronal	FOA (0.5)	Missing	-	Mild†	-	0.40 (7.4)	-/-	-	
11	Bicoronal	FOA (0.7)	1.64	-	Mild**	-	0.36 (4.4)	-/-	Missing	
12	Bicoronal	FOA (0.6)	-1.54	-	Missing	-	0.42 (0.3)	-/-	-	
13	Unicoronal	Endoscopic strip craniectomy†† (0.4), FOA (1.3)	0.84	-	Missing	-	0.37 (1.1)	-/-	Missing	
14	Bicoronal	FOA (0.9)	Missing	-	-	Missing	0.31 (0.9)	-/-	-	
15	Unicoronal	FOA (1.5)	-0.89	-	-	Missing	0.29 (1.5)	-/-	Missing	
16	Unicoronal	FOA (0.9)	0.14	-	-	Mild tonsillar descent (1.2, 6.7)	0.34 (0.8)	-/-	-	
17	Bicoronal	FOA (0.7)	Missing	-	-	Mild tonsillar descent (1.8, 8.1)	0.32 (8.1)	-/-	-	
18	Unicoronal	FOA (0.9)	-0.95	-	-	Mild tonsillar descent (1.2, 6.5)	0.30 (6.5)	-/-	Missing	
19	Bicoronal	FOA (0.8)	-1.21	-	-	Mild tonsillar descent (2.7, 4.0)	0.32 (4.0)	-/-	Missing	
20	Bicoronal	FOA (0.6)	0.73	-	-	-	0.32 (5.9)	-/-	-	
21	Bicoronal	FOA (0.9)	-0.43	-	-	-	0.34 (0.5)	-/-	-	
22	Bicoronal	FOA (1.0)	1.67	-	-	-	0.30 (0.4)	-/-	-	
23	Unicoronal	FOA (0.9)	0.54	-	-	-	0.33 (0.4)	-/-	-	
24	Bicoronal	Endoscopic strip craniectomy†† (0.2), FOA (1.2)	0.99	-	-	-	0.30 (1.3)	-/-	Missing	
25	Bicoronal	FOA (0.7)	2.53	-	Missing	Missing	0.34 (0.3)	-/-	-	
26	Bicoronal	FOA (1.3)	0.63	-	Missing	Missing	0.19 (0.9)	-/-	+	
27	Bicoronal	FOA (0.8)	-1.64	-	Missing	Missing	0.31 (0.3)	-/-	Missing	
28	Metopic	FOA (1.1)	-1.05	-	Missing	Missing	0.31 (0.8)	-/-	Missing	
29	Unicoronal	FOA (0.9)	1.38	-	-	CMI (5.6, 13.9)	0.33 (13.9)	Missing†††	-	
30	Bicoronal partially	FOA (0.9)	0.80	-	-	CMI (6.3, 11.8)	0.41 (7.8)	Missing†††	Missing	
31	Bicoronal partially	FOA (0.3)	Missing	-	Mild†	Missing	Missing	Missing†††	-	
32	Unicoronal	FOA (0.7)	0.68	-	-	-	0.36 (8.9)	Missing†††	+	
33	Bicoronal	FOA (0.8)	-0.41	-	Missing	-	0.34 (0.03)	Missing†††	-	
34	Bicoronal	FOA (0.4)	-1.75	-	-	-	0.33 (19.9)	Missing†††	-	

CONTINUED ON PAGE 419 »



» CONTINUED FROM PAGE 418

**TABLE 1. Overview of risk factors and ICH**

Pt No.	Involved Suture(s)	Op Type (age in yrs)	OFC		Deflecting		Neuroimaging			Papilledema Preop/FU	Hyperopia $\geq 3.00D$
			Before 1st Op, SD	Curve	OFC Growth	OSA	Cerebellar TH (tonsil position in mm, age in yrs)	Highest FOHR (age in yrs)*			
35	Both lambdoids + sagittal	FOA (0.6)	-2.41	-	-	-	-	0.36 (12.2)	Missing¶¶	-	
36	Bicoronal	FOA (0.7)	-1.73	-	-	-	-	0.34 (19.2)	Missing¶¶	-	
37	Unicoronal + both lambdoids	FOA (0.7)	-0.27	-	-	-	-	0.28 (10.6)	Missing¶¶	-	
38	Bicoronal	FOA (0.5)	-1.25	-	-	-	-	0.32 (7.3)	Missing¶¶	Missing	

CMI = Chiari I malformation; FU = follow-up; pt = patient; + = present; - = absent.

\* Ventricule size remained stable in all patients; none developed hydrocephalus.

† OFC deflection occurred after second cranial vault expansion. Tonsillar herniation was diagnosed 4 years after occipital expansion.

‡ Indicated because of papilledema.

¶ OSA resolved after a wait-and-see policy.

¶¶ OSA resolved after adenotonsillectomy.

†† Patient underwent endoscopic strip craniectomy elsewhere before referral to our center.

††† Fundoscopy results excluded due to insufficient follow-up with fundoscopy.

**TABLE 2. Overview of hearing capacity and ophthalmologic evaluation results in patients with Muenke syndrome**

	Value
Hearing capacity	
Pure tone audiometry (n = 21)	
No hearing loss	2
Unilat moderate sensorineural hearing loss (no hearing loss in the other ear)	2
Bilat sensorineural hearing loss*	
Mild	11
Mild in 1 ear, moderate in the other	4
Moderate	2
Severe	0
Otoacoustic emission testing (n = 7)	
Normal	4
Abnormal	3
Neonatal hearing screening abnormal	37/38 (97.4%)
Tympanostomy tubes	22/38 (57.9%)
Ophthalmologic evaluation	
Unicoronal pts	
Visual acuity of the better eye (logMAR)	0.02 (0.08–0.2)
Strabismus	7
Amblyopia	4
Bicoronal pts	
Visual acuity of the better eye (logMAR)	0.07 (-0.08 to 0.5)†
Strabismus	11
Amblyopia	6

Values are presented as number of patients (%) unless otherwise indicated. Mean values are presented with ranges.

\* Deficits were typically present at low and middle frequencies, e.g., 250/500 and 1000 Hz in 12 patients and 250/500/1000 and 2000 Hz in 7 patients. Thirteen patients required hearing aids.

† The patient with 0.5 logMAR visual acuity did not have papilledema, strabismus, or amblyopia. However, hyperopia +1.00D and astigmatism were diagnosed.

tion (21 pure-tone audiometry, 7 OAE testing). Twenty-one patients had hearing loss; see Table 2 for detailed information on the results and Fig. 1 for typical audiogram and OAE. Thirteen patients required hearing aids.

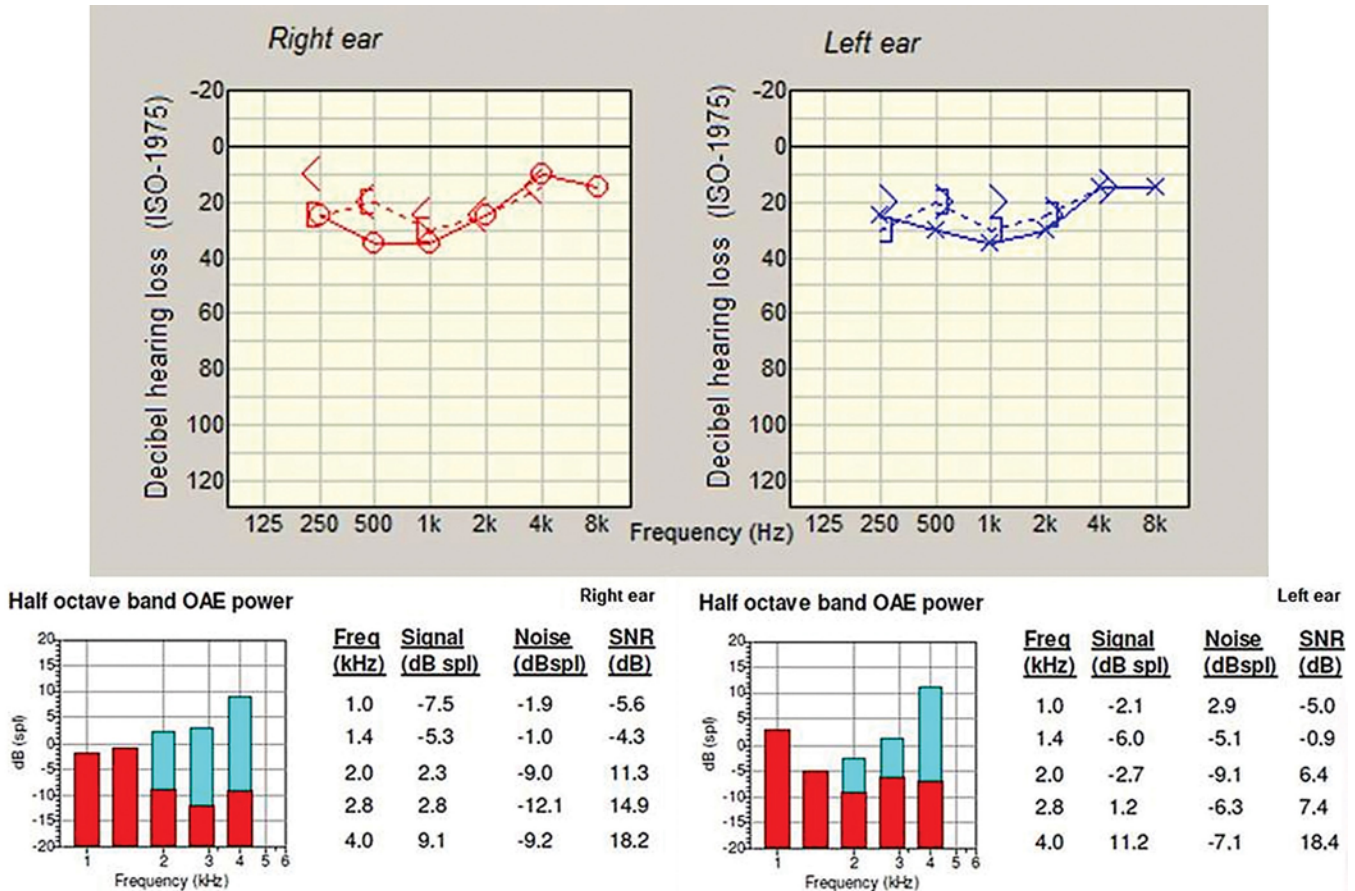
Twenty-two patients were referred for speech therapy because of delayed speech and language development. Ten patients had no delay, 2 patients were too young for evaluation, and 4 patients lacked data regarding referral.

**Ophthalmological Evaluation**

Twenty-three patients underwent visual acuity testing (median age at testing 8.7 years, range 3.4–16.63 years); see Table 2 for the results. Cycloplegic refraction was measured in 15 patients aged  $\geq 8$  years. One patient was emmetropic, 6 were mildly hyperopic, 4 had hyperopia, and 4 patients were myopic.

**Educational Level**

Twenty-eight patients were in a regular school curricu-



**FIG. 1.** Typical features of Muenke syndrome. **Upper:** Classic audiogram. **Lower:** Oto-acoustic emission. Freq = frequency; spl = sound pressure level. Figure is available in color online only.

lum. Five patients followed an individualized curriculum at a special school (3 because of speech and language delay, 2 because of behavioral problems). The educational level was missing in 1 patient, and 4 children were in nursery school.

### Discussion

Following our standard protocol of a single fronto-supraorbital advancement, signs of ICH occurred in only 8% of patients, which is a small fraction in comparison with other craniosynostosis syndromes.<sup>14,18,24,29</sup> Considering the ophthalmological anomalies in 2 of the patients with papilledema (hyperopia  $\geq 3.00D$  and hyperopia with sloping of the optic disc) without the presence of any other signs of ICH, the percentage might be even as low as 3%. The striking difference with ICH prevalence of 33.3% in patients with Saethre-Chotzen syndrome treated at our center is particularly interesting, because these patients underwent an identical surgical procedure at the same age.<sup>29</sup> Based on our results, we have a number of recommendations (see Table 3).

The causative factors for ICH—craniocerebral disproportion, OSA, hydrocephalus, and venous outflow obstruction—are all rare in Muenke syndrome, as shown in this study and previous ones.<sup>12</sup> Craniocerebral disproportion is

unusual; in the present study OFC deflection occurred in 2 patients and the mean SD value before the first surgery was  $-0.40$ . Moreover, brain volumes are normal in Muenke syndrome.<sup>8</sup> In this study OSA was detected in only 8% of the patients and was of mild severity, which does not increase the risk of ICH in craniosynostosis.<sup>29,30</sup> No patients had hydrocephalus.

Chiari I malformation and mild tonsillar descent occurred in 30% of the patients but was unrelated to papilledema or increased ventricular size, as is common in other craniosynostosis syndromes.<sup>8,31</sup> Additionally, factors influencing the development of tonsillar descent, such as a reduced posterior fossa volume, venous hypertension, and lambdoid suture synostosis are absent or arise infrequently in Muenke syndrome.<sup>4,12,26,27</sup> This suggests that the etiology of tonsillar descent in Muenke syndrome might be different than that in the other craniosynostosis syndromes. Primarily, tonsillar descent ( $< 5$  mm) also occurs in healthy children in at least 25% of cases.<sup>28</sup> Consequently, the tonsillar position might be normal in the majority of the Muenke patients. Another explanation can be the altered osseous configuration of the skull base, which can result in false-positive measurements of tonsillar position. Research has shown that patients with a reduced clivus length are more prone to a lower tonsillar position.<sup>11</sup> Likewise, the sphenoid-occipital synchondrosis closes earlier in

**TABLE 3. Muenke syndrome treatment protocol recommendations**

Diagnosics & Treatment	Protocol Recommendation
Genetic diagnosis	Screening for the P250R mutation in the <i>FGFR3</i> gene
(3D) CT scan	Preop in all pts to confirm craniosynostosis
MRI	Preop & postop at age 4 & 10 yrs for research purposes (monitoring of TH/ventriculomegaly)
Cranial vault remodeling	Single fronto-supraorbital advancement at age 12 mos
Polysomnography	If anamnestic breathing difficulties are present
Fundoscopy	In pts w/ deflecting OFC growth curve/ICH symptoms
Sight	Screening for refractive disorders from 1st visit, further ophthalmic workup if present. Visual acuity testing at age $\geq 3$ yrs
Hearing	OAE until 4 yrs, pure tone audiometry at age $\geq 4$ yrs
Evaluation of speech	Referral at age 2 yrs

approximately 30% of Muenke patients.<sup>19</sup> This structure is known to facilitate growth of the clivus.<sup>6</sup> A final explanation might be that the volumes of both the cerebellum and posterior fossa in Muenke patients are increased.<sup>26</sup> This may be associated with the position of cerebellar tonsils that we found, which mimics tonsillar descent on imaging, without being related to ICH. To further elucidate the evolution of tonsillar position in Muenke syndrome, repetitive MRI scans would be valuable, e.g., preoperatively and at the age of 4 and 10 years. This would be for research purposes only.

Hearing loss in our study patients was mostly sensorineural, and hearing was impaired in 75% of patients, which is similar to previously reported percentages.<sup>16</sup> However, the results of neonatal hearing screening were deviant in only 1 patient; thus, this is an unreliable screening method for Muenke patients. An explanation for the lower diagnostic accuracy of this screening in our patients is that the newborn hearing screening is found to be abnormal when OAEs are absent in 3 of the 5 tested frequencies. Our patients typically had no emissions in the lower 2 frequencies, which resulted in normal testing outcomes according to the screening. Earlier detection of hearing loss would be favorable, because mild hearing loss influences behavior and school performance<sup>2</sup> and can have an additional effect on the intrinsic intellectual and behavioral problems in children with Muenke syndrome.<sup>16,17</sup>

The most common refractive error was mild hyperopia, which occurred in 40% of patients, which is similar to the percentage in healthy children.<sup>21</sup> In contrast, high hyperopia occurred more frequently than in healthy children (32% in Muenke patients versus 16% in healthy controls < 6 years old).<sup>23</sup> An explanation for this higher prevalence might be that the orbits of these patients are deformed as a consequence of the coronal synostosis. This deformation

can result in an altered axis length of the eye, which is associated with axial ametropia.<sup>36</sup>

A limitation of our study was that data were incomplete in some patients. For example, repeated MR images were missing, which limits follow-up of the development and possible consequences of ventriculomegaly and cerebellar tonsillar herniation. For future research, it would be valuable to compare follow-up data of our patients to similar data for patients treated according to different protocols at other craniofacial centers.

## Conclusions

The outcomes of treating Muenke syndrome with a single fronto-supraorbital advancement within the first year of life demonstrate a low risk of developing symptoms of ICH (3%–8%), but a rather high prevalence of (mild) tonsillar descent of 33%, which is unrelated to ICH or ventricular size. A routine single-stage procedure appears to be sufficient treatment. The follow-up for these patients should particularly focus on visual assessment, hearing irrespective of neonatal screening outcome, and speech assessment.

## Acknowledgments

We would like to thank the “Janivo Stichting” for their financial contribution, which has made this work possible. The “Janivo Stichting” was not involved in the study design; the collection, analysis, or interpretation of data; the writing of the report; nor the decision to submit the paper for publication.

## References

- Bellus GA, Gaudenz K, Zackai EH, Clarke LA, Szabo J, Francomano CA, et al: Identical mutations in three different fibroblast growth factor receptor genes in autosomal dominant craniosynostosis syndromes. *Nat Genet* **14**:174–176, 1996
- Bess FH, Dodd-Murphy J, Parker RA: Children with minimal sensorineural hearing loss: prevalence, educational performance, and functional status. *Ear Hear* **19**:339–354, 1998
- Brodsky MC: *Pediatric Neuro-Ophthalmology*. New York: Springer, 2016
- Cinalli G, Spennato P, Sainte-Rose C, Arnaud E, Aliberti F, Brunelle F, et al: Chiari malformation in craniosynostosis. *Childs Nerv Syst* **21**:889–901, 2005
- Cornelissen M, Ottelander Bd, Rizopoulos D, van der Hulst R, Mink van der Molen A, van der Horst C, et al: Increase of prevalence of craniosynostosis. *J Craniomaxillofac Surg* **44**:1273–1279, 2016
- Currie K, Sawchuk D, Saltaji H, Oh H, Flores-Mir C, Lagraverre M: Posterior cranial base natural growth and development: a systematic review. *Angle Orthod* **87**:897–910, 2017
- de Jong T, Bannink N, Bredero-Boelhouwer HH, van Veelen ML, Bartels MC, Hoeve LJ, et al: Long-term functional outcome in 167 patients with syndromic craniosynostosis; defining a syndrome-specific risk profile. *J Plast Reconstr Aesthet Surg* **63**:1635–1641, 2010
- de Jong T, Rijken BF, Lequin MH, van Veelen ML, Mathijssen IM: Brain and ventricular volume in patients with syndromic and complex craniosynostosis. *Childs Nerv Syst* **28**:137–140, 2012
- de Jong T, Toll MS, de Gier HH, Mathijssen IM: Audiological profile of children and young adults with syndromic and complex craniosynostosis. *Arch Otolaryngol Head Neck Surg* **137**:775–778, 2011



10. Doherty ES, Lacbawan F, Hadley DW, Brewer C, Zalewski C, Kim HJ, et al: Muenke syndrome (FGFR3-related craniosynostosis): expansion of the phenotype and review of the literature. **Am J Med Genet A** **143A**:3204–3215, 2007
11. Dufton JA, Habeeb SY, Heran MK, Mikulis DJ, Islam O: Posterior fossa measurements in patients with and without Chiari I malformation. **Can J Neurol Sci** **38**:452–455, 2011
12. Florisson JM, Barmpalios G, Lequin M, van Veelen ML, Bannink N, Hayward RD, et al: Venous hypertension in syndromic and complex craniosynostosis: the abnormal anatomy of the jugular foramen and collaterals. **J Craniomaxillofac Surg** **43**:312–318, 2015
13. Johnson D, Wilkie AO: Craniosynostosis. **Eur J Hum Genet** **19**:369–376, 2011
14. Kress W, Schropp C, Lieb G, Petersen B, Büsse-Ratzka M, Kunz J, et al: Saethre-Chotzen syndrome caused by TWIST 1 gene mutations: functional differentiation from Muenke coronal synostosis syndrome. **Eur J Hum Genet** **14**:39–48, 2006
15. Kruzka P, Addissie YA, Agochukwu NB, Doherty ES, Muenke M: Muenke syndrome, in Adam MP, Ardinger HH, Pagon RA, et al (eds): **GeneReviews** [Internet]. Seattle: University of Washington, 1993–2019 (<https://www.ncbi.nlm.nih.gov/books/NBK1415/>) [Accessed May 30, 2019]
16. Kruzka P, Addissie YA, Yarnell CM, Hadley DW, Guillen Sacoto MJ, Platte P, et al: Muenke syndrome: an international multicenter natural history study. **Am J Med Genet A** **170A**:918–929, 2016
17. Maliepaard M, Mathijssen IM, Oosterlaan J, Okkerse JM: Intellectual, behavioral, and emotional functioning in children with syndromic craniosynostosis. **Pediatrics** **133**:e1608–e1615, 2014
18. Marucci DD, Dunaway DJ, Jones BM, Hayward RD: Raised intracranial pressure in Apert syndrome. **Plast Reconstr Surg** **122**:1162–1170, 2008
19. McGrath J, Gerety PA, Derderian CA, Steinbacher DM, Vosough A, Bartlett SP, et al: Differential closure of the sphenoccipital synchondrosis in syndromic craniosynostosis. **Plast Reconstr Surg** **130**:681e–689e, 2012
20. Moloney DM, Wall SA, Ashworth GJ, Oldridge M, Glass IA, Francomano CA, et al: Prevalence of Pro250Arg mutation of fibroblast growth factor receptor 3 in coronal craniosynostosis. **Lancet** **349**:1059–1062, 1997
21. Morgan IG, Rose KA, Ellwein LB: Is emmetropia the natural endpoint for human refractive development? An analysis of population-based data from the refractive error study in children (RESC). **Acta Ophthalmol** **88**:877–884, 2010
22. Nishikawa H, Evans M, Rodrigues D, Solanki G, White N, Dover S: Posterior calvarial distraction. A review of six years experience at the Birmingham Children's Hospital. **J Plast Reconstr Aesthet Surg** **67**:1605, 2014
23. Polling JR, Loudon SE, Klaver CC: Prevalence of amblyopia and refractive errors in an unscreened population of children. **Optom Vis Sci** **89**:e44–e49, 2012
24. Renier D, Lajeunie E, Arnaud E, Marchac D: Management of craniosynostoses. **Childs Nerv Syst** **16**:645–658, 2000
25. Rijken BF, den Ottelander BK, van Veelen ML, Lequin MH, Mathijssen IM: The occipitofrontal circumference: reliable prediction of the intracranial volume in children with syndromic and complex craniosynostosis. **Neurosurg Focus** **38**(5):E9, 2015
26. Rijken BF, Lequin MH, van der Lijn F, van Veelen-Vincent ML, de Rooi J, Hoogendam YY, et al: The role of the posterior fossa in developing Chiari I malformation in children with craniosynostosis syndromes. **J Craniomaxillofac Surg** **43**:813–819, 2015
27. Rijken BF, Lequin MH, Van Veelen ML, de Rooi J, Mathijssen IM: The formation of the foramen magnum and its role in developing ventriculomegaly and Chiari I malformation in children with craniosynostosis syndromes. **J Craniomaxillofac Surg** **43**:1042–1048, 2015
28. Smith BW, Strahle J, Bapuraj JR, Muraszko KM, Garton HJ, Maher CO: Distribution of cerebellar tonsil position: implications for understanding Chiari malformation. **J Neurosurg** **119**:812–819, 2013
29. Spruijt B, Joosten KF, Driessen C, Rizopoulos D, Naus NC, van der Schroeff MP, et al: Algorithm for the management of intracranial hypertension in children with syndromic craniosynostosis. **Plast Reconstr Surg** **136**:331–340, 2015
30. Spruijt B, Mathijssen IM, Bredero-Boelhouwer HH, Cherian PJ, Corel LJ, van Veelen ML, et al: Sleep architecture linked to airway obstruction and intracranial hypertension in children with syndromic craniosynostosis. **Plast Reconstr Surg** **138**:1019e–1029e, 2016
31. Spruijt B, Rijken BF, den Ottelander BK, Joosten KF, Lequin MH, Loudon SE, et al: First vault expansion in Apert and Crouzon-Pfeiffer syndromes: front or back? **Plast Reconstr Surg** **137**:112e–121e, 2016
32. Tamburrini G, Caldarelli M, Massimi L, Santini P, Di Rocco C: Intracranial pressure monitoring in children with single suture and complex craniosynostosis: a review. **Childs Nerv Syst** **21**:913–921, 2005
33. Thomas GP, Wilkie AO, Richards PG, Wall SA: FGFR3 P250R mutation increases the risk of reoperation in apparent 'nonsyndromic' coronal craniosynostosis. **J Craniomaxillofac Surg** **16**:347–354, 2005
34. Wenner Y, Brauer V, Kunze K, Besgen V, Kuhli-Hattenbach C, Bertelmann T, et al: Comparison of optic disc parameters in hyperopic and emmetropic eyes of healthy children with HRT and OCT. **Klin Monbl Augenheilkd** **235**:1129–1137, 2017
35. Wright KW, Spiegel PH, Thompson L (eds): **Handbook of Pediatric Strabismus and Amblyopia**. New York: Springer, 2006
36. Yanoff M, Duker JS: **Ophthalmology**, ed 5. Philadelphia: Elsevier, 2018

---

## Disclosures

The authors report no conflict of interest concerning the materials or methods used in this study or the findings specified in this paper.

## Author Contributions

Conception and design: den Ottelander, van Veelen, Lequin, Dremmen, Mathijssen. Acquisition of data: den Ottelander, de Goederen, van de Beeten, Lequin, Dremmen. Analysis and interpretation of data: all authors. Drafting the article: den Ottelander. Critically revising the article: den Ottelander, de Goederen, van Veelen, Mathijssen. Reviewed submitted version of manuscript: den Ottelander, Lequin, Dremmen, Loudon, Telleman, de Gier, Wolvius, Tjoa, Versnel, Joosten, Mathijssen. Approved the final version of the manuscript on behalf of all authors: den Ottelander. Statistical analysis: den Ottelander. Study supervision: van Veelen, Mathijssen.

## Correspondence

Bianca K. den Ottelander: Dutch Craniofacial Center, Sophia Children's Hospital–Erasmus University Medical Center, Rotterdam, the Netherlands. [b.denottelander@erasmusmc.nl](mailto:b.denottelander@erasmusmc.nl)