

# EUR Research Information Portal

## Predictors for Clinical Outcome of Untreated Stent Edge Dissections as Detected by Optical Coherence Tomography

**Published in:**

Circulation. Cardiovascular interventions

**Publication status and date:**

Published: 01/01/2020

**DOI (link to publisher):**

[10.1161/CIRCINTERVENTIONS.119.008685](https://doi.org/10.1161/CIRCINTERVENTIONS.119.008685)

**Document Version**

Publisher's PDF, also known as Version of record

**Citation for the published version (APA):**

Zandvoort, L., Tomaniak, M., Tovar Forero, M., Masdjedi, K., Visseren, L., Witberg, K., Ligthart, J., Kardys, I., Lemmert, M., Diletti, R., Wilschut, J., de Jaegere, P., Zijlstra, F., van Mieghem, N., & Daemen, J. (2020). Predictors for Clinical Outcome of Untreated Stent Edge Dissections as Detected by Optical Coherence Tomography. *Circulation. Cardiovascular interventions*, 13, e008685. <https://doi.org/10.1161/CIRCINTERVENTIONS.119.008685>

[Link to publication on the EUR Research Information Portal](#)

**Terms and Conditions of Use**

Except as permitted by the applicable copyright law, you may not reproduce or make this material available to any third party without the prior written permission from the copyright holder(s). Copyright law allows the following uses of this material without prior permission:

- you may download, save and print a copy of this material for your personal use only;
- you may share the EUR portal link to this material.

In case the material is published with an open access license (e.g. a Creative Commons (CC) license), other uses may be allowed. Please check the terms and conditions of the specific license.

**Take-down policy**

If you believe that this material infringes your copyright and/or any other intellectual property rights, you may request its removal by contacting us at the following email address: [openaccess.library@eur.nl](mailto:openaccess.library@eur.nl). Please provide us with all the relevant information, including the reasons why you believe any of your rights have been infringed. In case of a legitimate complaint, we will make the material inaccessible and/or remove it from the website.

## RESEARCH LETTER

# Predictors for Clinical Outcome of Untreated Stent Edge Dissections as Detected by Optical Coherence Tomography

Laurens J.C. van Zandvoort, BSc; Mariusz Tomaniak, MD, PhD; Maria Natalia Tovar Forero, MD; Kaneshka Masdjedi, MD; Lisanne Visseren, BSc; Karen Witberg, RN; Jurgen Ligthart, RT; Isabella Kardys, MD, PhD; Miguel E. Lemmert, MD, PhD; Roberto Diletti, MD, PhD; Jeroen Wilschut, MD; Peter de Jaegere, MD, PhD; Felix Zijlstra, MD, PhD; Nicolas M. Van Mieghem, MD, PhD; Joost Daemen, MD, PhD

**S**tent implantation for the treatment of coronary artery disease can cause unintended tearing at of vessel wall adjacent to the stent struts resulting in a stent edge dissection (SED). At present, limited data is available on the exact optical coherence tomography (OCT) characteristics of SEDs that might warrant further treatment. Given this background, we aimed to study the morphometric features and impact of untreated SEDs on clinical outcomes and assess dissection healing.

We retrospectively identified 295 untreated SEDs in 261 patients from a dedicated local database containing all OCT recordings from January 2009 to August 2017. Patients were eligible in case they underwent a percutaneous coronary intervention with stent implantation and postprocedural OCT evaluation. SEDs were defined as tearing of the vessel luminal surface within 5 mm of the proximal or distal stent border. Selected pullbacks with untreated SEDs were quantitatively analyzed using dedicated software (Rubo DICOM viewer 2.0; Rubo Medical Imaging, Aerdenhout, the Netherlands).

The plaque type at the site of the SED was categorized into fibrous, fibroatheroma, lipid or necrotic core, superficial calcium, or deep calcium. The following morphometric characteristics of each dissection were measured: longitudinal length, circumferential extension, cavity depth, maximal thickness of the dissection flap, minimal lumen area and area stenosis in the SED, dissection area and reference lumen area. The severity of each dissection was further characterized based on its extend to either subintimal or submedial and the presence of an

intramural hematoma or thrombus.<sup>1</sup> Finally, in the subset of 51 patients (53 SEDs) with follow-up OCT imaging, the presence of late persisting SEDs on OCT was evaluated stratified per follow-up timeframe, (1–7 days, 7 days–6 months, 6–12 months and >1 year). The primary end point of the study was a device-oriented composite end point (DOCE) at 1 year, defined as a composite of cardiac death, target lesion myocardial infarction, or target lesion revascularization. To evaluate independent predictors for DOCE at follow-up, all patients, vessel, and SED characteristics were first tested univariably using a Cox proportional hazards model, which accounted for the multilevel nature of the data. Subsequently, variables with a  $P < 0.05$  were inserted into the model. For the stratified analysis of distal and proximal SEDs, only univariate hazard ratios were examined since not enough events occurred for a multivariable analysis. The data and analytical methods used in this study will be not made available. The study was approved by the institutional review committee of the Erasmus Medical Centre, and all subjects gave informed consent.

The study population consisted of 71% males, 22% of the patients had diabetes mellitus, and 25% presented with an ST-segment-elevation myocardial infarction. The overall median SED length was  $2.0 \pm (1.4-3.0)$  mm with a median angle of  $54 \pm (34-92)^\circ$ . The minimal lumen areas in the proximal and distal SEDs were  $6.4 \pm (4.5-8.3)$  mm<sup>2</sup> and  $4.3 \pm (3.1-5.8)$  mm<sup>2</sup>, respectively. Clinical follow-up was available for 89% of the patients, and at 1 year, the cumulative incidence of the DOCE was 6.7%. Only SED

**Key Words:** coronary artery disease ■ myocardial infarction ■ optical coherence tomography ■ percutaneous coronary intervention ■ stent

Correspondence to: Joost Daemen, MD, PhD, Department of Cardiology, Room Rg-628, Erasmus University Medical Center, PO Box 2040, 3000 CA Rotterdam, the Netherlands. Email [j.daemen@erasmusmc.nl](mailto:j.daemen@erasmusmc.nl)

For Sources of Funding and Disclosures, see page 3.

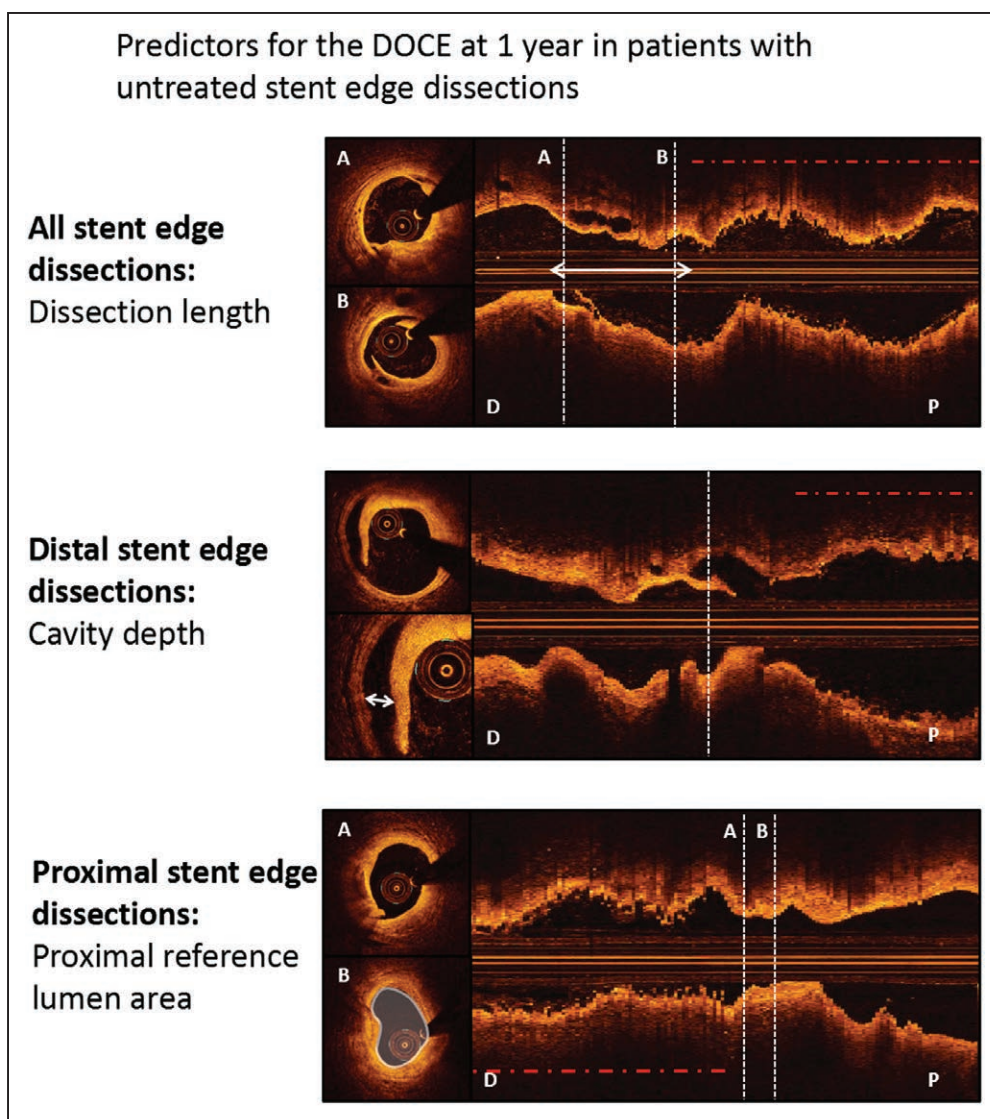
© 2020 American Heart Association, Inc.

*Circulation: Cardiovascular Interventions* is available at [www.ahajournals.org/journal/circinterventions](http://www.ahajournals.org/journal/circinterventions)

length (adjusted hazard ratio, 1.17 [95% CI, 1.02–1.34]) was associated with an increased risk of DOCE. For distal SEDs, cavity depth in mm was the only predictor of 1-year DOCE (hazard ratio, 1.029 [95% CI, 1.012–1.047]), whereas reference area in mm<sup>2</sup> (adjusted hazard ratio, 0.63 [95% CI, 0.45–0.87]) was the only predictor for 1-year DOCE in patients with proximal SEDs (Figure).

Within the first week, postprocedure, all (8/8) of the SEDs were still visible on OCT. Between 1 week and 6 months, SEDs remained visible in up to 15% (2/13), whereas between 6 and 12 months, 16% (3/19) were still visible. No remaining SEDs were visible after 1 year (median follow-up 22 months; 0/13).

The incidence of the DOCE in the present study was significantly lower as compared to previous studies reporting on the outcome of patients with SEDs.<sup>2–4</sup> The latter might be due to an overall lower risk of the present study population and follow-up truncation at 1 year. The CLI-OPCI ACS (Clinical Impact of Suboptimal Stenting and Residual Intrastent Plaque/Thrombus Protrusion in Patients With Acute Coronary Syndrome) and CLI-OPCI II used an arbitrary cutoff for flap thickness of 0.20 mm and found this to be a significant predictor for DOCE.<sup>2,3</sup> In contrast, we found dissection length (best cut-off for DOCE at 3.55 mm) to be the only independent predictor of the DOCE at 1 year. Almost 85% of the SEDs were



**Figure. Independent morphometric predictors of device-oriented clinical end point (DOCE) at 1 y in patient with stent edge dissections detected by optical coherence tomography.**

**Upper:** Dissection length is an independent predictor for DOCE at 1 y in all stent edge dissections (SED), cross-section A and B refer to the corresponding location on the longitudinal view. The combination of highest sensitivity and specificity for SED length indicated that the best cut-off for DOCE at 1 y was at 3.55 mm (Youden index=0.22, area under the curve=0.56). D and P denote distal and proximal, respectively.

**Middle:** Cavity depth is an independent predictor for DOCE at 1 y for distal SEDs, the cross-sections correspondent to the dashed line on the longitudinal view. **Lower:** Proximal reference lumen area is an independent predictor for DOCE at 1 y for proximal SEDs, cross-section A and B refer to the corresponding location on the longitudinal view. Cross-section B denotes the proximal reference lumen area in white. The red dash-dot lines denote the stented segment.

no longer visible at 6 months, whereas after 1 year, none of them were still visible. The latter is in line with previous research reporting SEDs were still visible in 10% of cases at 12 months follow-up.<sup>5</sup>

In conclusion, this is the largest cohort of patients with SEDs to date, demonstrating a 6.7% risk of 1-year cardiac events potentially linked to untreated dissections. In patients with SEDs, dissection length, cavity depth, and proximal reference area were identified as predictors of the DOCE.

## ARTICLE INFORMATION

### Affiliations

Department of Cardiology, Erasmus MC, Rotterdam, the Netherlands (L.J.C.v.Z., M.T., M.N.T.F., K.M., L.V., K.W., J.L., I.K., M.E.L., R.D., J.W., P.d.J., F.Z., N.M.V.M., J.D.). First Department of Cardiology, Medical University of Warsaw, Poland (M.T.).

### Disclosures

Dr Daemen received institutional grant/research support from Astra Zeneca, Abbott Vascular, Boston Scientific, Acist Medical, Medtronic, Pie Medical, ReCor Medical, and PulseCath, and consultancy and speaker fees from Acist Medical, Boston Scientific, ReCor Medical, Pie Medical, Medtronic, and Pulse Cath. The other authors report no disclosures.

## REFERENCES

1. Tearney GJ, Regar E, Akasaka T, Adriaenssens T, Barlis P, Bezerra HG, Bouma B, Bruining N, Cho JM, Chowdhary S, et al; International Working Group for Intravascular Optical Coherence Tomography (IWG-IVOC). Consensus standards for acquisition, measurement, and reporting of intravascular optical coherence tomography studies: a report from the International Working Group for intravascular optical coherence tomography standardization and validation. *J Am Coll Cardiol*. 2012;59:1058–1072. doi: 10.1016/j.jacc.2011.09.079
2. Prati F, Romagnoli E, Burzotta F, Limbruno U, Gatto L, La Manna A, Versaci F, Marco V, Di Vito L, Imola F, et al. Clinical impact of OCT findings during PCI: the CLI-OPCI II Study. *JACC Cardiovasc Imaging*. 2015;8:1297–1305. doi: 10.1016/j.jcmg.2015.08.013
3. Prati F, Romagnoli E, Gatto L, La Manna A, Burzotta F, Limbruno U, Versaci F, Fabbicchi F, Di Giorgio A, Marco V, et al. Clinical impact of suboptimal stenting and residual intrastent plaque/thrombus protrusion in patients with acute coronary syndrome: the CLI-OPCI ACS substudy (centro per la lotta contro l'infarto-optimization of percutaneous coronary intervention in acute coronary syndrome). *Circ Cardiovasc Interv*. 2016;9:e003726. doi: 10.1161/CIRCINTERVENTIONS.115.003726
4. Chamié D, Bezerra HG, Attizzani GF, Yamamoto H, Kanaya T, Stefano GT, Fujino Y, Mehanna E, Wang W, Abdul-Aziz A, et al. Incidence, predictors, morphological characteristics, and clinical outcomes of stent edge dissections detected by optical coherence tomography. *JACC Cardiovasc Interv*. 2013;6:800–813. doi: 10.1016/j.jcin.2013.03.019
5. Radu MD, Råber L, Heo J, Gogas BD, Jørgensen E, Kelbæk H, Muramatsu T, Farooq V, Helqvist S, Garcia-Garcia HM, et al. Natural history of optical coherence tomography-detected non-flow-limiting edge dissections following drug-eluting stent implantation. *EuroIntervention*. 2014;9:1085–1094. doi: 10.4244/EIJV9I9A183