

EUR Research Information Portal

Immersive virtual reality surgical planning of minimally invasive coronary artery bypass for Kawasaki disease

Published in:
European Heart Journal

Publication status and date:
Published: 01/01/2020

DOI (link to publisher):
[10.1093/eurheartj/ehaa518](https://doi.org/10.1093/eurheartj/ehaa518)

Document Version
Publisher's PDF, also known as Version of record

Citation for the published version (APA):
Sadeghi, H., Taverne, Y., Bogers, A., & Mahtab, E. (2020). Immersive virtual reality surgical planning of minimally invasive coronary artery bypass for Kawasaki disease. *European Heart Journal*, 41(34), 3279-3279.
<https://doi.org/10.1093/eurheartj/ehaa518>

[Link to publication on the EUR Research Information Portal](#)

Terms and Conditions of Use

Except as permitted by the applicable copyright law, you may not reproduce or make this material available to any third party without the prior written permission from the copyright holder(s). Copyright law allows the following uses of this material without prior permission:

- you may download, save and print a copy of this material for your personal use only;
- you may share the EUR portal link to this material.

In case the material is published with an open access license (e.g. a Creative Commons (CC) license), other uses may be allowed. Please check the terms and conditions of the specific license.

Take-down policy

If you believe that this material infringes your copyright and/or any other intellectual property rights, you may request its removal by contacting us at the following email address: openaccess.library@eur.nl. Please provide us with all the relevant information, including the reasons why you believe any of your rights have been infringed. In case of a legitimate complaint, we will make the material inaccessible and/or remove it from the website.



- coronary contrast-flow quantitative flow ratio. *J Am Coll Cardiol* 2019;**123**: 1722–1728.
38. Smits PC, Abdel-Wahab M, Neumann F-J, Boxma-de Klerk BM, Lunde K, Schotborgh CE, Piroth Z, Horak D, Wlodarczak A, Ong PJ, Hambrecht R, Angeräs O, Richardt G, Omerovic E. Fractional flow reserve-guided multivessel angioplasty in myocardial infarction. *N Engl J Med* 2017;**376**: 1234–1244.
39. Pijls NH, Klauss V, Siebert U, Powers E, Takazawa K, Fearon WF, Escaned J, Tsurumi Y, Akasaka T, Samady H, De Bruyne B. Coronary pressure measurement after stenting predicts adverse events at follow-up: a multicenter registry. *Circulation* 2002;**105**:2950–2954.
40. Fournier S, Ciccirelli G, Toth GG, Milkas A, Xaplanteris P, Tonino PAL, Fearon WF, Pijls NHJ, Barbato E, De Bruyne B. Association of improvement in fractional flow reserve with outcomes, including symptomatic relief, after percutaneous coronary intervention. *JAMA Cardiol* 2019;**4**:370–374.
41. Agarwal SK, Kasula S, Hacıoglu Y, Ahmed Z, Uretsky BF, Hakeem A. Utilizing post-intervention fractional flow reserve to optimize acute results and the relationship to long-term outcomes. *JACC Cardiovasc Interv* 2016;**9**:1022–1031.

CARDIOVASCULAR FLASHLIGHT

doi:10.1093/eurheartj/ehaa518

Online publish-ahead-of-print 8 July 2020

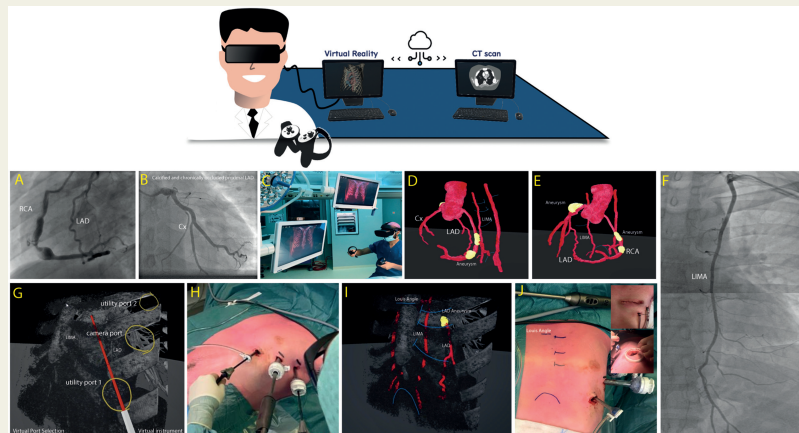
Immersive virtual reality surgical planning of minimally invasive coronary artery bypass for Kawasaki disease

Amir H. Sadeghi *, Yannick J. H. J. Taverne, Ad J. J. C. Bogers , and Edris A. F. Mahtab

Department of Cardiothoracic Surgery, Thoraxcenter, Erasmus Medical Center Rotterdam, Room Rg-635, PO Box 2040, 3015 GD Rotterdam, The Netherlands

*Corresponding author. Tel: +31 10 7035411, Email: h.sadeghi@erasmusmc.nl

We present the rendering of a computed tomography (CT) scan in an immersive virtual reality (VR) environment for reviewing anatomy and preoperative planning of minimally invasive direct coronary artery bypass (MIDCAB). An 18-year-old man with a history of Kawasaki disease and associated left anterior descending (LAD) and right coronary artery (RCA) aneurysms, was referred to our multidisciplinary heart meeting to evaluate the necessity of coronary revascularization. The patient had no complaints, the electrocardiogram was normal and echocardiogram showed no resting regional wall motion abnormalities. Stress cardiac magnetic resonance imaging established subendocardial hypoperfusion defects in the LAD region without signs of myocardial fibrosis. A coronary angiography revealed a proximally calcified aneurysm and an occlusion of the LAD with collateral retrograde filling from the RCA and no abnormalities in the left circumflex (Cx) artery (Panels A and B, [Supplementary material online, Videos S1 and S2](#)). Aneurysm formation of the left internal mammary artery (LIMA) was ruled out with angiography (Panel F). The patient was accepted for MIDCAB, LIMA to LAD coronary revascularization. To prepare for surgery, reconstructions of a CT scan were made by rendering 3D-VR images on our MedicalVR workstation (MedicalVR, Amsterdam, The Netherlands) (Panel C). An interactive reconstruction of the CT scan was made that enabled immersive-360° review of coronary anatomy in a head-mounted VR device (Panels D and E, [Supplementary material online, Video S3](#)). In addition, immersive VR was used to plan for the insertion location of thoracoscopic ports (for LIMA harvesting) and for determining the ideal location for anterior mini-thoracotomy (Panels G–J, [Supplementary material online, Videos S4–S6](#)) and direct off-pump MIDCAB using soft-tissue retractor. Cx, left circumflex artery; LAD, left anterior descending; LIMA, left internal mammary artery; RCA, right coronary artery.



[Supplementary material](#) is available at *European Heart Journal* online.

© The Author(s) 2020. Published by Oxford University Press on behalf of the European Society of Cardiology.

This is an Open Access article distributed under the terms of the Creative Commons Attribution Non-Commercial License (<http://creativecommons.org/licenses/by-nc/4.0/>), which permits non-commercial re-use, distribution, and reproduction in any medium, provided the original work is properly cited. For commercial re-use, please contact journals.permissions@oup.com