

EUR Research Information Portal

Pressure-Volume Loop Analysis in Percutaneous Coronary Intervention-Induced Shock

Published in:
JACC: Case Reports

Publication status and date:
Published: 01/01/2020

DOI (link to publisher):
[10.1016/j.jaccas.2020.07.026](https://doi.org/10.1016/j.jaccas.2020.07.026)

Document Version
Publisher's PDF, also known as Version of record

Citation for the published version (APA):
Dedic, A., Bastos, MB., & van Mieghem, N. (2020). Pressure-Volume Loop Analysis in Percutaneous Coronary Intervention-Induced Shock. *JACC: Case Reports*, 2(12), 1882-1883. <https://doi.org/10.1016/j.jaccas.2020.07.026>

[Link to publication on the EUR Research Information Portal](#)

Terms and Conditions of Use

Except as permitted by the applicable copyright law, you may not reproduce or make this material available to any third party without the prior written permission from the copyright holder(s). Copyright law allows the following uses of this material without prior permission:

- you may download, save and print a copy of this material for your personal use only;
- you may share the EUR portal link to this material.

In case the material is published with an open access license (e.g. a Creative Commons (CC) license), other uses may be allowed. Please check the terms and conditions of the specific license.

Take-down policy

If you believe that this material infringes your copyright and/or any other intellectual property rights, you may request its removal by contacting us at the following email address: openaccess.library@eur.nl. Please provide us with all the relevant information, including the reasons why you believe any of your rights have been infringed. In case of a legitimate complaint, we will make the material inaccessible and/or remove it from the website.

MINI-FOCUS ISSUE: INTERVENTIONAL CARDIOLOGY

INTERMEDIATE

IMAGING VIGNETTE: CLINICAL VIGNETTE

Pressure-Volume Loop Analysis in Percutaneous Coronary Intervention-Induced Shock



Admir Dedic, MD, PhD, Marcelo B. Bastos, MD, Nicolas M. Van Mieghem, MD, PhD

ABSTRACT

High-risk percutaneous coronary intervention may lead to undesirable clinical scenarios such as cardiogenic shock. We describe the hemodynamic changes using pressure-volume loop analyses in percutaneous coronary intervention-induced shock. (PULsecath mechanical Support Evaluation [PULSE]; [NCT03200990](https://clinicaltrials.gov/ct2/show/study/NCT03200990)) (**Level of Difficulty: Intermediate.**) (J Am Coll Cardiol Case Rep 2020;2:1882-3) © 2020 The Authors. Published by Elsevier on behalf of the American College of Cardiology Foundation. This is an open access article under the CC BY-NC-ND license (<http://creativecommons.org/licenses/by-nc-nd/4.0/>).

A 66-year-old male with no known cardiovascular disease was admitted after successful cardiopulmonary resuscitation following out-of-hospital cardiac arrest. Echocardiography showed poor left ventricular (LV) function without significant valve disease. Coronary angiography revealed chronic total occlusions of the right and left circumflex coronary arteries, and a complex, heavily calcified bifurcation lesion of the left anterior descending (LAD) coronary artery (**Figure 1**, right panel). Cardiac magnetic resonance imaging confirmed severely reduced LV ejection fraction of 28% but myocardial viability in all segments. There was heart team consensus for high-risk percutaneous coronary intervention under mechanical circulatory support.

A pulsatile LV assist device (model iVAC2L, PulseCath BV, Amsterdam, the Netherlands) was implanted through right femoral access. Invasive LV pressure-volume loops and pulmonary artery pressures were recorded as part of a research protocol (PULSE [PULsecath mechanical Support Evaluation]). Following balloon inflation in the LAD, progressive hemodynamic deterioration ensued (**Figure 1**, red/brown loops). The pressure-volume loop shifted further to the right with markedly reduced systolic and increased diastolic LV pressures resulting in a dramatic reduction in stroke volume. The patient developed bradycardia and severe hypotension (**Figure 1**, green loop), necessitating insertion of a temporary pacemaker. After initial recovery with vasopressor therapy, and upon continuation of the procedure, the patient developed refractory ventricular fibrillation. Cardiopulmonary resuscitation was initiated with effective chest compressions as illustrated by markedly increased systolic and lower diastolic pressures in combination with larger stroke volume (**Figure 1**, gray/yellow loops). Escalation of mechanical circulatory support from the iVAC2L to the Impella CP (Abiomed, Danvers, Massachusetts) was ineffective, and ventricular fibrillation persisted despite multiple defibrillations. Eventually, venoarterial extracorporeal membrane oxygenation was initiated, enabling a successful percutaneous coronary intervention of the LAD while the patient remained in ventricular fibrillation, despite multiple

From the Department of Cardiology, Erasmus University Medical Center, Rotterdam, the Netherlands.

The authors attest they are in compliance with human studies committees and animal welfare regulations of the authors' institutions and Food and Drug Administration guidelines, including patient consent where appropriate. For more information, visit the *JACC: Case Reports* [author instructions page](#).

Manuscript received June 24, 2020; accepted July 7, 2020.

attempts of electrical defibrillation. After LAD revascularization, sinus rhythm was restored successfully. The patient was transferred to the intensive care unit for further recovery.

AUTHOR RELATIONSHIP WITH INDUSTRY

Dr. Bastos has received personal fees from PulseCath BV, outside the submitted work. Dr. Van Mieghem has received grants and personal fees from PulseCath BV, personal fees from Abiomed, during the conduct of the study. All other authors have reported that they have no relationships relevant to the contents of this paper.

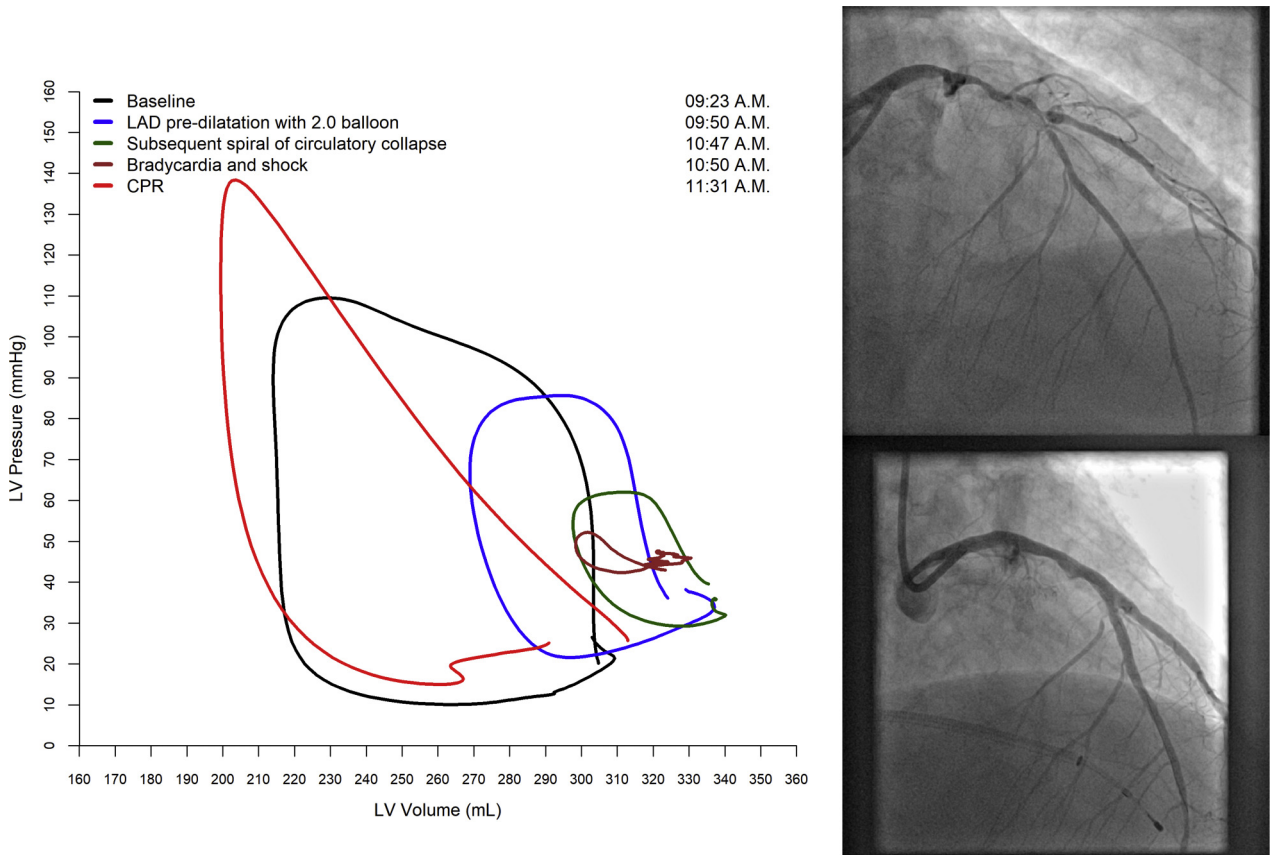
ABBREVIATIONS AND ACRONYMS

- ICU = intensive care unit
- LAD = left anterior descending coronary artery
- LV = left ventricle

ADDRESS FOR CORRESPONDENCE: Dr. Admir Dedic, Erasmus University Medical Center, Dr. Molewaterplein 40, 3015 GD, Room Rg-624, Rotterdam, the Netherlands. E-mail: a.dedic@erasmusmc.nl.

KEY WORDS cardiac assist devices, hemodynamics, percutaneous coronary intervention

FIGURE 1 Pressure-Volume Loops Show Subsequent Changes During Complicated High-Risk PCI



(Left) Pressure-volume loops show subsequent changes during complicated high-risk percutaneous coronary intervention (PCI). **(Right) (Top)** Angiographic right superior oblique view of the LAD prior and **(bottom)** after PCI. CPR = cardiopulmonary resuscitation; LAD = left anterior descending coronary artery.