

ORIGINAL RESEARCH ARTICLE

A multicenter observational survey of management strategies in 442 pregnancies with suspected placenta accreta spectrum

Heleen J. van Beekhuizen¹  | Vedran Stefanovic²  | Alexander Schwickert³  | Wolfgang Henrich³  | Karin A. Fox⁴  | Mina MHallem Gziri⁵  | Loïc Sentilhes⁶  | Lene Gronbeck⁷  | Frederic Chantraine⁸  | Oliver Morel^{9,10}  | Charline Bertholdt^{9,10}  | Thorsten Braun³  | Marcus J. Rijken¹¹  | Johannes J. Duvekot¹²  | the International Society of Placenta Accreta Spectrum (IS-PAS) group

¹Department of Gynecological Oncology, Erasmus MC Cancer Institute, Rotterdam, the Netherlands

²Department of Obstetrics and Gynecology, Fetomaternal Medical Center, Helsinki University Hospital and University of Helsinki, Helsinki, Finland

³Department of Obstetrics and Department of Experimental Obstetrics, Charité – Universitätsmedizin Berlin, Corporate Member of Freie Universität Berlin, Humboldt-Universität zu Berlin, Berlin Institute of Health, Berlin, Germany

⁴Division of Maternal-Fetal Medicine, Department of Obstetrics and Gynecology, Baylor College of Medicine, Houston, TX, USA

⁵Department of Obstetrics, Cliniques Universitaires Saint-Luc, Brussels, Belgium

⁶Department of Obstetrics and Gynecology, Bordeaux University Hospital, Bordeaux, France

⁷Department of Obstetrics, Rigshospitalet Copenhagen University Hospital, Copenhagen, Denmark

⁸Department of Obstetrics and Gynecology, Centre Hospitalier Universitaire de Liège, Site CHR Citadelle, Liège, Belgium

⁹Nancy Regional and University Hospital Center (CHRU, Women's Division, Université de Lorraine, Nancy, France

¹⁰Diagnosis and International Adaptive Imaging (IADI) Unit, Inserm, Université de Lorraine, Nancy, France

¹¹Department of Obstetrics, Division Women and Baby, Julius Global Health, The Julius center for Health Sciences and Primary Care, University Medical center Utrecht, Utrecht University, Utrecht, the Netherlands

¹²Department of Obstetrics and Gynecology, Division of Obstetrics and Prenatal Medicine, Erasmus MC, University Medical center Rotterdam, Rotterdam, the Netherlands

Correspondence

Heleen J. van Beekhuizen, Department of Gynecological Oncology, Erasmus Medical Center, Dr Molewaterplein 40, 3015 GD Rotterdam, the Netherlands.
Email: h.vanbeekhuizen@erasmusmc.nl

Funding information

Vedran Stefanovic was supported by a research grant (Y1017N0203) from Helsinki University and Helsinki University Hospital, Finland.

Abstract

Introduction: Management options for women with placenta accreta spectrum (PAS) comprise termination of pregnancy before the viable gestational age, leaving the placenta in situ for subsequent reabsorption of the placenta or delayed hysterectomy, manual removal of placenta after vaginal delivery or during cesarean section, focal resection of the affected uterine wall, and peripartum hysterectomy. The aim of this observational study was to describe actual clinical management and outcomes in PAS in a large international cohort.

Material and methods: Data from women in 15 referral centers of the International Society of PAS (IS-PAS) were analyzed and correlated with the clinical classification of the IS-PAS: From Grade 1 (no PAS) to Grade 6 (invasion into pelvic organs other than

Abbreviations: IS-PAS, International Society of Placenta Accreta Spectrum; PAS, placenta accreta spectrum.

International Society of Placenta Accreta Spectrum (IS-PAS) group are listed in Appendix 1.

This is an open access article under the terms of the Creative Commons Attribution-NonCommercial License, which permits use, distribution and reproduction in any medium, provided the original work is properly cited and is not used for commercial purposes.

© 2021 The Authors. *Acta Obstetrica et Gynecologica Scandinavica* published by John Wiley & Sons Ltd on behalf of Nordic Federation of Societies of Obstetrics and Gynecology (NFOG).

the bladder). PAS was usually diagnosed antenatally and the operators performing ultrasound rated the likelihood of PAS on a Likert scale of 1 to 10.

Results: In total, 442 women were registered in the database. No maternal deaths occurred. Mean blood loss was 2600 mL (range 150-20 000 mL). Placenta previa was present in 375 (84.8%) women and there was a history of a previous cesarean in 329 (74.4%) women. The PAS likelihood score was strongly correlated with the PAS grade ($P < .001$). The mode of delivery in the majority of women ($n = 252$, 57.0%) was cesarean hysterectomy, with a repeat laparotomy in 20 (7.9%) due to complications. In 48 women (10.8%), the placenta was intentionally left in situ, of those, 20 (41.7%) had a delayed hysterectomy. In 26 women (5.9%), focal resection was performed. Termination of pregnancy was performed in 9 (2.0%), of whom 5 had fetal abnormalities. The placenta could be removed in 90 women (20.4%) at cesarean, and in 17 (3.9%) after vaginal delivery indicating mild or no PAS. In 34 women (7.7%) with an antenatal diagnosis of PAS, the placenta spontaneously separated (false positives). We found lower blood loss ($P < .002$) in 2018-2019 compared with 2009-2017, suggesting a positive learning curve.

Conclusions: In referral centers, the most common management for severe PAS was cesarean hysterectomy, followed by leaving the placenta in situ and focal resection. Prenatal diagnosis correlated with clinical PAS grade. No maternal deaths occurred.

KEYWORDS

abnormal invasive placenta, cesarean section, placenta accreta spectrum, postpartum hemorrhage

1 | INTRODUCTION

Placenta accreta spectrum (PAS), also called abnormally invasive placenta (AIP), is a "spectrum disorder" that ranges from abnormally adherent to deeply invasive placental tissue. Even though PAS remains relatively rare (0.79-3.11 per 1000 births after prior cesarean),¹ PAS is the most common reason for peripartum hysterectomy and contributes to maternal deaths in low- and high-income countries. Maternal morbidity and mortality from PAS are disproportionately high in low-resource regions. Antenatal recognition of PAS is crucial for multidisciplinary planning, as it facilitates referral to a Center of Excellence, which reduces maternal mortality and morbidity.²⁻⁶

Management options for PAS are:

- Conservative management, intentionally leaving the placenta in situ⁷: after delivery, no effort is made to remove the placenta; the placenta is left in situ for either spontaneous reabsorption (ie for fertility-sparing management)⁸ or planned delayed hysterectomy (an option often used in placenta percreta with the aim of reducing surgical complexity).
- Cesarean hysterectomy: a fundal uterine incision is made to deliver the neonate, the cord is tied off, the placenta left undisturbed, the uterus is closed and a hysterectomy performed.⁹ This procedure can be combined with preoperative insertion of ureteral catheters for easy identification and/or placement of intravascular balloons

Key message

Placenta accreta spectrum was mostly managed by cesarean hysterectomy. Focal resection and leaving the placenta in situ were alternative approaches. A multidisciplinary team in referral centers increases accuracy of the diagnosis, and subsequent management by experts reduces morbidity.

in an attempt to reduce blood loss. Total hysterectomy is necessary if there is cervical invasion but supracervical hysterectomy may be appropriate if hemostasis is achievable in non-affected cervical tissue.

- Focal resection of the uterine wall (for a focal PAS): at cesarean the transverse incision in the uterine wall is placed cranially above the abnormally invasive part of the placenta and the baby is delivered. The placenta and affected myometrium are then removed and the uterus is closed.¹⁰
- Termination of pregnancy: considered for early PAS or concurrent fetal anomalies. Induction of labor and manual removal of the placenta may be attempted for placenta accreta but often a hysterectomy (en bloc), focal resection or conservative management is performed.¹¹

- Extirpative management: manual placental removal during cesarean or vaginal deliveries in the mildest cases of PAS. For this management strategy to be successful, there must be a reasonably thick myometrium, which can contract to stop the bleeding from the placental bed.

Lack of good quality data hampers a consensual guideline in management of PAS. The aim of this observational study was to describe the actual clinical management and outcomes in PAS across participating centers of the International Society of Placenta Accreta Spectrum (IS-PAS); All of these centers are regarded as referral centers.

2 | MATERIAL AND METHODS

Details of centers, women, PAS grading and the database are described in a report on the material and methods used.¹² The IS-PAS database contains both retrospectively and prospectively collected obstetric and surgical data from pregnant women >14 gestational weeks with suspected or clinically proven PAS. Data entry was completed by obstetricians and gynecologists from the IS-PAS (formerly the IS-AIP). Fourteen European and one non-European center (USA) provided cases collected retrospectively between 2008 and 2014 and prospectively from 2014 to 2019 in the FetView database. A data analysis core group was established consisting of five IS-PAS members from four centers, this group conducted the data extraction and quality control.

The IS-PAS clinical classification system¹³ (which was the basis for the subsequent FIGO classification system¹⁴) was used to grade the severity of PAS.¹² Data collection included patient demographics and obstetric history. The likelihood of PAS as predicted by antenatal imaging was scored by expert operators (usually perinatologists) after ultrasound and/or MRI imaging from 1 (unlikely) to 10 (very likely). The routes of delivery for all prior pregnancies and the index (PAS) pregnancies were recorded. In cases managed conservatively or with uterine-sparing surgery, placental management was documented, including whether the placenta was partially or completely removed, left in situ or additional surgeries were required. Cesarean hysterectomy was documented when definitive surgical management was chosen as the planned treatment strategy. Complications including bleeding, blood transfusion, infection, bladder or bowel injuries, and admission to intensive care unit were noted.

2.1 | Statistical analyses

Statistical analysis of management was descriptive. No comparative group was used.

The relationship between the certainty of PAS as scored on a Likert scale (1-10) by imaging experts and the clinical PAS grade at delivery was compared using the Chi-square test. A level of $P < .05$ was considered to be significant. The percentage of false-positive

PAS was calculated by dividing the number of women with a PAS score of 2 and more and spontaneous separating placentas, by all women with PAS score or more recorded in the database. Data on blood loss and blood transfusion were reported as mean, median and interquartile range. A Mann-Whitney U test was performed to compare data on blood loss in 2009-2017 and in 2018-2019 to detect a learning curve in the referral centers; a level of $P < .05$ was considered to be significant. We chose this cut-off because the IS-PAS published management guidelines in 2018,¹⁵ after which each center adjusted their management accordingly.

2.2 | Ethical approval

All participating centers were responsible for contributing to clinical and scientific research under local IRB/ethics committee approval and operated under Data Use Agreements between individual centers and the IS-PAS. Details of these can be found in the Table S1 contained in the second Commentary of this supplement.¹²

3 | RESULTS

3.1 | Population

There were 442 cases registered in the database. Parity and number of previous cesareans are described in Table 1. The mode of delivery in pregnancies immediately preceding index pregnancies was cesarean section in 329 (74.4%) women. In all, 166 (37.6%) women had previous intrauterine procedures other than cesarean delivery. There were 28 cases of previous retained placenta and 10 of previous PAS. Thirty-nine (8.8%) women had neither any prior caesarean nor a history of intrauterine surgery. The PAS grades of these 39 women were: 3 with grade 1, 17 with grade 2, 9 with grade 3, 6 with grade 4, 4 with grade 5, and 0 with grade 6.

TABLE 1 Number of previous pregnancies and number of previous cesarean sections in 442 women

Parity	Number of previous pregnancies		Number of previous caesareans		
	n	%	n	%	
0	43	9.7	0	84	19.0
1	152	34.4	1	176	39.8
2	129	29.2	2	105	23.8
3	66	14.9	3	46	10.4
4	32	7.2	4	23	5.2
5	12	2.7	5	7	1.6
6	8	1.8	6	1	0.2
Total	442	100.0	Total	442	100.0

3.2 | Index (PAS) pregnancy

At delivery, 375 women (84.8%) had placenta previa, of whom 282 (63.8%) had complete placenta previa (covering the cervical ostium). We used the ISUOG classification for placenta previa¹⁶: in 24 women (5.4%) the placenta previa was low-lying (>2 cm from internal OS), in 33 women (7.5%) marginal (0–2 cm from internal OS), and in 21 women (4.8%) partial (edge of placenta covering internal OS). In four women, the grade of placenta previa was not recorded. In 312 (70.6%) women, the placenta was lying over a previous scar (Table 2).

In 385 women (87.1%) the diagnosis of PAS was made antenatally by ultrasound or MRI. Imaging details are published separately.¹⁷ Imaging experts scored the likelihood that significant PAS was present at the time of imaging in 414 women (0 = unlikely, 10 = very likely) (Figure 2).

3.3 | Delivery and management

The most commonly planned mode of delivery was cesarean ($n = 397$, 89.9%). Cesarean delivery ($n = 397$) was performed by experienced obstetrician-gynecologists: in 311 (74.8%) a PAS expert was present, in 83 (20.0%) a senior doctor, and in 7 (1.6%) a junior doctor only (these data were missing from 15 cases, 3.6%). The urgency of the surgery was graded as follows: 20 cesareans (4.8%) were indicated as immediate/emergent (<30 minutes), 59 (14.2%) as urgent (<60 minutes), 60 (14.4%) as semi-urgent (<2 hours), 274 (65.9%) as elective, and in 3 (0.7%) the urgency was not recorded. In 115 women (27.6%), only regional anesthesia was used and in 143 (34.3%) only general anesthesia was used. In 150 women (36.1%), anesthesia started with regional techniques and was converted to general anesthesia; in eight women (2.0%), no mode of analgesia was recorded. The uterine incision was low transverse in 127 (30.5%), fundal in 188 (45.2%), "other" (eg J-shape) in 83 (20.0%), and not recorded in 18 (4.3%).

In total, 27 (6.1%) women planned a vaginal delivery. Nine (2.0%) women had a termination of pregnancy before viability. Planned delivery mode was missing in nine women (2.0%). Table 2 details

management method in relation to placental location. Information about blood loss, blood transfusion and complications are outlined in Table 3. Table 4 describes the distribution of clinical grade of PAS based on treatment strategy.

Of the 27 women who planned vaginal delivery, 17 (62.9%) were successful. Ten women delivered via cesarean. In Table S1, the management of PAS is described in relation to the different IS-PAS centers: all centers performed cesarean hysterectomy but techniques were practiced more heterogeneously: focal resection (between 0% and 26%) and leaving the placenta in situ (between 0% and 67%).

3.3.1 | Cesarean hysterectomy

Cesarean hysterectomy was performed in 252 women with a median blood loss of 2000 mL (range 450–20 000). In 188 women, the hysterectomy was planned, in 42 women the hysterectomy was unplanned, and in 22 women this was not recorded. Balloon occlusion (in iliac artery or aorta) was used in 57 women (12.9%). Incision was fundal in 137 women, lower transverse in 51, "other" in 52, and unknown in 12. Cystotomy or partial cystectomy and repair was required in 23 cases (9%).

The uterus was sent for histology in 207 women: 19 placenta accreta, 45 accreta with previa, 3 increta, 42 increta with previa, 17 percreta, and 81 percreta with previa.

3.3.2 | Placental extirpation/manual removal of placenta

In 90 women, the placenta was removed during cesarean and no cesarean hysterectomy was performed. After placental removal, local hemostasis was obtained with placental bed sutures, local hemostatic patches such as TachoSil®, chitosan impregnated gauze (Celox®) and other local measures. In this group, 32 false-positive cases of PAS were found (35.5%: grade 1) and 44 had mild (grade 2) PAS (46.6%).

TABLE 2 The grade of PAS in relation to localization of the placenta

Localization of the placenta in relation to management $n = 442$	Placenta overlying uterine scar			Placenta previa		
	Yes	No	NR	Yes	No	NR
Cesarean hysterectomy $n = 252$	202 (80.2%)	40 (15.9%)	10 (3.9%)	235 (93.3%)	16 (6.3%)	1 (0.4%)
Placenta removed, uterus in situ $n = 90$	46 (51.1%)	41 (45.6%)	3 (3.3%)	73 (81.1%)	17 (18.9%)	0
Placenta in situ $n = 48$	32 (66.7%)	15 (31.2%)	1 (2.1%)	40 (83.3%)	8 (16.7%)	0
Focal resection $n = 26$	22 (84.6%)	3 (11.5%)	1 (3.9%)	20 (76.9%)	6 (23.1%)	0
Vaginal delivery $n = 17$	3 (17.6%)	11 (64.7%)	3 (17.6%)	1 (5.9%)	15 (88.2%)	1 (5.9%)
Termination of pregnancy $n = 9$	7 (77.8%)	2 (22.2%)	0	6 (66.7%)	3 (33.3%)	0
Total ($n = 442$)	312 (70.6%)	112 (25.3%)	18 (4.1%)	375 (84.8%)	65 (14.7%)	2 (0.5%)

Abbreviation: NR, not recorded.

TABLE 3 Details of blood loss, blood transfusion and complications in 442 women

	Cesarean hysterectomy n = 252	Placenta extirpation/ manual removal n = 90	Placenta in situ n = 48	Focal resection at cesarean section n = 26	Vaginal delivery n = 17	Termination of pregnancy n = 9
Blood loss (mL)	range	450-20 000	150-10 000	500-7500	200-8000	100-5000
	interquartile range	1120-3500	500-3375	1175-2000	337-2400	800-3450
	median	2000	1500	2000	850	1500
	Data missing (n)	8	3	8	0	3
Red blood cells transfused (units)	range	0-34	0-15	0-10	4-18	0-10
	interquartile range	0-6	0-5	0-5	4-15	1-8
	median	3	1	5	6	4
	Data missing (n)	39	29	17	1	13
ICU admission	n (%)	107 (42.4%)	24 (26.6%)	8 (30.7%)	3	7
	Range (d)	1-56	1-32	1-2	1-3	1-3
	Median (d)	2	1	2	1	2
Salvage hysterectomy	n	N/A	0	0	2	5
	Bladder (n)	23	0	3	1	0
	Ureters (n)	6	0	0	0	0
Repeated surgery due to complications	Relaparotomy ^a (n)	20	1	0	0	1
	Uterine tamponade (n)	N/A	2	0	8	0
	Emergency embolization uterine arteries (n)	2	2	2	0	2
	Hysteroscopic resection or D&C (n)	N/A	4	8	1	6

^aRelaparotomy was performed due to bleeding (n = 12), ureter strictures (n = 3), ileus (n = 2), removal of drains (n = 2), vesicovaginal fistula (n = 2) and bowel injuries (n = 1).

TABLE 4 The grade of PAS in relation to management

Grading of PAS related to treatment n = 442	Grade 1 (no PAS)	Grade 2	Grade 3	Grade 4	Grade 5	Grade 6
Cesarean hysterectomy n = 252	1 (0.4%)	31 (12.3%)	52 (20.6%)	102 (40.5%)	42 (16.7%)	24 (9.5%)
Placenta removed, uterus in situ n = 90	32 (35.6%)	44 (48.9%)	6 (6.7%)	6 (6.7%)	0	2 (13.3%)
Placenta in situ n = 48	0	7 (14.5%)	7 (14.5%)	19 (39.6%)	11 (22.9%)	4 (8.3%)
Termination of pregnancy n = 9	0	4 (44%)	0	3 (33.3%)	1 (11.1%)	1 (11.1%)
Vaginal delivery n = 17	1 (5.9%)	8 (47.2%)	7 (41.1%)	1 (5.9%)	0	0
Focal resection n = 26	0	3 (11.6%)	2 (7.7%)	18 (69.2%)	1 (3.8%)	2 (7.7%)

3.3.3 | Conservative management with placenta left in situ

In 48 women (Figure 2), the placenta was completely (n = 43) or partially (n = 5) left in situ. In 43 of the women, this was pre-planned. In five women, methotrexate was given (dose 50 mg/m², 100 mg i.m. or 1 mg/kg). In almost all women (n = 41, 87.5%) intravenous antibiotics were

administered according to local protocols for 2-15 days. Cefuroxime or amoxicillin-clavulanic acid were the most frequently used. In 12 women (25.0%), pelvic artery embolization was performed: six were planned according to the local protocol, two were emergently embolized to manage heavy bleeding and in four, no indication was recorded. Of the 48 conservatively managed women, 20 (41.7%) had a delayed hysterectomy. In 12 women, the indication was bleeding or infection. Delayed hysterectomy was planned in four women and in a further women, it is unknown whether hysterectomy was planned. In the pre-planned group, hysterectomy was performed 4 weeks after the cesarean section. In the unplanned group, hysterectomy was performed a median of 67 days (range 0-134) after delivery. Fifteen women had supracervical and five a total hysterectomy. In 28 women (58%), the uterus was spared (see Figure 1). Histology was recorded in 14 cases and showed two accretas, two incretas, one increta with previa, six percretas, and three percretas with previa. Two women had a laparotomy with focal resection of myometrial and placental removal. In two women, an attempt at manual removal of the placenta using a vaginal approach ended in a hysterectomy. Complete resolution by resorption or expulsion was documented in five women whose placentas were left in situ for a median of 204 days (range 150-280).

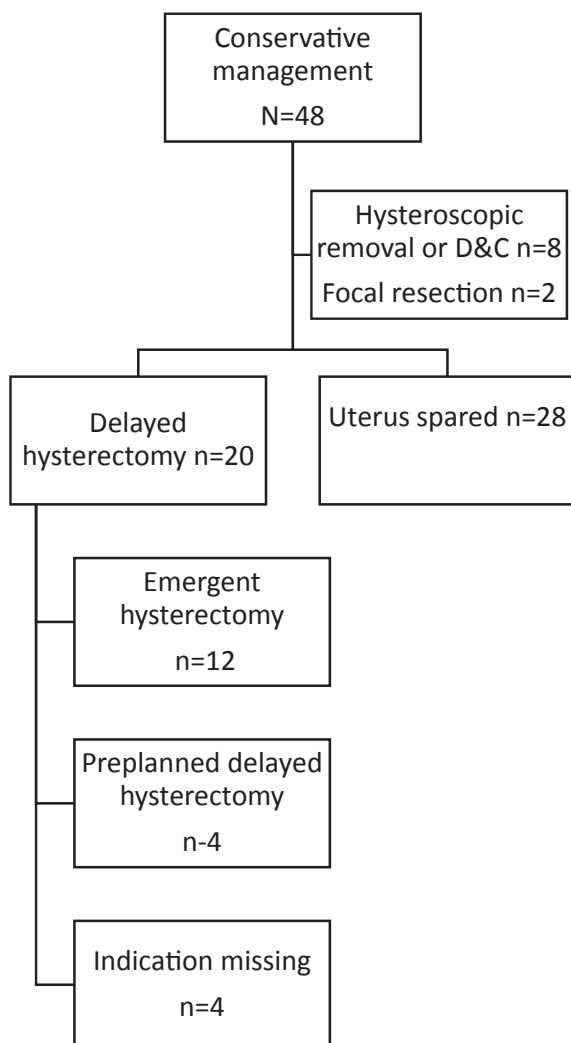


FIGURE 1 Details of conservative management in 48 patients. D&C, dilation and curettage

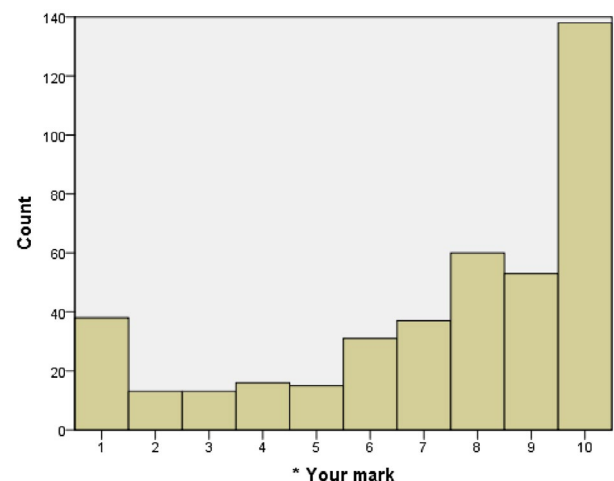


FIGURE 2 Likert scale assessment of certainty of PAS on antenatal imaging, as reported by imaging experts (1 = PAS unlikely, 10 = highly likely) [Color figure can be viewed at wileyonlinelibrary.com]

3.3.4 | Focal resection

Focal resection was performed successfully in 26 (6.1%) women. Balloon occlusion during surgery was applied in nine women (34.6%). Only four resected specimens were sent for histopathology: one accreta, one increta, and two percreta with previa.

3.3.5 | Vaginal delivery

Twenty-seven women were scheduled for vaginal delivery, of whom 17 had a vaginal delivery. Ten had a cesarean section for routine obstetrical indications. In two women, bleeding was the main indication for cesarean. In all, manual removal of the placenta was performed. Four had expectant management of small placental remnants. Antenatally, three did not have an ultrasound for PAS, and 11 were diagnosed with normal placentation, two with a mild suspicion and one with a moderate suspicion of PAS.

3.3.6 | Termination of pregnancy

Nine women had a termination of pregnancy, five because of fetal abnormalities and four because of PAS only. Median gestational age was 20⁺¹ (14-24) weeks. In three women, labor was induced by prostaglandins. In six cases, hysterotomy was planned to deliver the fetus, of whom one required a focal resection. Afterward, two women were treated conservatively with a placenta in situ and methotrexate. In one patient, the placenta could be extracted at hysterotomy. Three specimens were sent to the pathology lab: two accreta and one increta with previa placenta.

3.4 | Correlation between imaging and clinical findings and team learning

Prenatal imaging was performed in 414 women. The PAS likelihood as gauged by expert operators was strongly correlated with PAS with a median of 8 points on the Likert scale (Chi-square $P < .001$) (Figure 2). In the total group of 414 women in whom PAS was suspected at expert imaging during pregnancy, the placenta was easily removed and the diagnosis PAS was rejected in 32 women (7.7%). These women had a median of 6 points on the Likert scale. In total, 323 women with PAS were managed in 2008-2017 and 119 in 2018-2019. The median blood loss was 2000 and 1500 mL, respectively, and the mean blood loss 2789 and 2084 mL ($P < .002$), suggesting a substantial learning curve.

4 | DISCUSSION

The management of PAS cases differed widely in the 15 international centers participating in the IS-PAS. Notwithstanding the massive blood loss that often accompanied PAS, no woman died, and this

may be due to the experience and multidisciplinary team working in a referral center. The choice in management strategy appears to be largely dependent upon the degree of placental pathology, the experience of each team and patient preferences, as well as the size and degree of invasion of the placenta. Planned PAS management appears to be based chiefly on local tradition, resources, and the anticipated severity. Postpartum complications demanded emergent interventions in conservatively managed women, therefore ongoing vigilance and the ability to perform emergent hysterectomy remains a critical skill, even in centers where conservative management is routinely carried out.¹⁸

As expected, placenta previa and placenta overlying the uterine scar are both strongly associated with PAS. The false-positive rate of expert imaging was shown to be 7.7%.

Methotrexate was given in only five of the 48 women with conservative management that left the placenta in situ. In 2017, our group concluded that there is no evidence for the benefit of methotrexate,¹⁵ but since there is evidence for potential harm, we recommended not using methotrexate for conservative management of PAS. Since then, the use of methotrexate has been abandoned. We compared data from 2008-2017 with 2018-2019 and detected a significant difference in mean and median blood loss. This suggests that a learning curve is present.

This study has several limitations. PAS remains a very heterogeneous and rare disease and the data collection was partly retrospective. We used the original clinical classification system on which the recently proposed FIGO classification system was based, which differs slightly from the newer, improved version. Cases have been reported in 15 different centers. Multidisciplinary team learning and improvement of strategies at each center may have led to changes in management of PAS during this study. However, this is somewhat mitigated by the fact that all centers were already referral centers at the start of the study. Clear management recommendations cannot be inferred, as each case was managed according to local protocols. Research is still needed to identify which women will benefit from each specific management strategy.

Our report depicts the complexity of managing this difficult condition. No strategy is without risk of morbidity. The risks of severe bleeding and visceral injury during cesarean hysterectomy should be balanced with the risk of infection, bleeding and emergency hysterectomy if the placenta is left in situ.¹⁹ In a recent report on a large series on focal resection in PAS, a complication rate of 40.5% was reported.²⁰ In referral centers for PAS, a broad spectrum of measures is available, including suturing techniques, iliac balloon, hemostatic tamponades, conservative management protocols and embolization, which are individually employed according to PAS grade and local preference.

Our study may be generalizable to centers in developed countries, with multidisciplinary teams and readily available local resources including imaging experts, blood banking, neonatal intensive care, adult intensive care and round-the-clock availability of surgical experts. Our outcomes and findings will likely differ from those from centers in developing regions or hospitals with

more limited resources. It is also important to emphasize that even in referral centers, the maternal outcomes depend upon the skills and competency of the operating surgeon, and that this can vary within the same center and therefore the results should be extrapolated with caution.


5 | CONCLUSION

PAS is a life-threatening disease that is most common in women with placenta previa and previous cesarean sections. The goal of the contemporary obstetrical management should be to identify women with PAS by obstetric history and imaging techniques and then ensure delivery by multidisciplinary teams in specialized obstetric referral centers whenever possible. Even in expert hands, blood loss can still be massive and difficult to manage. In our series of 442 women, no maternal mortality occurred, despite massive hemorrhage in some women, which we attribute to the expert, team-based approach. We suspect that teams had a positive learning curve since we discovered that blood loss was significantly lower in the last 2 years of the study than in previous years. In our cohort, some women were able to have uterus-sparing treatment. Some women managed by leaving the placenta in situ, required salvage hysterectomy, suggesting that proper patient selection and vigilant monitoring is essential. In cases of severe PAS, waiting for partial resorption followed by delayed hysterectomy may be feasible. The main aim of focal resection and expectant management is to reduce morbidity. Expert antenatal imaging can accurately predict PAS. Despite expertise, minor forms of PAS are difficult to distinguish from severe PAS, leading to the possibility of false-positive diagnoses.¹⁷ The advantage of delivering in a referral center in these cases may be that conservative management can be offered more confidently, and hysterectomy can be avoided in false-positive cases and, when necessary, may be completed with fewer complications. We advocate that women at risk for PAS should be referred to referral centers for screening to optimize antenatal and intraoperative care. Future randomized studies are needed to answer unresolved questions related to delivery management.

CONFLICT OF INTEREST

Loïc Sentilhes and Olivier Morel carried out consultancy work and were lecturers for Ferring Laboratories in the previous 3 years. Karin A. Fox obtained NIH R01 Grant number: 1R01HD094347-01 Molecular and Vascular MRI of Placenta Accreta from the funding agency Eunice Kennedy Shriver National Institute of Child Health and Human Development, and has been a lecturer for Symposia Medicus. The rest of authors have no conflicts of interest to report.

ORCID

Heleen J. van Beekhuizen  <https://orcid.org/0000-0001-8899-7412>

Vedran Stefanovic  <https://orcid.org/0000-0001-5230-1698>

Alexander Schwickert  <https://orcid.org/0000-0003-2360-6016>

Wolfgang Henrich  <https://orcid.org/0000-0002-0759-832X>

Karin A. Fox  <https://orcid.org/0000-0002-8405-772X>

Mina MHalleem Gziri  <https://orcid.org/0000-0003-3528-2389>

Loïc Sentilhes  <https://orcid.org/0000-0003-0009-3625>

Lene Gronbeck  <https://orcid.org/0000-0003-3089-3711>

Frederic Chantraine  <https://orcid.org/0000-0001-9639-7038>

Oliver Morel  <https://orcid.org/0000-0001-6359-1328>

Charline Bertholdt  <https://orcid.org/0000-0001-9297-5363>

Thorsten Braun  <https://orcid.org/0000-0002-1989-9920>

Marcus J. Rijken  <https://orcid.org/0000-0003-0914-5508>

Johannes J. Duvekot  <https://orcid.org/0000-0003-3191-9362>

REFERENCES

1. Jauniaux E, Bunce C, Gronbeck L, Langhoff-Roos J. Prevalence and main outcomes of placenta accreta spectrum: a systematic review and meta-analysis. *Am J Obstet Gynecol.* 2019;221:208-218.
2. Silver RM, Fox KA, Barton JR, et al. Center of excellence for placenta accreta. *Am J Obstet Gynecol.* 2015;212:561-568.
3. Shamshirsaz AA, Fox KA, Salmanian B, et al. Maternal morbidity in patients with morbidly adherent placenta treated with and without a standardized multidisciplinary approach. *Am J Obstet Gynecol.* 2015;212(2):218.e1-218.e9.
4. Shamshirsaz AA, Fox KA, Erfani H, et al. Multidisciplinary team learning in the management of the morbidly adherent placenta: outcome improvements over time. *Am J Obstet Gynecol.* 2017;216:612.e1-612.e5.
5. Eller AG, Bennett MA, Sharshiner M, et al. Maternal morbidity in cases of placenta accreta managed by a multidisciplinary care team compared with standard obstetric care. *Obstet Gynecol.* 2011;117:331-337.
6. Jauniaux E, Hussein AM, Fox KA, Collins SL. New evidence-based diagnostic and management strategies for placenta accreta spectrum disorders. *Best Pract Res Clin Obstet Gynaecol.* 2019;61:75-88.
7. Sentilhes L, Ambroselli C, Kayem G, et al. Maternal outcome after conservative treatment of placenta accreta. *Obstet Gynecol.* 2010;115:526-534.
8. Sentilhes L, Kayem G, Ambroselli C, et al. Fertility and pregnancy outcomes following conservative treatment for placenta accreta. *Hum Reprod.* 2010;25:2803-2810.
9. Henrich W, Surbek D, Kainer F, et al. Diagnosis and treatment of peripartum bleeding. *J Perinat Med.* 2008;36:467-478.
10. Palacios-Jaraquemada J. One-step conservative surgery for abnormal invasive placenta (placenta accreta-increta-percreta). In: Arulkumaran SKM, Keith LG, eds. *A Comprehensive Textbook of Postpartum Hemorrhage.* 2nd ed. London, UK: Sapiens Publishing; 2008.
11. Cui R, Li M, Lu J, Bai H, Zhang Z. Management strategies for patients with placenta accreta spectrum disorders who underwent pregnancy termination in the second trimester: a retrospective study. *BMC Pregnancy Childbirth.* 2018;18:298.
12. Braun T, van Beekhuizen HJ, Morlando M, Morel O, Stefanovic V, on behalf of the IS-PAS. Developing a database for multicenter evaluation of Placenta Accreta Spectrum. *Acta Obstet Gynecol Scand.* 2021;100(Suppl. 1):7-11.
13. Collins SL, Stevenson GN, Al-Khan A, et al. Three-dimensional power Doppler ultrasonography for diagnosing abnormally invasive placenta and quantifying the risk. *Obstet Gynecol.* 2015;126:645-653.
14. Jauniaux E, Ayres-de-Campos D, Langhoff-Roos J, Fox KA, Collins S; FIGO Placenta Accreta Diagnosis and Management Expert Consensus Panel. FIGO classification for the clinical diagnosis of placenta accreta spectrum disorders. *Int J Gynaecol Obstet.* 2019;146:20-24.

15. Collins SL, Alemdar B, van Beekhuizen HJ, et al. Evidence-based guidelines for the management of abnormally invasive placenta: recommendations from the International Society for Abnormally Invasive Placenta. *Am J Obstet Gynecol.* 2019;220:511-526.
16. Morlando MJB, Gronbeck L. Placenta previa. *Visual Encyclopedia of Ultrasound in Obstetrics and Gynecology.* 2019. www.isuog.org.
17. Morel O, van Beekhuizen HJ, Braun T, et al. Performance of antenatal imaging to predict placenta accreta spectrum degree of severity. *Acta Obstet Gynecol Scand.* 2021;100(Suppl. 1):21-28.
18. Sentilhes L, Kayem G, Mattuizzi A. Conservative approach: Intentional retention of the placenta. *Best Pract Res Clin Obstet Gynaecol.* 2020;S1521-6934(20)30120-6.
19. Zuckerwise LC, Craig AM, Newton JM, Zhao S, Bennett KA, Crispens MA. Outcomes following a clinical algorithm allowing for delayed hysterectomy in the management of severe placenta accreta spectrum. *Am J Obstet Gynecol.* 2020;222(2):179.e1-179.e9.
20. Palacios-Jaraquemada JM, Fiorillo A, Hamer J, Martinez M, Bruno C. Placenta accreta spectrum: a hysterectomy can be prevented in almost 80% of cases using a resective-reconstructive technique. *J Matern Fetal Neonatal Med.* 2020;26:1-8.

SUPPORTING INFORMATION

Additional supporting information may be found online in the Supporting Information section.

How to cite this article: Beekhuizen HJ, Stefanovic V, Schwickert A, et al. A multicenter observational survey of management strategies in 442 pregnancies with suspected placenta accreta spectrum. *Acta Obstet Gynecol Scand.* 2021;100(Suppl. 1):12-20. <https://doi.org/10.1111/aogs.14096>

APPENDIX 1

Members of the International Society for Placenta Accreta Spectrum (IS-PAS)14 who contributed PAS cases and are not listed as authors

Pavel Calda, Department of Obstetrics and Gynaecology First Faculty of Medicine Charles University and General University Hospital in Prague, Czech Republic; Kinga M. Chalubinski, Department of Obstetrics and Gynecology, Division of Obstetrics and Feto-Maternal Medicine, Medical University of Vienna, Vienna, Austria; Sally Collins, Nuffield Department of Women's and Reproductive Health, University of Oxford, and the Fetal Medicine Unit, John Radcliffe Hospital, Oxford, UK; Pasquale Martinelli, MD Department of Neuroscience, Reproductive Sciences and Dentistry, University Federico II Naples, Italy; Maddalena Morlando, Department of Woman, Child and General and Specialized Surgery, Obstetrics and Gynecology Unit, University of Campania 'Luigi Vanvitelli', Naples, Italy; Andreas Nonnenmacher, Charité – Universitätsmedizin Berlin, corporate member of Freie Universität Berlin, Humboldt-Universität zu Berlin, and Berlin Institute of Health, Department of Obstetrics, Berlin, Germany; Jorma Paavonen, Department of Obstetrics and Gynecology, Helsinki University Hospital and University of Helsinki, Finland; Petra Pateisky, Department of Obstetrics and Gynecology, Division of Obstetrics and Feto-Maternal Medicine, Medical University of Vienna, Vienna, Austria; Philippe Petit, Department of Obstetrics and Gynecology, Centre Hospitalier Universitaire de Liège, site CHR Citadelle, Liège, Belgium; Mariola Ropacka, Department of Perinatology and Gynecology, Poznan University of Medical Sciences, Poland; Minna Tikkanen, Department of Obstetrics and Gynecology, Helsinki University Hospital and University of Helsinki, Finland; Boris Tutschek, Praenatal-Zuerich and Medical Faculty Heinrich Heine University, Duesseldorf, Germany; Alexander Weichert, Practice for Prenatal Diagnosis Bergmannstrasse Berlin and Department of Obstetrics, Charité – Universitätsmedizin Berlin, Corporate Member of Freie Universität Berlin, Humboldt-Universität zu Berlin Institute of Health, Campus Virchow-Klinikum, Berlin, Germany; Katharina von Weizsäcker, Charité – Universitätsmedizin Berlin, corporate member of Freie Universität Berlin, Humboldt-Universität zu Berlin, and Berlin Institute of Health, Department of Obstetrics, Berlin, Germany.