

EUR Research Information Portal

Aspiration or arthrotomy for paediatric septic arthritis of the shoulder and elbow

Published in:
EFORT Open Reviews

Publication status and date:
Published: 10/08/2021

DOI (link to publisher):
[10.1302/2058-5241.6.200122](https://doi.org/10.1302/2058-5241.6.200122)

Document Version
Publisher's PDF, also known as Version of record

Document License/Available under:
CC BY-NC

Citation for the published version (APA):
Spaans, A. J., Donders, C. M. L., Bessems, J. H. J. M. G., & van Bergen, C. J. A. (2021). Aspiration or arthrotomy for paediatric septic arthritis of the shoulder and elbow: a systematic review. *EFORT Open Reviews*, 6(8), 651-657.
<https://doi.org/10.1302/2058-5241.6.200122>

[Link to publication on the EUR Research Information Portal](#)

Terms and Conditions of Use

Except as permitted by the applicable copyright law, you may not reproduce or make this material available to any third party without the prior written permission from the copyright holder(s). Copyright law allows the following uses of this material without prior permission:

- you may download, save and print a copy of this material for your personal use only;
- you may share the EUR portal link to this material.

In case the material is published with an open access license (e.g. a Creative Commons (CC) license), other uses may be allowed. Please check the terms and conditions of the specific license.

Take-down policy

If you believe that this material infringes your copyright and/or any other intellectual property rights, you may request its removal by contacting us at the following email address: openaccess.library@eur.nl. Please provide us with all the relevant information, including the reasons why you believe any of your rights have been infringed. In case of a legitimate complaint, we will make the material inaccessible and/or remove it from the website.



Aspiration or arthrotomy for paediatric septic arthritis of the shoulder and elbow: a systematic review

Anne J. Spaans¹
C.M. (Lilian) Donders²
J.H.J.M. (Gert) Bessems^{3,4}
Christiaan J.A. van Bergen⁴

- Upper extremity arthritis in children can be treated with joint aspiration, arthroscopy or arthrotomy, followed by antibiotics. The literature seems inconclusive with respect to the optimal drainage technique. Therefore, the objective of this systematic review was to identify the most effective drainage technique for septic arthritis of the upper extremity in children.
- Two independent investigators systematically searched the electronic MEDLINE, EMBASE and Cochrane databases for original articles that reported outcomes of aspiration, arthroscopy or arthrotomy for septic arthritis of the paediatric shoulder or elbow. Outcome parameters were clinical improvement, need for repetitive surgery or drainage, and complications.
- Out of 2428 articles, seven studies with a total of 171 patients treated by aspiration or arthrotomy were included in the systematic review. Five studies reported on shoulder septic arthritis, one study on elbow septic arthritis, and one study on both joints. All studies were retrospective, except for one randomized prospective study. No difference was found between type of treatment and radiological or clinical outcomes. Aspiration of the shoulder or elbow joint required an additional procedure in 44% of patients, while arthrotomy required 12% additional procedures.
- Conclusion: Both aspiration and arthrotomy can achieve good clinical results in children with septic arthritis of the shoulder or elbow joint. However, the scientific quality of the included studies is low. It seems that the first procedure can be aspiration and washout and start of intravenous antibiotics, knowing that aspiration may have a higher risk of additional drainage procedures.

Keywords: arthrotomy; aspiration; child; elbow; paediatric; septic arthritis; shoulder; systematic review

Cite this article: *EFORT Open Rev* 2021;6:651-657.
DOI: 10.1302/2058-5241.6.200122

Introduction

Septic arthritis is an acute infection of the joint that occurs most commonly in young children. The infection is mainly monoarticular, and is frequently localized in the knee and hip joints, while it is less frequent in the joints of the upper extremity. The incidence of septic arthritis is 2–7 per 100,000 children in Europe.^{1,2} The child is susceptible because the joint can be infected by haematogenous inoculation through the transphyseal vessels, spread of infection of the adjacent metaphysis, or direct inoculation from trauma or surgery.³

Acute septic arthritis is a condition with the potential for joint destruction, physeal damage, osteonecrosis, systemic illness and even death, which warrants urgent identification and treatment.^{1–3} *Staphylococcus aureus* is the most commonly cultured organism, followed by *Kingella kingae* and Group A *Streptococcus*, depending on the age of the child.^{1,4}

Septic arthritis in children should be treated with joint drainage by aspiration (arthrocentesis), arthroscopy or arthrotomy followed by intravenous antibiotics, according to the guideline of the European Society for Paediatric Infectious Diseases (ESPID).¹ However, the literature is scarce with respect to the optimal drainage technique in children with septic arthritis. Therefore, the aim of this study was to systematically review the literature concerning the optimal drainage technique for children with septic arthritis of the upper extremity joints.

Material and methods

Study design

This systematic review was performed in accordance with the Preferred Reporting Items for Systematic Reviews and Meta-Analyses (PRISMA) guidelines.⁵ The study was registered in the International Prospective Register of

Systematic Reviews (PROSPERO) at <https://www.crd.york.ac.uk/PROSPERO/> under registration number CRD42 018117795.

Literature search and study selection

Three online medical databases (PubMed, Embase, and the Cochrane database for clinical trials) were searched on 24 August 2019 using the following keywords: septic arthritis, child, aspiration, arthroscopy, arthrotomy and their synonyms, each fitted for the specific databases. Full search details are available in Appendix I. Two independent reviewers (AS and CD) screened titles, abstracts and full texts to identify potentially relevant articles. Additionally, the reference lists of the included articles were manually checked to avoid missing relevant articles. Studies were not blinded for author, affiliation, or source. Any disagreement was resolved by discussion and consensus among the authors.

Inclusion and exclusion criteria

All included articles presented original data on paediatric patients who had septic arthritis. Studies were included if they were written in English, French, German or Dutch and reported on a minimum of five patients under 18 years of age. The diagnosis of acute septic arthritis had to fulfil at least one of the following criteria: (1) A positive culture of the joint fluid; (2) Pus aspirated from the joint; (3) White blood cell count in the joint fluid $> 50,000/\text{mm}^3$; (4) Positive gram stain. Reviews, letters to the editor, case reports, expert opinions and surgical technique articles were excluded. When different joints or patients with (concomitant) osteomyelitis were included without separate analysis, studies were also excluded from further analysis.

Data extraction

The following parameters were recorded when available: numbers of patients, sex, age, type of treatment (aspiration, arthroscopy, arthrotomy), and delay in treatment. Relevant outcome parameters included the duration of follow-up, need for repetitive drainage or surgery, complications seen on radiography and clinical complications.

Methodological quality

To assess the risk of bias, the Methodological Index for Non-Randomized Studies (MINORS) was used.⁶ MINORS is a validated and established index for evaluating the methodological quality of non-randomized studies. The index involves 12 criteria for comparative studies, of which eight criteria have been designed for non-comparative studies. These items were scored according to the set criteria: 0 (not reported), 1 (reported but inadequate), or 2 (reported and adequate). The maximum score for comparative studies was 24, and the maximum for non-comparative studies was 16. Two reviewers independently evaluated

each study according to the MINORS index, and the mean of these calculations was described.

To assess risk of bias for randomized trials, the Cochrane Collaboration tool was used. Bias was assessed as a judgment (high, low or unclear) for individual elements from five domains (selection, performance, attrition, reporting and other).⁷

Outcome measures and analysis

The outcome measures were clinical improvement, need for repetitive surgery or drainage, and complications. Descriptive data are presented in this review. Due to the heterogeneity of the data it was not possible to perform a meta-analysis and therefore no statistical tests were applied.

Results

Selection process

The search yielded a total of 2428 articles, including 1125 PubMed hits, 1241 Embase hits, and 62 Cochrane database hits. Duplicates were removed ($n = 529$) and 1899 articles were screened by title and abstract. A total of 210 studies were selected for full-text screening, of which 182 articles were excluded. Another 21 studies were excluded because they did not include (enough) patients with septic arthritis of any upper extremity joint. Seven articles were included in this review; five reported on the shoulder, one on the elbow, and one on both joints. The cross-reference check of the included studies did not result in additional relevant articles. A flowchart is presented in Fig. 1.

Methodological quality and risk of bias

The MINORS index was applied to all selected non-randomized articles and was generally low (median, 4; range 3–5). The major limitations on the methodology of the selected studies were non-calculated or small sample size, retrospective design, and no unbiased assessment of endpoints.

Shoulder

Six studies included patients with septic arthritis of the shoulder.^{8–13} Overall, 142 patients were included with a weighted mean follow-up of 48 months (range, 6–168 months). The study characteristics are described in Table 1. One randomized study compared aspiration and arthrotomy.⁸ Four studies described patients who were treated with aspiration.^{9–12} In one study, patients were treated using arthrotomy.¹³ None of the studies used arthroscopy.

Ernat et al included 22 patients with septic arthritis of the shoulder treated using arthrotomy. In eight patients, cultures were negative; therefore, these patients were not included in the present analysis.¹³ Lejman et al retrospectively reviewed 46 shoulders in 42 patients. Thirty-eight

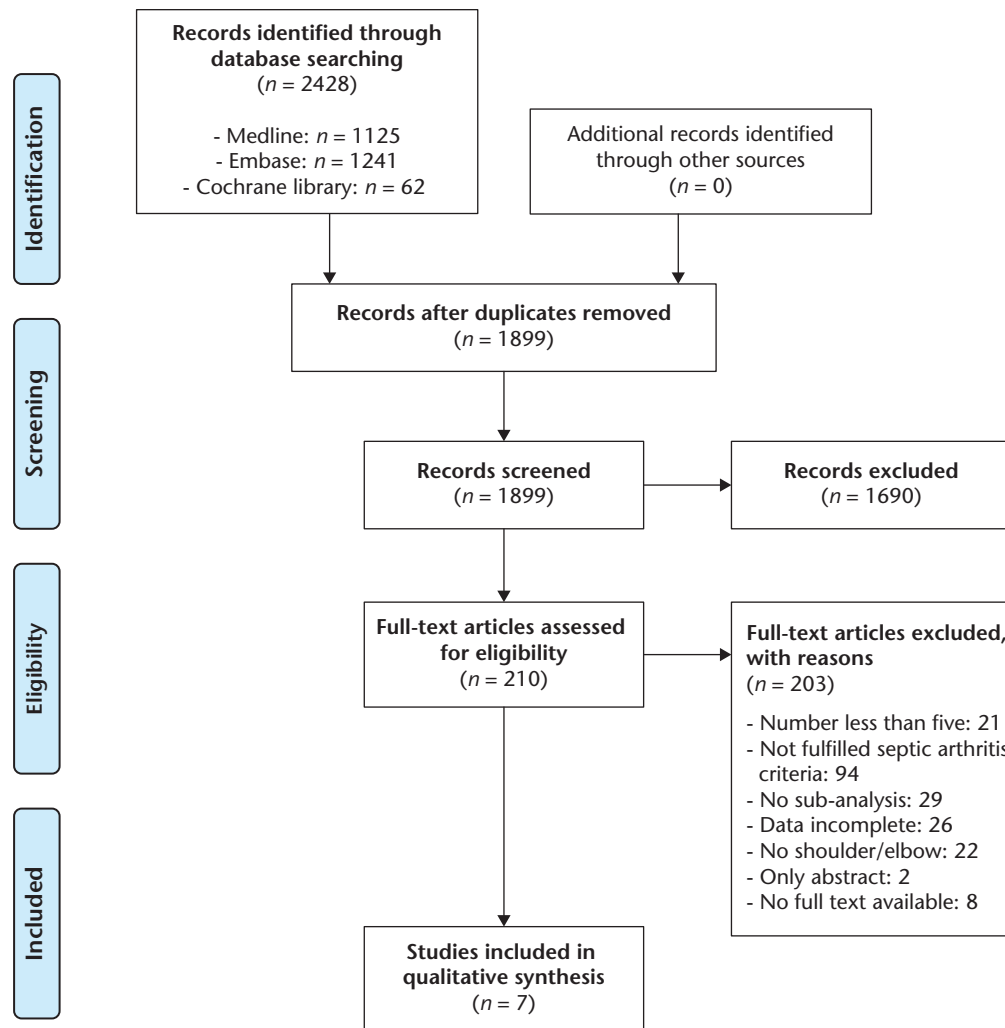


Fig. 1 Flowchart selection process.

shoulders were treated with aspiration. Eight joints were not drained but were diagnosed radiographically during follow-up. All 46 shoulders were analysed together in the original article.¹⁰ An attempt was made to contact the author, unfortunately without a response. All studies used additional antibiotics.

Need for repetitive surgery or drainage

In 90 of the 142 patients an aspiration was performed primarily.⁸⁻¹² In 41 of these patients (46%), an additional procedure was performed (two or more aspirations were performed in 36 patients and five patients underwent an arthrotomy).⁸⁻¹¹ Forty-four of the 142 patients underwent a primary arthrotomy, in seven (16%) of these patients one ($n = 5$) or more ($n = 2$) additional arthrotomies (one patient had a total of three arthrotomies and another had five) were performed.^{8,13}

Clinical results

Smith et al described that most shoulders had full range of motion. They found no significant differences between the arthrotomy and aspiration groups after a maximum of one year follow-up.⁸ Herndon et al and Griffet et al found that patients had no pain and no complaints.^{9,12} In the study by Lejman et al, six patients had continuing pain. The range of motion in this study was found to be reasonable, without significant differences between the groups with no, one or more aspirations in the study.¹⁰

Bos et al discovered that if treatment was initiated within two days there was full range of motion, whereas when the diagnosis was delayed, loss of external rotation of 10 to 20° was found.¹¹ No other analysis according to duration of symptoms was possible with the data given in the studies.^{9,11,12}

Table 1. Studies including shoulder joints

Study	Study design	Number of joints	Age (range)	Duration of symptoms	Total delay	Follow-up (range)	Treatment	Additional treatment	Duration antibiotic treatment (range)	Clinical outcome	Radiographic outcome	MINORS
Herndon et al, 1986 ⁹	Retrospective	5	24 m (1–156 m)	< 6 d	nm	37 m (12–68 m)	Aspiration	Arthrotomy (n = 2)	nm	No pain, no complaints	All normal	4/16
Lejman et al, 1995 ¹⁰	Retrospective	46	2 m (0–18 m)	nm	nm	82 m (16–253 m)	Aspiration (n = 38) No treatment (n = 8)	Multiple aspirations (n = 33) Arthrotomy (n = 1)	60 d (14–180 d)	n = 6 continuing pain Mean flexion 148° (range 30–180) Mean extension 47° (range 0–90) Mean abduction 152° (range 40–180) Mean external rotation 62° (range 0–90) Mean internal rotation 57° (range 0–85)	In 85% radiographic changes proximal humeral metaphysis. Only 7% of humeral heads appeared totally normal. Mean 2.4 cm humeral length discrepancy (range 0–9 cm).	3/16
Bos et al, 1998 ¹¹	Retrospective	10	0–2 m	0–7 d	nm	168 m (132–180 m)	Aspiration one or multiple (n = 10)	Arthrotomy (n = 2)	90 d (60–100 d)	Diagnosis < 2 d: full range of motion Diagnosis > 2 d: loss of external rotation 10–20°	Diagnosis < 2 d: less radiographic changes, no length discrepancies Diagnosis > 2 d: more radiographic changes, shorter humeral length (n = 5)	3/16
Smith et al, 2002 ⁸	Randomized prospective	61	8 m	nm	7 d	6 m (1.5–12 m)	Aspiration ¹ (n = 31) Arthrotomy (n = 30)	Aspiration (n = 3) Arthrotomy (n = 1)	42 d (first 48 h intravenous)	Most shoulders full range of motion	Radiographs (of 54% of patients) after 6 months showed in 70% evidence of damage to the glenohumeral joint, with more chance of changes in the arthrotomy group (odds ratio 1.56, difference was not statistically significant)	na
Griffet et al, 2011 ¹²	Retrospective	6	53 m (1–96 m)	3 d (1–5 d)	nm	23 m (12–36 m)	Aspiration + lavage system for 3–5 d	No	8–10 d intravenous, then oral	No pain, no other complaints	Normal radiographs	5/16
Ernat et al, 2017 ¹³	Retrospective	14	43 m (0–168 m)	nm	1 d (0–15 d)	nm	Arthrotomy	Arthrotomy (n = 6): N = 4 2x N = 1 3x N = 1 5x	Average 20 d intravenous, follow by an average of 32 d oral	nm	9 of 11 available radiographs at follow-up show abnormalities	5/16

Note. d, days; m, months; nm, not mentioned; n = number of patients; na, not applicable; MINORS, Methodological Index for Non-Randomized Studies.

¹Using a widebore needle (14 G) and an anterior approach until no more pus could be removed.

Radiological results

Smith et al found in 70% of patients evidence of damage to the glenohumeral joint, with higher chance of changes in the arthrotomy group (but this was not statistically

significant).⁸ Herndon et al and Griffet et al found normal radiographs.^{9,12} The other four studies found bony changes on radiographs in 70–93% of patients (including avascular necrosis, lucencies, and cortical irregularities).^{8,10,11,13}

Table 2. Studies including elbow joints

Study	Study design	Number of joints	Age (range)	Duration of symptoms	Total delay (days)	Follow-up (range)	Treatment	Extra surgery (n)	Duration antibiotic treatment (range)	Clinical outcome	Radiographic outcome	MINORS
Herndon et al, 1986 ⁹	Retrospective	14	24 m (1–156 m)	< 6 d	nm	37 m (12–68 m)	Aspiration	Arthrotomy (n = 5)	nm	No pain, no complaints	All normal	4/16
Kaziz et al, 2019 ¹⁴	Retrospective	15	108 (36–156 m)	4 d (1–11 d)	1 d	60 m (24–96 m)	Arthrotomy	None	7 d (4–12) intravenous followed by 38 d (30–45) oral	3 stiff elbows No growth disturbances MEPS 86	nm	5/16

Note. d, days; m, months; nm, not mentioned; n, number of patients; MEPS, Morrey Elbow Performance Score; MINORS, Methodological Index for Non-Randomized Studies.

Bos et al described that if treatment was initiated within two days, there were less radiographic changes and no arm length discrepancies compared to diagnosis after two days.¹¹ Lejman et al found humeral length discrepancies from 0 to 9 cm.¹⁰

Complications

None of the included studies reported on complications.

Elbow

Two studies included patients with septic arthritis of the elbow.^{9,14} In these studies 29 patients were included with a weighted mean follow-up of 49 months (range, 37–60 months). The study details are described in Table 2. Herndon et al studied 14 elbow joints treated by joint aspiration.⁹ Kaziz et al performed a lateral arthrotomy in 15 patients after aspiration identified cases with presumed septic arthritis of the elbow.¹⁴

Need for repetitive surgery or drainage

In the study by Herndon et al, the joints that did not respond to aspiration underwent arthrotomy, which was done in five of the 14 elbow joints.⁹ Kaziz et al did not perform repetitive surgeries.¹⁴

Clinical results

Herndon et al described there were no unsatisfactory clinical or radiographic results, regardless of the technique used.⁹ Kaziz et al found a mean Morrey Elbow Performance Score (MEPS) of 86 points (excellent in eight cases, good in three cases, fair in two cases, and poor in two cases) after two to eight years of follow-up. Three cases of elbow stiffness were identified; one with concomitant osteomyelitis, one after pinning of a supracondylar fracture, and one with previous extension deficit in concomitant sickle cell disease.¹⁴ Both studies mentioned the duration of symptoms, and Kaziz et al described these data for every individual patient. However, no firm conclusion could be made about the relation between the duration of symptoms and the functional outcome.

Radiological results

Herndon et al found normal radiographs.⁹

Complications

Kaziz et al concluded that no specific complications such as growth disturbance or elbow arthritis were revealed, and that no revision surgery was requested.¹⁴

Discussion

This systematic review shows that both aspiration and arthrotomy can achieve good clinical results in the treatment of septic arthritis of the shoulder or elbow joint. However, most of the included studies showed radiological abnormalities in the majority of patients during the follow-up period. In case of aspiration of the joint, there is a higher chance/risk of an additional procedure (in the majority of patients a second aspiration) compared to an arthrotomy. This difference (44% after aspiration versus 12% after arthrotomy) can mainly be attributed to the high percentage of additional treatment in the study of Lejman et al.¹⁰

Aspiration has the advantage of being a minimally invasive, safe and short procedure with faster return to normal activity, but has a possibly higher risk of ineffectively drainage of the viscous pus. Arthroscopy can give a good overview of the joint with the possibility of more extensive washout. However, it is technically more demanding, and the surgeon must be experienced in performing arthroscopies of the affected joint. With an arthrotomy there is a better overview of the joint and sufficient irrigation can be performed, but it can possibly lead to prolonged recovery, a higher risk of avascular necrosis, and associated problems such as stiffness of the joint.¹⁵ However, in the included studies these differences were not found. In the earlier published studies it was not specified whether the surgeons only performed an aspiration or also did a lavage or washout through the needle.^{9–11} Additional lavage might theoretically be beneficial in the treatment of septic arthritis. Furthermore, Bos et al and Ernat et al

suggested that longer duration of symptoms (and more delay) could initiate more necessary procedures.^{11,13} Therefore, early initiation of treatment by drainage followed by start of intravenous antibiotics seems beneficial. The minimally invasive nature of both aspiration and arthroscopy has advantages, but their availability depends on the surgeon's resources and experience.

One of the strengths of this review is the systematic search method to identify relevant articles for this subject. It has also been shown that this review is the first systematic review reporting on treatment methods for septic arthritis of upper extremity joints. In that light the results of the present review are useful in clinic for paediatric orthopaedic surgeons treating children with these conditions.

There are also several limitations. First, it was possible to include only seven studies with a total of 171 patients. A lot of studies were excluded because they were case reports or there was no established diagnosis of septic arthritis. Second, objective clinical and radiological outcome with adequate follow-up are essential to appreciate the results of the studies reliably. Smith et al performed the only prospective study that could be included. Their follow-up time was short with a maximum of one year in only 41% of patients.⁸ Ernat et al did not describe the follow-up time.¹³ Therefore, possible differences between aspiration and arthrotomy in the long term are not known. Additionally, other studies included did not describe objective outcome measures.^{8,9,11,12} Lejman et al included eight patients who had no treatment for their possible septic arthritis. In almost all of their patients (93%) radiographic changes were seen.¹⁰ We do not know the outcomes of the subgroup of patients that did not have surgery as compared to those that did. The third limitation of the present review is the inclusion of mainly small retrospective studies that used different aspiration techniques, lavage systems, and duration of postoperative antibiotic treatment. As a consequence, no robust conclusions can be drawn on the best treatment modality for septic arthritis of the shoulder or elbow joints.

Conclusion

Both aspiration and arthrotomy can achieve good clinical results in children with septic arthritis of the shoulder or elbow joint. However, the scientific quality of the included studies is low. Higher quality randomized controlled trials are required with adequate clinical and radiological outcome parameters and long follow-up time. Since the number of children suffering from septic arthritis of upper extremity joints is limited, multicentre trials could help in achieving a sufficient number of patients.

AUTHOR INFORMATION

¹Department of Orthopaedic Surgery, Sint Maartenskliniek Nijmegen/Boxmeer, the Netherlands.

²Department of Orthopaedic Surgery, Meander Medical Center Amersfoort, the Netherlands.

³Department of Children's Orthopaedics, Erasmus MC- Sophia Children's Hospital, University Medical Center Rotterdam, the Netherlands.

⁴Department of Orthopaedic Surgery, Amphia Hospital Breda, The Netherlands.

Correspondence should be sent to: Anne J. Spaans, Sint Maartenskliniek Nijmegen/Boxmeer, Postbus 9011, 6500 GM Nijmegen, the Netherlands.
Email: annespaans@gmail.com

ICMJE CONFLICT OF INTEREST STATEMENT

The authors declare no conflict of interest relevant to this work.

FUNDING STATEMENT

No benefits in any form have been received or will be received from a commercial party related directly or indirectly to the subject of this article.

SOCIAL MEDIA

Twitter: @anne_spaans

LinkedIn: Anne Spaans: <https://www.linkedin.com/in/anne-spaans-1a277845/>;

Gert Bessems: <https://linkedin.com/in/gert-bessems-8a956b9/>;

Christiaan van Bergen: <https://www.linkedin.com/in/christiaan-van-bergen-0027b6106/>

OPEN ACCESS

© 2021 The author(s)

This article is distributed under the terms of the Creative Commons Attribution-Non Commercial 4.0 International (CC BY-NC 4.0) licence (<https://creativecommons.org/licenses/by-nc/4.0/>) which permits non-commercial use, reproduction and distribution of the work without further permission provided the original work is attributed.

SUPPLEMENTAL MATERIAL

Supplemental material is available for this paper at <https://online.boneandjoint.org.uk/doi/suppl/10.1302/2058-5241.6.200122>

REFERENCES

1. Saavedra J, Falup-Pecurariu O, Faust S, et al. ESPID bone and joint infection guidelines, 2017. https://download.lww.com/wolterskluwer_vitalstream_com/Permalink/INF/C/INF_36_8_2017_05_10_SAAVEDRA_217-327_SDC1.pdf (date last accessed 25 November 2020).
2. Arnold JC, Bradley JS. Osteoarticular infections in children. *Infect Dis Clin North Am* 2015;29:557–574.
3. Montgomery NI, Epps HR. Pediatric septic arthritis. *Orthop Clin North Am* 2017;48:209–216.
4. Moumile K, Merckx J, Glorion C, Pouliquen JC, Berche P, Ferroni A. Bacterial aetiology of acute osteoarticular infections in children. *Acta Paediatr* 2005;94:419–422.
5. Moher D, Shamseer L, Clarke M, et al; PRISMA-P Group. Preferred reporting items for systematic review and meta-analysis protocols (PRISMA-P) 2015 statement. *Syst Rev* 2015;4:1–9.

6. **Slim K, Nini E, Forestier D, Kwiatkowski F, Panis Y, Chipponi J.** Methodological Index for Non-Randomized Studies (MINORS): development and validation of a new instrument. *ANZ J Surg* 2003;73:712–716.
7. **Higgins JP, Altman DG, Gøtzsche PC, et al; Cochrane Bias Methods Group; Cochrane Statistical Methods Group.** The Cochrane Collaboration's tool for assessing risk of bias in randomised trials. *BMJ* 2011;343:d5928.
8. **Smith SP, Thyoka M, Lavy CB, Pitani A.** Septic arthritis of the shoulder in children in Malawi: a randomised, prospective study of aspiration versus arthrotomy and washout. *J Bone Joint Surg Br* 2002;84:1167–1172.
9. **Herndon WA, Knauer S, Sullivan JA, Gross RH.** Management of septic arthritis in children. *J Pediatr Orthop* 1986;6:576–578.
10. **Lejman T, Strong M, Michno P, Hayman M.** Septic arthritis of the shoulder during the first 18 months of life. *J Pediatr Orthop* 1995;15:172–175.
11. **Bos CF, Mol LJ, Obermann WR, Tjin a Ton ER.** Late sequelae of neonatal septic arthritis of the shoulder. *J Bone Joint Surg Br* 1998;80:645–650.
12. **Griffet J, Oborocianu I, Rubio A, Leroux J, Lauron J, Hayek T.** Percutaneous aspiration irrigation drainage technique in the management of septic arthritis in children. *J Trauma* 2011;70:377–383.
13. **Ernat J, Riccio AI, Fitzpatrick K, Jo C, Wimberly RL.** Osteomyelitis is commonly associated with septic arthritis of the shoulder in children. *J Pediatr Orthop* 2017;37:547–552.
14. **Kaziz H, Triki MA, Mouelhi T, Bouattour K, Naouar N, Ben Ayeche ML.** Septic elbow arthritis in children: epidemiology and outcome. *Arch Pediatr* 2019; 26:38–43.
15. **Xu G, Spoerri M, Rutz E.** Surgical treatment options for septic arthritis of the hip in children. *Afr J Paediatr Surg* 2016;13:1–5.