

EUR Research Information Portal

Veno-arterial thrombosis and microcirculation imaging in a patient with COVID-19

Published in:

Respiratory Medicine Case Reports

Publication status and date:

Published: 13/05/2021

DOI (link to publisher):

[10.1016/j.rmcr.2021.101428](https://doi.org/10.1016/j.rmcr.2021.101428)

Document Version

Publisher's PDF, also known as Version of record

Document License/Available under:

CC BY-NC-ND

Citation for the published version (APA):

Akin, S., van Hooven, D., Ince, C., & Jansen, T. (2021). Veno-arterial thrombosis and microcirculation imaging in a patient with COVID-19. *Respiratory Medicine Case Reports*, 33, Article 101428. <https://doi.org/10.1016/j.rmcr.2021.101428>

[Link to publication on the EUR Research Information Portal](#)

Terms and Conditions of Use

Except as permitted by the applicable copyright law, you may not reproduce or make this material available to any third party without the prior written permission from the copyright holder(s). Copyright law allows the following uses of this material without prior permission:

- you may download, save and print a copy of this material for your personal use only;
- you may share the EUR portal link to this material.

In case the material is published with an open access license (e.g. a Creative Commons (CC) license), other uses may be allowed. Please check the terms and conditions of the specific license.

Take-down policy

If you believe that this material infringes your copyright and/or any other intellectual property rights, you may request its removal by contacting us at the following email address: openaccess.library@eur.nl. Please provide us with all the relevant information, including the reasons why you believe any of your rights have been infringed. In case of a legitimate complaint, we will make the material inaccessible and/or remove it from the website.

Contents lists available at [ScienceDirect](https://www.sciencedirect.com)

Respiratory Medicine Case Reports

journal homepage: www.elsevier.com/locate/rmcr

Case report

Veno-arterial thrombosis and microcirculation imaging in a patient with COVID-19

Sakir Akin^{a,b,c,*}, Daphne van Hooven^a, Can Ince^b, Tim Jansen^a^a Dept. of Intensive Care, Haga Teaching Hospital, The Hague, the Netherlands^b Dept. of Intensive Care, Erasmus MC, University Medical Center Rotterdam, Rotterdam, the Netherlands^c Dept. of Cardiology, Erasmus MC, University Medical Center Rotterdam, Rotterdam, the Netherlands

ARTICLE INFO

Keywords:

SARS-CoV-2 pneumonia
ARDS
Microcirculation
Thrombosis
COVID-19
IDF-Imaging

ABSTRACT

The Coronavirus pandemic has brought new challenges in intensive care medicine. Understanding of the pathophysiology of the vascular complications of SARS-CoV-2 infection could bring new resuscitation and therapeutic options. In this case report, we present a patient with COVID-19 pneumonia, who was admitted to our ICU and treated with high-flow nasal cannula, dexamethasone, remdesivir and high-dose prophylactic low molecular weight heparin. During ICU admission, substantial venous and arterial thrombosis developed. Meanwhile the microcirculation showed more than double amount of organ perfusion with very high total vessel density. We hypothesize that this might be a compensatory mechanism for the generalized prothrombotic state in which the microcirculation increases the oxygen extraction capacity preventing multi-organ failure.

1. Introduction

The coronavirus disease 2019 (COVID-19) pandemic has so far caused over 120 million confirmed cases and resulted in at least 2.6 million deaths worldwide [1]. Severe SARS-CoV-2 infection leads to acute respiratory distress syndrome (ARDS) induced hypoxemia, requiring intensive care treatment. Critical illness, underlying patient risk factors and the SARS-CoV-2 infection itself predispose to arterial and venous thrombotic events, such as venous thromboembolism (VTE), acute coronary syndrome (ACS), disseminated intravascular coagulation (DIC), stroke and critical limb ischemia [2]. The mechanisms of coagulopathy in COVID-19 patients is still not entirely clear. In severely affected COVID-19 patients a cytokine storm is observed, which leads to endothelial dysfunction and a hypercoagulable state [3–5]. Furthermore, a direct effect of the SARS-CoV-2 virus on the renin-angiotensin-aldosterone system and endothelial cells contributes to this state [3,6].

Apart from monitoring macro vascular parameters and following patients biomarkers, monitoring microcirculation at the bedside could give the clinician information about the current status of the patient and the optimal treatment [5]. In resuscitation of critically ill patients, targeting vascular hemodynamic parameters does not always ensure correction of microcirculation [7]. Moreover, microcirculatory

alterations have showed to be a better predictor of outcome than global hemodynamic variables [8]. In this case report sublingual microcirculation was measured in a critically ill patient with COVID-19 pneumonia, using the Cytocam-IDF (Incident Dark Field illumination), a handheld microscope [9].

2. Case presentation

A 62-year-old man with a medical history of COPD Gold II and Hashimoto's disease presented to the emergency department with increasing complaints of shortness of breath, coughing, fever and myalgia. He had experienced symptoms for ten days and tested positive for SARS-CoV-2 seven days before. Due to severe hypoxia, the patient had to be admitted to our intensive care. At admission, treatment with remdesivir, dexamethasone and high-dose prophylactic low molecular weight heparin twice a day (LMWH) was started. The dose of LMWH was adjusted to therapeutic range based on anti-Xa levels (range 0.6–1.0 IU/ml). Computed tomography pulmonary angiography (CTPA) did not show pulmonary embolisms at day of admission. Despite eight days on high - flow nasal cannula support, the patient experienced increased events of paroxysmal hypoxia for several minutes in addition to chest pain. His macrocirculation was stable with persisting mono-organ failure (SOFA score of 2). The electrocardiogram, cardiac markers, and

* Corresponding author. Haga Ziekenhuis, Department of Intensive Care; Room: E2.40, Els Borst-Eilersplein 275, 2545 AA, The Hague, the Netherlands.
E-mail address: s.akin@hagaziekenhuis.nl (S. Akin).

<https://doi.org/10.1016/j.rmcr.2021.101428>

Received 30 January 2021; Received in revised form 5 May 2021; Accepted 7 May 2021

Available online 11 May 2021

2213-0071/© 2021 The Authors.

Published by Elsevier Ltd.

This is an open access article under the CC BY-NC-ND license

(<http://creativecommons.org/licenses/by-nc-nd/4.0/>).

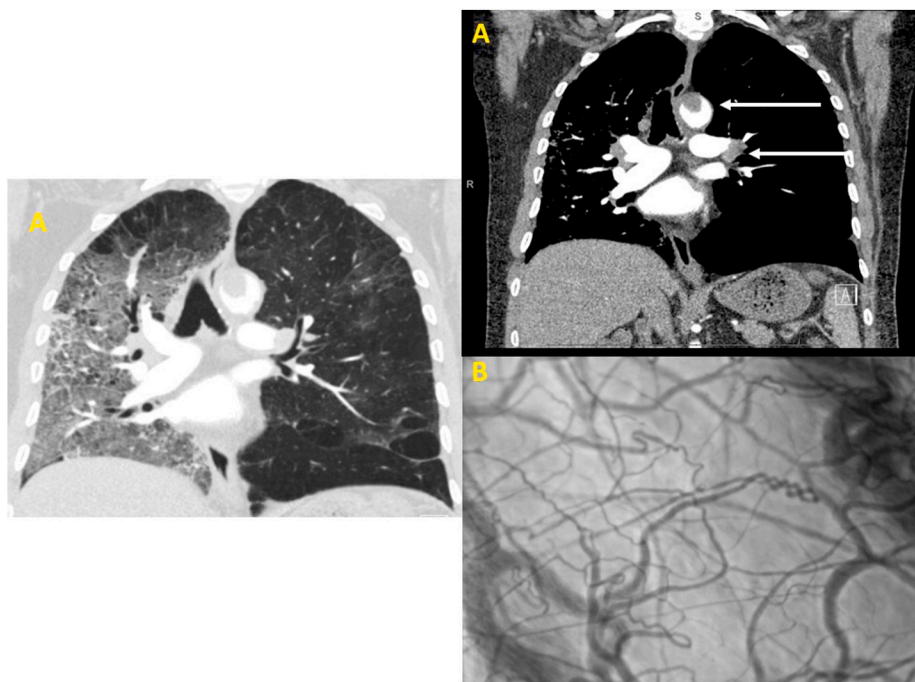


Fig. 1. A and B: CTPA (Panels A) showing large vessel thrombosis of both the pulmonary arteries and the thoracic aorta (arrows) and unilateral pulmonary opacity. Image B shows the sublingual microcirculation measurement: hyperdynamic circulation and increased amount of total vessel density of capillaries, without thrombosis.

Table 1

Functional parameters of the microcirculation.

| Variable | Value |
|---------------------------|--------------|
| TVD [mm/mm ²] | 24.7 ± 4.4 |
| FCD [mm/mm ²] | 23.85 ± 3.97 |
| PPV [%] | 0.97 ± 0.03 |
| RBCv [μm/s] | 366 ± 40 |

Values are presented as mean ± standard deviation.

Abbreviations: FCD, functional capillary density; PPV, proportion of perfused vessels; RBCv, red blood cell velocity; TVD, total vessel density.

echocardiography showed no abnormalities. However, D-dimer was increased from 1,73 mg/L to 8,44 mg/L. A new CTPA was performed which showed large vessel thrombosis of both the pulmonary arteries and the thoracic aorta (Fig. 1A). Partial abdominal imaging showed renal and spleen infarction. Sublingual microcirculation measurements at five different sublingual locations all showed hyperdynamic circulation (Table 1) and an excessive increased amount of total vessel density of capillaries, without thrombosis (Fig. 1B). At the time of these findings, the patient only exhibited isolated respiratory failure.

Treatment with continuous high molecular weight heparin infusion was started, adjusted for therapeutic target APTT every 6 h. The subsequent day the patient's respiratory status deteriorated and he needed mechanical ventilation. One week later, *Staphylococcus Aureus* pneumoniae caused progressive multi-organ failure and the patient died.

3. Discussion

This case report shows a COVID-19 patient suffering from massive macrovascular thrombotic complications in the pulmonary arteries, thoracic aorta, spleen and kidneys. However, at the time of these complications, the patient experienced only single organ failure without need for mechanical ventilation. His microcirculation showed no evidence of micro-thrombosis, but a hyperdynamic circulation with increased amount of total vessel density and red blood cell velocity.

In microcirculation research in septic patients, microvascular

variables are markedly altered, showing a decreased proportion of perfused vessels and slower microvascular flow [8]. So far, published results of sublingual measurements in COVID-19 patients are limited in number and there is heterogeneity in the parameters of microvascular circulation reported.

As far as we know, this is the only report of sublingual measurements in a patient with severe thrombotic complications.

In the available literature on sublingual circulation in COVID-19 patients, the results are contradictory. A case series by Damiani et al. measured low total vessel density (TVD) and perfused vessel density (PVD), however, they found a proportion of perfused vessels (PPV) of 97.3% and microvascular flow index (MFI) of 2.9 [11]. Rovas et al. found a decrease in vessel density and in patients with need for mechanical ventilation, red blood cell velocity was significantly lower compared to healthy controls; COVID-19 patients without ventilation showed normal velocity values [10]. Kanoore Edul et al. found a higher total and perfused vessel density in twenty-seven COVID-19 patients, however, the PPV, MFI, and red blood cell velocity was lower compared to healthy controls [12].

Hutchings et al. compared thirty mechanically ventilated COVID-19 patients to thirty-three patients with septic shock and twelve healthy volunteers. In COVID 19 patients, total vessel density and perfused vessel density were higher than in controls, with a lower MFI and PPV [14]. Favaron et al. measured a significant increase in total vessel density, functional capillary density, proportion of perfused vessels and a significant higher red blood cell velocity in thirty-four COVID-19 patients compared to controls, suggesting a hyperdynamic microvascular circulation [13].

The sublingual microcirculatory parameters in this case report and a previous case report of our study group [15], are in line with the findings of Hutchings and Favaron and support our hypothesis that the microcirculation is able to enhance its oxygen extraction capacity as a compensatory mechanism. This microcirculatory response has also been observed in studies reporting sublingual microcirculatory vessel density in healthy persons subjecting themselves to hypobaric hypoxic conditions [16,17]. The role of sublingual microcirculation measurements in COVID-19 would be promising for monitoring disease severity and

activity in patients before and after suffering from multiple thrombotic events when this compensated state of microcirculation is persisting despite treatment.

This case reports has multiple limitations. Unfortunately, we only have the measurement of sublingual microcirculation on the day of first respiratory deterioration while on high-flow nasal cannula and detection of the arterial and vascular thrombosis. It would have been insightful to be able to compare measurements at the different points in disease progression. We would then be able to verify hemodynamic coherence in COVID-19, matching macrovascular hemodynamic parameters, current clinical state and microcirculation. Further research is warranted to assess the potential clinical use of sublingual microcirculation measurements as a parameter of disease severity and response to treatment in COVID-19 patients.

CRedit author statement

S Akin: Conceptualization, investigation, writing of original draft, reviewing and supervision. D van Hooven: writing of original draft, visualization and reviewing. C Ince: reviewing and editing. T Jansen: reviewing, editing and supervision.

Declaration of competing interest

Dr. Ince has developed SDF imaging and is listed as an inventor on related patents that were commercialized by Micro Vision Medical (MVM) under a license from the Academic Medical Center (AMC). He receives no royalties or benefits from this license. He has been a consultant for MVM in the past but has not been involved with this company for more than five years and holds no shares or stock. Braedius Medical, which is a company that is owned by a relative of Dr. Ince, has developed and designed a handheld microscope, namely, the CytoCam-IDF imaging microscope. Dr. Ince has no financial relationship with Braedius Medical of any sort (he has never owned shares or received consultancy or speaker fees from Braedius Medical). Dr. Ince runs an internet site (<https://microcirculationacademy.org>) that offers services (e.g., training, courses, and analysis) that are related to clinical microcirculation.

The other authors declare that they have no competing interests.

References

[1] WHO, Coronavirus disease—COVID-19 global data. <https://covid19.who.int/>.

- [2] B. Bikkeli, M.V. Madhavan, D. Jimenez, et al., COVID-19 and thrombotic or thromboembolic disease: implications for prevention, antithrombotic therapy, and follow-up: JACC state-of-the-art review, *J. Am. Coll. Cardiol.* 75 (23) (2020), <https://doi.org/10.1016/j.jacc.2020.04.031>.
- [3] M.G. Lazzaroni, S. Piantoni, S. Masneri, et al., Coagulation dysfunction in COVID-19: the interplay between inflammation, viral infection and the coagulation system, *Blood Rev.* (2020), <https://doi.org/10.1016/j.blre.2020.100745>. Published online March 1.
- [4] W. Miesbach, M. Makris, COVID-19: coagulopathy, risk of thrombosis, and the rationale for anticoagulation, *Clin. Appl. Thromb. Hemost.* 26 (2020), <https://doi.org/10.1177/1076029620938149>.
- [5] R. Martini, The compelling arguments for the need of microvascular investigation in COVID-19 critical patients, *Clin. Hemorheol. Microcirc.* 75 (1) (2020) 27–34, <https://doi.org/10.3233/CH-200895>.
- [6] L. Østergaard, SARS CoV-2 related microvascular damage and symptoms during and after COVID-19: consequences of capillary transit-time changes, tissue hypoxia and inflammation, *Phys. Rep.* 9 (3) (2021), <https://doi.org/10.14814/phy2.14726>.
- [7] C. Ince, Hemodynamic coherence and the rationale for monitoring the microcirculation, *Crit. Care* 19 (2015), <https://doi.org/10.1186/cc14726>.
- [8] D. De Backer, K. Donadello, Y. Sakr, et al., Microcirculatory alterations in patients with severe sepsis: impact of time of assessment and relationship with outcome, *Crit. Care Med.* 41 (3) (2013) 791–799, <https://doi.org/10.1097/CCM.0b013e3182742e8b>.
- [9] G. Aykut, G. Veenstra, C. Scorcella, C. Ince, C. Boerma, Cytocam-IDF (incident dark field illumination) imaging for bedside monitoring of the microcirculation, *Intensive Care Med. Exp.* 3 (1) (2015), <https://doi.org/10.1186/s40635-015-0040-7>.
- [10] A. Rovas, I. Osiaevi, K. Buscher, et al., Microvascular Dysfunction in COVID-19: the MYSTIC Study. *Angiogenesis*, 2020, <https://doi.org/10.1007/s10456-020-09753-7>. Published online February 1.
- [11] E. Damiani, A. Carsetti, E. Casarotta, et al., Microvascular alterations in patients with SARS-COV-2 severe pneumonia, *Ann. Intensive Care* 10 (1) (2020), <https://doi.org/10.1186/s13613-020-00680-w>.
- [12] V.S. Kanoore Edul, J.F. Caminos Eguillor, G. Ferrara, et al., Microcirculation alterations in severe COVID-19 pneumonia, *J. Crit. Care* 61 (2021) 73–75, <https://doi.org/10.1016/j.jcrc.2020.10.002>.
- [13] E. Favaron, C. Ince, M.P. Hilty, et al., Capillary leukocytes, microaggregates, and the response to hypoxemia in the microcirculation of coronavirus disease 2019 patients, *Crit. Care Med.* 49 (4) (2021) 661–670, <https://doi.org/10.1097/CCM.0000000000004862>.
- [14] S.D. Hutchings, J. Watchorn, F. Trovato, et al., Microcirculatory, Endothelial and Inflammatory Responses in Critically Ill Patients with COVID-19 Are Distinct from Those Seen in Septic Shock: a Case Control Study, 2020, <https://doi.org/10.1097/SHK.0000000000001672>. Published online.
- [15] S. Grewal, B. Harjo, G. Aykut, et al., Case report: sublingual microcirculatory alterations in a covid-19 patient with subcutaneous emphysema, venous thrombosis, and pneumomediastinum, *Front. Med.* 7 (2021), <https://doi.org/10.3389/fmed.2020.624695>.
- [16] E. Gilbert-Kawai, J. Coppel, H. Phillip, M. Grocott, C. Ince, D. Martin, Changes in labial capillary density on ascent to and descent from high altitude [version 1; referees: 2 approved], *F1000Res.* (2016) 5, <https://doi.org/10.12688/F1000RESEARCH.7649.1>.
- [17] M.P. Hilty, T.M. Merz, U. Hefti, C. Ince, M. Maggiorini, J. Pichler Hefti, Recruitment of non-perfused sublingual capillaries increases microcirculatory oxygen extraction capacity throughout ascent to 17126 m, *J. Physiol.* 597 (10) (2019) 2623–2638, <https://doi.org/10.1113/JP277590>.