

# EUR Research Information Portal

## A basic review on systemic treatment options in WHO grade II-III gliomas

**Published in:**

Cancer Treatment Reviews

**Publication status and date:**

Published: 01/01/2021

**DOI (link to publisher):**

[10.1016/j.ctrv.2020.102124](https://doi.org/10.1016/j.ctrv.2020.102124)

**Document Version**

Publisher's PDF, also known as Version of record

**Document License/Available under:**

CC BY-NC-ND

**Citation for the published version (APA):**

Mair, M.J., Geurts, M., van den Bent, M., & Berghoff, A.S. (2021). A basic review on systemic treatment options in WHO grade II-III gliomas. *Cancer Treatment Reviews*, 92, Article 102124. <https://doi.org/10.1016/j.ctrv.2020.102124>

[Link to publication on the EUR Research Information Portal](#)

**Terms and Conditions of Use**

Except as permitted by the applicable copyright law, you may not reproduce or make this material available to any third party without the prior written permission from the copyright holder(s). Copyright law allows the following uses of this material without prior permission:

- you may download, save and print a copy of this material for your personal use only;
- you may share the EUR portal link to this material.

In case the material is published with an open access license (e.g. a Creative Commons (CC) license), other uses may be allowed. Please check the terms and conditions of the specific license.

**Take-down policy**

If you believe that this material infringes your copyright and/or any other intellectual property rights, you may request its removal by contacting us at the following email address: [openaccess.library@eur.nl](mailto:openaccess.library@eur.nl). Please provide us with all the relevant information, including the reasons why you believe any of your rights have been infringed. In case of a legitimate complaint, we will make the material inaccessible and/or remove it from the website.



## Tumour Review

## A basic review on systemic treatment options in WHO grade II-III gliomas

Maximilian J. Mair<sup>a</sup>, Marjolein Geurts<sup>b</sup>, Martin J. van den Bent<sup>b</sup>, Anna S. Berghoff<sup>a,\*</sup><sup>a</sup> Division of Oncology, Department of Medicine I, Medical University of Vienna, Waehringer Guertel 18-20, 1090 Vienna, Austria<sup>b</sup> The Brain Tumor Center at Erasmus Medical Center Cancer Institute, Dr.Molewaterplein 40, 3015 GD Rotterdam, the Netherlands

## ARTICLE INFO

## Keywords:

Glioma  
Astrocytoma  
Oligodendroglioma  
Temozolomide  
Chemotherapy

## ABSTRACT

WHO grade II-III gliomas are rare primary brain tumors occurring at a median age of about 35–55 years. Median survival is longer in WHO grade II-III glioma compared with WHO grade IV glioblastoma as survival times of up to 10 years and longer can be observed. Maximal safe resection and adjuvant therapies including chemotherapy and radiotherapy are the mainstay of treatment. Clinical trials in WHO grade II-III tumors are challenging due to the rarity and the long follow up times. The 2016 WHO Classification of Central Nervous Tumours introduced a new diagnostic framework relying on molecular characteristics, providing the definition of prognostically more homogenous subgroups compared to the histopathological analysis. Most available evidence on the adjuvant treatment of WHO II-III gliomas was generated in the pre-molecular era, challenging the interpretation of study results. The present review therefore summarizes the available data from prospective trials on systemic treatment options in WHO grade II-III glioma, considering molecular markers, recently published results and future outlooks in the field.

## Introduction

The overall age-adjusted incidence of malignant primary CNS tumors in the US reaches about 7.1/100000 [1]. The vast majority of primary CNS tumors are composed of diffuse gliomas, a clinical and molecular heterogeneous group of tumors deriving from glial precursor cells [1]. Whereas glioblastoma (WHO grade IV) accounts for approximately 55% of glioma [1], the remaining 45% of glial tumor are composed of several different histologies including grade II (diffuse) and grade III (anaplastic) astrocytoma as well as WHO grade II and III oligodendroglioma.

Maximal safe resection with preservation of neurological functioning is the major backbone of the therapeutic strategy as there is clear evidence that more extensive resections result in improved prognosis [2]. Furthermore, surgery follows a diagnostic scope as tissue sampling is needed to obtain a histological and molecular diagnosis to guide further treatment decisions. Despite aiming for radiologically complete resection, most patients eventually experience recurrence due to the infiltrative and disseminated growth pattern as single tumor cells can be found within far distance of the tumor [3]. Of note, the prognostic impact of the extent of resection is more pronounced in astrocytoma with isocitrate dehydrogenase (IDH) 1/2 mutations as compared to

oligodendroglioma [4]. Therefore, adjuvant therapeutic approaches are needed to delay tumor progression and improve survival. Several prospective trials therefore focused on the adjuvant treatment including radiotherapy as well as chemotherapy. Table 1 gives an overview on the investigated treatment modalities including radiotherapy and chemotherapy. In general, radiotherapy is applied at a dosage of 50–60 Gy at fractions of 1.8–2 Gy, as it has been shown that higher doses are not superior in terms of outcome but may come at the cost of more severe side effects and long-term toxicities [5].

The 2016 WHO Classification of Tumours of the Central Nervous System introduced the molecular definition of gliomas in addition to the so far established diagnosis based on histological characteristics [6]. High interobserver variability was frequently reported for the histopathological grading of glioma, underscoring the need for inclusion of objective parameters such as molecular markers to define the diagnosis [7,8]. The resulting considerable changes in glioma classification in consequence to the WHO 2016 version pose significant challenges for the treating physician. Therapeutic decisions mainly rely on clinical trials whose subjects were diagnosed based on histopathological features according to previous WHO classification versions with post-hoc molecular analyses; therefore, these diagnoses may not coincide with the results of a current diagnostic workup. In addition, the “Consortium

\* Corresponding author.

E-mail addresses: [maximilian.mair@meduniwien.ac.at](mailto:maximilian.mair@meduniwien.ac.at) (M.J. Mair), [m.geurts@erasmusmc.nl](mailto:m.geurts@erasmusmc.nl) (M. Geurts), [m.vandenbent@erasmusmc.nl](mailto:m.vandenbent@erasmusmc.nl) (M.J. van den Bent), [anna.berghoff@meduniwien.ac.at](mailto:anna.berghoff@meduniwien.ac.at) (A.S. Berghoff).

<https://doi.org/10.1016/j.ctrv.2020.102124>

Received 23 July 2020; Received in revised form 20 October 2020; Accepted 22 October 2020

Available online 13 November 2020

0305-7372/© 2020 The Author(s).

Published by Elsevier Ltd.

This is an open access article under the CC BY-NC-ND license

(<http://creativecommons.org/licenses/by-nc-nd/4.0/>).

**Table 1**  
Applied therapy regimens in WHO grade II-III glioma. PCV = procarbazine, lomustine (CCNU), vincristine; conc. = concomitant; adjuv. = adjuvant; RT = radiotherapy.

	1	2	3	4	5	6	7	8	9	10	11	12	13	14	15	16	17	18	19	20	21	22	23	24	25	26	27	28	29	
PCV (q6w) <sup>a</sup>								x	x	x	x	x	x	x	x	x	x	x	x	x										
o.																														
Lomustine 110 mg/m <sup>2</sup> p.o.	x																													
Vincristine 1.4 mg/m <sup>2</sup> i.v.																														
TMZ conc. <sup>b</sup>																														
o.																														
TMZ adjuv. (q4w)																														
o.																														
Procarbazine 60 mg/m <sup>2</sup> p.																														
o.																														
Temozolomide 150-200 mg/m <sup>2</sup> p.o.																														
o.																														

<sup>a</sup> Preceded by radiotherapy (54 Gy, 30 fractions of 1.8 Gy).

<sup>b</sup> During radiotherapy (RT, 50 – 60 Gy, fractions of 1.8 – 2 Gy, Monday - Friday), concomitant TMZ is administered on 7 days per week until completion of RT.

to Inform Molecular and Practical Approaches to CNS Tumor Taxonomy” (cIMPACT-NOW) was founded in 2016 to update with consensus papers between the release of two WHO classifications and ensure that upcoming important diagnostic markers are rapidly included [9]. Diffuse gliomas have also been addressed in updates from the cIMPACT-NOW consortium to respond to recent advances in this rapidly evolving field. The conduct of clinical trials in WHO grade II and III glioma is further complicated by the required duration of follow up, as overall survival reaches up to several years [10]. Therefore, the aim of this review is to give an overview on the evidence for adjuvant treatment in WHO grade II and III gliomas based on the 2016 WHO classification and recent cIMPACT-NOW updates.

### Integrated molecular diagnosis of glioma

Molecular analyses of IDH mutation and 1p19q codeletion are mandatory for the diagnostic work-up in WHO grade II-III glioma according to the 2016 WHO Classification of Tumours of the Central Nervous System. Fig. 1 provides an overview on the distribution, the median age at diagnosis as well as the median overall survival (data from [10–12]) in WHO grade II-III glioma.

#### (1) Mutations in the isocitrate dehydrogenase 1/2 (IDH) gene

More than 75% of lower-grade gliomas display IDH mutations, with the R132H mutation as the most frequently detected mutation [13]. Gain-of-function mutations of IDH lead to the increased formation of 2-hydroxyglutarate [14] and result in an extensive DNA methylation, which is responsible for deregulation of gene transcription and cellular dedifferentiation [15]. Clinically, IDH-mutated (IDH-mt) tumors are associated with longer survival [16,17] and higher response rates to chemotherapy [18,19] than their wild-type counterparts. Importantly, increasing evidence supports that IDH-wildtype (IDH-wt) astrocytoma, despite the pathological II or III grading, resemble WHO grade IV glioblastoma in terms of prognosis and molecular drivers. According to cIMPACT-NOW update 3, IDH-wt diffuse astrocytoma showing either epidermal growth factor receptor (EGFR) amplification, combined loss of chromosome 10 and gain of chromosome 7 or telomerase reverse transcriptase (TERT) promotor mutation are defined as IDH-wt low grade glioma with molecular features of glioblastoma [20]. Indeed, the prognosis of anaplastic astrocytoma patients without IDH mutation (IDH-wt) is significantly worse (median overall survival (OS) 19.4–20 months) compared to IDH-mt anaplastic astrocytoma (median OS 65–81.1 months) [16,17]. In addition, cIMPACT-NOW update 5 recommended to classify IDH-mt astrocytic gliomas showing histological characteristics of grade 4 tumors (i.e. microvascular proliferation or necrosis) and/or homozygous deletion of cyclin dependent kinase inhibitors 2A/2B (CDKN2A/2B) as IDH-mt astrocytoma, grade 4.

#### (2) Codeletion of the chromosome arms 1p and 19q

1p19q codeletion is the defining hallmark for IDH-mt oligodendroglioma according the WHO 2016 classification. In contrast to IDH mutations, its pathogenetic implications are still partly unclear; nevertheless, 1p19q codeletion is linked to longer survival [21] and better response towards cytotoxic agents [18,22]. 1p19q codeletion is mutually exclusive with loss of nuclear expression of alpha thalassemia mental retardation syndrome x-linked (ATRX). With regard to diffuse glioma, cIMPACT-NOW update 2 proposed that the diagnosis of diffuse astrocytoma (IDH-mt) can be assigned without further 1p19q testing in the case of clear astrocytic histology, IDH mutation and unequivocal loss of nuclear expression of ATRX and/or strong immunopositivity for p53 (detected by immunohistochemistry) [23]. This modified diagnostic approach using simple immunohistochemistry allows to spare more costly and complicated 1p19q testing in selected patients with the outlined clear-cut characteristics.

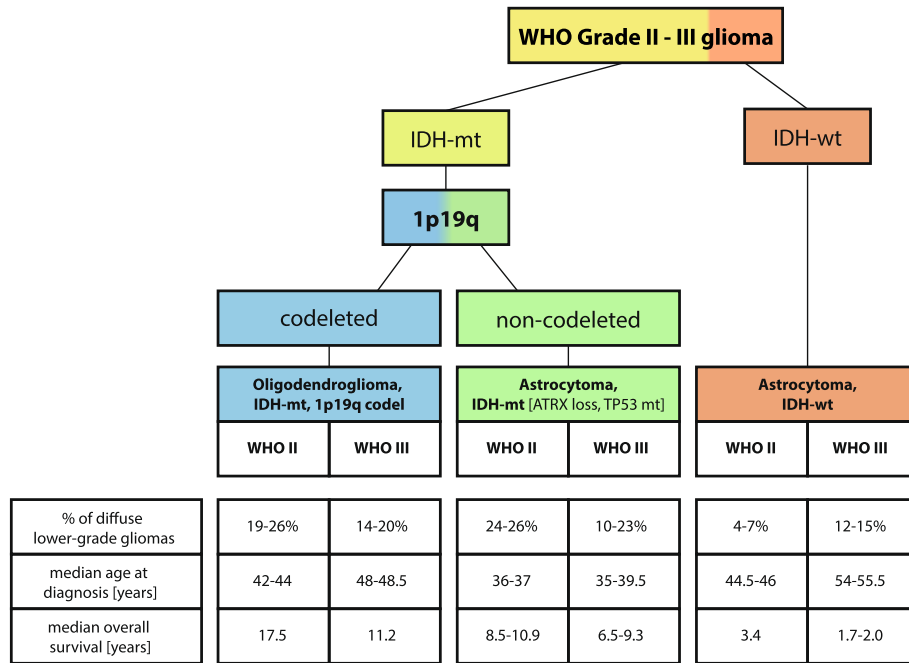


Fig. 1. WHO grade II-III glioma diagnosis according to the WHO Classification of Central Nervous Tumors 2016 including relative share of total LGG, median age at diagnosis and overall survival of LGG subgroups [10–12].

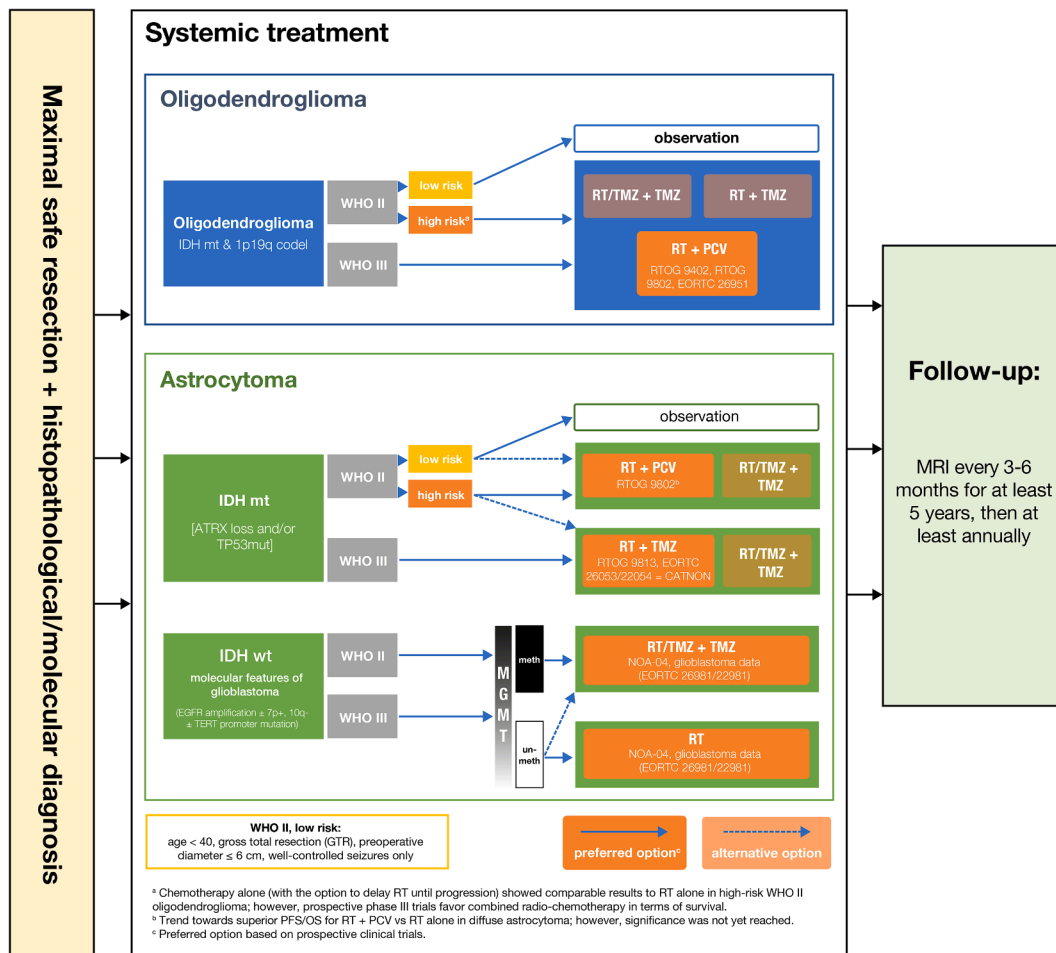


Fig. 2. Summary of the available evidence for adjuvant treatment strategies of WHO grade II-III glioma. References are given in the text.

In addition to these mandatory molecular markers for diagnosis, methylation of the O6-methylguanine-DNA transferase (MGMT) promoter is frequently included as a potentially predictive marker for response to alkylating chemotherapeutic agents in glioblastoma WHO grade IV. Initially, MGMT promoter methylation was investigated in a post-hoc analysis of the EORTC 26981/22981 glioblastoma trial which showed a survival benefit for the addition of temozolomide to radiotherapy in patients with newly diagnosed glioblastoma. MGMT methylation did not only have prognostic impact on survival, but was also predictive to the outcome to temozolomide [24]. Importantly, the large majority of IDH-mt gliomas present with MGMT methylation, resulting in limited additional predictive potential in IDH-mt gliomas [25]. This was also confirmed by a recently published post-hoc analysis on the RTOG 9802 trial, which is further discussed below [26]. However, in a subsequent analysis of the single-arm RTOG 0424 phase II trial investigating the addition of TMZ to radiotherapy only, MGMT was shown as an IDH-independent prognostic marker in high-risk WHO grade II glioma [27]. Therefore, MGMT methylation was also added as a post-hoc analysis in several WHO grade II and III glioma studies and is therefore discussed in the following paragraphs.

### Evidence on adjuvant treatment modalities in WHO grade II-III glioma

Most clinical trials investigating on adjuvant treatment modalities in WHO grade II-III glioma are from the pre-molecular era as the design was developed before the introduction of the WHO 2016 classification. In the following section, we will outline clinical trial results and point out molecular data and their implications on the efficacy of adjuvant therapies. A summary of the available evidence is given in Fig. 2.

#### WHO grade II glioma (IDH-mt)

Patients with IDH-mt WHO grade II glioma have a median survival of more than 10 years [28]. In light of the relatively young patient population (median age 36–42 years, Fig. 1), therapeutic procedures have to consider the benefit of prolonging survival at the cost of therapy-related side effects and toxicities. A long-term observation of health-related quality of life measures in low grade glioma found that patients had worse physical role functioning and general health perceptions than healthy controls [29]. Another long-term study in WHO grade II glioma survivors showed a progressive deterioration in neurocognitive functioning in patients who received radiotherapy compared to patients treated without adjuvant radiotherapy [30]. Combinational radiochemotherapy approaches were shown to be associated with decline in non-phonemic verbal fluency, mood and quality of life [31]. Moreover, due to the young patient age, fertility and reproductive outcomes remain an issue. On one hand, increased radiological growth rates and higher risks of tumor progression during pregnancy were reported [32,33]. On the other hand, radiotherapy involving the hypothalamus or pituitary gland may cause hormonal dysfunction and result in impaired reproductive outcomes. In addition, chemotherapy regimens including temozolomide (TMZ) or vincristine and procarbazine may reduce sperm counts and ovarian function [34,35].

Balancing benefits against risks of treatment-related long-term sequelae, prognostic factors are used as a basis for patient selection and define the patient population of WHO grade II “high risk” glioma patients likely to experience early tumor progression. Factors determining “high-risk” patients were primarily identified from post-hoc analyses of clinical trial populations in the pre-molecular era and were so far not validated in a prospective manner. The identified risk factors include older age, tumor size, presence of a midline-crossing tumor, preoperative magnetic resonance imaging (MRI) contrast enhancement, non-gross-total resection, astrocytic histology, presence of neurological symptoms or epileptic seizures and duration of first symptoms (Table 2) [28,36–39]. Subsequent clinical trials stratified or selected patients

**Table 2**

Available prognostic models for risk stratification in WHO grade II glioma. For Pignatti et al. [36], low-risk is defined as 0–2 risk factors present and high risk for 3–5 risk factors. For Gorlia et al. [38], prognostic stratification and survival estimates can be calculated on <http://www.eortc.be/tools/lggcalculator/calculator.aspx> [accessed on 2020/07/03].

	EORTC 22844/22845 (Pignatti et al. [36])	EORTC 22844/22845 (Gorlia et al. [38])
Age	Age $\geq$ 40 years	(not included)
Tumor diameter	Largest diameter of the tumor $\geq$ 6 cm	Largest diameter of the tumor $\geq$ 5 cm
Tumor location	Tumor crossing midline	(not included)
Histology	Astrocytic histology	Astrocytic histology
Neurological symptoms	Neurologic deficit present	Time since first symptoms $\geq$ 30 weeks
Treatment	(not included)	Treatment (delayed radiotherapy vs. immediate RT)

based on this “high risk” definition. Nevertheless, prospective studies including a molecular marker-based stratification of “high risk” are warranted.

The EORTC 22033-26033 trial defined high-risk patients by exhibiting at least one predefined feature including age  $>$ 40 years, progressive disease as diagnosed by radiology, tumor size  $>$ 5 cm, a tumor crossing the midline, new or worsening neurological symptoms or uncontrollable seizures [40]. The aim of the EORTC 22033-26033 was to compare adjuvant radiotherapy (50.4 Gy in fractions of 1.87 Gy) with adjuvant chemotherapy with temozolomide (TMZ, 75 mg/m<sup>2</sup> per day for 21 days, repeated every 28 days (one cycle) for up to 12 cycles or until disease progression or unacceptable toxicity) in high-risk WHO grade II glioma patients [40]. The primary study endpoint was progression-free survival (PFS). In the total study population, median PFS was 40.5 months in the TMZ group and 51.0 months in the radiotherapy arm (HR 1.18; 95%CI 0.87–1.60;  $p = 0.30$ ). IDH status was available in 392/477 (82.2%) and 1p19q status in 357/477 (74.8%) patients. 327/392 (83.4%) patients presented with IDH mutation and 117/357 (32.8%) with 1p19q deletion. Both IDH mutational status and 1p19q assessment were available in 318/477 (66.6%). In this subgroup, 104/318 (32.7%) IDH-mt/1p19q-codeleted oligodendrogliomas, 165/318 (51.9%) IDH-mt/1p19q-non-codeleted astrocytoma and 49/318 (15.4%) IDH-wt grade II glioma were included. Central histology review highlighted the diagnostic challenge to differentiate between grade II and grade III tumors, as 20/458 (4.4%) initially as grade II rated tumors were not confirmed in the central review (where available). In IDH-mt/1p19q-codeleted oligodendrogliomas ( $n = 104$ ) median PFS was 55.0 months in the TMZ group and 61.6 months in the radiotherapy group (HR 1.04; 95%CI 0.56–1.93;  $p = 0.91$ ). In IDH-mt/1p19q non-codeleted astrocytoma ( $n = 165$ ) median PFS was 19.4 months in the TMZ group and 42.5 months in the radiotherapy group (HR 1.86; 95%CI 1.21 – 2.87;  $p = 0.004$ ). In the small subgroup ( $n = 49$ ) of IDH-wt grade II glioma, median PFS was 28.9 months in the temozolomide group and 40.2 months in the radiotherapy group (HR 0.67; 95%CI 0.34–1.32;  $p = 0.24$ ). Long-term, mature follow-up on overall survival of this study is still pending.

In RTOG 9802, “high risk” was defined based on extent of resection and patient age, as patients were included if either aged 40 and older or having undergone non-gross total resection [41]. RTOG 9802 aimed to assess the efficacy of radiotherapy + chemotherapy containing procarbazine, lomustine (CCNU) and vincristine (PCV) in comparison to radiotherapy alone in WHO grade II gliomas. In the overall population, addition of PCV chemotherapy to radiotherapy significantly prolonged survival compared to radiotherapy alone (13.3 years vs. 7.8 years, HR = 0.59,  $p = 0.003$ ) [41]. IDH mutation could be investigated in 113/251 (45.0%) specimens, while conclusive 1p19q testing was available in only 63/251 (25.1%) of the whole population, and no subgroup analyses according to 1p19q status were initially provided. 36/56 (64.3%)

specimens in the PCV group presented with IDH mutation and 35/57 (61.5%) in the radiotherapy only group. The benefit of adjuvant PCV was most pronounced in IDH-mt grade II gliomas for both OS (HR 0.43,  $p = 0.009$ ) and PFS (HR = 0.36,  $p < 0.001$ ). Recently, the results of a post-hoc analysis incorporating further genetic markers have been published [26]. Most importantly, the beneficial effect of adjuvant PCV remained significant in both IDH-mt/1p19q-codeleted oligodendroglioma and IDH-mt astrocytoma in terms of OS and PFS, whereas the addition of PCV had no effect in the IDH-wt subgroup. In specific, OS in the molecular oligodendroglioma subgroup reached 13.9 years (radiotherapy) vs. not reached (radiotherapy + PCV, HR 0.21,  $p = 0.029$ ), while PFS was 5.8 years (radiotherapy) vs. not reached (radiotherapy + PCV, HR 0.13,  $p < 0.001$ ). In IDH-mt astrocytoma, OS was 4.3 years in radiotherapy vs. 11.4 years in the radiotherapy + PCV group (HR 0.38,  $p = 0.013$ ), while PFS was significantly worse in radiotherapy-only treated patients (3.3 years) than in those who received adjuvant PCV (10.4 years, HR = 0.32,  $p = 0.003$ ).

To spare the detrimental long-term effects of radiotherapy, chemotherapy alone has been studied as a treatment of high-risk WHO grade II glioma. Wahl et al. conducted a phase II study of adjuvant TMZ for 12 monthly cycles in grade II glioma with residual disease after resection [42]. Molecular subtype was known in 81% of patients, with 37% of oligodendroglioma, 31% IDH-mt astrocytoma and 13% IDH-wt glioma. Whereas radiographic responses could be observed in only 6% of patients, 81% showed stable disease. Survival times were comparable with that of the radiotherapy-only arm of the RTOG 9802 trial (PFS, OS). Of note, the benefit of TMZ-based adjuvant therapy was most pronounced in oligodendroglioma according to the WHO 2016 classification (IDH-mt/1p19q-codeleted), followed by IDH-mt astrocytoma and, lastly, IDH-wt glioma. Still, the results have to be interpreted cautiously as radiographic responses were not evaluated according to the Response Assessment in Neuro-Oncology (RANO) criteria [43], and no control arm was included. Another similarly designed trial with monthly TMZ for up to 18 cycles in high-risk WHO grade II glioma showed comparable results [44], with 48.3% of included patients with a diagnosis of oligodendroglioma, 15% of IDH-mt astrocytoma and 36.7% of IDH-wt astrocytoma. A response rate of 76% according to RANO criteria was reached in IDH-mt/1p19q-codeleted WHO grade II glioma, followed by 55% in IDH-mt astrocytoma and 36% in IDH-wt glioma. Furthermore, median PFS in the whole cohort was 3.4 years (95%CI: 2.2–4.3), while median OS equaled 9.2 years (95%CI: 8.2–11.9), which is again well comparable with the radiotherapy-only arm of RTOG 9802. Again, in contrast to the above-mentioned randomized controlled trial EORTC 22033-26033 which also investigated upfront chemotherapy, no formal comparison to a radiotherapy-receiving control cohort was performed. The currently available evidence (while still being limited for molecular subgroups) nevertheless favors a combined radio-chemotherapy approach in terms of survival.

In difference to “high risk” WHO II glioma patients, a watch and wait strategy is a well-accepted post-surgical strategy for “low risk” WHO II glioma patients. The IWOT (EORTC-BTG-1635) trial on IDH-mt grade II and III astrocytoma defines “low risk” patients by the absence of tumor-associated functional deficits except for post-surgical deficits, the absence of uncontrolled seizures as well as the absence of contrast enhancement on postoperative MRI except for surgery-associated alterations. In this cohort with favorable prognosis, an active surveillance will be compared with immediate post-operative adjuvant radiotherapy followed by adjuvant temozolomide (clinicaltrials.gov identifier: NCT03763422).

To conclude, the data on optimal adjuvant treatment strategies in IDH-mt WHO grade II gliomas are limited, with limited data on molecular alterations in the available prospective studies. No prospective trial so far differentiated between astrocytoma and oligodendroglioma as defined by the 2016 WHO classification based on molecular characteristics. Further, the risk assessment currently does not include molecular factors and is based on clinical features. Based on the available

evidence, the guidelines of the European Association for Neuro-Oncology (EANO) issued in 2017 [45] suggest radiotherapy + PCV or a watch-and-wait approach in IDH-mt WHO grade II-III glioma based on clinical risk factors such as age or the absence/presence of other neurological symptoms than seizures.

#### *Anaplastic oligodendroglioma (IDH-mt, 1p19q-codeleted) WHO grade III*

The role of adjuvant PCV following radiotherapy in anaplastic oligodendroglioma WHO grade III has been elucidated in RTOG 9402 [22] and EORTC 26951 [18]. These two randomized phase III trials compared radiotherapy only to radiotherapy plus adjuvant PCV in patients with oligodendroglioma. The EORTC 26951 trial investigated the sequence of radiotherapy followed by six cycles of PCV, while the RTOG 9402 investigated 4 cycles of PCV followed by radiotherapy. Molecular markers were not mandatory for inclusion but were analyzed in pre-planned or post-hoc analyses.

The EORTC 26951 trial included 368 patients. IDH status was available in 178/368 (48.4%) patients, while 1p19q codeletions were assessed in 316/368 (85.9%) patients. 81/178 (45.5%) patients presented with IDH mutation and 80/316 (25.3%) with 1p19q codeletion. Overall, only 90/161 (55.9%) of patients received all planned 6 cycles of PCV. 38% of patients stopped PCV due to toxicity. In the 1p19q-codeleted subgroup ( $n = 80$ ), adjuvant PCV did not significantly improve OS (HR 0.56, 95%CI 0.31–1.03) but PFS was significantly longer when compared to radiotherapy only (HR 0.42, 95%CI 0.24–0.74). Further, radiotherapy + PCV significantly prolonged OS and PFS in IDH-mt tumors irrespective of the oligodendroglioma-defining 1p19q status. Data on patients with both IDH mutations and 1p19q codeletions were published in a post-hoc analysis where targeted next-generation sequencing was performed [46]. 126 cases could be molecularly classified as either IDH-mt, 1p19q-non-codeleted astrocytoma ( $n = 20$ ), IDH-mt, 1p19q-codeleted oligodendroglioma ( $n = 46$ ) and IDH-wt, 1p19q-non-codeleted and 7+/10- or TERT promoter mutated molecular glioblastoma ( $n = 55$ ). However, molecular subtype was not shown to be correlated with response towards PCV chemotherapy although results have to be interpreted cautiously as the sample size was much lower than in the original trial population.

In the RTOG 9402 trial IDH status was assessed in 210/291 (72.2%) patients, while 263/291 (90.4%) patients were assessed for 1p19q codeletions [19,22]. 156/210 (74.3%) patients presented with IDH mutation and 126/263 (47.9%) with 1p19q codeletion. 70/147 (54%) patients in the PCV + radiotherapy arm completed all planned 4 full-dose cycles of PCV [47]. Longer OS was observed in the 1p19q-codeleted subgroup regardless of the applied treatment. Patients with 1p19q-codeleted tumors treated with radiotherapy + PCV had a better outcome compared to treatment with radiotherapy alone (OS 176.4 vs. 87.6 months, HR 0.59, 95% CI 0.37–0.95;  $p = 0.01$ ), while there was no statistically significant OS difference between radiotherapy and radiotherapy + PCV in non-codeleted tumors (32.4 vs 31.2 months; HR 0.85; 95% CI 0.58–1.23;  $p = 0.39$ ). In a subsequent analysis [19], IDH-mt tumors had improved OS and PFS after radiotherapy + PCV treatment, while patients with IDH-wt tumors did not show a statistically significant impact on OS due to the addition of PCV to radiotherapy (15.6 vs 21.6 months; HR 1.14, 95%CI 0.63–2.04;  $p = 0.67$ ) [19]. In both IDH-mt and 1p19q-codeleted tumors, meeting the molecular definition of oligodendroglioma according to the WHO 2016 definition, radiotherapy + PCV was superior to radiotherapy alone (176.4 vs 81.6 months; HR 0.49; 95%CI 0.28 – 0.85;  $p = 0.01$ ).

The NOA-04 trial compared adjuvant radiotherapy with chemotherapy with either PCV or TMZ in WHO grade III glioma patients [48]. Molecular analysis was available on IDH in 202/274 (73.7%) and on 1p19q status in 197/274 (71.9%) patients. 68/198 (34.3%) were classified as anaplastic oligodendroglioma based on the molecular profile. In this subgroup ( $n = 33$ ), no difference in PFS was observed between the treatment groups (HR 1.30; 95%CI 0.70 – 2.38;  $p = 0.416$ ). Although the

study was not powered for the comparison of PCV with TMZ, median PFS was improved in the PCV group (9.4 years vs 4.46 years;  $p = 0.0254$ ), while a numerical trend towards improved OS was observed (not reached vs. 8.09 years;  $p = 0.0689$ ) [48]. No proper comparison of PCV versus TMZ in patients with anaplastic oligodendroglioma is currently available.

The ongoing CODEL trial (EORTC 26081-22086) aims to address whether the PCV chemotherapy regimen could be substituted by TMZ. The initial three-arm design with radiotherapy only versus radiotherapy with concomitant TMZ followed by adjuvant TMZ (RT/TMZ + TMZ) versus radiotherapy + PCV was adapted due to the results of the RTOG 9402 and EORTC 26951 trials clearly supporting the addition of chemotherapy to radiotherapy compared to radiotherapy only. Besides, the French multi-center POLCA trial (NCT02444000) is designed to compare radiotherapy + PCV to PCV only in anaplastic oligodendroglioma. The latter option would allow to avoid the long-term impact of radiotherapy on quality of life and neurocognitive functioning, while keeping radiotherapy as a therapeutic option at tumor recurrence. The results of both the CODEL and POLCA trials remain to be awaited.

In summary, the available evidence favors radiotherapy + PCV as preferred regimen, as further data on the efficacy of TMZ-based radiochemotherapy are needed. However, even in anaplastic oligodendroglioma a watch-and-wait strategy may be taken into consideration in young patients after gross total resection and in the absence of neurological symptoms according to the EANO guidelines [45].

#### *Anaplastic astrocytoma (IDH-mt) WHO grade III*

Prognosis of anaplastic astrocytoma patients without IDH mutation is significantly worse (median OS 19.4–20 months) compared to anaplastic astrocytoma, IDH-mt (median OS 65–81.1 months) [16,17].

The RTOG 9813 trial was designed to compare radiotherapy + TMZ with radiotherapy + nitrosourea (either BCNU or CCNU) in anaplastic gliomas with less than 25% of oligodendroglial components [49]. IDH mutational status was determined in only 111/197 (56.3%) patients, no data regarding 1p19q status are available. In light of the missing molecular data, the transfer of the result to the modern definition of anaplastic astrocytoma is challenging. OS and PFS did not significantly differ between both treatment arms. However, after stratification and adjustment for pre-treatment characteristics, a statistically significant treatment effect in favor of TMZ was detected with regard to PFS (HR = 0.7, 95%CI 0.50–0.98,  $p = 0.039$ ). Importantly, only 21.4% of patients receiving nitrosourea-based therapy completed the protocol as planned, while 60.4% did so in the group treated with TMZ ( $p < 0.001$ ). Whereas chemotherapy was terminated in 27.8% of nitrosourea-receiving patients due to side effects, no toxicity-related therapy discontinuation at all was observed in subjects treated with TMZ.

The post-hoc molecular analysis of the RTOG 9402 and the EORTC 26951 trials revealed the inclusion of a significant fraction of patients actually presenting with anaplastic astrocytoma as defined by the molecular profile. 137/263 (52.1%) patients in the RTOG 9402 and 236/368 (64.1%) in the EORTC 26951 trial actually presented without 1p19q deletion and would therefore be classified as astrocytoma according to the WHO 2016 classification. Overall, no statistically significant clinical benefit of additional adjuvant PCV over radiotherapy alone could be shown for OS (31.2 vs. 32.4 months, HR 0.85, 95% CI 0.58–1.23;  $p = 0.39$ ) as well as for PFS (14.4 vs. 12 months, HR 0.81, 95% CI 0.56–1.16;  $p = 0.24$ ) in the RTOG 9402 trial [22]. EORTC 26951 suggested a beneficial effect of adjuvant PCV on PFS in the non-codeleted subgroup (14.8 vs. 8.7 months, HR 0.73, 95% CI 0.56 – 0.97,  $p = 0.026$ ), while there was no statistically significant difference in OS [18].

The NOA-04 trial included 72/274 (26.3%) patients with IDH-mt anaplastic astrocytoma. No difference between radiotherapy and chemotherapy was observed for IDH-mt anaplastic astrocytoma patients (survival times/hazard ratios not reported). Importantly, the study was not powered to compare TMZ with PCV, and in the anaplastic

astrocytoma cohort no difference between the chemotherapeutic approaches was evident. In the IDH-mt group, MGMT promoter methylation was not associated with PFS in either treatment group and had therefore neither prognostic nor predictive value [50]. However, only few IDH-mt tumors present with unmethylated MGMT promoter, limiting the power to detect statistically significant differences between IDH-wt and IDH-mt glioma.

The CATNON trial (EORTC 26053-22054) was the first prospective trial to specifically include anaplastic astrocytoma patients based on the molecular profile as 1p19q codeletion was determined as an exclusion criterion. In a  $2 \times 2$  factorial design, the efficacy of concomitant and adjuvant chemotherapy with TMZ was evaluated. Dosage and timing of TMZ were those of the EORTC 26981/22981 glioblastoma trial (75 mg/m<sup>2</sup> concomitant TMZ followed by 150–200 mg/m<sup>2</sup> adjuvant TMZ); however, up to 12 cycles of adjuvant chemotherapy were applied instead of 6. The protocol was amended to include the exploratory analysis of the impact of IDH mutations. IDH-mt anaplastic astrocytoma patients had significantly higher 5-year survival rates when adjuvant TMZ was added to radiotherapy compared to radiotherapy alone (5-year OS 76% vs. 68%, HR 0.63, 95% CI 0.43–0.91). Further, concomitant TMZ also resulted in an increase of the 5-year survival rate (5-year OS 83% vs. 60%, HR 0.46, 95% CI 0.32–0.67) in IDH-mt anaplastic astrocytoma patients. Concomitant TMZ in addition to adjuvant TMZ versus adjuvant TMZ alone did not present with a statistically significant benefit (5-year OS 84.4% vs. 80.4%;  $p = 0.258$ ). However, median OS was not reached with only 46 events in 194 subjects, and the data are therefore currently not yet mature enough to definitely answer the question whether radiotherapy/TMZ + TMZ is superior to radiotherapy + TMZ in IDH-mt patients [51].

To conclude, temozolomide-based radio-chemotherapy should now be considered as the standard of care in IDH-mt anaplastic astrocytoma based on the interim results of CATNON.

#### **Diffuse and anaplastic astrocytoma (IDH-wt) WHO grades II-III**

Increasing evidence from the molecular fingerprint of anaplastic astrocytoma without IDH mutation suggest most of these tumors rather resemble glioblastoma WHO grade IV on a molecular basis as well as in terms of prognosis. This is also reflected by the recent cIMPACT-NOW update 3, according to which IDH-wt glioma can be classified as “diffuse astrocytic glioma, IDH-wt, with molecular features of glioblastoma” in the presence of EGFR amplification, combined chromosome 10 loss/chromosome 7 gain or TERT promoter mutations [20]. Indeed, in a DNA methylation-based reclassification of a prospective CNS tumor cohort, 12% of histological diagnoses were changed and many of them were IDH-wt astrocytomas [52]. Of note, many cases of IDH-wt glioma WHO grade II-III were reclassified as IDH-wt glioblastoma, while others were designated as diffuse midline glioma, pleomorphic xanthoastrocytoma, (anaplastic) pilocytic astrocytoma, ganglioglioma, ependymoma, diffuse neuroectodermal tumor or medulloblastoma. These results suggest that IDH-wt gliomas are a heterogeneous group of tumors. While “glioblastoma-like” tumors may benefit from more aggressive treatment, this remains unclear for IDH-wt glioma which do not meet the diagnostic criteria as defined by cIMPACT-NOW. Further insights on the biological behavior of these tumors are needed to refine diagnostic definitions and to determine optimal treatment modalities.

Overall, response rates towards chemotherapy were shown to be lower in IDH-wt than in IDH-mt tumors [18,19]. Among these lines, in the CATNON trial (EORTC 26053-22054) IDH-wt patients did not have benefit of neither concomitant TMZ (HR 1.16, 95% CI 0.83–1.63) nor adjuvant TMZ (HR 1.03, 95% CI 0.73–1.44).

Data from the NOA-04 trials suggest that in IDH-wt astrocytoma the benefit of TMZ treatment is dependent on MGMT promoter methylation like in glioblastoma [24,48]. MGMT methylation was statistically significantly associated with response towards alkylating agents, while no impact of MGMT promoter methylation on therapy response was

observed in IDH-mt glioma [50]. Therefore, an MGMT methylation-adapted approach should be considered in patients with anaplastic astrocytoma without IDH mutation.

### Future perspectives: IDH inhibitors in IDH-1-mutant glioma

IDH mutations also occur in other solid and hematological malignancies such as acute myeloid leukemia (AML) and cholangiocarcinoma. In AML, the IDH-1 inhibitor ivosidenib was FDA-approved as durable remissions and a favorable side effect profile were observed in both newly-diagnosed as well as refractory disease [53,54]. Similarly, ivosidenib was shown to improve PFS in advanced, IDH-1-mutant cholangiocarcinoma [55].

In IDH-1-mutant glioma, a recently published phase I trial in 66 patients with advanced, IDH-1-mt WHO grade II-IV glioma showed that 85.7% of radiologically non-enhancing and 45.2% of enhancing gliomas achieved stable disease. Furthermore, the median PFS in non-enhancing glioma reached 13.6 months, while that of enhancing glioma was 1.4 months [56]. These results indicate that ivosidenib may be especially active in non-contrast enhancing lower-grade glioma. Moreover, the results of a phase I trial investigating the pan-IDH-1/2-mutant inhibitor vorasidenib have been presented recently [57]. Of note, an objective response rate of 18.2% was observed, and 72.7% of included patients had stable disease. Non-enhancing glioma patients under vorasidenib treatment reached a PFS of 31.4 months in median (95%CI: 11.2–40.8). However, results have to be taken cautiously as the patient number in these phase II trials was low and no control group was included; further randomized controlled trials such as the phase III INDIGO trial (NCT04164901) are warranted to confirm these positive signals.

### Conclusions

The interpretation of the available evidence in WHO grade II-III glioma is challenging. The application of the current WHO Classification in clinical practice yields diagnoses which do not correspond to the inclusion criteria of historical clinical trials. To take account of the modifications in the WHO Classification, the EANO issued updated guidelines for the treatment of glial tumors as outlined in the respective sections [45]. Some issues remain controversial, such as the still unproven non-inferiority of TMZ as compared to PCV, the justification of a watch-and-wait policy in certain subgroups of grade II gliomas and the value of MGMT promoter methylation in WHO grade II-III glioma. Although clinical trial inclusion is currently based on molecular markers, the completion of the currently running trials such as CODEL or IWOT will take many years due to low incidence and long survival of WHO grade II-III patients.

### Author contributions

MJM: Conceptualization; writing, review and editing of the manuscript draft.

MG: Conceptualization, writing, review and editing of the manuscript draft.

MvdB: Conceptualization, writing, review and editing of the manuscript draft.

ASB: Conceptualization, writing, review and editing of the manuscript draft.

All authors read and approved the final version of the manuscript.

### Declaration of Competing Interest

Anna Sophie Berghoff has research support from Daiichi Sankyo and honoraria for lectures, consultation or advisory board participation from Roche Bristol-Meyers Squibb, Merck, Daiichi Sankyo as well as travel support from Roche, Amgen and AbbVie. Martin van den Bent has received honoraria from Carthera, Genenta, Nerviano, Agios, Cellgene,

Abbvie, Boston Pharmaceuticals and Bayer.

All other authors have no conflicts of interest to declare.

### Acknowledgements

This review was performed within the PhD thesis project of Maximilian Mair with the title "Clinical and immunological characteristics associated with lower-grade glioma prognosis" in the Clinical Neurosciences (CLINS) program at the Medical University of Vienna.

### Funding

This research was funded by the research budget of the Medical University of Vienna.

### References

- [1] Ostrom QT, Gittleman H, Truitt G, Boscia A, Kruchko C, Barnholtz-Sloan JS. CBTUS statistical report: primary brain and other central nervous system tumors diagnosed in the United States in 2011–2015. *Neuro Oncol* 2018;20(iv1–86). <https://doi.org/10.1093/neuonc/now131>.
- [2] Jakola AS, Skjalsvik AJ, Myrnes KS, Sjøvik K, Unsgård G, Torp SH, et al. Surgical resection versus watchful waiting in low-grade gliomas. *Ann Oncol* 2017;28:1942–8. <https://doi.org/10.1093/annonc/mdx230>.
- [3] Capper D, Weissert S, Balss J, Habel A, Meyer J, Jäger D, et al. Characterization of R132H mutation-specific IDH1 antibody binding in brain tumors. *Brain Pathol* 2010. <https://doi.org/10.1111/j.1750-3639.2009.00352.x>.
- [4] Wijnenga MMJ, French PJ, Dubbink HJ, Dinjens WNM, Atmodimedjo PN, Kros JM, et al. The impact of surgery in molecularly defined low-grade glioma: an integrated clinical, radiological, and molecular analysis. *Neuro Oncol* 2018. <https://doi.org/10.1093/neuonc/nox176>.
- [5] Shaw E, Arusell R, Scheithauer B, O'Fallon J, O'Neill B, Dinapoli R, et al. Prospective randomized trial of low-versus high-dose radiation therapy in adults with supratentorial low-grade glioma: initial report of a North Central Cancer Treatment Group/Radiation Therapy Oncology Group/Eastern Cooperative Oncology Group Study. *J Clin Oncol* 2002;20:2267–76. <https://doi.org/10.1200/JCO.2002.09.126>.
- [6] Louis DN, Perry A, Reifenberger G, von Deimling A, Figarella-Branger D, Cavenee WK, et al. The 2016 world health organization classification of tumors of the central nervous system: a summary. *Acta Neuropathol* 2016;131:803–20. <https://doi.org/10.1007/s00401-016-1545-1>.
- [7] van den Bent MJ. Interobserver variation of the histopathological diagnosis in clinical trials on glioma: a clinician's perspective. *Acta Neuropathol* 2010;120:297–304. <https://doi.org/10.1007/s00401-010-0725-7>.
- [8] Aldape K, Simmons ML, Davis RL, Mücke R, Wiencke J, Barger G, et al. Discrepancies in diagnoses of neuroepithelial neoplasms: the San Francisco Bay Area Adult Glioma Study. *Cancer* 2000;88:2342–9.
- [9] Louis DN, Aldape K, Brat DJ, Capper D, Ellison DW, Hawkins C, et al. Announcing cIMPACT-NOW: the consortium to inform molecular and practical approaches to CNS tumor taxonomy. *Acta Neuropathol* 2017;133:1–3. <https://doi.org/10.1007/s00401-016-1646-x>.
- [10] Pekmezci M, Rice T, Molinaro AM, Walsh KM, Decker PA, Hansen H, et al. Adult infiltrating gliomas with WHO 2016 integrated diagnosis: additional prognostic roles of ATRX and TERT. *Acta Neuropathol* 2017;133:1001–16. <https://doi.org/10.1007/s00401-017-1690-1>.
- [11] Aoki K, Nakamura H, Suzuki H, Matsuo K, Kataoka K, Shimamura T, et al. Prognostic relevance of genetic alterations in diffuse lower-grade gliomas. *Neuro Oncol* 2018;20:66–77. <https://doi.org/10.1093/neuonc/now132>.
- [12] Reuss DE, Mamatjan Y, Schrimpf D, Capper D, Hovestadt V, Kratz A, et al. IDH mutant diffuse and anaplastic astrocytomas have similar age at presentation and little difference in survival: a grading problem for WHO. *Acta Neuropathol* 2015;129:867–73. <https://doi.org/10.1007/s00401-015-1438-8>.
- [13] Eckel-Passow JE, Lachance DH, Molinaro AM, Walsh KM, Decker PA, Sicotte H, et al. Glioma groups based on 1p/19q, IDH, and TERT promoter mutations in tumors. *N Engl J Med* 2015;372:2499–508. <https://doi.org/10.1056/NEJMoa1407279>.
- [14] Dang L, White DW, Gross S, Bennett BD, Bittinger MA, Driggers EM, et al. Cancer-associated IDH1 mutations produce 2-hydroxyglutarate. *Nature* 2009;462:739–44. <https://doi.org/10.1038/nature08617>.
- [15] Turcan S, Rohle D, Goenka A, Walsh LA, Fang F, Yilmaz E, et al. IDH1 mutation is sufficient to establish the glioma hypermethylation phenotype. *Nature* 2012;483:479–83. <https://doi.org/10.1038/nature10866>.
- [16] Sanson M, Marie Y, Paris S, Idbaih A, Laffaire J, Ducray F, et al. Isocitrate dehydrogenase 1 codon 132 mutation is an important prognostic biomarker in gliomas. *J Clin Oncol* 2009;27:4150–4. <https://doi.org/10.1200/JCO.2009.21.9832>.
- [17] Yan H, Parsons W, Jin G, McLendon R, Rasheed A, Yuan W, et al. IDH1 and IDH2 mutations in gliomas. *N Engl J Med* 2009;360:765–73. <https://doi.org/10.1056/NEJMoa0808710>.
- [18] van den Bent MJ, Brandes AA, Taphoorn MJB, Kros JM, Kouwenhoven MCM, Delattre J-Y, et al. Adjuvant procarbazine, lomustine, and vincristine



- chemotherapy in newly diagnosed anaplastic oligodendroglioma: long-term follow-up of EORTC brain tumor group study 26951. *J Clin Oncol* 2013;31:344–50. <https://doi.org/10.1200/JCO.2012.43.2229>.
- [19] Cairncross JG, Wang M, Jenkins RB, Shaw EG, Giannini C, Brachman DG, et al. Benefit from procarbazine, lomustine and vincristine in oligodendroglial tumors is associated with mutation of IDH. *J Clin Oncol* 2014;32:783–90. <https://doi.org/10.1200/JCO.2013.49.3726>.
- [20] Brat DJ, Aldape K, Colman H, Holland EC, Louis DN, Jenkins RB, et al. cIMPACT-NOW update 3: recommended diagnostic criteria for “Diffuse astrocytic glioma, IDH-wildtype, with molecular features of glioblastoma, WHO grade IV”. *Acta Neuropathol* 2018;136:805–10. <https://doi.org/10.1007/s00401-018-1913-0>.
- [21] Ramirez C, Bowman C, Maura CA, Dubois F, Blond S, Porchet N, et al. Loss of 1p, 19q, and 10q heterozygosity prospectively predicts prognosis of oligodendroglial tumors-towards individualized tumor treatment? *Neuro Oncol* 2010;12:490–9. <https://doi.org/10.1093/neuonc/nop071>.
- [22] Cairncross G, Wang M, Shaw E, Jenkins R, Brachman D, Buckner J, et al. Phase III trial of chemoradiotherapy for anaplastic oligodendroglioma: long-term results of RTOG 9402. *J Clin Oncol* 2013;31:337–43. <https://doi.org/10.1200/JCO.2012.43.2674>.
- [23] Louis DN, Giannini C, Capper D, Paulus W, Figarella-Branger D, Lopes MB, et al. cIMPACT-NOW update 2: diagnostic clarifications for diffuse midline glioma, H3 K27M-mutant and diffuse astrocytoma/anaplastic astrocytoma, IDH-mutant. *Acta Neuropathol* 2018;135:639–42. <https://doi.org/10.1007/s00401-018-1826-y>.
- [24] Hegi ME, Diserens A-C, Gorlia T, Hamou M-F, de Tribolet N, Weller M, et al. MGMT gene silencing and benefit from temozolomide in glioblastoma. *N Engl J Med* 2005;352:997–1003. <https://doi.org/10.1056/NEJMoa043331>.
- [25] Molinaro AM, Taylor JW, Wiencke JK, Wrensch MR. Genetic and molecular epidemiology of adult diffuse glioma. *Nat Rev Neurol* 2019;15:405–17. <https://doi.org/10.1038/s41582-019-0220-2>.
- [26] Bell EH, Zhang P, Shaw EG, Buckner JC, Barger GR, Bullard DE, et al. Comprehensive genomic analysis in NRG oncology/RTOG 9802: a phase III trial of radiation versus radiation plus procarbazine, lomustine (CCNU), and vincristine in high-risk low-grade glioma. *J Clin Oncol* 2020. <https://doi.org/10.1200/jco.19.02983>.
- [27] Bell EH, Zhang P, Fisher BJ, Macdonald DR, McElroy JP, Lesser GJ, et al. Association of MGMT promoter methylation status with survival outcomes in patients with high-risk glioma treated with radiotherapy and temozolomide: an analysis from the NRG oncology/RTOG 0424 trial. *JAMA Oncol* 2018;4:1405–9. <https://doi.org/10.1001/jamaoncol.2018.1977>.
- [28] Rasmussen BK, Hansen S, Laursen RJ, Kosteljanetz M, Schultz H, Nørgård BM, et al. Epidemiology of glioma: clinical characteristics, symptoms, and predictors of glioma patients grade I-IV in the Danish Neuro-Oncology Registry. *J Neurooncol* 2017;135:571–9. <https://doi.org/10.1007/s11060-017-2607-5>.
- [29] Boele FW, Douw L, Reijneveld JC, Robben R, Taphoorn MJB, Aaronson NK, et al. Health-related quality of life in stable, long-term survivors of low-grade glioma. *J Clin Oncol* 2015;33:1023–9. <https://doi.org/10.1200/JCO.2014.56.9079>.
- [30] Douw L, Klein M, Fagel SS, van den Heuvel J, Taphoorn MJ, Aaronson NK, et al. Cognitive and radiological effects of radiotherapy in patients with low-grade glioma: long-term follow-up. *Lancet Neuro* 2009;8:810–8. [https://doi.org/10.1016/S1474-4422\(09\)70204-2](https://doi.org/10.1016/S1474-4422(09)70204-2).
- [31] Correa DD, Shi W, Thaler HT, Cheung AM, DeAngelis LM, Abrey LE. Longitudinal cognitive follow-up in low grade gliomas. *J Neurooncol* 2008;86:321–7. <https://doi.org/10.1007/s11060-007-9474-4>.
- [32] Pallud J, Mandonnet E, Deroulers C, Fontaine D, Badoual M, Capelle L, et al. Pregnancy increases the growth rates of World Health Organization grade II gliomas. *Ann Neurol* 2010;67:398–404. <https://doi.org/10.1002/ana.21888>.
- [33] Yust-Katz S, De Groot JF, Liu D, Wu J, Yuan Y, Anderson MD, et al. Pregnancy and glial brain tumors. *Neuro Oncol* 2014;16:1289–94. <https://doi.org/10.1093/neuonc/nou019>.
- [34] Van Den Berg H, Furstner F, Van Den Bos C, Behrendt H. Decreasing the number of MOPP courses reduces gonadal damage in survivors of childhood Hodgkin disease. *Pediatr Blood Cancer* 2004;42:210–5. <https://doi.org/10.1002/psc.10422>.
- [35] Berthaut I, Montjean D, Dessolle L, Morcel K, Deluen F, Poirrot C, et al. Effect of temozolomide on male gametes: an epigenetic risk to the offspring? *J Assist Reprod Genet* 2013;30:827–33. <https://doi.org/10.1007/s10815-013-9999-8>.
- [36] Pignatti F, van den Bent M, Curran D, Debruyne C, Sylvester R, Therasse P, et al. Prognostic factors for survival in adult patients with cerebral low-grade glioma. *J Clin Oncol* 2002;20:2076–84. <https://doi.org/10.1200/JCO.2002.08.121>.
- [37] Chaichana KL, McGirt MJ, Latterra J, Olivi A, Quiñones-Hinojosa A. Recurrence and malignant degeneration after resection of adult hemispheric low-grade gliomas. *J Neurosurg* 2010;112:10–7. <https://doi.org/10.3171/2008.10.JNS08608>.
- [38] Gorlia T, Wu W, Wang M, Baumert BG, Mehta M, Buckner JC, et al. New validated prognostic models and prognostic calculators in patients with low-grade gliomas diagnosed by central pathology review: a pooled analysis of EORTC/RTOG/NCCTG phase III clinical trials. *Neuro Oncol* 2013;15:1568–79. <https://doi.org/10.1093/neuonc/not117>.
- [39] Van Den Bent MJ, Afra D, De Witte O, Ben Hassel M, Schraub S, Hoang-Xuan K, et al. Long-term efficacy of early versus delayed radiotherapy for low-grade astrocytoma and oligodendroglioma in adults: The EORTC 22845 randomised trial. *Lancet* 2005;366:985–90. [https://doi.org/10.1016/S0140-6736\(05\)67070-5](https://doi.org/10.1016/S0140-6736(05)67070-5).
- [40] Baumert BG, Hegi ME, van den Bent MJ, von Deimling A, Gorlia T, Hoang-Xuan K, et al. Temozolomide chemotherapy versus radiotherapy in high-risk low-grade glioma (EORTC 22033–26033): a randomised, open-label, phase 3 intergroup study. *Lancet Oncol* 2016;17:1521–32. [https://doi.org/10.1016/S1470-2045\(16\)30313-8](https://doi.org/10.1016/S1470-2045(16)30313-8).
- [41] Buckner JC, Shaw EG, Pugh SL, Chakravarti A, Gilbert MR, Barger GR, et al. Radiation plus procarbazine, CCNU, and vincristine in low-grade glioma. *N Engl J Med* 2016;374:1344–55. <https://doi.org/10.1056/NEJMoa1500925>.
- [42] Wahl M, Phillips JJ, Molinaro AM, Lin Y, Perry A, Haas-Kogan DA, et al. Chemotherapy for adult low-grade gliomas: clinical outcomes by molecular subtype in a phase II study of adjuvant temozolomide. *Neuro Oncol* 2017;19:242–51. <https://doi.org/10.1093/neuonc/now176>.
- [43] van den Bent MJ, Wefel JS, Schiff D, Taphoorn MJB, Jaeckle K, Junck L, et al. Response assessment in neuro-oncology (a report of the RANO group): assessment of outcome in trials of diffuse low-grade gliomas. *Lancet Oncol* 2011;12:583–93. [https://doi.org/10.1016/S1470-2045\(11\)70057-2](https://doi.org/10.1016/S1470-2045(11)70057-2).
- [44] Rudà R, Pellerino A, Pace A, Maria C, Cristina C, Manuela D, et al. Efficacy of initial temozolomide for high - risk low grade gliomas in a phase II AINO (Italian Association for Neuro - Oncology) study : a post - hoc analysis within molecular subgroups of WHO 2016. *J Neurooncol* 2019;145:115–23. <https://doi.org/10.1007/s11060-019-03277-x>.
- [45] Weller M, van den Bent M, Tonn JC, Stupp R, Preusser M, Cohen-Jonathan-Moyal E, et al. European Association for Neuro-Oncology (EANO) guideline on the diagnosis and treatment of adult astrocytic and oligodendroglial gliomas. *Lancet Oncol* 2017;18:e315–29. [https://doi.org/10.1016/S1470-2045\(17\)30194-8](https://doi.org/10.1016/S1470-2045(17)30194-8).
- [46] Dubbink HJ, Atmodimedjo PN, Kros JM, French PJ, Sanson M, Idbaih A, et al. Molecular classification of anaplastic oligodendroglioma using next-generation sequencing: a report of the prospective randomized EORTC Brain Tumor Group 26951 phase III trial. *Neuro Oncol* 2016;18:388–400. <https://doi.org/10.1093/neuonc/nov182>.
- [47] Cairncross G, Berkey B, Shaw E, Jenkins R, Scheithauer B, Brachman D, et al. Phase III trial of chemotherapy plus radiotherapy compared with radiotherapy alone for pure and mixed anaplastic oligodendroglioma: intergroup radiation therapy oncology group trial 9402. *J Clin Oncol* 2006;24:2707–14. <https://doi.org/10.1200/JCO.2005.04.3414>.
- [48] Wick W, Roth P, Hartmann C, Hau P, Nakamura M, Stockhammer F, et al. Long-term analysis of the NOA-04 randomized phase III trial of sequential radiochemotherapy of anaplastic glioma with PCV or temozolomide. *Neuro Oncol* 2016;18:1529–37. <https://doi.org/10.1093/neuonc/now133>.
- [49] Chang S, Zhang P, Cairncross JG, Gilbert MR, Bahary JP, Dolinkas CA, et al. Phase III randomized study of radiation and temozolomide versus radiation and nitrosourea therapy for anaplastic astrocytoma: results of nrg oncology RTOG 9813. *Neuro Oncol* 2017;19:252–8. <https://doi.org/10.1093/neuonc/now23>.
- [50] Wick W, Meisner C, Hentschel B, Platten M, Schilling A, Wiestler B, et al. Prognostic or predictive value of MGMT promoter methylation in gliomas depends on IDH1 mutation. *Neurology* 2013;81:1515–22. <https://doi.org/10.1212/WNL.0b013e3182a95680>.
- [51] Van Den Bent MJ, Erridge S, Vogelbaum MA, Nowak AK, Sanson M, Brandes AA, et al. Second interim and first molecular analysis of the EORTC randomized phase III intergroup CATNON trial on concurrent and adjuvant temozolomide in anaplastic glioma without 1p/19q codeletion. *J Clin Oncol* 2019;37:2000. [https://doi.org/10.1200/JCO.2019.37.15\\_suppl.2000](https://doi.org/10.1200/JCO.2019.37.15_suppl.2000).
- [52] Capper D, Jones DTW, Sill M, Hovestadt V, Schrimpf D, Sturm D, et al. DNA methylation-based classification of central nervous system tumours. *Nature* 2018;555:469–74. <https://doi.org/10.1038/nature26000>.
- [53] DiNardo CD, Stein EM, De Botton S, Roboz GJ, Altman JK, Mims AS, et al. Durable remissions with ivosidenib in IDH1-mutated relapsed or refractory AML. *N Engl J Med* 2018;378:2386–98. <https://doi.org/10.1056/NEJMoa1716984>.
- [54] Roboz GJ, DiNardo CD, Stein EM, de Botton S, Mims AS, Prince GT, et al. Ivosidenib induces deep durable remissions in patients with newly diagnosed IDH1-mutant acute myeloid leukemia. *Blood* 2020;135:463–71. <https://doi.org/10.1182/blood.2019002140>.
- [55] Abou-Alfa GK, Macarulla T, Javle MM, Kelley RK, Lubner SJ, Adeva J, et al. Ivosidenib in IDH1-mutant, chemotherapy-refractory cholangiocarcinoma (ClarIDHy): a multicentre, randomised, double-blind, placebo-controlled, phase 3 study. *Lancet Oncol* 2020;21:796–807. [https://doi.org/10.1016/S1470-2045\(20\)30157-1](https://doi.org/10.1016/S1470-2045(20)30157-1).
- [56] Mellingshoff IK, Ellingson BM, Touat M, Maher E, De La Fuente MI, Holdhoff M, et al. Ivosidenib in isocitrate dehydrogenase 1 - mutated advanced glioma. *J Clin Oncol* 2020. <https://doi.org/10.1200/jco.19.03327>.
- [57] Mellingshoff IK, Peters KB, Cloughesy TF, Burris III HA, Maher EA, Janku F, et al. Vorasidenib (VOR; AG-881), an inhibitor of mutant IDH1 and IDH2, in patients (pts) with recurrent/progressive glioma: updated results from the phase I non-enhancing glioma population. *J Clin Oncol* 2020;38:2504. [https://doi.org/10.1200/JCO.2020.38.15\\_suppl.2504](https://doi.org/10.1200/JCO.2020.38.15_suppl.2504).