

## Original article

# During development of rheumatoid arthritis, intermetatarsal bursitis may occur before clinical joint swelling: a large imaging study in patients with clinically suspect arthralgia

Bastiaan T. van Dijk <sup>1</sup>, Fenne Wouters <sup>1</sup>, Elise van Mulligen <sup>2</sup>,  
Monique Reijnen<sup>3</sup> and Annette H.M. van der Helm-van Mil<sup>1,2</sup>

## Abstract

**Objectives.** Intermetatarsal bursitis (IMB) represents juxta-articular synovial inflammation of the intermetatarsal bursae. Recent MRI studies identified IMB as feature of early RA, but whether IMB already occurs in the pre-arthritis phase is unknown. We performed a large MRI study in clinically suspect arthralgia (CSA) to assess the occurrence and prognostic value of IMB.

**Methods.** A total of 577 consecutive CSA patients underwent contrast-enhanced MRI of the forefoot, metacarpophalangeal joints and wrist. MRIs were evaluated for subclinical synovitis/tenosynovitis/osteitis in line with the RA MRI scoring system (summed as RAMRIS inflammation) and for IMB. IMB was considered present if uncommon in the general population at the same location (i.e. size scored above the 95th percentile in age-matched symptom-free controls). The relation of IMB with other MRI-detected subclinical inflammation (synovitis/tenosynovitis/osteitis) was studied. Cox-regression assessed the association with clinical arthritis development during median 25 months follow-up. ACPA stratification was performed.

**Results.** At presentation with CSA, 23% had IMB. IMB was more frequent in ACPA-positive than ACPA-negative CSA (47% vs 19%,  $P < 0.001$ ). Patients with IMB were more likely to also have subclinical synovitis [OR 3.4 (95% CI 1.8, 6.5)] and tenosynovitis [5.9(2.8, 12.6)]. IMB conferred higher risk of developing arthritis [HR 1.6(1.0–2.7) adjusted for other subclinical inflammation]. IMB-presence predicted arthritis development in ACPA-positive CSA [adjusted HR 2.2(1.0–4.7)], but not in ACPA-negative CSA-patients [0.8(0.4–1.7)].

**Conclusion.** Approximately a quarter of CSA patients have IMB, which is frequently accompanied by subclinical synovitis and tenosynovitis. IMB precedes development of clinical arthritis, particularly in ACPA-positive CSA. These results reinforce the notion that juxta-articular synovial inflammation is involved in the earliest phases of RA development.

**Key words:** RA, MRI, inflammation, foot, epidemiology, synovium, biomarkers

### Rheumatology key messages

- Inflammation of the synovium-lined intermetatarsal bursae occurs in 23% of clinically suspect arthralgia (CSA) patients.
- Intermetatarsal bursitis (IMB) may precede development of clinical arthritis and particularly predicts ACPA-positive RA.
- These results support the notion that juxta-articular synovial inflammation is involved in the earliest phases of RA development.

<sup>1</sup>Department of Rheumatology, Leiden University Medical Centre, Leiden, <sup>2</sup>Department of Rheumatology, Erasmus Medical Centre, Rotterdam and <sup>3</sup>Department of Radiology, Leiden University Medical Centre, Leiden, The Netherlands

Submitted 30 June 2021; accepted 27 October 2021

Correspondence to: B. T. van Dijk, Department of Rheumatology, Leiden University Medical Centre, P.O. Box 9600, 2300 RC Leiden, The Netherlands. E-mail: b.t.van\_dijk@lumc.nl

## Introduction

RA is traditionally known for targeting the synovial lining of small joints, which leads to intra-articular synovitis. There is increasing awareness that synovial tissue outside the joint capsules (juxta-articular) exists and is frequently inflamed as well. For instance, tendons around small hand and foot joints are surrounded by a synovial sheath that is frequently affected in RA, leading to tenosynovitis. Tenosynovitis at the small joints is detectable by MRI, has a high specificity for early RA and contributes to RA-related symptoms [1–4].

Similarly to tendon sheaths around small hand and foot joints, the bursae situated between the metatarsal heads also possess a synovial lining that may become inflamed, leading to intermetatarsal bursitis (IMB) [5–8]. These bursae form a distinct tissue without anatomical connection to the MTP joints and have a physiological function in reducing mechanical strain and friction [5]. Recently, an MRI study showed that IMB is present in two-thirds of early RA patients and is highly specific for RA in comparison to healthy controls [9]. Moreover, IMB frequently accompanies other RA-related synovial inflammation (synovitis and tenosynovitis), contributes to local joint swelling and tenderness and seems responsive to treatment with DMARDs [10]. Therefore, IMB may be considered a novel feature of juxta-articular synovial inflammation in RA.

Despite these properties of IMB in early RA, MRI-detected IMB has never been systematically studied in the pre-arthritis phase. In contrast to IMB, tenosynovitis has been studied extensively, showing that it is among the first tissues where inflammation manifests and associates with development of clinical arthritis in at-risk populations [11–17]. This gives rise to the hypothesis that IMB, which like tenosynovitis represents juxta-articular synovial inflammation, might also precede RA, as suggested by some case reports [18, 19]. Therefore, we performed a large MRI study in patients with clinically suspect arthralgia (CSA) to assess the occurrence of IMB and whether its relation with synovitis and tenosynovitis as found in early RA is already present. In addition, we studied the prognostic value of IMB for development of clinical arthritis, for both ACPA-positive and ACPA-negative CSA patients.

## Methods

### Patients

The prospective CSA cohort is based in the Leiden University Medical Centre (LUMC) in the Netherlands and has been described in detail previously [20]. In short, since 2012 this cohort has enrolled patients with recent-onset (<1 year) arthralgia of the small joints who were at increased risk of developing RA according to the clinical expertise of their rheumatologist. Inclusion was not based on positivity for auto-antibodies; in accordance with national guidelines for general practitioners (GPs)

these are generally not tested in primary care. Importantly, CSA does not comprise patients in whom clinical arthritis is already present or when another cause of the arthralgia is more likely (e.g. osteoarthritis, fibromyalgia, injury). Previous research demonstrated that this definition of CSA, based on clinical expertise and pattern recognition, indeed confers a strongly increased risk of developing RA [21].

At baseline, physical joint examination was conducted, blood tests were performed (including IgG ACPA and IgM RF). In addition, MRI was performed in absence of contra-indications. For the current study, we assessed 577 consecutive CSA patients who underwent MRI at baseline between July 2013 and March 2020, since contrast-enhanced MRI sequences of the forefoot were added to the CSA protocol in July 2013 (for the flowchart, see [Supplementary Fig. S1](#), available at *Rheumatology* online).

The CSA study was conducted in accordance with the Declaration of Helsinki and its protocol was approved by the medical ethical committee of the Leiden University Medical Centre (Commissie Medische Ethiek LUMC; file number P11.210). All patients provided written informed consent.

### MRI scanning and scoring

At baseline, unilateral contrast-enhanced 1.5T MRIs (ONI, GE, WI, USA) were made of the MTP(1st–5th), MCP(2nd–5th) and wrist joints of the side with the most symptoms, or the dominant side in case of equally severe symmetrical symptoms. MRIs were evaluated for synovitis, tenosynovitis and osteitis in line with the RA MRI scoring system (RAMRIS) by two independent trained readers, as reported previously [22–25]. The scanning protocol and RAMRIS scoring are described extensively in [Supplementary Data S1](#), available at *Rheumatology* online.

In addition, MRIs of the forefoot were evaluated for IMB. The intermetatarsal bursae are situated in the superior intermetatarsal spaces, which lie in between the intermetatarsal heads, the deep transverse metatarsal ligament and the deep dorsal aponeurosis [5, 7]. IMB was therefore defined as contrast-enhancement of the bursa in the superior intermetatarsal space, with or without rim enhancement on  $\geq 2$  consecutive slices in the axial and coronal plane [9]. At each of the four superior intermetatarsal spaces, IMB presence and size were recorded by a single trained reader as published previously [10]. For IMB size, the dorsoplantar dimension was used because the bursae are confined transversally by the metatarsal heads and may, theoretically, distend in dorsoplantar direction more freely [26].

MRI scoring was done blinded for clinical data. In addition, IMB and RAMRIS inflammation were evaluated separately by different readers, unaware of each other's scores.

Reliability was ascertained by calculating intra-class correlation coefficients (ICCs). For IMB size, the intrareader ICC was 0.87. For the RAMRIS,

inter- and intrareader ICCs were  $\geq 0.90$  as published previously [23].

#### Defining positivity of RAMRIS inflammation and IMB

Positivity for subclinical RAMRIS inflammation was defined using healthy controls as reference, as described previously: synovitis, tenosynovitis or osteitis was considered present if scored by both readers in a severity that was present at the same location in  $< 5\%$  of age-matched healthy controls [27, 28]. Reference scores were determined in a previous study of 193 healthy controls using the same MRI machine [27].

Also, for IMB it was deemed important to discern possibly pathologic lesions from normal variations, because small amounts of bursal fluid are considered common in healthy individuals [29]. Therefore, measurements of healthy controls were also applied to determine IMB positivity [9, 27]. Patients were considered to have IMB if they had  $\geq 1$  IMB that was uncommon in healthy controls, i.e. an IMB size exceeding the 95th percentile in age-matched symptom-free controls (with IMB size equal to zero if IMB was absent). Age matching was performed because older, symptom-free controls had IMB more often (Supplementary Fig. S2, available at *Rheumatology* online). In addition, reference values were determined separately for each intermetatarsal space because the frequency of IMB is known to differ per location [9]. For example, in patients aged  $< 40$  years any bursal contrast enhancement between MTP1 and MTP2 was considered as IMB, while in patients aged  $\geq 60$ , only contrast enhancement  $\geq 12$  mm was considered as IMB (for all reference values, see Supplementary Table S1, available at *Rheumatology* online). Finally, no distinction was made between men and women because sex was not statistically significantly associated with IMB presence and size in symptom-free controls (Supplementary Fig. S2, available at *Rheumatology* online).

#### Outcome

The primary outcome was development of clinical arthritis, defined as joint swelling palpable at physical joint examination. Also, joints not assessed by MRI were considered at outcome assessment. The full 66 swollen joint count-66 was used during examinations. Thus, the primary outcome was defined as a swollen joint count-66  $\geq 1$ . Follow-up visits were scheduled at 4/12/24 months, but patients could come in for an additional visit whenever their symptoms required, to ensure timely detection of clinical arthritis. Electronic hospital records were reviewed until 2.5 years after inclusion or until 27 January 2021 (whichever came first). Patients and clinicians were unaware of IMB presence at baseline, allowing unbiased outcome assessment.

Treatment with disease-modifying anti-rheumatic drugs (DMARDs, including systemic or intra-articular corticosteroids) was not allowed during follow-up in the CSA cohort, thus before reaching the outcome. CSA

patients who presented between April 2015 and August 2019 were, however, eligible for participation in a randomized placebo-controlled trial (RCT) studying the efficacy of methotrexate to prevent RA development if they had subclinical inflammation (synovitis/tenosynovitis/osteitis) on MRI [30]. These trial participants were excluded from current prognostic analyses due to their 50% chance of methotrexate use (Supplementary Fig. S1, available at *Rheumatology* online). Within patients who would have been eligible for the RCT based on presence of subclinical RAMRIS inflammation, there were no clinically relevant differences in baseline characteristics regarding clinical variables, IMB and RAMRIS inflammation parameters, between those who were and were not included in the RCT (Supplementary Table S2, available at *Rheumatology* online).

#### Statistical analyses

Patient-level associations between IMB presence and RAMRIS inflammation at the MTP joints were assessed using univariable logistic regression. Multivariable analyses with all three RAMRIS inflammation features (synovitis, tenosynovitis, osteitis) as separate independent variables were also performed.

In addition, associations between IMB presence and RAMRIS inflammation were assessed at the local level, namely at individual intermetatarsal bursae with the two MTP joints located next to it. Here, generalized estimating equations (GEEs) were used wherein each patient contributed four intermetatarsal bursae ( $n = 2308$  bursae). Presence of IMB was the outcome variable and presence of RAMRIS inflammation in the two MTP joints neighbouring the bursa was the independent variable.

The relation between IMB presence and development of clinical arthritis was studied using Kaplan–Meier curves and Cox-regression. Multivariable Cox-regression analyses were used to adjust for presence of RAMRIS inflammation features (synovitis, tenosynovitis and osteitis at the MTP, MCP or wrist joints), and to assess whether IMB predicts clinical arthritis development independent of variables previously identified as prognostic [15].

Analyses were repeated with stratification for ACPA status. IBM SPSS (version 25) was used. Two-sided  $P$ -values  $< 0.05$  were considered statistically significant.

#### Sensitivity analyses

Longitudinal analyses were repeated using RA development as outcome (fulfilment of the 2010 or 1987 criteria for RA, or a clinical diagnosis of RA with initiation of DMARDs) [31, 32]. In addition, the prognostic value of IMB was assessed in CSA patients who fulfilled the EULAR definition of arthralgia suspicious for progression to RA, as fulfilling this on top of the clinical diagnosis of CSA confers a slightly higher risk of RA development and may aid generalizability to other CSA populations [33, 34].

## Results

### Patients

In total, 35% of patients (203/577) had any IMB, without correction for normal variations in the general population. The frequency of IMB at each intermetatarsal space is presented in Fig. 1A. The third intermetatarsal space (between MTP3 and 4) was most frequently affected (24%). The relative distribution of IMB between intermetatarsal spaces was similar in ACPA-positive and ACPA-negative patients (Fig. 1B and C).

A total of 23% of all CSA patients (131/577) had  $\geq 1$  IMB larger than the normal reference and were therefore considered positive for IMB. Henceforth, presence of IMB refers to IMB exceeding the reference obtained from healthy controls.

Baseline characteristics are presented in Table 1. On average, patients with IMB more often had increased CRP (34% vs 19%,  $P=0.004$ ), and were more often ACPA-positive (28% vs 9%,  $P<0.001$ ) and RF-positive (35% vs 15%,  $<0.001$ ).

Out of 78 ACPA-positive CSA patients, 60 were also positive for RF (ACPA+/RF+). These ACPA+/RF+ patients had IMB more often than ACPA+/RF- patients (58% vs 11%,  $P<0.001$ ).

### IMB particularly accompanies tenosynovitis and synovitis

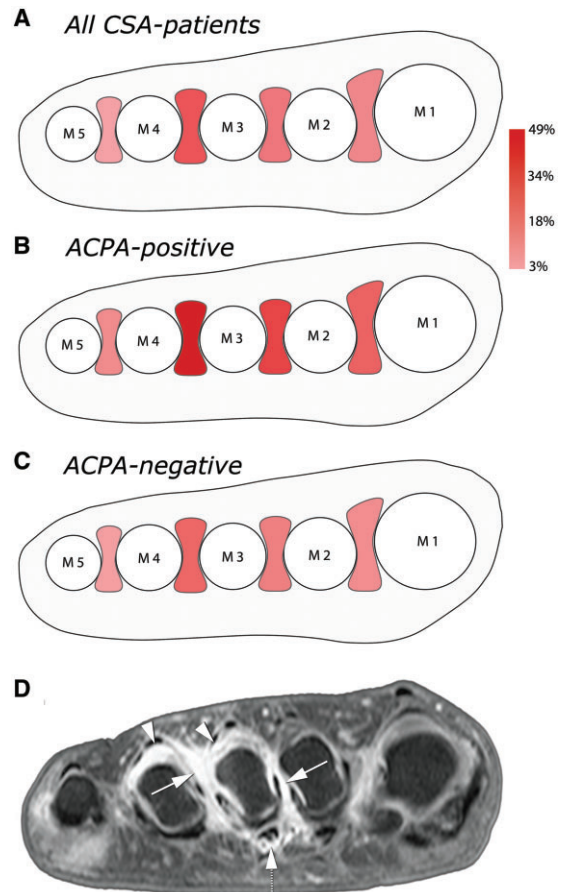
Patients with MRI-detected IMB were more likely to have synovitis, tenosynovitis and/or osteitis at the MTP-joints (Table 2). Because these features may co-occur, multivariable analyses were also performed, which showed that presence of synovitis [OR 3.4 (95% CI 1.8, 6.5)] and tenosynovitis [5.9(2.8, 12.6)] was independently associated with IMB presence. Similar findings were obtained in analyses at the local level (Table 3). In summary, IMB was particularly accompanied by synovial inflammation at the MTP joints (synovitis) and in tendon sheaths (tenosynovitis), but not by inflammation in metatarsal bones (osteitis).

Fig. 1D shows an example MR image of synovitis and tenosynovitis co-occurring with IMB. Additional examples of IMB of different severity are presented in Supplementary Fig. S3, available at *Rheumatology* online.

### ACPA status in relation to IMB presence and RAMRIS inflammation

Analyses were stratified for ACPA status, because ACPA-positive and ACPA-negative RA harbour differences in pathophysiology [35, 36]. Tenosynovitis was independently associated with IMB presence in both groups (Table 2). The association with synovitis was statistically significant in ACPA-negative and not ACPA-positive CSA [OR 3.6(1.7–7.4) vs 2.2(0.5–10.1)]. Local level analyses in both groups showed that synovitis and tenosynovitis were more often present at MTP joints with adjacent IMB (Table 3).

**Fig. 1** Heatmaps of IMB presence per intermetatarsal space (A, B, C) and MRI example of IMB co-occurring with synovitis and flexor-tenosynovitis (D)



**A–C** IMB of any size is included in the heatmaps, without correction for normal variations in the general population. M1 to M5: metatarsal heads 1 to 5. **A** Percentages: 4% (M5-M4); 24% (M4-M3); 15% (M3-M2); 11% (M2-M1) **B** Percentages: 10% (M5-M4); 49% (M4-M3); 29% (M3-M2); 21% (M2-M1) **C** Percentages: 3% (M5-M4); 20% (M4-M3); 13% (M3-M2); 9% (M2-M1) **D** Coronal T1-weighted fat suppressed images after gadolinium administration of the forefoot at the level of the metatarsal heads of a female CSA patient aged 47 years. Arrows: enhancement of thickened synovium in the 2nd and 3rd intermetatarsal space, consistent with IMB. Dotted arrow: enhancement at the 3rd MTP joint surrounding the flexor tendon at the 3rd MTP joint, consistent with tenosynovitis. Arrowheads: synovitis at the 3rd and 4th MTP joint. CSA: clinically suspect arthralgia; IMB: intermetatarsal bursitis; MR: magnetic resonance.

### IMB presence at presentation associates with increased risk of clinical arthritis development

During follow-up, 76 of 469 patients (16%) developed clinical arthritis after median 18 weeks (IQR 4–35). Median follow-up of patients who did not develop clinical arthritis was 110 weeks (68–117). Kaplan–Meier curves

**TABLE 1** Baseline characteristics of all CSA patients and according to presence of IMB

	IMB at baseline			P
	All (n = 577)	Present (n = 131)	Absent (n = 446)	
Age in years, mean (s.d.)	44 (13)	43 (12)	45 (13)	0.25
Female, n (%)	433 (75)	100 (76)	333 (74)	0.73
BMI, mean (s.d.)	27 (5)	27 (6)	27 (5)	0.59
Symptom duration in weeks, median (IQR)	20 (9–43)	19 (8–40)	20 (10–46)	0.51
TJC-68, median (IQR)	5 (2–9)	5 (2–8)	5 (2–10)	0.85
≥1 tender MTP joint, n (%)	256 (45)	64 (50)	192 (44)	0.27
ACPA-positive, n (%)	78 (14)	37 (28)	41 (9)	<0.001
RF-positive, n (%)	111 (19)	46 (35)	65 (15)	<0.001
ACPA- and RF-positive, n (%)	60 (10)	35 (27)	25 (6)	<0.001
Increased CRP (≥5 mg/L), n (%)	130 (23)	44 (34)	86 (19)	0.001
Locations with IMB, <sup>a</sup> mean (s.d.)	0.3 (0.7)	1.5 (0.7)	—	—

<sup>a</sup>Range: 0–4 (the number of intermetatarsal spaces on one side). CSA: clinically suspect arthralgia; IMB: intermetatarsal bursitis; IQR: interquartile range; TJC: tender joint count.

**TABLE 2** Associations at patient level between IMB presence and presence of other inflammation features at any MTP joint

	Synovitis	Tenosynovitis	Osteitis	Any (synovitis, tenosynovitis and/or osteitis)
	OR (95% CI)	OR (95% CI)	OR (95% CI)	OR (95% CI)
All CSA patients				
Univariable	6.8 (4.0, 11.4)	11.7 (5.9, 23.0)	2.9 (1.7, 5.0)	4.2 (2.7, 6.6)
Multivariable	3.4 (1.8, 6.5)	5.9 (2.8, 12.6)	1.2 (0.6, 2.4)	—
ACPA-positive patients				
Univariable	8.5 (2.7, 26.4)	14.9 (3.9, 57.0)	4.4 (1.4, 13.8)	7.4 (2.7, 20.3)
Multivariable	2.2 (0.5, 10.1)	7.7 (1.6, 38.0)	1.6 (0.4, 6.8)	—
ACPA-negative patients				
Univariable	4.9 (2.6, 9.2)	6.9 (3.0, 16.1)	2.0 (1.01, 3.9)	2.9 (1.7, 4.9)
Multivariable	3.6 (1.7, 7.4)	4.1 (1.6, 10.2)	1.0 (0.5, 2.3)	—

An OR >1 indicates that presence of the feature concerned (synovitis, tenosynovitis, osteitis) increases the chance that the patient has IMB. <sup>a</sup>Multivariable model: with adjustment for presence of the two other features. CSA: clinically suspect arthralgia; IMB: intermetatarsal bursitis.

of clinical arthritis development are depicted in [Fig. 2](#); CSA patients with IMB at baseline developed clinical arthritis at a higher rate than patients without IMB [HR 3.3(2.1–5.2)].

Multivariable Cox-regression showed that IMB presence at baseline associated with clinical arthritis development independent of synovitis, tenosynovitis and osteitis presence ([Table 4](#)); the adjusted HR was 1.6 (95% CI 1.0, 2.7;  $P=0.048$ ).

Then, we studied whether IMB was an independent predictor of clinical arthritis development when both clinical and MRI parameters were considered. The choice of covariates for this analysis was based on a previous study that identified the following predictors for clinical arthritis development in CSA: ACPA positivity, RF positivity, subclinical RAMRIS inflammation at >2

locations (at the MTP, MCP and wrist joints) and MCP-extensor tenosynovitis [15]. In this analysis, IMB was not statistically significant as independent predictor ([Supplementary Table S3](#), available at *Rheumatology* online); adjusted HR 1.2(0.7–2.1).

#### ACPA status and the relation between IMB and clinical arthritis development

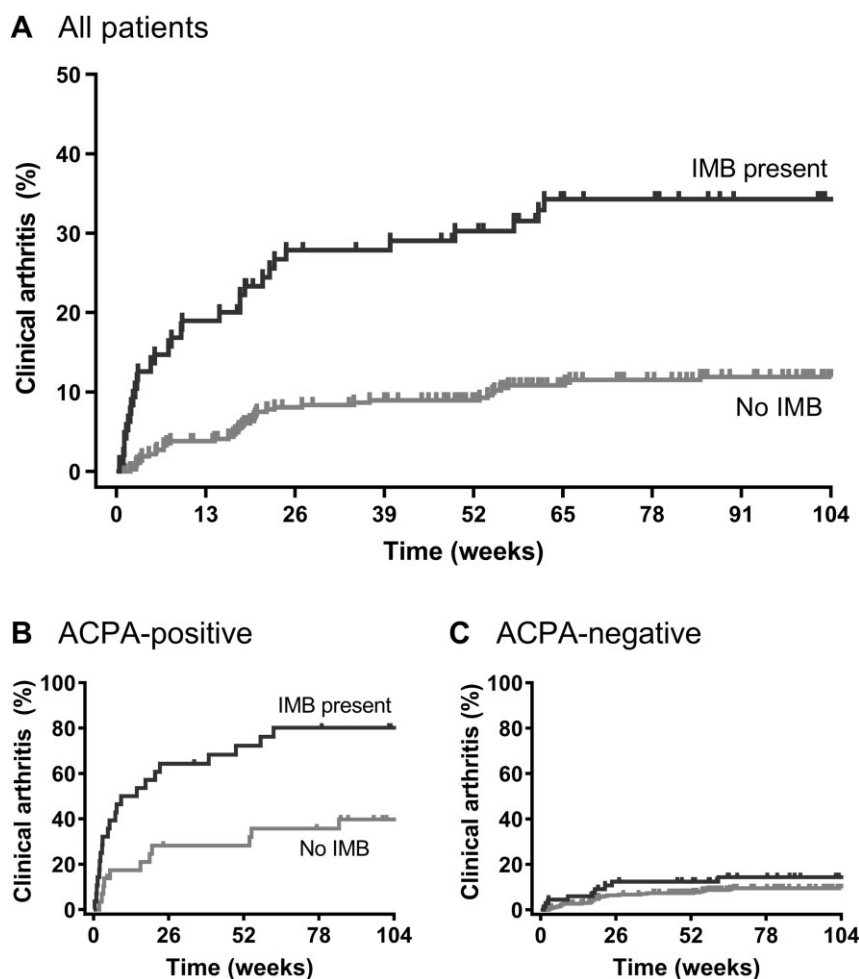
Stratified univariable analyses showed that IMB presence conferred increased risk to develop ACPA-positive clinical arthritis [HR 3.2(1.6–6.7)], while for ACPA-negative clinical arthritis, no statistically significant association was observed [1.5(0.7–3.0); [Fig. 2](#)]. In multivariable analyses including synovitis, tenosynovitis and osteitis presence, IMB presence predicted arthritis

**TABLE 3** Associations at the local level between IMB presence and presence of other inflammation features in adjacent MTP joints

	Synovitis	Tenosynovitis	Osteitis	Any (synovitis, teno-synovitis and/or osteitis)
	OR (95% CI)	OR (95% CI)	OR (95% CI)	OR (95% CI)
All CSA patients				
Univariable	5.8 (3.6, 9.3)	8.0 (4.8, 13.5)	2.3 (1.2, 4.5)	5.0 (3.3, 7.6)
Multivariable <sup>a</sup>	3.7 (2.1, 6.5)	5.0 (2.7, 9.2)	0.9 (0.5, 1.8)	—
ACPA-positive patients				
Univariable	4.4 (2.4, 8.0)	5.0 (2.7, 9.3)	1.7 (0.8, 3.7)	5.1 (3.0, 8.8)
Multivariable <sup>a</sup>	2.9 (1.4, 5.8)	3.7 (1.9, 7.2)	1.1 (0.5, 2.3)	—
ACPA-negative patients				
Univariable	5.1 (2.5, 10.5)	8.1 (3.6, 18.3)	2.6 (1.1, 6.0)	3.6 (2.0, 6.6)
Multivariable <sup>a</sup>	3.2 (1.4, 7.5)	4.8 (1.9, 12.4)	1.0 (0.4, 2.2)	—

An OR >1 indicates that presence of the inflammation feature concerned (synovitis, tenosynovitis, osteitis) at an MTP joint increases the chance that the adjacent bursa is affected by IMB. <sup>a</sup>Multivariable model: adjusted for presence of the two other features. GEE: generalized estimating equation; IMB: intermetatarsal bursitis; OR: odds ratio.

**Fig. 2** Kaplan–Meier curves of progression to clinical arthritis according to presence of IMB at presentation



HR (95% CI): (A) 3.3 (2.1, 5.2); (B) 3.2 (1.6, 6.7); (C) 1.5 (0.7, 3.0). HR: hazard ratio; IMB: intermetatarsal bursitis.

**TABLE 4** The association of IMB presence with development of clinical arthritis, adjusted for presence of other subclinical inflammation features

	Univariable HR (95% CI)	Multivariable <sup>a</sup> HR (95% CI)
IMB	3.3 (2.1, 5.2)	1.6 (1.0, 2.7)*
Synovitis	3.5 (2.2, 5.4)	1.4 (0.8, 2.4)
Tenosynovitis	6.9 (4.3, 11.0)	4.8 (2.8, 8.3)
Osteitis	2.2 (1.4, 3.5)	1.3 (0.8, 2.2)

<sup>a</sup>Multivariable model: all four MRI features were entered as independent variables. Synovitis, tenosynovitis and osteitis were evaluated at the MTP, MCP and wrist joints. \*Statistically significant at the 0.05 level ( $P=0.048$ ). HR: hazard ratio; IMB: intermetatarsal bursitis.

development in ACPA-positive CSA with borderline statistical significance [adjusted HR 2.2(1.0–4.7); [Supplementary Table S4](#), available at *Rheumatology* online], but not in ACPA-negative CSA patients [0.8(0.4–1.7)].

#### Sensitivity analyses

Longitudinal analyses with RA development as outcome yielded similar results as the main analyses ([Supplementary Tables S5](#), available at *Rheumatology* online). IMB was also similarly predictive in patients who fulfilled the EULAR definition of arthralgia suspicious for progression to RA ([Supplementary Tables S6](#), available at *Rheumatology* online).

## Discussion

Although intra-articular synovitis is the most well-known characteristic of RA, recent studies illustrate that RA also frequently involves juxta-articular synovial inflammation, which was demonstrated for tenosynovitis [2, 4]. Tenosynovitis already occurs in the phase of CSA and predicts progression to clinical arthritis [14, 23]. The current large MRI study adds that IMB also occurs in CSA, especially when synovitis or tenosynovitis are present. In addition, IMB precedes clinical arthritis, particularly in ACPA-positive individuals. Together with previous results showing that IMB is highly prevalent in RA at diagnosis, this suggests that intermetatarsal bursae are one of the target tissues early involved in RA [10].

Intriguingly, the association of juxta-articular synovial inflammation features (IMB and tenosynovitis) with progression to clinical arthritis was stronger than of intra-articular synovitis ([Table 4](#)), suggesting that juxta-articular synovial inflammation is even more relevant or distinctive than previously considered. These results are an important step forward to improve the understanding of the development of RA.

Next to pathophysiology, there is the question whether IMB could serve as valuable prognostic marker in clinical practice. In ACPA-positive CSA, IMB presence

associated significantly with progression to clinical arthritis in univariable analyses and after adjustment for other features of subclinical joint inflammation. However, IMB presence did not remain an independent predictor when the auto-antibodies (ACPA, RF) were also incorporated in the model, suggesting that the added value of IMB is limited when it is assessed in addition to serology and ‘traditional’ subclinical inflammation (i.e. RAMRIS inflammation). The prognostic value of IMB will, however, depend on the availability of other measurements; future studies may shed further light on the settings wherein IMB could prove useful. For example, when full RAMRIS scoring is not feasible, IMB scoring might be a less comprehensive alternative.

The current study is the first to systematically investigate MRI-detected IMB in individuals at increased risk of RA. This provides stronger evidence than previous case reports, suggesting that IMB can precede RA [18, 19]. The prevalence of MRI-detected IMB (regardless of IMB size) was higher in CSA than previously found in healthy controls (35% vs 16%,  $P<0.001$ ) and lower than in early RA patients (69%,  $P<0.001$ ) [9]. The relative distribution of IMB across the intermetatarsal spaces was similar to in early RA, with the highest frequency between MTP3 and 4, and the lowest between MTP4 and 5 ([Fig. 1B](#)) [9].

Interestingly, the prevalence of IMB (regardless of size) in ACPA-positive CSA was similar to previously reported in early ACPA-positive RA (64% and 70%, respectively,  $P=0.14$ ), whereas in ACPA-negative CSA the prevalence was lower than in ACPA-negative RA (31% vs 69%,  $P<0.001$ ) [10]. Moreover, in the current study, IMB associated with clinical arthritis development only in ACPA-positive CSA. However, ACPA positivity in CSA is a strong risk factor for progression to clinical arthritis and ACPA-negative CSA comprises relatively fewer patients who progress to RA [14]; this may have resulted in differences in the strength of associations with IMB that were found between the ACPA subgroups. The differences between the ACPA-positive and ACPA-negative subgroups may also suggest a difference in the timing of involvement of IMB: while IMB may be more abundant around the time of presentation with arthralgia in ACPA-positive patients, it may develop later in ACPA-negative RA. Analysis of repeated MRIs during progression from CSA to arthritis development is essential to study this.

In addition, we found that ACPA+/RF+ patients more often had IMB than ACPA+/RF- patients. This shows that patients that have both autoantibodies have IMB more often. Interestingly, this is in line with others’ findings on disease severity; e.g. CSA patients with both autoantibodies also have more erosions [37, 38].

CSA patients with IMB had MTP tenderness slightly more often than patients without IMB, but this was not statistically significant ([Table 1](#)). This is in contrast to early RA patients, where IMB presence has been shown to contribute to joint tenderness [10]. Possibly, IMB severity may increase during development of arthritis and

does not yet reach the threshold of inducing tenderness in the phase of CSA. The fact that not all CSA patients ultimately develop RA and the lower prevalence of IMB in CSA compared with RA may also weaken this association.

A clinical sign that has been reported to be potentially indicative of IMB presence is 'opening toes', which was described in a case report [18]. This concerns the phenomenon that enlargement of the bursa due to IMB can push the adjacent metatarsal bones outwards, leading to an increase in space between the toes. However, this has so far only been reported in one RA patient and has not yet been systematically studied, neither in RA nor pre-RA. Additional studies would be required to assess whether this sign can indeed identify IMB in the phase of CSA.

There were some limitations. Firstly, we were unable to discern IMB directly related to CSA from IMB possibly related to extraneous factors, such as mechanical loading of the forefoot or presence of Morton's neuroma. Although the correction for normal variations incorporates adjustment for mechanical effects to some extent, deviations of forefoot bones (e.g. hallux valgus and hammer toes) could not specifically be accounted for as no weightbearing radiographs were available [39–42]. Although mechanical strain (for example due to deformities or altered mechanical loading) is presumed to be involved in the development of bursitis, it is unclear what its role specifically is in development of IMB in RA or at-risk individuals (CSA) [40–42]. Future studies may elucidate whether mechanical loading, deformities and the resulting mechanical strain promote development of IMB and other local inflammation.

Secondly, some patients were excluded from longitudinal analyses because of participation in an RCT involving a 50% chance of methotrexate use (Supplementary Fig. S1, available at *Rheumatology* online). Because presence of subclinical RAMRIS inflammation was an inclusion criterion for that RCT, the frequency of subclinical RAMRIS inflammation at baseline was hereby lowered in the patient sample used for analyses on arthritis development. As presence of subclinical RAMRIS inflammation is a risk factor for arthritis development [14], excluding part of these patients may have resulted in lower rates of clinical arthritis development. Theoretically, this could have influenced the association found between IMB and clinical arthritis development. Reassuringly, however, there were no clinically relevant differences in baseline characteristics between eligible patients included and excluded in the longitudinal analyses; also, the frequency of IMB did not differ (Supplementary Table S2, available at *Rheumatology* online). In addition, when analyses were limited to patients included before April 2015 and from August 2019, thus outside the time-window of the RCT, IMB was associated with clinical arthritis development [univariable HR 2.2 (1.02–4.5)].

Notably, no validated scoring method for IMB exists. Therefore, our approach to evaluate MRIs for IMB was

developed locally in collaboration with an MSK radiologist with >20 years of experience and was reported previously [9, 10]. Reliability of this approach to score IMB was reassuring (intra-reader ICC 0.87; see Results section).

Based on our findings, we suggest that juxta-articular synovial tissues are incorporated in future imaging and histopathological studies. In recent years, many histopathological and biomarker studies have been conducted using synovial biopsies from intra-articular origin [43]. Likewise, recent ultrasound studies in individuals at risk of RA often assessed intra-articular synovitis and not juxta-articular synovial inflammation [44–48]. However, based on the combination of current and previous results, inflammation of juxta-articular synovial tissues occurs during RA development. In addition, it would be interesting to assess whether early symptoms and signs that are currently mainly attributed to intra-articular synovitis (e.g. the squeeze test of MTP joints) may be associated with juxta-articular inflammation as well.

In conclusion, IMB is detectable by MRI in a quarter of CSA patients and is frequently accompanied by subclinical synovitis and tenosynovitis. In addition, IMB precedes development of clinical arthritis, particularly in ACPA-positive CSA. These results reinforce the notion that juxta-articular synovial inflammation is involved in the earliest phases of arthritis development in RA.

## Acknowledgements

We thank G. Kracht for his assistance in preparing the MR images.

**Funding:** This work was supported by the European Research Council (ERC) under the European Union's Horizon 2020 research and innovation programme [Starting grant, agreement No. 714312], and by the Dutch Arthritis Society.

**Disclosure statement:** The authors have declared no conflicts of interest.

## Data availability statement

Data are available from the corresponding author upon reasonable request.

## Supplementary data

Supplementary data are available at *Rheumatology* online.

## References

- 1 Nieuwenhuis WP, van Steenberg HW, Mangnus L *et al.* Evaluation of the diagnostic accuracy of hand and foot MRI for early rheumatoid arthritis. *Rheumatology* 2017;56:1367–77.



- 2 Rogier C, Hayer S, van der Helm-van Mil A. Not only synovitis but also tenosynovitis needs to be considered: why it is time to update textbook images of rheumatoid arthritis. *Ann Rheum Dis* 2020;79:546–7.
- 3 Eshed I, Feist E, Althoff CE *et al.* Tenosynovitis of the flexor tendons of the hand detected by MRI: an early indicator of rheumatoid arthritis. *Rheumatology* 2009;48: 887–91.
- 4 Matthijssen XME, Wouters F, Sidhu N, Niemantsverdriet E, van der Helm-van Mil A. Tenosynovitis has a high sensitivity for early ACPA-positive and ACPA-negative RA: a large cross-sectional MRI study. *Ann Rheum Dis* 2021; 80:974–80.
- 5 Theumann NH, Pfirrmann CW, Chung CB *et al.* Intermetatarsal spaces: analysis with MR bursography, anatomic correlation, and histopathology in cadavers. *Radiology* 2001;221:478–84.
- 6 Awerbuch MS, Shephard E, Vernon-Roberts B. Morton's metatarsalgia due to intermetatarsophalangeal bursitis as an early manifestation of rheumatoid arthritis. *Clin Orthop Relat Res* 1982;167:214–21.
- 7 Chauveaux D, Le Huec JC, Midy D. The supra-transverse intermetatarsocapital bursa: a description and its relation to painful syndromes of the forefoot. *Surg Radiol Anat* 1987;9:13–8.
- 8 Jovanovic MS, Royer J, Roy PE *et al.* A comparative study of the spaces between the metacarpal and metatarsal heads. *Surg Radiol Anat* 1990;12:31–6.
- 9 Dakkak YJ, Niemantsverdriet E, van der Helm-van Mil AHM, Reijnierse M. Increased frequency of intermetatarsal and submetatarsal bursitis in early rheumatoid arthritis: a large case-controlled MRI study. *Arthritis Res Ther* 2020;22:277.
- 10 van Dijk BT, Dakkak YJ, Matthijssen XME *et al.* Intermetatarsal bursitis, a novel feature of juxta-articular inflammation in early rheumatoid arthritis that is related to clinical signs: results of a longitudinal MRI-study. *Arthritis Care Res* 2021;doi:10.1002/acr.24640.
- 11 van de Stadt LA, Bos WH, Meursinge Reynders M *et al.* The value of ultrasonography in predicting arthritis in auto-antibody positive arthralgia patients: a prospective cohort study. *Arthritis Res Ther* 2010;12:R98.
- 12 Hensvold AH, Kisten Y, Hansson M *et al.* P023 Tenosynovitis and HLA-SE predict arthritis onset in ACPA-positive individuals at risk of developing rheumatoid arthritis. *Ann Rheum Dis* 2019;78(Suppl 1):A8.
- 13 Sahbudin I, Pickup L, Cader Z *et al.* OP0015 ultrasound-defined tenosynovitis is a strong predictor of early rheumatoid arthritis. *Ann Rheum Dis* 2015;74:69–70.
- 14 van Steenberg HW, Mangnus L, Reijnierse M, Huizinga TWJ, van der Helm-van Mil AHM. Clinical factors, anticitrullinated peptide antibodies and MRI-detected subclinical inflammation in relation to progression from clinically suspect arthralgia to arthritis. *Ann Rheum Dis* 2016;75:1824–30.
- 15 Matthijssen X, Van Dijk B, Wouters F, Niemantsverdriet E, Van der Helm-van Mil A. FRI0542 obtaining high positive predictive values for the development of clinically apparent arthritis in patients presenting with clinically suspect arthralgia; is it feasible? *Ann Rheum Dis* 2020; 79:872.
- 16 Ten Brinck RM, van Steenberg HW, van der Helm-van Mil AHM. Sequence of joint tissue inflammation during rheumatoid arthritis development. *Arthritis Res Ther* 2018;20:260.
- 17 Hayer S, Redlich K, Korb A *et al.* Tenosynovitis and osteoclast formation as the initial preclinical changes in a murine model of inflammatory arthritis. *Arthritis Rheum* 2007;56:79–88.
- 18 Endo Y, Koga T, Eguchi M *et al.* Utility of power Doppler ultrasonography for detecting forefoot bursae in early rheumatoid arthritis: a case report. *Medicine* 2018;97: e13295.
- 19 Albtoush OM, Xenitidis T, Horger M. Intermetatarsal bursitis as first disease manifestation in different rheumatological disorders and related MR-imaging findings. *Rheumatol Int* 2019;39:2129–36.
- 20 van Steenberg HW, van Nies JAB, Huizinga TWJ *et al.* Characterising arthralgia in the preclinical phase of rheumatoid arthritis using MRI. *Ann Rheum Dis* 2015;74: 1225–1232.
- 21 van Steenberg HW, van der Helm-van Mil AHM. Clinical expertise and its accuracy in differentiating arthralgia patients at risk for rheumatoid arthritis from other patients presenting with joint symptoms. *Rheumatology* 2016;55:1140–1.
- 22 Dakkak YJ, Matthijssen XME, van der Heijde D, Reijnierse M, van der Helm-van Mil AH. Reliability of Magnetic Resonance Imaging (MRI) scoring of the metatarsophalangeal joints of the foot according to the rheumatoid arthritis MRI score. *J Rheumatol* 2020;47: 1165–1173. jrheum.190258.
- 23 Matthijssen XME, Wouters F, Boeters DM *et al.* A search to the target tissue in which RA-specific inflammation starts: a detailed MRI study to improve identification of RA-specific features in the phase of clinically suspect arthralgia. *Arthritis Res Ther* 2019;21:249.
- 24 Haavardsholm EA, Østergaard M, Ejbjerg BJ, Kvan NP, Kvien TK. Introduction of a novel magnetic resonance imaging tenosynovitis score for rheumatoid arthritis: reliability in a multireader longitudinal study. *Ann Rheum Dis* 2007;66:1216–20.
- 25 Østergaard M, Edmonds J, McQueen F *et al.* An introduction to the EULAR-OMERACT rheumatoid arthritis MRI reference image atlas. *Ann Rheum Dis* 2005;64(Suppl 1):i3–i7.
- 26 Hartmann D. The tendon sheaths and synovial bursae of the foot. By Gustav Schwalbe, 1896. Translated by Hartmann. *Foot Ankle* 1981;1:247–69.
- 27 Mangnus L, van Steenberg HW, Reijnierse M, van der Helm-van Mil AHM. Magnetic resonance imaging-detected features of inflammation and erosions in symptom-free persons from the general population. *Arthritis Rheumatol* 2016;68:2593–602.
- 28 Boer AC, Burgers LE, Mangnus L *et al.* Using a reference when defining an abnormal MRI reduces false-positive MRI results—a longitudinal study in two cohorts at risk for rheumatoid arthritis. *Rheumatology* 2017;56:1700–6.

- 29 Zanetti M, Strehle JK, Zollinger H, Hodler J. Morton neuroma and fluid in the intermetatarsal bursae on MR images of 70 asymptomatic volunteers. *Radiology* 1997; 203:516–20.
- 30 Niemantsverdriet E, Dakkak YJ, Burgers LE *et al.* TREAT Early Arthralgia to Reverse or Limit Impending Exacerbation to Rheumatoid arthritis (TREAT EARLIER): a randomized, double-blind, placebo-controlled clinical trial protocol. *Trials* 2020;21:862.
- 31 Aletaha D, Neogi T, Silman AJ *et al.* 2010 Rheumatoid arthritis classification criteria: an American College of Rheumatology/European League Against Rheumatism collaborative initiative. *Arthritis Rheum* 2010;62:2569–81.
- 32 Arnett FC, Edworthy SM, Bloch DA *et al.* The American Rheumatism Association 1987 revised criteria for the classification of rheumatoid arthritis. *Arthritis Rheum* 1988;31:315–24.
- 33 Burgers LE, Siljehult F, ten Brinck RM *et al.* Validation of the EULAR definition of arthralgia suspicious for progression to rheumatoid arthritis. *Rheumatology* 2017; 56:2123–8.
- 34 van Steenberg HW, Aletaha D, Beaat-van de Voorde LJJ *et al.* EULAR definition of arthralgia suspicious for progression to rheumatoid arthritis. *Ann Rheum Dis* 2017;76:491–496.
- 35 Daha NA, Toes RE. Rheumatoid arthritis: are ACPA-positive and ACPA-negative RA the same disease? *Nat Rev Rheumatol* 2011;7:202–3.
- 36 Matthijssen XME, Niemantsverdriet E, Huizinga TWJ, van der Helm-van Mil AHM. Enhanced treatment strategies and distinct disease outcomes among autoantibody-positive and -negative rheumatoid arthritis patients over 25 years: a longitudinal cohort study in the Netherlands. *PLoS Med* 2020;17:e1003296.
- 37 Hecht C, Englbrecht M, Rech J *et al.* Additive effect of anti-citrullinated protein antibodies and rheumatoid factor on bone erosions in patients with RA. *Ann Rheum Dis* 2015;74:2151–6.
- 38 ten Brinck RM, Toes REM, van der Helm-van Mil AHM. Inflammation functions as a key mediator in the link between ACPA and erosion development: an association study in Clinically Suspect Arthralgia. *Arthritis Res Ther* 2018;20:89.
- 39 Fuhrmann RA, Layher F, Wetzel WD. Radiographic changes in forefoot geometry with weightbearing. *Foot Ankle Int* 2003;24:326–31.
- 40 Bowen CJ, Culliford D, Allen R *et al.* Forefoot pathology in rheumatoid arthritis identified with ultrasound may not localise to areas of highest pressure: cohort observations at baseline and twelve months. *J Foot Ankle Res* 2011;4:25.
- 41 Helliwell P, Siddle H, Redmond A, eds. The foot and ankle in rheumatology. Reports on the Rheumatic Diseases. Top Rev 2011.
- 42 Nouh MR, Khalil AA. Forefoot: a basic integrated imaging perspective for radiologists. *Clin Imaging* 2014;38:397–409.
- 43 Small A, Wechalekar MD. Synovial biopsies in inflammatory arthritis: precision medicine in rheumatoid arthritis. *Expert Rev Mol Diagnostics* 2020;20:315–25.
- 44 van der Ven M, van der Veer-Meerkerk M, Ten Cate DF *et al.* Absence of ultrasound inflammation in patients presenting with arthralgia rules out the development of arthritis. *Arthritis Res Ther* 2017;19:202.
- 45 Zufferey P, Rebell C, Benaim C *et al.* Ultrasound can be useful to predict an evolution towards rheumatoid arthritis in patients with inflammatory polyarthralgia without anticitrullinated antibodies. *Joint Bone Spine* 2017;84:299–303.
- 46 Nam JL, Hensor EMA, Hunt L *et al.* Ultrasound findings predict progression to inflammatory arthritis in anti-CCP antibody-positive patients without clinical synovitis. *Ann Rheum Dis* 2016;75:2060–2067.
- 47 van Beers-Tas MH, Blanken AB, Nielen MMJ *et al.* The value of joint ultrasonography in predicting arthritis in seropositive patients with arthralgia: a prospective cohort study. *Arthritis Res Ther* 2018;20:279.
- 48 Di Matteo A, Mankia K, Duquenne L *et al.* Ultrasound erosions in the feet best predict progression to inflammatory arthritis in anti-CCP positive at-risk individuals without clinical synovitis. *Annals Rheum Dis* 2020; 79:901–907.