

EUR Research Information Portal

Clinical findings are not helpful in detecting lentigo maligna melanoma in patients with biopsy-proven lentigo maligna

Published in:

Journal of the European Academy of Dermatology and Venereology

Publication status and date:

Published: 01/12/2022

DOI (link to publisher):

[10.1111/jdv.18346](https://doi.org/10.1111/jdv.18346)

Document Version

Publisher's PDF, also known as Version of record

Document License/Available under:

CC BY-NC-ND

Citation for the published version (APA):

Zoutendijk, J., Koljenovic, S., Wakkee, M., Mooyaart, A. L., Nijsten, T., & van den Bos, R. R. (2022). Clinical findings are not helpful in detecting lentigo maligna melanoma in patients with biopsy-proven lentigo maligna. *Journal of the European Academy of Dermatology and Venereology*, 36(12), 2325-2330. <https://doi.org/10.1111/jdv.18346>

[Link to publication on the EUR Research Information Portal](#)

Terms and Conditions of Use

Except as permitted by the applicable copyright law, you may not reproduce or make this material available to any third party without the prior written permission from the copyright holder(s). Copyright law allows the following uses of this material without prior permission:

- you may download, save and print a copy of this material for your personal use only;
- you may share the EUR portal link to this material.


In case the material is published with an open access license (e.g. a Creative Commons (CC) license), other uses may be allowed. Please check the terms and conditions of the specific license.

Take-down policy

If you believe that this material infringes your copyright and/or any other intellectual property rights, you may request its removal by contacting us at the following email address: openaccess.library@eur.nl. Please provide us with all the relevant information, including the reasons why you believe any of your rights have been infringed. In case of a legitimate complaint, we will make the material inaccessible and/or remove it from the website.

ORIGINAL ARTICLE

Clinical findings are not helpful in detecting lentigo maligna melanoma in patients with biopsy-proven lentigo maligna

J. Zoutendijk,¹  S. Koljenovic,^{2,3} M. Wakkee,¹ A.L. Mooyaart,² T. Nijsten,¹ R.R. van den Bos^{1,*}

¹Department of Dermatology, Erasmus MC Cancer Institute, University Medical Center Rotterdam, Rotterdam, The Netherlands

²Department of Pathology, Erasmus MC University Medical Center, Rotterdam, The Netherlands

³Department of Pathology, Antwerp University Hospital, Antwerp, Belgium

*Correspondence: R.R. van den Bos. E-mail: r.vandenbos@erasmusmc.nl

Abstract

Background Lentigo maligna (LM) based on biopsy material might be lentigo maligna melanoma (LMM) after excision.

Objectives Investigate whether clinical and dermoscopic mapping increases the detection rate of LMM when investigating staged excision specimens of biopsy proven LM.

Methods Patients with biopsy-proven LM planned for staged excision were included. Using clinical inspection and dermoscopy, spots suspicious for LMM were marked. After the excision, needles were placed at the marked spots. Histological examination using vertical sections was done at the needles followed by the standard amount of vertical sections.

Results In 28 of the 58 biopsy-proven LM, there was clinical suspicion of LMM, only 3 of these 28 cases were upgraded into LMM. These three cases showed LMM in other sections, whereas only 1 case showed LMM around the needle. Within the group without clinical suspicion of LMM, 2 cases were LMM. Biopsy-proven LM were in fact LMM in 8.6% of the cases and were found without the clinical guidance of the dermatologist.

Conclusions 8.6% of the biopsy-proven LM were LMM after complete histological examination. In this study, the dermatologist was not able to increase the detection rate of LMM by using clinical and dermoscopic mapping.

Received: 23 December 2021; Accepted: 29 April 2022

Conflicts of interest

No conflict of interest to declare.

Funding sources

None.

Introduction

Lentigo maligna (LM) is the most common subtype of melanoma *in situ* and the precursor of lentigo maligna melanoma (LMM)^{1,2} which accounts for 4%–15% of all cutaneous melanomas.² LM usually occurs in elderly patients and is most commonly located in the head and neck region on chronically sun-damaged skin.³ The incidence rates of LM and LMM are rising globally.^{4,5} This increase in incidence is probably due to the higher levels of UV exposure and the ageing of the population, in conjunction with more awareness among patients and physicians resulting in increased biopsy rate of pigmented lesions such as LM.⁴ The presentation of LM and LMM may be subtle and a diagnostic delay is common.⁶ Dermoscopy may help differentiating between LM, LMM, other types of melanoma and solar lentigo.^{7–9}

Complete surgical (staged) excision is the best treatment of clinical and biopsy-proven LM¹⁰ as it enables histological examination of the lesion. It allows differentiating between LM and

LMM¹¹ and assesses whether the margins are free of lentigo maligna (melanoma).¹² Histological assessment of skin excisions typically involves regularly spaced vertical sections ('bread-loaf sectioning')¹⁰ and only 2%–3% of the material is examined. So, it may occur that an invasive component is missed. It has therefore been advocated that dermatologists should indicate areas suspicious for invasive growth within a LM lesion for guided histological examination to increase the likelihood of LMM diagnosis. The following dermoscopic criteria are clues for LMM: homogenous areas, irregular blotches, black colour, obliterated hair follicles and milky red areas.^{7–9} To our knowledge studies investigating this clinically guided investigation of LM lesions are lacking.

The aim of this study was to investigate whether clinical and dermoscopic mapping increases the detection rate of LMM during the investigation of staged excision specimens of biopsy-proven LM.

Material and methods

Patients

From February 2017 until November 2018, all patients with biopsy proven LM planned for staged excision at the department of Dermatology of Erasmus MC Cancer Institute, a tertiary care hospital, were included in this prospective study. All patients who were approached for participation agreed to inclusion in the study.

Standard staged excision procedure and additions to the procedure for this study

All patients with biopsy-proven LM (mostly single 3-mm punch biopsies which were often performed by physicians referring the patient) were treated with the staged excision procedure as described previously.¹⁰ At the start of the procedure, the lesion was marked with a margin of 3 mm, marking stiches were placed and the lesion was excised under local anaesthesia. Prior to the procedure, the research physician and the dermatologist with oncologic experience used dermoscopy to mark 0–5 spots within the LM that were suspect for invasive growth using this criteria: homogenous areas, irregular blotches, black colour, obliterated hair follicles and milky red areas.^{7–9} In the absence of suspect spots no needle was placed.

The specimen was pinned on a marked cardboard with small needles to ensure the clinical orientation. Pictures were made of the defect and the specimen and added in the surgical file.¹⁰ The wound was covered with a bandage to remain open until histology results were available. After the procedure, the investigator placed the study needles at the marked spots in the excised specimen. Additional (dermoscopic) photos were made before the procedure, after marking the suspect spots and after placing the needle(s) in the specimen (Fig. 1). Figure 1 shows a specimen with the orange needle placed in the clinically suspect area.

At the pathology department, the margins of the specimen were separated from the central part.¹⁰ All pieces (margins and central part) were embedded in paraffin and stained with haematoxylin and eosin and on request of the pathologist, additional immunohistochemistry for Melan A and SOX 10 were performed. The central part of the specimen was cut with a 'bread-loaf' technique every 3–5 mm to investigate if invasive growth was present. Additional skin was excised when needed and the steps could be repeated until the margins were free of LM(M). In case of invasive growth (LMM) and if it was surgically feasible, the margins (depth and lateral) of the re-excision were followed conform the current guideline.^{11,13} In this study, vertical sections in the area of the placed needles were performed followed by the standard staged excision to assess the presence of invasive growth in the central part. If no signs of invasion (LMM) were observed in the slide at the site of the needle, 3

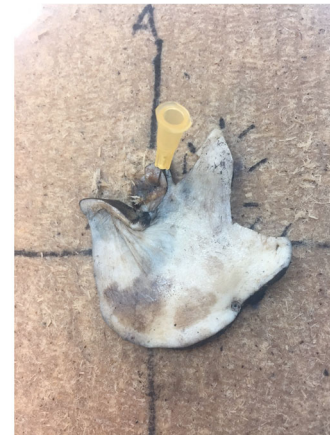

Figure 1 LM specimen pinned on a marked cardboard with orange marking needle.

additional (deeper) sections were performed in this block to search this specific part thoroughly.

The protocol was submitted to the local medical ethics committee of the Erasmus University Medical Center and exempt for formal approval (MEC-2017-102).

Statistics

Patients were anonymously recorded in Excel and SPSS statistics version 25 and SPSS was used to perform the statistical analysis. Descriptive statistics and frequencies were used to evaluate the data, continuous data were presented as mean with standard deviation (SD) and categorical data in absolute numbers with percentages or median with interquartile range (IQR).

Results

Study population

For inclusion in this study, 58 cases that were diagnosed with LM with a (incision) biopsy were eligible (Table 1). The majority of all cases were female (63.8%) and the mean age was 71.3 years (SD 12.3). Median size was between 2 and 5 cm (IQR 2–3) and almost all (94.8%) of the LM(M) were located in the head and neck region, only 3 (5.2%) cases were located on the extremities (Table 1).

The additional effect of placing needles

In this study, 53 of the 58 biopsy-proven LM cases remained LM after complete histology and in 5 patients (8.6%) there was an upgrade into LMM based on the staged excision (Table 1). The mean Breslow thickness of the upgraded LMM was 0.7 mm (SD 0.1) (Table 1).

Table 1 Baseline characteristics of patients with histologically proven LM treated with staged excision

	Diagnosis after staged excision		
	LM	Upstaged LMM	Total
Total patients, <i>n</i>	53	5	58
Age at diagnosis in years, mean (SD)	71.4 (12.4)	70.4 (11.6)	71.3 (12.3)
Sex			
Female, <i>n</i> (%)	34 (64.2)	3 (60.0)	37 (63.8)
Male, <i>n</i> (%)	19 (35.8)	2 (40)	21 (36.2)
Size, <i>n</i> (%)			
<1 cm	3 (5.7)	-	3 (5.2)
1–2 cm	27 (50.9)	2 (40)	29 (50)
2–5 cm	21 (39.6)	1 (20)	22 (37.9)
>5 cm	2 (3.8)	2 (40)	4 (6.9)
Tumour location, <i>n</i> (%)			
Head neck	50 (94.3)	5 (100)	55 (94.8)
Trunk	-	-	-
Other	3 (5.7)	-	3 (5.2)
Breslow thickness mm, mean (SD)	-	0.7 (0.1)	-
Rounds, median (IQR)	1 (1–2)	2 (1.5–2.5)	1 (1–2)
Cases with needles	25	3	28
Number of needles placed (if placed), median (IQR)	1 (1–2)	2 (1)	1 (1–1)

IQR, interquartile range; LM, lentigo maligna; LMM, lentigo maligna melanoma; SD, standard deviation.

In 28 of the 58 cases, there was a clinical and/or dermoscopic suspicion of invasive growth and a needle was placed (Fig. 2). The median number of placed needles was 1 (IQR 1–1).

Three of the 28 clinically suspect cases were upgraded into LMM after histopathological examination. Of these 3 LMM the number of needles placed were 2, 1 and 5. Two out of the three LMM were detected during the standard histological examination (and not at site of the needle or additional deeper sections) and one showed an invasive component at the site of the needle. However, in the latter lesion, LMM was also observed in the standard procedure at a different location than the needle site (Fig. 2).

In the remaining 25 LM lesions where needles were placed at sites suspicious for invasive growth, no invasive growth was observed in the standard histology procedure of the central part of excised LM specimen, at the needle sites and/or deeper sections (Fig. 2). In these LM cases, the pathologist describes the following histological findings: melanophages in the papillary and superficial reticular dermis,¹³ inflammation,⁹ irregular or increased pigmentation,¹¹ extended or proliferative LM⁴ and a few times a dermal nevus² (Table 2). However, during the 2-year clinical follow-up after the surgery, 2 patients of this group of 25 LM cases that were clinically but not histologically suspicious were diagnosed with melanoma metastasis. Both of these two patients had no history of a primary melanoma other than the treated LM.

Figure 3a and 3b show a gap where a needle was placed with irregular pigmentation and inflammation around. This case was a histologically proven LM, a needle was placed at the arrow (Fig. 3c) and remained LM after staged excision.

Although 30/58 LM cases did not show clinically suspicious regions (no needle placed), 2 were upgraded into LMM following standard histological examination (Fig. 2). These 2 LMM were diagnosed in the central slides of the standard procedure.

Discussion

This prospective study shows that guidance of the dermatologist, including assessment with the dermatoscope, is not able to increase the detection of LMM in staged excision specimens of biopsy-proven LM. There was an upgrade from LM into LMM in 8.6% but all the LMM would have been found anyway, without the clinical guidance of the dermatologist.

In 28 of the 58 LM cases, there was suspicion of LMM, only 3 of these 28 cases were upgraded into LMM, but all 3 cases showed LMM in other sections, whereas only 1 case actually showed invasive growth at the site of the needle. In the cases where the dermatologist had no clinical suspicion of LMM, 2 cases were nevertheless upgraded into LMM.

In our study, the dermatologist typically placed a needle when observing obliterated hair follicles, streaks, very dark areas and rhomboid areas with dermoscopy. In contrast, we found hardly any resemblance between clinically suspect areas in LM and the corresponding histology. An explanation could be that the clinicians were eager to place needles for the purpose of this study. Another explanation could be that all LM lesions were biopsied for diagnosis prior to the study; these biopsies may have resulted in clinical suspect characteristics in fact caused by for example melanophages and scarring. Remarkably, there were 'some activity' found around the needle(s) in the 25 cases where no invasive growth was found; this activity consisted of (dermal) melanophages, inflammation, irregular or increased pigmentation, extended or proliferative LM and a few times a dermal nevus. Possibly, these histological findings mimic clinical characteristics found in invasive areas. Interestingly on the other hand from the pathologist's perspective, a recent study found specific histologic features in the biopsies that were associated with an invasive component in the whole lesion: melanocytes forming rows, nests, subepidermal clefts and a lesser degree of elastosis.¹⁴ In addition, others suggest that pagetoid spread of tumour cells and moderate-to-strong dermal inflammation creates alertness for invasive growth.¹⁵

In total, 8.6% of the biopsy-proven LM cases were upgraded into LMM. This is similar with the 9% that was found in our retrospective study¹² and 8.5% in an American study.¹⁶ It is, however, much lower than a Spanish and French study described (34% and 20%, respectively).^{14,15} A possible explanation for the difference in upgrade rate could be a lower threshold in diagnosing LMM by the pathologist when examining the whole lesion.

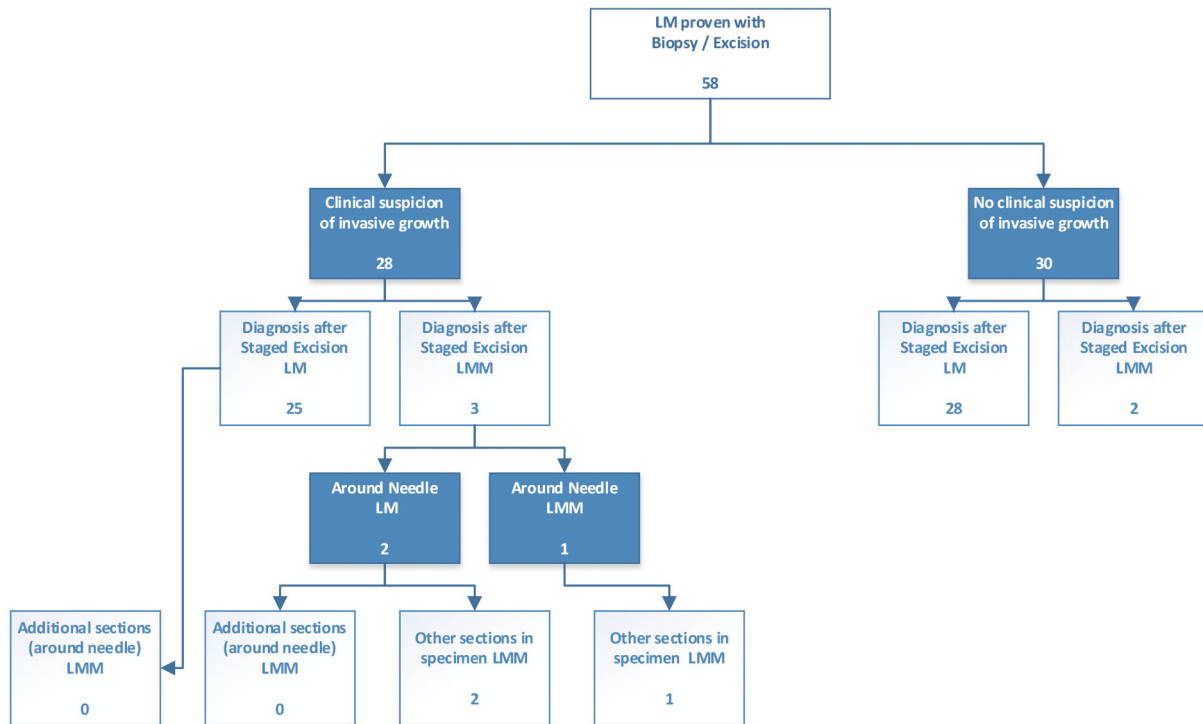


Figure 2 Flowchart of the cases diagnosed with a biopsy- or excision-proven LM and the diagnosis after staged excision. LM, lentigo maligna; LMM, lentigo maligna.

Table 2 Histology findings around the placed needles in LM cases that remained LM after staged excision

Histology	Number of cases (multiple options possible)
Dermal nevus	2
Infiltrate	9
Extended LM/proliferative LM	4
(dermal) Melanophages	13
Increased and irregular pigmentation	11
Other	4

LM, lentigo maligna.

A second explanation could be that the pathologist does not easily detect invasiveness in a small biopsy. The third explanation could be the variation between pathologists in the judgement of melanocytic lesions leading to a low reproducibility.¹⁷

If we would include the 2 LM patients who developed metastases during follow-up in the upgraded group, the total upgrade rate would increase to 12.1%. We assume that these metastases were from the study LM which should have had an undetected invasive part, but it is also possible that it were metastases of an unknown primary melanoma.

Surgical excision is the first choice of treatment for biopsy-proven LM with staged excision as the preferred surgical

method.^{18,19} Other treatment modalities (e.g. cryotherapy, radiation therapy, imiquimod, laser therapy)^{20–22} have the risk to leave an invasive component untreated. It is a misassumption that biopsied LM is purely epidermal (even in clinical/dermoscopic not suspect cases) and we advise to seriously consider the fair chance to an upgrade into LMM when choosing a non-invasive treatment.

Strong assets of this clinical study are the prospective design and the precise and thorough histological examination after clinical evaluation. Limitations of this study are the limited number and proportion of patients with an invasive LMM and the lack of using a scoring system for dermoscopy findings. Second, selection bias may be a problem as the included cases may have been a selection of low risk patients. All included patients were biopsy-proven LM and it is plausible that the clinician took a biopsy from the most suspicious part of the lesion thereby already excluding high-risk patients who were histologically diagnosed as a LMM.

In conclusion, we have shown that 8.6% (5/58) of the biopsy-proven LM cases were in fact LMM after histological assessment of the staged excision, emphasizing the importance of a surgical treatment. It seems that the dermatologist was not able to increase the number of detected LMM with clinical guidance and dermoscopy before staged excision.

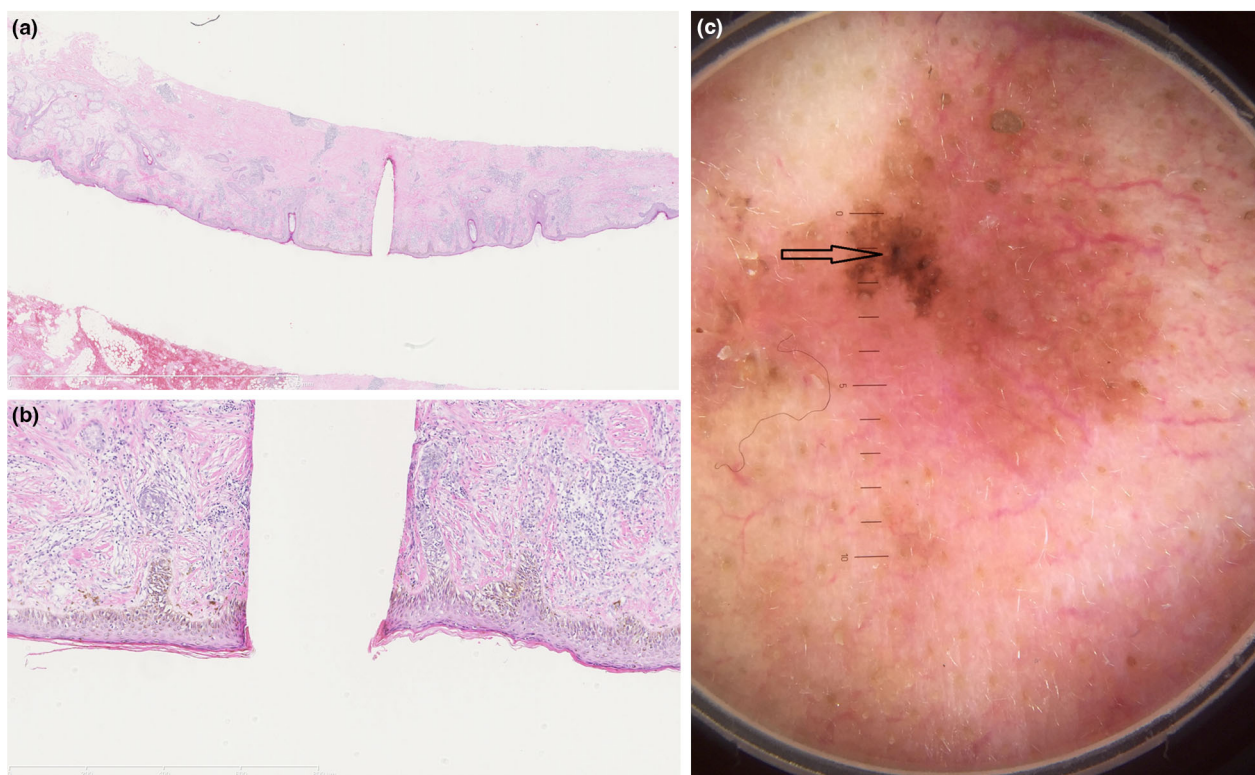


Figure 3 (a) H&E staining of the staged excision specimen of lentigo maligna with in the centre the gap of the placed needle. (b) H&E staining of the staged excision specimen of lentigo maligna with in the centre the gap of the placed needle. (c) Dermoscopy picture of biopsy proven lentigo maligna with a clinically suspicion of invasive growth.

Acknowledgements

The authors thank the dermatologists: P.K. Dikrama and R. Waalboer-Spuij and pathologist J. Damman for their contribution to the inclusion of patients and assessment of the histology.

Informed consent

The patients in this manuscript have given written informed consent to the publication of their case details.

Data availability statement

The data that support the findings of this study are available from the corresponding author upon reasonable request.

References

- van der Leest RJ, Zoutendijk J, Nijsten T *et al*. Increasing time trends of thin melanomas in The Netherlands: what are the explanations of recent accelerations? *Eur J Cancer* 2015; **51**: 2833–2841.
- Swetter SM, Boldrick JC, Jung SY, Egbert BM, Harvell JD. Increasing incidence of lentigo maligna melanoma subtypes: northern California and national trends 1990–2000. *J Invest Dermatol* 2005; **125**: 685–691.
- Smalberger GJ, Siegel DM, Khachemoune A. Lentigo maligna. *Dermatol Ther* 2008; **21**: 439–446.
- Greveling K, Wakkee M, Nijsten T, van den Bos RR, Hollestein LM. Epidemiology of lentigo Maligna and lentigo Maligna melanoma in The Netherlands, 1989–2013. *J Invest Dermatol* 2016; **136**: 1955–1960.
- Guitera P, Collgro H, Madronio CM *et al*. The steadily growing problem of lentigo maligna and lentigo maligna melanoma in Australia: population-based data on diagnosis and management. *Australas J Dermatol* 2019; **60**: 118–125.
- Pralong P, Bathelier E, Dalle S, Poulalhon N, Debarbieux S, Thomas L. Dermoscopy of lentigo maligna melanoma: report of 125 cases. *Br J Dermatol* 2012; **167**: 280–287.
- Schiffner R, Schiffner-Rohe J, Vogt T *et al*. Improvement of early recognition of lentigo maligna using dermoscopy. *J Am Acad Dermatol* 2000; **42**(1 Pt 1): 25–32.
- Stolz W, Schiffner R, Burgdorf WH. Dermoscopy for facial pigmented skin lesions. *Clin Dermatol* 2002; **20**: 276–278.
- Peruilh-Bagolini L, Apalla Z, González-Cuevas R *et al*. Dermoscopic predictors to discriminate between in situ and early invasive lentigo maligna melanoma: a retrospective observational study. *J Am Acad Dermatol* 2020; **83**: 269–271.
- de Vries K, Greveling K, Prens LM *et al*. Recurrence rate of lentigo maligna after micrographically controlled staged surgical excision. *Br J Dermatol* 2016; **174**: 588–593.
- Marsden JR, Newton-Bishop JA, Burrows L *et al*. Revised U.K. guidelines for the management of cutaneous melanoma 2010. *Br J Dermatol* 2010; **163**: 238–256.

- 12 Zoutendijk J, Tio D, Koljenovic S, van den Bos RR. Nine per cent of biopsy-proven lentigo maligna lesions are reclassified as lentigo maligna melanoma after surgery. *Br J Dermatol* 2019; **181**: 383–384.
- 13 American Joint Committee on Cancer (AJCC). AJCC Cancer Staging Manual Eight Edition. 2017.
- 14 Moreno A, Manrique-Silva E, Viros A *et al.* Histologic features associated with an invasive component in lentigo Maligna lesions. *JAMA Dermatol* 2019; **155**: 782–788.
- 15 Aouidad I, Fargeas C, Romero P *et al.* Histologic predictors of invasion in partially biopsied lentigo maligna melanoma. *J Am Acad Dermatol* 2019; **80**: 1150–1152.
- 16 Levoska MA, Schmults CD, Waldman AH. Upstaging of melanoma in situ and lentigo maligna treated with Mohs micrographic surgery rarely results in additional surgical management. *Arch Dermatol Res* 2020; **312**: 753–756.
- 17 Elmore JG, Barnhill RL, Elder DE *et al.* Pathologists' diagnosis of invasive melanoma and melanocytic proliferations: observer accuracy and reproducibility study. *BMJ* 2017; **357**: j2813.
- 18 Work G, Swetter SM, Tsao H *et al.* Guidelines of care for the management of primary cutaneous melanoma. *J Am Acad Dermatol* 2019; **80**: 208–250.
- 19 Robinson M, Primiero C, Guitera P *et al.* Evidence-based clinical practice guidelines for the Management of Patients with lentigo Maligna. *Dermatology* 2020; **236**: 111–116.
- 20 Tio D, van der Woude J, Prinsen CA, Jansma EP, Hoekzema R, van Montfrans C. A systematic review on the role of imiquimod in lentigo maligna and lentigo maligna melanoma: need for standardization of treatment schedule and outcome measures. *J Eur Acad Dermatol Venereol* 2016; **31**: 616–624.
- 21 Greveling K, de Vries K, van Doorn MB, Prens EP. A two-stage treatment of lentigo maligna using ablative laser therapy followed by imiquimod: excellent cosmesis, but frequent recurrences on the nose. *Br J Dermatol* 2016; **174**: 1134–1136.
- 22 Erickson C, Miller SJ. Treatment options in melanoma in situ: topical and radiation therapy, excision and Mohs surgery. *Int J Dermatol* 2010; **49**: 482–491.