



Camrelizumab—targeting a novel PD-1 epitope to treat hepatocellular carcinoma

Yannick Sebastiaan Rakké¹, Dave Sprengers², Jaap Kwekkeboom², Jan Nicolaas Maria IJzermans¹

¹Department of Surgery, ²Department of Gastroenterology and Hepatology, Erasmus University Medical Centre, Rotterdam, The Netherlands

Correspondence to: Dave Sprengers. Dr. Molewaterplein 40, Office Na-610, P.O. Box 2040, 3000 CA Rotterdam, The Netherlands.

Email: d.sprengers@erasmusmc.nl.

Comment on: Qin S, Ren Z, Meng Z, *et al.* Camrelizumab in patients with previously treated advanced hepatocellular carcinoma: a multicentre, open-label, parallel-group, randomised, phase 2 trial. *Lancet Oncol* 2020;21:571-80.

Submitted May 27, 2020. Accepted for publication Jun 05, 2020.

doi: 10.21037/atm-2020-115

View this article at: <http://dx.doi.org/10.21037/atm-2020-115>

Hepatocellular carcinoma (HCC) is the fourth leading cause of cancer-related death rating sixth in incidence worldwide (1). Whereas non-alcoholic fatty liver disease (NAFLD) and subsequent non-alcoholic steatohepatitis (NASH) related HCC is emerging in Western society, hepatitis B (HBV) and C viral (HCV) infections still remain the leading global risk factors for HCC (2). HCC patients frequently get diagnosed at advanced-stage disease subjecting them to systemic therapies including the kinase inhibitors sorafenib and regorafenib that have only shown limited overall survival benefit up to now (3). Immune checkpoint blockade (ICB), (re)invigorating T cell-mediated anti-tumour immune responses via reversing PD-1 pathway-mediated intra-tumoural immunosuppression [Figure 1 (4,5)], has been shown to have anti-tumour activity in advanced HCC leading to accelerated FDA-approval of the anti-PD-1 monoclonal antibodies (mAb) nivolumab and pembrolizumab for patients with sorafenib-resistant HCC.

Recently, Qin and colleagues reported their findings on camrelizumab, a novel humanised, high-affinity, IgG4/isotype anti-PD-1 mAb, in the treatment of therapy-resistant advanced HCC in a population majorly consisting of HBV-related HCC (6). The open-label, parallel-group, phase 2 trial included 217 adult patients (83% HBV seropositive) from 13 Chinese sites enrolled between November 2016 and November 2017. The study cohort consisted of histologically or cytologically proven HCC patients with Child-Pugh score ≤ 7 and radiologically proven progressive disease (PD) upon or intolerance to previous systemic treatment. Patients were randomised 1:1 to receive 3 mg/kg camrelizumab intravenously

once every 2 or 3 weeks (group A and B, resp.) until investigator-assessed disease progression was noted as defined by RECIST 1.1, unacceptable toxicity, withdrawal of consent, or study completion. Coprimary endpoints were blinded independent central review (BICR) assessed objective response (OR) rate (ORR) and 6-month overall survival (OS).

At the data cut-off on November, 2018, median follow-up was 12.5 months (IQR 5.7–15.5). OS at 6 months was 74.7% (75.9% and 73.0% in group A and B, resp.). OR was observed in 32/217 (14.7%; 97.5% CI: 9.8–21.0) patients, with a median time to response of 2.0 months (IQR 1.9–3.4) and consisting of partial responses only. Median progression-free survival (PFS) was 2.1 months (95% CI: 2.0–3.2). Median duration of response was not reached (IQR 3.7–14.0) as 18 responders were still on treatment at data cut-off.

Most common treatment-related adverse events (TRAE) observed were reactive cutaneous capillary endothelial proliferation [RCCEP; 145 (67%)], increased aspartate aminotransferase [AST; 55 (25%)], increased alanine aminotransferase [ALT; 51 (24%)], and proteinuria [50 (23%)]. Grade 3–4 TRAEs occurred in 47/217 (22%) patients, mainly consisting of increased AST [10 (5%)] and decreased neutrophil count [7 (3%)]. Two patients experienced treatment-related death due to liver dysfunction and multiple organ failure, respectively. Immune-mediated AEs were observed in 181 (83.4%) patients, including RCCEP (66.8%), hypothyroidism (9.2%), and immune-related hepatitis (7.4%). During follow-up 46 patients showed increased HBV-DNA of which 74% occurred after

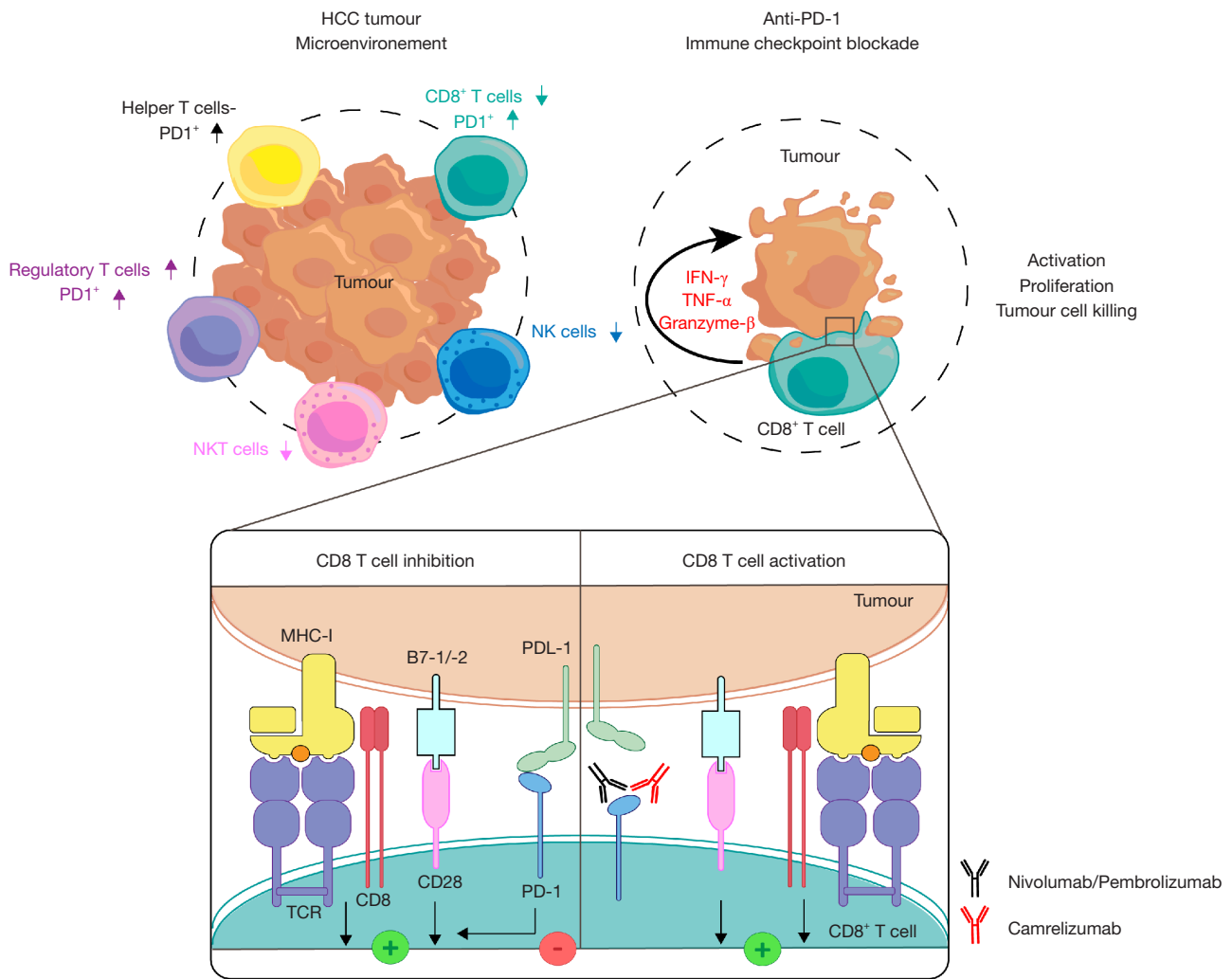


Figure 1 Tumour cell and CD8 T cell interaction. HCC harbours an immunosuppressive tumour microenvironment (TME). Compared to tumour-free (TF) surrounding liver tissues, intratumoural immune infiltrates have increased proportions of immunosuppressive regulatory T cells (Tregs) and decreased proportions of proinflammatory natural killer (NK-), NKT, and cytotoxic CD8⁺ T cells (4). PD-1 is upregulated on tumour-infiltrating helper and CD8⁺ T cells (5). Tumour cells and tumour-infiltrating myeloid cells express PD-1-Ligand (PDL-1) and suppress T cell functionality via downstream inhibition of T cell receptor (TCR) and costimulatory (B7-1/-2-CD28) signalling through the interaction of PDL-1 with PD-1. Immunosuppression via PD-1 is abrogated by anti-PD-1 blocking antibodies (e.g., nivolumab, pembrolizumab, camrelizumab), that prevent PD-1/PDL-1 ligation, restoring CD8⁺ T cell-mediated antitumour immune responses.

PD or last dose before PD. HBV-DNA increase did not lead to treatment interruption nor discontinuation.

Qin and colleagues suggest camrelizumab might represent a novel second-line treatment option for advanced HCC, having shown antitumour activity, potential survival benefit, and manageable safety profiles. These results observed in a Chinese cohort of patients with treatment-resistant advanced HCC should be interpreted with caution.

Phase 2 clinical trials are designed to test for efficacy

and AEs. Researchers in the current phase 2 trial were not blinded to dosage regimen and no discrepancies between the two regimens were described. Notably, nivolumab and pembrolizumab have failed to meet their primary endpoints in subsequent phase 3 clinical trials (7,8), despite having shown promising antitumour effects in early phase clinical trials (9,10). Therefore, before generally stating that camrelizumab might be a suitable second-line treatment, therapeutic effectiveness should be tested in larger sample

double-blinded phase 2/3 clinical trials, proving superiority or non-inferiority to placebo control or standard treatment. Nevertheless, based on this trial's results one might find some support for camrelizumab to be used as second-line treatment as all included patients were demonstrated to have progressive disease or intolerance to prior systemic therapy and tumour response was observed in some patients.

Qin *et al.* have used 6-month OS as coprimary endpoint. Though OS remains the gold-standard for measuring therapeutic benefit, one should be careful interpreting the data from the current study. Forty percent (87/217) of the patients received additional treatment after camrelizumab discontinuation, including targeted, systemic, and local therapies. Additionally, in the current study 95 of 161 (59%) patients with PD continued camrelizumab after PD was observed, either as monotherapy or in combination with other therapies. Therefore, the actual clinical benefit of camrelizumab beyond PD, might have been influenced by these sequential treatments, undermining the value of OS to fairly prove the therapeutic benefit of camrelizumab monotherapy (11). Radiological surrogate endpoints (e.g., ORR, PFS) are useful when assessing early signs of efficacy prior to application of any other subsequent therapeutic regimen (11,12). Notably, Qin and colleagues reported a median PFS of 2.1 months. As recommended by the EASL guidelines, advanced HCC radiological assessment should preferably be interpreted using both conventional RECIST 1.1 and modified RECIST (mRECIST) criteria, measuring viable tumour as well (12). Systemic therapies might cause treatment-induced intratumoural necrosis without reducing tumour diameter. mRECIST has proven to capture higher ORR and has shown to be independently associated with improved OS. However, Qin and colleagues have used conventional RECIST 1.1, thus potentially underestimating the actual therapeutic benefit of camrelizumab. It should be noted that in previous trials studying the effects of nivolumab and pembrolizumab in advanced HCC both radiological response criteria were used (8,9). Besides radiological surrogate endpoints, on-target immune monitoring (e.g., circulating ki67⁺ CD8 T cell enhancement relative to tumour burden) might be a relevant approach to specifically detect and monitor treatment-related immunological effects predicting early clinical responses, as was demonstrated for melanoma patients treated with PD-1-blockade (13).

Since the majority of therapy-resistant advanced HCC patients does not seem to benefit from camrelizumab,

identifying responders using a biomarker is deemed crucial. Due to limited sample size, unfortunately no conclusion could be drawn on PD-L1 expression as predictive biomarker for camrelizumab. So far, combined PD-L1 expression on tumour cells and leukocytes has only shown a trend towards higher response rates to pembrolizumab in HCC (10). As a substantial number of PD-L1-negative patients also respond to anti-PD-1 therapies, it remains elusive whether ligand expression is a suitable predictive biomarker.

Previously, phase 1/2 trials studying ICB using anti-PD-1 mAbs reported similar results, supporting that only a minor subset of advanced HCC patients seem to benefit from anti-PD-1 therapy. In sorafenib-experienced patients, best overall complete and partial response (CR and PR, resp.) of the intention-to-treat (ITT) population was shown to be limited to 3% (5/145) and 15% (22/145) for nivolumab and 1% (1/104) and 16% (17/104) for pembrolizumab (9,10). In general, OS rates of camrelizumab were comparable to both nivolumab [6-mo OS 74.4% (95% CI: 68.0–79.7%) *vs.* 83.0% (95% CI: 78.0–88.0%), resp.] and pembrolizumab [12-mo OS 55.9% (95% CI: 48.9–62.2%) *vs.* 54% (95% CI: 44–63%)] (9,10).

Qin and colleagues highlight the importance of testing ICB-efficacy among patients infected with HBV. Related to aetiology, genomic profiles of HCC in Asian countries are substantially different from non-Asian countries (2,14). Evidence of enhanced disease progression in HBV-mediated HCC remains weak. Yet, it is hypothesized to harbour impaired *in situ* anti-tumour immune responses based on molecular and histopathological features, potentially making ICB less efficacious in these patients (15,16). Similar to previous trials, Qin, *et al.* have demonstrated that anti-PD-1 therapy can be safely applied in the Asian population with similar clinical response rates as non-Asian HCC patients (9,10,17). However, all current studies were underpowered to statistically compare outcomes of HBV-mediated to non-infectious HCC.

Camrelizumab displayed similar rates of grade 3–4 TRAEs compared to nivolumab and pembrolizumab, ranging 22–25% of the ITT populations. Strikingly, RCCEP was observed more frequently compared to nivolumab and pembrolizumab (67.0% *vs.* 2.4%) (18). Qin *et al.*, hypothesize that this might be attributed to the novel PD-1 binding epitope that is targeted by camrelizumab as a means to achieve ICB-optimization, potentially disrupting the balance between pro- and anti-angiogenic growth factors (19).

ICB-optimization via binding epitope-selection is hypothesized to be crucial in improving binding efficiency or specificity, potentially leading to increased anti-PD-1 efficacy and decreased TRAEs. Nivolumab and pembrolizumab have partly overlapping binding epitopes interacting with the flexible N- and C'D-loops of the PD-1 molecule, respectively (20). Instead, camrelizumab is said to interact with the unique glycosylated ASN58 position of the PD-1 molecule via its CDRH2 domain. Data regarding another novel anti-PD-1 mAb (MW11-h317) confirms that glycosylation dependent binding to ASN58 provides high affinity binding to the PD-1 molecule. However, it does not show any superiority to nivolumab when comparing *in vitro* binding affinity to PD-1, inhibitory effects, and pre-clinical *in vivo* antitumour effects (20). Pharmacodynamics data from human phase 1 trials on camrelizumab and nivolumab support these pre-clinical data revealing comparable PD-1 binding affinity (K_D , 3.31×10^{-9} M vs. 3.65×10^{-9} M, resp.) and receptor occupancy on circulating T lymphocytes (85% vs. 70%, resp.) (20-22).

In summary, the study from Qin and colleagues suggests that camrelizumab represents an alternative for nivolumab and pembrolizumab in Chinese sorafenib-resistant advanced HCC patients. Despite its binding to a novel PD-1 epitope, results are largely similar to those of nivolumab and pembrolizumab for both infectious and non-infectious HCC. However, subsequent phase 3 clinical trials of these agents in similar patient populations have failed to meet their primary endpoints (7,8). Yet, any comparative trial results on camrelizumab have not been reported so far. Since recently improved clinical effectiveness is achieved with combinatorial approaches using ICB and anti-angiogenic therapies (23,24), positive phase 3 data may be expected from the announced international multi-centre randomised trial comparing camrelizumab plus apatinib [vascular endothelial growth factor-receptor 2 inhibitor (VEGFR2i)] versus sorafenib alone (NCT03764293), albeit in a first line setting.

Acknowledgments

Funding: None.

Footnote

Provenance and Peer Review: This article was commissioned by the editorial office, *Annals of Translational Medicine*. The article did not undergo external peer review.

Conflicts of Interest: All authors have completed the ICMJE uniform disclosure form (available at <http://dx.doi.org/10.21037/atm-2020-115>). The authors have no conflicts of interest to declare.

Ethical Statement: The authors are accountable for all aspects of the work in ensuring that questions related to the accuracy or integrity of any part of the work are appropriately investigated and resolved.

Open Access Statement: This is an Open Access article distributed in accordance with the Creative Commons Attribution-NonCommercial-NoDerivs 4.0 International License (CC BY-NC-ND 4.0), which permits the non-commercial replication and distribution of the article with the strict proviso that no changes or edits are made and the original work is properly cited (including links to both the formal publication through the relevant DOI and the license). See: <https://creativecommons.org/licenses/by-nc-nd/4.0/>.

References

1. Ferlay J, Ervik M, Lam F, et al. Global Cancer Observatory: Cancer Today. Lyon, France: International Agency for Research on Cancer. 2018. Available online: <https://gco.iarc.fr/today>, accessed 11-05-2020.
2. McGlynn KA, Petrick JL, El-Serag HB. Epidemiology of hepatocellular carcinoma. *Hepatology* 2020. doi: 10.1002/hep.31288.
3. Forner A, Reig M, Bruix J. Hepatocellular carcinoma. *Lancet* 2018;391:1301-14.
4. Pedroza-Gonzalez A, Verhoef C, IJzermans JNM, et al. Activated tumor-infiltrating CD4+ regulatory T cells restrain antitumor immunity in patients with primary or metastatic liver cancer. *Hepatology* 2013;57:183-94.
5. Zhou G, Sprengers D, Boor PPC, et al. Antibodies against immune checkpoint molecules restore functions of tumor-infiltrating t cells in hepatocellular carcinomas. *Gastroenterology* 2017;153:1107-1119.e10.
6. Qin S, Ren Z, Meng Z, et al. Camrelizumab in patients with previously treated advanced hepatocellular carcinoma: a multicentre, open-label, parallel-group, randomised, phase 2 trial. *Lancet Oncol* 2020;21:571-80.
7. Yau T, Park JW, Fin RS, et al. Checkmate 459: a randomized, multi-center phase III study of nivolumab (NIVO) vs sorafenib (SOR) as first-line (1L) treatment in patients (pts) with advanced hepatocellular carcinoma (aHCC). *Ann Oncol* 2019;30:v874-5.

8. Finn RS, Ryoo BY, Merle P, et al. Pembrolizumab as second-line therapy in patients with advanced hepatocellular carcinoma in KEYNOTE-240: a randomized, double-blind, phase iii trial. *J Clin Oncol* 2020;38:193-202.
9. El-Khoueiry AB, Sangro B, Yau T, et al. Nivolumab in patients with advanced hepatocellular carcinoma (CheckMate 040): an open-label, non-comparative, phase 1/2 dose escalation and expansion trial. *Lancet* 2017;389:2492-502.
10. Zhu AX, Finn RS, Edeline J, et al. Pembrolizumab in patients with advanced hepatocellular carcinoma previously treated with sorafenib (KEYNOTE-224): a non-randomised, open-label phase 2 trial. *Lancet Oncol* 2018;19:940-52.
11. Llovet JM, Montal R, Villanueva A. Randomized trials and endpoints in advanced HCC: role of PFS as surrogate of survival. *J Hepatol* 2019;70:1262-77.
12. Llovet JM, Lencioni R. mRECIST for HCC: performance and novel refinements. *J Hepatol* 2020;72:288-306.
13. Huang AC, Postow MA, Orlowski RJ, et al. T-cell invigoration to tumour burden ratio associated with anti-PD-1 response. *Nature* 2017;545:60-5.
14. Choo SP, Tan WL, Goh BKP, et al. Comparison of hepatocellular carcinoma in Eastern versus Western populations. *Cancer* 2016;122:3430-46.
15. Calderaro J, Ziol M, Paradis V, et al. Molecular and histological correlations in liver cancer. *J Hepatol* 2019;71:616-30.
16. Calderaro J, Petitprez F, Becht E, et al. Intra-tumoral tertiary lymphoid structures are associated with a low risk of early recurrence of hepatocellular carcinoma. *J Hepatol* 2019;70:58-65.
17. Yau T, Hsu C, Kim TY, et al. Nivolumab in advanced hepatocellular carcinoma: sorafenib-experienced Asian cohort analysis. *J Hepatol* 2019;71:543-52.
18. Hwang SJ, Carlos G, Wakade D, et al. Cutaneous adverse events (AEs) of anti-programmed cell death (PD)-1 therapy in patients with metastatic melanoma: a single-institution cohort. *J Am Acad Dermatol* 2016;74:455-61.e1.
19. Chen X, Ma L, Wang X, et al. Reactive capillary hemangiomas: a novel dermatologic toxicity following anti-PD-1 treatment with SHR-1210. *Cancer Biol Med* 2019;16:173-81.
20. Wang M, Wang J, Wang R, et al. Identification of a monoclonal antibody that targets PD-1 in a manner requiring PD-1 Asn58 glycosylation. *Commun Biol* 2019;2:392.
21. Mo H, Huang J, Xu J, et al. Safety, anti-tumour activity, and pharmacokinetics of fixed-dose SHR-1210, an anti-PD-1 antibody in advanced solid tumours: a dose-escalation, phase 1 study. *Br J Cancer* 2018;119:538-45.
22. Topalian SL, Hodi FS, Brahmer JR, et al. Safety, activity, and immune correlates of anti-PD-1 antibody in cancer. *N Engl J Med* 2012;366:2443-54.
23. Finn RS, Qin S, Ikeda M, et al. Atezolizumab plus bevacizumab in unresectable hepatocellular carcinoma. *N Engl J Med* 2020;382:1894-905.
24. Qin S, Ren Z, Feng Y, et al. OP02-03 Efficacy and safety of atezolizumab + bevacizumab vs sorafenib in Chinese patients with unresectable HCC in the phase III IMBrave150 study. *Liver Cancer Summit 2020, Prague, Czech Republic.*

Cite this article as: Rakké YS, Sprengers D, Kwekkeboom J, IJzermans JNM. Camrelizumab—targeting a novel PD-1 epitope to treat hepatocellular carcinoma. *Ann Transl Med* 2020;8(23):1614. doi: 10.21037/atm-2020-115