

EUR Research Information Portal

Magnetic Resonance Imaging-based Monitoring in Active Surveillance

Published in:

European Urology Open Science

Publication status and date:

Published: 01/04/2022

DOI (link to publisher):

[10.1016/j.euros.2022.02.001](https://doi.org/10.1016/j.euros.2022.02.001)

Document Version

Publisher's PDF, also known as Version of record

Document License/Available under:

CC BY-NC-ND

Citation for the published version (APA):

Bangma, C. H., & Schoots, I. G. (2022). Magnetic Resonance Imaging-based Monitoring in Active Surveillance: Are We Ready To Jump on the Bandwagon? *European Urology Open Science*, 38, 49-51.

<https://doi.org/10.1016/j.euros.2022.02.001>

[Link to publication on the EUR Research Information Portal](#)

Terms and Conditions of Use

Except as permitted by the applicable copyright law, you may not reproduce or make this material available to any third party without the prior written permission from the copyright holder(s). Copyright law allows the following uses of this material without prior permission:

- you may download, save and print a copy of this material for your personal use only;
- you may share the EUR portal link to this material.

In case the material is published with an open access license (e.g. a Creative Commons (CC) license), other uses may be allowed. Please check the terms and conditions of the specific license.

Take-down policy

If you believe that this material infringes your copyright and/or any other intellectual property rights, you may request its removal by contacting us at the following email address: openaccess.library@eur.nl. Please provide us with all the relevant information, including the reasons why you believe any of your rights have been infringed. In case of a legitimate complaint, we will make the material inaccessible and/or remove it from the website.



Open Horizon – Editorial

Magnetic Resonance Imaging-based Monitoring in Active Surveillance: Are We Ready To Jump on the Bandwagon?

Chris H. Bangma^{a,*}, Ivo G. Schoots^b

^a Department of Urology, Erasmus Cancer Institute, Erasmus University Medical Centre, Rotterdam, The Netherlands; ^b Department of Radiology & Nuclear Medicine, Erasmus Cancer Institute, Erasmus University Medical Centre, Rotterdam, The Netherlands

The important message in the Open Horizon paper by Giganti et al [1] in this issue of *European Urology Open Science* is the repeated call for the introduction of risk-based strategies for follow-up of low-risk prostate cancer [2]. The primary goal is to reduce the number of unnecessary and unwanted prostate biopsies without compromising long-term oncological safety and missing incurable cancers. The authors argue that it is possible to avoid routine rebiopsy in cases with stable magnetic resonance imaging (MRI) findings on serial scans and stable prostate-specific antigen (PSA) kinetics.

In the primary setting, MRI is a powerful stratification tool for discriminating MRI-positive (suspicion scores 3–5) and MRI-negative (scores 1–2) cases before prostate biopsy [3]. Still, any MRI finding must be interpreted in the light of the a priori risk of clinically significant prostate cancer [4], which is also true for low-risk populations such as men on active surveillance. In this context, we believe that routine rebiopsy could be safely avoided by men with stable negative MRI findings, while this approach might be premature for men with positive MRI results.

A recent publication by the Movember Foundation's Global Action Plan Prostate Cancer Active Surveillance (GAP3) consortium [5] on more than 2000 men on active surveillance in a multicenter setting with MRI at program entry provides interesting data. The percentage of patients with histological progression (among other parameters) was evaluated over 5 yr of surveillance, with stratification according to the presence (scores 3–5) or absence (scores 1–2) of a suspicious lesion at baseline MRI. There was a higher risk of histological progression (hazard ratio 1.69, 95% confidence interval [CI] 1.30–2.20) for men with suspicious MRI (30%, 95% CI 26–34%) versus nonsuspicious MRI (19%, 95% CI 15–23%) at 5 yr.

These data show that MRI guidance may benefit surveillance protocols and that men with negative MRI findings have a lower chance of upgrading in the long term. Furthermore, these data are concordant with the high sensitivity and high negative predictive value (>90% for both) of MRI in the primary diagnostic setting of men suspected of harboring prostate cancer [3]. Subsequent serial nonsuspicious MRI scans over time will underline the arguments for avoiding routine rebiopsy during surveillance.

However, for men with positive MRI findings on active surveillance, even if findings for the visible lesion are stable, there is no strict guarantee of the absence of histological upgrading over time. For men on active surveillance with positive MRI findings, we still need to find convincing evidence that performing only MRI without biopsy provides appropriate information regarding tumor status. In a recent systematic review and meta-analysis on serial prostate MRI scans in active surveillance, Rajwa et al [6] concluded that MRI cannot be a stand-alone factor for excluding progression or triggering rebiopsy for men on active surveillance. Their results (based on 15 studies and 2240 men) suggest that MRI-guided surveillance for 1000 men would result in rebiopsy avoidance by up to 683 patients, while missing up to 124 cases of cancer progression. The odds of histological progression would be worse among MRI-positive cases than among MRI-negative cases. Considering the marginal positive predictive values for identifying disease progression, the authors also conclude that MRI progression alone should not be the only trigger for biopsy and needs to be considered among other clinical factors in a decision-making process [6].

In primary diagnostic testing, studies have shown that for combinations of risk factors, especially PSA density (PSAD) together with Prostate Imaging-Reporting and Data

* Corresponding author. Department of Urology, Erasmus Medical Centre, P.O. Box 2040, 3000 CA Rotterdam, The Netherlands. Tel. + 31 10 7033607. E-mail address: c.h.bangma@erasmusmc.nl (C.H. Bangma).



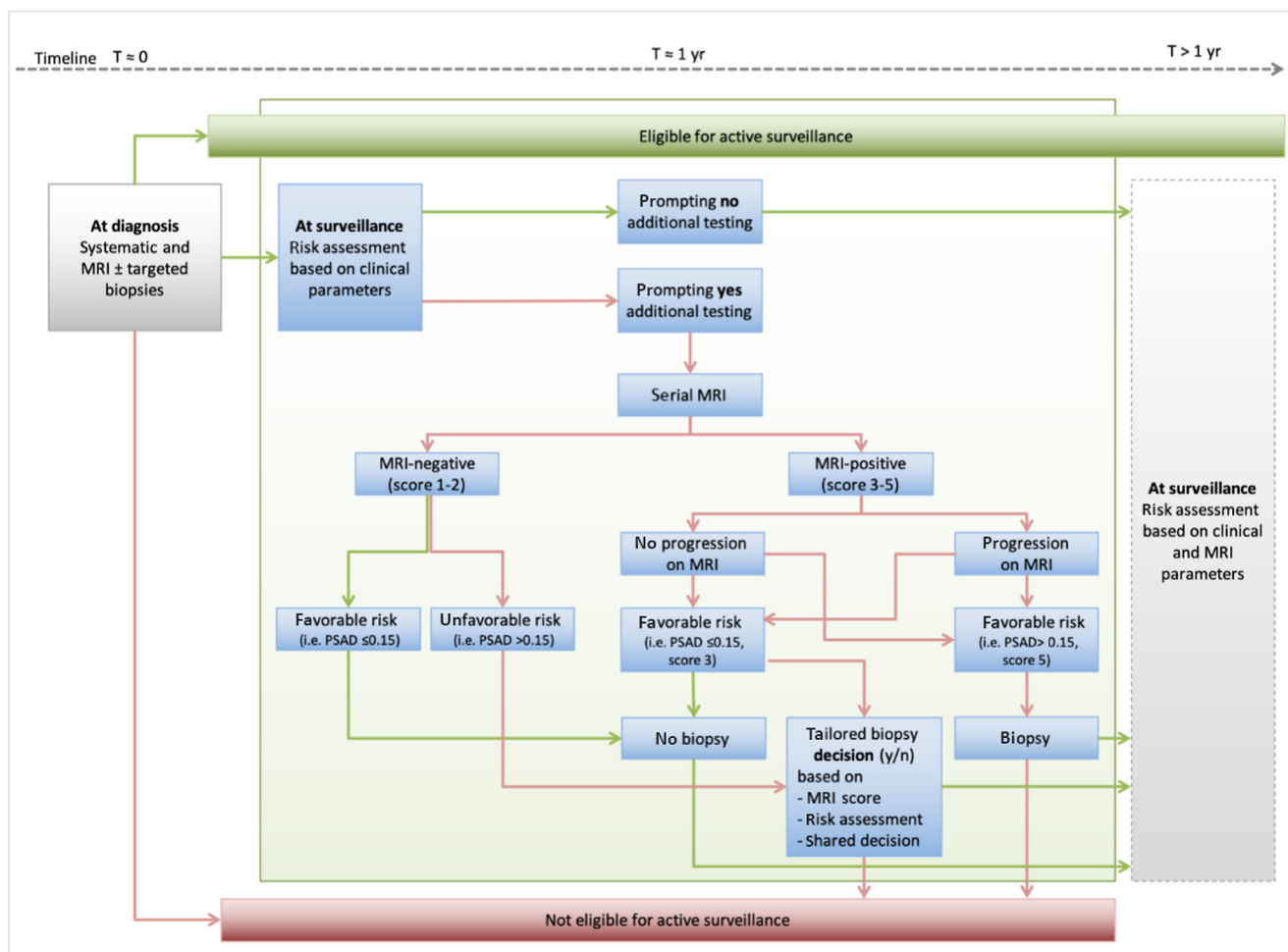


Fig. 1 – A proposed risk-based protocol for MRI use in combination with clinical parameters for biopsy decisions for patients under active surveillance for prostate cancer. MRI = magnetic resonance imaging; PSAD = prostate-specific antigen density (in ng/ml²).

System (PI-RADS) assessment scores, hardly any aggressive cancer is detected on biopsy when the combination of these factors is “favorable”. Favorable risk factors are PI-RADS scores of 1–2 combined with PSAD <0.15–0.20 ng/ml² or PI-RADS 3 with PSAD <0.10–0.15 ng/ml² [7].

In a data analysis from PRIAS (Prostate Cancer International Active Surveillance) by Luiting et al (unpublished) of 1488 men under surveillance, the proportion of men with PI-RADS 1–2 findings was 29.5%. The risk of histological grade progression was 3% (10/315) for MRI-negative cases with PSAD <0.15 ng/ml² (20% of the cohort) and 15% (20/132) for those with PSAD >0.15 ng/ml² (10% of the cohort). Therefore, a substantial percentage of men with negative MRI findings can be classified as having very low risk of disease progression for whom rebiopsy could be avoided. By contrast, for men with negative MRI findings and unfavorable clinical risk factors, a biopsy decision could be considered (a risk-based biopsy decision).

Before jumping on the bandwagon of preferential biopsy avoidance, we need substantial evidence of the value of serial MRI scans in monitoring men with MRI-positive findings in daily practice. The PRECISE criteria for follow-up of MRI-suspicious lesions provide a scheme for reporting over time, but the data so far on changes on MRI do not allow

avoidance of biopsies with great certainty [8]. Jumping to conclusions for this (in particular) higher-risk population on active surveillance should not be fueled by minimal information or the tendency to confirm one’s beliefs. Further improvements in the assessment of disease progression or stable disease are mandatory before “we can say goodbye to protocol-based biopsies” for MRI-positive cases. A redesigned biopsy-based surveillance protocol, with a move to a risk-based protocol that includes (changes on) MRI in close combination with clinical parameters and biomarkers, should then be used for biopsy decisions (Fig. 1).

There is a concern that the use of more risk parameters such as MRI might “inflate” the risk of staying on active surveillance and reduce the number of men continuing surveillance [2], leading to overtreatment. Using close monitoring, even the current thresholds for surveillance eligibility could then subsequently be expanded and a more tailored approach could be adopted [9].

Just as previously, when the definition of low-risk cancers changed with re-evaluation of the role of PSA doubling time or the number of positive systematic biopsies or the introduction of small Gleason 4 components (excluding cribriform growth pattern), the role of MRI should be

assessed when deciding on changes to make in protocols and prospective evaluation, leaving some of the established reflexes of traditional protocols behind, such as (annual) protocol-based biopsy. Until then, a proposed risk stratification (Fig. 1) that combines clinical data and serial MRI findings, potentially with other emerging biomarkers, will help in identifying patients on active surveillance who can either safely avoid or actually need repeat biopsy.

Conflicts of interest: The authors have nothing to disclose.

References

- [1] Giganti F, Stavrinos V, Moore C. Magnetic resonance imaging-guided active surveillance of prostate cancer: time to say goodbye to protocol-based biopsies. *Eur Urol Open Sci* 2022;38:40–3. <https://doi.org/10.1016/j.euros.2021.08.016>.
- [2] Venderbos LD, Luiting H, Hogenhout R, Roobol MJ. Interaction of MRI and active surveillance in prostate cancer: time to re-evaluate the active surveillance inclusion criteria. *Urol Oncol* 2021. <https://doi.org/10.1016/j.urolonc.2021.08.008>, In press.
- [3] Drost FH, Osses D, Nieboer D, et al. Prostate magnetic resonance imaging, with or without magnetic resonance imaging-targeted biopsy, and systematic biopsy for detecting prostate cancer: a Cochrane systematic review and meta-analysis. *Eur Urol* 2020;77:78–94.
- [4] Rouviere O, Souchon R, Melodelima C. Pitfalls in interpreting positive and negative predictive values: application to prostate multiparametric magnetic resonance imaging. *Diagn Interv Imaging* 2018;99:515–8.
- [5] Olivier J, Li W, Nieboer D, et al. Prostate cancer patients under active surveillance with a suspicious magnetic resonance imaging finding are at increased risk of needing treatment: results of the Movember Foundation's Global Action Plan Prostate Cancer Active Surveillance (GAP3) consortium. *Eur Urol Open Sci* 2022;35:59–67.
- [6] Rajwa P, Pradere B, Quhal F, et al. Reliability of serial prostate magnetic resonance imaging to detect prostate cancer progression during active surveillance: a systematic review and meta-analysis. *Eur Urol* 2021;80:549–63.
- [7] Schoots IG, Padhani AR. Risk-adapted biopsy decision based on prostate magnetic resonance imaging and prostate-specific antigen density for enhanced biopsy avoidance in first prostate cancer diagnostic evaluation. *BJU Int* 2021;127:175–8.
- [8] Luzzago S, Piccinelli ML, Mistretta FA, et al. Repeat MRI during active surveillance: natural history of prostatic lesions and upgrading rates. *BJU Int* 2021. <https://doi.org/10.1111/bju.15623>, In press.
- [9] Padhani AR, Rouviere O, Schoots IG. Magnetic resonance imaging for tailoring the need to biopsy during follow-up for men on active surveillance for prostate cancer. *Eur Urol* 2021;80:564–6.