

LONG-TERM TREATMENT OUTCOMES AFTER BEVACIZUMAB THERAPY FOR MACULAR NEOVASCULARIZATION IN WHITE PATIENTS WITH HIGH MYOPIA

MONICA RAVENSTIJN, MD,*‡; CAROLINE C. W. KLAVER, MD, PhD,†‡§¶; SUZANNE YZER, MD, PhD*§

Purpose: To report long-term treatment outcomes of intravitreal bevacizumab in myopic macular neovascularization (MNV).

Methods: Retrospective analysis of longitudinal, clinical data of patients with high myopic MNV treated with intravitreal bevacizumab. One-hundred and seventeen eyes of 106 patients were followed from first injection up to 12 years. Outcome measures were best-corrected visual acuity change during follow-up and myopic MNV recurrence.

Results: Mean (\pm SD) baseline best-corrected visual acuity (0.56 ± 0.46 logMAR, 20/80) significantly improved after first treatment (0.33 ± 0.33 , 20/50, $P < 0.001$). At 4 years ($n = 86$), best-corrected visual acuity was no longer significantly better than at baseline (0.55 ± 0.57 , $P = 0.30$) and continued to deteriorate to 0.84 ± 0.76 (20/125) at 10 years ($n = 27$). Of the 27 eyes (23%) who reached 10 years of follow-up, 53% developed MNV-related chorioretinal atrophy. The cumulative incidence of recurrent myopic MNV was 34% at 2 years and 59% at 5 years. Best-corrected visual acuity decrease in eyes with or without recurrent MNV was similar ($P = 0.58$). Patchy chorioretinal atrophy (hazard ratio 3.0, $P = 0.02$) and subfoveal MNVs (hazard ratio 2.5, $P = 0.048$) were significantly associated with recurrent MNV.

Conclusion: This retrospective myopic MNV study revealed that visual improvement after intravitreal bevacizumab injections was not maintained over time. Macular neovascularization recurrences occurred frequently but did not alter the already poor visual prognosis.

RETINA 43:444–453, 2023

Myopic macular neovascularization (MNV) is a sight-threatening complication that occurs in 5% to 11% of eyes with high myopia.¹ Antivascular endothelial growth factor (anti-VEGF) agents, such as bevacizumab, have proven their effectiveness and

safety to treat myopic MNV and are now the first-line treatment.^{2–4} Although short-term results look promising, the visual improvement after treatment is of temporary nature.^{5–8} Development of chorioretinal atrophy (CRA) around the regressed MNV lesion

From the *Rotterdam Ophthalmic Institute, Rotterdam Eye Hospital, Rotterdam, The Netherlands; Departments of †Epidemiology, and ‡Ophthalmology, Erasmus Medical Center, Rotterdam, The Netherlands; §Department of Ophthalmology, Radboud University Medical Center, Nijmegen, The Netherlands; and ¶Institute of Molecular and Clinical Ophthalmology, Basel, Switzerland.

Supported by Oogfonds, Landelijke Stichting voor Blinden en Slechtzienden, Algemene Nederlandse Vereniging Ter Voorkoming Van Blindheid and Stichting Beheer 't Schild through Uitzicht (2019-14), Rotterdamse Stichting Blindenbelangen (20190034), and Stichting Wetenschappelijk Onderzoek Oogziekenhuis (2019S06). C. C. W. Klaver obtained funding from Netherlands Organization for Scientific Research (NWO, Grant 91815655), and from European Research Council (ERC) under the European Union's Horizon 2020 Research and Innovation Programme (Grant 648268).

Paper Presented at Dutch Ophthalmologic Conference, Maastricht, the Netherlands, March 26, 2021; ARVO 2022 Annual Meeting, Denver, CO, May 4, 2022.

None of the authors has any financial/conflicting interests to disclose.

This is an open access article distributed under the terms of the Creative Commons Attribution-Non Commercial-No Derivatives License 4.0 (CCBY-NC-ND), where it is permissible to download and share the work provided it is properly cited. The work cannot be changed in any way or used commercially without permission from the journal.

Reprint requests: Suzanne Yzer, MD, PhD, Department of Ophthalmology, Radboud University Medical Center, Geert Grooteplein Zuid 10, 6525 GA Nijmegen, The Netherlands; e-mail: suzanne.yzer@radboudumc.nl

affects the visual acuity in the treated eye eventually.^{5–9} Better visual outcomes were seen in eyes with higher visual acuity at baseline, smaller MNV lesions, and extrafoveal lesions.^{5,7,10} East-Asian patients seem to have a higher visual acuity gain than White patients after anti-VEGF treatment,¹¹ but it is unclear whether this also translates to a better visual prognosis on the long-term compared with White patients.

In contrast to MNVs in age-related macular degeneration (AMD), highly myopic eyes usually do not need lifelong treatment.^{5,12–15} Nevertheless, after successful treatment of the first episode of myopic MNV, studies have reported retreatment or recurrence of MNV in 62% and 85% of patients.^{7,8} The risk profile and visual outcome of persons developing multiple myopic MNVs is currently unclear, which hampers clinical management and patient counseling. Therefore, the aim of this study was to investigate long-term outcome of intravitreal bevacizumab (IVB) in White patients with myopic MNV. We compared the course of visual acuity in treated eyes with fellow myopic eyes and to the current literature.

Methods

Participants

This retrospective study included consecutive patients with myopic MNV treated with IVB between January 2008 and December 2018 at the Rotterdam Eye Hospital (Rotterdam, the Netherlands). Inclusion criteria were high myopia (spherical equivalent [SE] ≤ -6 Diopters (D) or axial length [AL] >26.5 mm); active MNV confirmed by leakage on fluorescein angiography or by optical coherence tomography (OCT) angiography combined with signs of active MNV (e.g., subretinal fluid) on SD-OCT and White ethnicity. Exclusion criteria were MNV secondary to any cause other than high myopia or eyes with other ocular (coexisting) pathology such as AMD, advanced cataract, intraocular inflammation, previous ocular trauma, and hereditary chorioretinal diseases. Of the 196 screened patients, 90 (46%) were excluded because of ethnicity ($n = 42$, 47%), SE > -6 D ($n = 24$, 27%), secondary MNV ($n = 13$, 14%) and unavailable imaging or any follow-up ($n = 11$, 12%). This study was approved by the institutional scientific review board and adhered to the principles of the Declaration of Helsinki.

Data Collection

Patient characteristics were ascertained from medical records. The phenotypic features were determined

on multimodal imaging (color fundus imaging, OCT, and fundus autofluorescence), and central macular thickness and treatment regime at the first visit were registered. The algorithms provided by the OCT mapping software (Canon and Heidelberg) were used to calculate central macular thickness. Myopic macular degeneration was graded according to the META-PM classification system based on the available multimodal-imaging at baseline and at last visit. Graders were masked to the clinical data of the participants. The size of CRA and the MNV lesion was indicated as a proportion of the disc size. Best-corrected visual acuity (BCVA) was assessed at each visit during follow-up. Macular neovascularization was considered subfoveal when any portion of the lesion was located underneath the fovea, juxtafoveal when any portion was located ≤ 200 μm of the fovea, and extrafoveal when the MNV was located >200 μm of the fovea. Recurrent myopic MNV was defined as a new MNV lesion or reactivation of a previous MNV lesion more than 3 months after the last injection. Blindness and vision impairment were defined according to the World Health Organization criteria.¹⁶ In brief, moderate vision impairment was defined as visual acuity 0.52 LogMAR to 1.00 LogMAR, severe vision impairment as 1.02 LogMAR to 1.30 LogMAR, and blindness as more than 1.30 LogMAR.

Intervention

A 30-gauge needle was used to inject 1.25-mg bevacizumab intravitreally. The patients underwent ophthalmic examination including BCVA testing and OCT one month after a loading dose of 1 to 3 injections. When fluid persisted on OCT or a new retinal hemorrhage or hard exudates were observed, monthly injections were continued. The number of IVB injections at each episode was noted.

Outcomes and Statistical Analysis

Best-corrected visual acuity and recurrent myopic MNV incidence were primary outcomes. The number of injections and the incidence of vision impairment and blindness were secondary outcomes. Descriptive statistics of normally distributed data are summarized using their mean and SD; not normally distributed data using the median and interquartile range. Categorical data were summarized using frequencies and proportions. Decrease of BCVA per year was calculated per patient: $(\text{BCVA at the last visit} - \text{BCVA after treatment}) / (\text{Total follow-up duration} - \text{duration of treatment})$. The paired *t*-test was used to assess BCVA and central macular thickness differences before and after treatment in the first episode. To study the effect of

time on the BCVA, a linear mixed model was used to account for the correlations between the eyes of one patient. To investigate differences in continuous variables between different MNV locations, a one-way ANOVA was used. Post hoc analysis was performed with Bonferroni correction. Incidence rates and cumulative incidences with their 95% confidence intervals (CIs) were calculated for recurrent myopic MNV (at 2, 5, and 10 years), vision impairment (at 10 years), and blindness (at 10 years). For recurrent myopic MNV, the last treatment of the first episode was taken as a starting point (T[0]), and for vision impairment and blindness, the first treatment was taken as T[0]. The analysis of the risk factors for recurrent myopic MNV and VI/blindness was performed with a frailty model with the subject identification number as random factor to account for analyzing both eyes in the same patient. The analysis was performed using R, version 4.0.3. software, and a *P* value of 0.05 was considered statistically significant.

Results

In this study, 117 highly myopic eyes of 106 consecutive patients treated with IVB for myopic MNV were included. Sixty patients (57%) were women; the mean age of MNV onset was 58 ± 14 years, and the mean SE was -14 ± 4 D. Signs of myopic macular degeneration were present in 91 eyes (81%) at the first visit. Macular neovascularization lesions were located subfoveal (56 eyes, 48%), juxtafoveal (39 eyes, 33%), or extrafoveal (22 eyes, 18%). Other baseline characteristics are summarized in Table 1. Owing to the design of this study, follow-up ranged between 20 months and 153 months (mean SD = 77 ± 38 months). Ten eyes (9%) were lost to follow-up.

Treatment of First Episode Myopic Macular Neovascularization

Treatment loading dose(s) varied during the first episode and was dependent on the managing clinician (Table 1). Overall, the median total number of IVB injections during the first episode was 2 (IQR 1–5). In those who received a single dose, 30 of 93 eyes (32%) responded well with complete inactivation of the myopic MNV. Thirty of 117 eyes responded well with inactivation of the MNV after two injections, and in 20 of 117 eyes (17%) the MNV regressed after three injections. The first episode resulted in inactivity of all MNVs after a median period of 2 (IQR 0–5) months. During treatment of the first myopic MNV episode, the mean central macular thickness decreased significantly from $345 \pm 86 \mu\text{m}$ to $286 \pm 58 \mu\text{m}$ ($P < 0.001$), and

Table 1. Clinical Characteristics of Patients With Myopic MNV Treated With Intravitreal Bevacizumab Injections

Characteristics	Total (117 Patients/106 Eyes)
Age (years)	58 ± 14
Sex, female	57 (60%)
SE (diopters)	-14 ± 4
Axial length (mm)	30.4 ± 1.9
Pseudophakic	39 (46%)
Degree of myopic macular degeneration*	
None or fundus tessellation	17 (17%)
Diffuse CRA	27 (30%)
Patchy CRA	48 (53%)
Baseline BCVA (LogMAR)	0.56 ± 0.46
Baseline CMT (μm)	345 ± 86
Type 1 MNV (occult)	10 (9%)
Type 2 MNV (classic)	97 (83%)
Mixed Type 1 and Type 2 MNV	6 (5%)
MNV size (% disc diameter)	0.7 ± 0.5
Subfoveal MNV	56 (48%)
Juxtafoveal MNV	39 (33%)
Extrafoveal MNV	22 (18%)
Treatment loading dose(s)	
One dose	93 (80%)
Two doses	9 (7%)
Three doses	15 (13%)

Values are mean \pm SD unless otherwise indicated.

*The images of 92 eyes at baseline were graded for the presence of myopic macular degeneration.

CMT, central macular thickness

the mean BCVA improved from 0.56 ± 0.46 (20/80 Snellen) to 0.33 ± 0.33 LogMAR (20/50 Snellen; $P < 0.001$). No ocular injection-related adverse events were observed during the follow-up.

Recurrent Myopic Macular Neovascularization

The incidence rate of recurrent myopic MNV in the studied population was 15.8 (95% CI: 12.4–19.7) cases per 100 persons per year. The cumulative incidence of recurrent myopic MNV was 34% (95% CI: 26%–43%) at 2 years, 59% (95% CI: 48%–69%) at 5 years, and 67% (95% CI: 55%–77%) at 10 years as shown in Figure 1A. All recurrences were treated with IVB injections, the median number of injections per recurrence was 2 (IQR 1–6). Sex, age at the first diagnosis, SE, lacquer cracks, and size of MNV lesion were not significantly associated with recurrent myopic MNV (Table 2). Recurrent myopic MNV was significantly associated with the presence of patchy CRA (hazard ratio [HR] 3.0, $P = 0.02$) at baseline and subfoveal location of the MNV (HR 1.3, $P = 0.048$, Table 2). Diffuse CRA was borderline significantly associated with recurrent myopic MNV (HR 2.4, $P = 0.059$).

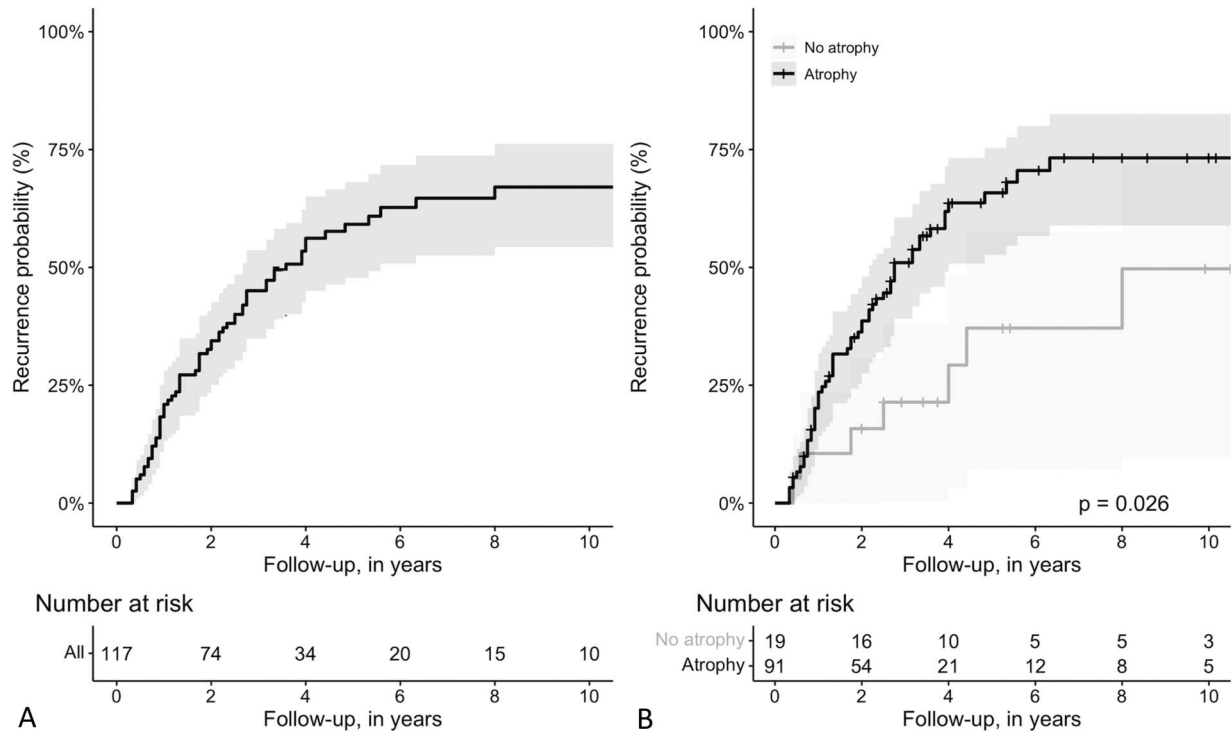


Fig. 1. A. and B. Recurrence probability of myopic MNV after the first onset in all eyes (A) and in eyes with or without CRA (B). Diffuse and patchy CRA were combined to a single line.

Course of Best-Corrected Visual Acuity

In this treated study population, the BCVA significantly improved from 0.56 ± 0.46 LogMAR at baseline to 0.38 ± 0.45 at 12 months ($P < 0.001$) and remained significantly better at 24 months (0.44 ± 0.47 LogMAR, $P < 0.001$) and at 36 months (0.43 ± 0.47 LogMAR, $P = 0.001$). At 48 months, the BCVA was no longer significantly better than baseline (0.55 ± 0.57 LogMAR, $P = 0.30$) and decreased further during the follow-up (Figure 2). The BCVA decreased with a mean of 0.05 ± 0.15 LogMAR per year in the affected eye after regression of the first MNV episode and 0.01 ± 0.01 LogMAR per year in the healthy fellow eye ($P < 0.001$). Best-corrected visual acuity in eyes with recurrent myopic MNV decreased at a similar rate as eyes with MNV without recurrences ($P = 0.58$, 95% CI: -0.02 to 0.04). The course of the BCVA in eyes with myopic MNV after anti-VEGF treatment in this study and previous studies is shown in Figure 3A.

In Table 3, the clinical characteristics per MNV location are summarized. Patients with subfoveal MNV had significantly shorter eyes ($P = 0.007$), a larger MNV lesion ($P < 0.001$), and more IVB injections at the first episode ($P = 0.008$) compared with patients with extrafoveal MNV. In Figure 3B the BCVA course of treated myopic MNV eyes per loca-

tion are presented. Subfoveal MNV had a significant worse baseline BCVA and final BCVA compared with eyes with extrafoveal MNV ($P < 0.001$, $P = 0.001$) and juxtafoveal MNV ($P < 0.001$, $P = 0.049$).

Vision Impairment and Blindness

The incidence rate of moderate vision impairment after the first diagnosis of myopic MNV was 6.7 (95% CI: 4.7–9.2) cases per 100 persons per year, the incidence rate of severe vision impairment was 2.7 (95% CI: 1.6–4.3) cases per 100 persons per year, and the incidence rate of blindness was 2.1 (95% CI: 1.1–3.5) cases per 100 persons per year. The cumulative incidence of moderate vision impairment at 5 years was 27% (95% CI: 19%–36%) and at 10 years 44% (95% CI: 31%–56%); of severe vision impairment 12% (95% CI: 7%–19%) and 22% (95% CI: 12%–34%) and of blindness 11% (95% CI: 6%–19%) and 25% (95% CI: 12%–40%) as shown in Figure 4. Baseline BCVA was significantly associated with developing moderate vision impairment (HR 4.9 95% CI: 2.2–11.0, $P < 0.001$), severe vision impairment (HR 4.9 95% CI: 2.1–11.4, $P < 0.001$), and blindness (HR 4.3 95% CI: 1.6–11.4, $P = 0.003$) after adjusting for age. Subfoveal location of the MNV was also associated with worse visual outcome (Table 2).

Table 2. Univariate and Multivariable Frailty Model of Associated Risk Factors for Recurrent Myopic MNV, Moderate and Severe Vision Impairment

<i>Univariate Frailty Model</i>						
Variable	Recurrent MNV		Moderate Vision Impairment		Severe Vision Impairment	
	HR (95% CI)	<i>P</i>	HR (95% CI)	<i>P</i>	HR (95% CI)	<i>P</i>
Sex	1.09 (0.65–1.82)	0.75	0.80 (0.42–1.55)	0.52	0.47 (0.18–1.25)	0.13
Age	1.01 (0.99–1.03)	0.47	1.01 (0.99–1.04)	0.28	1.05 (1.01–1.09)	0.02
SE	1.04 (0.96–1.13)	0.32	1.02 (0.94–1.10)	0.71	0.97 (0.87–1.09)	0.63
Tessellated fundus	1.0	—	1.0	—	1.0	—
Diffuse CRA	2.34 (0.91–6.04)	0.08	1.46 (0.56–3.79)	0.44	5.65 (0.72–44.08)	0.10
Patchy CRA	3.14 (1.17–8.48)	0.02	1.14 (0.41–3.20)	0.80	2.36 (0.26–21.16)	0.44
Lacquer cracks	1.19 (0.59–2.38)	0.63	1.22 (0.60–2.48)	0.59	1.62 (0.61–4.32)	0.34
Location; extrafoveal MNV	1.0	—	—	—	—	—
Juxtafoveal MNV	1.86 (0.72–4.81)	0.20	—	—	—	—
Subfoveal MNV	2.72 (1.11–6.65)	0.03	2.51 (1.11–5.66)	0.03	1.58	0.43
Baseline BCVA	—	—	6.43 (3.21–12.89)	<0.001	4.32 (1.95–9.59)	<0.001
Size of MNV	1.31 (0.63–2.77)	0.47	2.20 (1.39–3.47)	<0.001	2.01 (1.39–3.47)	0.04
<i>Multivariate Frailty Model</i>						
Variable	Recurrent MNV		Moderate Vision Impairment*		Severe Vision Impairment	
	HR (95% CI)	<i>P</i>	HR (95% CI)	<i>P</i>	HR (95% CI)	<i>P</i>
Sex	—	—	—	—	—	—
Age	—	—	1.00 (0.97–1.04)	0.81	1.06 (1.01–1.10)	0.01
SE	—	—	—	—	—	—
Tessellated fundus	1.0	—	—	—	—	—
Diffuse CRA	2.38 (0.97–5.84)	0.059	—	—	—	—
Patchy CRA	3.04 (1.19–7.78)	0.02	—	—	—	—
Lacquer cracks	—	—	—	—	—	—
Location; extrafoveal MNV	1.0	—	—	—	—	—
Juxtafoveal MNV	1.55 (0.59–4.06)	0.38	—	—	—	—
Subfoveal MNV	2.52 (1.01–6.29)	0.048	2.21 (0.91–5.38)	0.08	—	—
Baseline BCVA	—	—	5.95 (2.34–15.14)	<0.001	4.90 (2.10–11.44)	<0.001
Size of MNV	—	—	—	—	—	—

For each variable, HR and 95% CI are reported. The patient identification number was used as a random factor to account for analyzing both eyes of the same patient.

*Adjusted for age.

Chorioretinal Atrophy

Chorioretinal atrophy developed or increased between baseline and the final visit in 61 of 116 eyes (53%). Figure 5 shows an example of a high myopic patient after treatment with IVB injections. Of the 23 eyes with tessellated fundus at baseline, three eyes (13%) progressed to diffuse CRA, two eyes (9%) to patchy CRA, and two eyes (9%) to macular atrophy. Ten (20%) of the 49 eyes with diffuse CRA at baseline progressed to patchy atrophy and 10 (20%) eyes to macular atrophy. In 40 eyes (90%) with patchy CRA at baseline the size of atrophy increased, and in 13 eyes (30%), the atrophy progressed to the fovea. Eyes with increase of CRA during follow-up had a worse baseline BCVA and worse final BCVA ($P = 0.003$, $P = 0.003$, respectively).

Discussion

This study investigated the long-term outcome of IVB in White patients with myopic MNV. A median of two injections per MNV episode sufficed to successfully treat half of the patients, and 9% needed more than 10 injections to establish regression of the neovascular lesion. In most of the patients, BCVA improved significantly at the initial phase but decreased below baseline after approximately 5 years. The myopic eyes which had developed MNV had a worse decline of BCVA than myopic fellow eyes without MNV. After 10 years, one of two eyes with macular neovascularization was at least moderately visually impaired. Recurrence of MNV occurred

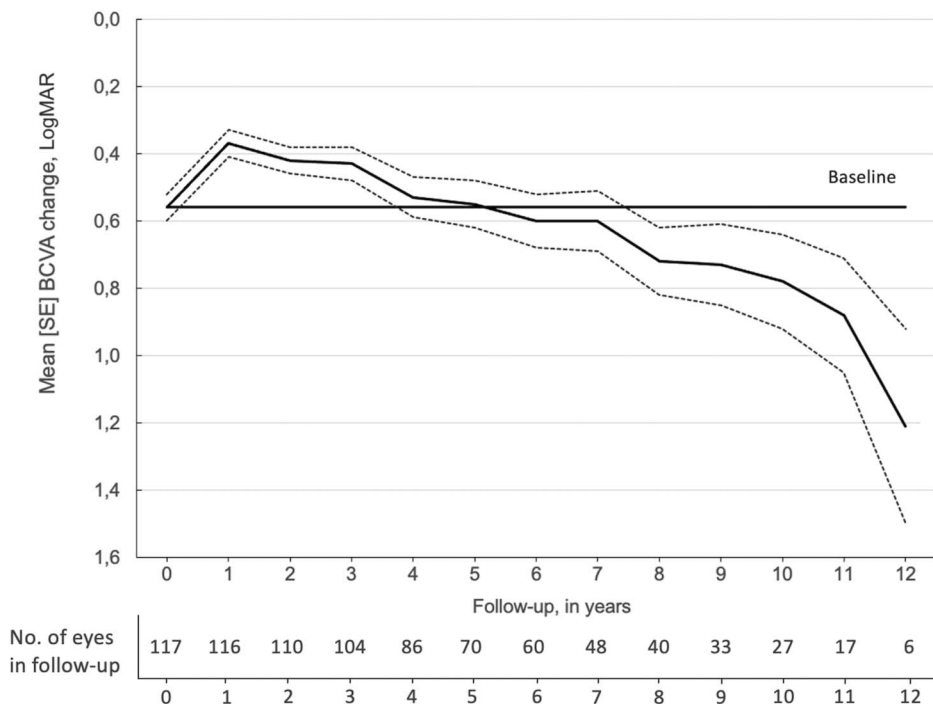


Fig. 2. Changes in the mean BCVA (LogMAR) after treatment with IVB injections. The error bars illustrate the standard error of the mean. The horizontal line represents the mean BCVA before treatment. Mean BCVA significantly improved compared with baseline during the first 3 years of follow-up (all $P < 0.05$, linear mixed model). After returning to baseline at 5 years, the BCVA deteriorates even further (all $P \geq 0.05$).

frequently in our patients; however, visual outcome in eyes with recurrences was similar to eyes without.

This study has strengths and limitations. Strengths include the routine care setting and the long duration of follow-up. Although follow-up was variable for each patient, at least one of five eyes completed 10 years of follow-up. In contrast to clinical trials, we had very few

exclusion criteria, which facilitates external validity and may direct patient management in routine clinical practice. Another strength is the comparison with BCVA in non-MNV myopic fellow eyes, which served as a reference for the natural course in highly myopic eyes. Potential limitations of this study are the retrospective design, relative small sample size,

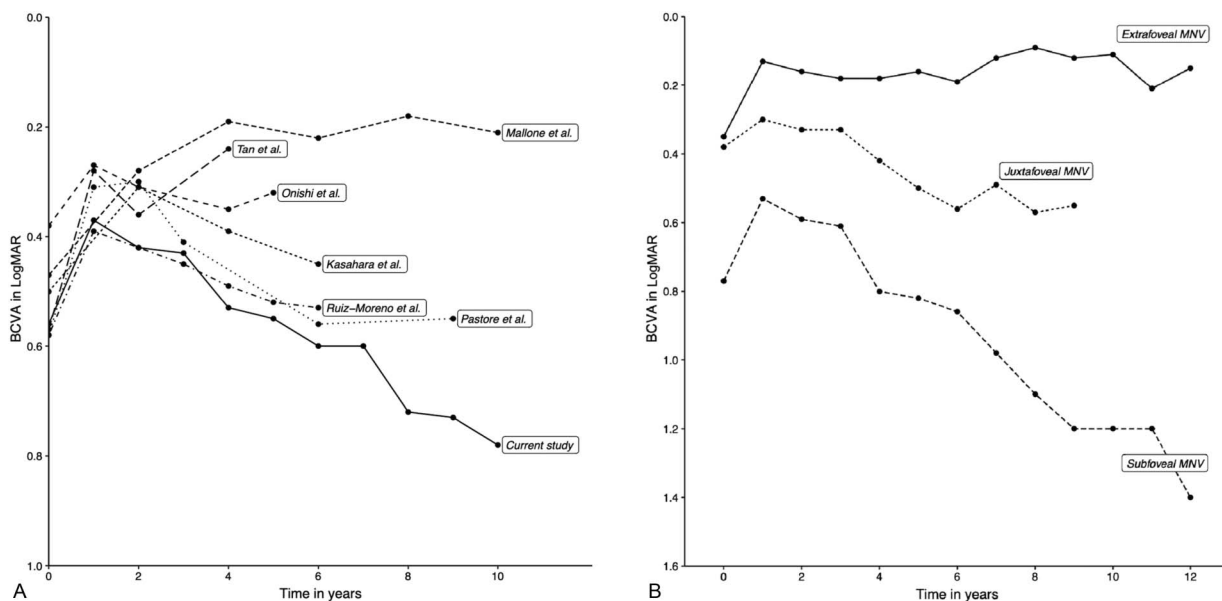


Fig. 3. A. and B. Changes of the mean BCVA (LogMAR) after IVB injections in myopic MNV. **A.** shows the course of the BCVA in this study and previous myopic MNV studies. Patients in this study ($n = 117$) and in the studies of Kasahara et al⁵ ($n = 36$), Mallone et al⁹ ($n = 30$), and Ruiz-Moreno et al⁷ ($n = 97$) received IVB, while patients in the studies of Onishi et al¹⁰ ($n = 51$), Ruiz-Moreno et al¹⁷ ($n = 19$), Pastore et al²² ($n = 17$), and Tan et al ($n = 41$) were treated with intravitreal ranibizumab. **B.** Shows the mean BCVA per MNV location in this study. Eyes with subfoveal MNV had a significant worse final BCVA compared with juxtafoveal lesions ($P = 0.049$) and extrafoveal lesions ($P < 0.001$).

Downloaded from http://journals.lww.com/retinajournal by BhdMf5ePHkav1zEoun1QIN4a+kLlHEZqbslHo4XMI0 hCymCX1AMnYQp/llQrHD38D00DRy7TtVSFI4C3VC4OAVpDDa8K2+Ya6h515KE= on 03/22/2023

Table 3. Clinical Characteristics of Patients With Myopic MNV per Location

	Group 1: Subfoveal MNV	Group 2: Juxtafoveal MNV	Group 3: Extrafoveal MNV	<i>P</i> ANOVA	Group 1 Versus Group 2 <i>P</i> = (95% CI)	Group 1 Versus Group 3 <i>P</i> = (95% CI)
No. of eyes	54	38	21			
Age (years)	60 ± 13	58 ± 14	52 ± 16	0.04	NS	0.04 (0.2–17.4)
SE (diopters)	−13 ± 3	−14 ± 4	−16 ± 5	0.006	NS	0.005 (0.8–6.0)
Axial length (mm)	29.8 ± 1.5	30.6 ± 1.8	32.4 ± 2.6	0.008	NS	0.007 (−4.6 to −0.6)
BCVA (LogMAR)						
Baseline	0.76 ± 0.47	0.40 ± 0.34	0.34 ± 0.42	<0.001	<0.001 (0.18–0.61)	<0.001 (0.16–0.68)
After treatment	0.45 ± 0.37	0.25 ± 0.28	0.14 ± 0.16	<0.001	0.004 (0.06–0.38)	<0.001 (0.13–0.52)
Last visit	0.77 ± 0.66	0.49 ± 0.55	0.29 ± 0.43	<0.001	0.049 (0.00–0.59)	0.001 (0.21–0.93)
Baseline CMT (μm)	381 ± 86	319 ± 71	300 ± 76	<0.001	0.006 (14–106)	0.001 (29–142)
MNV size (% disc diameter)	0.9 ± 0.6	0.7 ± 0.3	0.4 ± 0.3	<0.001	NS	<0.001 (0.2–0.7)
Number of injections						
First episode, median (IQR)	3 (2–6)	2 (1–4)	1 (1–3)	0.007	NS	0.008 (1.1–9.3)
Total, median (IQR)	7 (5–17)	4 (2–12)	2 (1–7)	0.05	—	—

Values are mean ± SD unless otherwise indicated. None of the post hoc tests between juxtafoveal and extrafoveal MNV were significant and therefore not stated in this table.

CMT, central macular thickness; NS, not significant

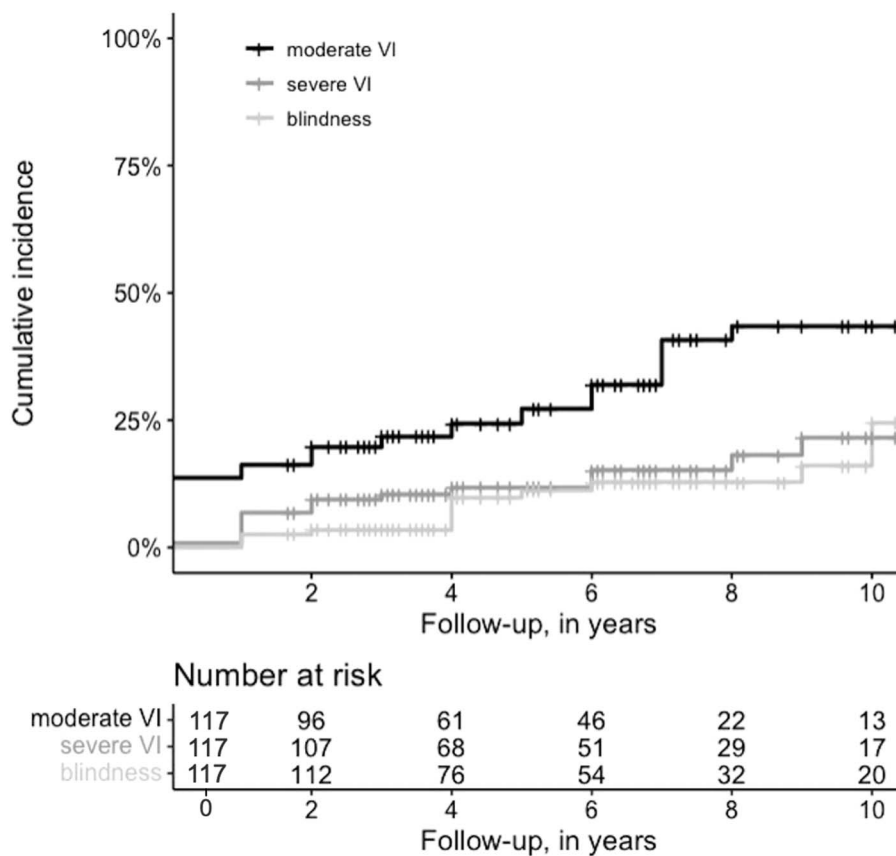


Fig. 4. Cumulative incidence of moderate vision impairment, severe vision impairment and blindness after treatment for MNV in high myopic eyes during follow-up.

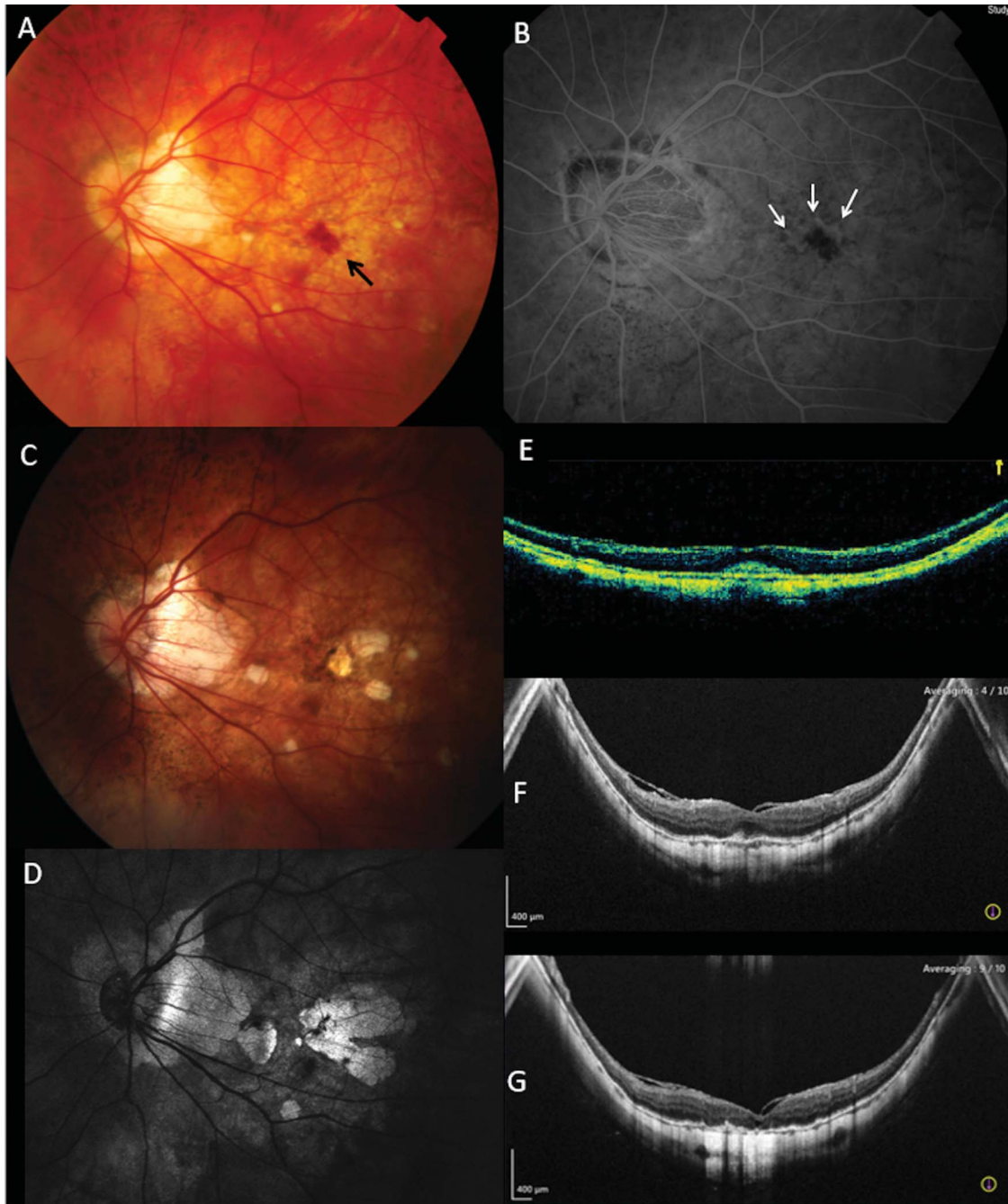


Fig. 5. A.–G. Development and enlargement of the MNV-related atrophy after IVB for myopic MNV. **A.** Left eye of a 58-year-old man with an axial length of 30.6 mm; the black arrow indicates a hemorrhage. **B.** Fluorescein angiogram shows hyperfluorescence with active leakage in the macula (white arrows). BCVA was 20/63, and the patient was treated with four IVB injections. **C.** Four years after the initial treatment, small atrophic lesions are present in the macula. **D.** Eight years after treatment the lesions have merged into one large macular lesion. Optical coherence tomography shows the development of the MNV-related atrophy with the subfoveal lesion at baseline (**E**), after 4 years (**F**), and after 8 years (**G**).

nonstandardized treatment regimen, and irregular follow-up. Nevertheless, this study is one of the largest studies on myopic MNV. Treatment loading dose was depended on the treating physician; which in some cases led to initiation of a series of IVB injections. This may resulted in an overestimation of the number of IVB

injection needed in some cases. However, only 11 of the 24 cases that received two or three injections as a treatment loading dose did not require further treatment.

In contrast to MNV's in AMD, highly myopic eyes usually do not need lifelong treatment. Ruiz-Moreno et al¹⁷ reported that one single loading dose in eyes

with myopic MNV had similar anatomical and visual outcomes as three loading dosages. Other studies confirmed the efficacy of a single dose in 33% to 67% of the eyes.^{5,12,14,15,18,19} These results changed the clinical routine for myopic MNV in many clinics to injection of one single loading dose followed by additional injections when needed. In this study, 80% of the eyes were treated with one single injection during the first episode of myopic MNV, of which 32% was successful. Thus, 20% was treated with 2 to 3 loading doses, which may not have been necessary. The RADIANCE study¹¹ showed that larger myopic MNV lesions will require more injections; and similar results have been found by Ruiz-Moreno et al.⁷ These results could not be supported in our study. However, eyes with subfoveal MNV required significant more IVB injections than eyes with extrafoveal MNV. In addition, subfoveal MNV lesions were significantly larger than extrafoveal MNV lesions. These results suggest that either location or size of the lesion contribute to the total number of injections. In contrast to the standard neovascular AMD protocol, we recommend to start with a single injection for MNV due to myopia. Highly myopic eyes are at significant risk of developing atrophy,²⁰ and at this stage, it is still unclear whether anti-VEGF accelerates this process.

Our data support previous studies which demonstrated efficacy of anti-VEGF agents in improving visual acuity in myopic eyes with MNV as an initial response.^{5–8,13,15,21} Most longer-term studies reported that the improved visual acuity could not be maintained. Ruiz-Moreno et al⁷ retrospectively studied the long-term outcomes of highly myopic eyes with MNV treated with IVB (78 eyes) or ranibizumab (19 eyes) and was unable to detect a significant difference in BCVA at 48 months. Kasahara et al⁵ reported a significant increase of the BCVA in 36 highly myopic eyes after treatment with IVB, but this could not be maintained at 6 years. In their series, the baseline BCVA, size of the MNV lesion, and size of the MNV-related atrophy were significant predictors for the final BCVA. Recently, Mal-lone et al⁹ reported 10-year treatment outcomes of IVB injections in 30 highly myopic eyes. Although all eyes had developed MNV-related CRA at 5 years, BCVA remained significantly better compared with baseline at 10 years. In contrast to our study where most MNVs were located subfoveally, most of the MNVs in their study were located juxtafoveal (47%) or extrafoveal (33%), which could explain the stable BCVA over time. Pastore et al²² investigated intravitreal ranibizumab in 17 eyes with myopic MNV. Best-corrected visual acuity initially improved measured at 12 and 24 months; however,

at 60 months, BCVA returned to baseline where it remained. Wu et al²³ showed a similar pattern in 18 eyes with mostly subfoveal MNV lesions, and Holtz et al¹¹ reported that at 48 months, the BCVA gain could be maintained in all 16 eyes in post RADIANCE observations. Both studies used intravitreal ranibizumab. Our study includes one of the longest follow-up period of treatment outcomes in myopic MNV reported up until now; our results demonstrate that BCVA not only returns to baseline after 5 years but continues to deteriorate to 1.21 LogMAR (20/320 Snellen) after 12 years. Interestingly, this course does not seem to be specific for myopic MNV because neovascular AMD shows a similar pattern after treatment.^{24,25} As we summarized in Figure 3A, our study and most other long-term follow-up studies, show a similar pattern of BCVA after IVB injections for myopic MNV up to approximately 6 years. However, the development of CRA seems an important predictor for the final visual function, and this study in addition to other reports, also shows that the location of the MNV is crucial for the visual prognosis.

The terminology for recurrent myopic MNV varies widely among previous studies. Tan et al showed that 9.8% of their patients developed a MNV recurrence during 48 months of follow-up, which corresponded to an annualized rate of 0.06 recurrences/year. Other studies have reported on the number of eyes that remained free of retreatment. These reports however do not have further specifications. In our study recurrence of a myopic MNV was defined as a reactivation or a new MNV more than 3 months after the last injection; others did not provide definitions hampering a true comparison. We show that the risk profile for recurrent myopic MNV is similar to that of the first myopic MNV, namely presence of patchy CRA. In addition, eyes with subfoveal MNVs are more likely to develop a recurrent MNV. Other factors, such as age, SE, and MNV size were not significant predictors for MNV recurrence in this study. All recurrent myopic MNVs were treated with IVB injections, it is however of interest that these recurrences did not alter the visual prognosis.

To summarize, this retrospective myopic MNV study in White patients showed that the positive treatment effect of anti-VEGF injections lasted for 5 years. Lifelong treatment is not necessary for most myopic MNV: 1 to 10 injections were enough to cause regression of the MNV in 91% of cases. One of two eyes developed a recurrent myopic MNV over time, but recurrences did not worsen the course of the BCVA. Large prospective studies using multimodal imaging are needed to build on these findings and

elude biomarkers to optimize treatment and visual outcome.

Key words: anti-vascular endothelial growth factor therapy, bevacizumab, macular neovascularization, myopia, visual outcome, recurrence, chorioretinal atrophy.

References

1. Wong TY, Ferreira A, Hughes R, et al. Epidemiology and disease burden of pathologic myopia and myopic choroidal neovascularization: an evidence-based systematic review. *Am J Ophthalmol* 2014;157:9–25.e12.
2. Wolf S, Balciuniene VJ, Laganovska G, et al. RADIANCE: a randomized controlled study of ranibizumab in patients with choroidal neovascularization secondary to pathologic myopia. *Ophthalmology* 2014;121:682–692.e2.
3. Ikuno Y, Ohno-Matsui K, Wong TY, et al. Intravitreal aflibercept injection in patients with myopic choroidal neovascularization: the MYRROR study. *Ophthalmology* 2015;122:1220–1227.
4. Tufail A, Narendran N, Patel PJ, et al. Ranibizumab in myopic choroidal neovascularization: the 12-month results from the repair study. *Ophthalmology* 2013;120:1944–1945.e1.
5. Kasahara K, Moriyama M, Morohoshi K, et al. Six-year outcomes of intravitreal bevacizumab for choroidal neovascularization in patients with pathologic myopia. *Retina* 2017;37:1055–1064.
6. Chhablani J, Paulose RM, Lasave AF, et al. Intravitreal bevacizumab monotherapy in myopic choroidal neovascularisation: 5-year outcomes for the PAN-American Collaborative Retina Study Group. *Br J Ophthalmol* 2018;102:455–459.
7. Ruiz-Moreno JM, Montero JA, Araiz J, et al. Intravitreal anti-vascular endothelial growth factor therapy for choroidal neovascularization secondary to pathologic myopia six years outcome. *Retina* 2015;35:2450–2456.
8. Sarao V, Veritti D, Macor S, Lanzetta P. Intravitreal bevacizumab for choroidal neovascularization due to pathologic myopia: long-term outcomes. *Graefes Arch Clin Exp Ophthalmol* 2016;254:445–454.
9. Mallone F, Giustolisi R, Franzone F, et al. Ten-year outcomes of intravitreal bevacizumab for myopic choroidal neovascularization: analysis of prognostic factors. *Pharmaceuticals (Basel)* 2021;14:1042.
10. Onishi Y, Yokoi T, Kasahara K, et al. Five-year outcomes of intravitreal ranibizumab for choroidal neovascularization in patients with pathologic myopia. *Retina* 2019;39:1289–1298.
11. Holz FG, Tufail A, Leveziel N, et al. Ranibizumab in myopic choroidal neovascularization: a subgroup Analysis by ethnicity, age, and ocular characteristics in RADIANCE. *Ophthalmologica* 2016;236:19–28.
12. Ahn SJ, Woo SJ, Kim KE, Park KH. Association between choroidal morphology and anti-vascular endothelial growth factor treatment outcome in myopic choroidal neovascularization. *Invest Ophthalmol Vis Sci* 2013;54:2115–2122.
13. Hayashi K, Shimada N, Moriyama M, et al. Two-year outcomes of intravitreal bevacizumab for choroidal neovascularization in Japanese patients with pathologic myopia. *Retina* 2012;32:687–695.
14. Kuo JZ-C, Ong FSC, Yeung L, et al. Predictive factors for visual outcome to intravitreal bevacizumab in young Chinese patients with myopic choroidal neovascularization. *Retina* 2011;31:1835–1840.
15. Ikuno Y, Sayanagi K, Soga K, et al. Intravitreal bevacizumab for choroidal neovascularization attributable to pathological myopia: one-year results. *Am J Ophthalmol* 2009;147:94–100.e1.
16. World Health Organization. World Report on Vision; 2019. Available at: https://www.who.int/docs/default-source/documents/world-vision-report-post-launch-accessible.pdf?sfvrsn=1b29f0e7_2. Accessed August 2022.
17. Ruiz-Moreno JM, Montero JA, Arias L, et al. Three versus one intravitreal bevacizumab injections as initial protocol to treat myopic choroidal neovascularization. *Acta Ophthalmol* 2012;90:e82–e83.
18. Zheng F, Wong CW, Sabanayagam C, et al. Prevalence, risk factors and impact of posterior staphyloma diagnosed from wide-field optical coherence tomography in Singapore adults with high myopia. *Acta Ophthalmol* 2021;99:e144–e153.
19. Peiretti E, Vinci M, Fossarello M. Intravitreal bevacizumab as a treatment for choroidal neovascularisation secondary to myopia: 4-year study results. *Can J Ophthalmol* 2012;47:28–33.
20. Hayashi K, Ohno-Matsui K, Shimada N, et al. Long-term pattern of progression of myopic maculopathy: a natural history study. *Ophthalmology* 2010;117:1595–1611.e1-4.
21. Gharbiya M, Allievi F, Mazzeo L, Gabrieli CB. Intravitreal bevacizumab treatment for choroidal neovascularization in pathologic myopia: 12-month results. *Am J Ophthalmol* 2009;147:84–93.e1.
22. Pastore M, Capuano V, Bruyère E, et al. Nine-year outcome of ranibizumab monotherapy for choroidal neovascularization secondary to pathologic myopia. *Ophthalmologica* 2018;239:133–142.
23. Wu TT, Kung YH. Five-year outcomes of intravitreal injection of ranibizumab for the treatment of myopic choroidal neovascularization. *Retina* 2017;37:2056–2061.
24. Gillies MC, Campain A, Barthelmes D, et al. Long-term outcomes of treatment of neovascular age-related macular degeneration: data from an observational study. *Ophthalmology* 2015;122:1837–1845.
25. Rofagha S, Bhisitkul RB, Boyer DS, et al. Seven-year outcomes in ranibizumab-treated patients in ANCHOR, MARINA, and HORIZON: a multicenter cohort study (SEVEN-UP). *Ophthalmology* 2013;120:2292–2299.