

EUR Research Information Portal

Diagnostic performance of endoscopic tissue acquisition for pancreatic ductal adenocarcinoma in the PREOPANC and PREOPANC-2 trials

Published in:
HPB

Publication status and date:
Published: 01/10/2023

DOI (link to publisher):
[10.1016/j.hpb.2023.04.018](https://doi.org/10.1016/j.hpb.2023.04.018)

Document Version
Publisher's PDF, also known as Version of record

Document License/Available under:
CC BY

Citation for the published version (APA):

Janssen, Q. P., Quispel, R., the Dutch Pancreatic Cancer Group (DPCG), Besselink, M. G., Bonsing, B. A., Bruno, M. J., Doukas, M., Sarasqueta, A. F., Homs, M. Y. V., van Hooft, J. E., van Tienhoven, G., van Velthuysen, M. L. F., Verheij, J., Voermans, R. P., Wilmink, J. W., Groot Koerkamp, B., van Eijck, C. H. J., & van Driel, L. M. J. W. (2023). Diagnostic performance of endoscopic tissue acquisition for pancreatic ductal adenocarcinoma in the PREOPANC and PREOPANC-2 trials. *HPB*, 25(10), 1161-1168. <https://doi.org/10.1016/j.hpb.2023.04.018>

[Link to publication on the EUR Research Information Portal](#)

Terms and Conditions of Use

Except as permitted by the applicable copyright law, you may not reproduce or make this material available to any third party without the prior written permission from the copyright holder(s). Copyright law allows the following uses of this material without prior permission:

- you may download, save and print a copy of this material for your personal use only;
- you may share the EUR portal link to this material.

In case the material is published with an open access license (e.g. a Creative Commons (CC) license), other uses may be allowed. Please check the terms and conditions of the specific license.

Take-down policy

If you believe that this material infringes your copyright and/or any other intellectual property rights, you may request its removal by contacting us at the following email address: openaccess.library@eur.nl. Please provide us with all the relevant information, including the reasons why you believe any of your rights have been infringed. In case of a legitimate complaint, we will make the material inaccessible and/or remove it from the website.

ORIGINAL ARTICLE

Diagnostic performance of endoscopic tissue acquisition for pancreatic ductal adenocarcinoma in the PREOPANC and PREOPANC-2 trials

Quisette P. Janssen¹, Rutger Quispel², Marc G. Besselink³, Bert A. Bonsing⁴, Marco J. Bruno⁵, Michael Doukas⁶, Arantza F. Sarasqueta⁷, Marjolein Y.V. Homs⁸, Jeanin E. van Hooft⁹, Geertjan van Tienhoven¹⁰, Marie-Louise F. van Velthuysen⁶, Joanne Verheij⁷, Rogier P. Voermans¹¹, Johanna W. Wilmink¹², Bas Groot Koerkamp¹, Casper H.J. van Eijck^{1, #}, Lydi M.J.W. van Driel^{5#} on behalf of the Dutch Pancreatic Cancer Group

¹Department of Surgery, Erasmus MC Cancer Institute, Rotterdam, the Netherlands, ²Department of Gastroenterology, Reinier de Graaf Group, Delft, the Netherlands, ³Department of Surgery, Amsterdam UMC, University of Amsterdam, Cancer Center Amsterdam, Amsterdam, the Netherlands, ⁴Department of Surgery, Leiden University Medical Center, Leiden, the Netherlands, ⁵Department of Gastroenterology and Hepatology, Erasmus MC Cancer Institute, Rotterdam, the Netherlands, ⁶Department of Pathology, Erasmus MC Cancer Institute, Rotterdam, the Netherlands, ⁷Department of Pathology, Amsterdam UMC, University of Amsterdam, Cancer Center Amsterdam, Amsterdam, the Netherlands, ⁸Department of Medical Oncology, Erasmus MC University Medical Center, Rotterdam, the Netherlands, ⁹Department of Gastroenterology and Hepatology Leiden University Medical Center, Leiden, the Netherlands, ¹⁰Department of Radiation Oncology, Amsterdam UMC, University of Amsterdam, Cancer Center Amsterdam, Amsterdam, the Netherlands, ¹¹Department of Gastroenterology and Hepatology, Amsterdam UMC, University of Amsterdam, Amsterdam Gastroenterology and Metabolism, Amsterdam, the Netherlands, and ¹²Department of Medical Oncology, Amsterdam UMC, University of Amsterdam, Cancer Center Amsterdam, Amsterdam, the Netherlands

Abstract

Background: Neoadjuvant treatment for pancreatic ductal adenocarcinoma (PDAC) has increased, necessitating histopathologic confirmation of cancer. This study evaluates the performance of endoscopic tissue acquisition (TA) procedures for borderline resectable and resectable PDAC.

Methods: Pathology reports of patients included in two nationwide randomized controlled trials (PREOPANC and PREOPANC-2) were reviewed. The primary outcome was sensitivity for malignancy (SFM), considering both “suspicious for” and “malignant” as positive. Secondary outcomes were rate of adequate sampling (RAS) and diagnoses other than PDAC.

Results: Overall, 892 endoscopic procedures were performed in 617 patients, including endoscopic ultrasonography (EUS)-guided TA in 550 (89.1%), endoscopic retrograde cholangiopancreatography (ERCP)-guided brush cytology in 188 (30.5%), and periampullary biopsies in 61 patients (9.9%). The SFM was 85.2% for EUS, 88.2% for repeat EUS, 52.7% for ERCP, and 37.7% for periampullary biopsies. The RAS ranged 94–100%. Diagnoses other than PDAC were other periampullary cancers in 24 (5.4%), premalignant disease in five (1.1%), and pancreatitis in three patients (0.7%).

Conclusions: EUS-guided TA of patients with borderline resectable and resectable PDAC included in RCTs had an SFM above 85% for both first and repeat procedures, meeting international standards. Two percent had false positive result for malignancy and 5% had other (non-PDAC) periampullary cancers.

Received 3 October 2022; accepted 30 April 2023

Correspondence

Quisette P. Janssen, Department of Surgery, Erasmus MC Cancer Institute, University Medical Center Rotterdam, Dr. Molewaterplein 40, 3015 GD, Rotterdam, the Netherlands. E-mail: q.janssen@erasmusmc.nl

Correspondence

Lydi M.J.W. van Driel, Department of Gastroenterology and Hepatology, Erasmus MC Cancer Institute, University Medical Center Rotterdam, Dr. Molewaterplein 40, 3015 GD, Rotterdam, the Netherlands. E-mail: l.m.j.w.vandriel@erasmusmc.nl

* This paper is not based on previous communication to a society or meeting.

These authors share co-last authorship.

Introduction

The use of neoadjuvant treatment for patients with PDAC has increased. It is considered mandatory to obtain histological or cytological diagnosis prior to systemic treatment. Inherently, the role of endoscopy-guided tissue acquisition (TA) has increased significantly over time.¹ Endoscopic ultrasound (EUS) is recommended as first-line procedure when pathology diagnosis is required.² Additionally, endoscopic retrograde cholangiopancreatography (ERCP)-guided brush cytology can be performed during stent placement for obstructive jaundice. Last, endoscopy-guided biopsies of the duodenum, ampulla, or distal bile duct can prove malignancy.

Over the past decade, several studies have assessed the yield of EUS-guided TA for solid pancreatic or pancreatobiliary lesions.^{3,4} However, these studies were often small, generally performed in tertiary referral centres, and often included patients with varying diagnoses besides PDAC. It remains unclear whether these results can also be applied to patients with suspected PDAC who require a tissue confirmation of malignancy for neoadjuvant treatment. Moreover, only a few mostly small series have reported on the utility of a repeated endoscopic procedure in patients with initial inconclusive TA.^{5–9} Furthermore, the role of ERCP-guided brush cytology and periampullary biopsies for the diagnosis of PDAC has not been studied in large prospective cohorts. Moreover, definitive surgical histopathology or sufficient clinical follow-up is necessary to determine the final diagnosis, which is not always available for retrospective studies.

The aim of this study was to evaluate the diagnostic performance of the three different endoscopy-guided TA procedures in a post-hoc analysis of patients with borderline resectable or resectable PDAC participating in two nationwide RCTs (PREOPANC and PREOPANC-2).^{10,11} The quality indicators sensitivity for malignancy (SFM) $\geq 85\%$ and rate of adequate sampling (RAS) $\geq 85\%$ as proposed by the American Society for Gastrointestinal Endoscopy (ASGE)/American College of Gastroenterology (ACG) Task Force on Quality in Endoscopy were used to assess diagnostic performance.^{12,13}

Methods

Study design and patient selection

We performed a post-hoc analysis by reviewing the endoscopy-guided TA of 623 patients with borderline resectable and resectable PDAC included in two nationwide RCTs: the PREOPANC (April 2013–June 2017) and PREOPANC-2 (June 2018–January 2021) trial.^{10,11} Inclusion and exclusion criteria for the trials are outlined in [Supplementary Table 1](#). The nationwide network and registry of pathology in the Netherlands (PALGA: Dutch Pathology Registry) was used as source for the cyto- and histopathologic diagnoses before therapy and the final surgical pathology diagnosis.¹⁴ Patients without an endoscopic-TA procedure for suspected PDAC prior to inclusion of the

trial or patients who withdrew informed consent were excluded from the present study. The trial protocols were centrally approved by the institutional review board of the Erasmus MC University Medical Center (MEC-2012-249, approved December 11, 2012; MEC-2018-004, approved May 16, 2018) with subsequent local approval by all participating centers. Both trials were registered at the EU Clinical Trials Register (Eudra-CT 2012-003181-40, December 11, 2012; Eudra-CT 2017-002036-17, March 6, 2018). All patients provided written informed consent for trial participation. This study is presented according to the STROBE guidelines.

Endoscopy-guided tissue acquisition

EUS-guided FNA and/or FNB, ERCP-guided brush cytology, and/or endoscopy-guided periampullary biopsy was performed to obtain proof of suspected PDAC prior to inclusion. The diagnostic work-up was conducted at local referring centers or at one of the 17 designated pancreatic surgery referral centers in the Netherlands assembled in the Dutch Pancreatic Cancer Group (DPCG), often with pathology review at one of the DPCG centers. Based on the pathology reports, cytology and histology materials were classified into six categories; insufficient for analysis (b1), benign (b2), atypical (b3), neoplastic other (b4, e.g., noninvasive intraductal papillary mucinous neoplasm (IPMN), pancreatic neuroendocrine tumor (pNET)), suspicious for malignancy (b5), and malignant (b6), based on the standard for evaluating pancreatic cytology by the Papanicolaou Society of Cytopathology.¹⁵ This classification was performed by QP with supervision of MvV (expert pathologist with 27 years of experience). Duodenal, ampullary, and distal bile duct biopsies were combined as periampullary biopsies for the analyses. Tumor location was categorized as pancreas head or body/tail, whereby masses in the pancreatic head, neck, uncinate process, and periampullary region were included as head tumors. ERCP-guided brush cytology was acquired by cannulation of the distal common bile duct in the stenotic area going through the pancreas.

PALGA cohort

For the present study, all reports containing the term “*pancreas*”, “*extrahepatic bile duct*”, or “*duodenum*” of the patients included in the PREOPANC and PREOPANC-2 trial were retrieved from the national pathology registry PALGA.¹⁴ The reports included data on sex, age, and date of investigation.

Outcomes

The primary outcome was the SFM of the different endoscopy-guided TA procedures. SFM was calculated by dividing the number of true positives (i.e., malignancy based on EUS-guided TA with a malignant final diagnosis) by the sum of true positives and false negatives (i.e., both malignant and non-malignant diagnosis based on endoscopy-guided TA in patients with a

malignant final diagnosis). Diagnostic materials were considered positive for malignancy if described as “suspicious” or “positive for malignancy” in the pathology report (broad definition, b6+b5). Histopathology of the resected specimen or clinical follow-up for at least one year for patients without a resection was used as reference standard. Postoperative diagnoses of noninvasive IPMN and well-differentiated pNET were considered premalignant tumors, thereby negative for malignancy.

Secondary outcomes included the SFM considering only specimens described as malignant in the pathology report (strict definition, b6), the SFM for repetition of the same endoscopic procedure, the RAS, the rate of final diagnoses other than PDAC, and the number of procedures performed to obtain pathological diagnosis of PDAC. The RAS was defined as the proportion of all procedures yielding a specimen sufficient for cyto-and/or histopathological analysis. To avoid confirmation bias, the rate of final diagnoses other than PDAC was solely based on the resection cohort.

Four subgroup analyses were performed. First, the SFM was calculated solely based on the surgical histopathology as reference standard (i.e. for patients who underwent resection only). Second, the SFM of the different procedures was compared between patients with a head or body/tail tumor. Third, the SFM of the different procedures was compared based on sex. Last, the value of external pathology review was assessed by comparing the classification of the diagnostic specimens with and without consideration of pathology review. Specificity, positive predictive value, negative predictive value, and accuracy were not calculated since evidence of PDAC was a requirement for both trials.

Statistical analysis

Outcomes were presented for the complete cohort and separately for tumors in the head and body/tail. Continuous variables were presented as medians with interquartile ranges (IQRs) and categorical variables as frequencies and proportions. Number of missing data were shown in the table notifications. Differences in continuous variables between groups were calculated using the Mann–Whitney U test. For categorical variables, the Chi-square test or Fisher’s exact test was used, as appropriate. All tests were two-sided and a p-value less than 0.05 was considered statistically significant. All analyses were performed using R software version 3.4.3.

Results

Patient and tumor characteristics

The PREOPANC ($n = 248$) and PREOPANC-2 ($n = 375$) trials included 623 patients in total. Six patients were excluded due to withdrawal of informed consent or because no endoscopic-TA procedure was performed. The remaining 617 patients were analyzed (Fig. 1). Patient and tumor characteristics are shown in Table 1a. In total, 447 patients underwent a resection, of whom 415 (92.8%) had PDAC and 32 (7.2%) had a diagnosis other than

PDAC, including other periampullary cancer type (mostly distal cholangiocarcinoma) in 24 (5.4%), a premalignant disease (mostly IPMN) in five (1.1%), and pancreatitis in three patients (0.7%). The 171 patients who did not undergo a resection all had a malignant diagnosis based on clinical follow-up. Table 2 gives an overview of the endoscopic procedures and highest cytological classification for the 32 patients with other final diagnoses.

Endoscopy-guided tissue acquisition

In total, 892 procedures were performed in 617 patients (Fig. 1, Table 1B). The most performed procedure was EUS-guided TA in 550 patients (89.1%). ERCP-guided brush cytology was performed in 188 patients (30.5%), whilst an endoscopic periampullary biopsy was performed in 61 patients (9.9%). Patients with a tumor in the head of the pancreas more often underwent an additional TA attempt (35.7% vs. 7.1%, $p < 0.001$).

Diagnostic performance

The diagnostic performance of the endoscopy-guided TA procedures is shown in Table 3. Considering only the first procedures, the SFM (broad definition, b6+b5) was 85.2% for EUS, 52.7% for ERCP, and 37.7% for periampullary biopsies. The SFM using the strict definition (b6) was considerably lower for all procedures, ranging from 26.9% for ERCP to 64.8% for EUS. Considering the repeat procedures, EUS also showed the highest SFM using both the broad (88.2%) and strict (61.8%) definition. In a subgroup analysis of the patients who underwent a resection, the SFM was similar; 85.2% for EUS, 54.3% for ERCP, and 24.4% for periampullary biopsies. The RAS was high for all procedures, ranging from 94 to 100%.

In a subgroup analysis comparing patients with pancreas head and body/tail tumors, the SFM for the first EUS-guided TA procedure was higher for patients with a body/tail tumor (83.7% vs. 94.0%, $p = 0.01$) when the broad definition was used, yet comparable when the strict definition was used (64.3% vs. 66.7%, $p = 0.68$) (Supplementary Table 2). No difference was found between pancreas head and body/tail tumors for the repeat EUS-guided TA procedures.

In a subgroup analysis comparing the SFM based on sex, no difference was found for any of the endoscopy-guided TA procedures (Supplementary Table 3).

Tissue proof of malignancy

For 42 patients (6.8%), the proof of malignancy (broad definition, b6+b5) was based on more than one procedure (Supplementary Figure 1). EUS-guided TA most often provided the proof of malignancy (85.9%), either by itself ($n = 490$, 79.4%) or also by ERCP-guided brush cytology ($n = 35$, 5.7%) or periampullary biopsies ($n = 5$, 0.8%). Regarding the certainty of the diagnosis, the specimen was categorized as malignant (b6) in 467 patients (75.7%) and suspicious for malignant (b5) in 144 patients (23.3%), whilst five patients (1.0%) were included in the trials (i.e., protocol violations) based on the presence of atypical

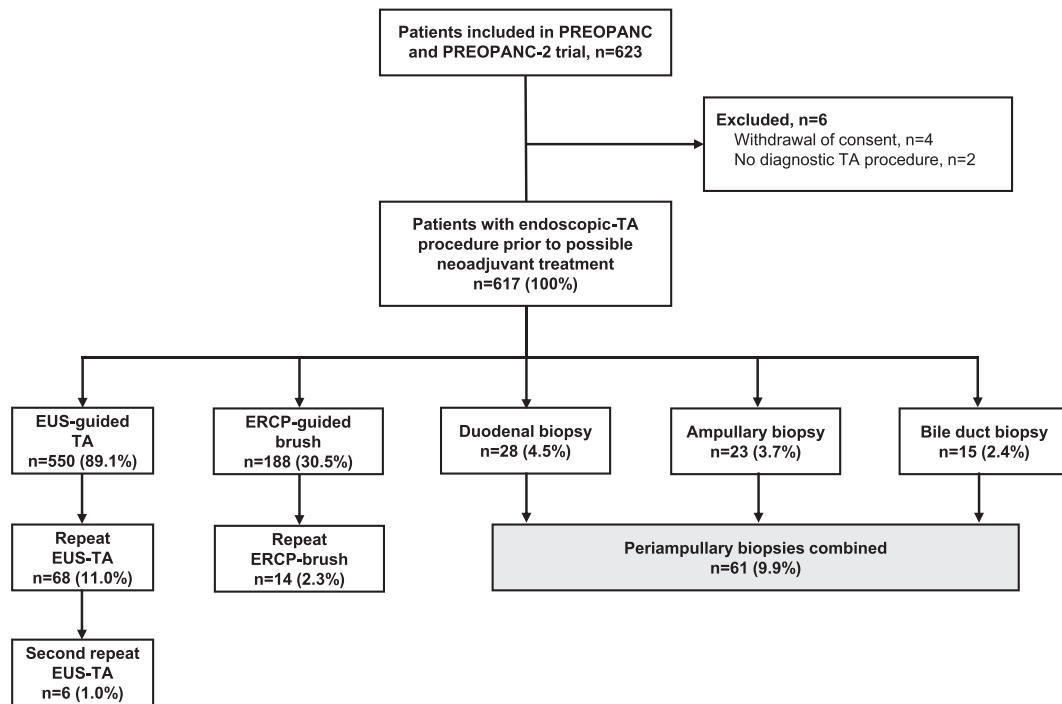


Figure 1 Flow diagram of diagnostic tissue acquisition procedures. Abbreviations: EUS, Endoscopic ultrasonography; ERCP, Endoscopic retrograde cholangiopancreatography; TA, tissue acquisition

cells (b3, $n = 3$) or benign cytology (b2, $n = 2$). Final diagnosis for these patients was PDAC in three and pancreatitis in two patients. In total, external pathology review was performed in 126 patients (20.4%), leading to the same classification in 103 (81.7%), a higher classification in 20 (15.9%), and a lower classification in three patients (2.3%) (Supplementary Table 4). Next-generation sequencing was used in 20 patients.

Discussion

This was the first nationwide study evaluating the performance of different endoscopy-guided TA techniques in patients with borderline resectable and resectable PDAC. In this post-hoc analysis of two nationwide RCTs, EUS-guided TA had an SFM above 85% for both first and repeat procedures compared with 50% for ERCP-guided brush cytology. The RAS was high for all TA procedures. Misdiagnosis of PDAC occurred in 7%, mostly other periampullary cancers whilst 2% was false positive for malignancy.

The SFM (broad definition) for EUS-guided TA in the current study equals the reference standard of $\geq 85\%$ as proposed by the ASGE/ACG Task Force on Quality in Endoscopy.¹³ In addition, the reference standard for RAS of $\geq 85\%$ was clearly met. For the other endoscopy-guided TA methods, no international reference standard is defined. The modest SFM of 52.7% for ERCP-guided brush cytology and 37.7% for periampullary biopsies confirms that EUS should be preferred in case of suspected PDAC. A brush

or periampullary biopsy, however, is easily performed during ERCP with stent placement and may prevent the need for additional EUS-guided TA. Likewise, pathology review in a pancreas expert center prior to scheduling a second procedure for TA is recommended. Last, based on recent studies, next-generation sequencing and K-RAS mutation analysis may increase the SFM of TA procedures, although this could not be analyzed in the current study due to insufficient data.^{16,17}

In the current analysis, a large difference in SFM of 20% between the strict and broad definition was found. This difference, however, may not be clinically relevant, since the malignancy rate of patients with cytology suspicious for malignancy after EUS-FNA is estimated 88–96%.^{18,19} In the present study, the rate of false positive results was also negligible for suspicious malignant specimens (Table 2). Apparently, even expert pathologists tend to be cautious to give the definite pathological diagnosis of PDAC, given the evident implications of the interpretation of their findings. Nevertheless, the multidisciplinary decision to include these patients as malignant based on suspicious malignant cytology in combination with the imaging, tumor marker values, and the clinical presentation seemed justifiable, preventing the need for additional procedures.

Real-world data on the results of EUS-guided TA including procedures performed in referring centers is limited.^{20–22} A Dutch nationwide retrospective cohort study reported on 1638 consecutive patients who underwent a resection for PDAC (2014–2018), of whom 691 (42.2%) underwent preoperative EUS-guided TA in

Table 1 Patient and tumor characteristics and endoscopy-guided tissue acquisition procedures

	Overall n = 617	Head ^a n = 532	Body/tail ^b n = 85	P-value
A. Patient and tumor characteristics				
Sex				0.870
Male, n (%)	347 (56.2)	298 (56.0)	49 (57.6)	
Female, n (%)	270 (43.8)	234 (44.0)	36 (42.4)	
Age, years (median [IQR])	66.0 [59.0, 72.0]	66.0 [59.0, 72.0]	67.0 [62.0, 73.0]	0.129
Resection performed, n (%)	447 (72.4)	383 (72.0)	64 (75.3)	0.616
Final diagnosis (%)				0.122
PDAC	415 (92.8)	353 (92.2)	62 (96.9)	
Distal cholangiocarcinoma	19 (4.3)	19 (5.0)	0 (0.0)	
Ampullary carcinoma	5 (1.1)	5 (1.3)	0 (0.0)	
pNET	1 (0.2)	1 (0.3)	0 (0.0)	
IPMN (noninvasive)	4 (0.9)	2 (0.5)	2 (3.1)	
Pancreatitis	3 (0.7)	3 (0.8)	0 (0.0)	
Malignant - no resection performed ^c	171	150	21	
B. Endoscopy-guided TA procedures				
EUS-guided TA, n (%)	550 (89.1)	465 (87.4)	85 (100.0)	0.001
ERCP-guided brush cytology, n (%)	188 (30.5)	188 (35.3)	0 (0.0)	<0.001
Ampullary biopsy, n (%)	23 (3.7)	23 (4.3)	0 (0.0)	0.100
Duodenal biopsy, n (%)	28 (4.5)	28 (5.3)	0 (0.0)	0.060
Distal bile duct biopsy, n (%)	15 (2.4)	15 (2.8)	0 (0.0)	0.235
More than 1 procedure, n (%)	196 (31.8)	190 (35.7)	6 (7.1)	<0.001

Abbreviations: EUS, endoscopic ultrasonography; ERCP, endoscopic retrograde cholangiopancreatography; IPMN, intraductal papillary mucinous neoplasm; IQR, interquartile range; PDAC, pancreatic ductal adenocarcinoma; pNET, pancreatic neuroendocrine tumor; TA, tissue acquisition.

^a Pancreatic head/neck/uncinate process ($n = 508$) or periaampullary tumor ($n = 24$).

^b Pancreatic body or tail tumor.

^c Patients who did not undergo a resection ($n = 171$), all had a malignant diagnosis based on clinical and/or radiological follow-up of at least one year.

either an academic or community hospital. This study showed a median SFM (broad definition) of 65%. Although the patients in these studies partly overlap, the SFM in the current study was approximately 20% higher. A possible explanation for this divergence is a difference in patient selection for EUS-guided TA. In the earlier years of the cohorts, patients with a lesion highly suspicious for PDAC on cross-sectional imaging were less likely to undergo EUS-guided TA, since upfront surgery was often considered treatment of choice for these patients. Therefore, EUS-guided TA may have been mainly performed for smaller or unclear lesions in those early years. With more patients participating in the RCTs, EUS-guided TA also became customary for patients with a clear pancreatic lesion in order to obtain a tissue diagnosis as requirement for trial participation. Potentially, this requirement has also motivated the endosonographers to obtain the best possible specimen, the pathologist to commit to a clear diagnosis, and it may have increased the use of external pathology review and next-generation sequencing. This phenomenon is also known as the Hawthorne effect.²³

A comparison of the SFM of EUS-guided TA for pancreas head compared with body/tail tumors showed a significantly better SFM

for body/tail tumors (broad definition only). Other studies have shown conflicting results on this topic.^{24–26} This potential difference may lie in the challenging position of head tumors, whereby a sharp angulation of the needle may be necessary to advance the needle into the tumor. In addition, lesions in the pancreatic body and tail are generally larger at diagnosis compared to pancreatic head or periaampullary tumors. Indeed, a large single-center study by Haba *et al.* reported a lower SFM for smaller tumors,²⁷ but other studies reported no influence of tumor size.^{6,24,25}

The SFM of repeat procedures was relatively high for both repeat EUS (88.2%) and repeat ERCP-guided brush cytology (61.5%). Apparently, it is worthwhile to perform a repeat procedure in patients with a pancreatic lesion who had an initial indeterminate or negative diagnosis. This is consistent with previous studies.^{5–9}

Despite apparent ‘proof’ of PDAC, 32 patients (7.2% of resection cohort) ultimately did not have PDAC. It should be noted that a clear differentiation between PDAC and distal cholangiocarcinoma can even be unclear based on final pathology, since these cancers are not distinguishable based on immunohistochemistry or morphology.²⁸ The challenge of

Table 2 Endoscopic procedures and highest cytological classification of patients with a final diagnosis other than PDAC (n = 32)

	Distal cholangiocarcinoma (n = 19)	Ampullary carcinoma (n = 5)	pNET (n = 1)	IPMN (noninvasive) (n = 4)	Pancreatitis (n = 3)
PROCEDURE	Overall number; (number of b6; b5; b4; b3; b2)				
EUS-guided TA	11 (5; 6; 0; 0; 0)	3 (2; 1; 0; 0; 0)	1 (0; 1; 0; 0; 0)	4 (2 ^a ; 2; 0; 0; 0)	1 (0; 1; 0; 0; 0)
ERCP-guided brush	4 (2; 2; 0; 0; 0)	(2; 2; 0; 0; 0)	1 (0; 1; 0; 0; 0)		
Periampullary biopsy	1 (1; 0; 0; 0; 0)				
Both EUS-guided TA and ERCP-guided brush	1 (1; 0; 0; 0; 0)				1 (0; 0; 0; 1; 0)
Both EUS-guided TA and periampullary biopsy	1 (1; 0; 0; 0; 0)	1 (1; 0; 0; 0; 0)			1 (0; 0; 0; 0; 1 ^b)
Both ERCP-guided brush and periampullary biopsy	1 (1; 0; 0; 0; 0)				

Abbreviations: EUS, endoscopic ultrasonography; ERCP, endoscopic retrograde cholangiopancreatography; TA, tissue acquisition.

^a Two patients with malignant cytological preoperative diagnosis had IPMN with high-grade dysplasia as final postoperative pathology.

^b The classification of pathologic specimen of one patients was revised to benign disease (b2) based on pathology review, which occurred after inclusion and randomization into the trial.

Table 3 Diagnostic performance of endoscopy-guided tissue acquisition procedures

	First EUS-guided TA	Repeat EUS-guided TA	First ERCP-guided brush cytology	Repeat ERCP-guided brush cytology	Other periampullary biopsies
ALL PATIENTS					
SFM (broad definition, b6+b5)	462/542 (85.2%)	60/68 ^a (88.2%)	98/186 (52.7%)	8/13 (61.5%)	23/61 ^a (37.7%)
SFM (strict definition, b6)	352/544 (64.7%)	42/68 ^a (61.8%)	50/186 (26.9%)	1/13 (7.7%)	17/61 ^a (27.9%)
RESECTION COHORT					
SFM (broad definition, b6+b5)	334/392 (85.2%)	43/49 (87.8%)	75/138 (54.3%)	6/9 (66.7%)	10/41 ^a (24.4%)
SFM (strict definition, b6)	250/394 (63.5%)	30/49 (61.2%)	36/138 (26.1%)	1/9 (11.1%)	7/41 ^a (17.1%)
ALL PATIENTS					
RAS	531/550 (96.6%)	71/74 (95.9%)	185/188 (98.4%)	14/14 (100%)	62/66 (93.9%)
Malignant (b6)	354/550 (64.4%)	45/74 (60.8%)	50/188 (26.6%)	1/14 (7.1%)	17/66 (25.8%)
Suspicious for malignancy (b5)	115/550 (20.9%)	20/74 (27.0%)	48/188 (25.5%)	7/14 (50.0%)	6/66 (9.1%)
Atypical (b3)	34/550 (6.2%)	4/74 (5.4%)	34/188 (18.1%)	4/14 (28.6%)	8/66 (12.1%)
Negative for malignancy (b4+b2)	28/550 (5.1%)	2/74 (2.7%)	53/188 (28.2%)	2/14 (14.3%)	31/66 (47.0%)

Sensitivity for malignancy was calculated by dividing True Positives by the sum of True Positives and False Negatives. Rate of adequate sampling was calculated by dividing the number of adequate samples with sufficient material for pathological examination by the total number of samples. Abbreviations: EUS, endoscopic ultrasonography; ERCP, endoscopic retrograde cholangiopancreatography; RAS, rate of adequate sampling; SFM, sensitivity for malignancy; TA, tissue acquisition.

^a The highest classified diagnosis (i.e., b1 - b6) was included for patients who had more than one periampullary biopsy.

correctly diagnosing patients with a pancreatic or periampullary tumor has previously been reported by a large multicenter retrospective cohort study of 1244 patients undergoing pancreatoduodenectomy for a pancreatic or periampullary tumor.²⁹ In this study, 16% of patients had a misdiagnosis. This higher percentage of misdiagnoses compared to the current study is most likely because the preoperative diagnosis was based on imaging only in 25% of the patients in their study and patients with an unclear tumor origin were likely not included in the RCTs.

Some studies have suggested differences in anatomy, echogenicity, and fat-to-parenchyma ratio between males and females, which may impact the diagnostic performance of endoscopy-guided TA procedures.^{30,31} In the current study, no difference

based on sex was found for any of the endoscopy-guided TA procedures.

Strengths of our study include its prospective nature, the large number of patients included in the two largest RCTs on neoadjuvant treatment for PDAC globally, the assessment of SFM and RAS for all endoscopy-guided TA procedures including repeat procedures, and the nationwide coverage with diagnostic work-up in both referring and referral centers. However, some limitations should also be considered. First, inherent to the inclusion criteria for the RCTs, this study only included patients with a preoperative confirmation of PDAC. This may have led to an overestimation of the SFM and RAS, since patients with false negative TA attempts were not included. However, a study on the generalizability of the results of the PREOPANC trial showed that

only 4% of potentially eligible patients were not included because of failed endoscopic-TA attempts.³² In addition, since the required reference group of patients without PDAC diagnosis was excluded from the trials, the specificity, positive predictive value, negative predictive value, and accuracy could not be calculated. However, the influence of confirmation bias is limited by our selection criteria, as opposed to analyses focusing on these other statistical outcomes. Second, the data were derived from existing prospectively maintained databases which did not include specifications of the endoscopic procedures. As a consequence, we were not able to differentiate between cytological (FNA) and histological (FNB) specimens, lesion size, needle size, and suction techniques. The newest generation FNB needles may increase the accuracy and decrease the number of needle passes needed.^{3,33} Third, despite mandatory tissue acquisition prior to inclusion in the RCTs, 7% of patients had final diagnoses other than pancreatic cancer. Fourth, no data on adverse events were available. However, tissue acquisition during an endoscopic procedure is associated with low rate of adverse events.³⁴

In conclusion, EUS-guided TA showed the highest yield in patients with borderline resectable and resectable PDAC, with excellent RAS and adequate SFM approximating the ASGE/AGT reference standard. This study confirmed that EUS-guided TA should be used as preferred endoscopic-TA procedure for patients with suspected PDAC and this procedure should be repeated in case of an initial inconclusive diagnosis.

Source of funding

This study is supported by the Dutch Cancer Society (KWF) (UVA 2012–5696 and 10955) and by ZonMw (843004108). No funding agency was involved in the design of the study, or the collection, analysis, and interpretation of data. The authors are solely responsible for the content of the study and do not necessarily represent the viewpoint of the Dutch Cancer Society or ZonMw.

Acknowledgements

We would like to thank Annette Gijsbers-Bruggink from PALGA, and Carlien Theeuwes, Loes van den Niewenhof-Biesheuvel, Anja Stam, Eelke Lemmens, Petra Roza, Marina Kleinlugtenbeld-Jansen, Graziella Kallenberg-Lantrua, Jisce Puik, Els Wink, Trudy Rapmund, Debbie Arens, Marion van der Kolk, Linda Garms, Marie-Louise van Groesen, Nicol Pepels-Aarts, Eva Versteijne, Anneke Brandsma, Jacintha Berensen, Linda van Zutphen, Carolien Haazer, and Leonie van de Water for their help in the patient selection. Moreover, we would like to thank all gastroenterologists, pathologists, surgeons, medical oncologists, radiation oncologists, and supporting professionals contributing to the PREOPANC and PREOPANC-2 trials. Last, we thank all patients participating in both trials.

Author contributions

Conception and design: All Authors.

Drafting the article or revising it critically for important intellectual content: All Authors.

Analysis and interpretation of the data: QJ, RQ, LvD, CvE.
Final approval of the version to be published: All Authors.

Conflict of interest

None to declare.

References

1. Cazacu IM, Luzuriaga Chavez AA, Saftoiu A, Vilmann P, Bhutani MS. (2018) A quarter century of EUS-FNA: progress, milestones, and future directions. *Endosc Ultrasound* 7:141–160.
2. Committee AsoP, Eloubeidi MA, Decker GA, Chandrasekhara V, Chathadi KV, Early DS *et al.* (2016) The role of endoscopy in the evaluation and management of patients with solid pancreatic neoplasia. *Gastrointest Endosc* 83:17–28.
3. van Riet PA, Erler NS, Bruno MJ, Cahen DL. (2021 Apr) Comparison of fine-needle aspiration and fine-needle biopsy devices for endoscopic ultrasound-guided sampling of solid lesions: a systemic review and meta-analysis. *Endoscopy* 53:411–423.
4. Hewitt MJ, McPhail MJ, Possamai L, Dhar A, Vlavianos P, Monahan KJ. (2012) EUS-guided FNA for diagnosis of solid pancreatic neoplasms: a meta-analysis. *Gastrointest Endosc* 75:319–331.
5. Tadic M, Kujundzic M, Stoos-Veic T, Kaic G, Vukelic-Markovic M. (2008) Role of repeated endoscopic ultrasound-guided fine needle aspiration in small solid pancreatic masses with previous indeterminate and negative cytological findings. *Dig Dis* 26:377–382.
6. Suzuki R, Lee JH, Krishna SG, Ramireddy S, Qiao W, Weston B *et al.* (2013) Repeat endoscopic ultrasound-guided fine needle aspiration for solid pancreatic lesions at a tertiary referral center will alter the initial inconclusive result. *J Gastrointest Liver Dis* 22:183–187.
7. Téllez-Ávila FI, Martínez-Lozano JA, Rosales-Salinas A, Bernal-Méndez AR, Guerrero-Velásquez C, Ramírez-Luna M *et al.* (2016) Repeat endoscopic ultrasound fine needle aspiration after a first negative procedure is useful in pancreatic lesions. *Endosc Ultrasound* 5:258–262.
8. Mitchell RA, Stanger D, Shuster C, Telford J, Lam E, Enns R. (2016) Repeat endoscopic ultrasound-guided fine-needle aspiration in patients with suspected pancreatic cancer: diagnostic yield and associated change in access to appropriate care. *Chin J Gastroenterol Hepatol* 20167678403.
9. Eloubeidi MA, Varadarajulu S, Desai S, Wilcox CM. (2008) Value of repeat endoscopic ultrasound-guided fine needle aspiration for suspected pancreatic cancer. *J Gastroenterol Hepatol* 23:567–570.
10. Versteijne E, Suker M, Groothuis K, Akkermans-Vogelaar JM, Besselink MG, Bonsing BA *et al.* (2020) Preoperative chemoradiotherapy versus immediate surgery for resectable and borderline resectable pancreatic cancer: results of the Dutch randomized phase III PREOPANC trial. *J Clin Oncol* 38:1763–1773.
11. Janssen QP, van Dam JL, Bonsing BA, Bos H, Bosscha KP, Coene P *et al.* (2021) Total neoadjuvant FOLFIRINOX versus neoadjuvant gemcitabine-based chemoradiotherapy and adjuvant gemcitabine for resectable and borderline resectable pancreatic cancer (PREOPANC-2 trial): study protocol for a nationwide multicenter randomized controlled trial. *BMC Cancer* 21:300.
12. Jacobson BC, Chak A, Hoffman B, Baron TH, Cohen J, Deal SE *et al.* (2006) Quality indicators for endoscopic ultrasonography. *Gastrointest Endosc* 63(4 Suppl):S35–S38.
13. Wani S, Wallace MB, Cohen J, Pike IM, Adler DG, Kochman ML *et al.* (2015) Quality indicators for EUS. *Gastrointest Endosc* 81:67–80.

14. Casparie M, Tiebosch AT, Burger G, Blauwgeers H, van de Pol A, van Krieken JH *et al.* (2007) Pathology databanking and biobanking in The Netherlands, a central role for PALGA, the nationwide histopathology and cytopathology data network and archive. *Cell Oncol* 29:19–24.
15. Pitman MB, Centeno BA, Ali SZ, Genevay M, Stelow E, Mino-Kenudson M *et al.* (2014) Standardized terminology and nomenclature for pancreatobiliary cytology: the Papanicolaou Society of Cytopathology guidelines. *Diagn Cytopathol* 42:338–350.
16. Sibinga Mulder BG, Mieog JSD, Farina Sarasqueta A, Handgraaf HJ, Vasen HFA, Swijnenburg RJ *et al.* (2018) Diagnostic value of targeted next-generation sequencing in patients with suspected pancreatic or periampullary cancer. *J Clin Pathol* 71:246–252.
17. Fuccio L, Hassan C, Laterza L, Correale L, Pagano N, Bocus P *et al.* (2013) The role of K-ras gene mutation analysis in EUS-guided FNA cytology specimens for the differential diagnosis of pancreatic solid masses: a meta-analysis of prospective studies. *Gastrointest Endosc* 78:596–608.
18. Layfield LJ, Schmidt RL, Hirschowitz SL, Olson MT, Ali SZ, Dodd LL. (2014) Significance of the diagnostic categories "atypical" and "suspicious for malignancy" in the cytologic diagnosis of solid pancreatic masses. *Diagn Cytopathol* 42:292–296.
19. Virk RK, Gamez R, Mehrotra S, Atieh M, Barkan GA, Wojcik EM *et al.* (2017) Variation of cytopathologists' use of the indeterminate diagnostic categories "atypical" and "suspicious for malignancy" in the cytologic diagnosis of solid pancreatic lesions on endoscopic ultrasound-guided fine-needle aspirates. *Diagn Cytopathol* 45:3–13.
20. Savides TJ, Donohue M, Hunt G, Al-Haddad M, Aslanian H, Ben-Menachem T *et al.* (2007) EUS-guided FNA diagnostic yield of malignancy in solid pancreatic masses: a benchmark for quality performance measurement. *Gastrointest Endosc* 66:277–282.
21. James PD, Hegagi M, Antonova L, Tinmouth J, Heitman SJ, Simone C *et al.* (2017) Regional differences in use of endoscopic ultrasonography in Ontario: a population-based retrospective cohort study. *CMAJ Open* 5:E437–E443.
22. Quispel R, van Driel L, Honkoop P, Hadithi M, Anten MP, Smedts F *et al.* (2019) Collaboration of community hospital endosonographers improves diagnostic yield of endoscopic ultrasonography guided tissue acquisition of solid pancreatic lesions. *Endosc Int Open* 7:E800–E807.
23. McCambridge J, Witton J, Elbourne DR. (2014) Systematic review of the Hawthorne effect: new concepts are needed to study research participation effects. *J Clin Epidemiol* 67:267–277.
24. Uehara H, Ikezawa K, Kawada N, Fukutake N, Katayama K, Takakura R *et al.* (2011) Diagnostic accuracy of endoscopic ultrasound-guided fine needle aspiration for suspected pancreatic malignancy in relation to the size of lesions. *J Gastroenterol Hepatol* 26:1256–1261.
25. Malak M, Masuda D, Ogura T, Imoto A, Abdelaal UM, Sabet EA *et al.* (2016) Yield of endoscopic ultrasound-guided fine needle aspiration and endoscopic retrograde cholangiopancreatography for solid pancreatic neoplasms. *Scand J Gastroenterol* 51:360–367.
26. Ushijima T, Okabe Y, Ishida Y, Sugiyama G, Sasaki Y, Kuraoka K *et al.* (2014) Evaluation of endoscopic cytological diagnosis of unresectable pancreatic cancer prior to and after the introduction of endoscopic ultrasound-guided fine-needle aspiration. *Mol Clin Oncol* 2:599–603.
27. Haba S, Yamao K, Bhatia V, Mizuno N, Hara K, Hijioka S *et al.* (2013) Diagnostic ability and factors affecting accuracy of endoscopic ultrasound-guided fine needle aspiration for pancreatic solid lesions: Japanese large single center experience. *J Gastroenterol* 48:973–981.
28. Schmuck RB, de Carvalho-Fischer CV, Neumann C, Pratschke J, Bahra M. (2016) Distal bile duct carcinomas and pancreatic ductal adenocarcinomas: postulating a common tumor entity. *Cancer Med* 5: 88–99.
29. van Roessel S, Soer EC, Daamen LA, van Dalen D, Fariña Sarasqueta A, Stommel MWJ *et al.* (2021 Oct) Preoperative misdiagnosis of pancreatic and periampullary cancer in patients undergoing pancreatoduodenectomy: a multicentre retrospective cohort study. *Eur J Surg Oncol* 47: 2525–2532.
30. Wang M, Gorelick F, Bhargava A. (2021) Sex differences in the exocrine pancreas and associated diseases. *Cell Mol Gastroenterol Hepatol* 12: 427–441.
31. Saisho Y, Butler AE, Meier JJ, Monchamp T, Allen-Auerbach M, Rizza RA *et al.* (2007) Pancreas volumes in humans from birth to age one hundred taking into account sex, obesity, and presence of type-2 diabetes. *Clin Anat* 20:933–942.
32. Versteijne E, Suker M, Groen JV, Besselink MG, Bonsing BA, Bosscha K *et al.* (2022 May 1) External validity of the multicenter randomized PREOPANC trial on neoadjuvant chemoradiotherapy in pancreatic cancer: outcome of eligible but non-randomized patients. *Ann Surg* 275:972–978.
33. Chen YI, Chatterjee A, Berger R, Kanber Y, Wyse J, Lam E *et al.* (2022) Endoscopic ultrasound (EUS)-guided fine needle biopsy alone vs. EUS-guided fine needle aspiration with rapid onsite evaluation in pancreatic lesions: a multicenter randomized trial. *Endoscopy* 54:4–12.
34. Polkowski M, Larghi A, Weynand B, Boustiere C, Giovannini M, Pujol B *et al.* (2012) Learning, techniques, and complications of endoscopic ultrasound (EUS)-guided sampling in gastroenterology: European Society of Gastrointestinal Endoscopy (ESGE) Technical Guideline. *Endoscopy* 44:190–206.

Appendix A. Supplementary data

Supplementary data to this article can be found online at <https://doi.org/10.1016/j.hpb.2023.04.018>.